

Masse addominali: cosa ci dice la radiologia e quando l'ecografia non basta?



Giliola Spattini
DVM, PhD, DECVDI

Objectives

- The mass effect is an essential factor in defining the origin of a mass in radiology
- Sometimes different modalities are essential to define the origin of a large abdominal mass



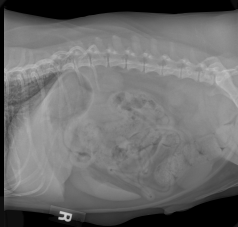Abdominal mass: radiology or ultrasound?

Radiology

General overview

Easy to define the location and the interaction with other abdominal organs

If effusion present only visible the mass effect



Ultrasound

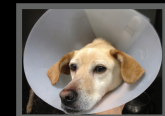
Focal spot

More detailed morphology

More difficult to locate

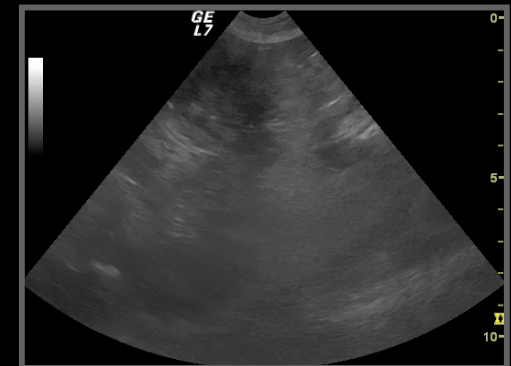
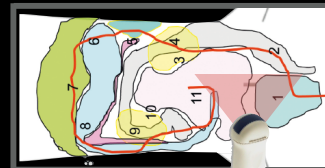
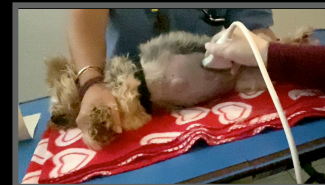
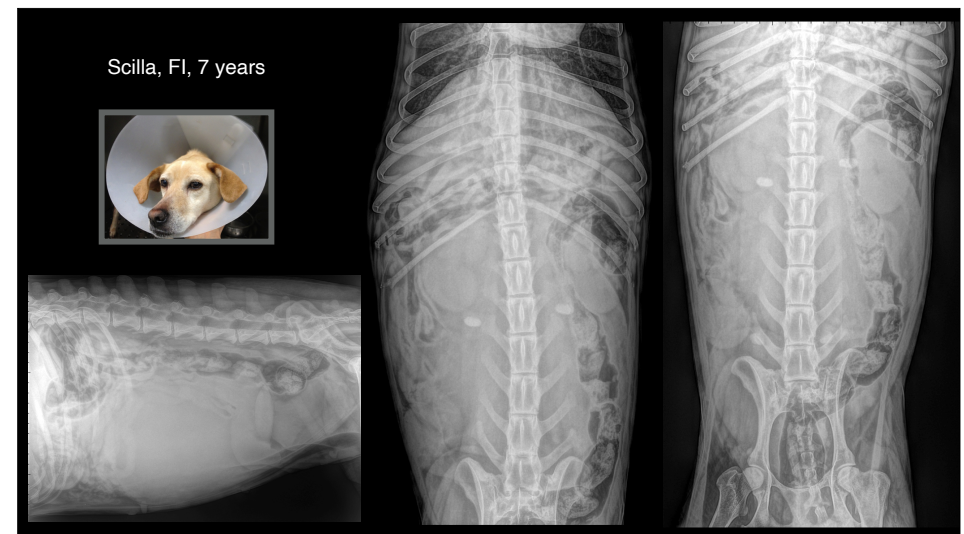
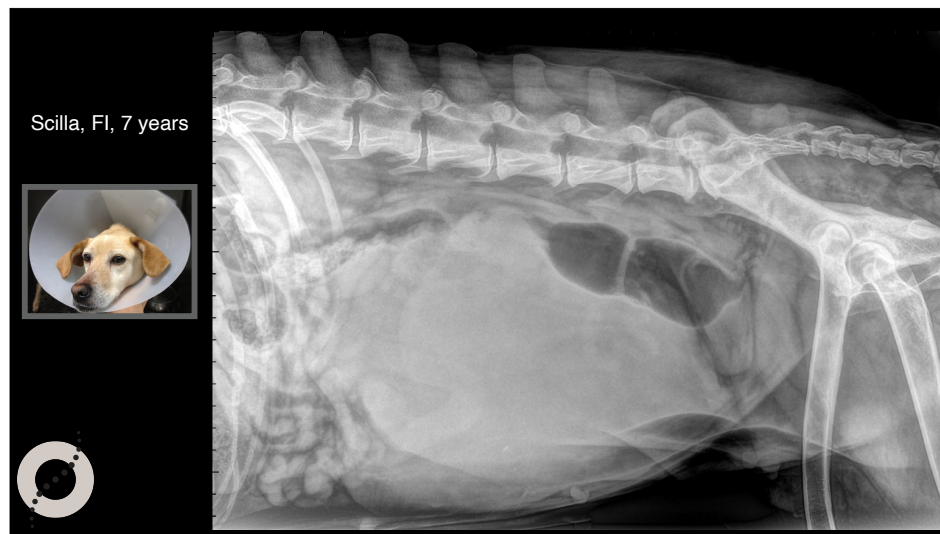
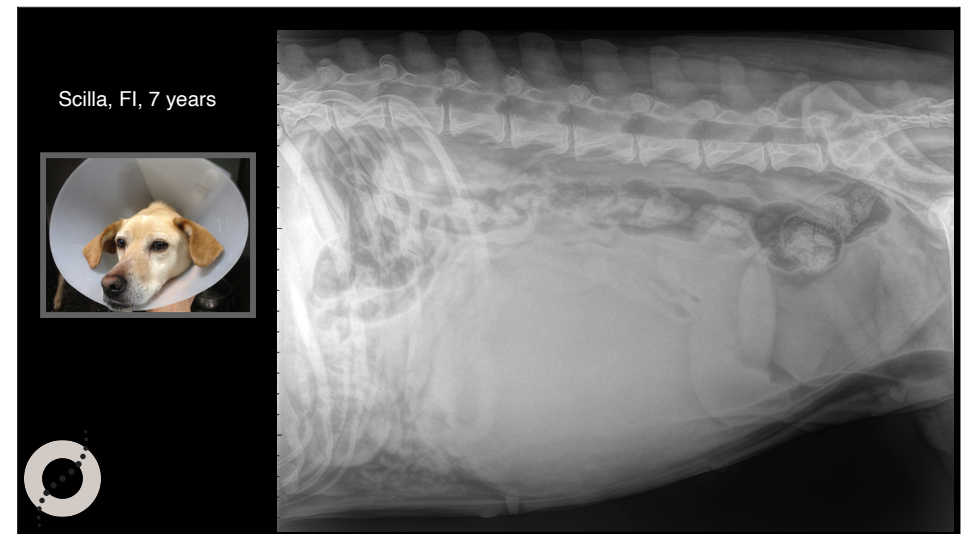
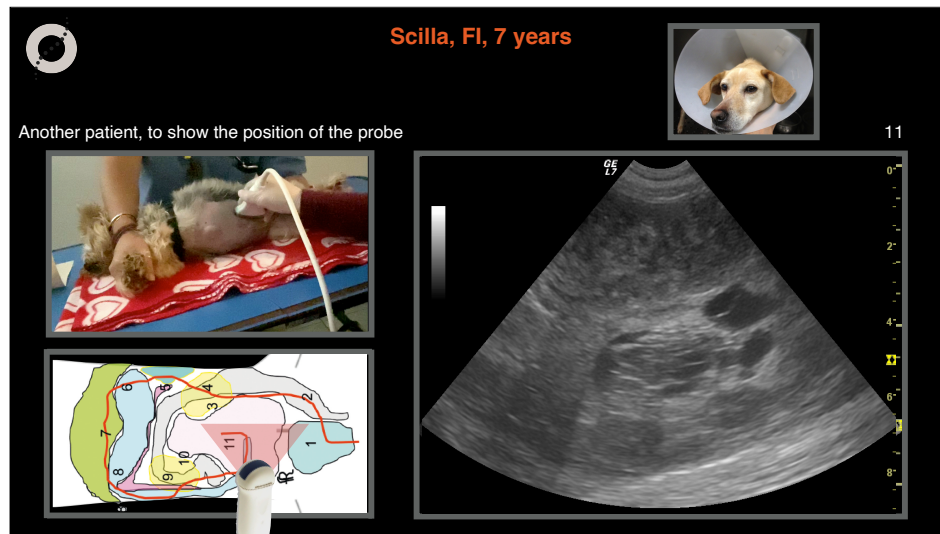
Scilla, FI, 7 years



1-11

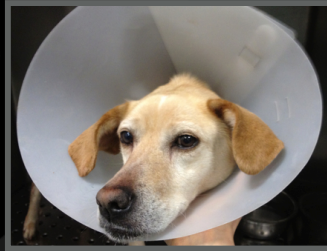Another patient, to show the position of the probe





Scilla, Mongrel, FI, 7 years

- Nobody's dog
- Progressive abdominal distension last two months
- Bloody vaginal discharge since last week



Scilla, Mongrel, FI, 7 years

Radiographic diagnoses:

- Space occupying uterine mass
- Possible associated piometra

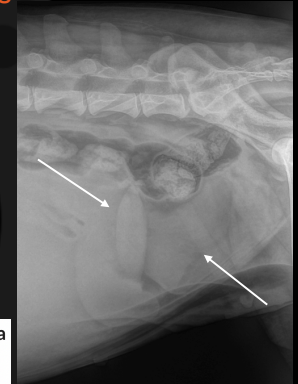
Conclusions:

- Surgery

Co-existing monophasic teratoma and uterine adenocarcinoma in a female dog

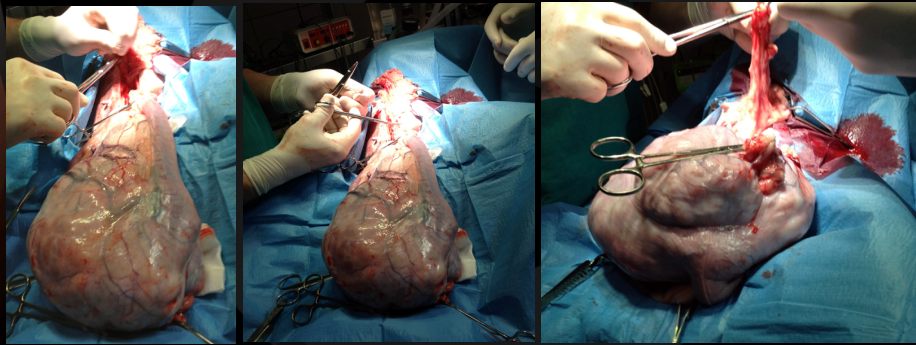
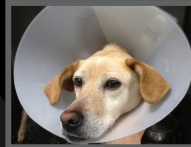
Reprod Dom Anim. 2019;54:1044–1049

Maria dos Anjos Pires¹ | José Carlos Catarino² | Hugo Vilhena^{1,3,4} | Susana Faim⁵ |
Tiago Neves⁵ | Andreia Freire⁵ | Fernanda Seixas¹ | Leonor Orge^{1,6} |
Rita Payan-Carreira^{1,7}



Scilla, Mongrel, FI, 7 years

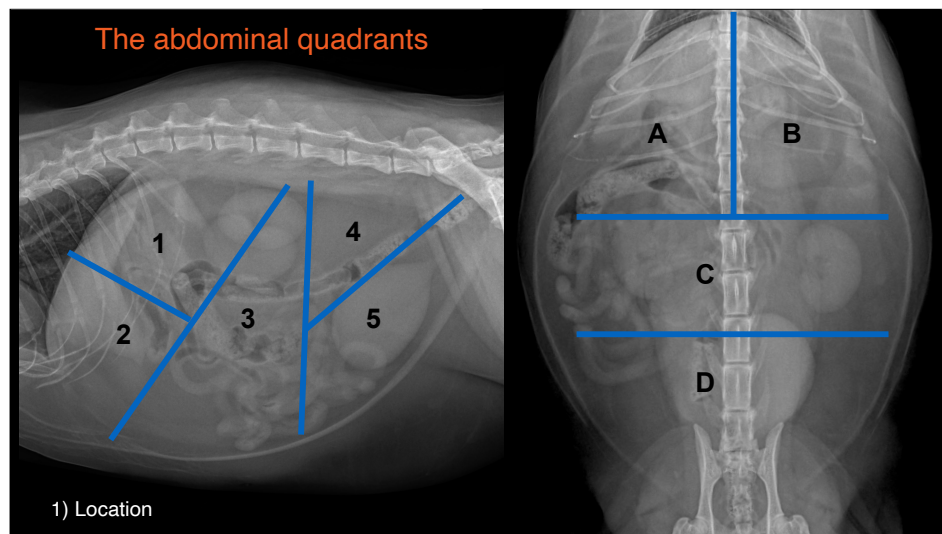
Histology report: uterine fibroma



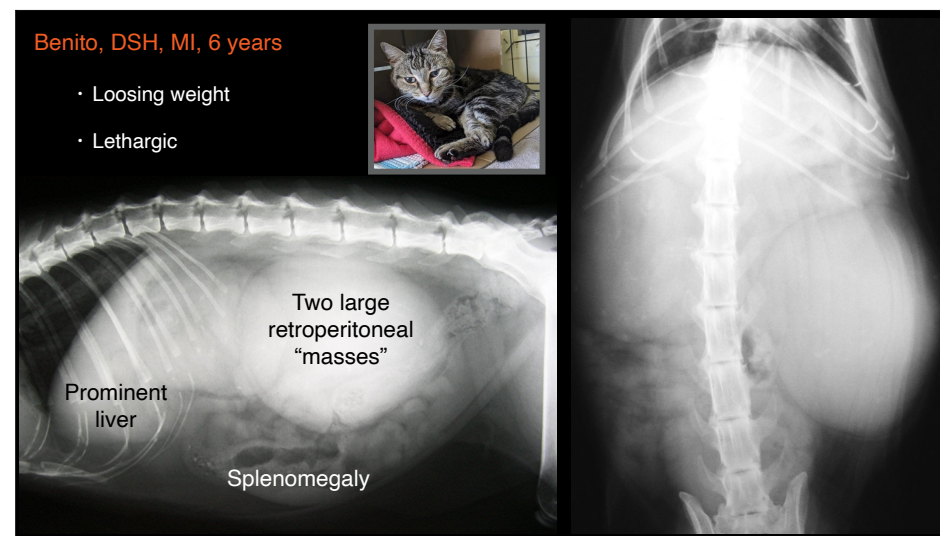
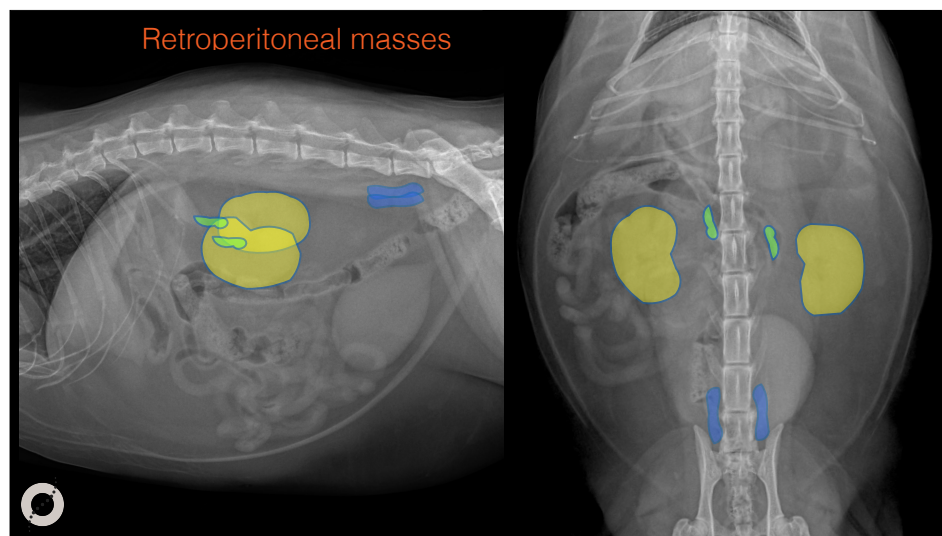
Characteristics used to define an abdominal mass on radiology

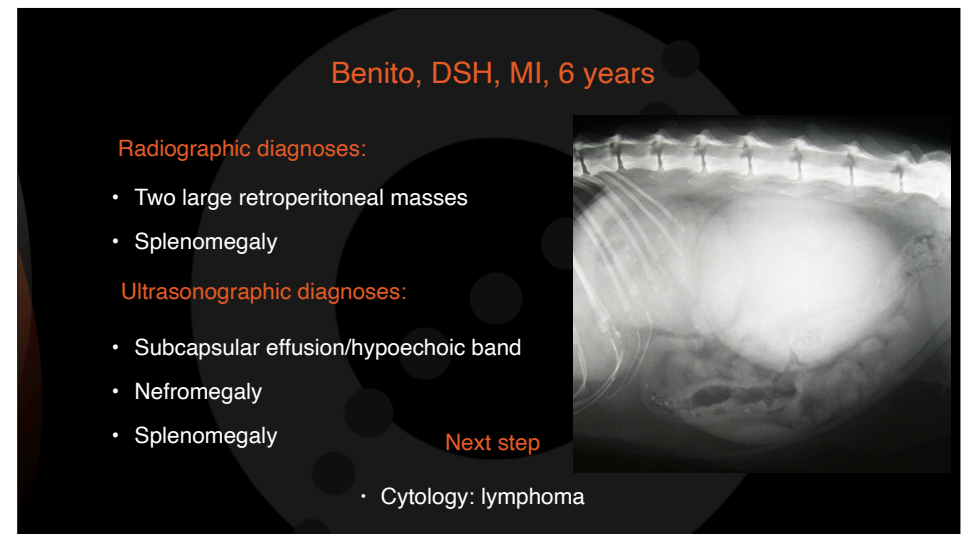
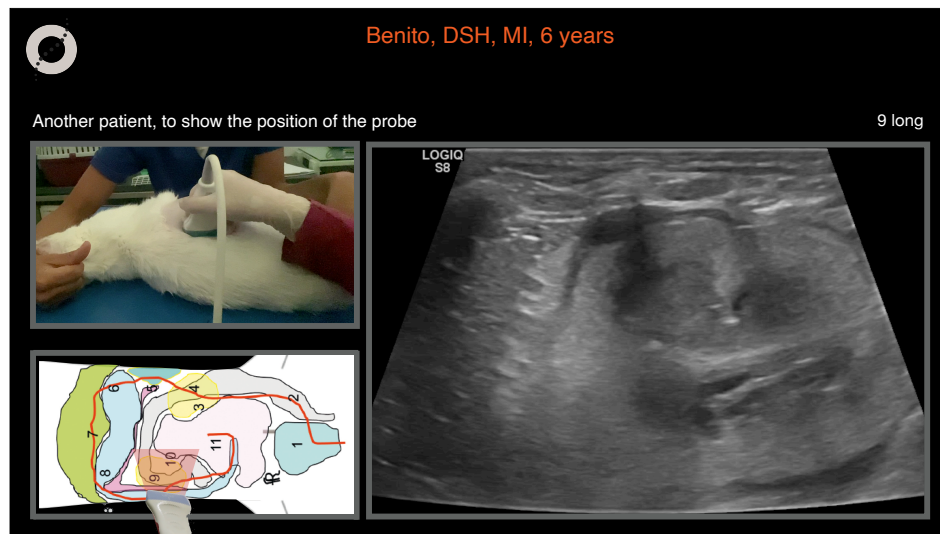
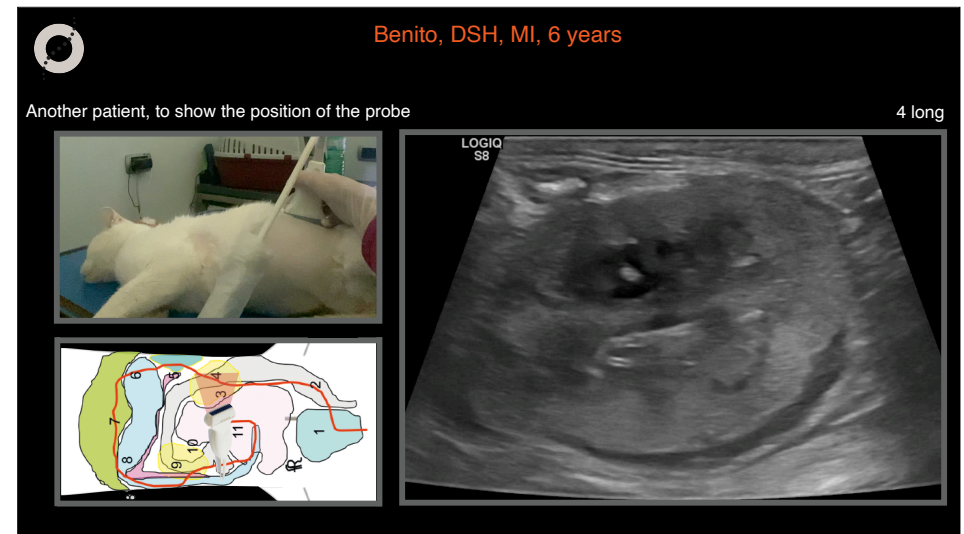
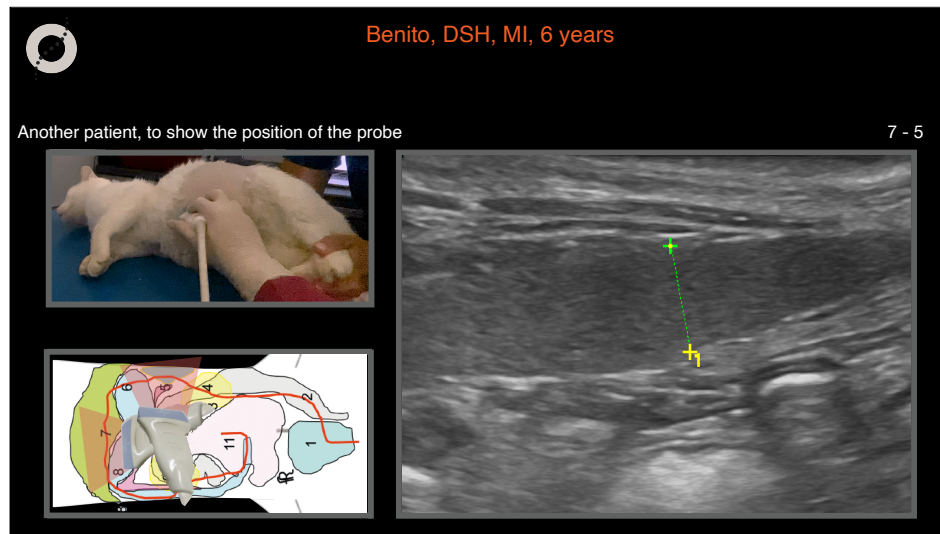
- Location
- Opacity
- Mass effect / dislocation
- Mass continuation





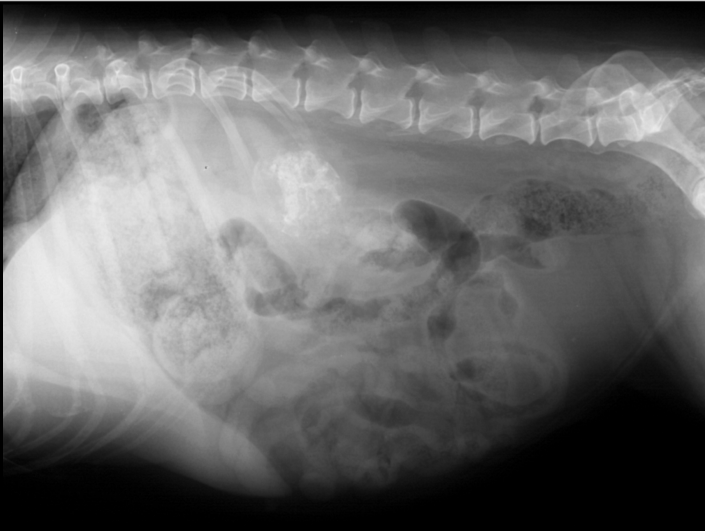AREA	ORGANS
1A	LIVER AND GB PYLORUS DUODENUM PANCREAS
1B	LIVER STOMACH PANCREAS HEAD OF THE SPLEEN
2A	LIVER AND GB STOMACH PANCREAS
2B	LIVER STOMACH PANCREAS SPLENIC BODY
3C	KIDNEYS, ADRENALS SPLEEN, LYMPH NODES UTERUS, OVARY, RETAINED TESTICLE GI TRACT
4D	URETERS ILIAC LYMPH NODES
5D	COLON, URINARY BLADDER UTERUS, PROSTATE RETAINED TESTICLE



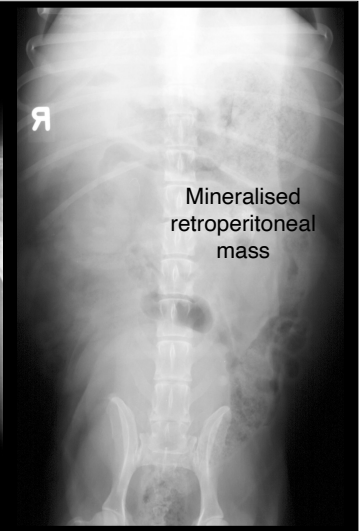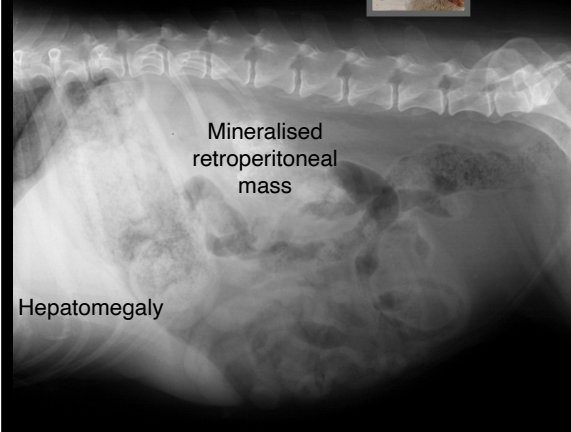


Lilly, Mongrel
FS, 12 years

- PU/PD
- Extreme weakness
- Diarrhoea



Lilly, FS, 12 years

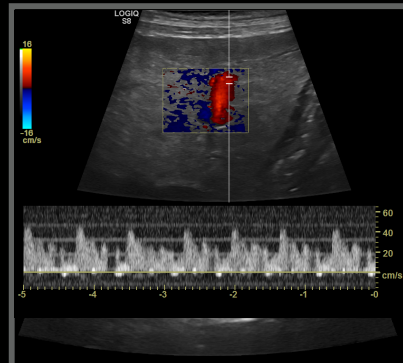
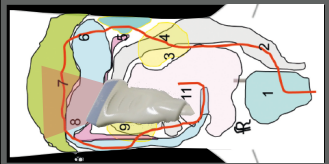
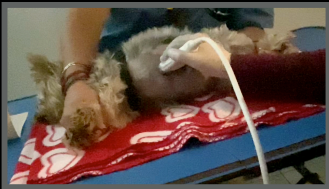

Lilly, FS, 12 years



Another patient, to show the position of the probe

6-7-8

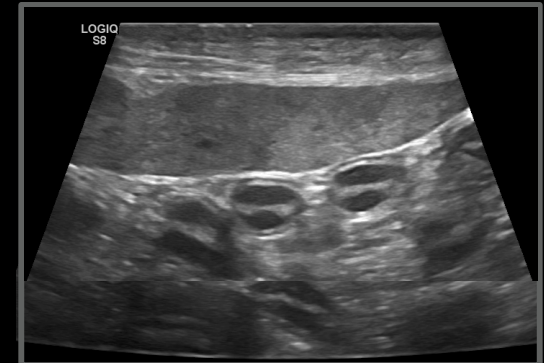
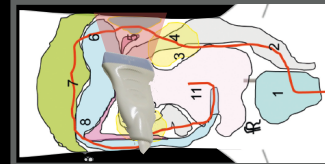
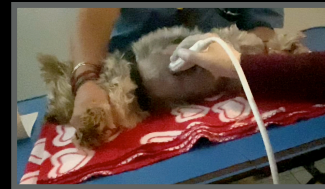

Lilly, FS, 12 years



Another patient, to show the position of the probe

6-5

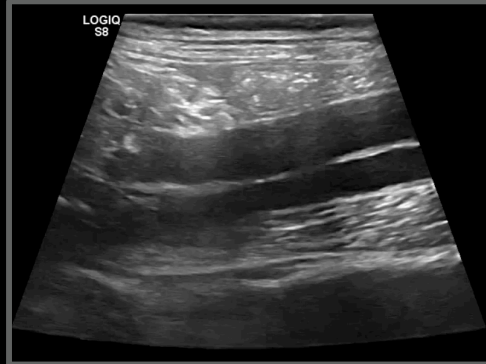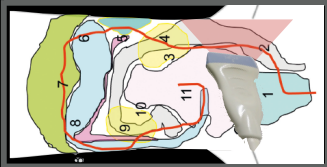

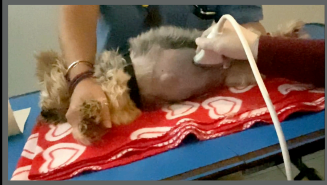


Lilly, FS, 12 years

Another patient, to show the position of the probe

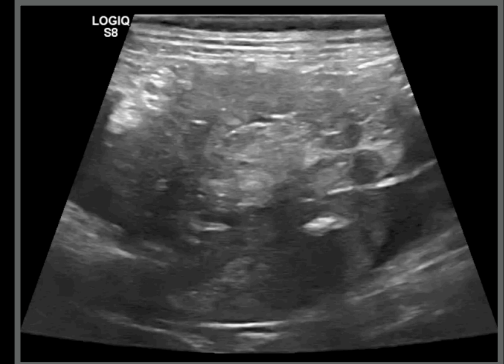
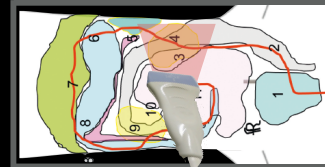
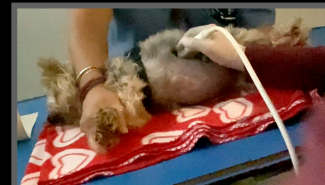2



Lilly, FS, 12 years

Another patient, to show the position of the probe

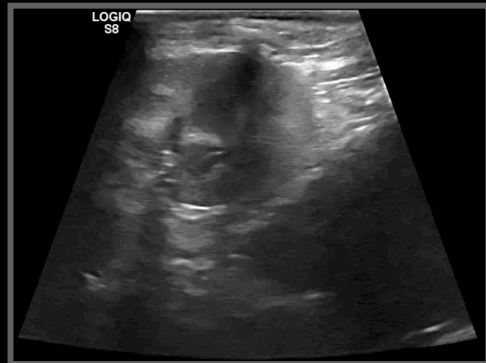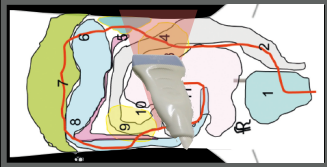
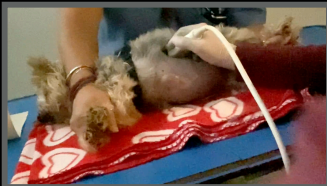3



Lilly, FS, 12 years

Another patient, to show the position of the probe

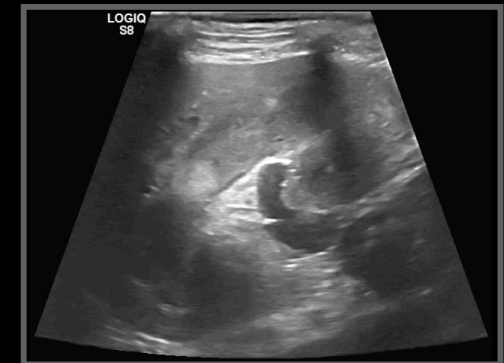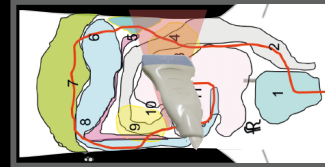
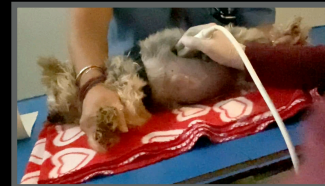3-4



Lilly, FS, 12 years

Another patient, to show the position of the probe

4

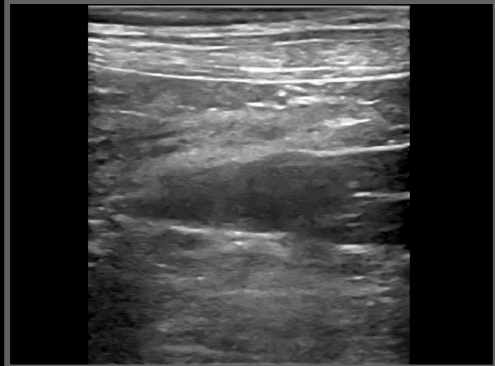
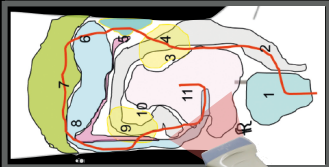
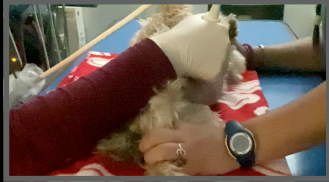



Lilly, FS, 12 years

Another patient, to show the position of the probe

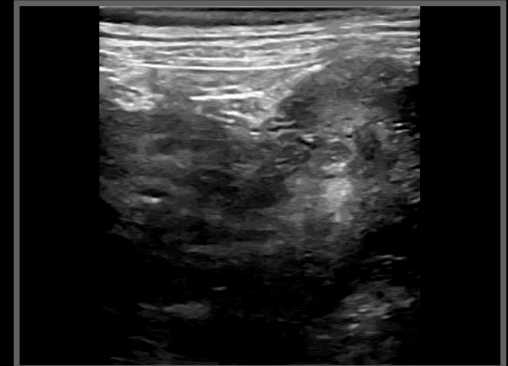
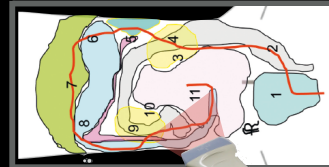
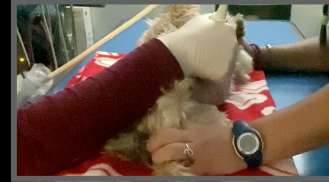12



Lilly, FS, 12 years

Another patient, to show the position of the probe

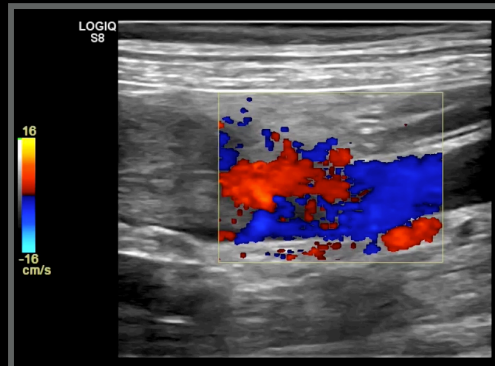
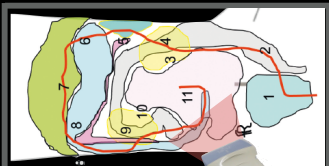
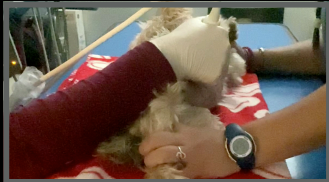9-12



Lilly, FS, 12 years

Another patient, to show the position of the probe

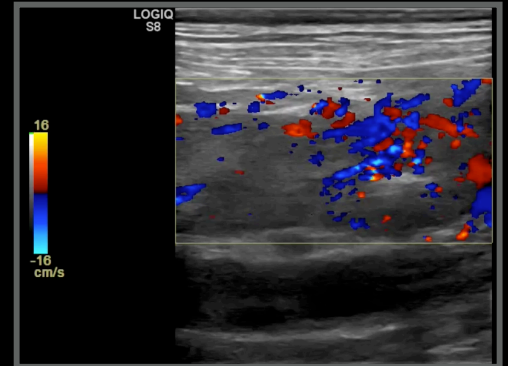
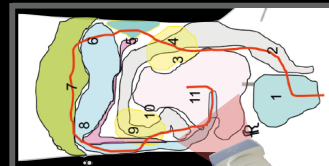
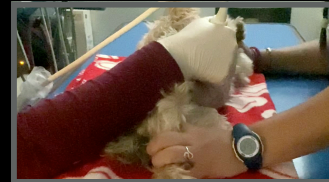9-12



Lilly, FS, 12 years

Another patient, to show the position of the probe

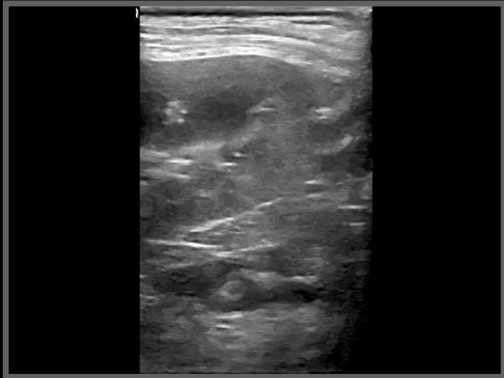
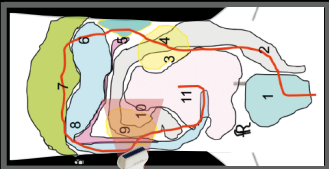

9-12



Lilly, FS, 12 years

Another patient, to show the position of the probe


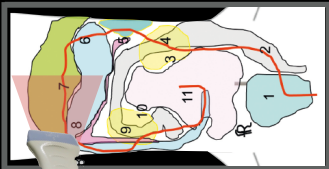

9

Lilly, FS, 12 years

Another patient, to show the position of the probe

8'

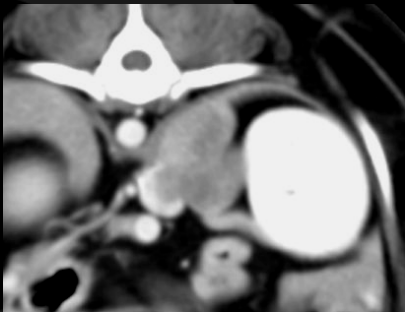
Lilly, Mongrel, FS, 12 years

Ultrasonographic diagnoses:

- Mass invading the caudal vena cava
- Extending to the left renal vein
- Likely arising from the left adrenal gland
- Suspected severely atrophied right adrenal gland


Conclusions:

- US suspicion confirmed on CT
- Adenocarcinoma diagnoses on FNA



Characteristics used to define an abdominal mass

- Location
- Opacity
- Mass effect / dislocation
- Mass continuation

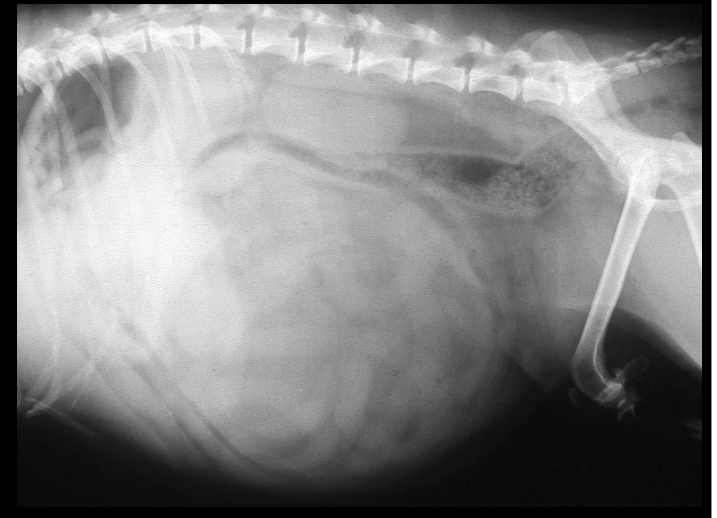



Luna, Mongrel, FS, 11 years

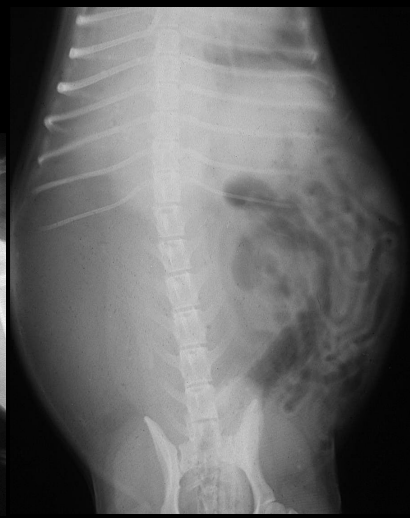
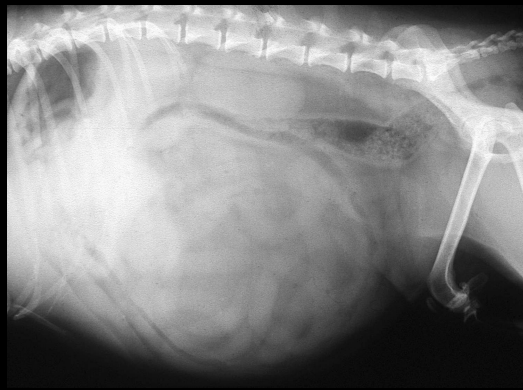
- Progressively over distended abdomen
- Otherwise healthy



Luna, FS,
11 years

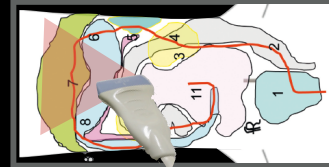
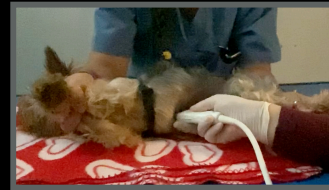

Luna, FS,
11 years

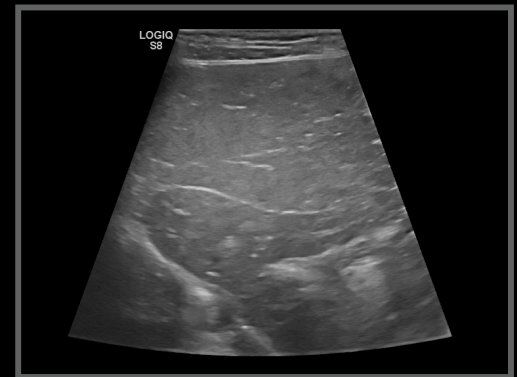

Luna, FS, 11 years

Another patient, to show the position of the probe



6-7 long

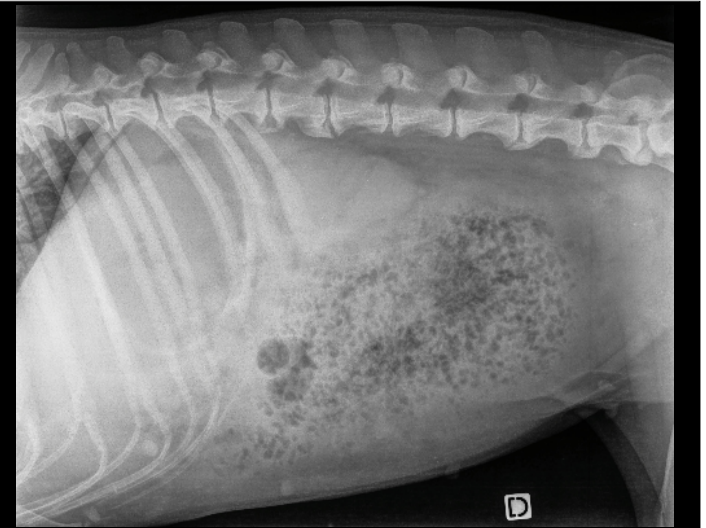



Lu, Malinois, FI, 5 year

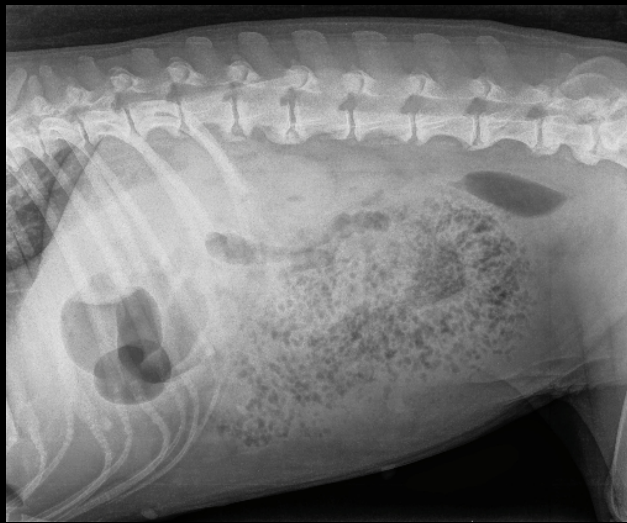

• Acute abdomen



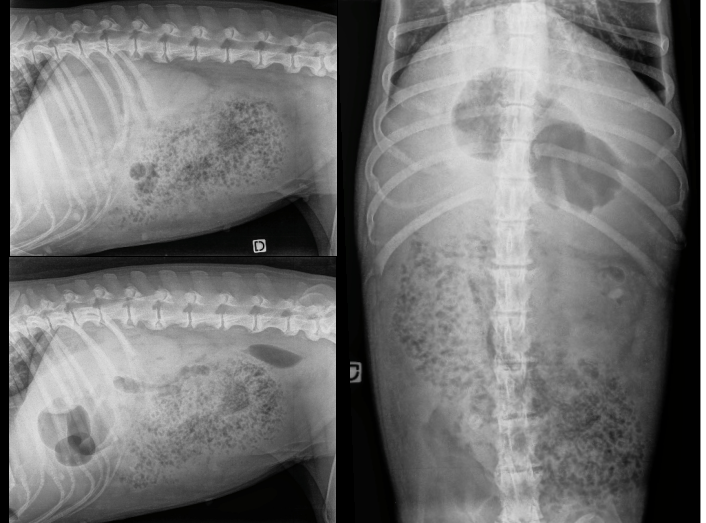
Lu, FI, 5 years

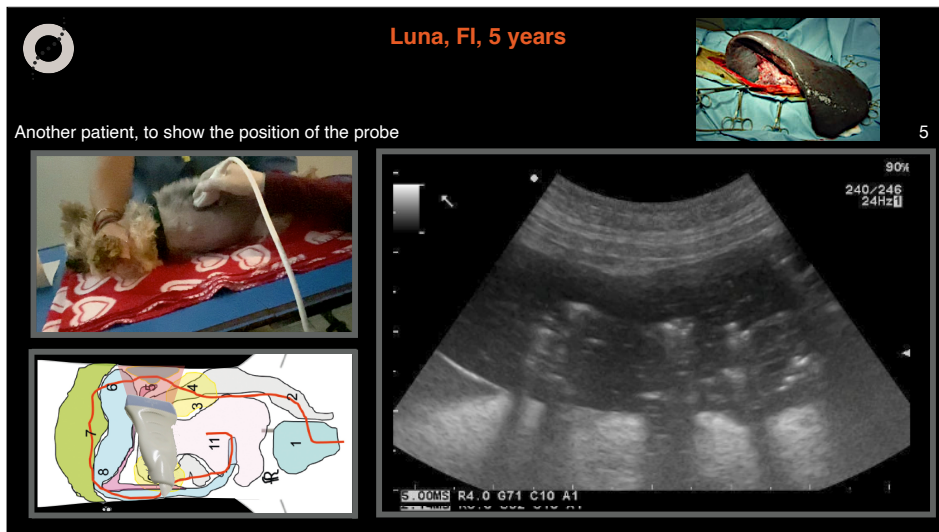


Lu, FI, 5 years



Lu, FI, 5 years





Primary splenic torsion in dogs: 102 cases (1992–2014)

JAVMA • Vol 248 • No. 6 • March 15, 2016

Whitney DeGroot DVM

Michelle A. Giuffrida VMD

Jacob Rubin DVM

Jeffrey J. Runge DVM

Amy Zide BS

Philipp D. Mayhew BVMS

William T. N. Culp VMD

Kelley Thieman Mankin DVM, MS

Pierre M. Amsellem DVM, MS

Brandi Petrukovich DVM

P. Brendon Ringwood DVM, MS

J. Brad Case DVM, MS

Ameet Singh DVM, DVSc

RESULTS

93 of the 102 (91.2%) dogs survived to hospital discharge. German Shepherd Dogs (24/102 [23.5%]), Great Danes (15/102 [14.7%]), and English Bulldogs (12/102 [11.8%]) accounted for 50% of cases. Risk factors significantly associated with death prior to hospital discharge included septic peritonitis at initial examination (OR, 32.4; 95% confidence interval [CI], 2.1 to 502.0), intraoperative hemorrhage (OR, 22.6; 95% CI, 1.8 to 289.8), and postoperative development of respiratory distress (OR, 35.7; 95% CI, 2.7 to 466.0). Histopathologic evidence of splenic neoplasia was not found in any case.

CONCLUSIONS AND CLINICAL RELEVANCE

Results suggested that the prognosis for dogs undergoing splenectomy because of PST was favorable. Several risk factors for death prior to discharge were identified, including preexisting septic peritonitis, intraoperative hemorrhage, and postoperative development of respiratory distress. (*J Am Vet Med Assoc* 2016;248:661–668)

Characteristics used to define an abdominal mass

- Location
- Opacity
- Mass effect / dislocation
- Mass continuation




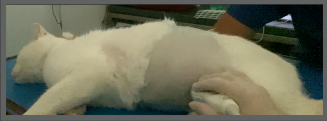
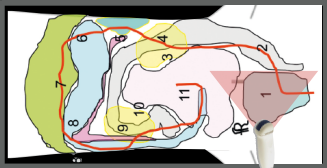
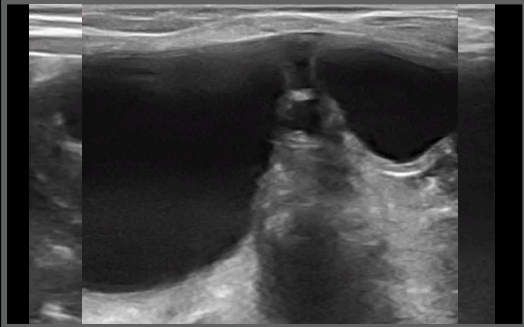
Newton, DSH, FI, 16 years

- Distended abdomen
- One episode of vomiting
- Less active
- Indoor only



Newton, FI, 16 years

Another patient, to show the position of the probe

1


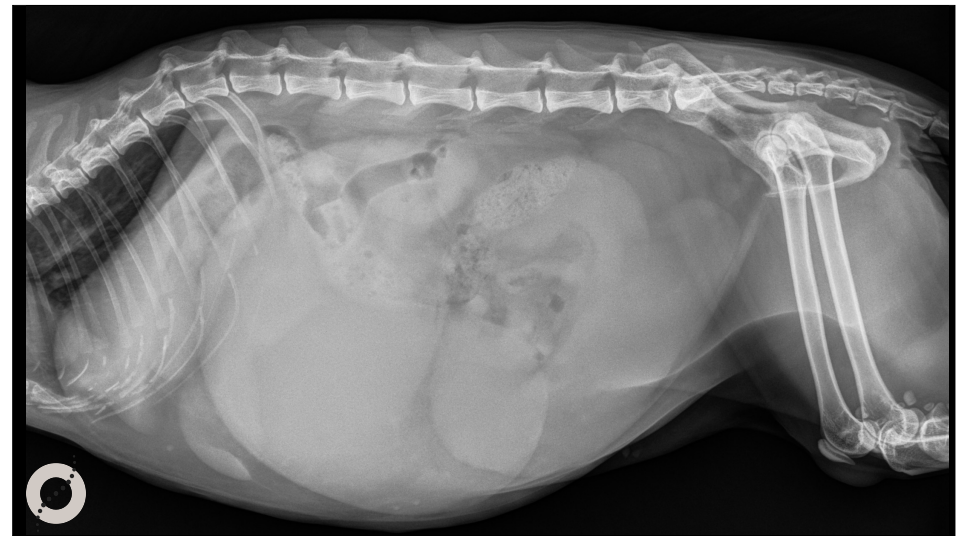
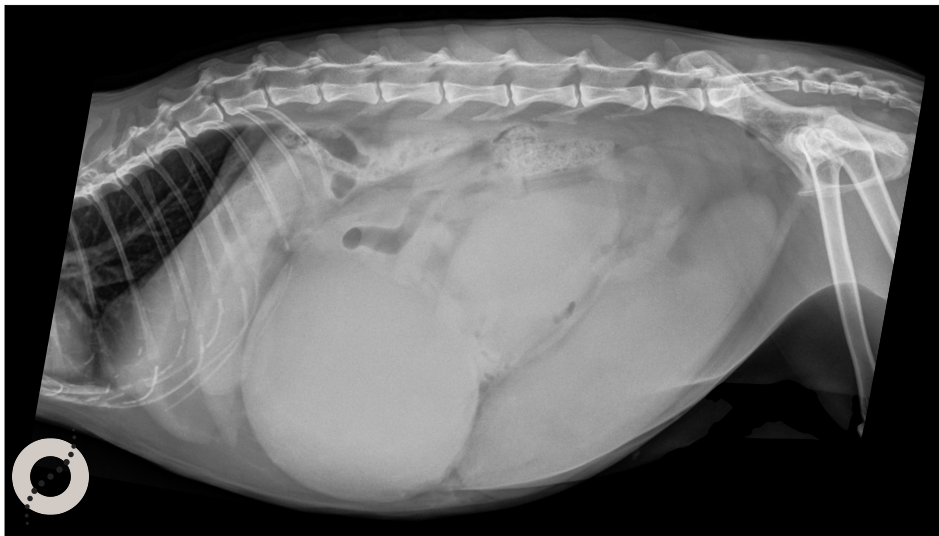
Newton, DSH, FI, 16 years

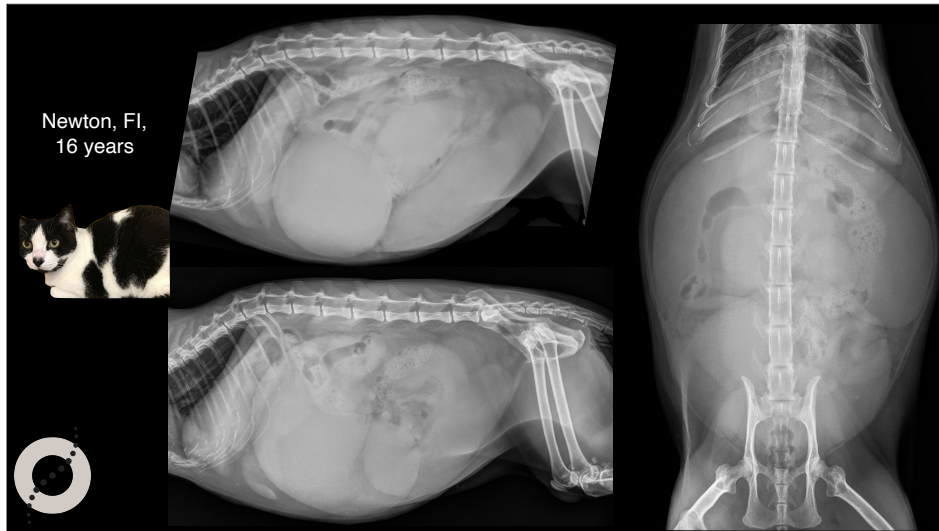
Ultrasonographic diagnoses:

- “Double” urinary bladder, only one has a neck region
- Cystic structure inside a fluid filled structure?
- The kidneys were unremarkable for the age
- Uterus not seen, could be involved?

Conclusions:

- ???
- Pyometra/hydrometra?



Uterine torsion

- Pregnancy predisposing factor
- One overdistended by fluid horn
- Focal eccentric "lump"

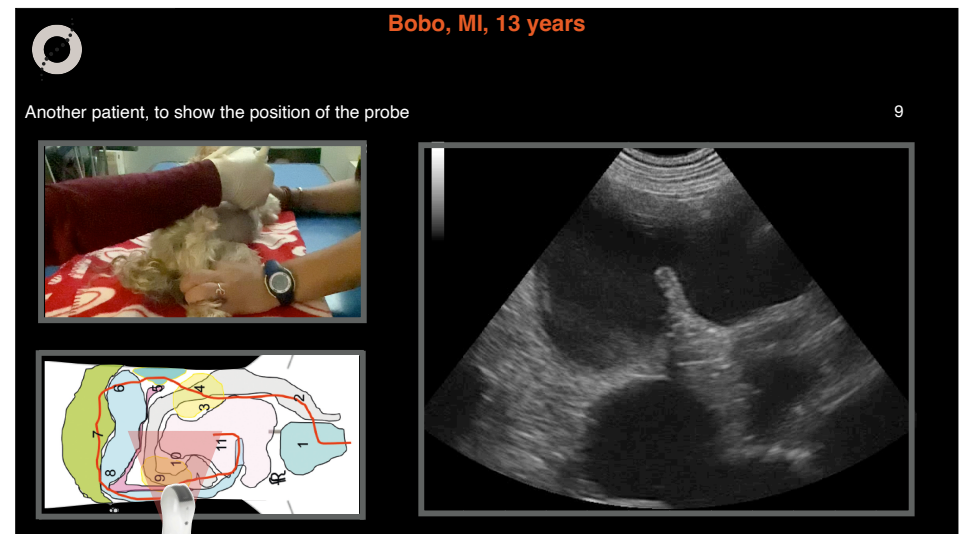
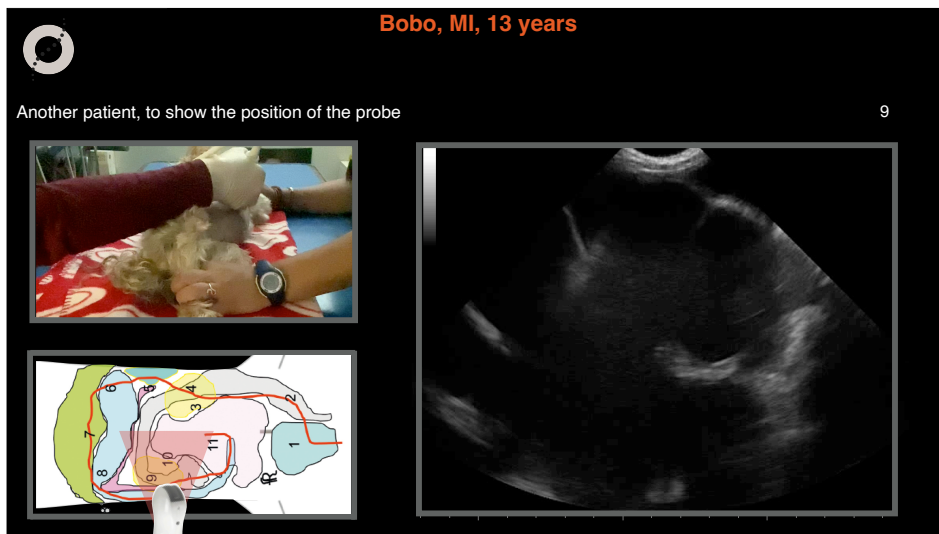
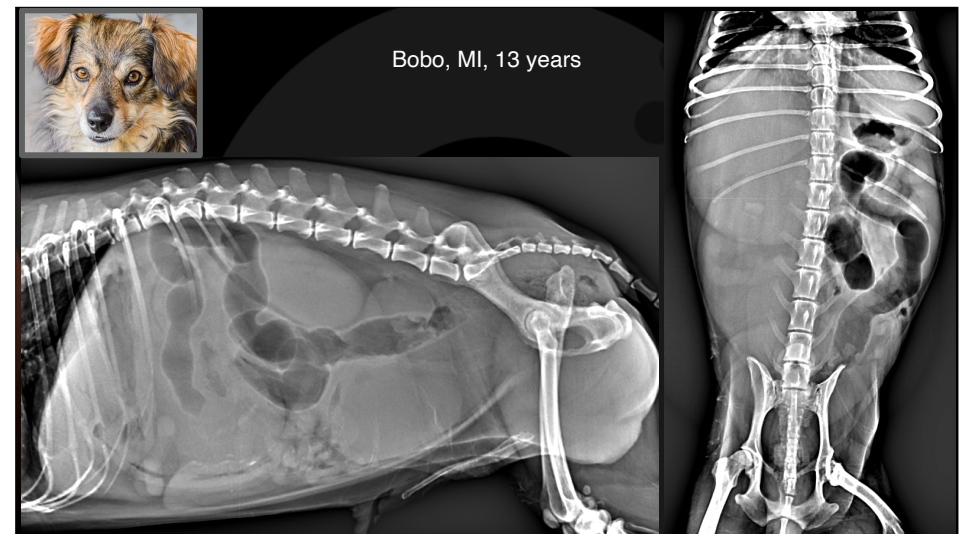
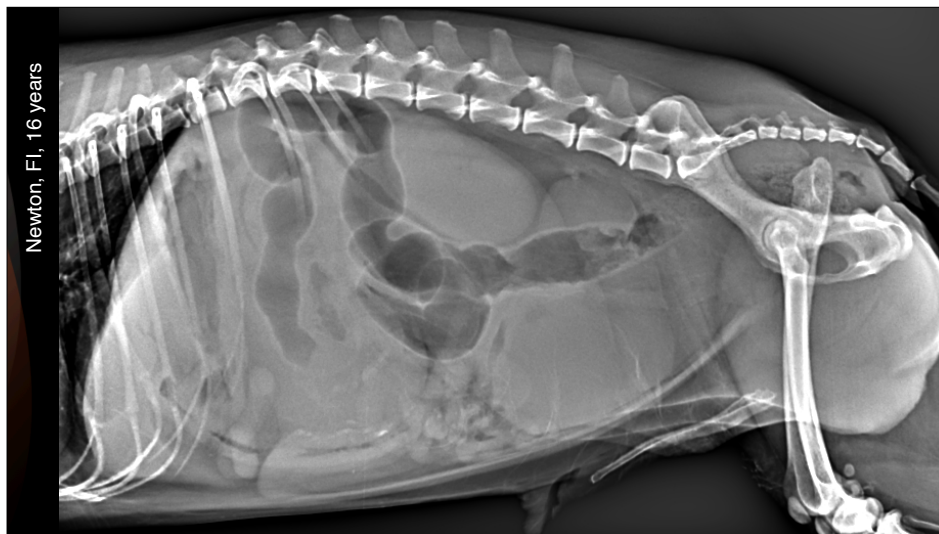[Bilateral segmental aplasia with unilateral uterine horn torsion in a Pomeranian bitch.](#)
Nakamura K, Yamasaki M, Osaki T, Ohta H, Sasaki N, Aoshima K, Kimura T, Takiguchi M.
J Am Anim Hosp Assoc. 2012 Sep-Oct;48(5):327-30. doi: 10.5326/JAAHA-MS-6771. Epub 2012 Jul 27.
PMID: 22843825

Characteristics used to define an abdominal mass

- Location
- Opacity
- Mass effect / dislocation
- Mass continuation

Bobo, Mongrel, MI, 13 years

- Progressively distended abdomen for the last weeks
- Acute abdomen

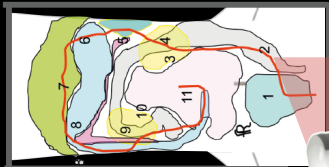
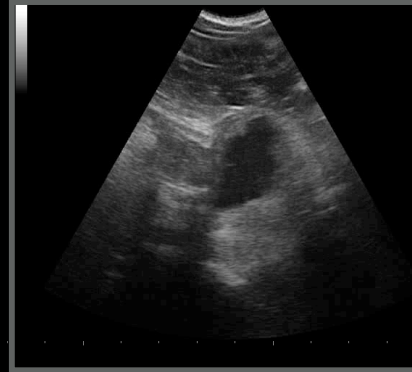
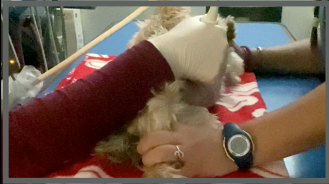



Bobo, MI, 13 years

Another patient, to show the position of the probe

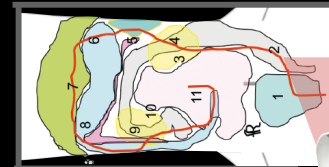
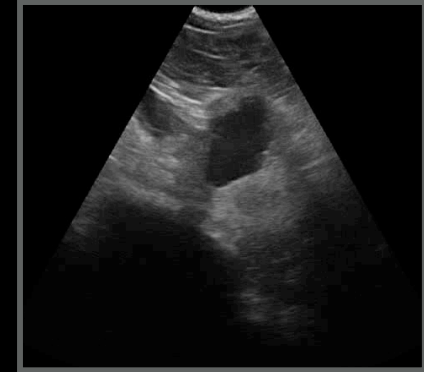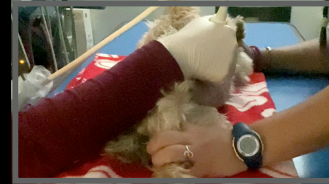1



Bobo, MI, 13 years

Another patient, to show the position of the probe

1



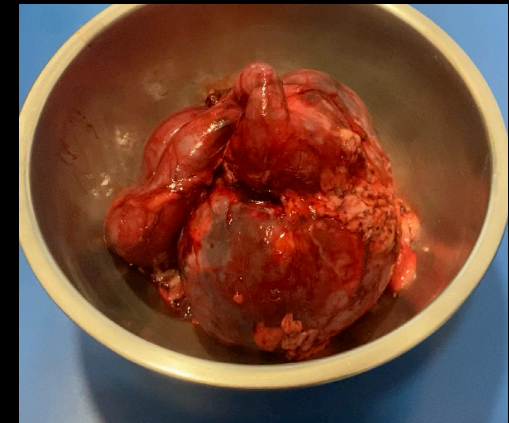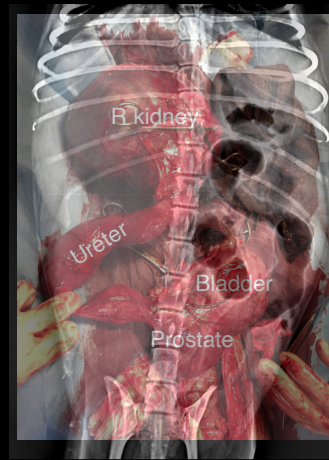
Bobo, Mongrel, MI, 13 years


Ultrasonographic diagnoses:

- Severe right sided ureter
- Severely over distended right ureter
- Prostatic termination of the right ureter



Bobo, Mongrel, MI, 13 years






Conclusions

Radiology is usually a good first step to
Identify an abdominal mass

Ultrasound better for staging and sampling

CT most of the time needed for planning
surgery and the best treatment plan



Thank you



Diagnostic Mindset
www.diagnosticmindset.com