

Masse addominali: cosa ci dice la radiologia e quando l'ecografia non basta?



Giliola Spattini  
DVM, PhD, DECVDI

## Objectives

- The mass effect is an essential factor in defining the origin of a mass in radiology
- Sometimes different modalities are essential to define the origin of a large abdominal mass



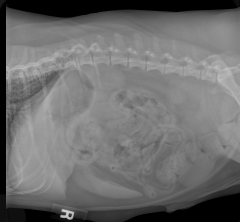## Abdominal mass: radiology or ultrasound?

### Radiology

General overview

Easy to define the location and the interaction with other abdominal organs

If effusion present only visible the mass effect



### Ultrasound

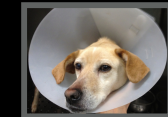
Focal spot

More detailed morphology

More difficult to locate

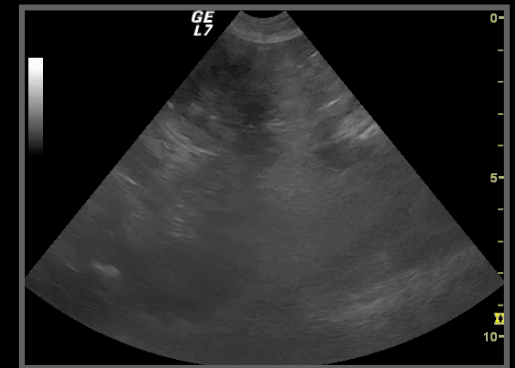
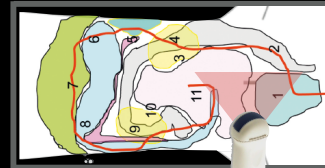
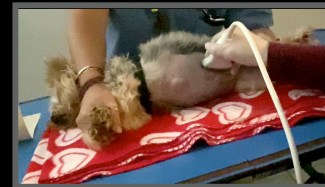

## Scilla, FI, 7 years



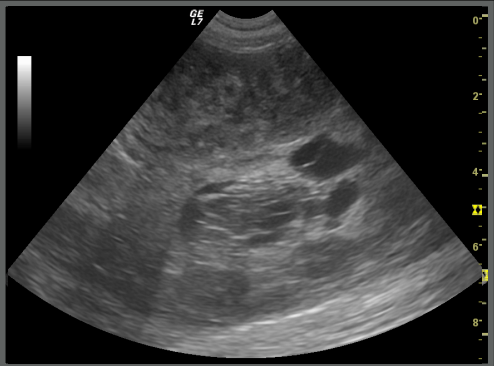
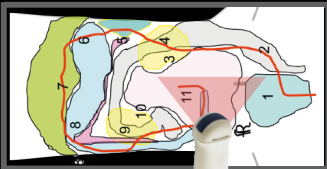

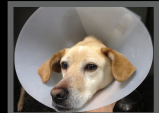
1-11

Another patient, to show the position of the probe






Scilla, FI, 7 years

Another patient, to show the position of the probe









11

Scilla, FI, 7 years






Scilla, FI, 7 years

Scilla, FI, 7 years



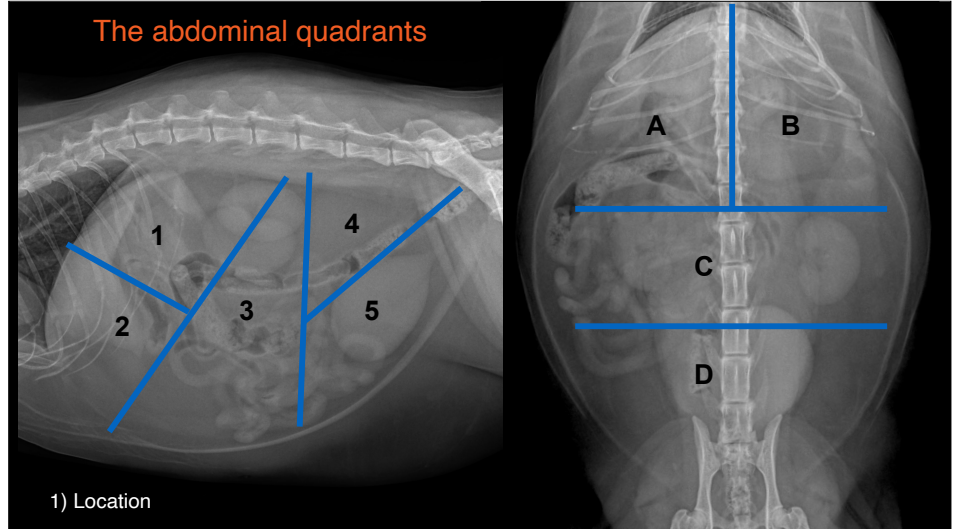



## Characteristics used to define an abdominal mass on radiology

- Location
- Opacity
- Mass effect / dislocation
- Mass continuation



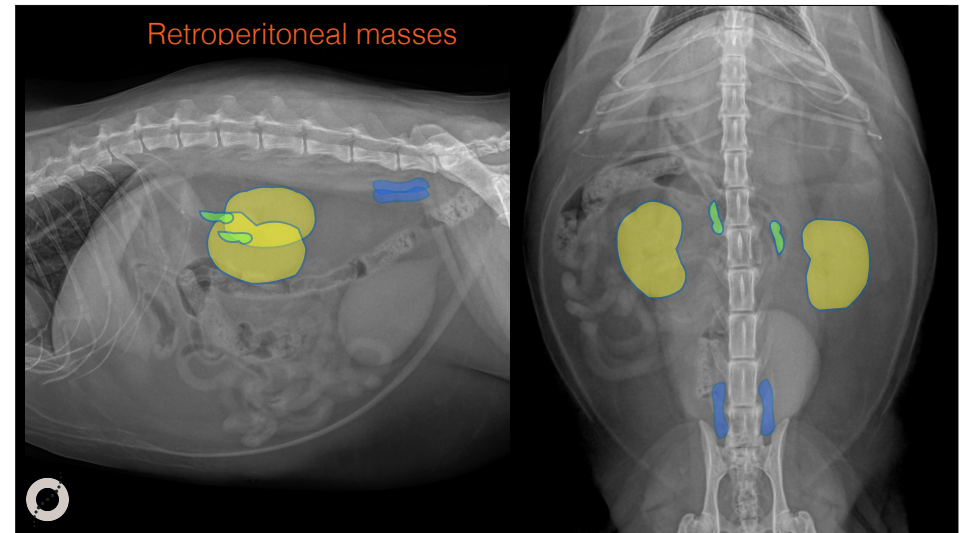
## The abdominal quadrants



1) Location

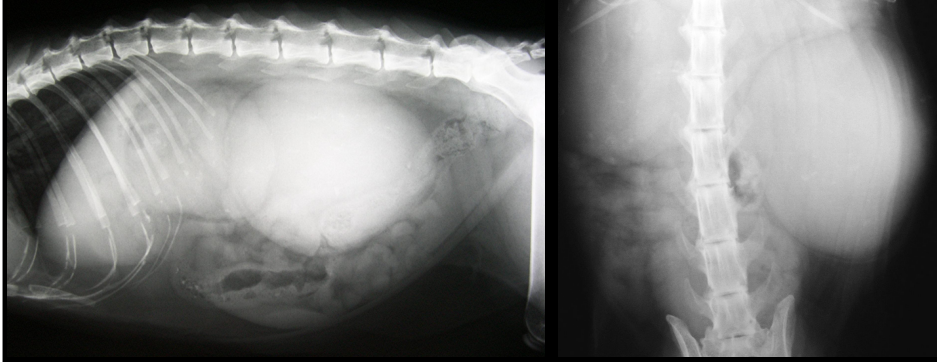

AREA	ORGANS
1A	LIVER AND GB PYLORUS DUODENUM PANCREAS
1B	LIVER STOMACH PANCREAS HEAD OF THE SPLEEN
2A	LIVER AND GB STOMACH PANCREAS
2B	LIVER STOMACH PANCREAS SPLENIC BODY
3C	KIDNEYS, ADRENALS SPLEEN, LYMPH NODES UTERUS, OVARY, RETAINED TESTICLE
4D	GI TRACT URETERS ILIAC LYMPH NODES
5D	COLON, URINARY BLADDER UTERUS, PROSTATE RETAINED TESTICLE

## Retroperitoneal masses



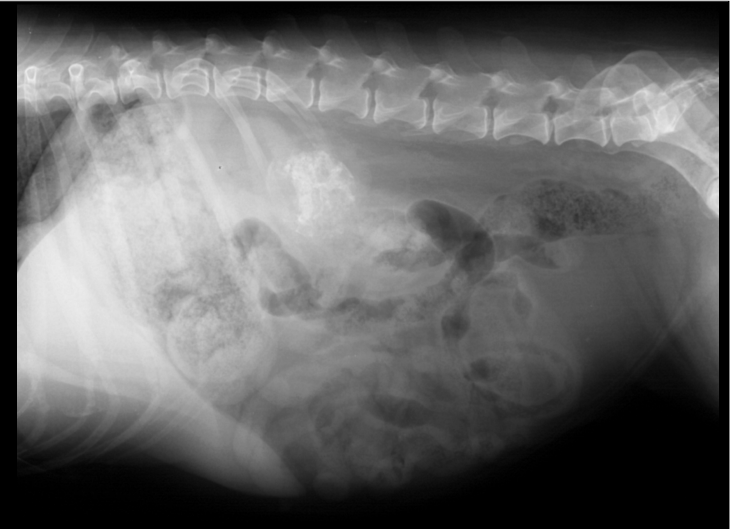Benito, DSH, MI, 6 years

- Loosing weight
- Lethargic

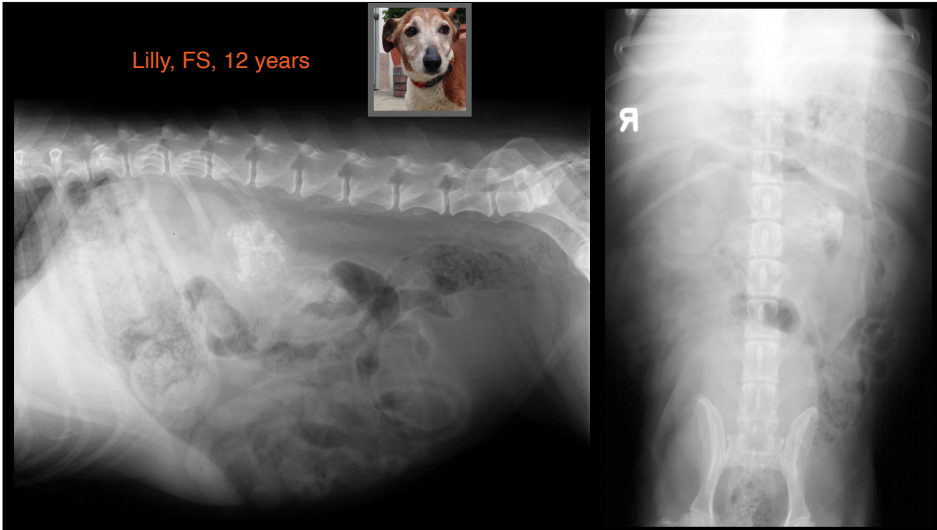


Lilly, Mongrel  
FS, 12 years

- PU/PD
- Extreme weakness
- Diarrhoea



Lilly, FS, 12 years



### Characteristics used to define an abdominal mass

- Location
- Opacity
- Mass effect / dislocation
- Mass continuation

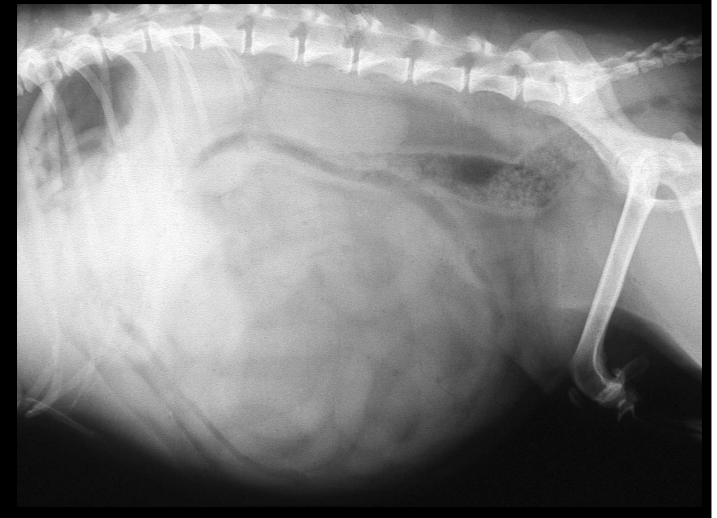



Luna, Mongrel, FS, 11 years

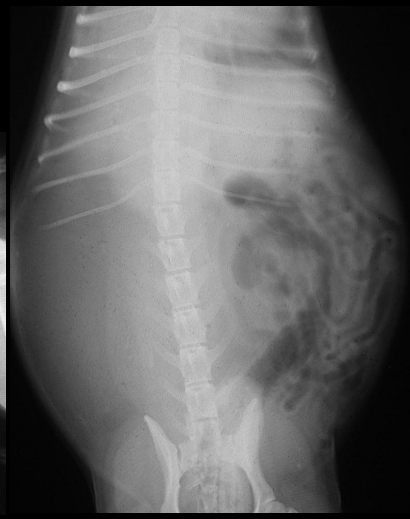
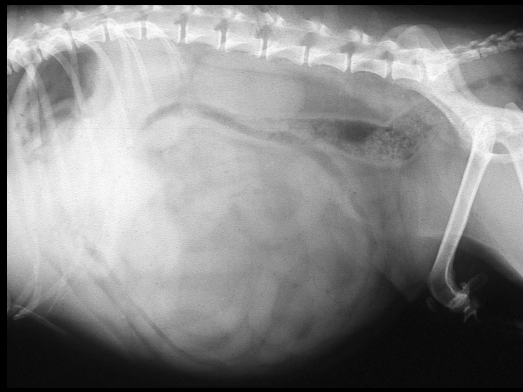
- Progressively over distended abdomen
- Otherwise healthy



Luna, FS,  
11 years



Luna, FS,  
11 years

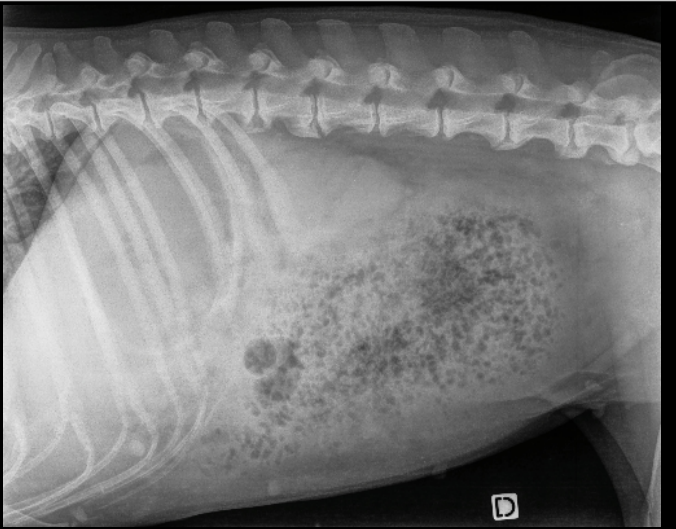


Lu, Malinois, FI, 5 year

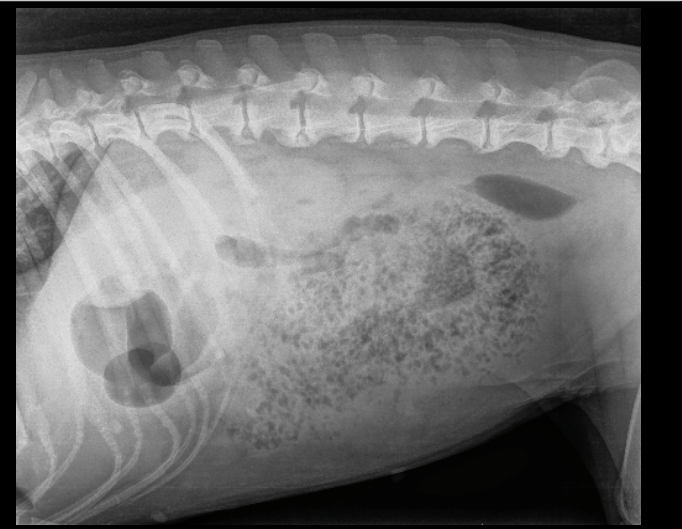
- Acute abdomen



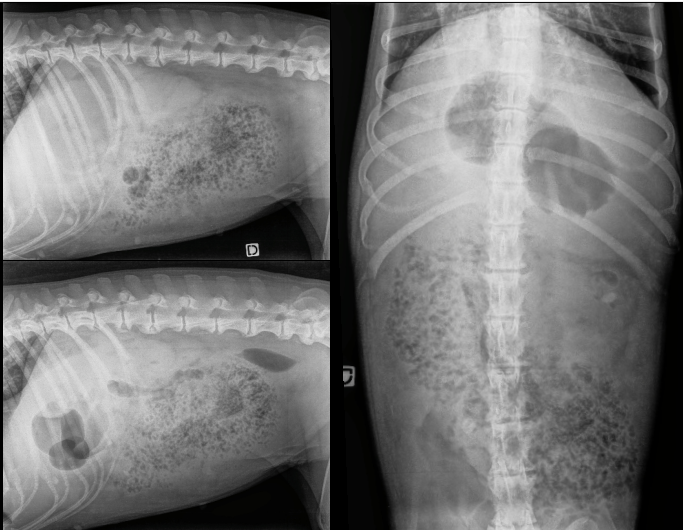Lu, FI, 5 years



Lu, FI, 5 years



Lu, FI, 5 years



### Characteristics used to define an abdominal mass

- Location
- Opacity
- Mass effect / dislocation
- Mass continuation



## Newton, DSH, FI, 16 years

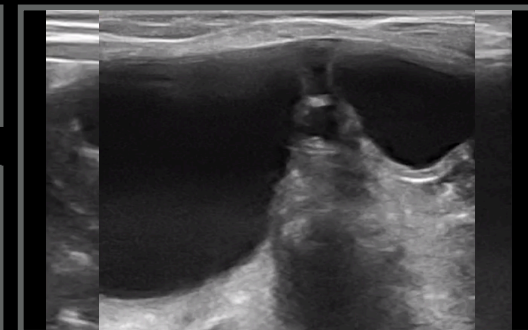
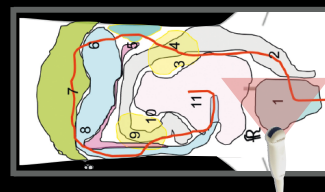
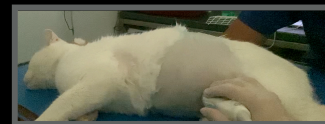
- Distended abdomen
- One episode of vomiting
- Less active
- Indoor only



## Newton, FI, 16 years



Another patient, to show the position of the probe



## Newton, DSH, FI, 16 years

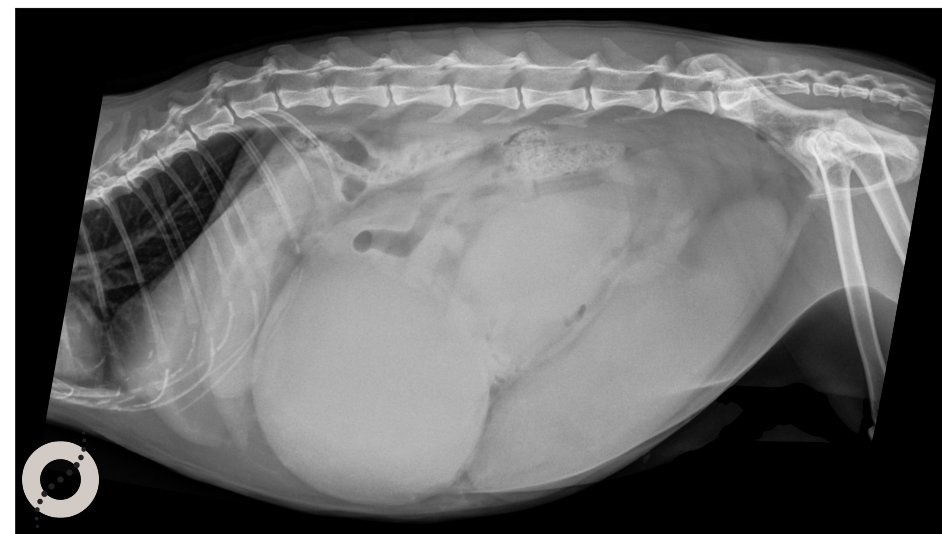
### Ultrasonographic diagnoses:

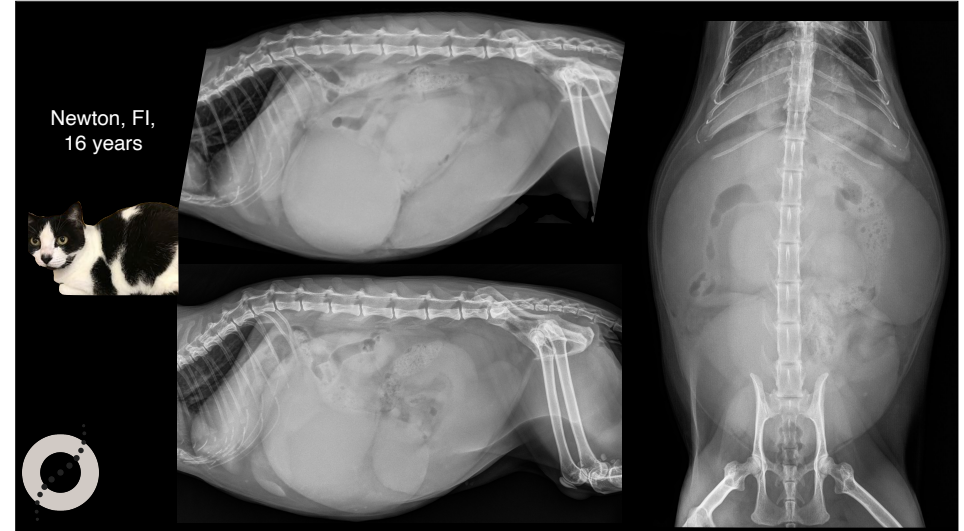
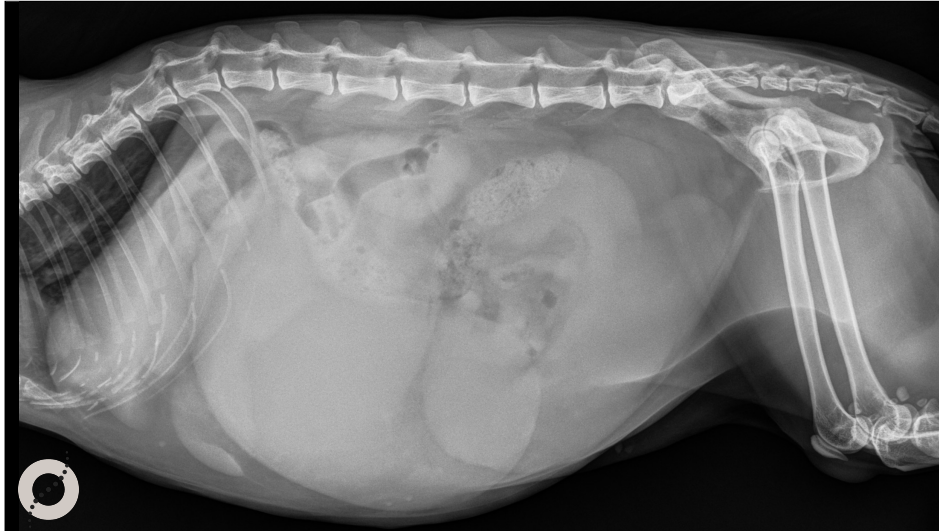- “Double” urinary bladder, only one has a neck region
- Cystic structure inside a fluid filled structure?
- The kidneys were unremarkable for the age
- Uterus not seen, could be involved?



### Conclusions:

- ???
- Pyometra/hydrometra?





### Characteristics used to define an abdominal mass


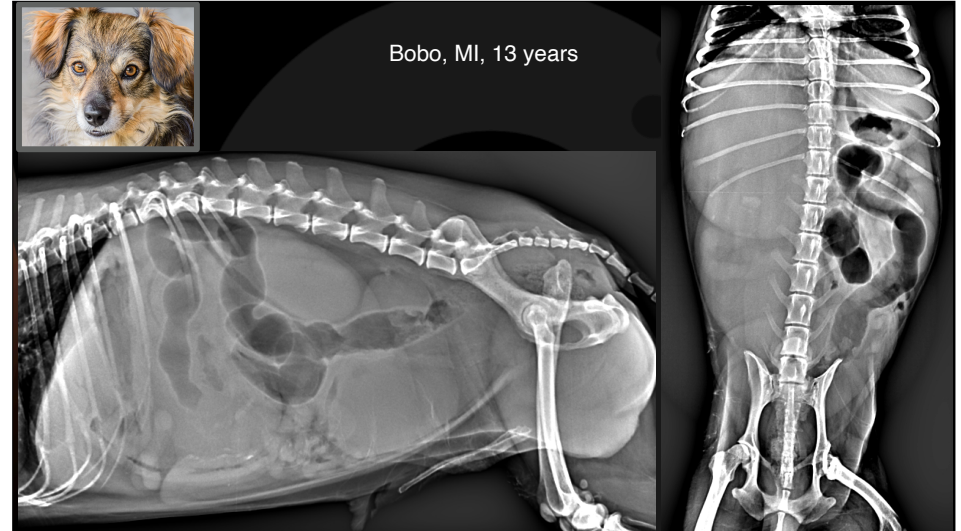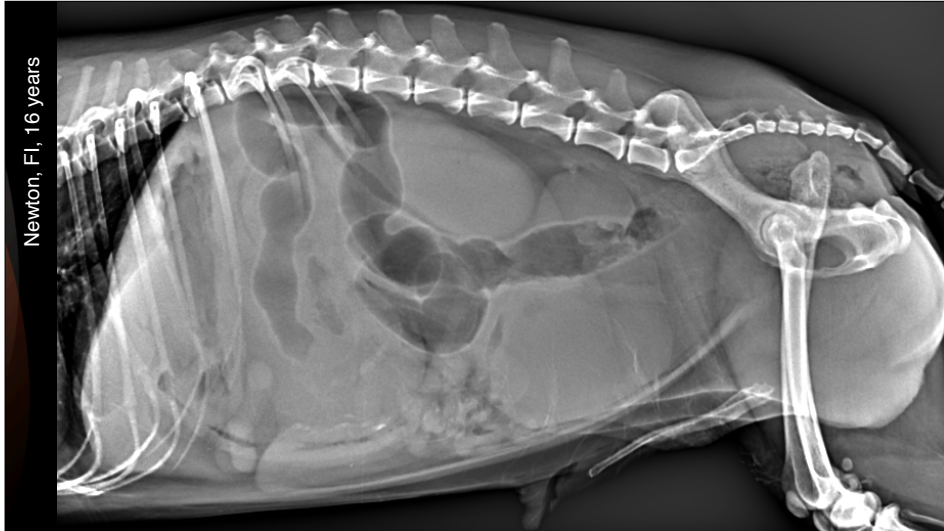
- Location
- Opacity
- Mass effect / dislocation
- Mass continuation



### Bobo, Mongrel, MI, 13 years

- Progressively distended abdomen for the last weeks
- Acute abdomen





### Conclusions

Radiology is usually a good first step to identify an abdominal mass

Ultrasound better for staging and sampling

CT most of the time needed for planning surgery and the best treatment plan

Thank you



Diagnostic Mindset

[www.diagnosticmindset.com](http://www.diagnosticmindset.com)