

L'apparato genitale femminile e maschile



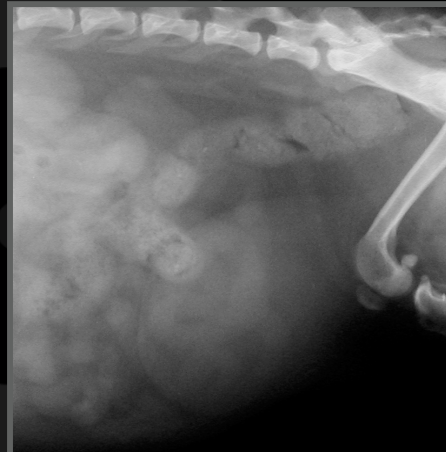
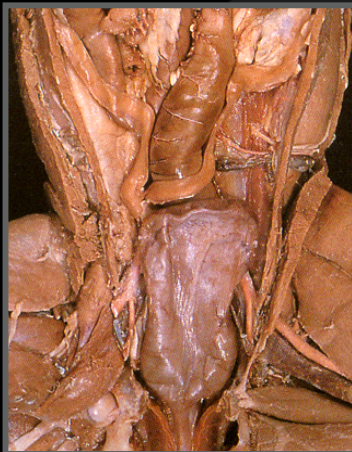Giliola Spattini
DVM, PhD, DECVDI

Objectives

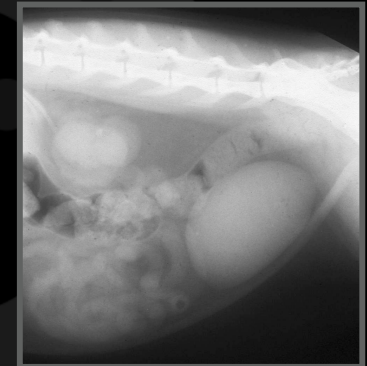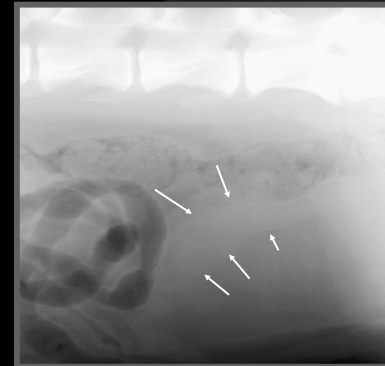
- When radiology is still useful in assessing the genital tract?
- When is better or needed despite of ultrasound?



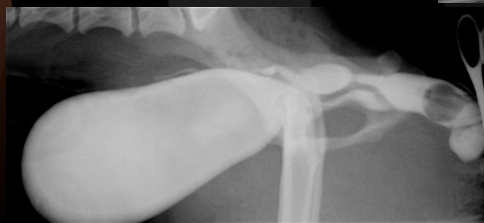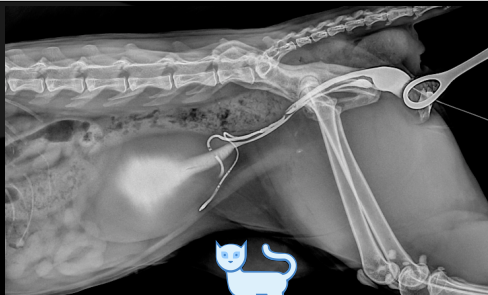
Radiographic anatomy of female genital tract



Radiographic anatomy of female genital tract

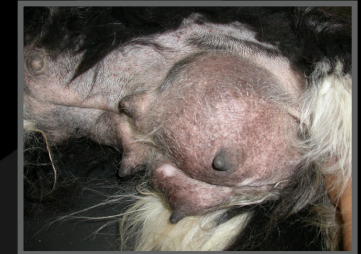

Radiographic contrast evaluation of female genital tract



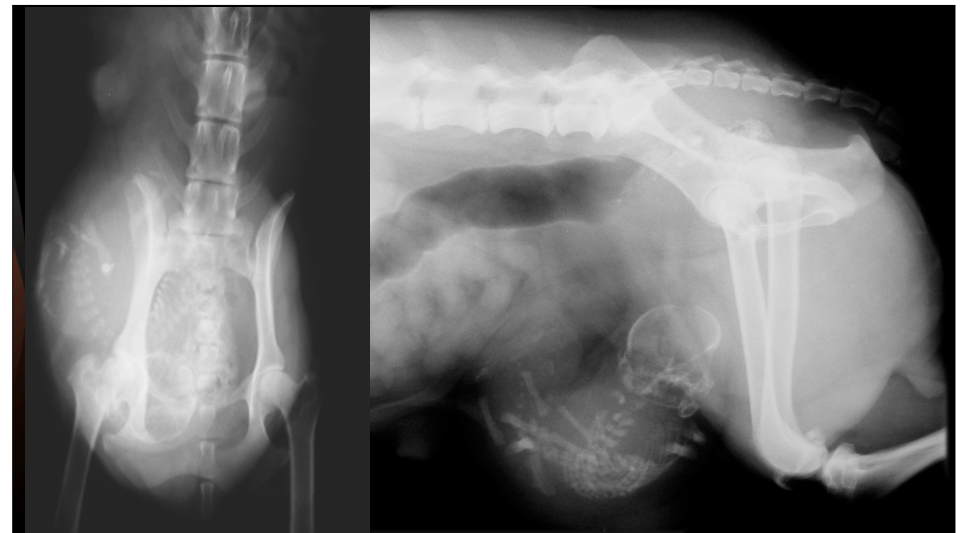
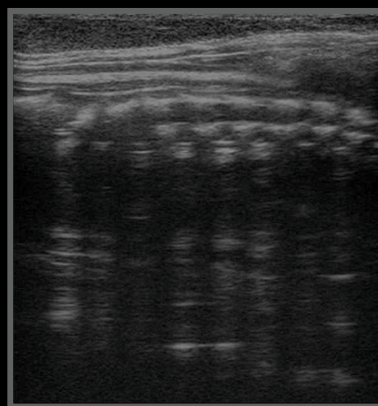
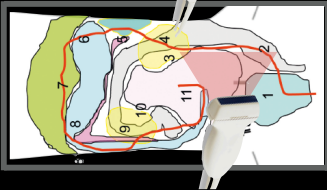
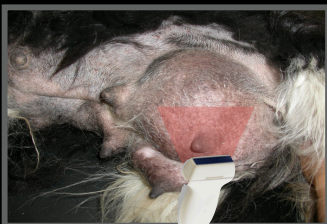Lilly, Mongrel, FS, 14 years

- The owner said:
- Yesterday this lump was not there
- She is otherwise doing fine, today mildly depressed



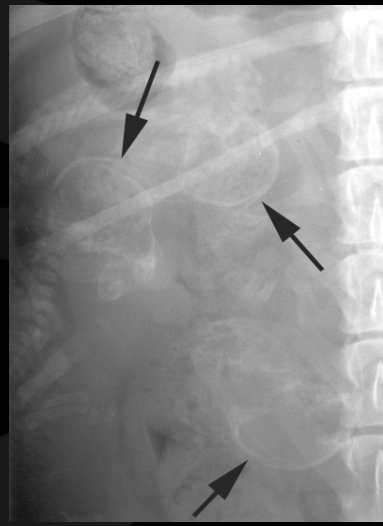
Lilly, FI, 14 years

11-2

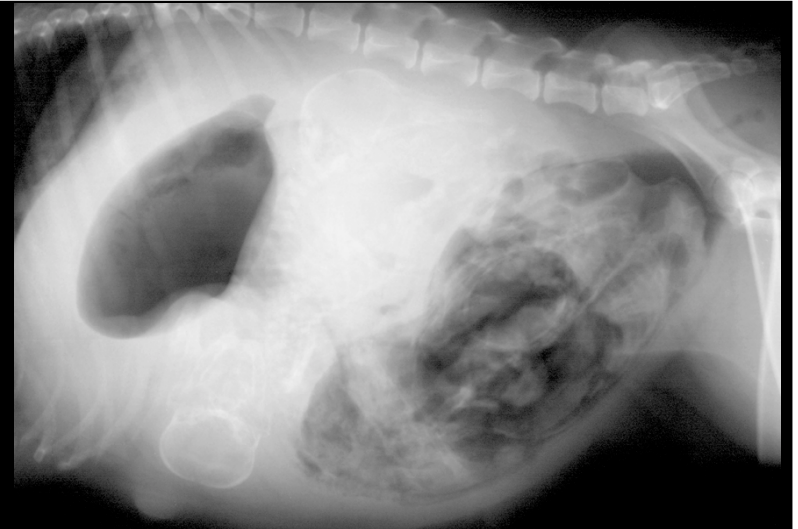


Radiographic diagnosis of fetal death

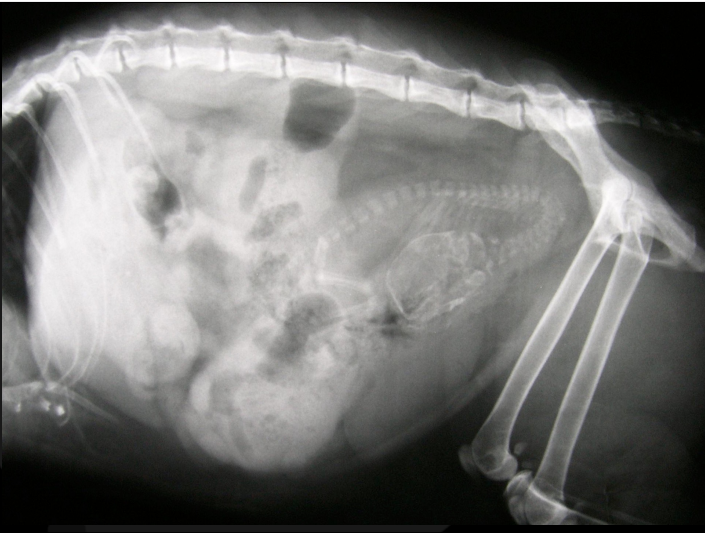
- Head splitting
- Generalised reduced fetal opacity
- Not uniform fetal opacity



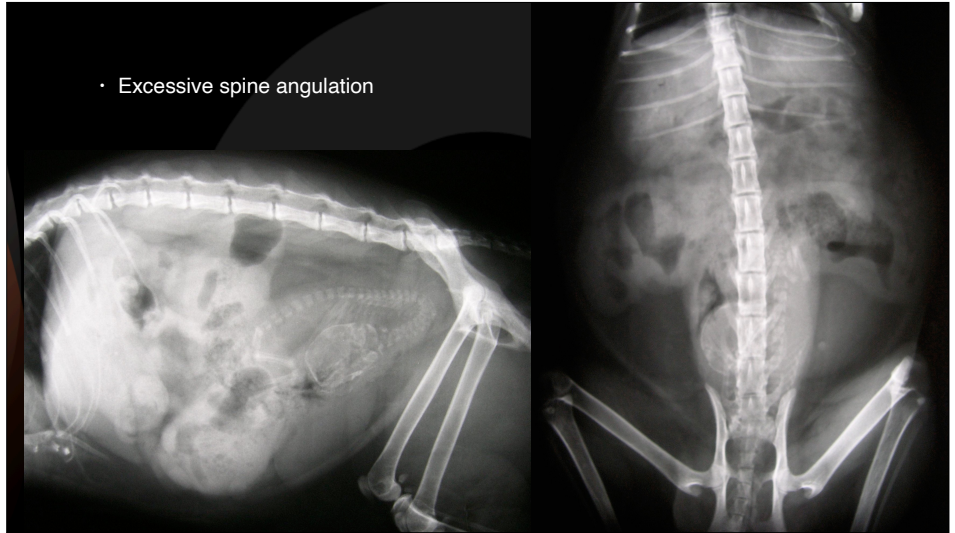
- Excessive uterine gas content



- Excessive spine angulation

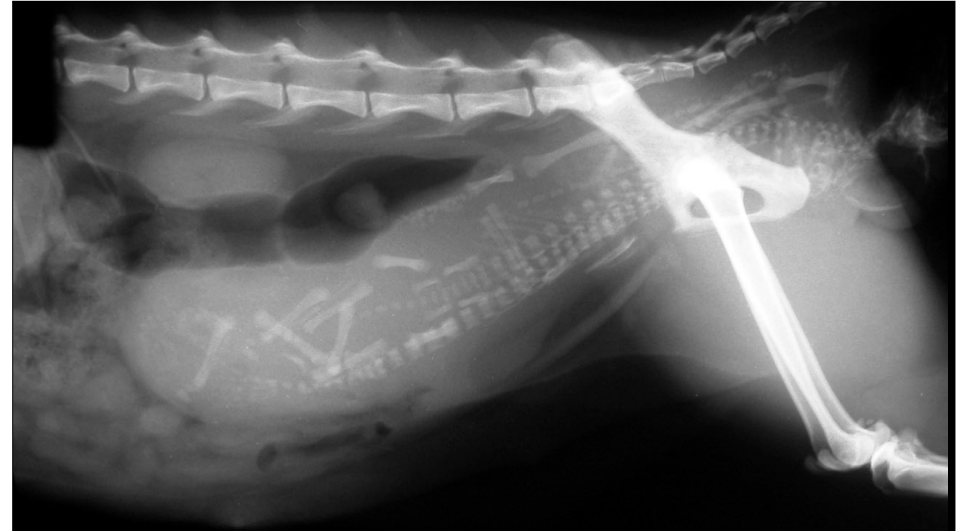
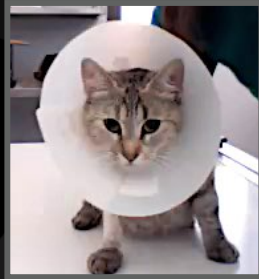


- Excessive spine angulation

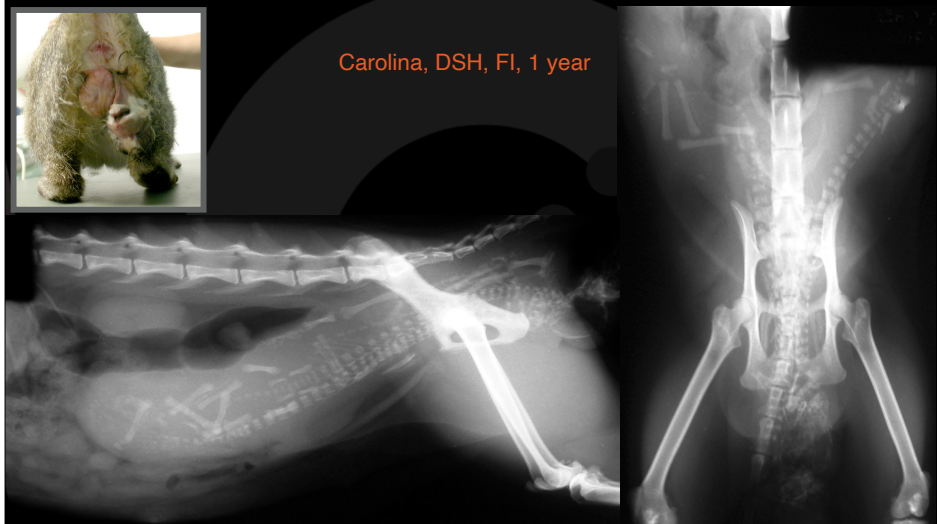
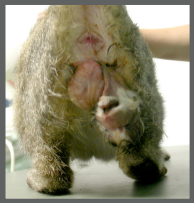

Carolina, DSH, FI, 1 year

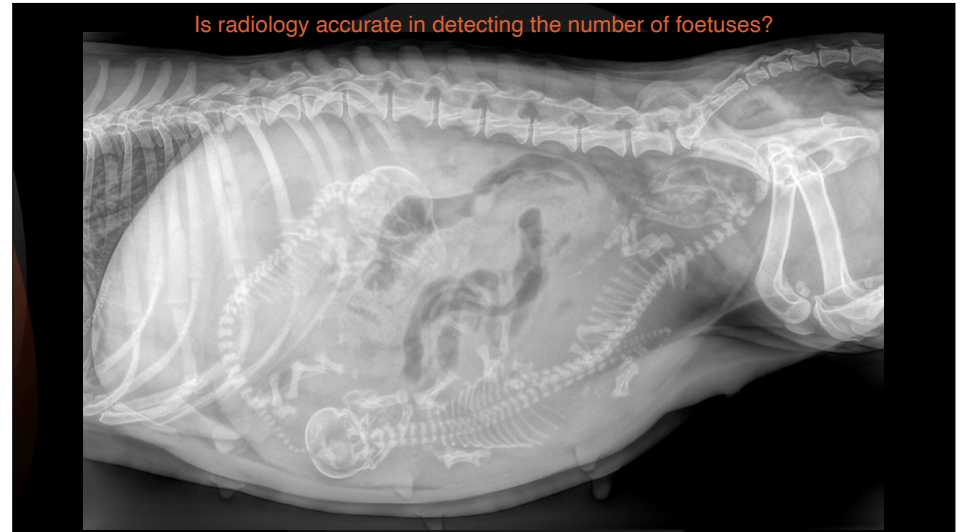- The owner said: the cat smell badly
- Outdoor and indoor
- Not clear if She is eating or urinating



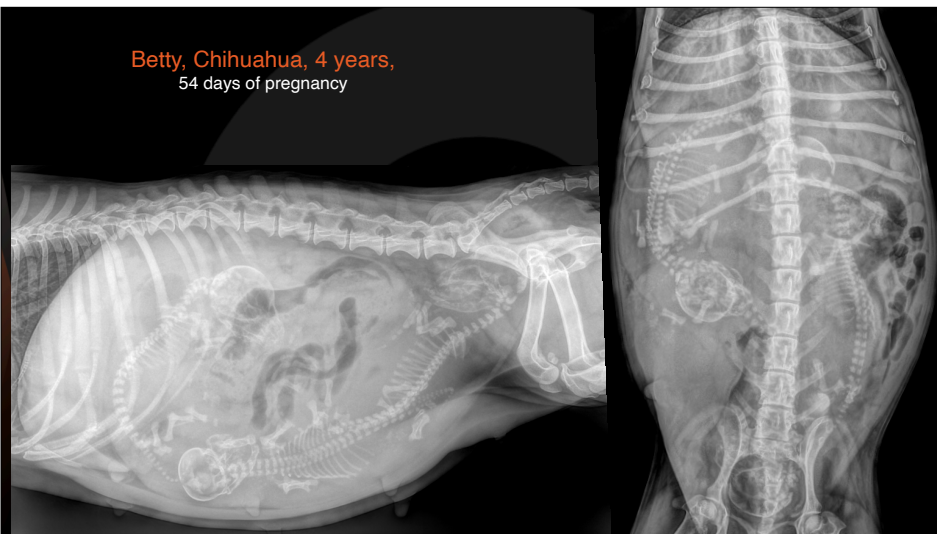Carolina, DSH, FI, 1 year



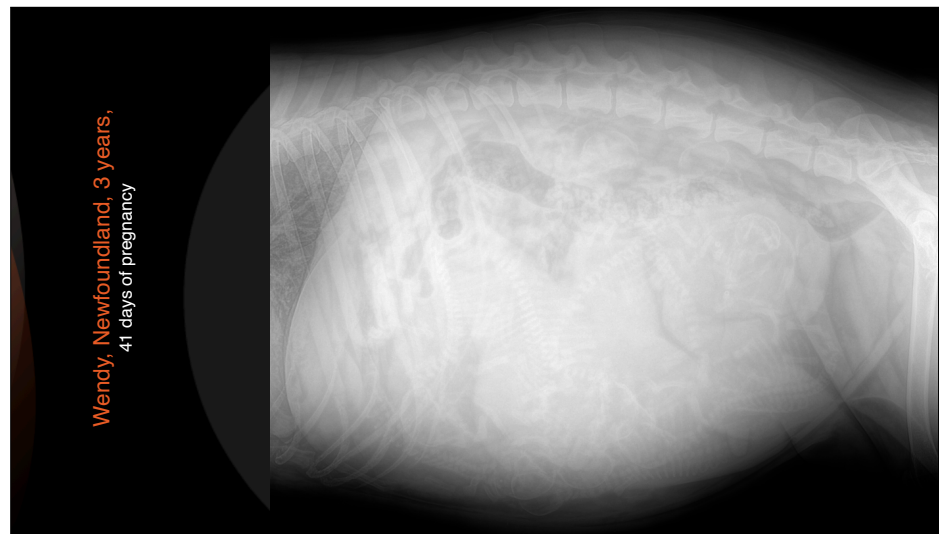
Is radiology accurate in detecting the number of fetuses?



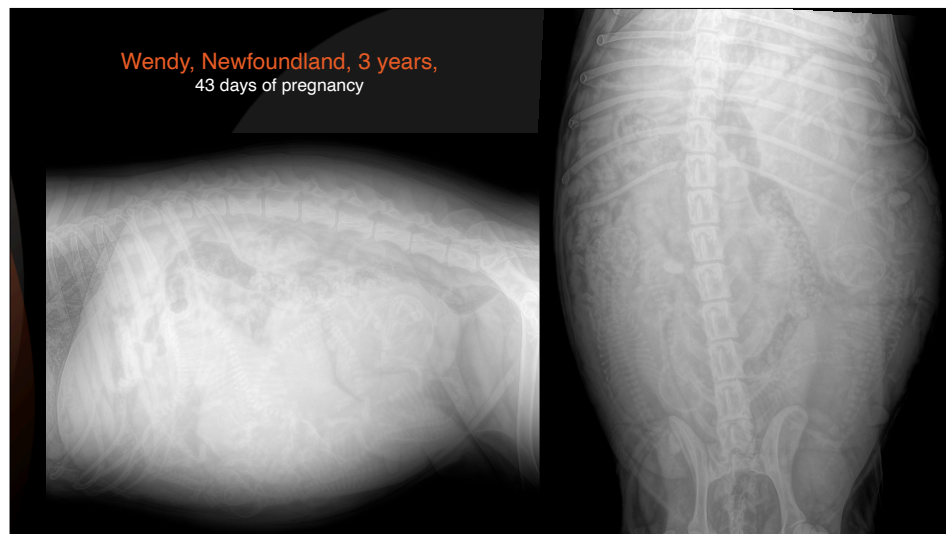
Betty, Chihuahua, 4 years,
54 days of pregnancy



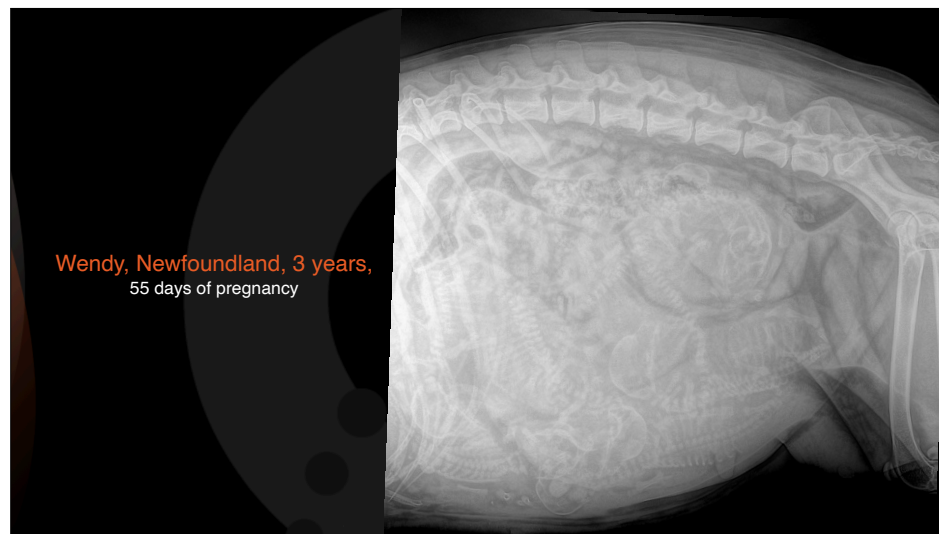
Wendy, Newfoundland, 3 years,
41 days of pregnancy



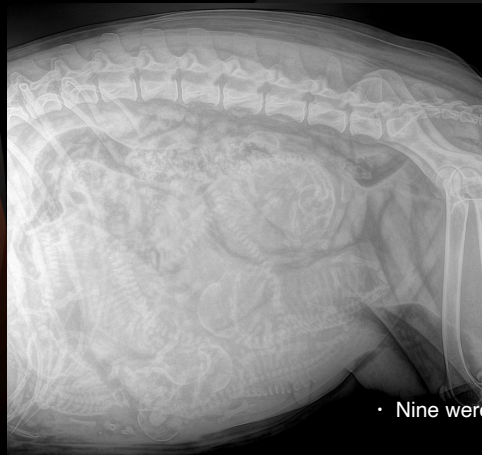Wendy, Newfoundland, 3 years,
43 days of pregnancy



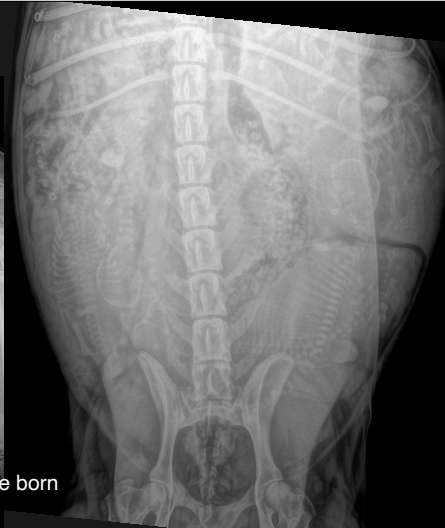Wendy, Newfoundland, 3 years,
55 days of pregnancy



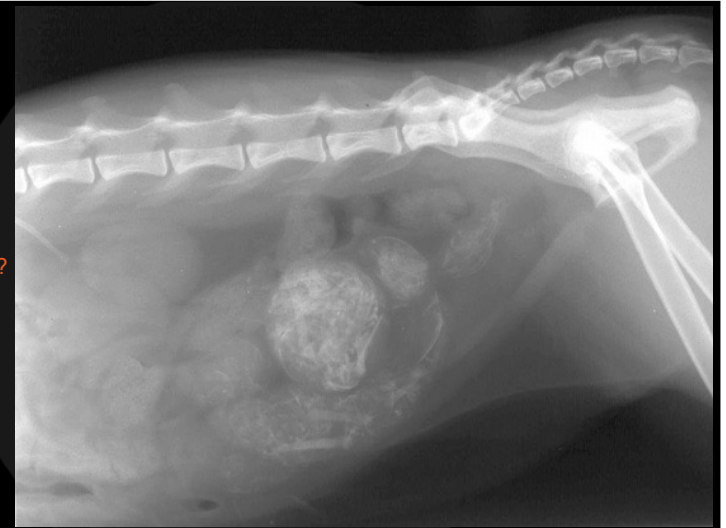Wendy, Newfoundland, 3 years,
55 days of pregnancy



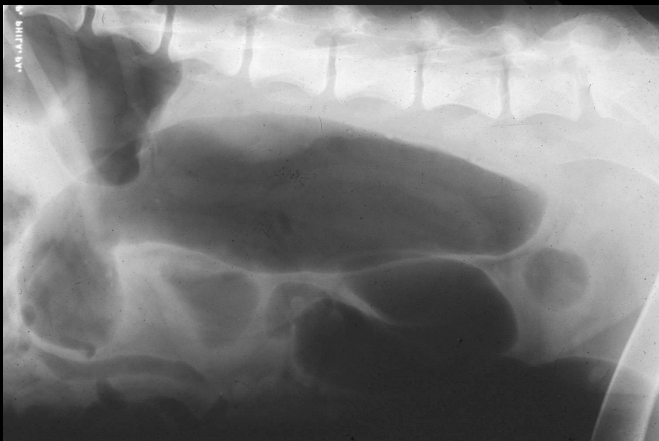
• Nine were born



Uterus or intestine?

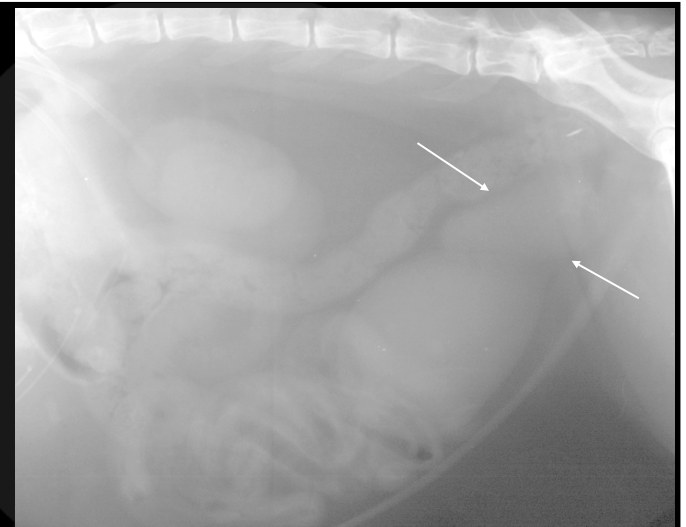


Emphysematous pyometra

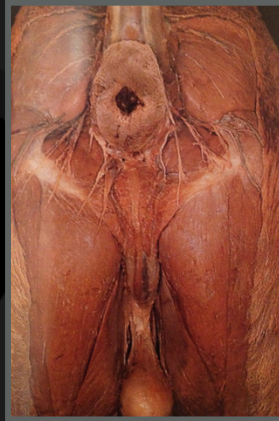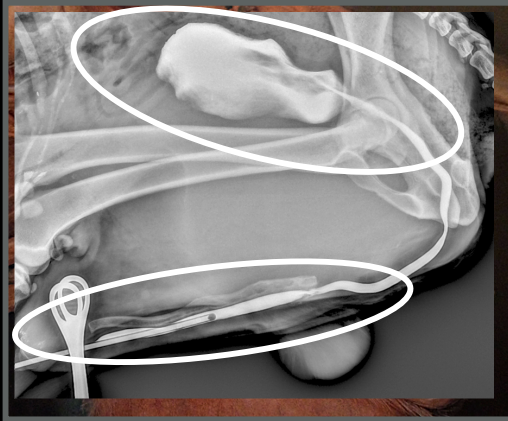


What is the problem?

Stump granuloma



Gross anatomy of male genital tract



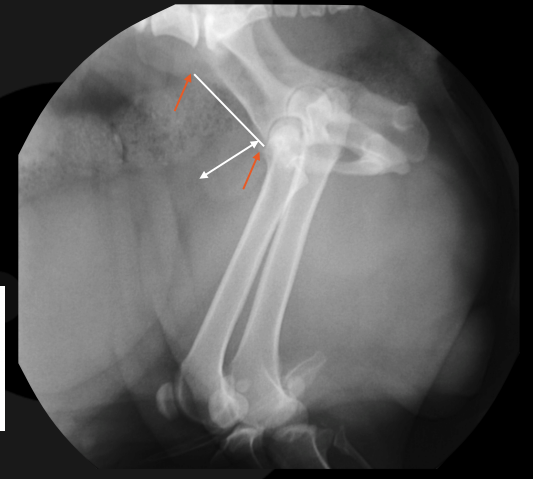
Radiographic anatomy of the canine prostate



- The length of the prostate should be \leq of 70% of pubic eminence/iliac angle distance

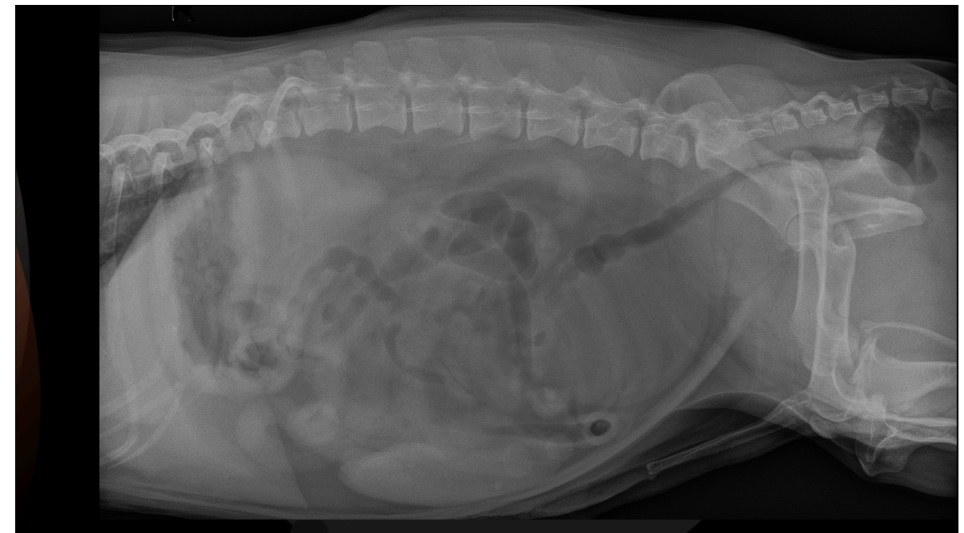Validation of canine prostate volumetric measurements in computed tomography determined by the slice addition technique using the Amira program

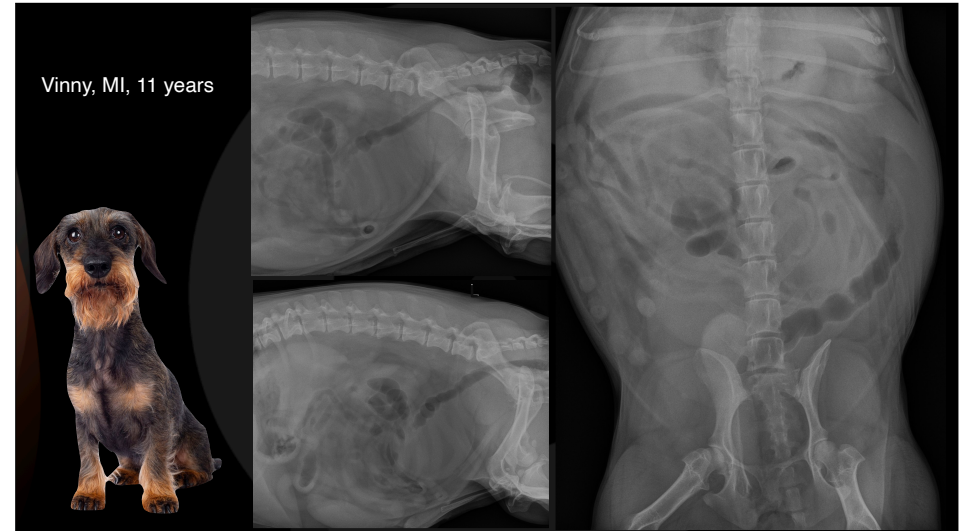
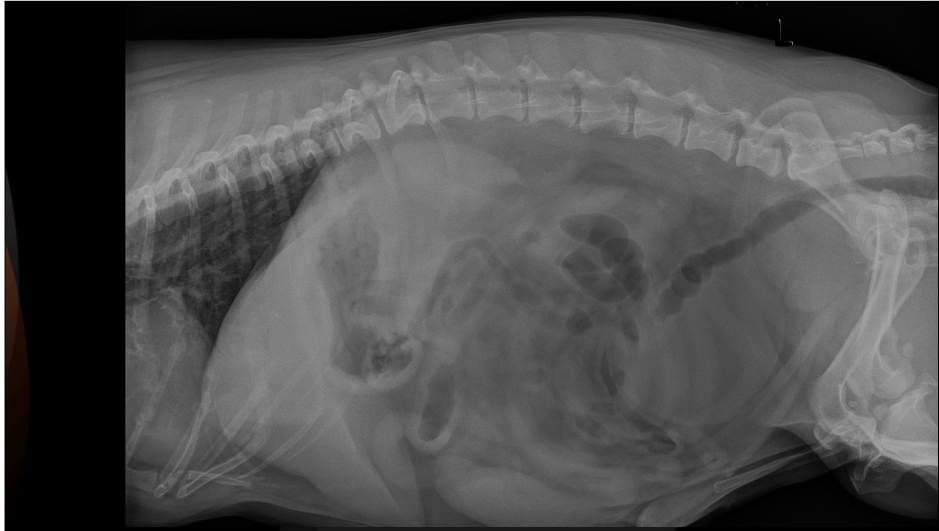Humbert et al. BMC Veterinary Research 2019, 15:48
Katharina Haverkamp^{1*}, Lisa Katharina Harder^{1†}, Nora Sophie Maria Kuhnt^{1†}, Matthias Lipke^{1†}, Ingo Nolte¹ and Patrick Wefstaedt^{1†}



Vinny, Dachshund, MI, 11 years

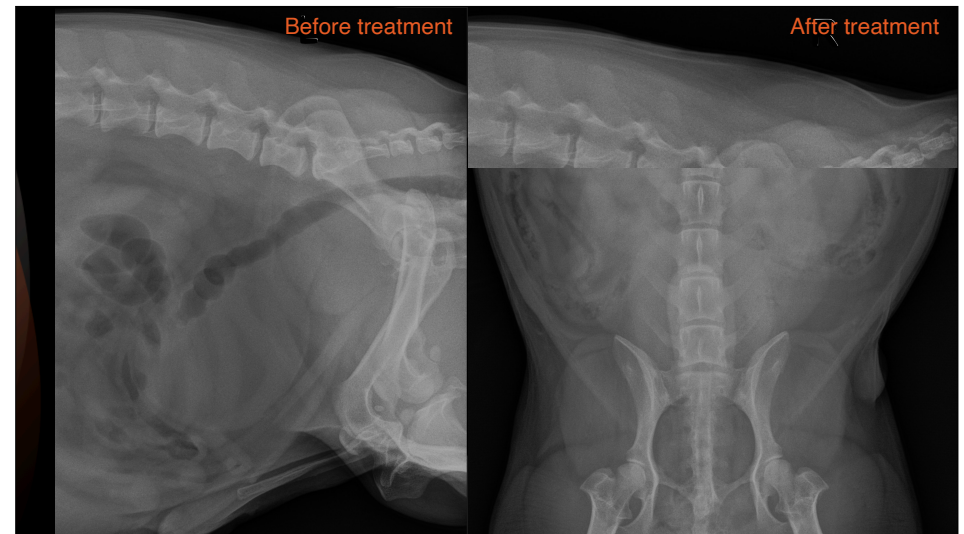
- Tenesmus
- Mildly tense abdomen
- In the past back pain





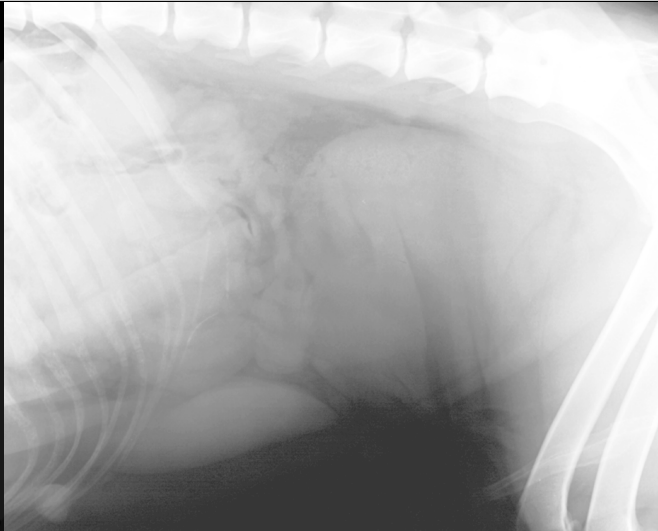Vinny, Dachshund, MI, 11 years

- Treated with finasteride for BPH for 2 months
- No clinical signs
- Prostate size recheck

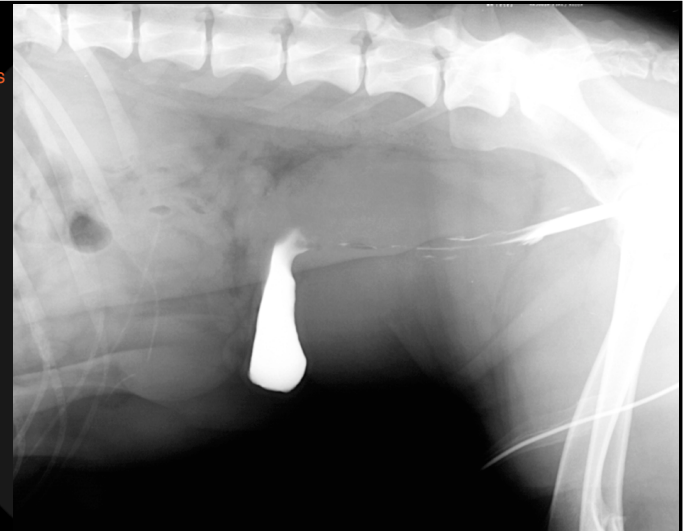
Benny, Beagle, MI, 9 years

- Hematuria
- Episodes of constipation



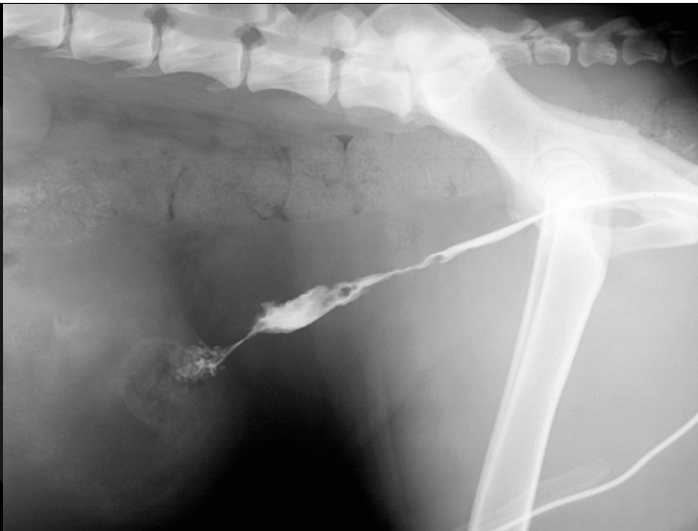
Benny, Beagle, MI, 9 years

- Hematuria
- Episodes of constipation



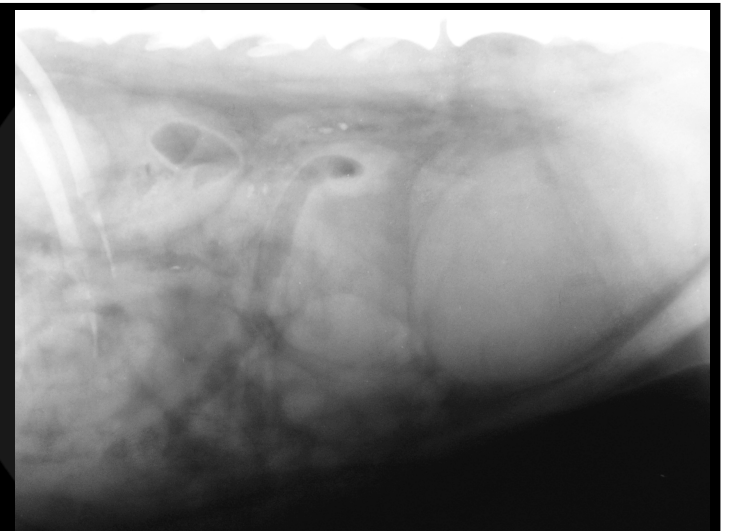
Tod, Mongrel, MI, 11 years

- Hematuria
- Stranguria



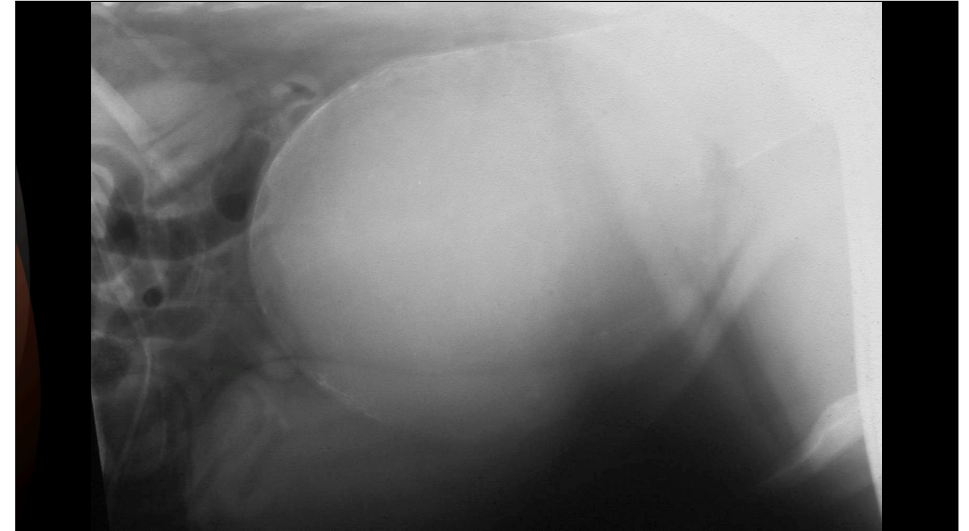
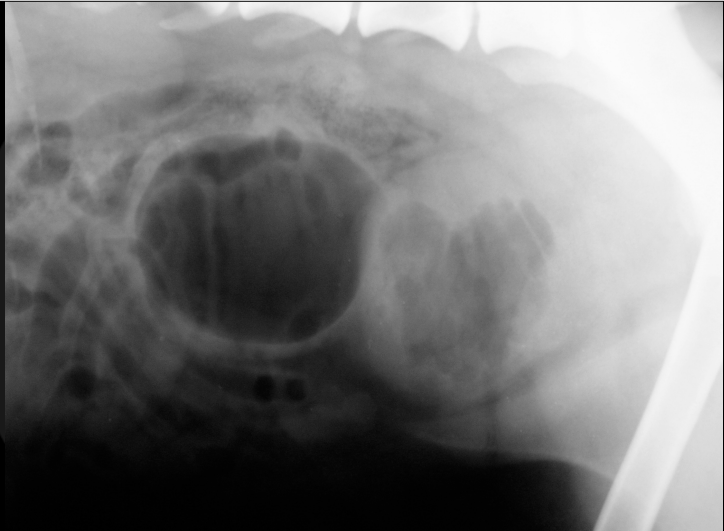Berto, Mongrel, MI, 12 years

- Hematuria
- Stranguria



Berto, Mongrel,
MI, 12 years

- Hematuria
- Stranguria

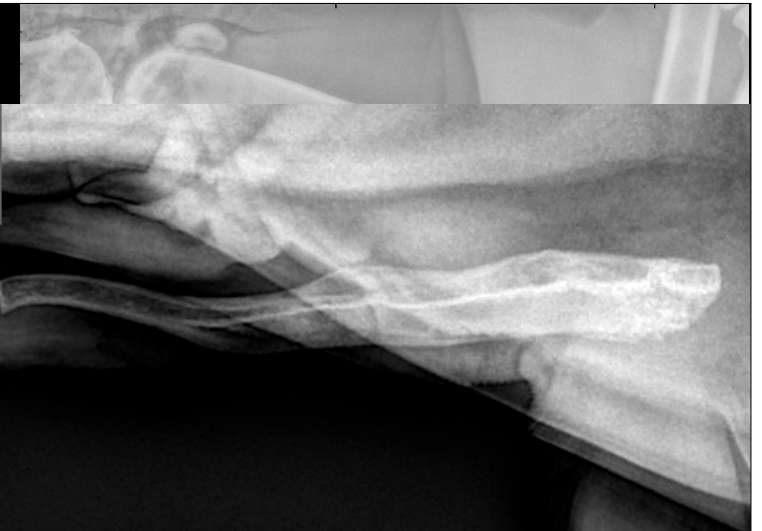

Cafù, Drahthaar, MI, 12 years

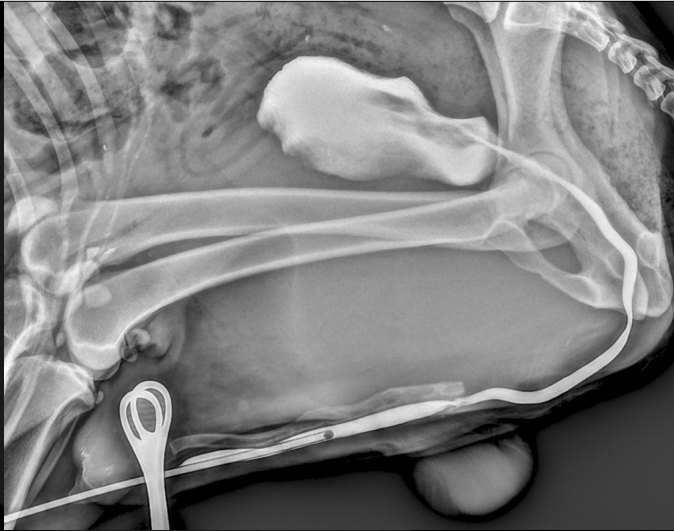
- Stranguria for the last week
- Loosing weight and urine recently
- Reduced urine stream, drop by drop
- Soft tissue thickening at the base of the os penis



Cafù, MI, 12 years



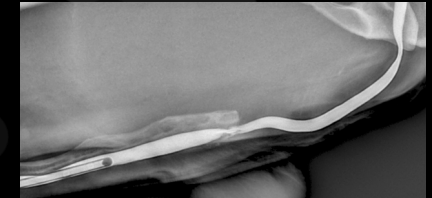
Cafù, MI, 12 years



Cafù, Drahthaar, MI, 12 years

Radiographic diagnoses:

- Urethral focal stenosis at the base of the os penis
- Ultrasound shows periosteal proliferation and lack of soft tissue mass



Next step:

Urinary Obstruction Secondary to an Ossifying Fibroma of the Os Penis in a Dog
J Am Anim Hosp Assoc 2004;40:152-156.

- Urethrostomy or surgical curettage of the os penis?

Conclusions

- Radiology can still be useful in genital tract for:
 - Count of the foetus
 - Incidental diagnosis of uterine disorder
 - Large uterine mass
 - Prostatic carcinoma
 - Para-prostatic cysts, size of the prostate



Thank you



Diagnostic Mindset

www.diagnosticmindset.com