Ultrasound of the most common front-digits diseases in sporting dogs

Diagnostic Mindset

Thanks to www.imaios.com

Giliola Spattini
DVM, PhD, DECVDI

Objectives

- High-resolution US improves the visualisation of distal MSK structures
- The information obtained can affect the planning for treatment

Front limb

Digital anatomy

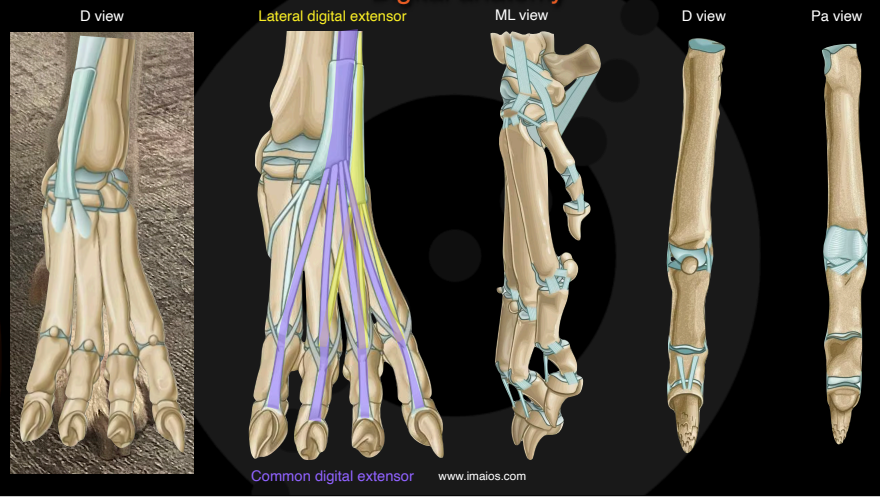

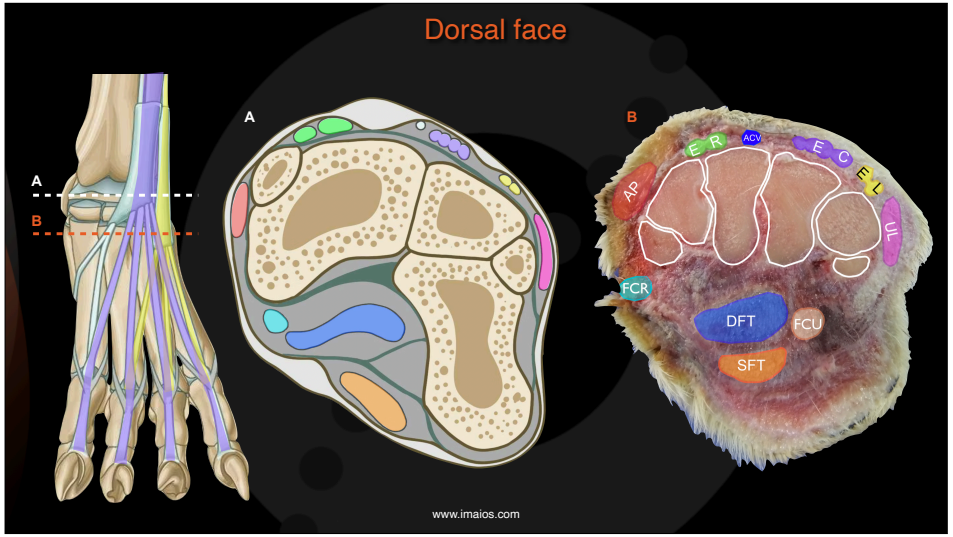
Dorsal face
A
B
A
B
E
R
ACV
E
C
EL
AP
UL
FCR
DFT
FCU
SFT
www.imaios.com

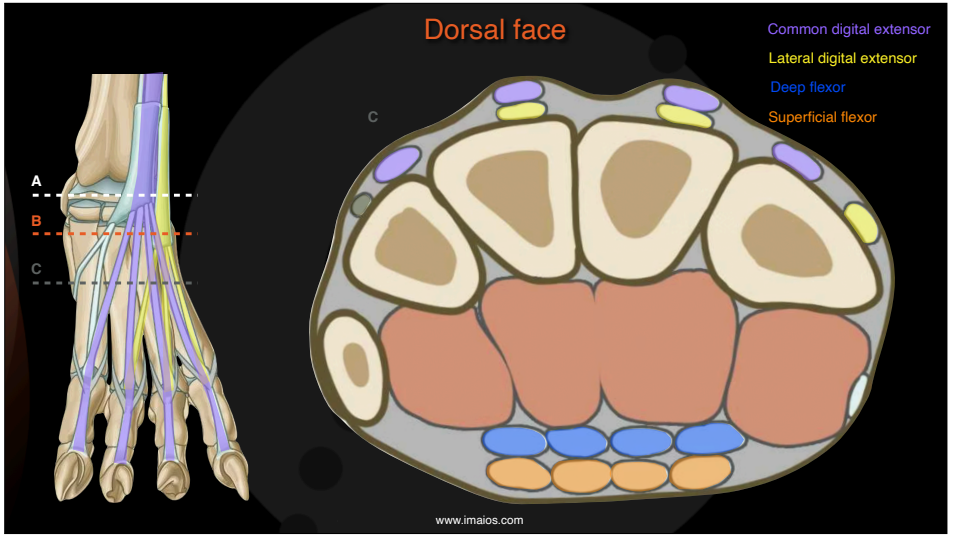
Dorsal face
Common digital extensor
Lateral digital extensor
Deep flexor
Superficial flexor
A
B
C
C
www.imaios.com

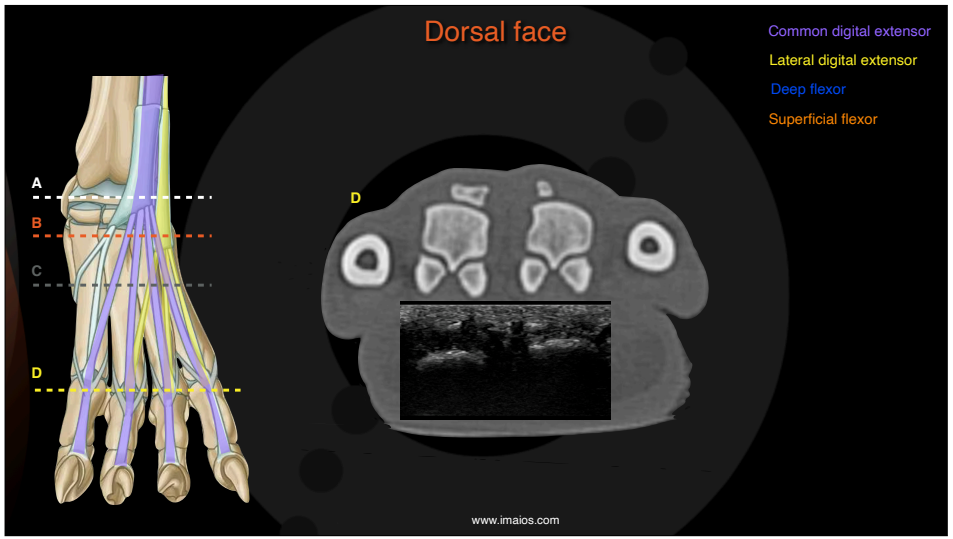
Dorsal face
Common digital extensor
Lateral digital extensor
Deep flexor
Superficial flexor
A
B
C
D
D
www.imaios.com

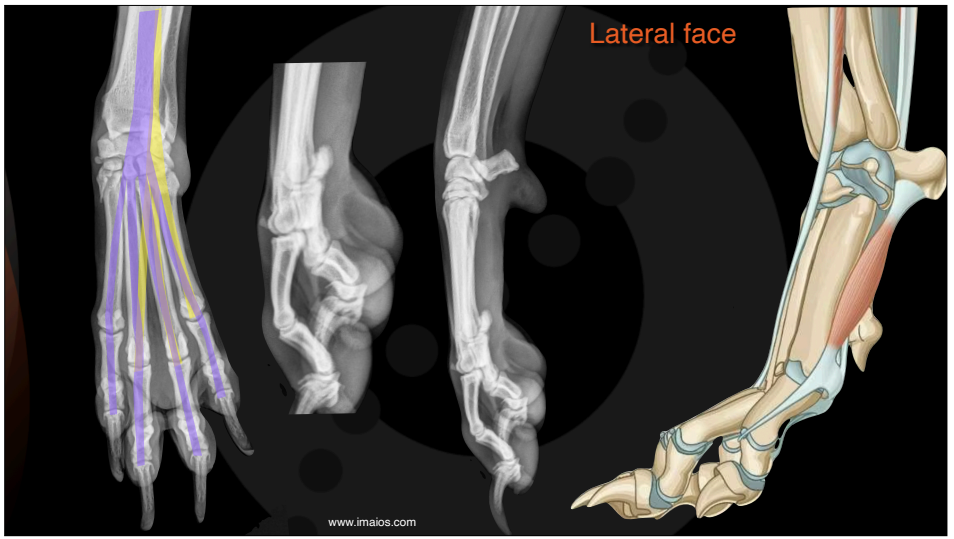
Lateral face
www.imaios.com

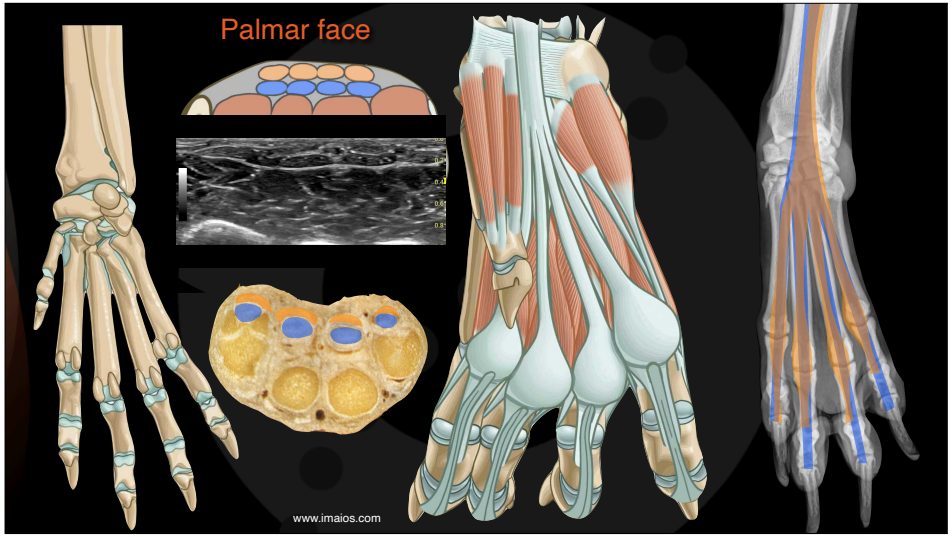

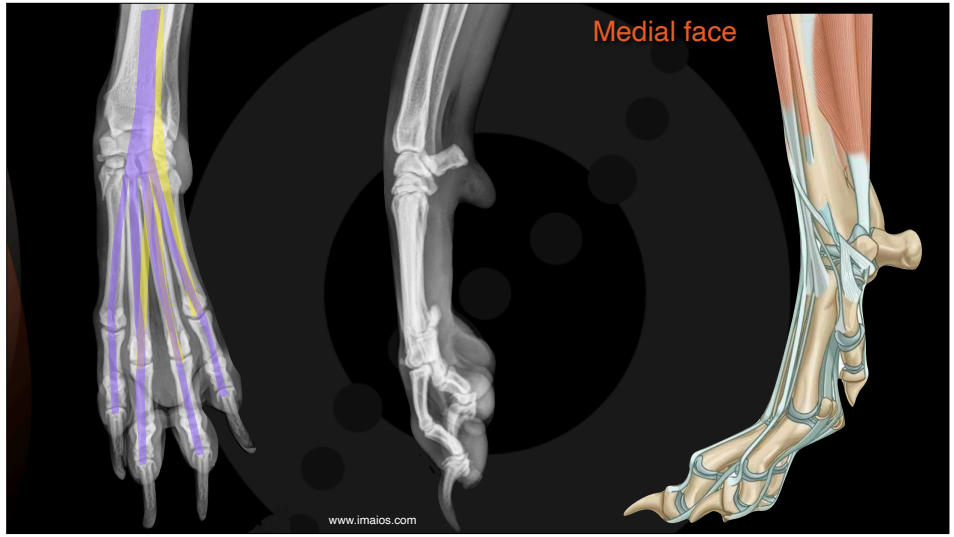

What are you looking for with an ultrasound?

- Start with a transverse scan at the dorsal sesamoid bones
- Extensors tendons
- Joint stability-DJD-inflammatory changes
- Distal phalangeal displacement
- Are the flexor tendons competent?

Max, Greyhound, MN, 4 years

- Ex racing
- Arrived at the new home three months ago
- After two months of lameness every time He runs
- He has recurrent digital dermatitis - inflamed digits

Max, MN, 4 years

Max, MN, 4 years

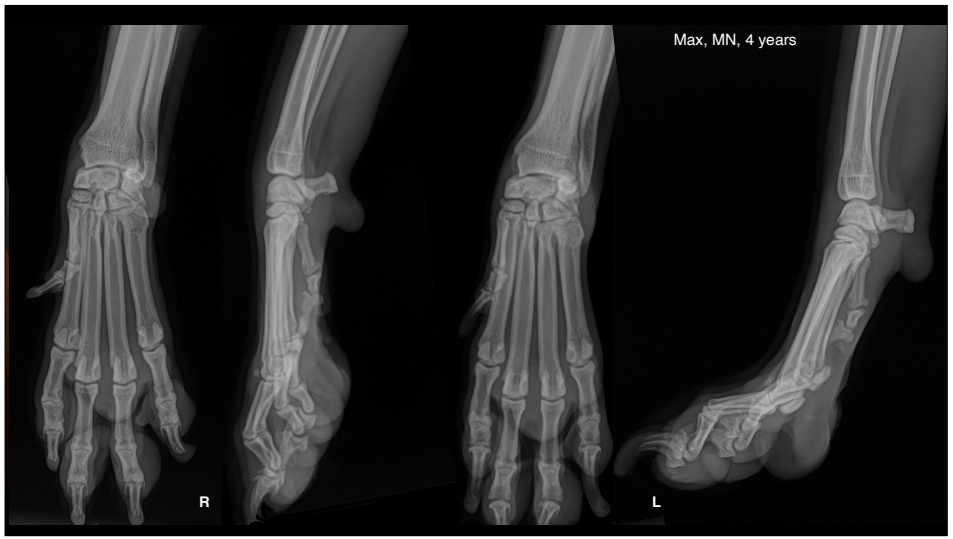
Max, MN, 4 years
R
L

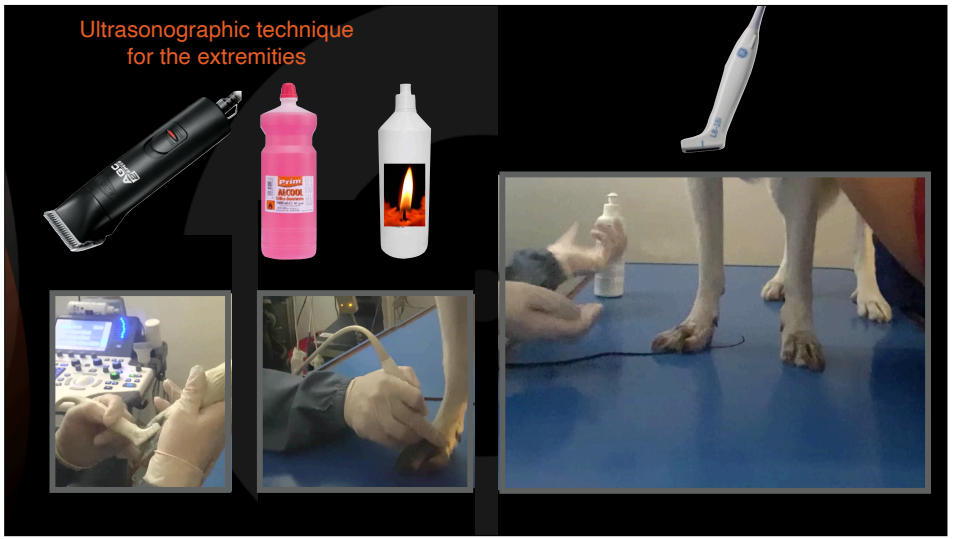
Ultrasonographic technique
for the extremities

Max, Greyhound, MN, 4 years

- Ex racing
- Arrived at the new home three months ago
- After two months of lameness every time He runs
- He has recurrent digital dermatitis - inflamed digits

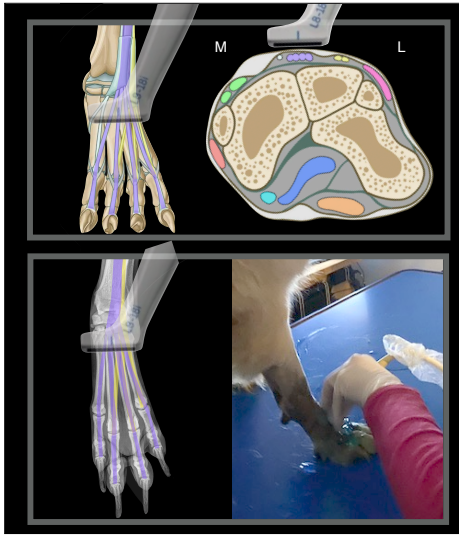

Max, MN, 4 years

Right metacarpus

Transverse scan plan

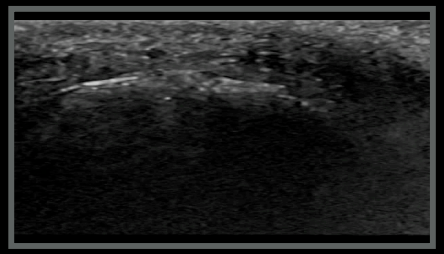

www.imaios.com

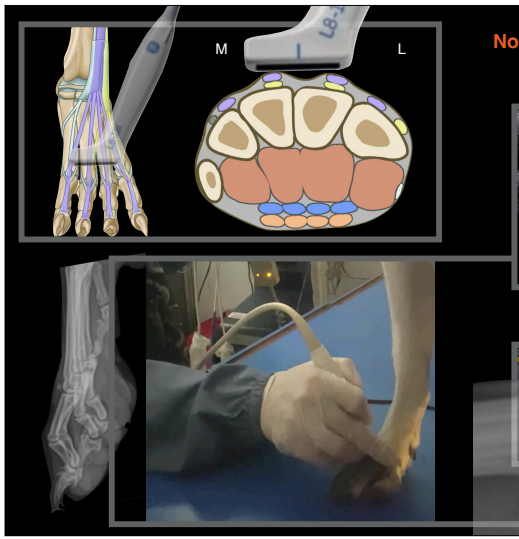

Normal anatomy of the metacarpal region

Left metacarpus

Transverse scan plan

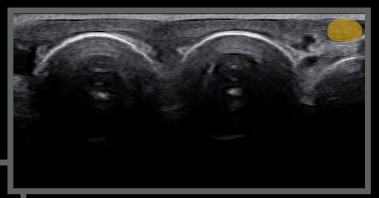

Longitudinal scan plan

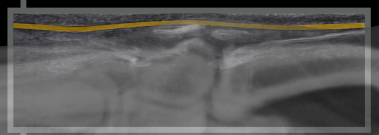

www.imaios.com

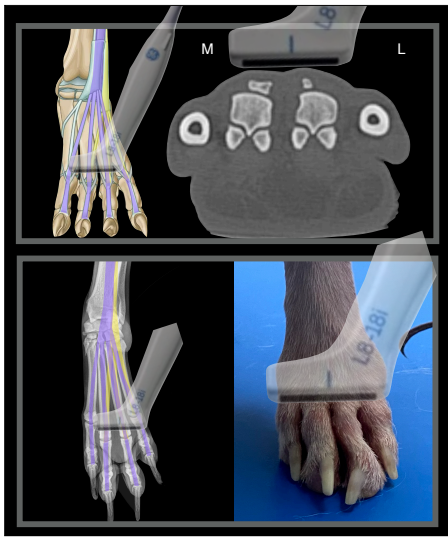

Normal anatomy of the MC-P1 third and fourth digits

Left metacarpus

Transverse scan plan, dorsal face

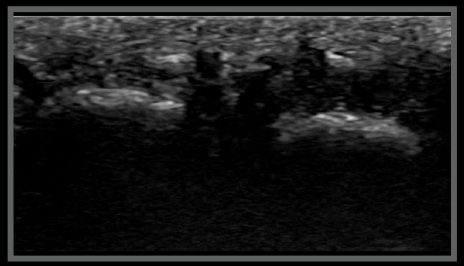

www.imaios.com

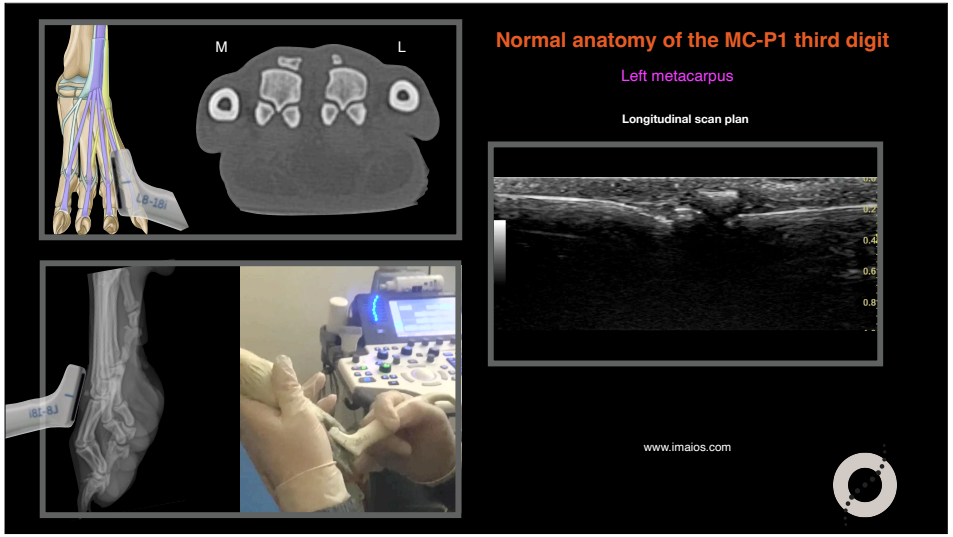
M
L
Normal anatomy of the MC-P1 third digit
Left metacarpus
Longitudinal scan plan
www.imaios.com

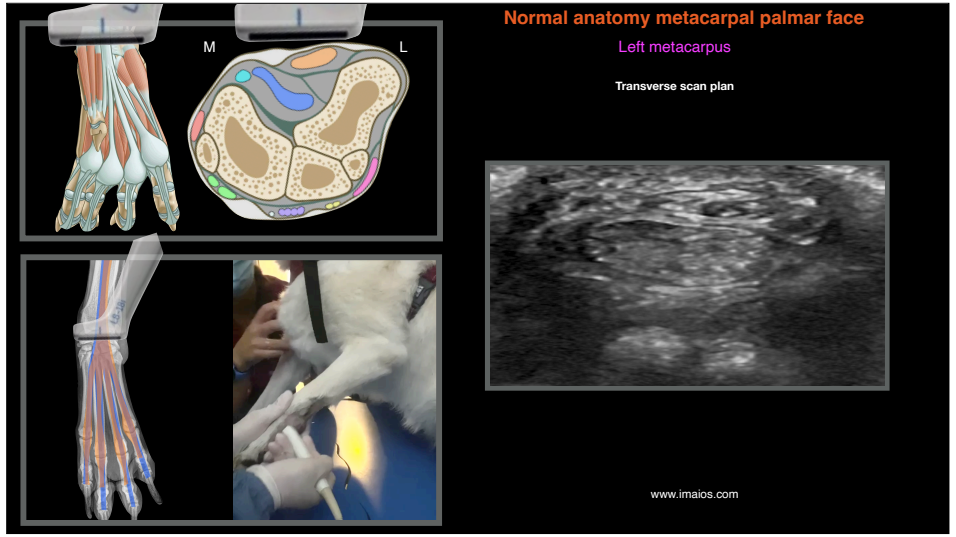
M
L
Normal anatomy metacarpal palmar face
Left metacarpus
Transverse scan plan
www.imaios.com

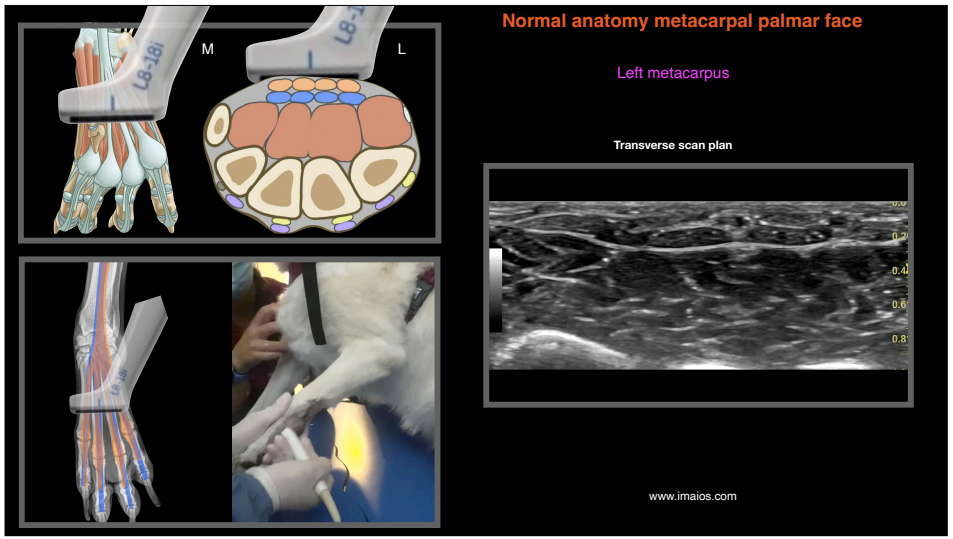
M
L
Normal anatomy metacarpal palmar face
Left metacarpus
Transverse scan plan
www.imaios.com

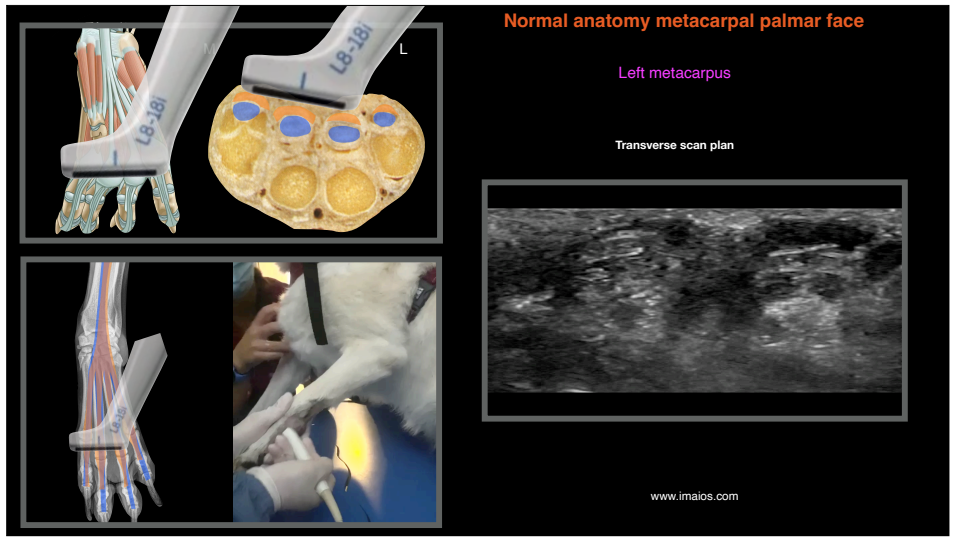
L
Normal anatomy metacarpal palmar face
Left metacarpus
Transverse scan plan
www.imaios.com

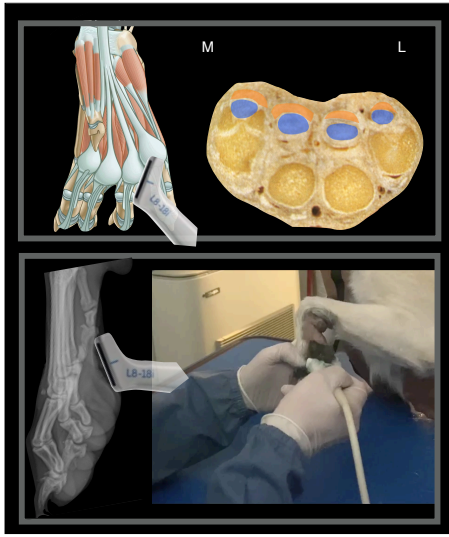

Normal anatomy metacarpal palmar face

Left metacarpus

Transverse scan plan

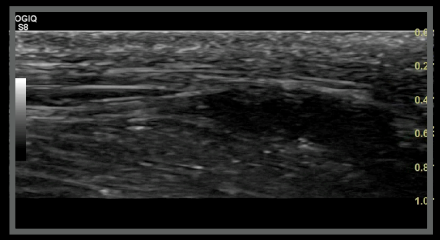

www.imaios.com

Max, Greyhound, MN, 4 years

- Ex racing
- Arrived at the new home three months ago
- After two months of lameness every time He runs
- He has recurrent digital dermatitis - inflamed digits

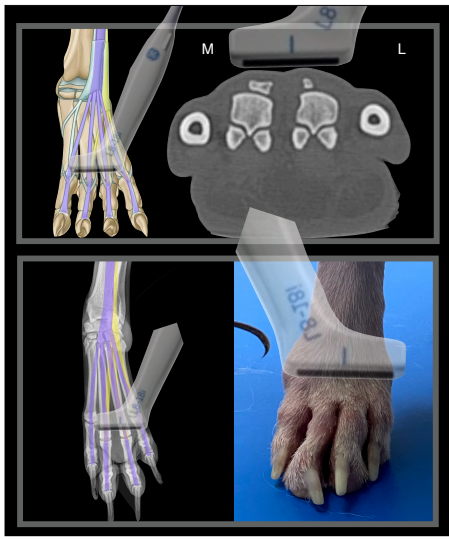

Max, Mn, 4 years

Right metacarpus

Transverse scan plan, dorsal face

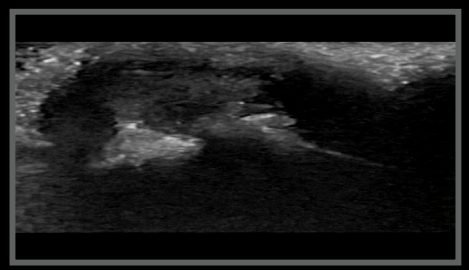

www.imaios.com

Max, Greyhound, MN, 4 years

Normal anatomy

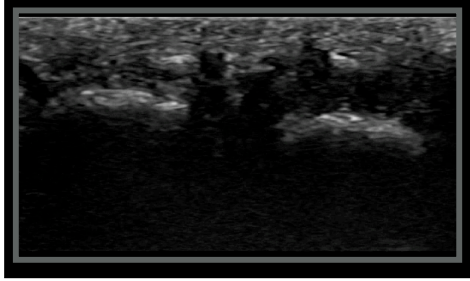

Right metacarpus

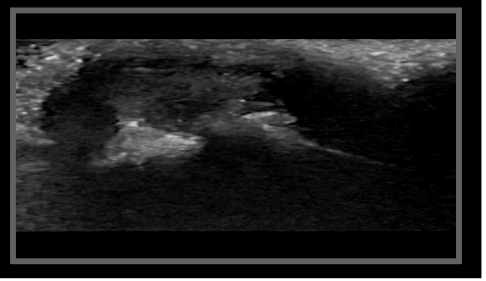

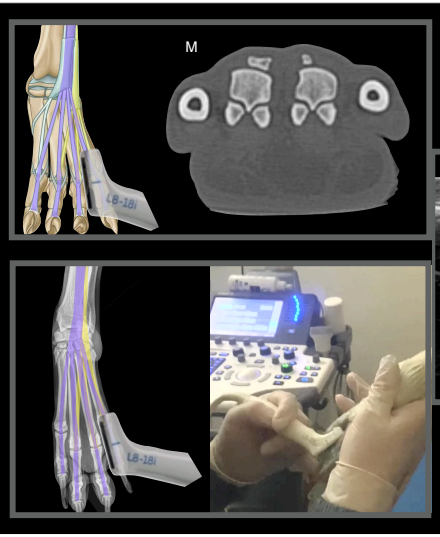

Max, Mn, 4 years

Right metacarpus

Longitudinal scan plan, dorsal face

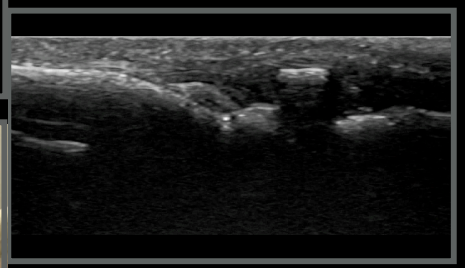

www.imaios.com

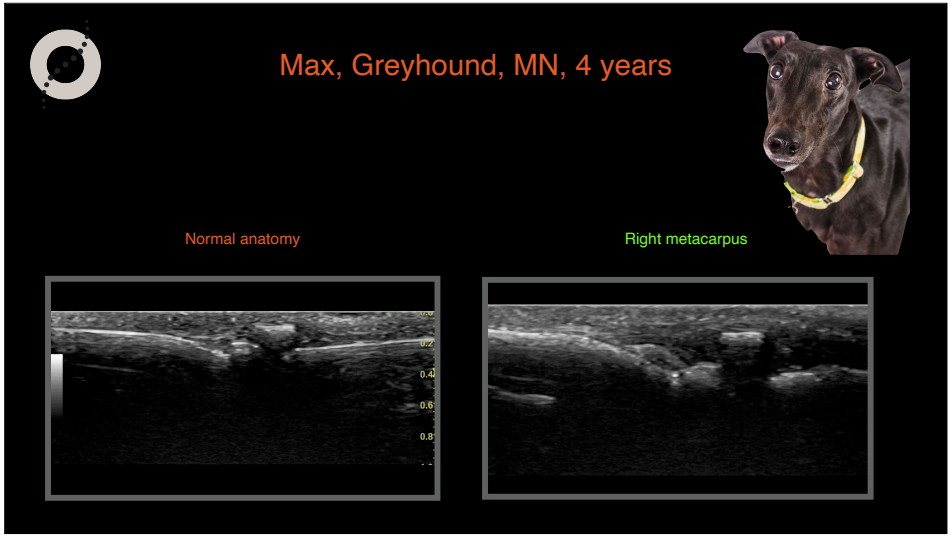

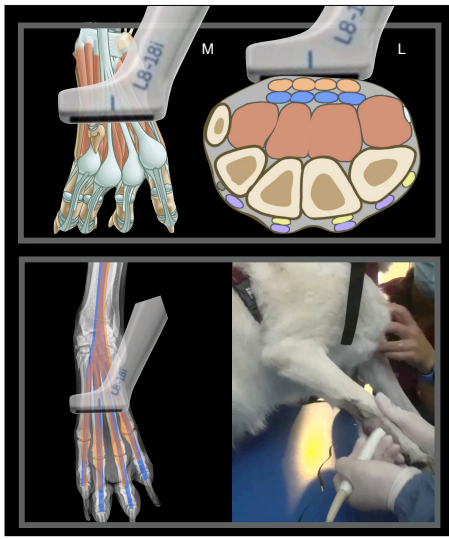

Max, Mn, 4 years

Right metacarpus

Transverse scan plan second-third metacarpal bone plantar face

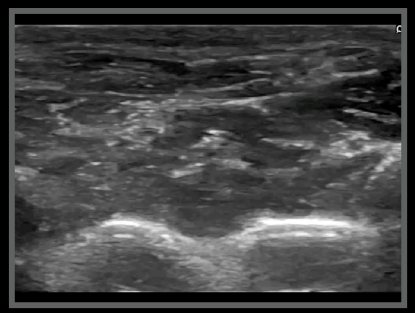

www.imaios.com

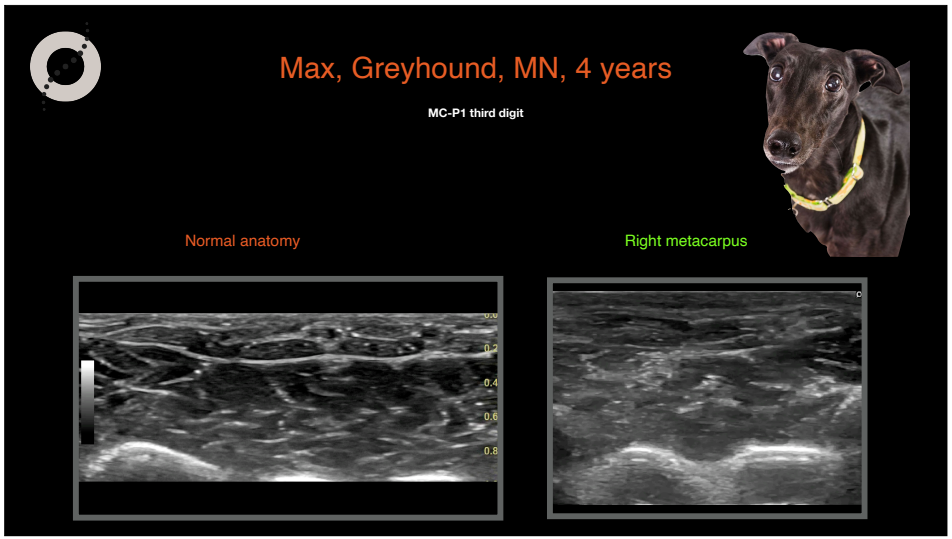

Max, Greyhound, MN, 4 years

Ultrasonographic diagnoses (right third front digit):

- Severe effusion MC-P1 joint
- Severe tendon sheath effusion of the deep flexor tendon
- Core lesion of the distal portion of the deep flexor tendon

What next?

Max, Greyhound, MN, 4 years

- Custom made shoes
- Proprioceptive exercises to increase the flexor's tone
- Different activities to increase the general muscle tones

Thank you

Diagnostic Mindset

www.diagnosticmindset.com