

Abdominal positioning

How to perform a correctly positioned
VD abdominal radiographic view in dogs



Diagnostic Mindset

Thanks to Clinica Veterinaria Castellarano



Giliola Spattini
DVM, PhD, DECVDI

Alex, Italian short-haired Segugio, MI, 7 years

- Chronic cough
- Suspected to have ingested a bone



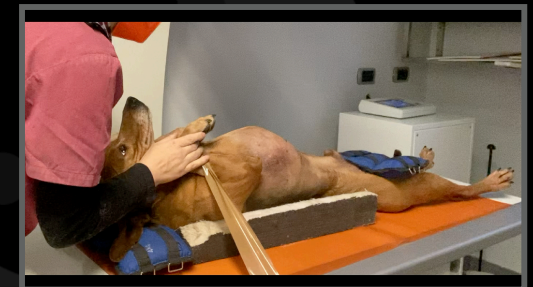Abdominal positioning VD

- Put the dog on the table, standing
- Flip the patient gently
- Use an holding device





Abdominal positioning VD

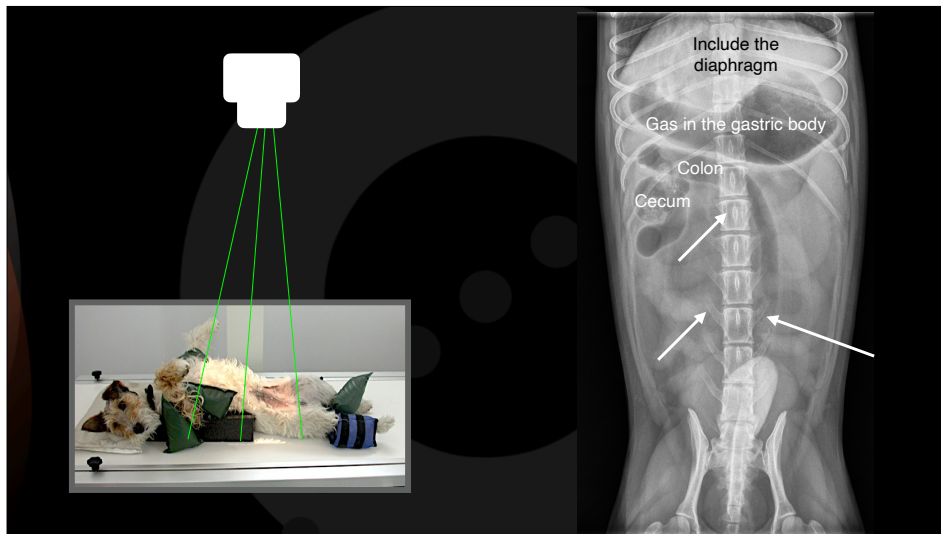
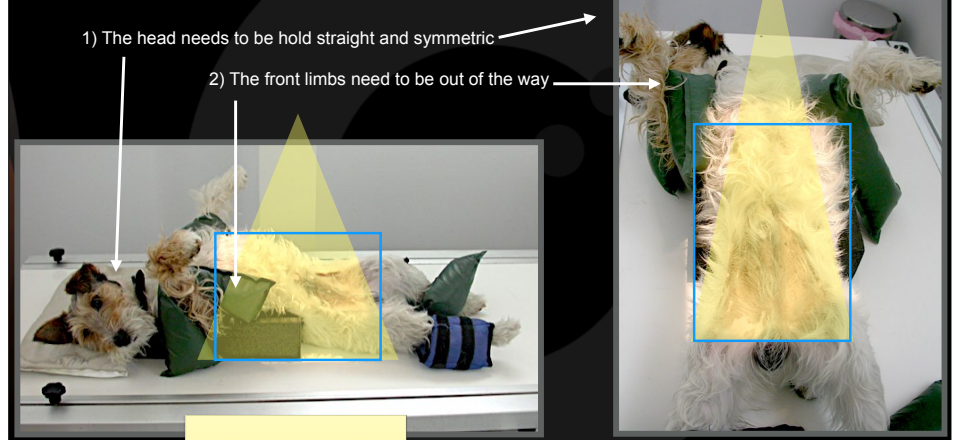
- Gently extend the head
- Put a holding bag on the mandible
- Keep the patient relaxed



Abdominal positioning



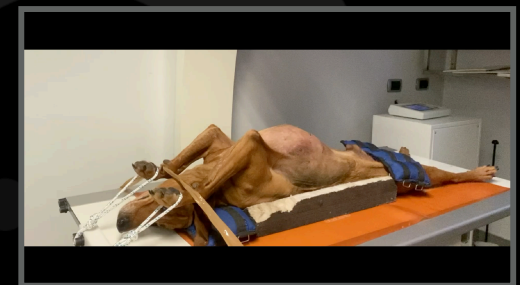Abdominal positioning VD



Abdominal positioning

Aftercare VD view

- Gently remove the tape
- Gently remove the ropes
- Hold and keep the dog relaxed



Thank you



Diagnostic Mindset

www.diagnosticmindset.com