

Systematic approach to abdominal radiology



Giliola Spattini
DVM, PhD, DECVDI


Objectives

1. Optimise the exposure
2. Optimise the positioning
3. Systematic evaluation



How to reduce the mistakes:

- To be systematic !
- To be systematic !
- To be systematic !
- To be systematic !
- To be systematic !
- To be systematic !
- To be systematic !
- To be systematic !
- To be systematic !



QUALITA'			COMMENTI
ESPOSIZIONE	OK	ERRATA	
POSIZIONAMENTO	OK	ERRATO	
IDENTIFICAZIONE	OK	ERRATA	
SVILUPPO	OK	ERRATO	
ARTIFATTI	OK	ERRATI	
INTERPRETAZIONE			
TESSUTI MOLLI EXTRA-ADDOMINALI	OK	NON OK	
STRUTTURE OSSEE	OK	NON OK	
PARETE ADDOMINALE	OK	NON OK	
TORACE CAUDALE	OK	NON OK	
DIAGRAMMA	OK	NON OK	
FEGATO	OK	NON OK	
MILZA	OK	NON OK	
STOMACO	OK	NON OK	
PANCREAS	OK	NON OK	
PICCOLO INTESTINO	OK	NON OK	
GROSSO INTESTINO	OK	NON OK	
CAVITA' PERITONEALE	OK	NON OK	
SPAZZO RETROPERITONEALE	OK	NON OK	
RENI	OK	NON OK	
VESICULA	OK	NON OK	
PROSTATI	OK	NON OK	

• Valutazione sistematica

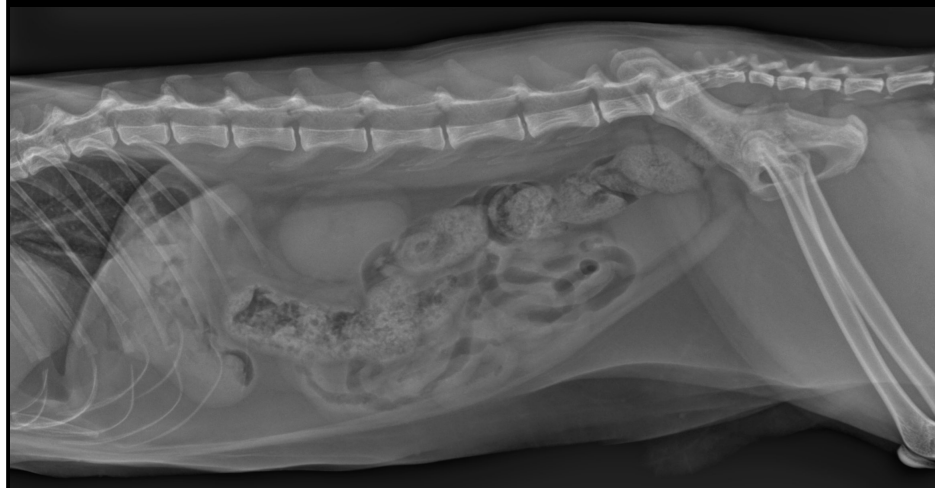
UTERO ED OVAIE	OK	NON OK	
LINFONODI	OK	NON OK	
SE TUTTO OK			ADDOME NEI LIMITI DELLA NORMA
DIAGNOSI RADIOGRAFICA			
DIAGNOSI DIFFERENZIALI			
COME CONTINUARE			

Duffy, DHS, FS, 7 years

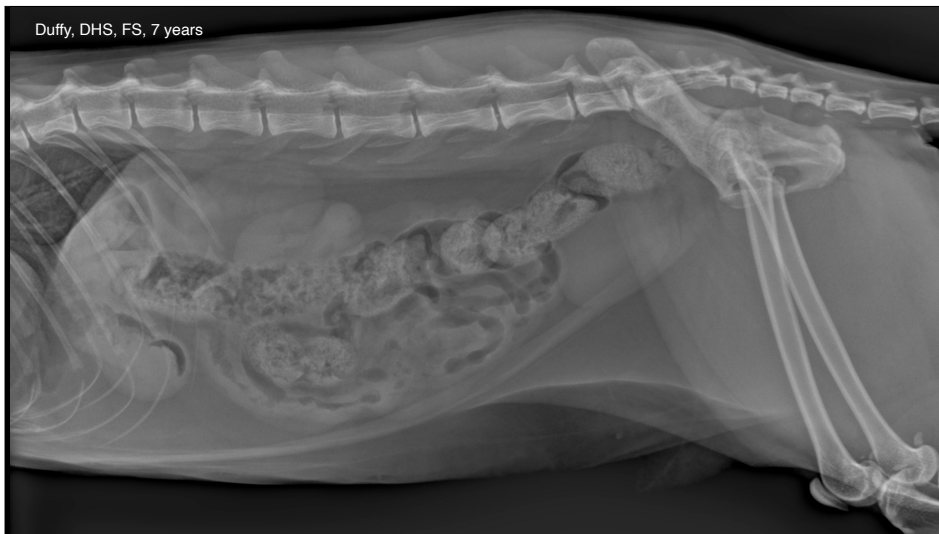
- Attacked by a dog
- Laceration of the soft tissues between the shoulder blades and swelling on the abdominal wall
- Abdominal perforation?



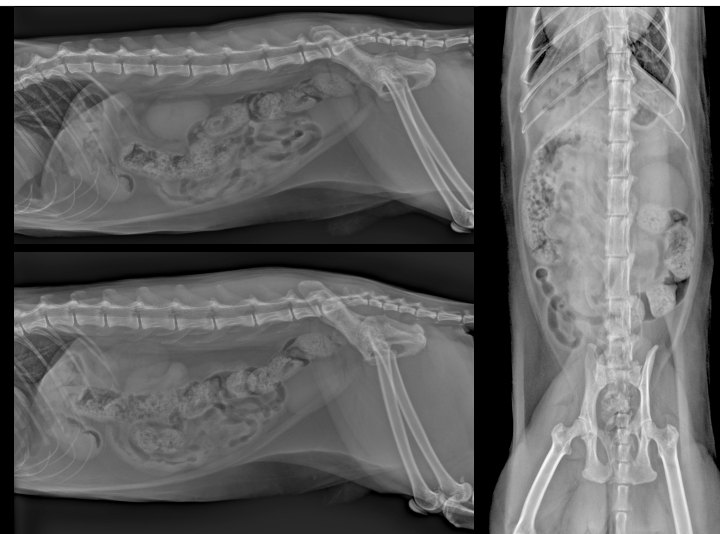
Duffy, DHS, FS, 7 years



Duffy, DHS, FS, 7 years



Duffy, DHS, FS, 7 years



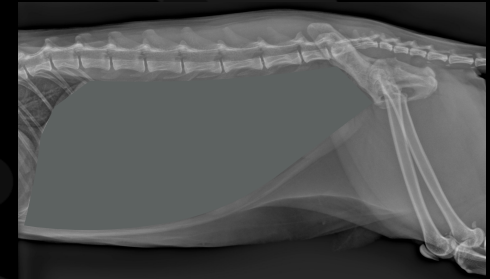
Your evaluation

- Is there hip dysplasia?
- Is there hepatomegaly?
- The stomach is full?



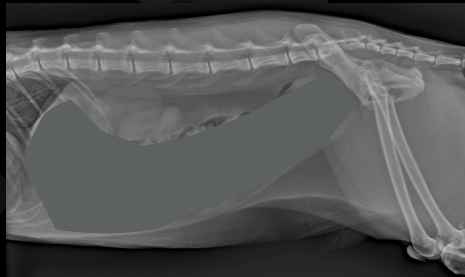
Systemic evaluation: 1

- Extra-abdominal structures:
 - Thorax
 - Vertebral column
 - Pelvis and hind limbs
 - Subcutaneous tissues
 - Abdominal walls



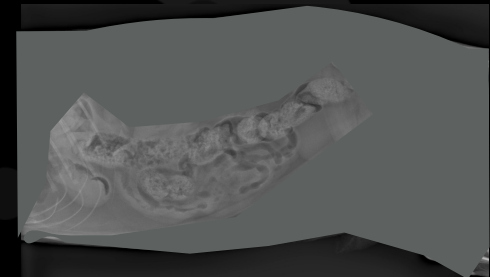
Systemic evaluation: 2

- Retroperitoneal space



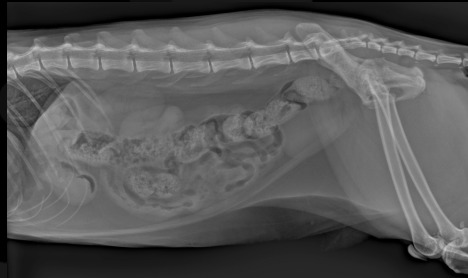
Systemic evaluation: 3

- Peritoneal space:
 - How is the detail?
 - How is the contrast?



Systemic evaluation: 4

- The abdominal organs:
 - Evaluation by Roentgen numbers



Roentgen Numbers

- Opacity
- Size
- Shape
- Margins
- Position
- Numbers



You need to know the normal to be able to understand the abnormal

Radiopacity

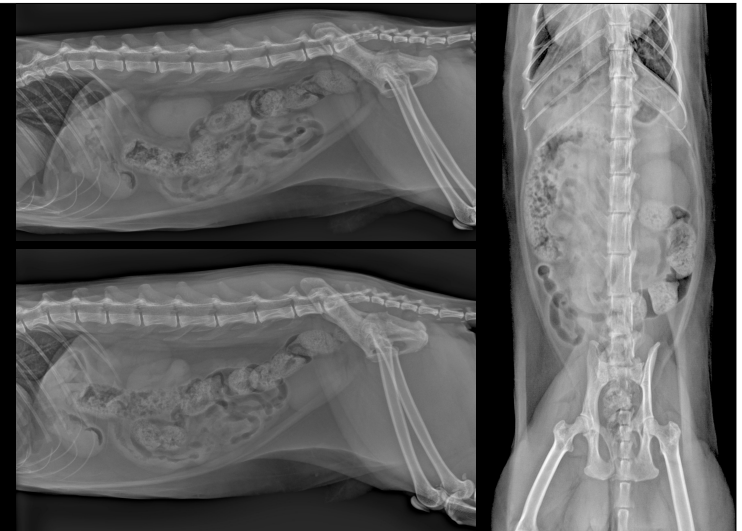
Opacity >>

<< Opacity



Duffy, DHS, FS, 7 years

Radiographic diagnoses



Duffy, DHS, FS, 7 years

Radiographic diagnoses:

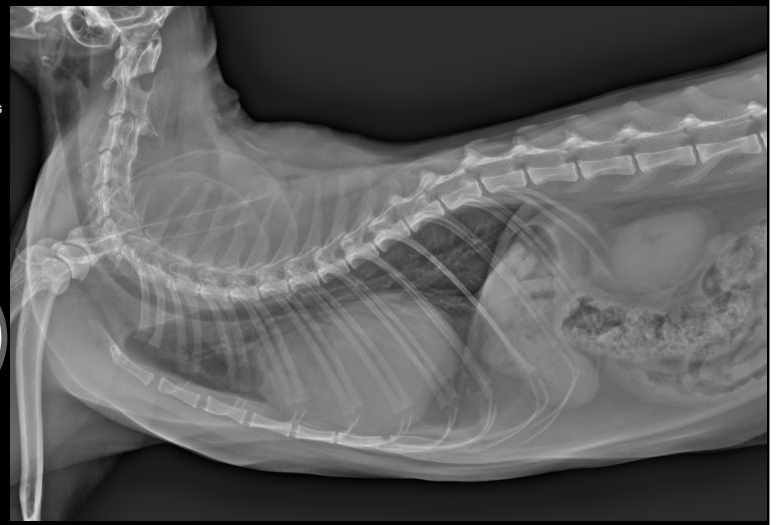
- Displaced-absent liver
- No signs of abdominal perforation

Conclusions:

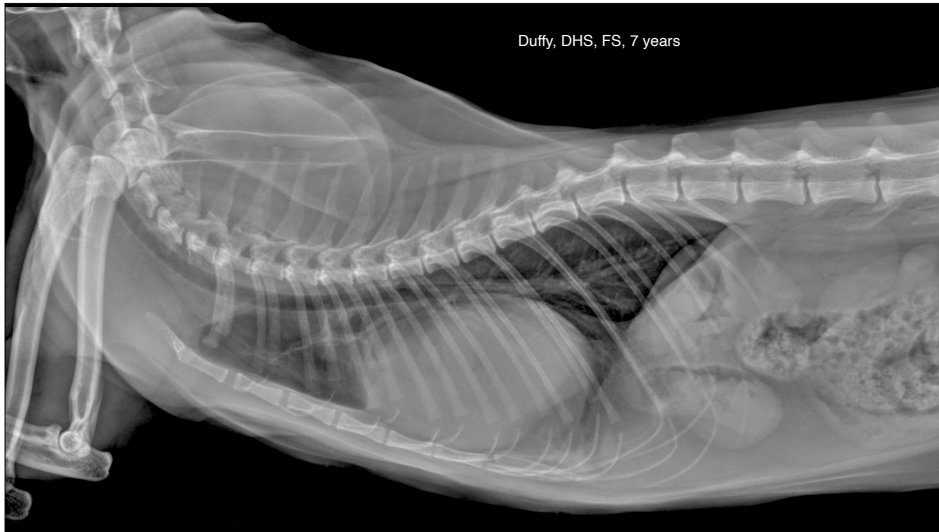- Suspected ruptured diaphragm or PPDH
- Thoracic imaging



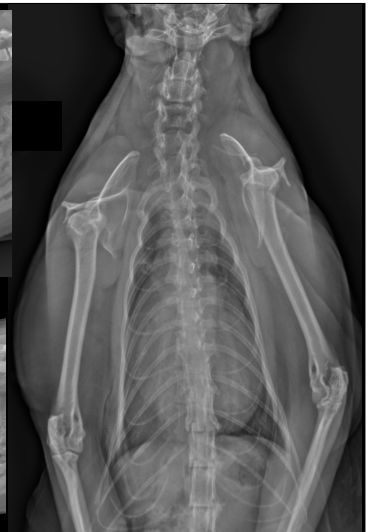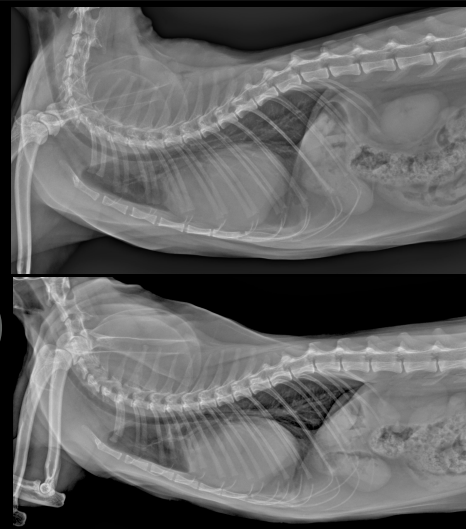
Duffy, DHS, FS, 7 years

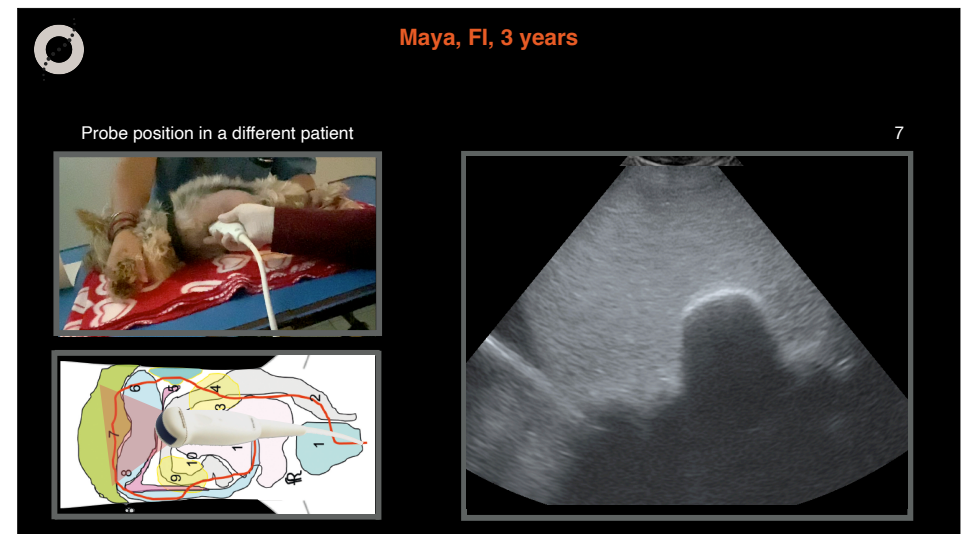
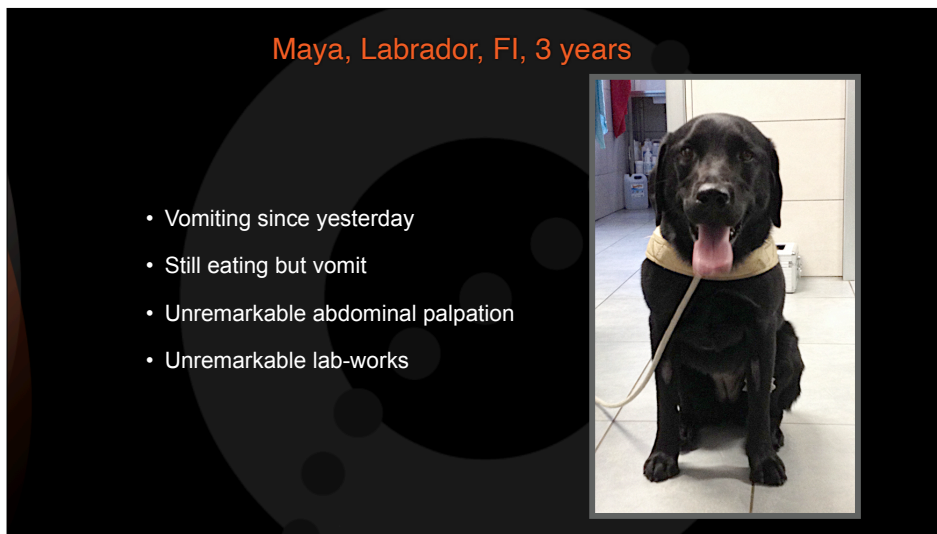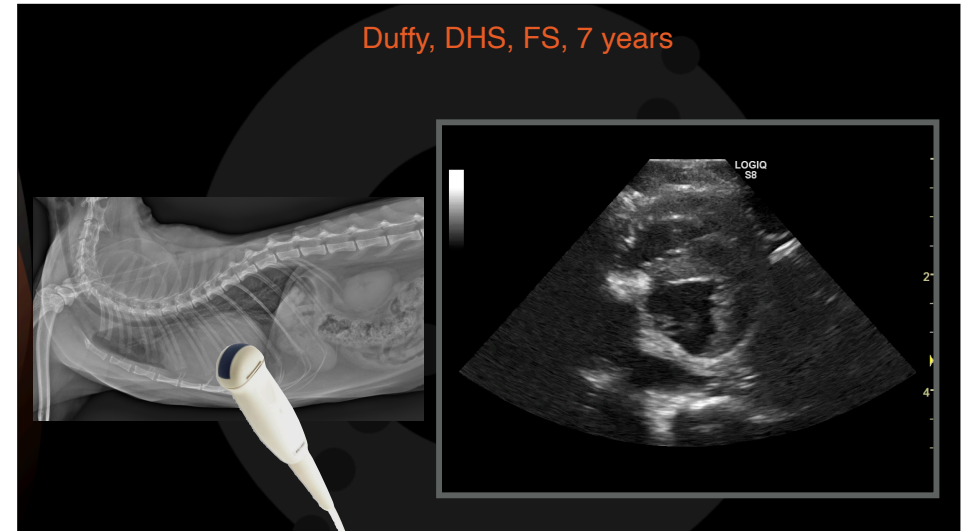
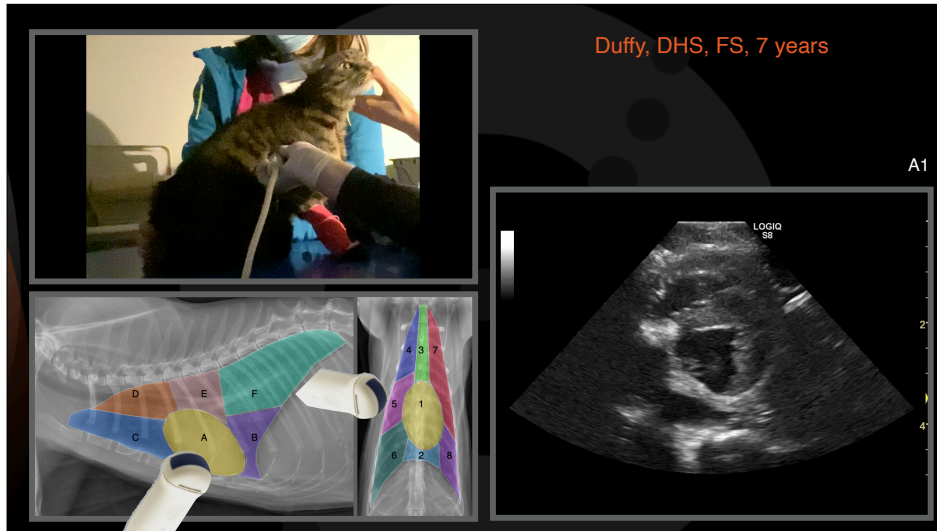


Duffy, DHS, FS, 7 years



Duffy, DHS,
FS, 7 years

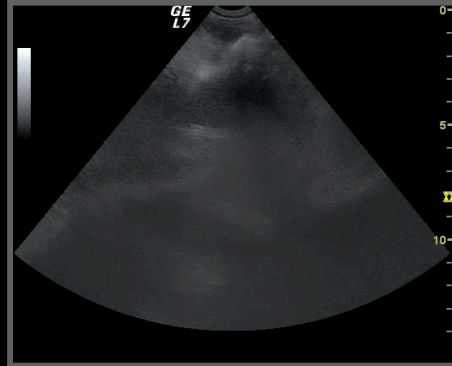
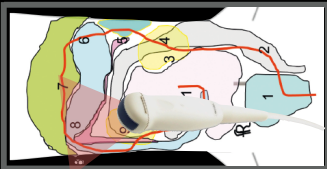
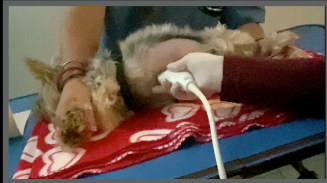





Maya, FI, 3 years

Probe position in a different patient

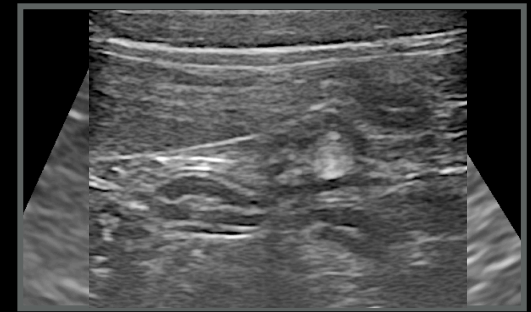
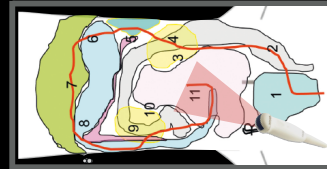
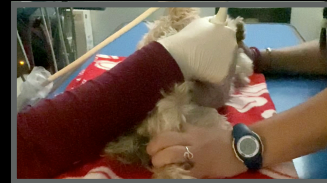

8



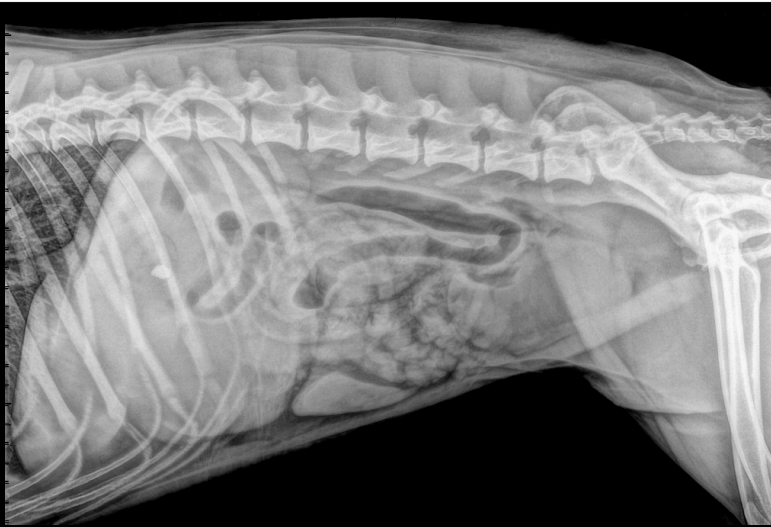
Maya, FI, 3 years

Probe position in a different patient

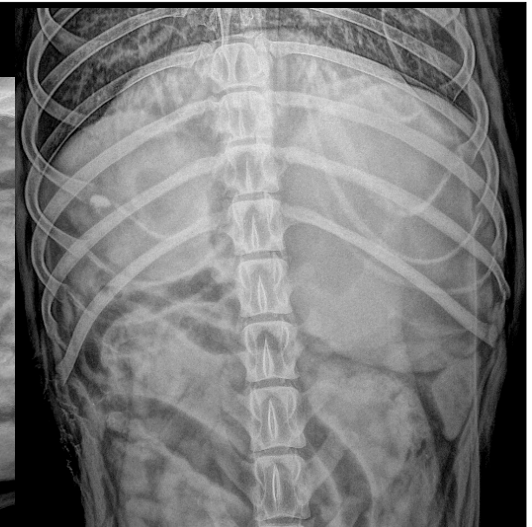
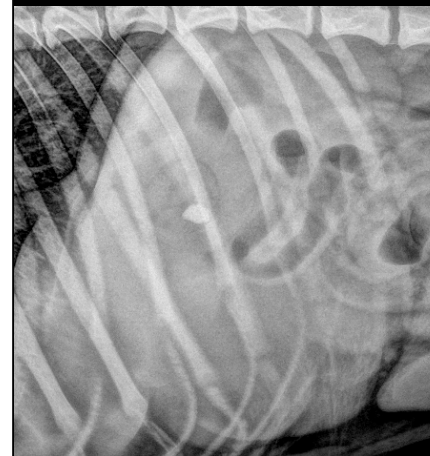


11

Maya, FI,
3 years



Maya, FI, 3 years



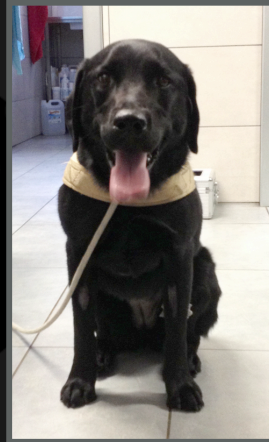
Maya, Labrador, FI, 3 years

Radiographic diagnoses:

- Pyloric obstruction by a FB

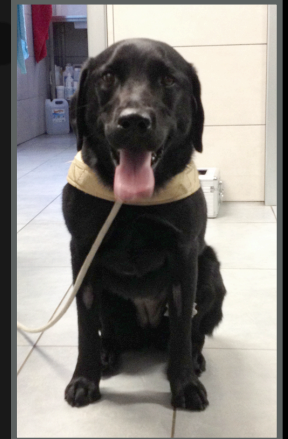

Conclusions:

- Surgery?
- Endoscopy?

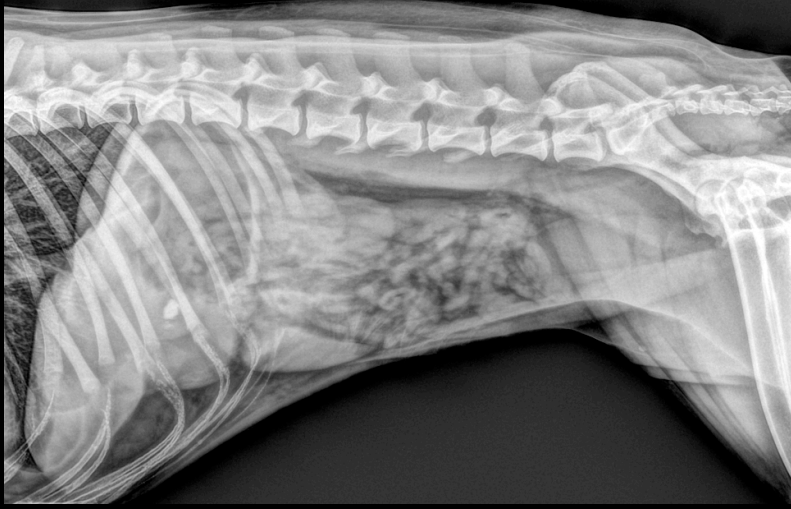


Maya, Labrador, FI, 3 years

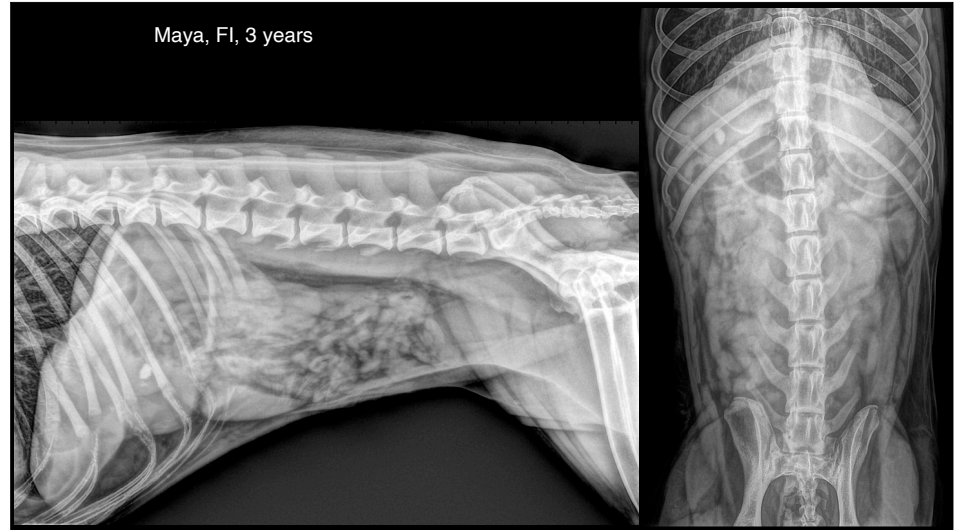
- While the medical team discuss about Maya, She vomits the foreign body!



Maya, FI,
3 years

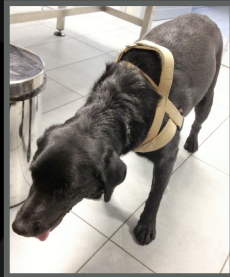


Maya, FI, 3 years



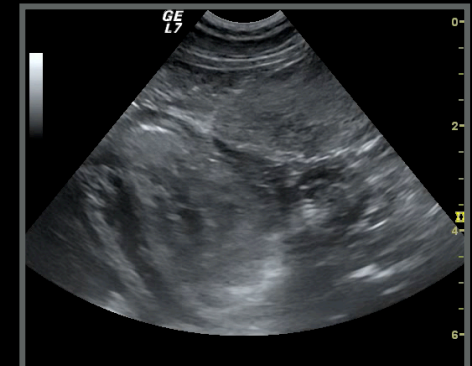
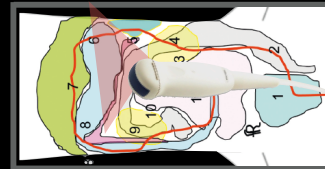
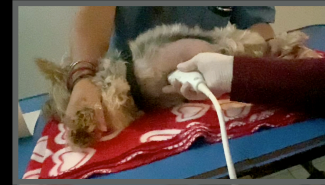Maya, Labrador, FI, 3 years

- Diagnosed a pyloric FB-resolved
- Send home, recheck in two days
- Come back the day after for acute vomiting
- Not eating
- Abdominal pain



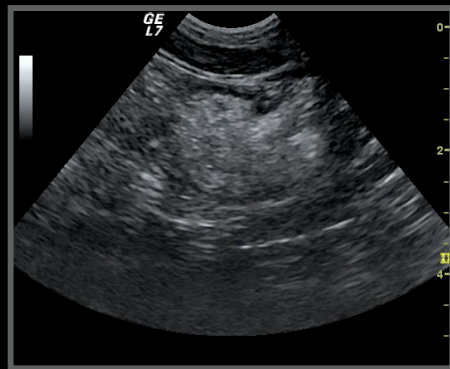
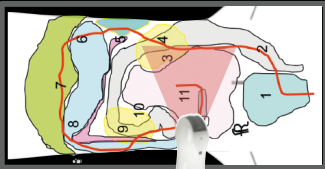
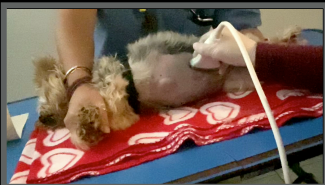Maya, FI, 3 years

Probe position in a different patient



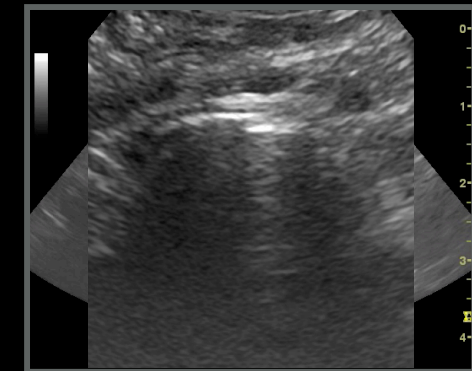
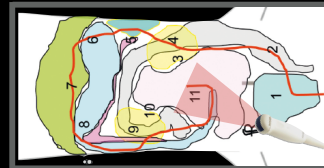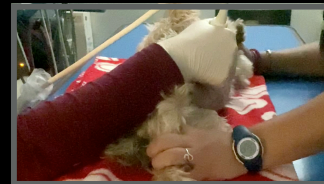Maya, FI, 3 years

Probe position in a different patient



Maya, FI, 3 years

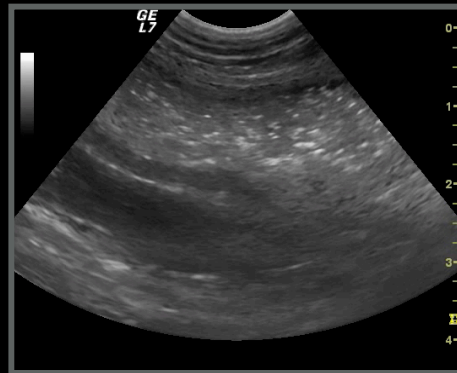
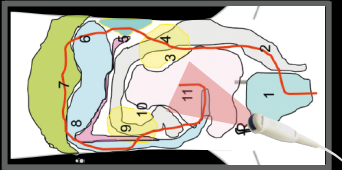
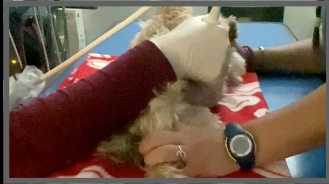Probe position in a different patient





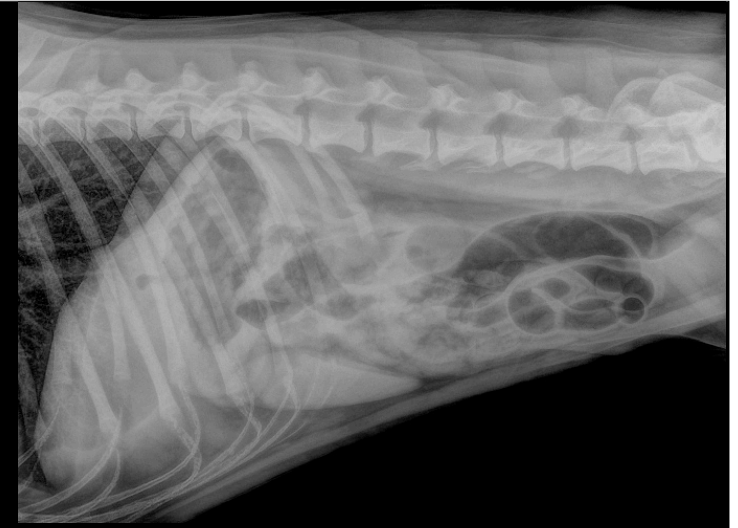
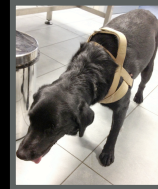Maya, FI, 3 years

Probe position in a different patient

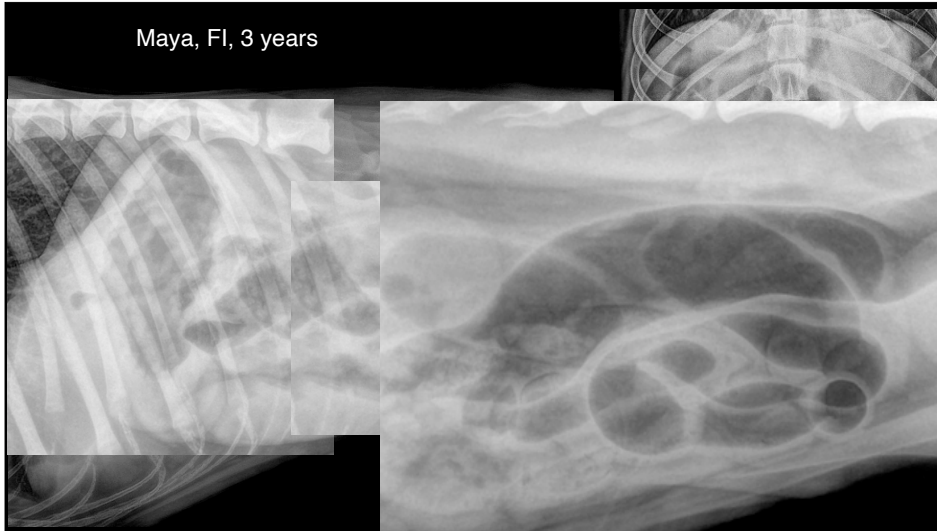


11

Maya, FI,
3 years



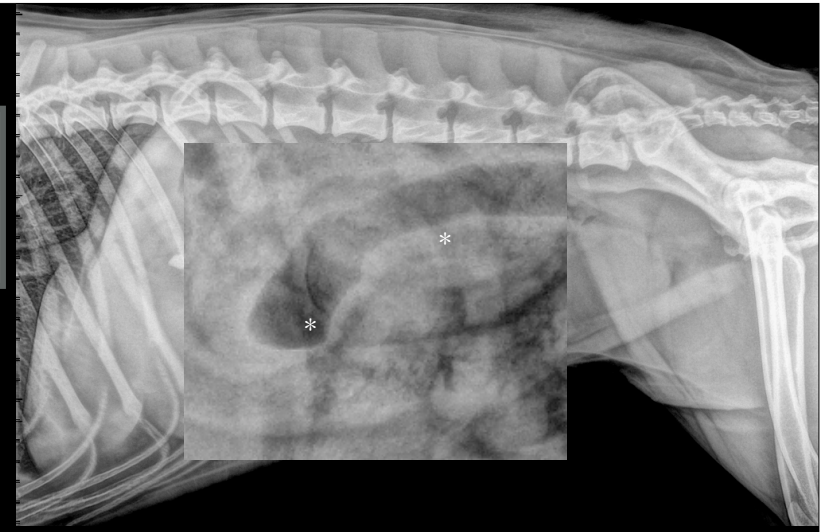
Maya, FI, 3 years

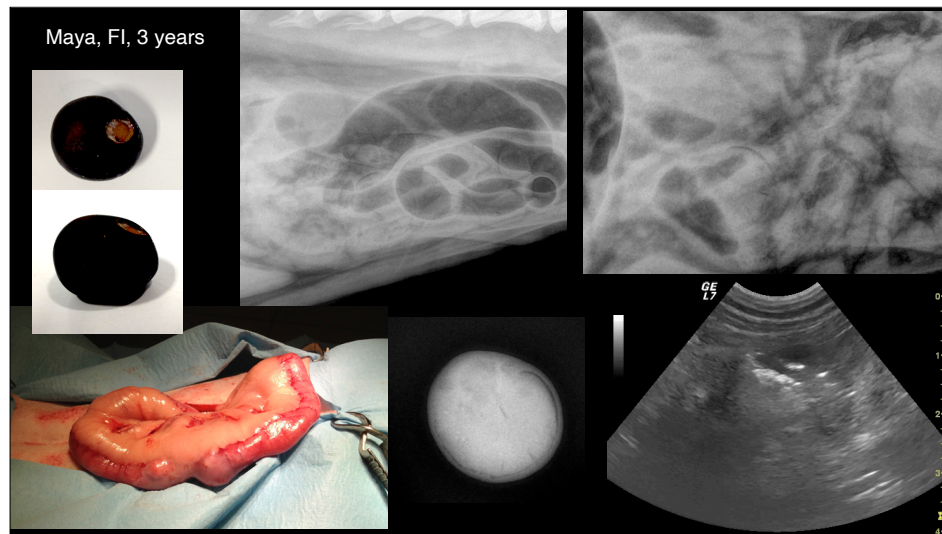


Maya, FI,
3 years



Revision!





Conclusions

To decrease the interpretation errors it is necessary to be systematic!!!

Thank you

Diagnostic Mindset
www.diagnosticmindset.com