

Il dettaglio addominale
nell'addome acuto:
radiologia od ecografia?

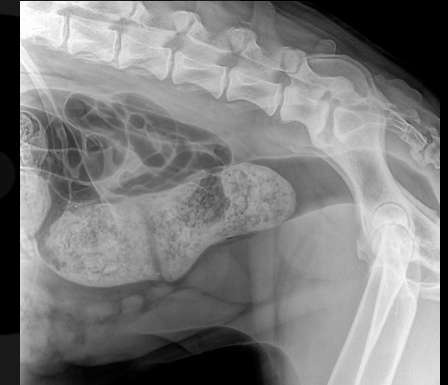

Giliola Spattini
DVM, PhD, DECVDI



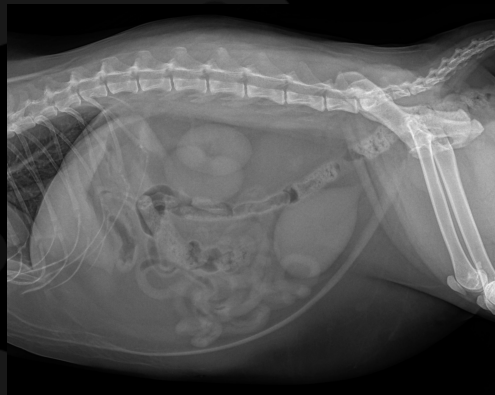Why radiology is used in medicine?

- Because they have interactions with the biological tissues
- Because the fat is different than soft tissue :-)
- Unfortunately fluid and parenchymas have the same opacity :-)

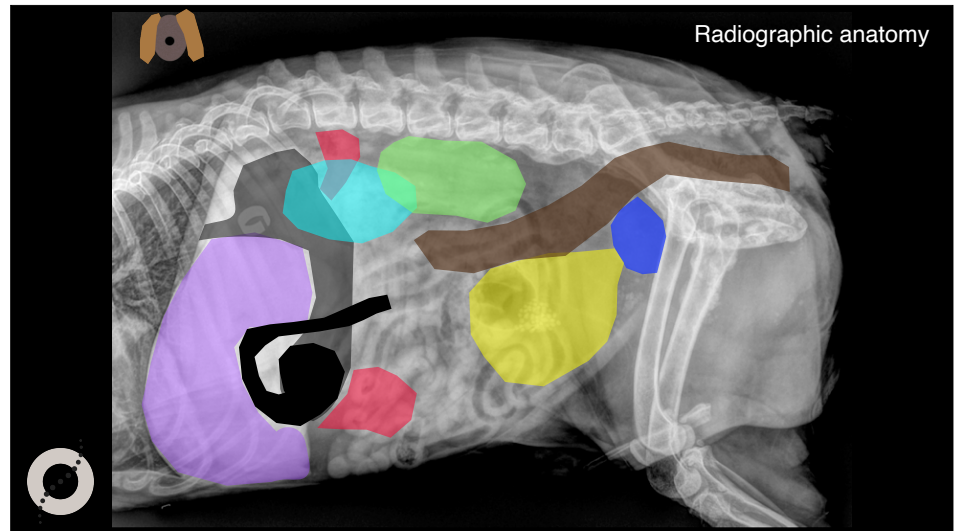


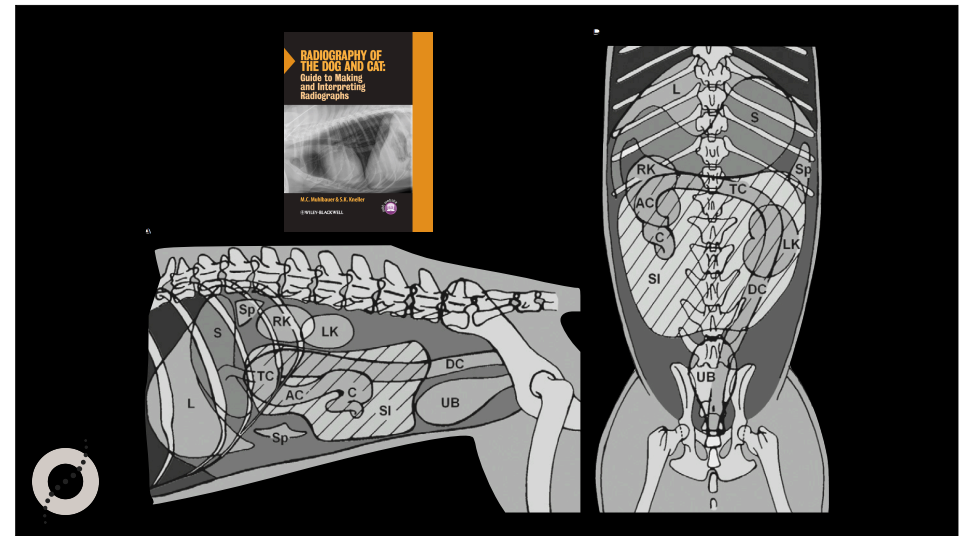
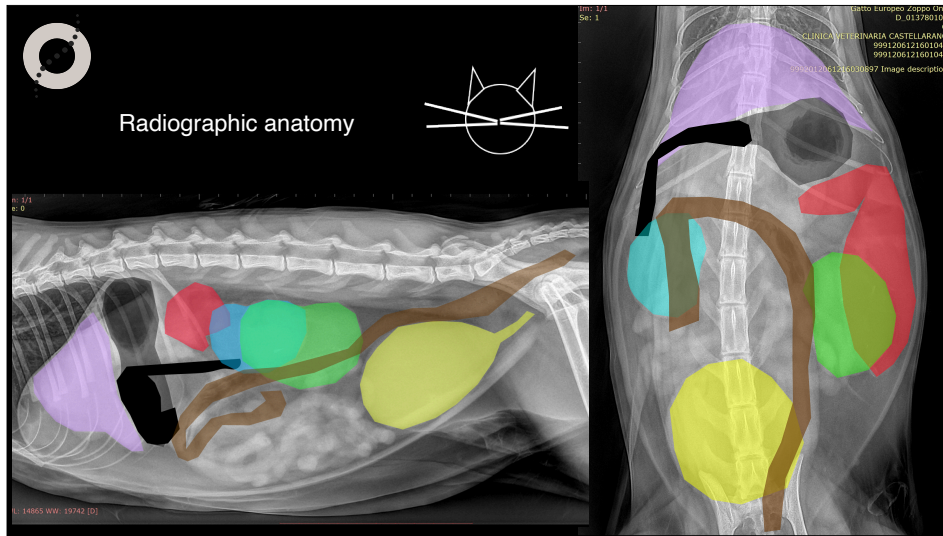
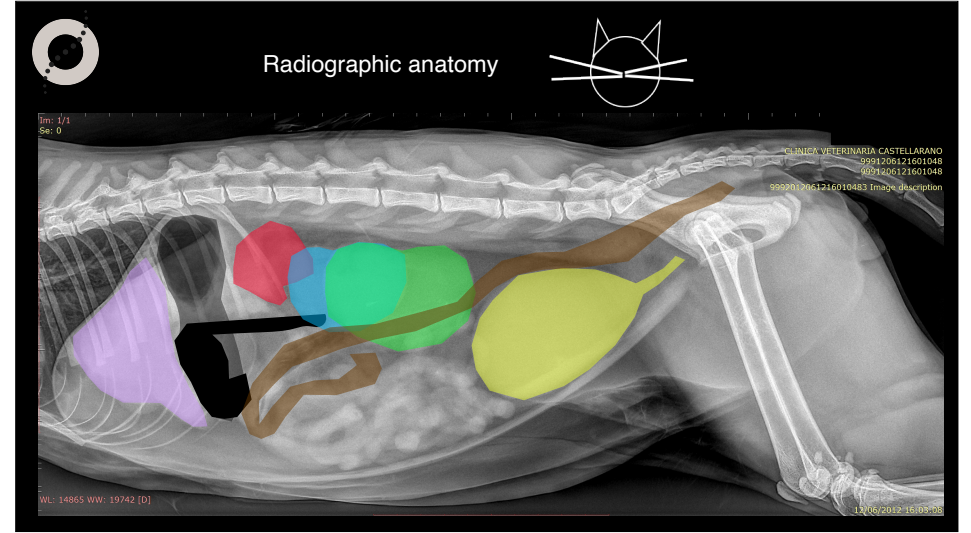
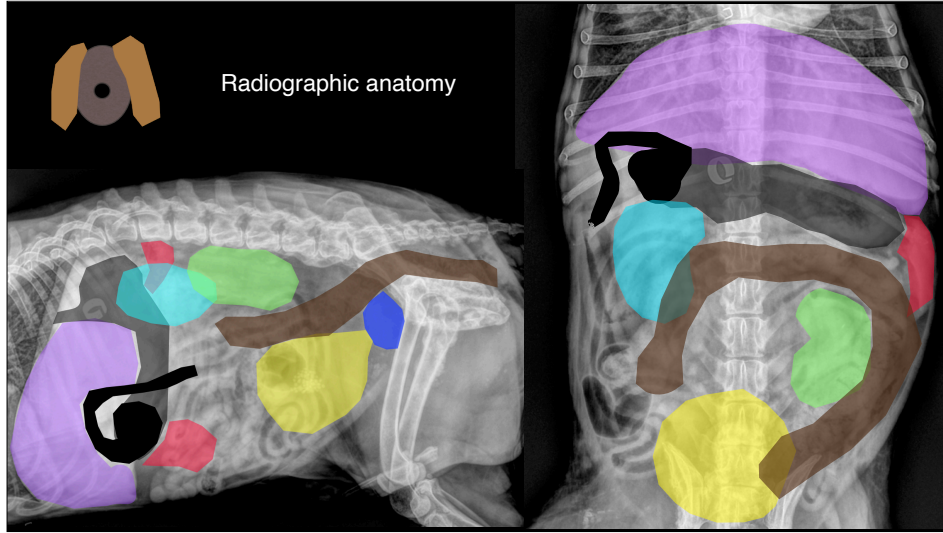
Which factors determine the abdominal details?

- Fat deposition (age, breed...)
- Thickness
- Body condition score
- Anatomy of the different quadrants

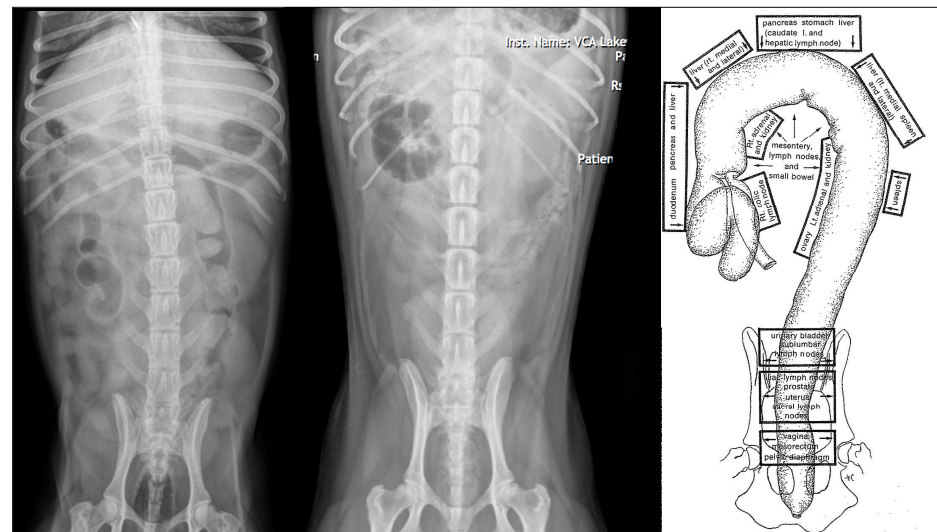
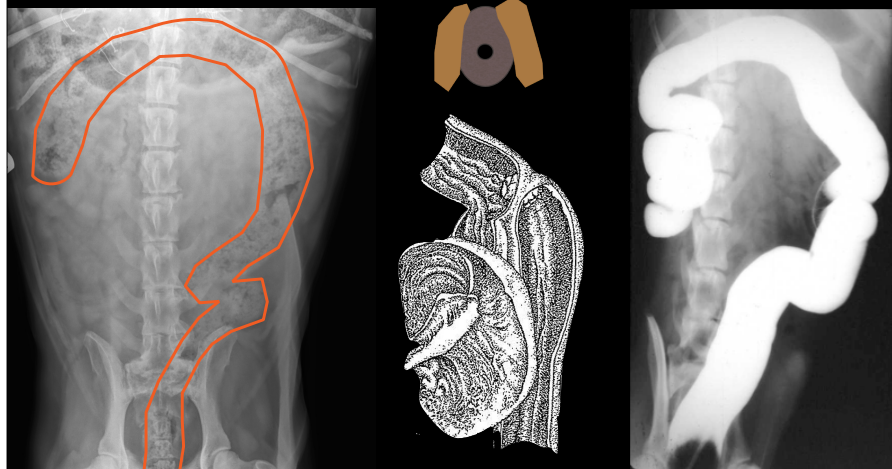


Radiographic anatomy

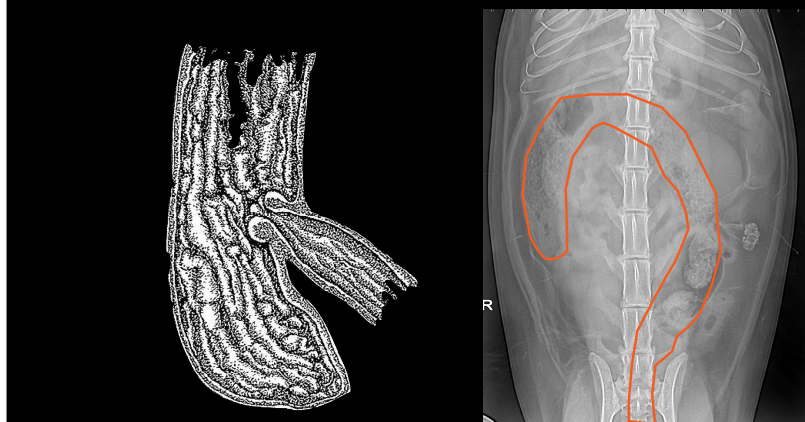




The colon and the cecum in the dog



The colon and the cecum in the cat



Abdominal detail

- Within normal limits
- Increased



- Decreased/absent

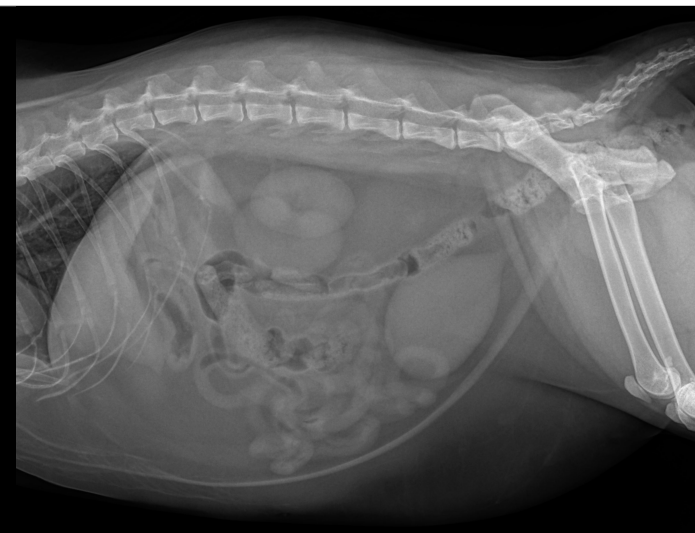


Beemer, DSH, MN, 9 years

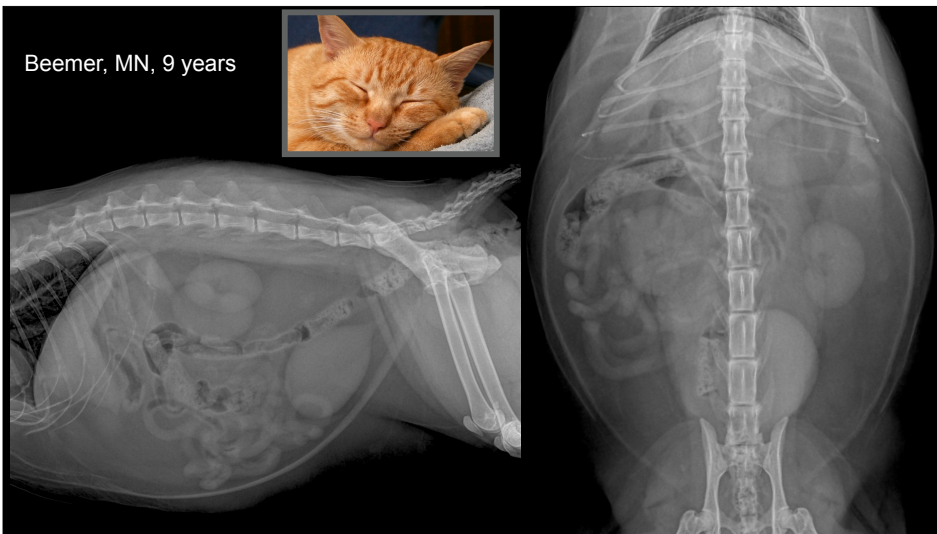

- Senior wellness



Beemer, MN, 9 years



Beemer, MN, 9 years



Beemer, DSH, MN, 12 years

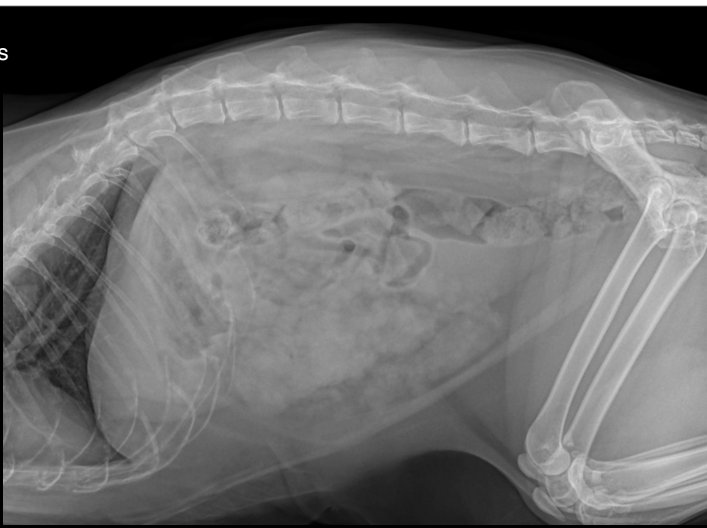
Loosing weight

Anorexic


Lethargic



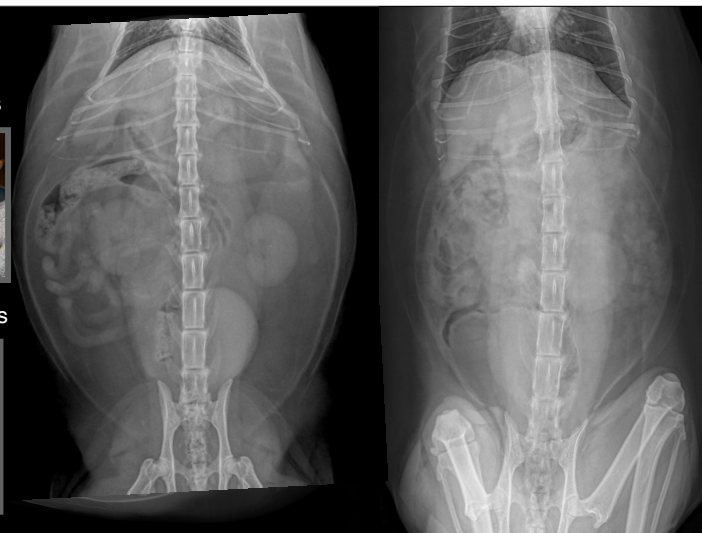
Beemer, MN, 12 years



Beemer, MN, 9 years



Beemer, MN, 12 years



Differential diagnoses for altered abdominal details:

Artefacts

Wet fur
Subcutaneous emphysema
Subcutaneous edema

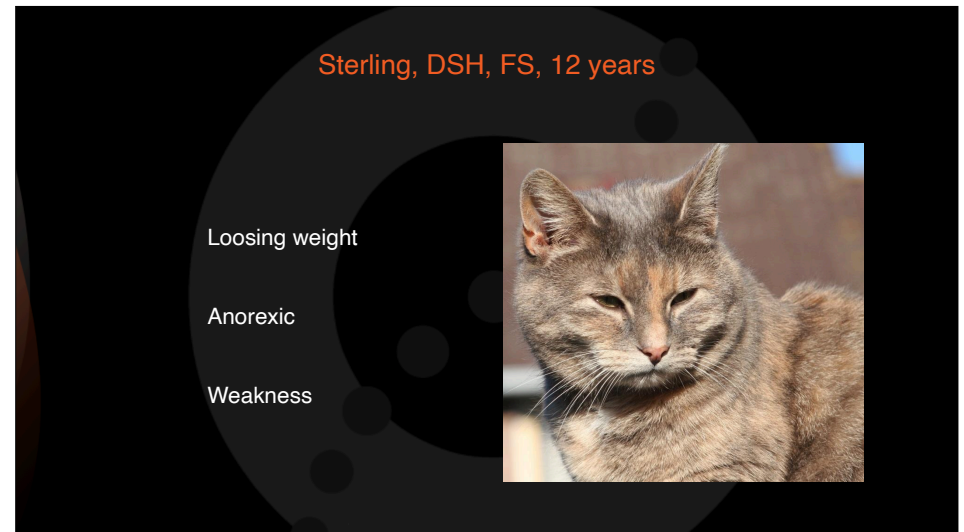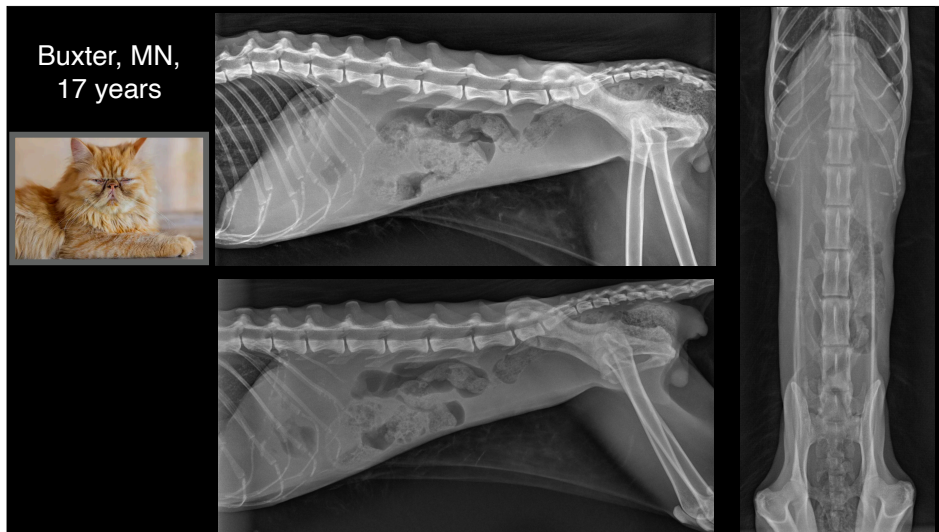
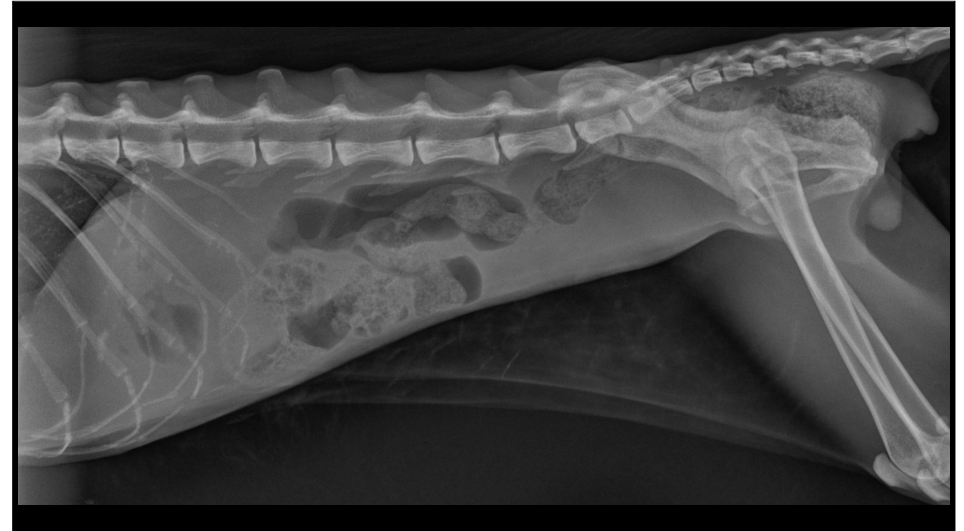
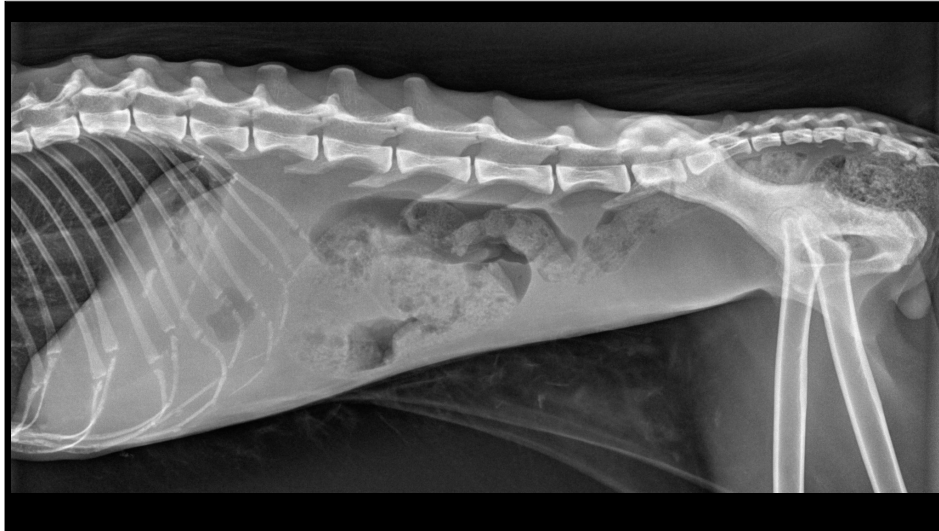
Pathologies

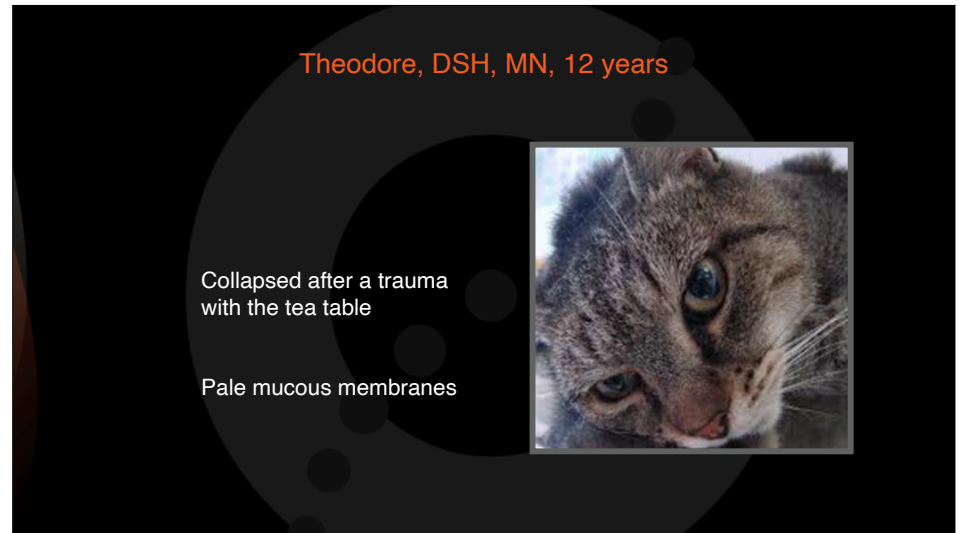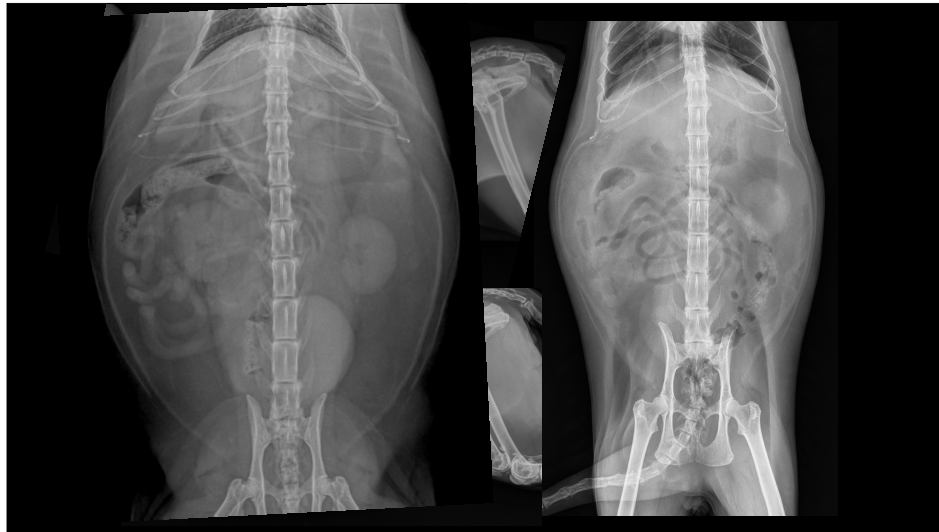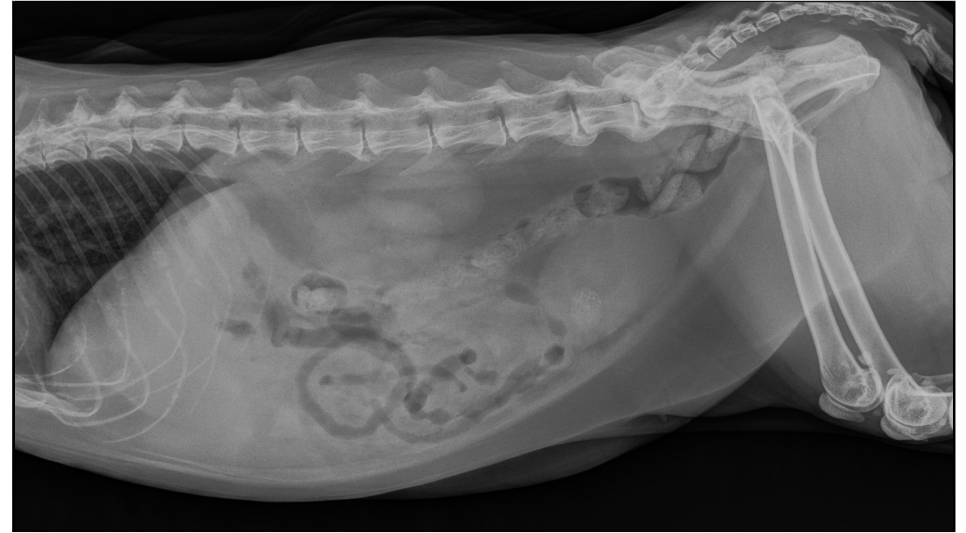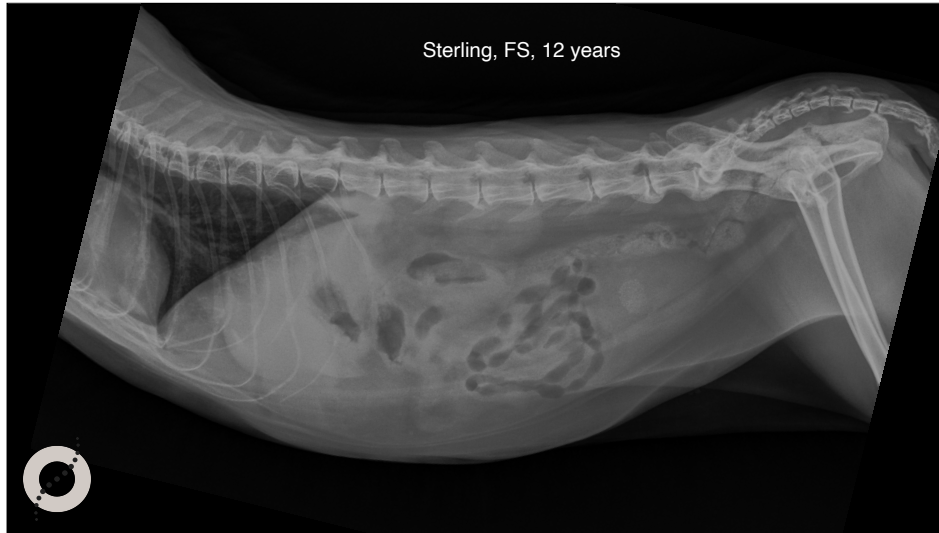Peritonitis
Carcinomatosis
Pancreatitis
Focal infection-abscess
Minimal fluid accumulation

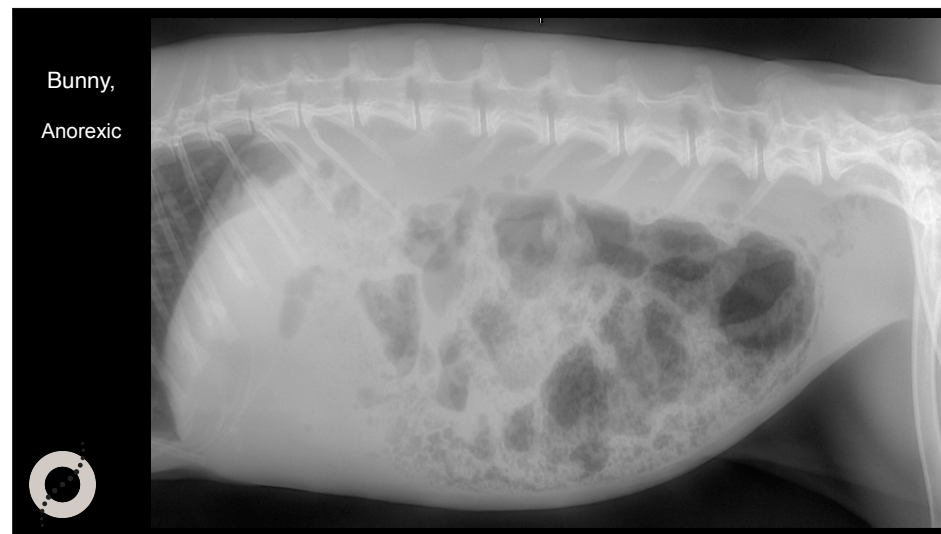
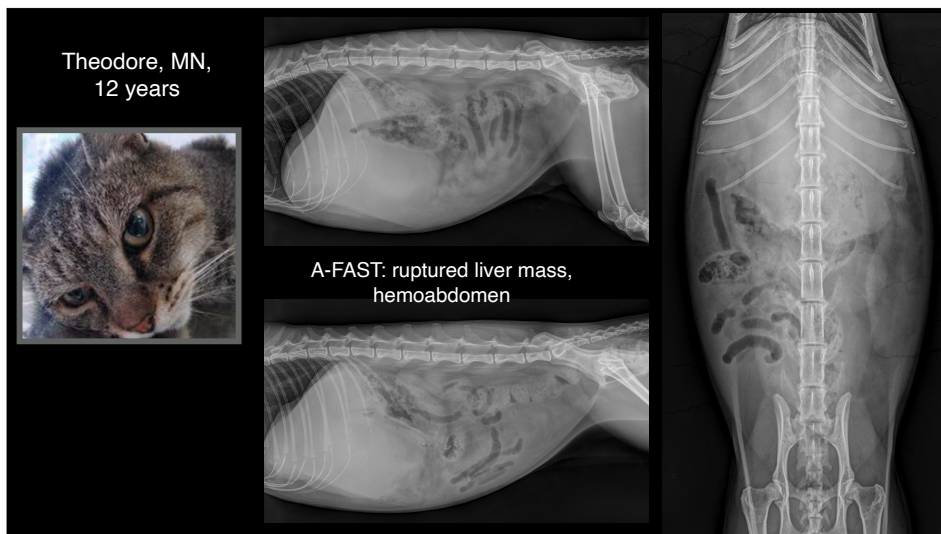
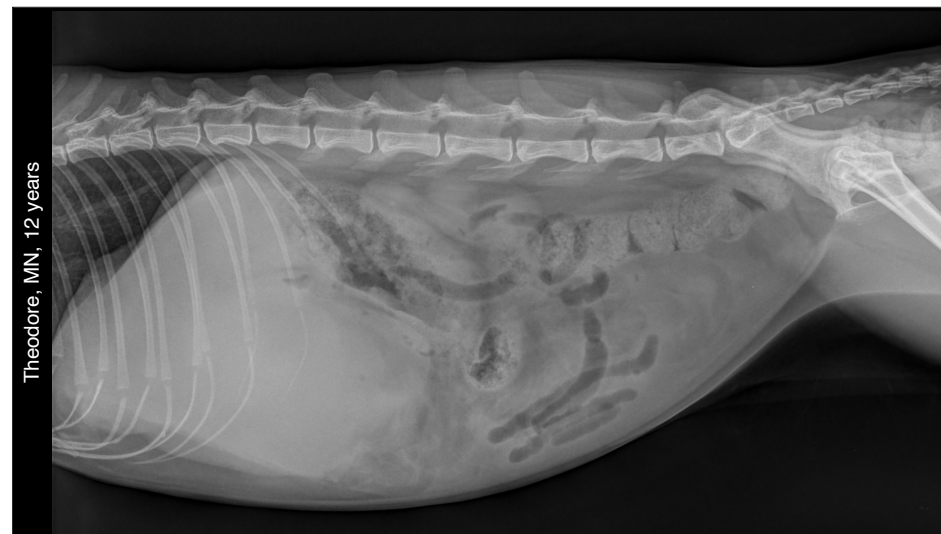
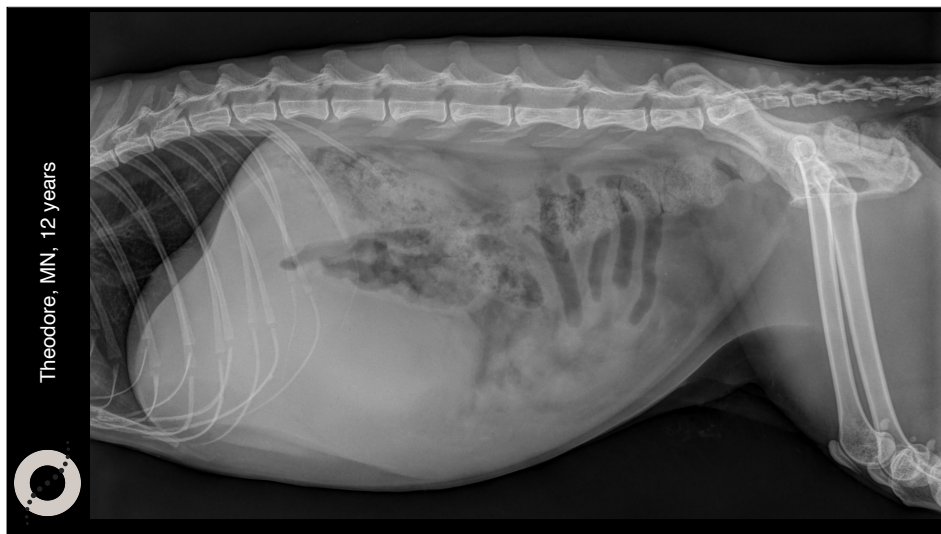
Buxter, Persiano, MN, 17 years

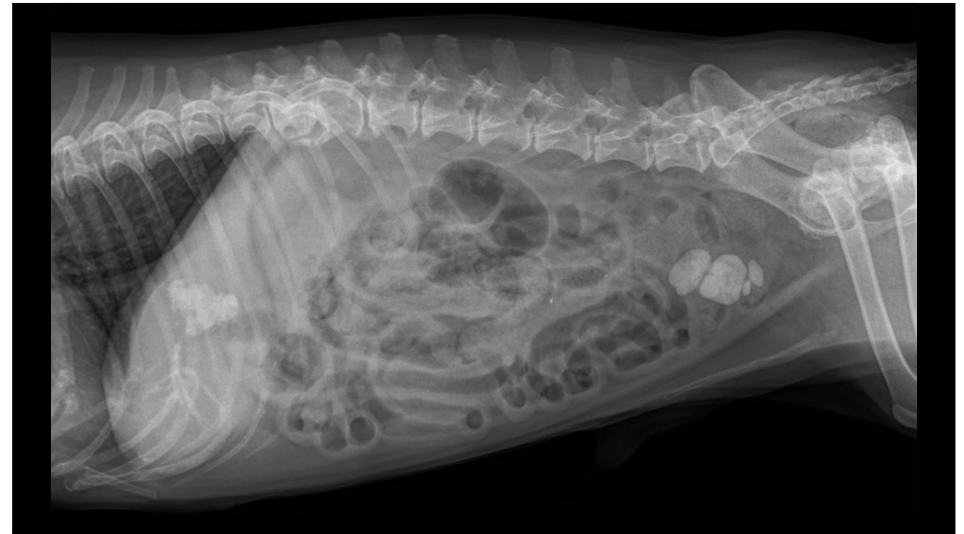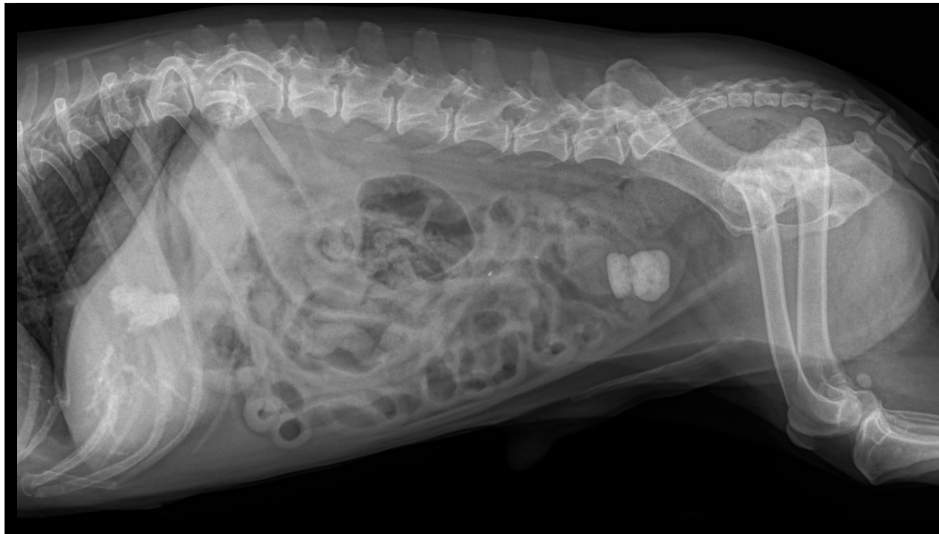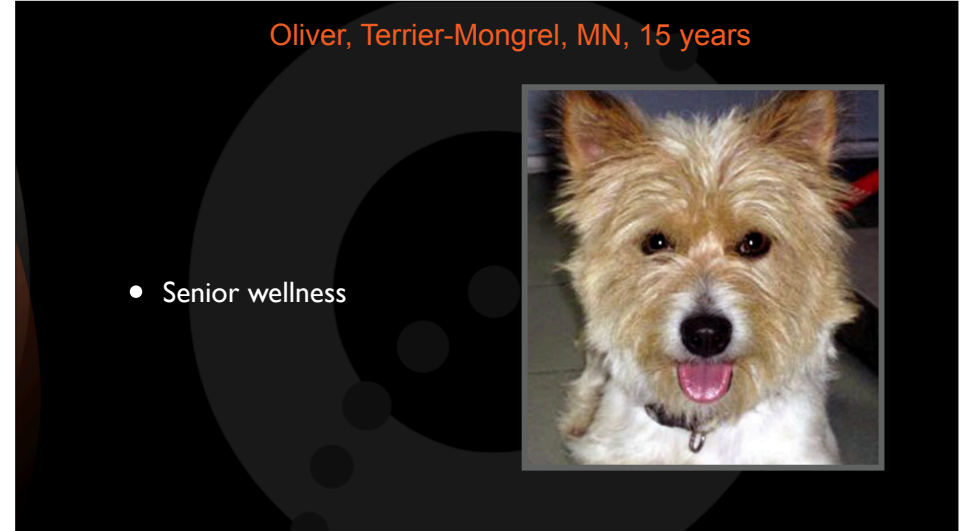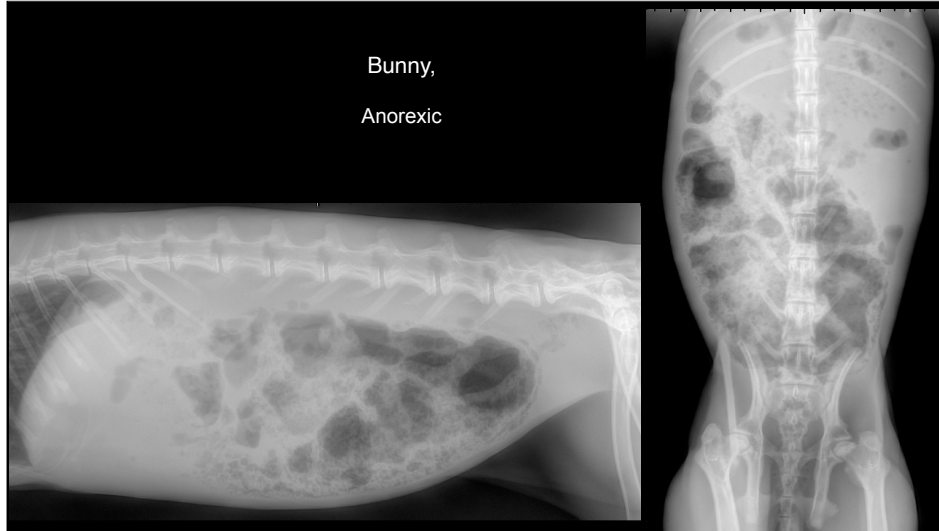- Constipation
- Lethargic
- Back pain?

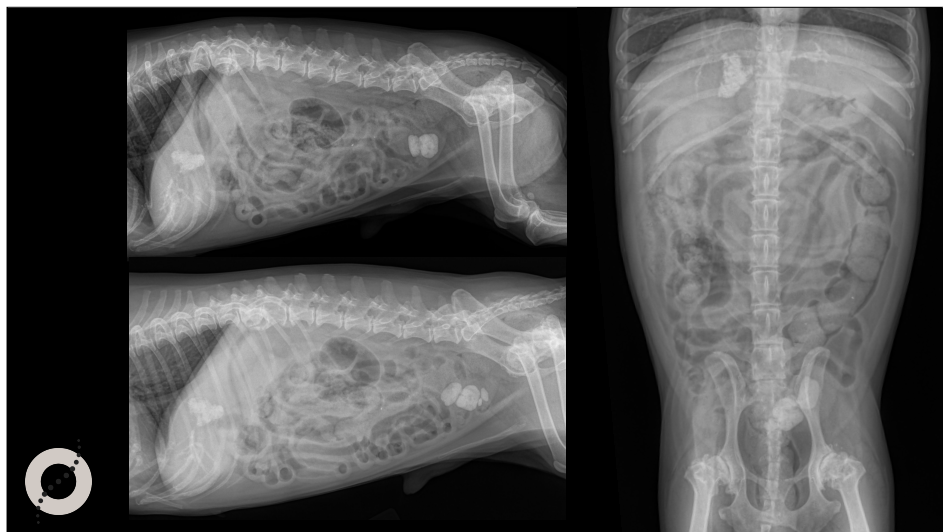






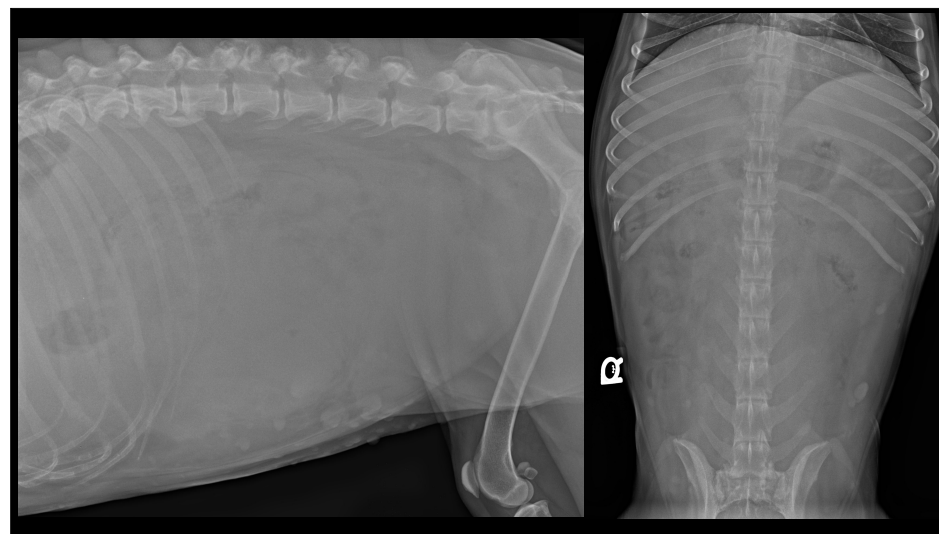
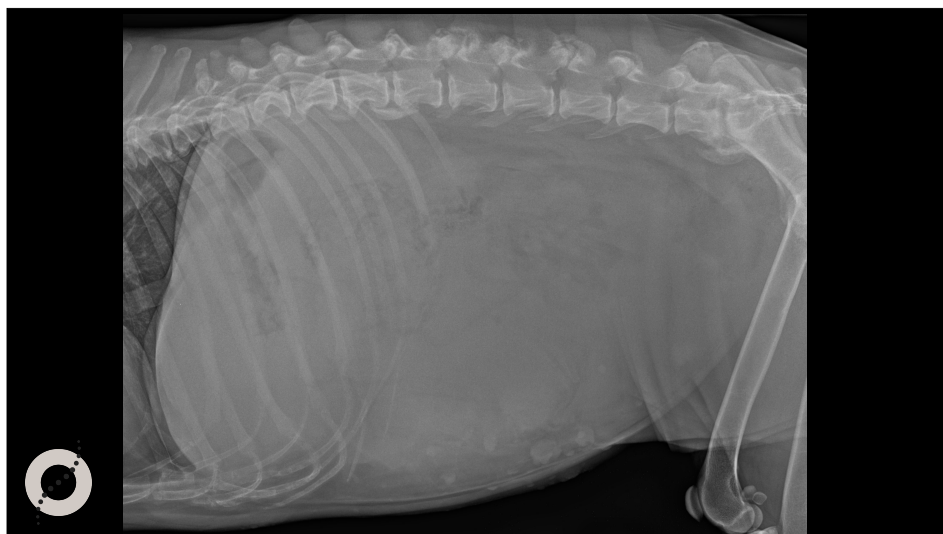





Lucy, Pitbull, FS, 12 years

- Back pain
- Now pale mucous membrane and not moving

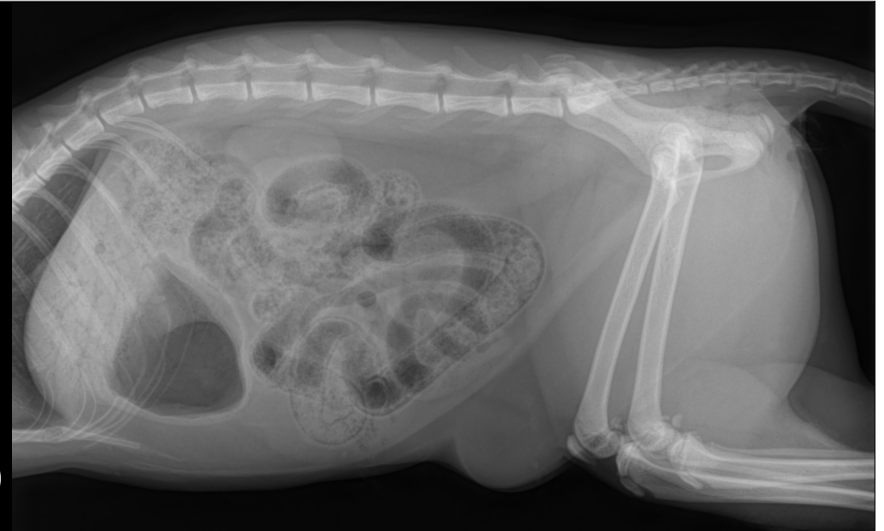

Fiona, DHS, FS, 5 months

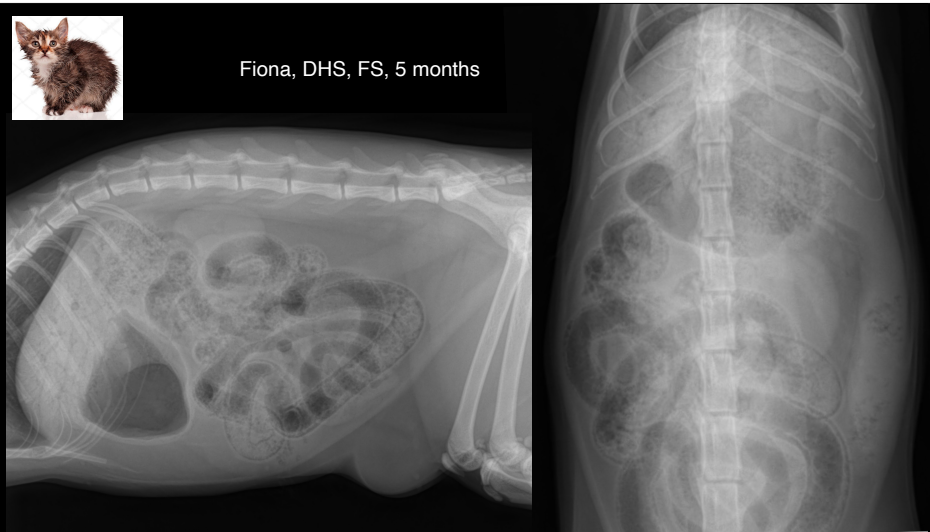
- Blocked in the washer
- Now stuporous



Fiona, DHS, FS, 5 months



Fiona, DHS, FS, 5 months



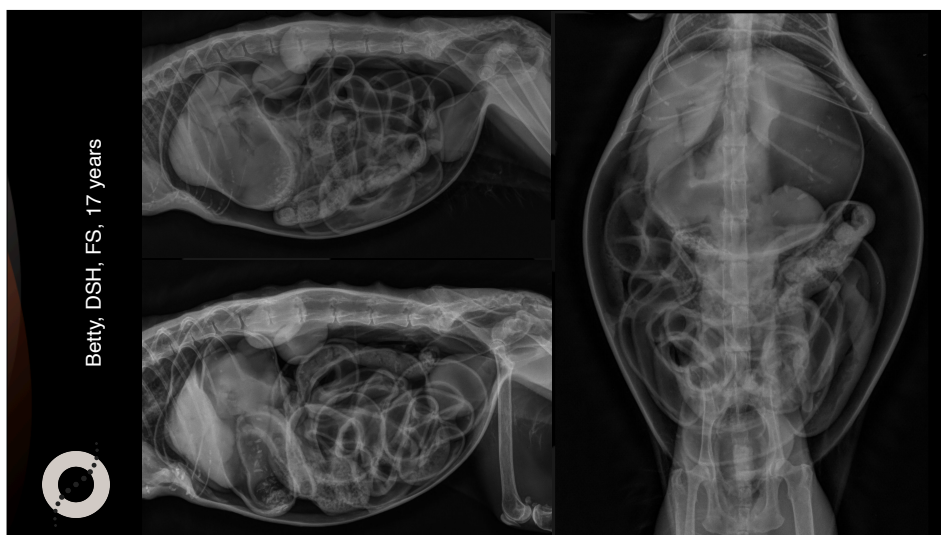
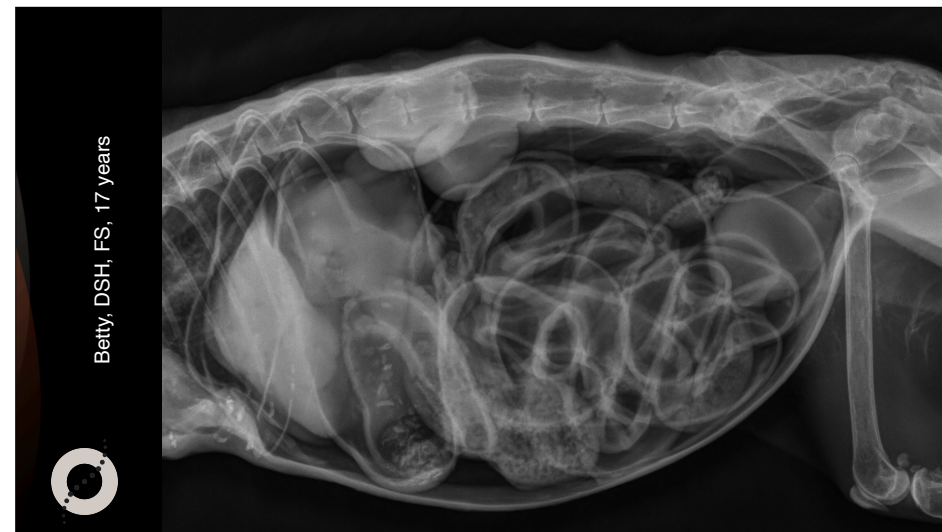
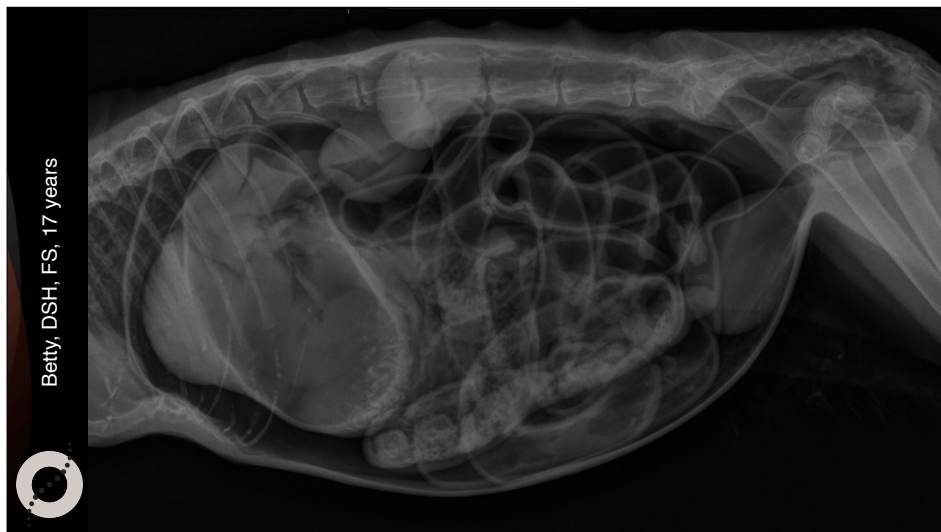
Betty, DSH, FS, 17 years

The owner says: She is "different"

Increased grooming

This morning, she didn't climb the bed as usual

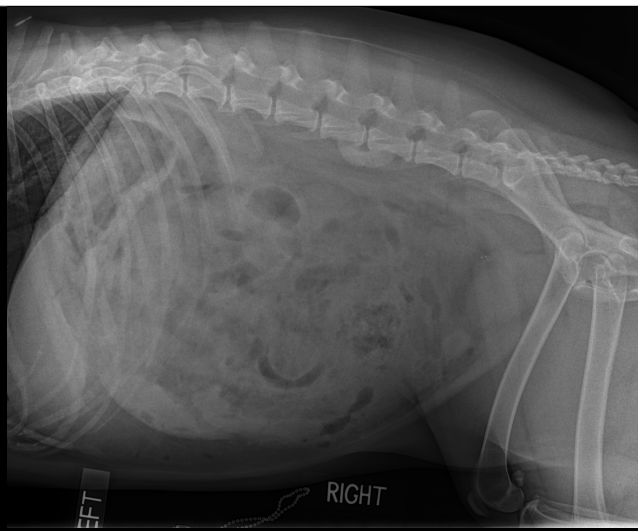




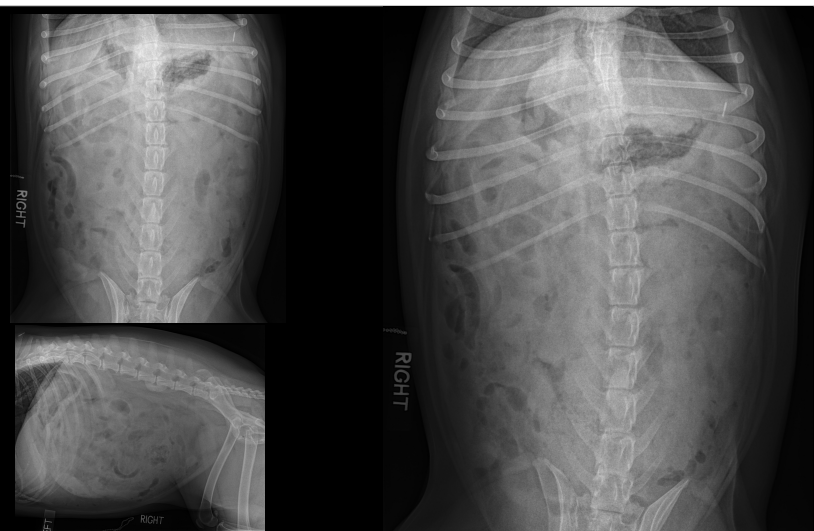Nalü, Golden-Mongreal, FS, 7 years

- Hit by a car yesterday
- Lethargic
- Vomiting
- TRC >2"

Naliù, Golden-Mongreal,
FS, 7 years



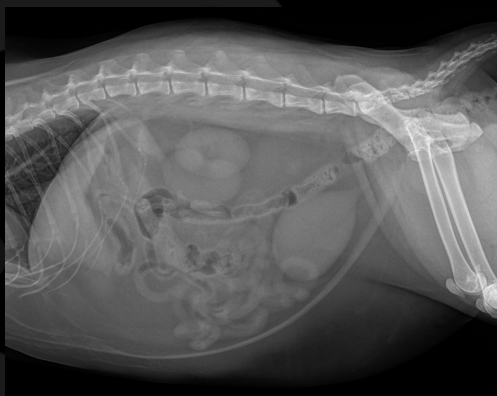Naliù, Golden-Mongreal,
FS, 7 years



Conclusions

The most difficult radiographic
feature is to define what is normal

Detail and contrast depend on
many factors



Thank you



Diagnostic Mindset

www.diagnosticmindset.com