

Esofago e stomaco, dove la radiologia la fa da padrona



Diagnostic Mindset

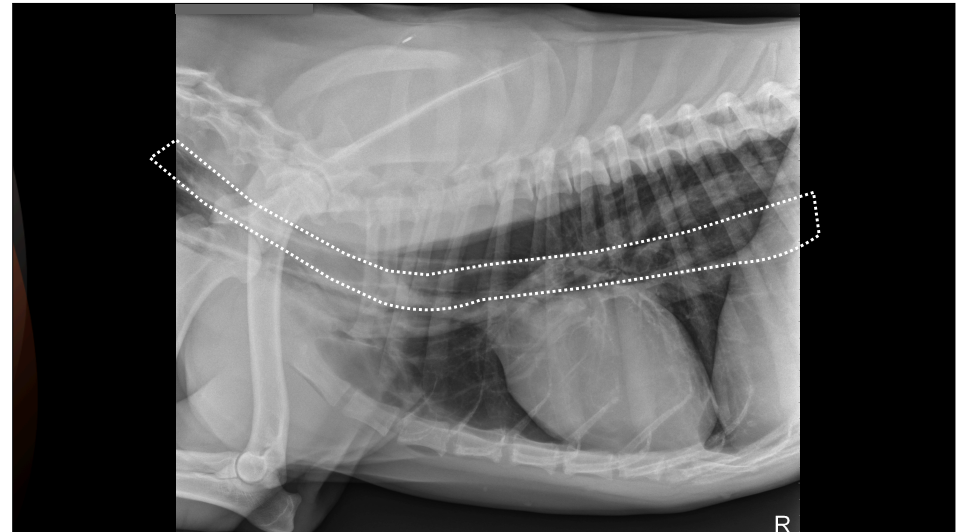
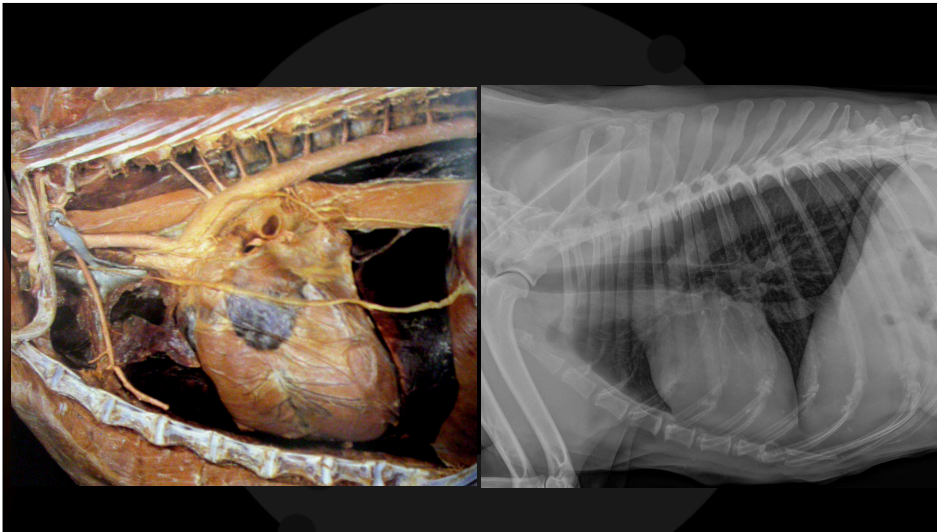
Thank to www.imaios.com
Thank to Maria Grazia Entani

Giliola Spattini
DVM, PhD, DECVDI



Objectives

- The oesophagus is part of the GE tract and can affect the abdomen and the thorax
- Always check the part of the thorax that is visible in the image



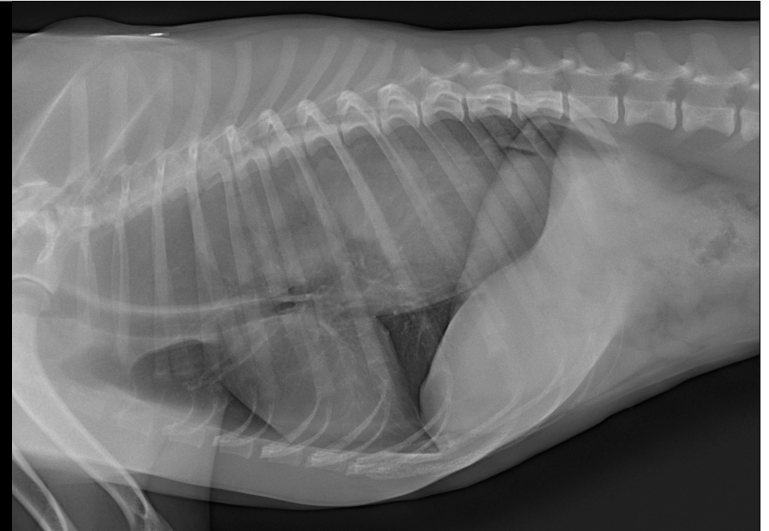
Olivia, Pit-bull, FI, 1 year

Previously diagnosed megaesophagus

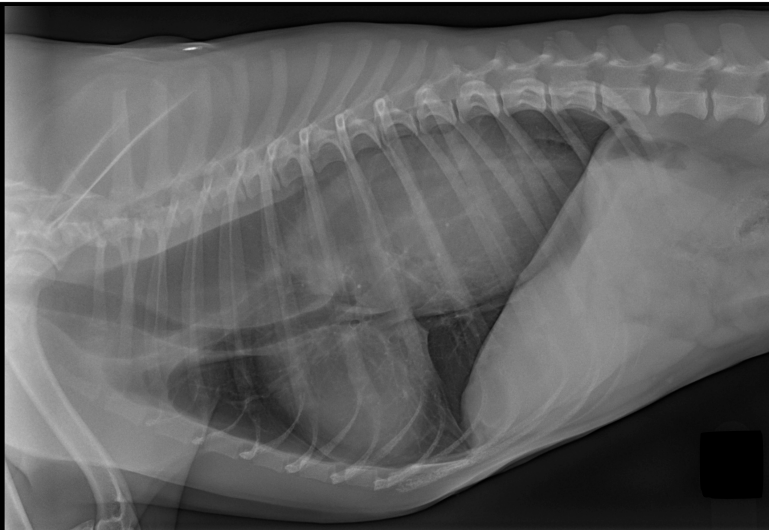
Severe vomiting with hematemesis for the last eight hours



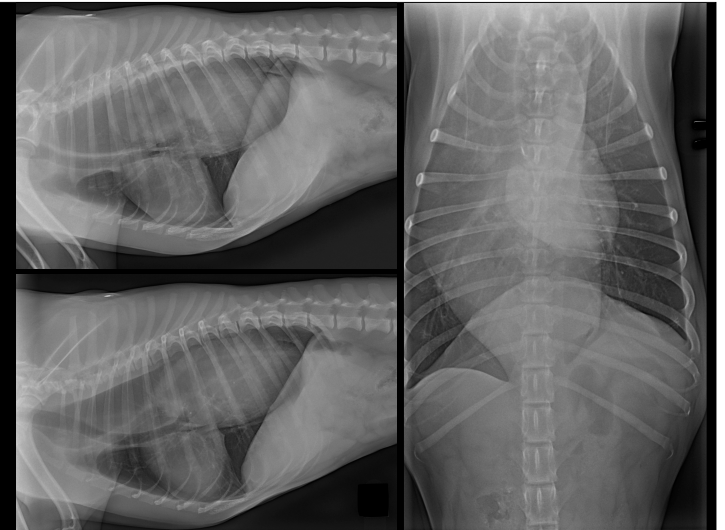
Olivia, FI, 1 year



Olivia, FI, 1 year

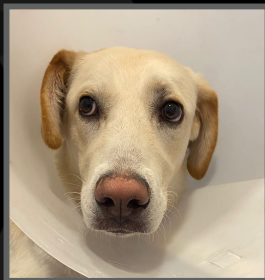

Olivia, FI, 1 year

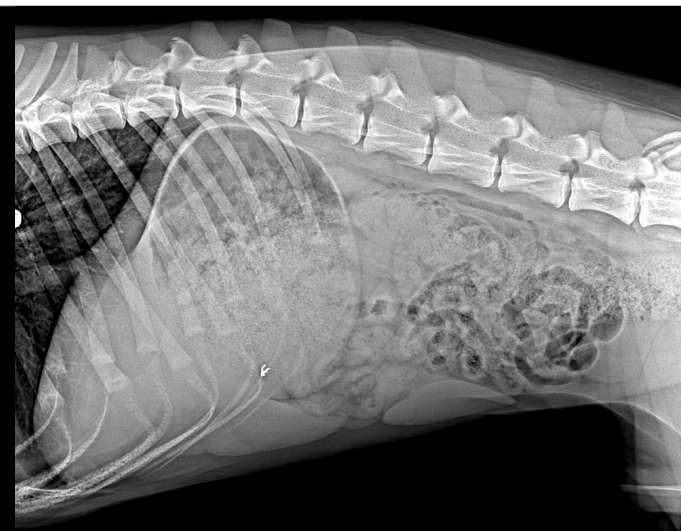
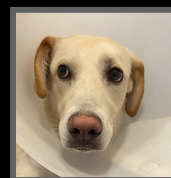

Ettore, Mongrel, MI, 9 months

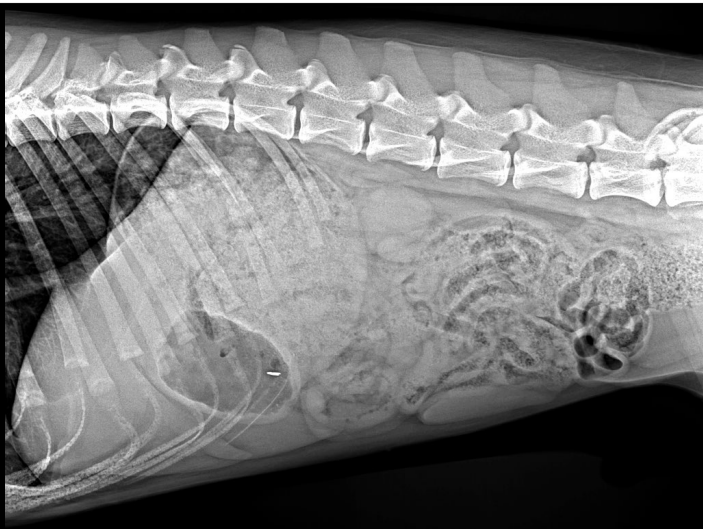
- Acute self-limiting diarrhea last three weeks
- Since yesterday, severe algic position
- Abdominal pain
- He woke up in the middle of the night crying



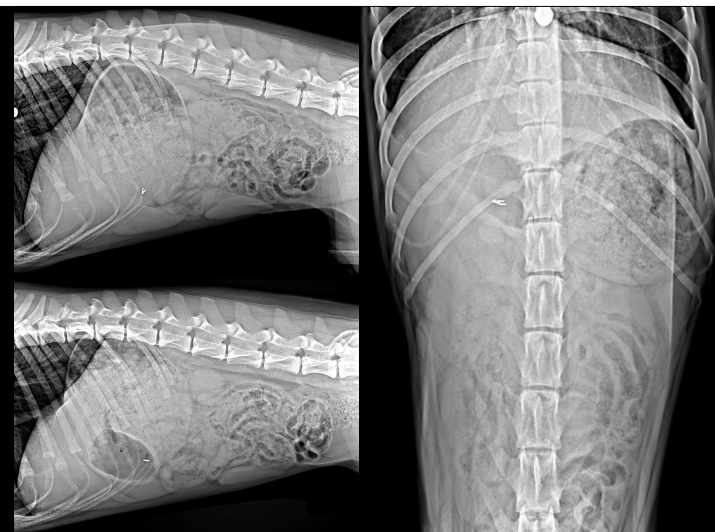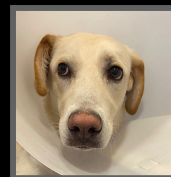Ettore,
MI, 9 months



Ettore,
MI, 9 months



Ettore,
MI, 9 months



Thank you



Diagnostic Mindset

www.diagnosticmindset.com