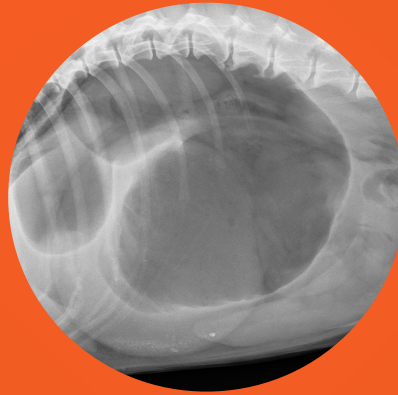


## Gastric dilatation or gastric volvulus in the radiographs of dogs?

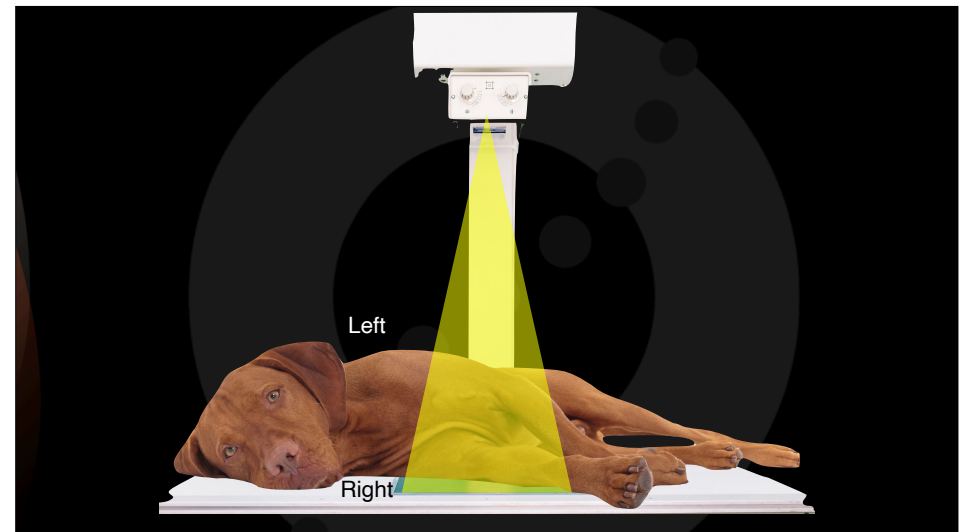
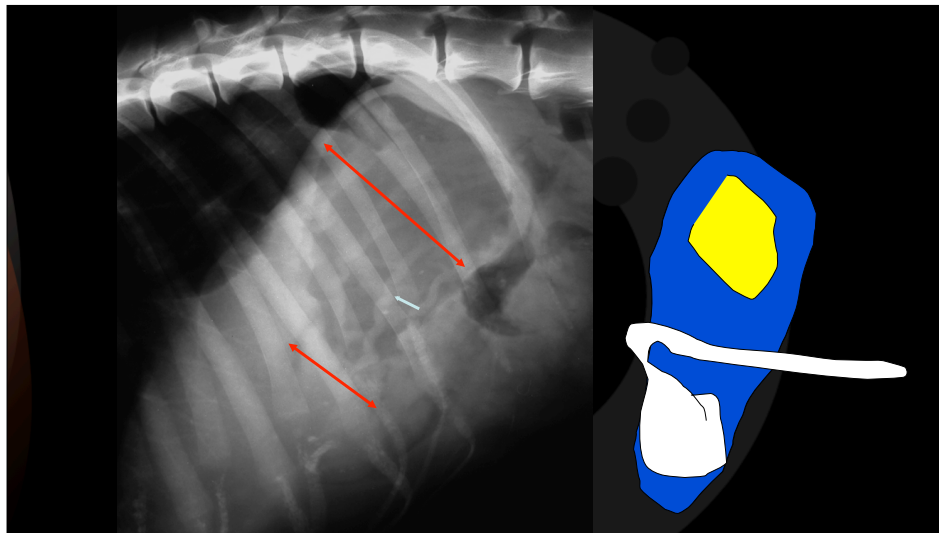
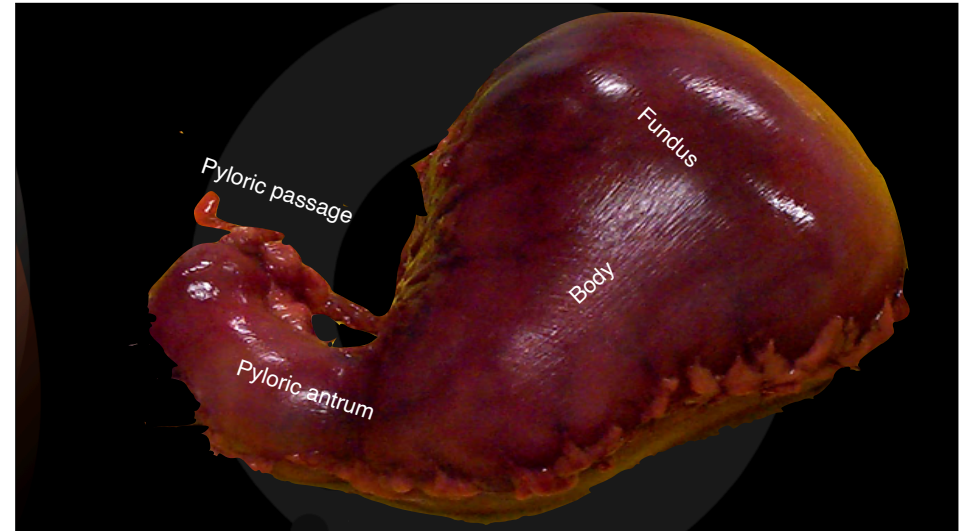
How to differentiate a gastric dilatation from a gastric volvulus on canine radiographs.

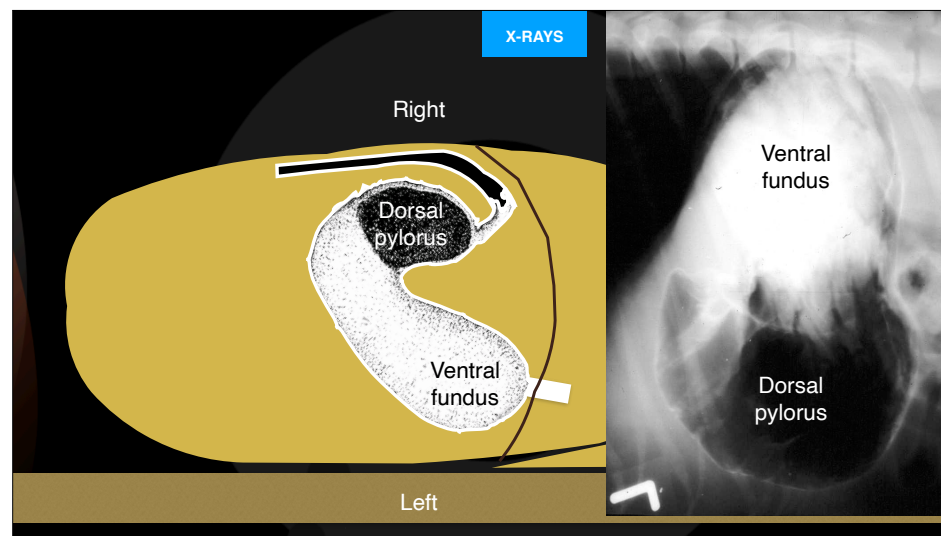
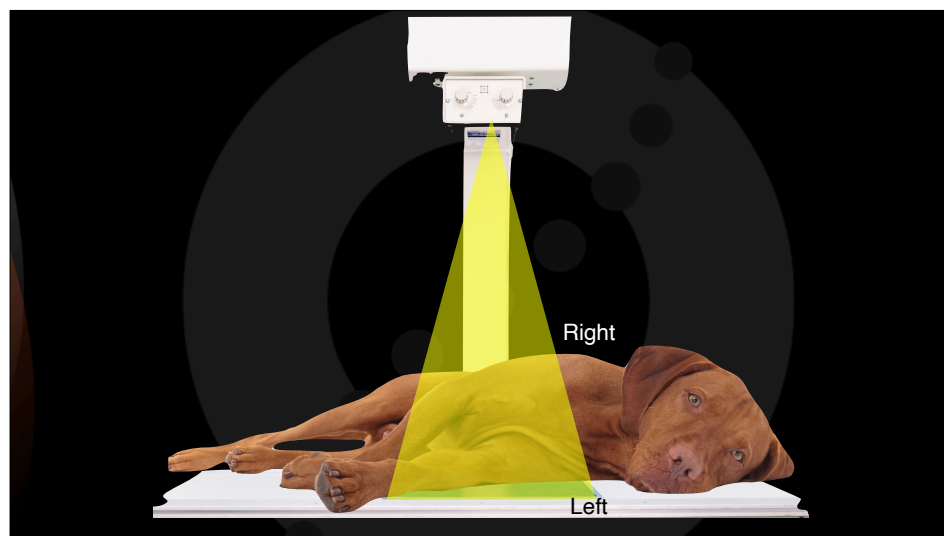
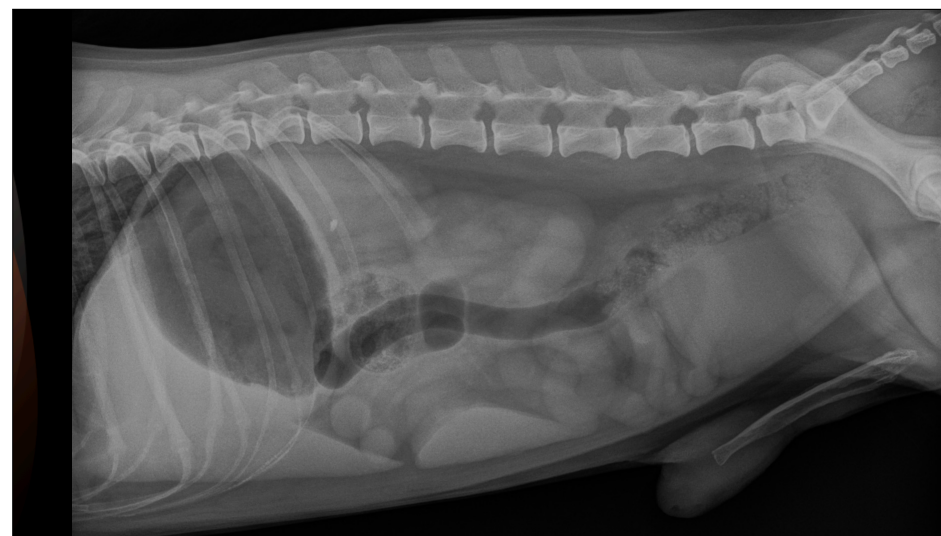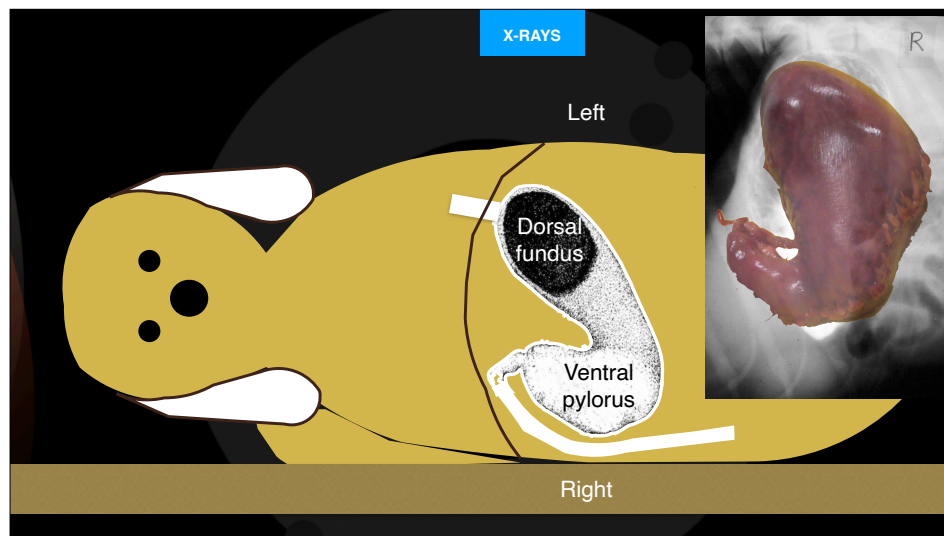


Diagnostic Mindset

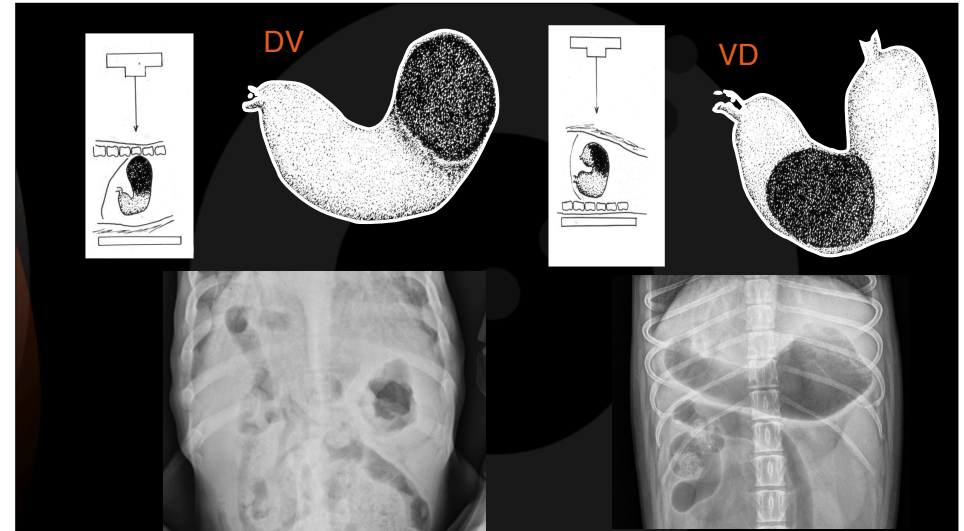
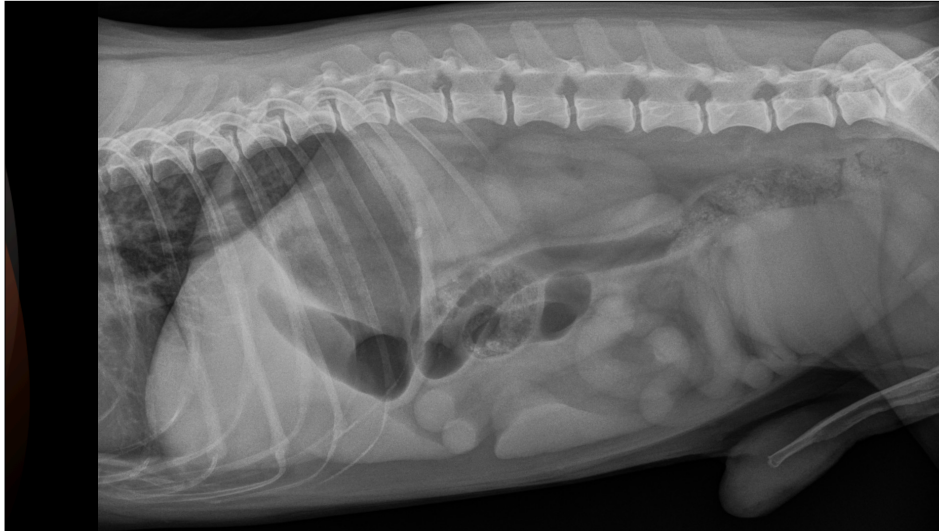Thanks to Clinica Veterinaria Castellarano

Giliola Spattini  
DVM, PhD, DECVDI



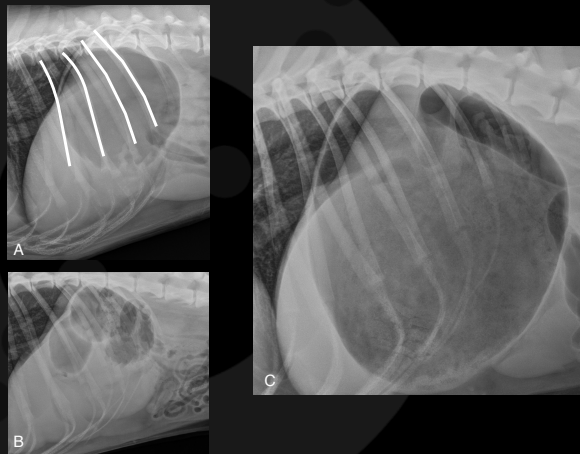






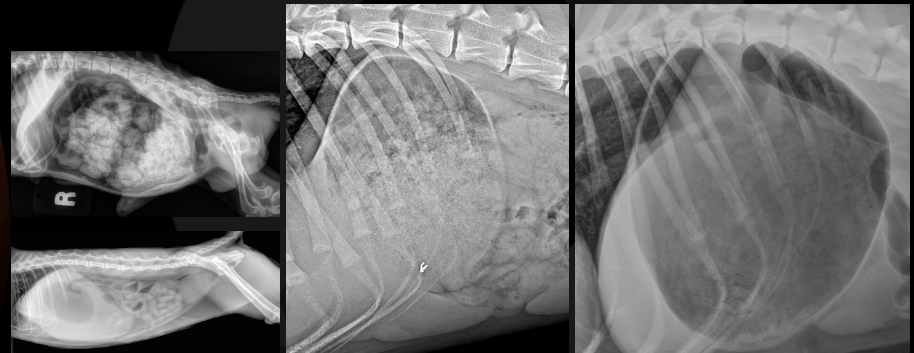
### When the stomach is considered enlarged?

- When the width of the fundus is more than three intercostal space



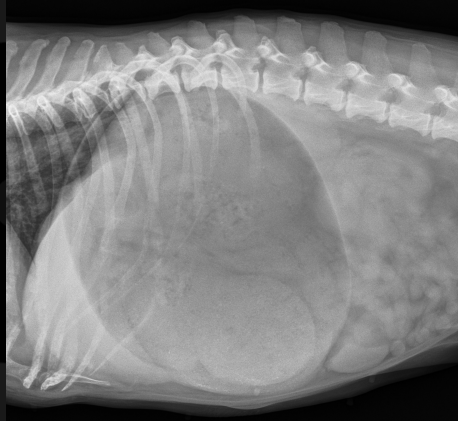### Does the gastric content matters?

- Gas • Dilatation or Volvulus
- Fluid • Sub-occlusion or severe gastritis
- Granular material • Gastric congestion



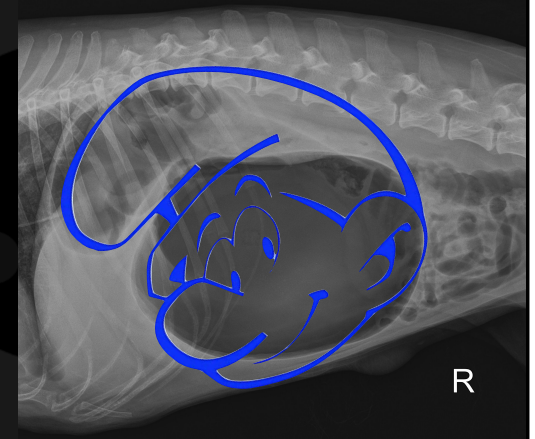
### How to check for a gastric volvulus

- The fundus is dorsal and to the left?
- The pylorus is ventral and to the right?



### How to check for a gastric volvulus

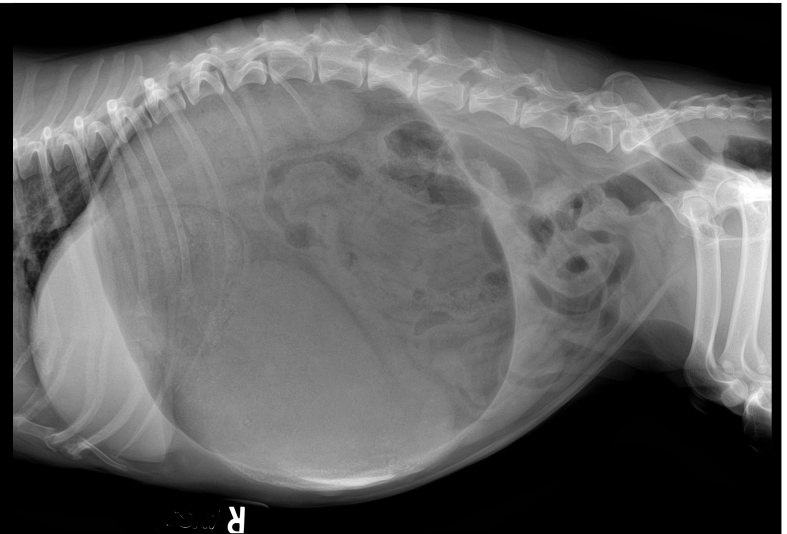- Is the fundus dorsal and to the left?
- Is the pylorus ventral and to the right?
- Can you see a smurf face?



Learning check!

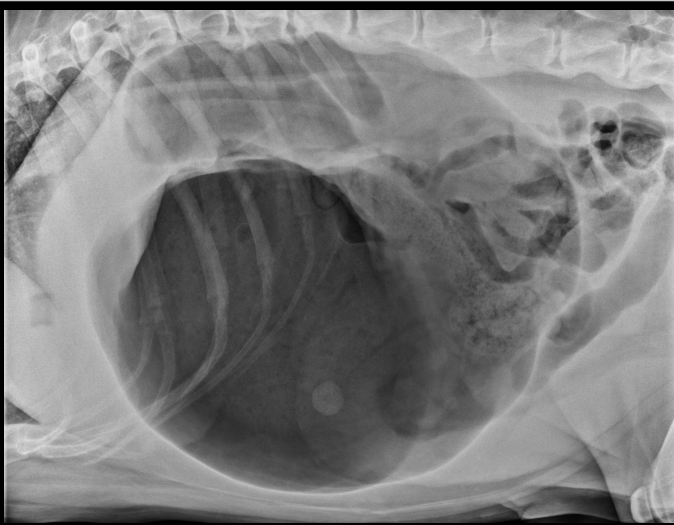
CASE 1

Lilly, Dachshund, FS, 15 years



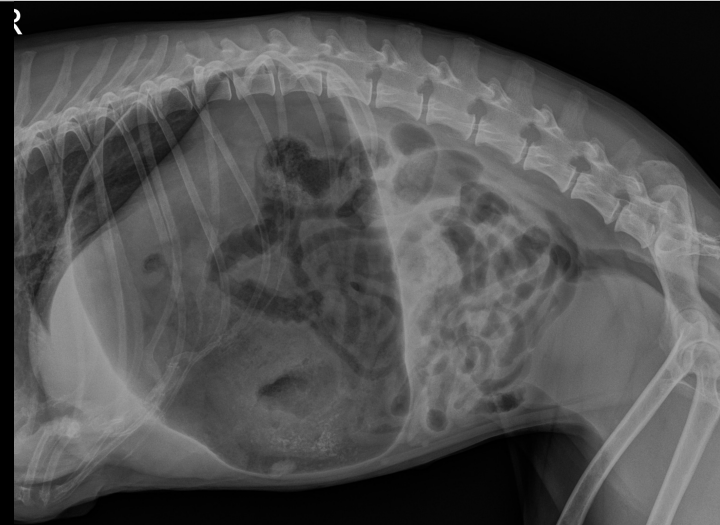CASE 2

Tank, American SH, MN, 10 years



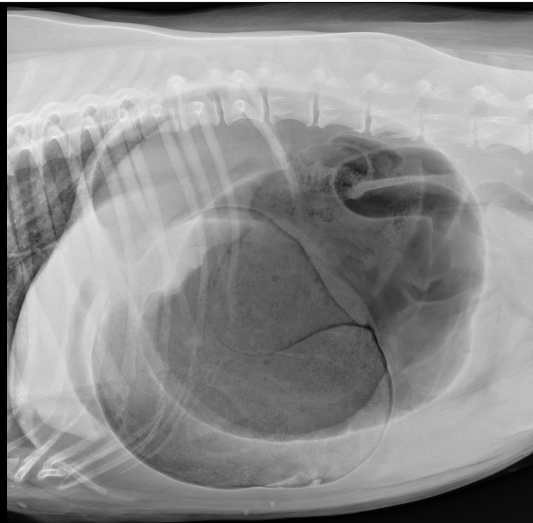CASE 3

Princess, Mongrel, FS, 17 years



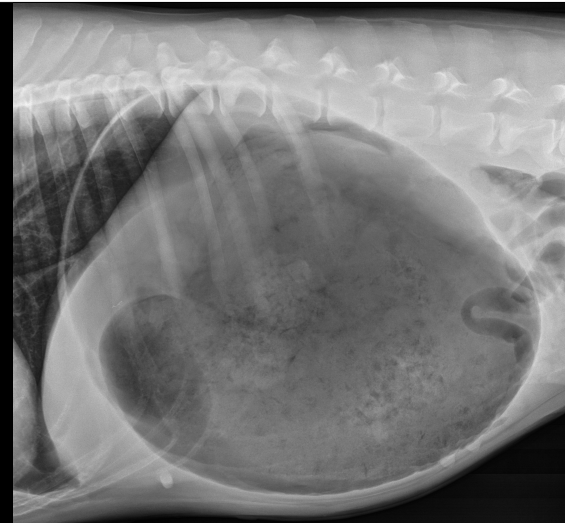
CASE 4

Bella, Mongrel, FS, 7 years



CASE 5

Basil, Great Dane, FI, 7 years



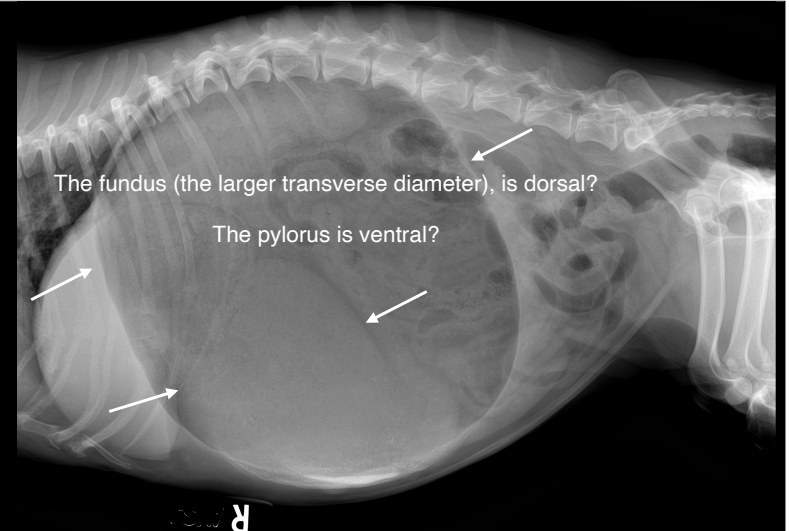


## Your evaluation

- Which patient has a gastric volvulus, and which has a gastric dilatation?
- Where is the fundus, and where is the pylorus?

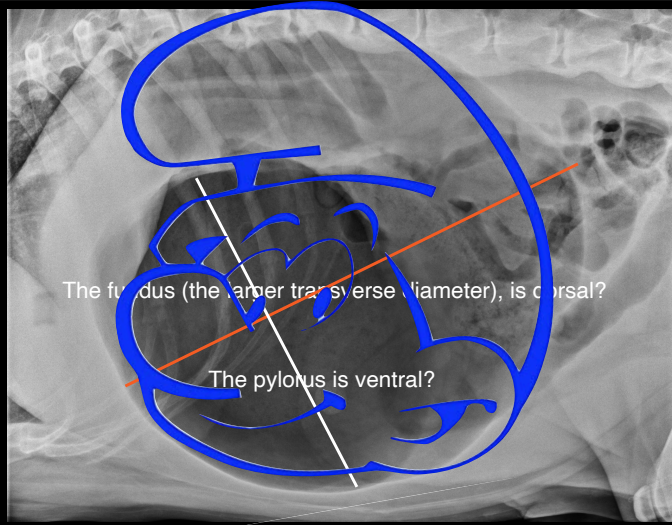
CASE 1

Lilly, Dachshund, FS, 15 years



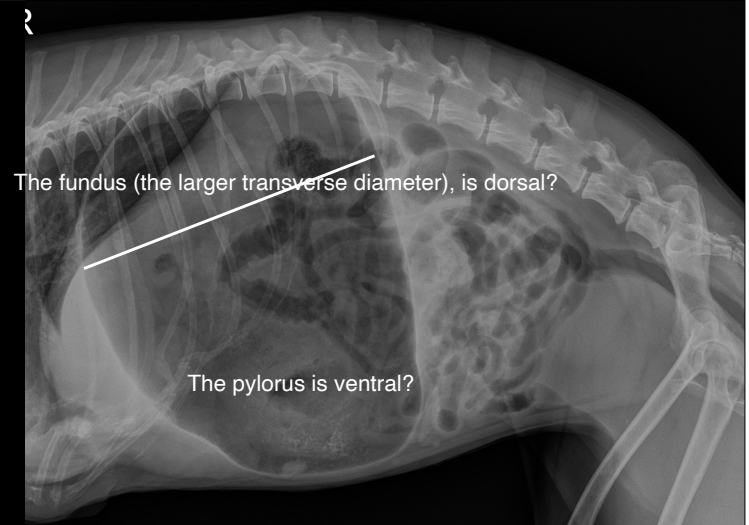
CASE 2

Tank, American SH, MN, 10 years



CASE 3

Princess, Mongrel, FS, 17 years



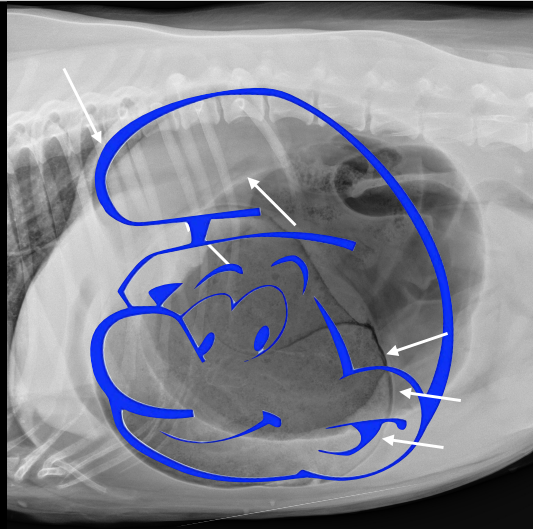


#### CASE 4

Bella, Mongrel, FS, 7 years

The fundus (the larger transverse diameter), is dorsal?

The pylorus is ventral?

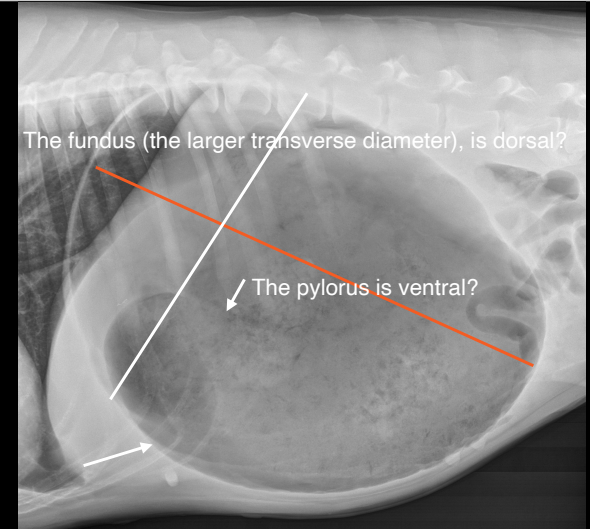


#### CASE 5

Basil, Great Dane, FI, 7 years

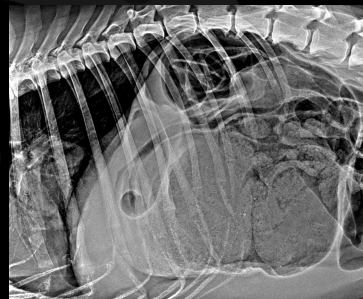
The fundus (the larger transverse diameter), is dorsal?

The pylorus is ventral?



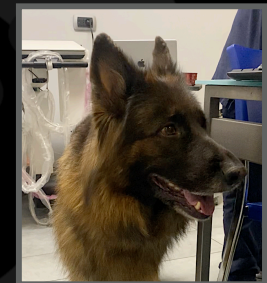
#### Key points

- Check the pylorus
- Check the fundus
- Smurfs face
- Check every radiographic details

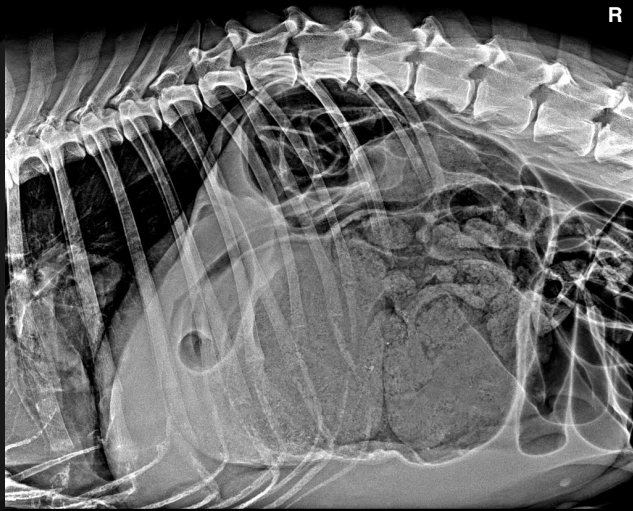
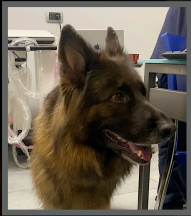

#### Kim, German Shepherd, MI, 9 years

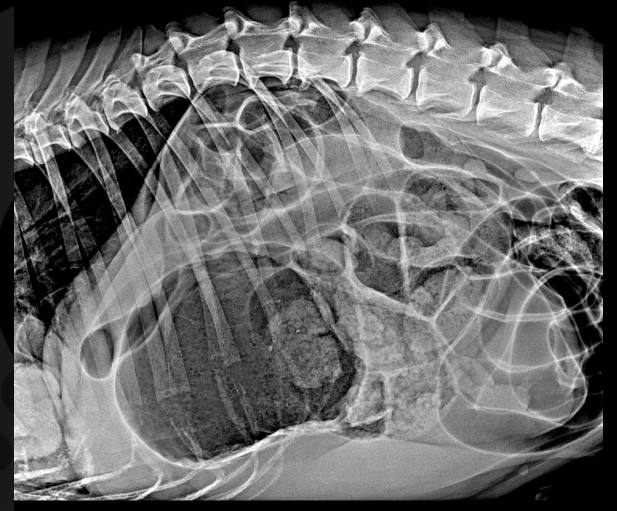
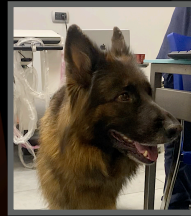- He ate more than usual
- Soon after, He started to attempt to vomit
- He seems painful
- Overdistended stomach



Kim, Ml, 9 years

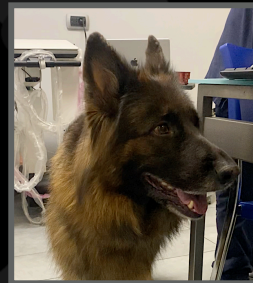

Kim, Ml, 9 years

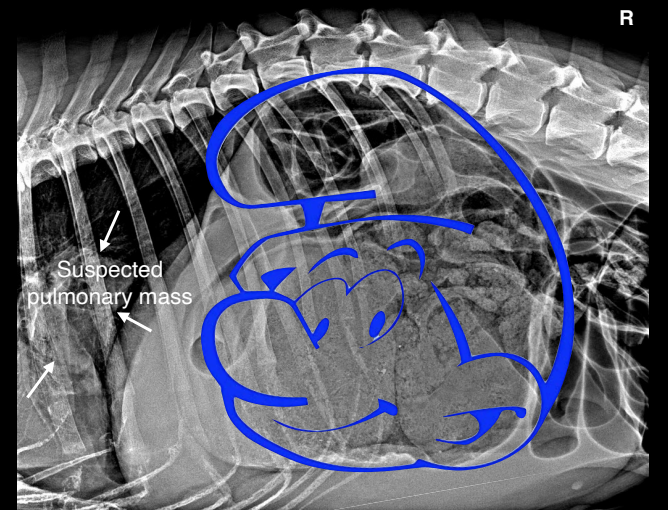
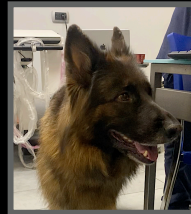

### Your evaluation

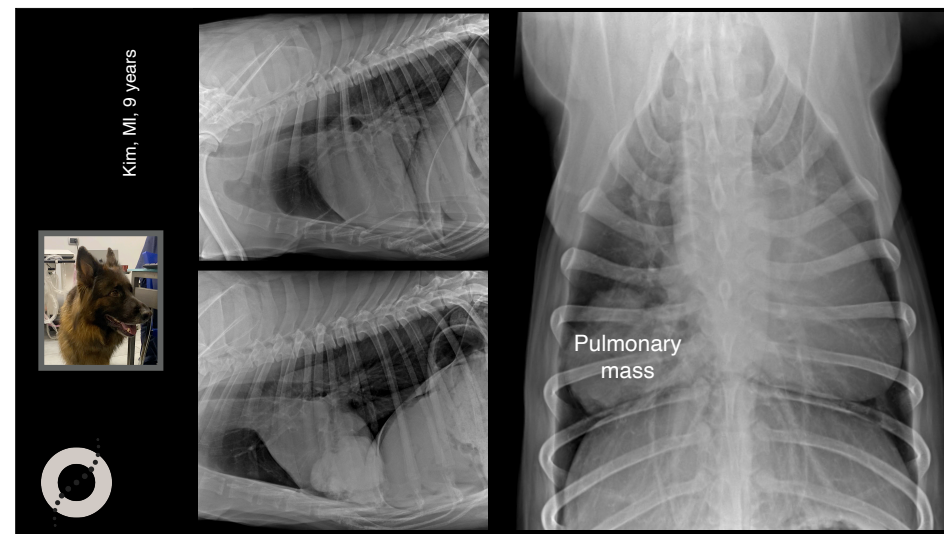
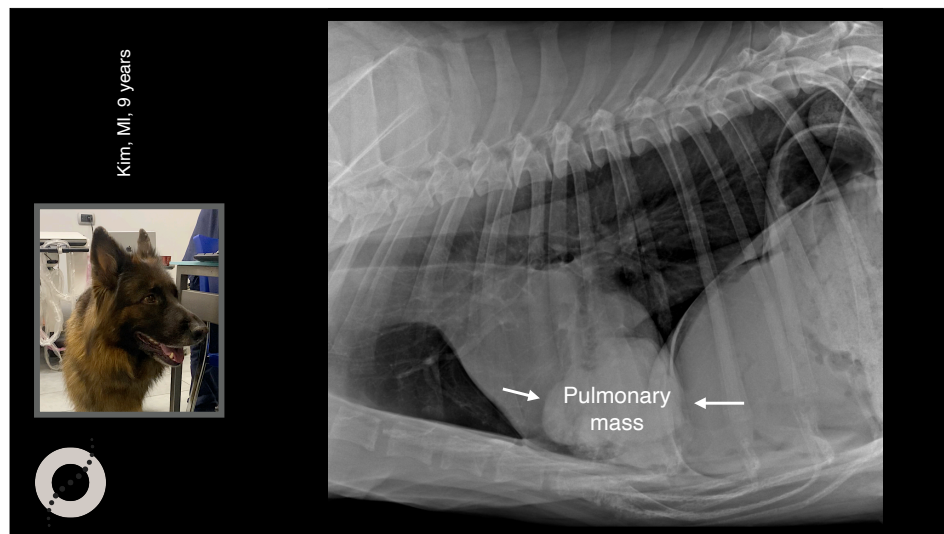
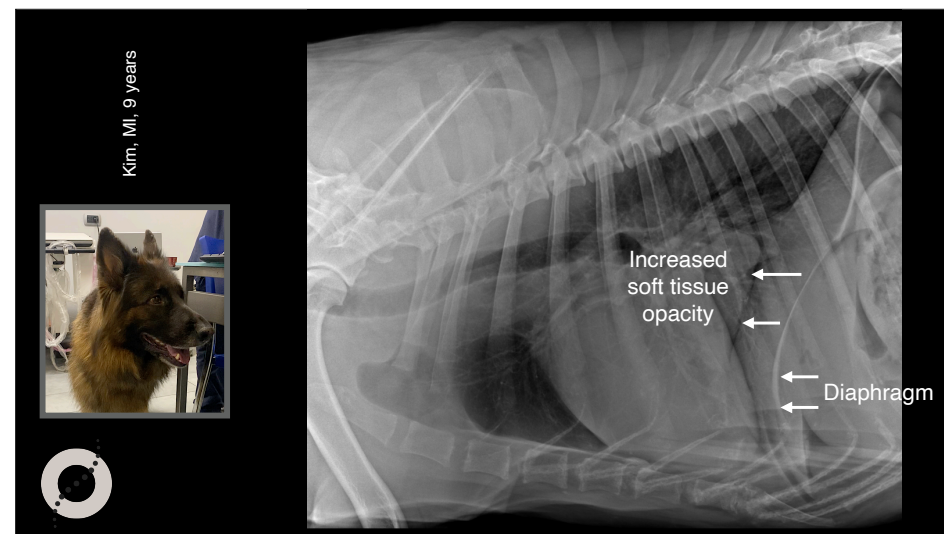
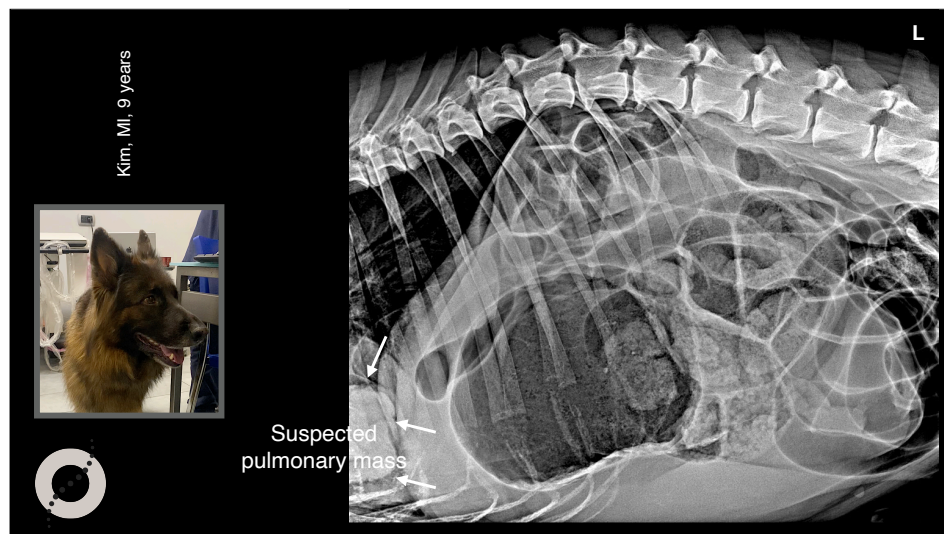
- Is there lumbar spondylosis?
- Is there gastric dilatation?
- Is there gastric volvulus?



Kim, Ml, 9 years

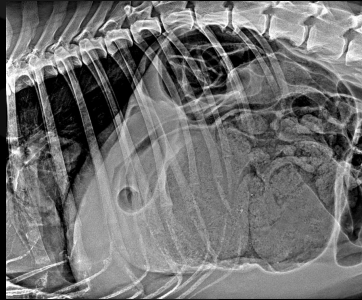






### Key points

- Check the pylorus
- Check the fundus
- Smurfs face
- Check every radiographic details



## Thank you



Diagnostic Mindset

[www.diagnosticmindset.com](http://www.diagnosticmindset.com)