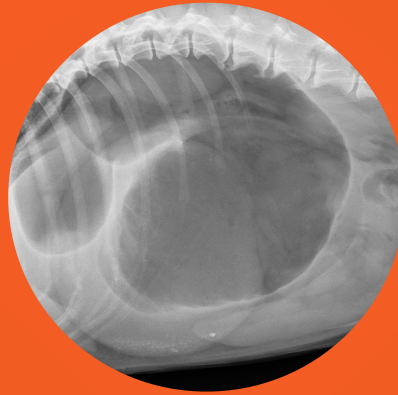


Gastric dilatation or gastric volvulus in the radiographs of dogs?

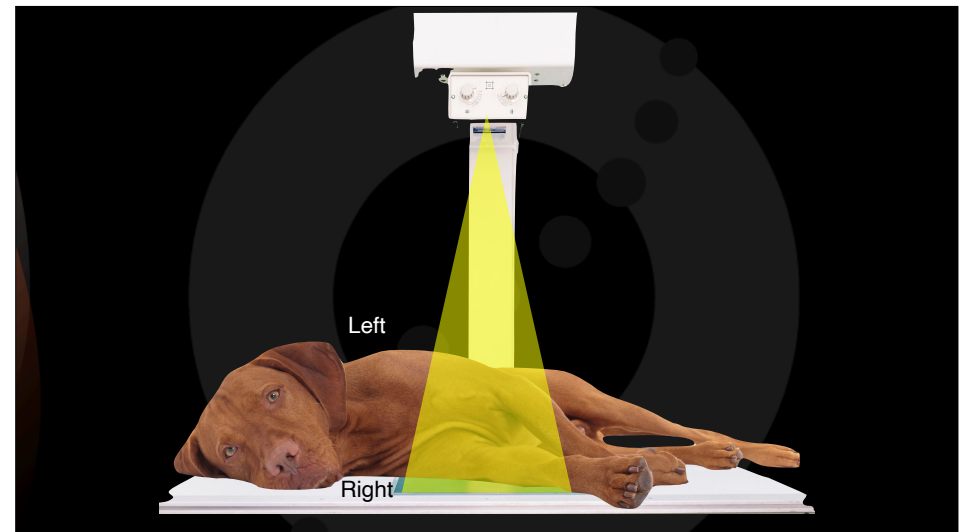
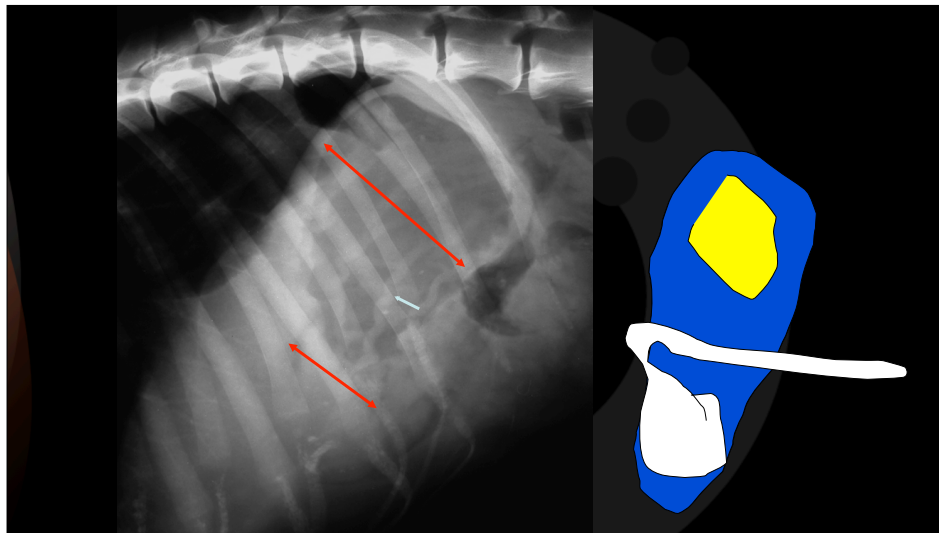
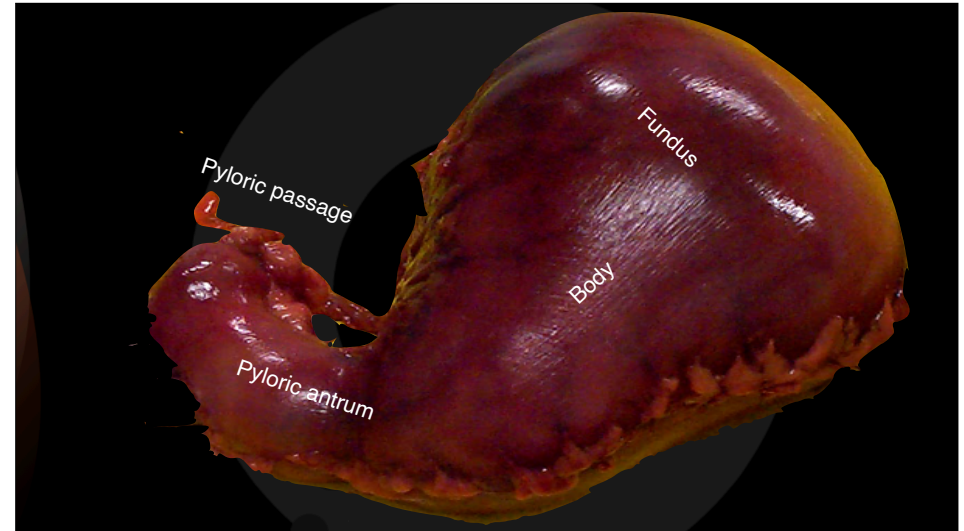
How to differentiate a gastric dilatation from a gastric volvulus on canine radiographs.

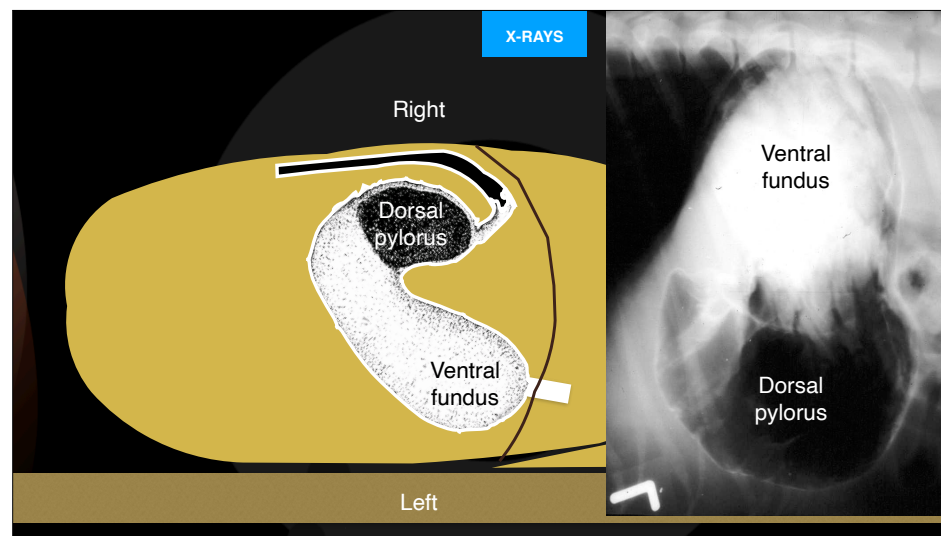
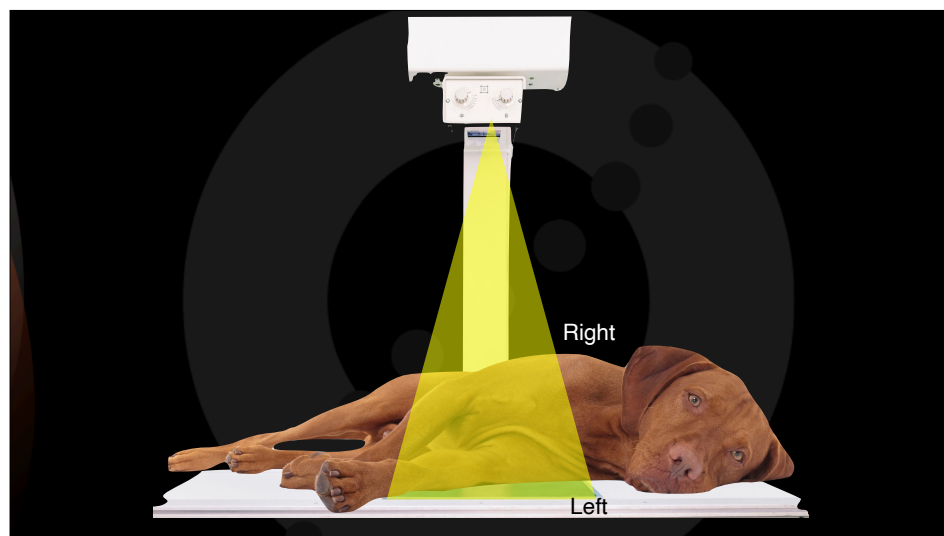
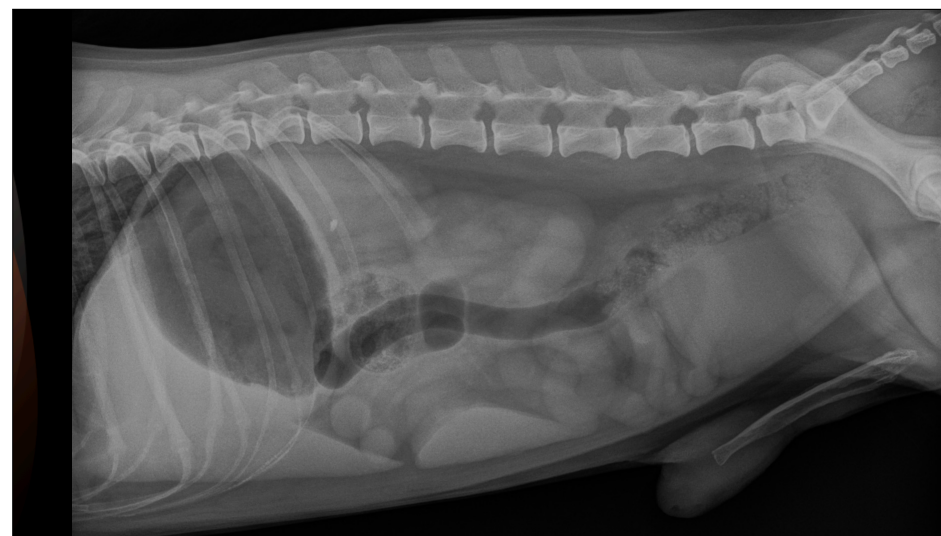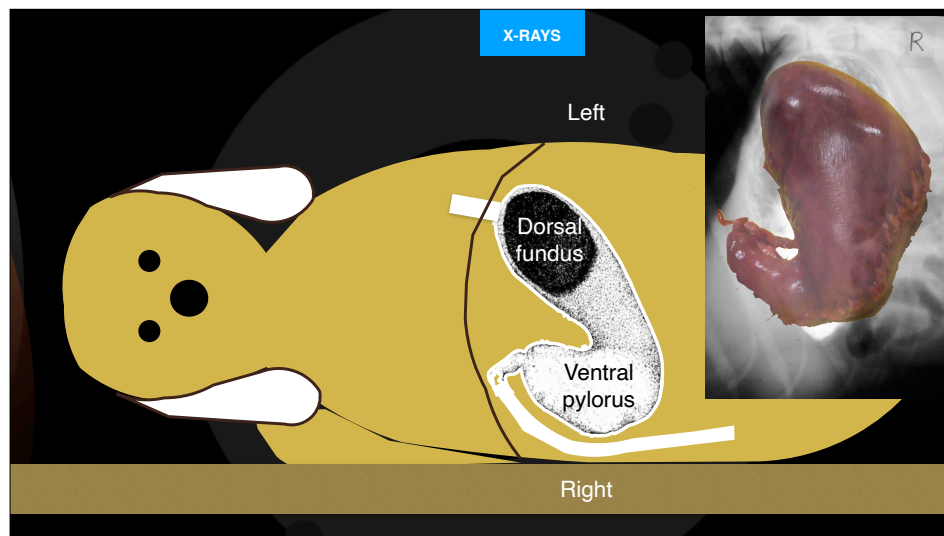


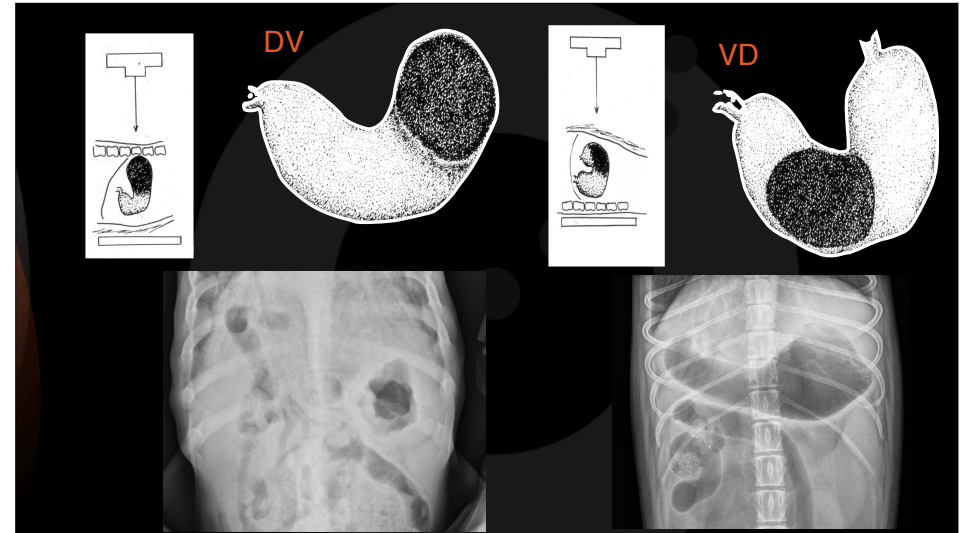
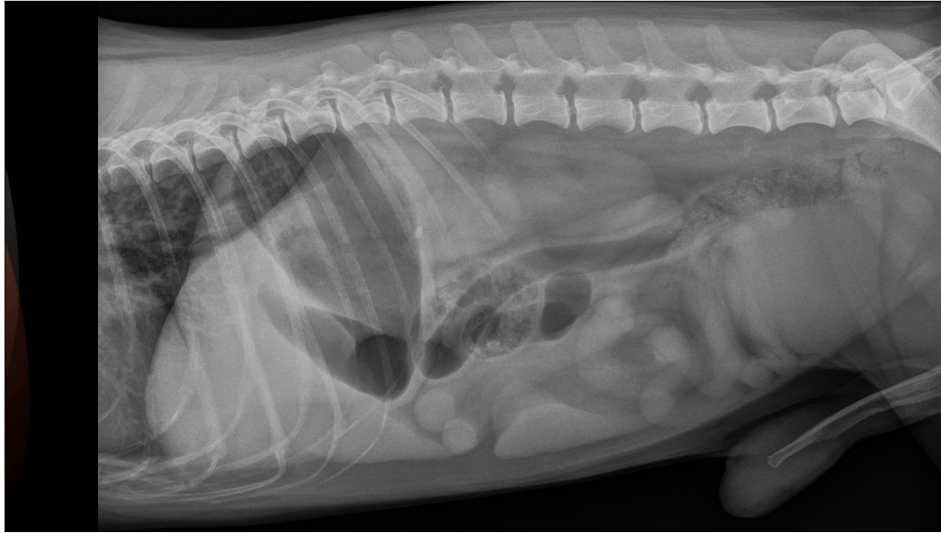Diagnostic Mindset

Thanks to Clinica Veterinaria Castellarano

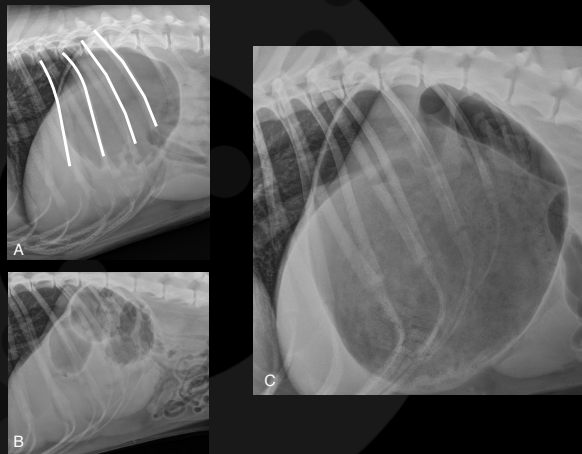
Giliola Spattini
DVM, PhD, DECVDI



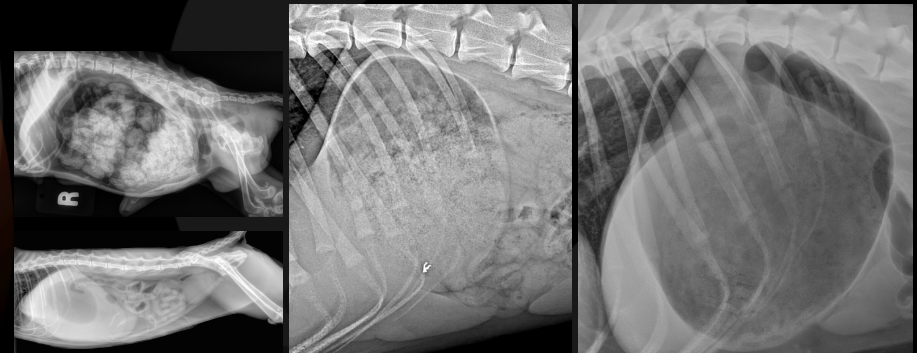




When the stomach is considered enlarged?

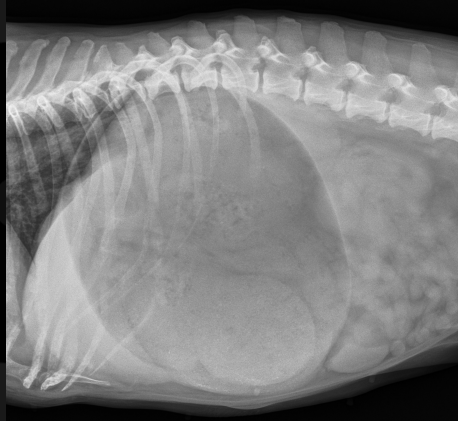

Does the gastric content matters?



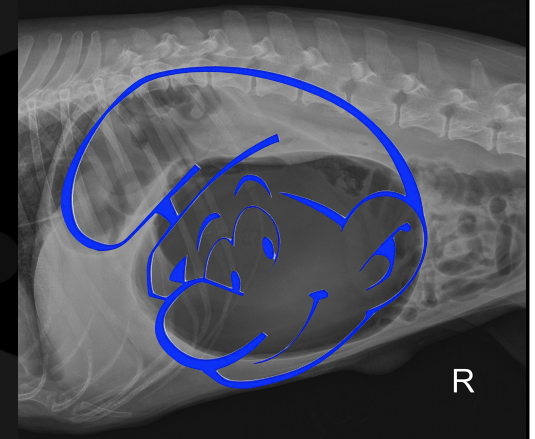
How to check for a gastric volvulus

- The fundus is dorsal and to the left?
- The pylorus is ventral and to the right?



How to check for a gastric volvulus

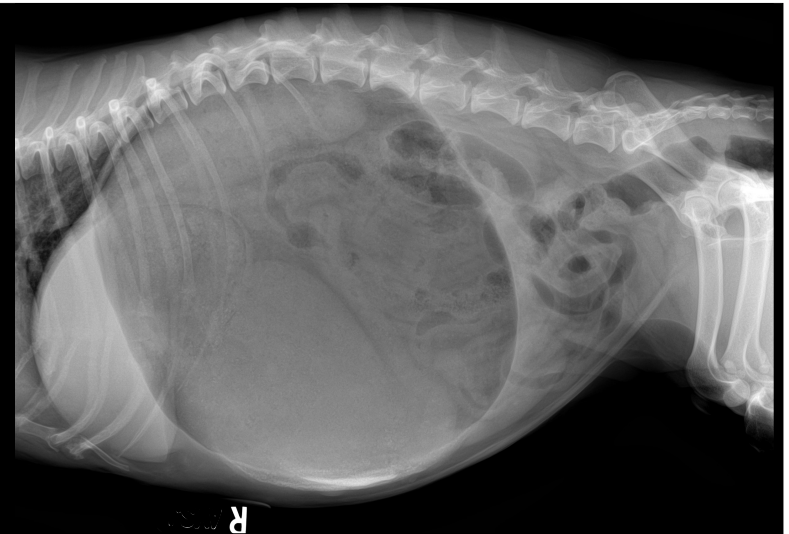- Is the fundus dorsal and to the left?
- Is the pylorus ventral and to the right?
- Can you see a smurf face?



Learning check!

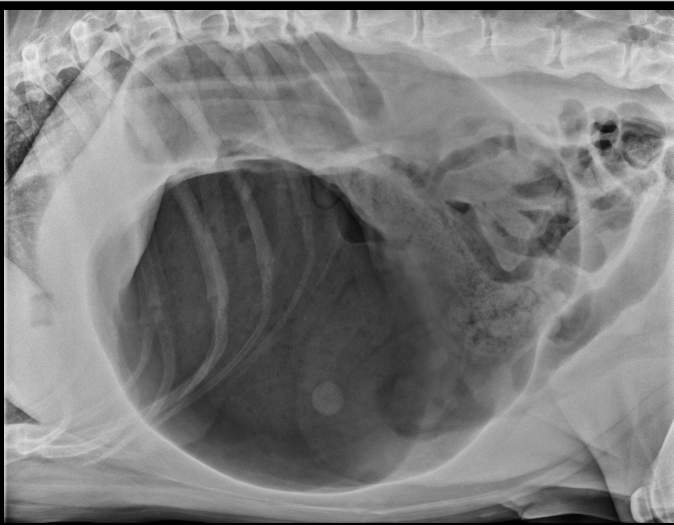
CASE 1

Lilly, Dachshund, FS, 15 years



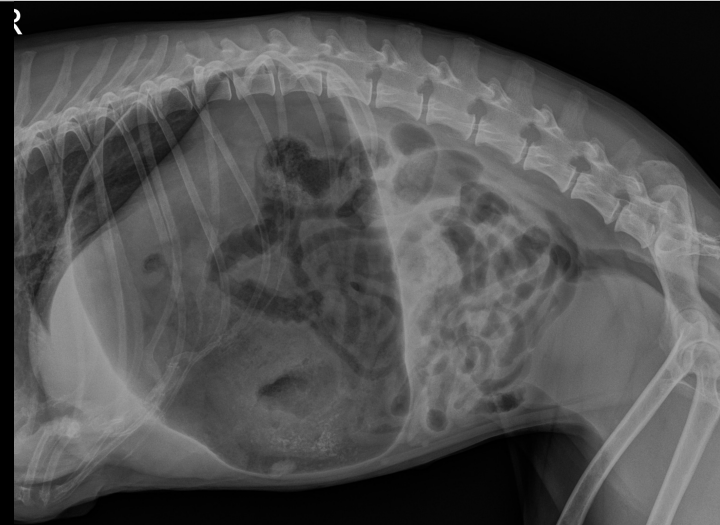CASE 2

Tank, American SH, MN, 10 years



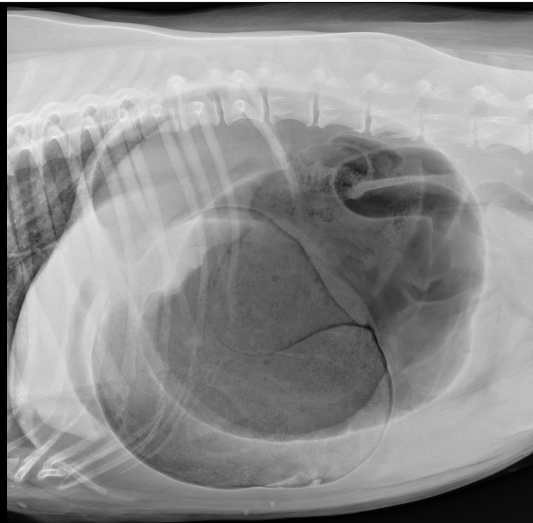CASE 3

Princess, Mongrel, FS, 17 years



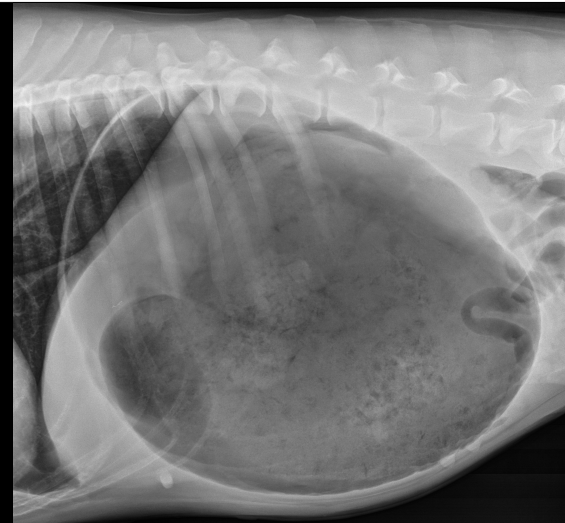
CASE 4

Bella, Mongrel, FS, 7 years



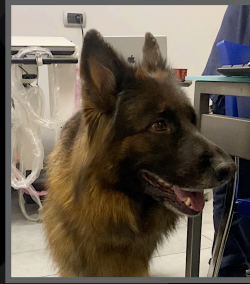CASE 5

Basil, Great Dane, FI, 7 years

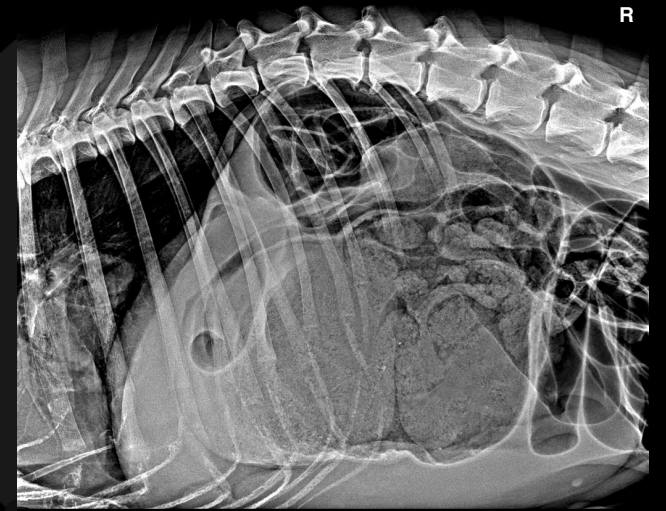
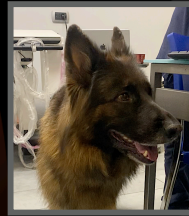

Kim, German Shepherd, MI, 9 years

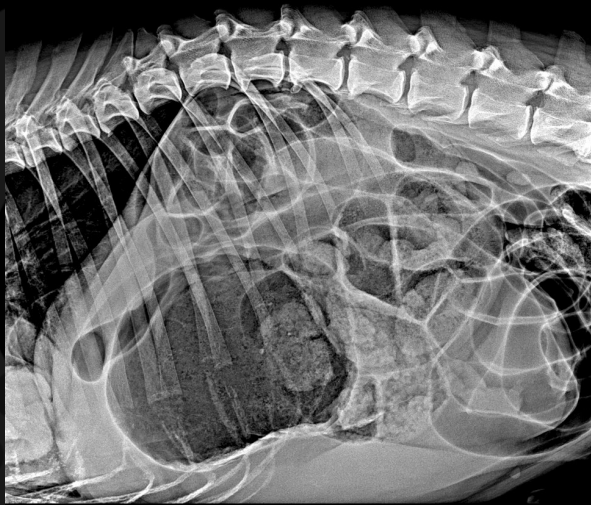
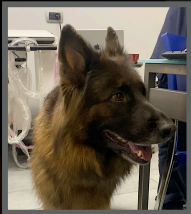- He ate more than usual
- Soon after, He started to attempt to vomit
- He seems painful
- Overdistended stomach



Kim, MI, 9 years

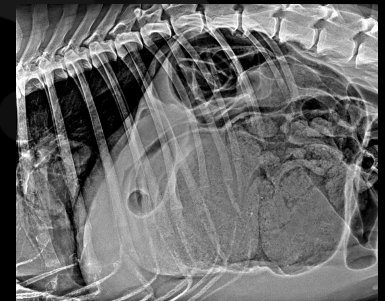


Kim, MI, 9 years



Key points

- Check the pylorus
- Check the fundus
- Smurfs face
- Check every radiographic details



Thank you



Diagnostic Mindset

www.diagnosticmindset.com