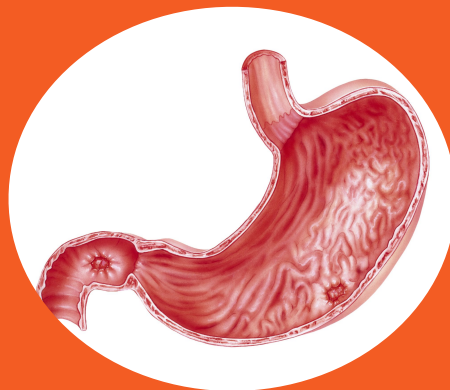

Radiologia di altre patologie gastriche



Thank to www.imaio.com
Thank to Maria Grazia Entani

Giliola Spattini
DVM, PhD, DECVDI

Rocky, Mongrel, MN, 13 years

Stiff gait

The owner is concern for
back pain

Tense abdomen on PE

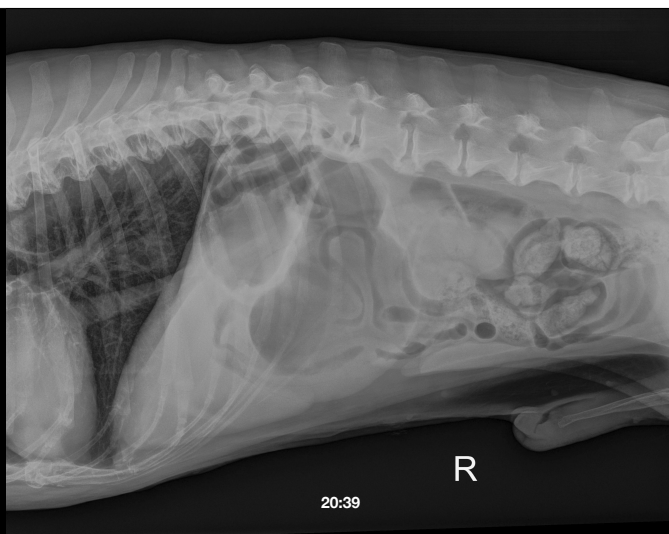


Rocky
MN, 13 years



20:39

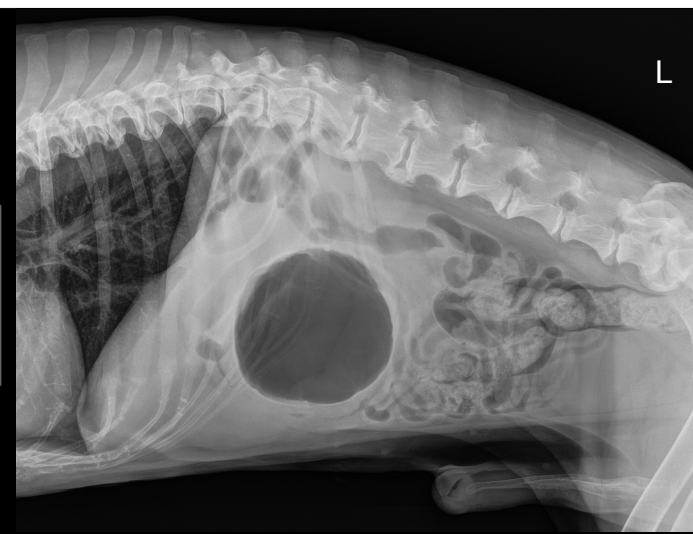
R

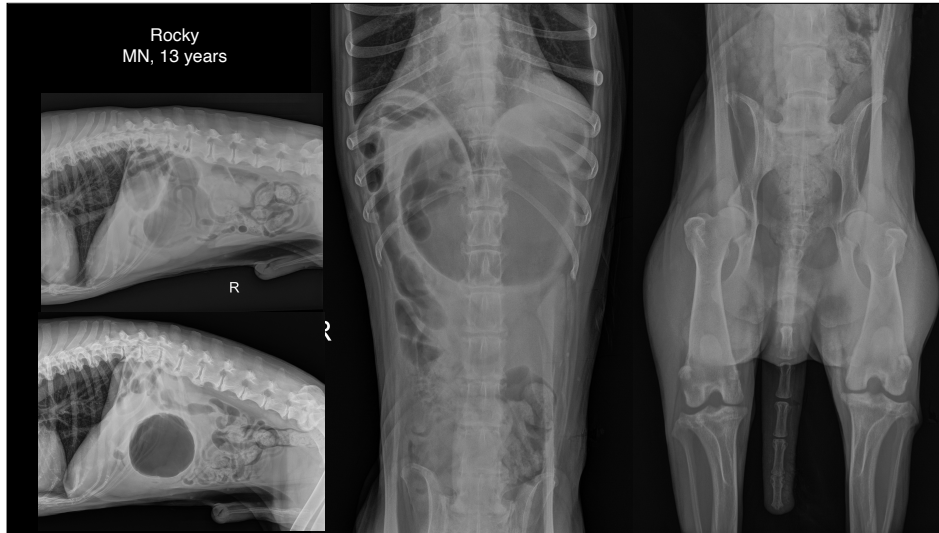


Rocky
MN, 13 years



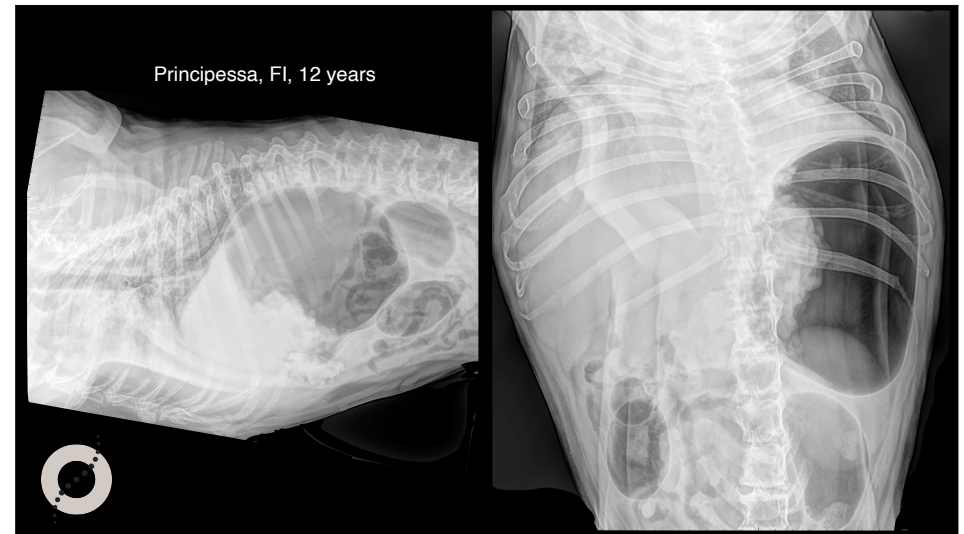
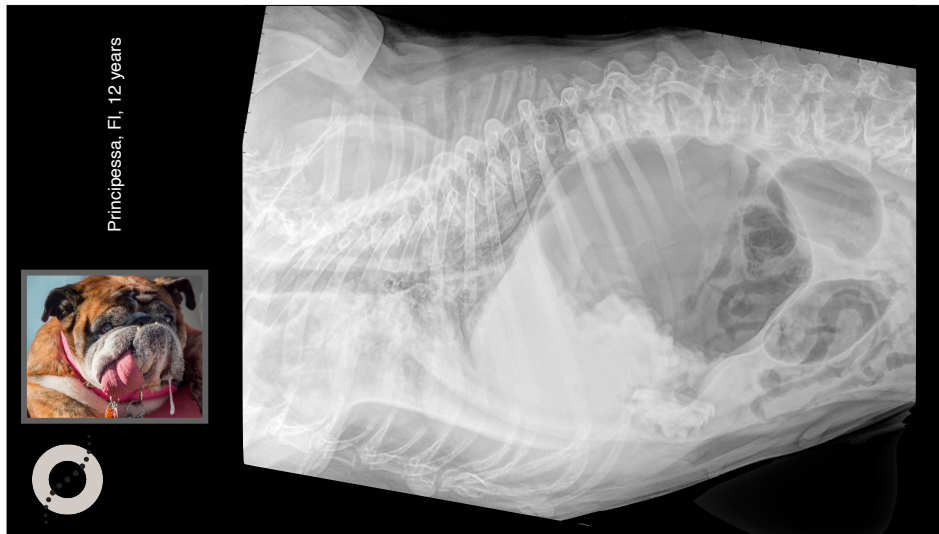
L





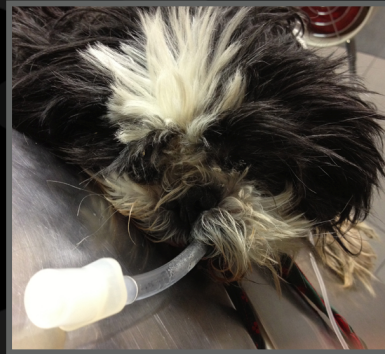Principessa, English Bulldog, FI, 12 years

- Severe vomiting for the last two months
- Severe weight loss
- Suspected gastric mass on first ultrasonographic consultation
- Second ultrasonographer didn't find the suspected mass

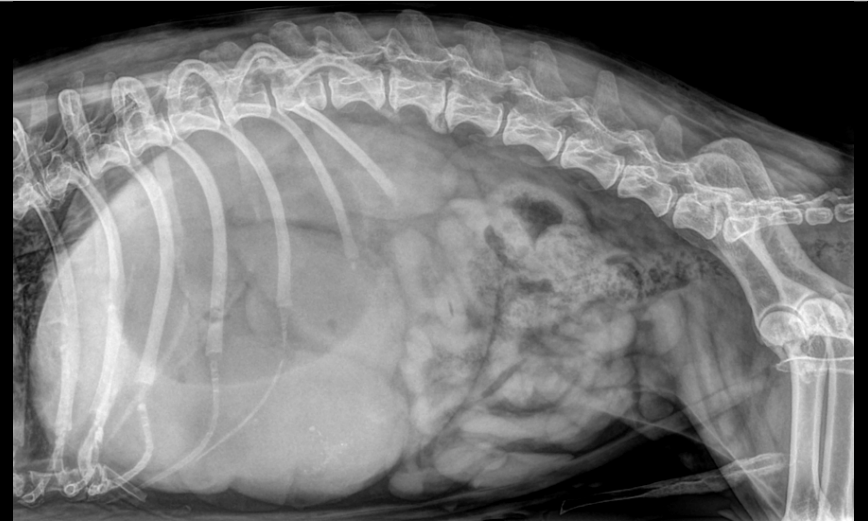


Romeo, Shitzu, MN, 13 years

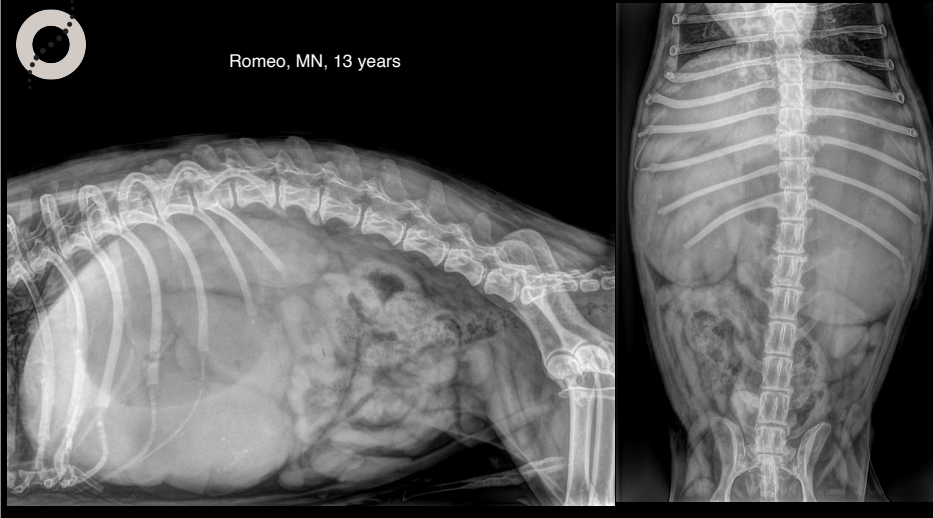- Chronically vomiting twice weekly
- Now worsening
- Still eating



Romeo, MN, 13 years

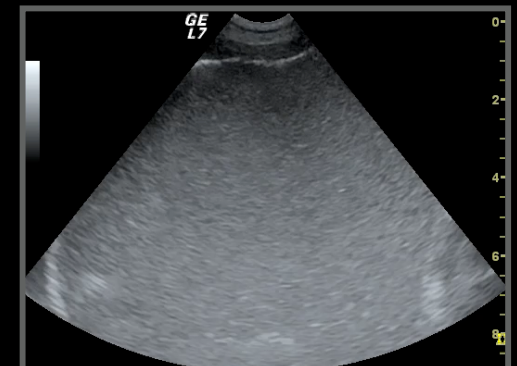
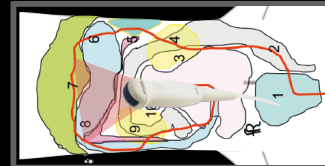
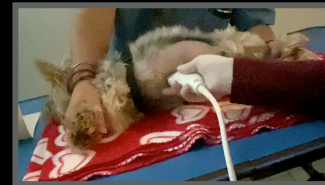

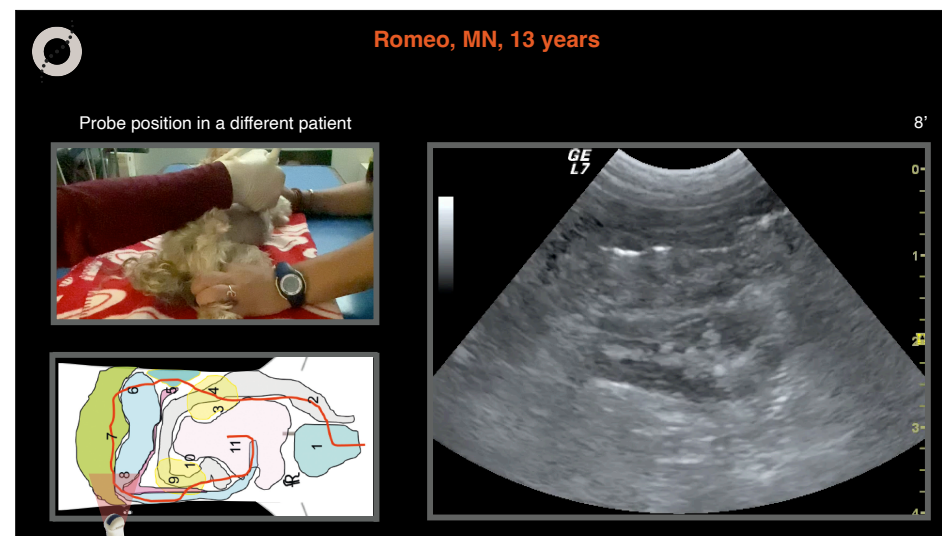
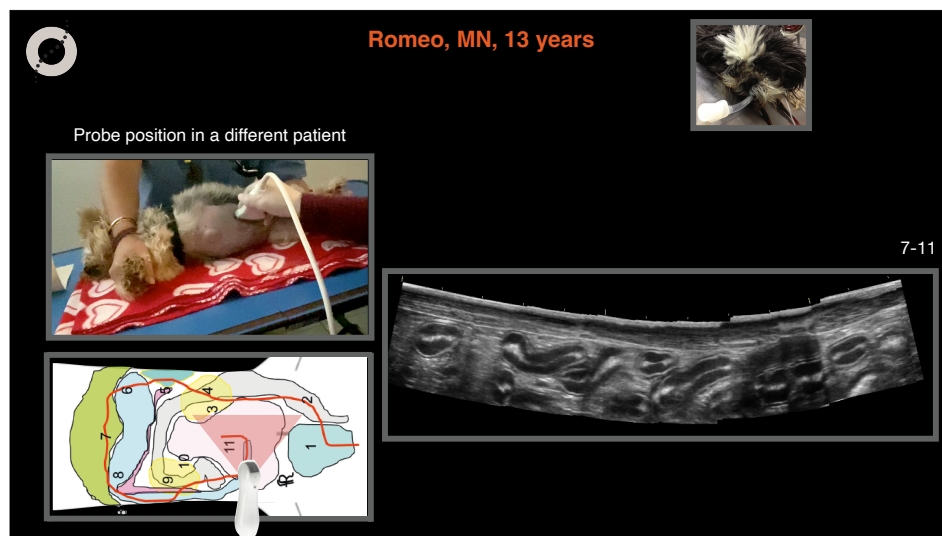
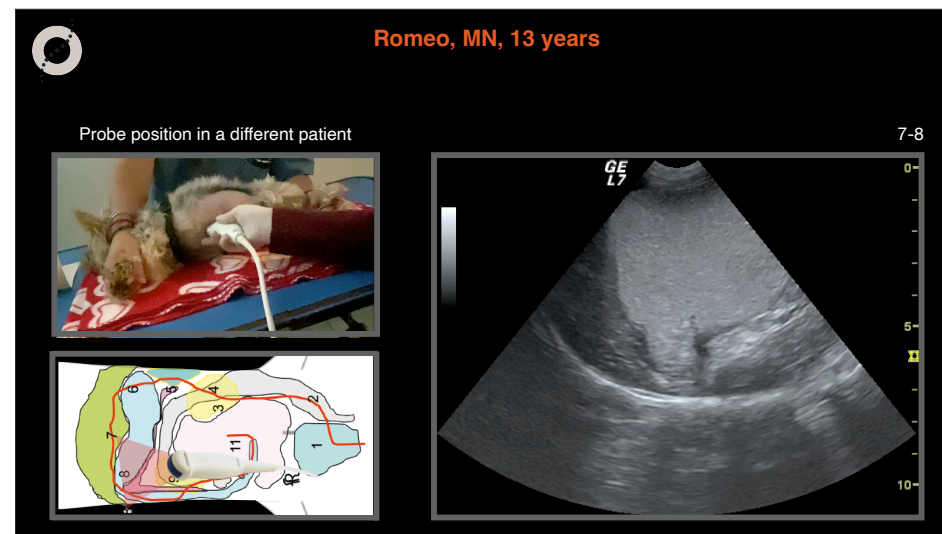
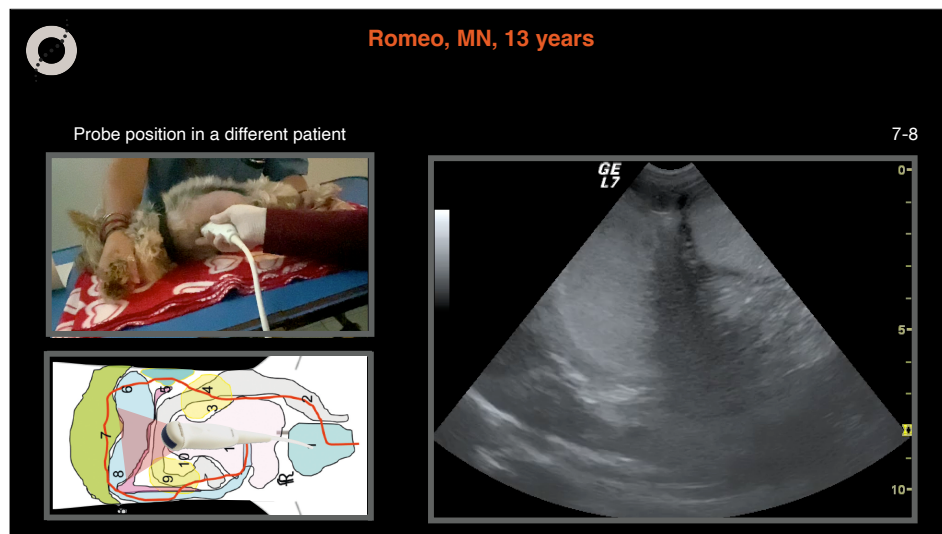
Romeo, MN, 13 years



Romeo, MN, 13 years

Probe position in a different patient



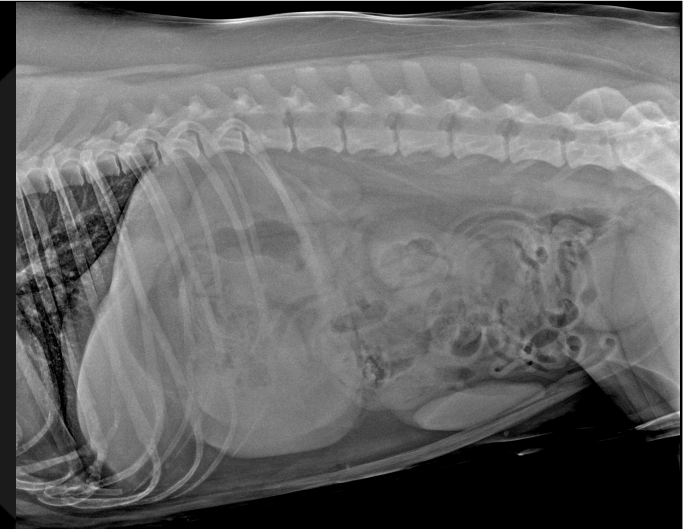


Hermes, Australian Shepherd, MN, 6 years

- Vomiting for three days
- Reduced appetite
- Drinks but then vomits bile

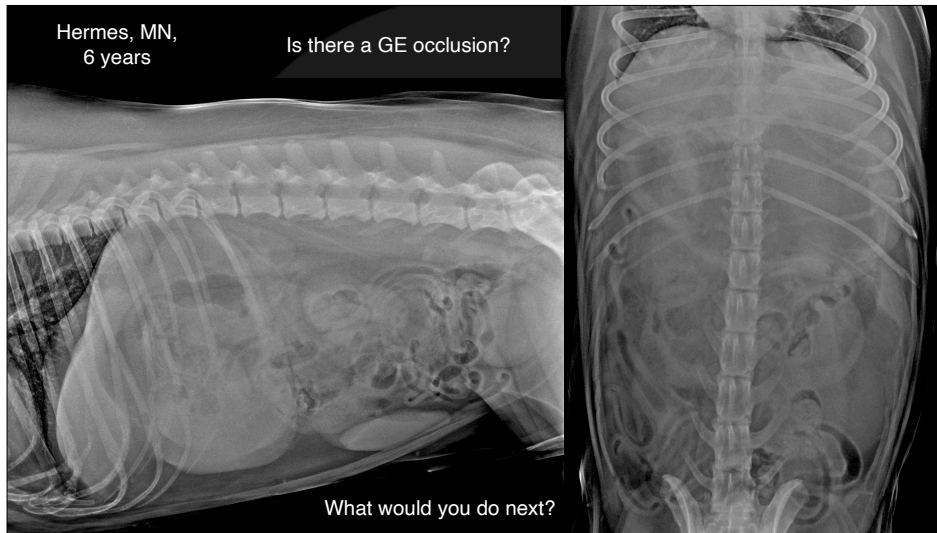


Hermes, MN,
6 years



Hermes, MN,
6 years

Is there a GE occlusion?



What would you do next?

Thank you



Diagnostic Mindset

www.diagnosticmindset.com