

Contrast medium and pathologies of the large intestine

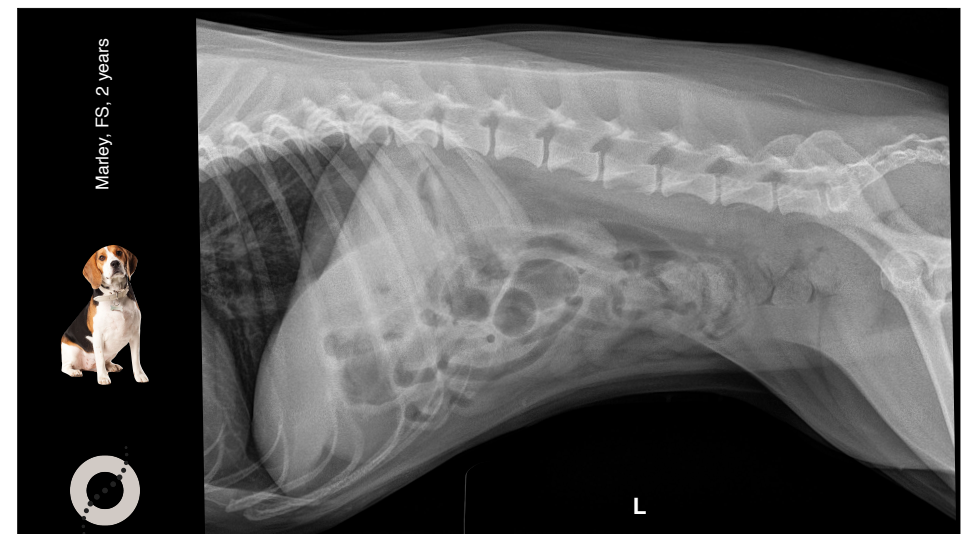
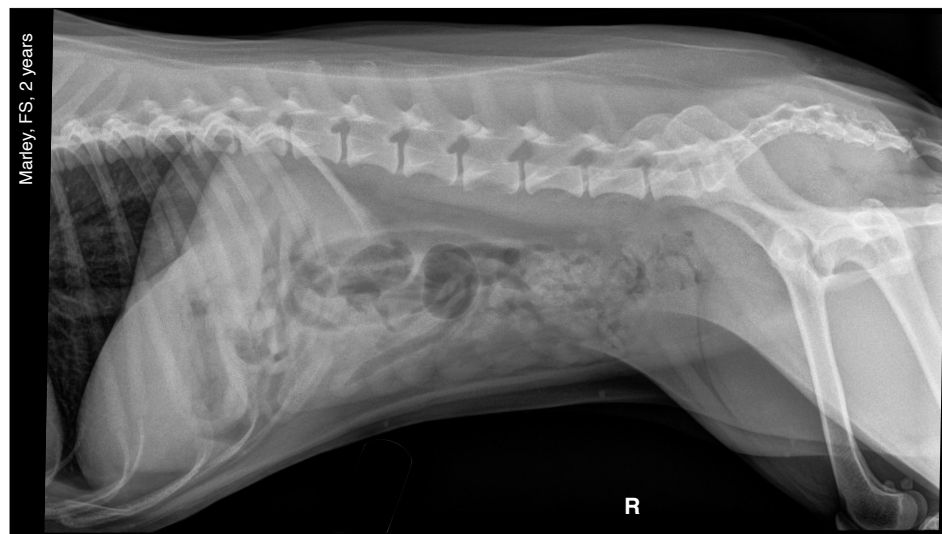


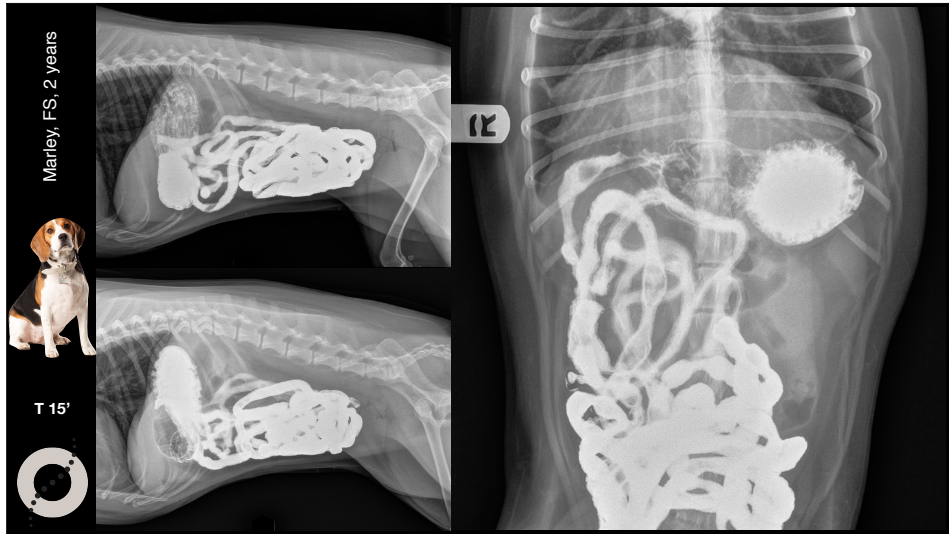
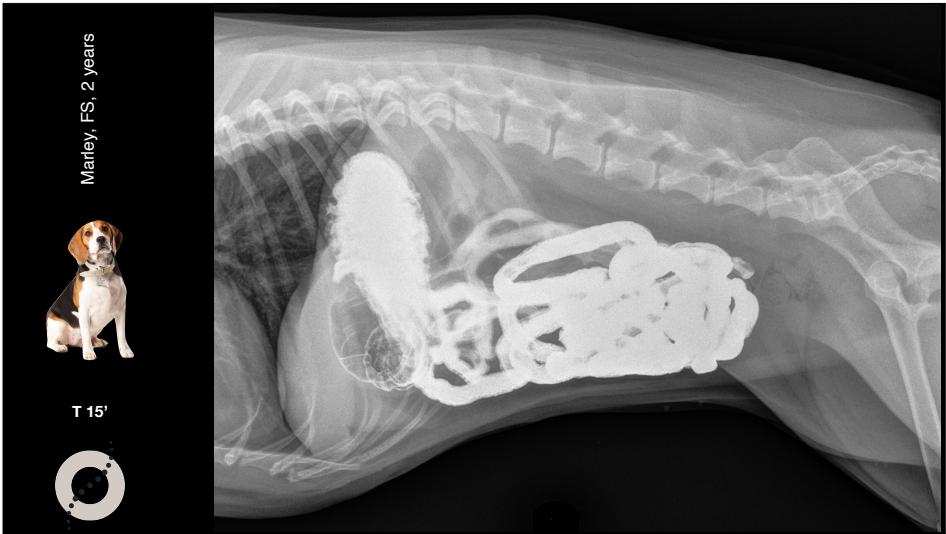
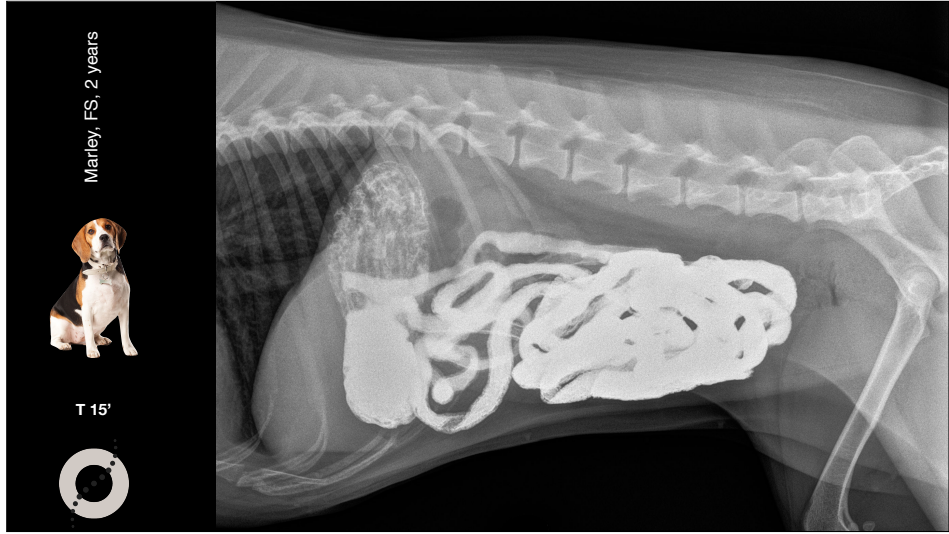
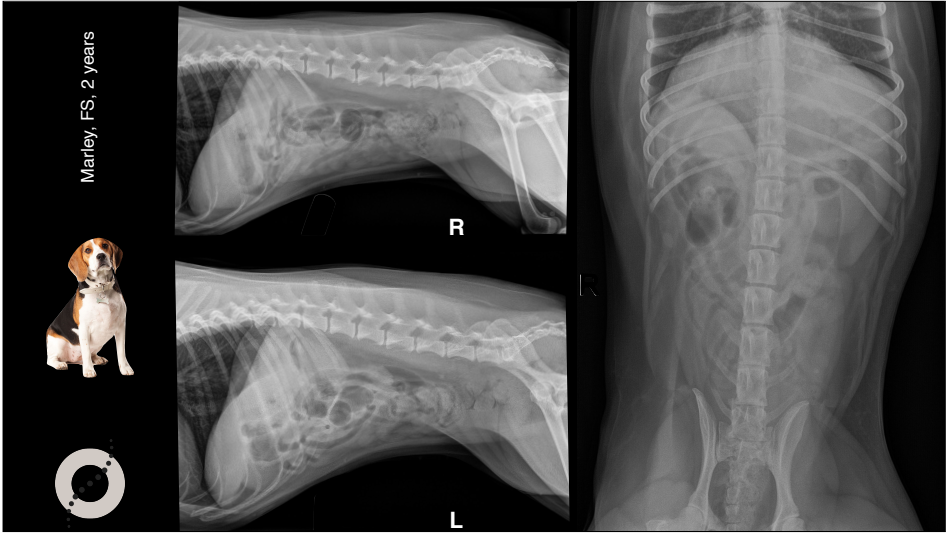
Diagnostic Mindset

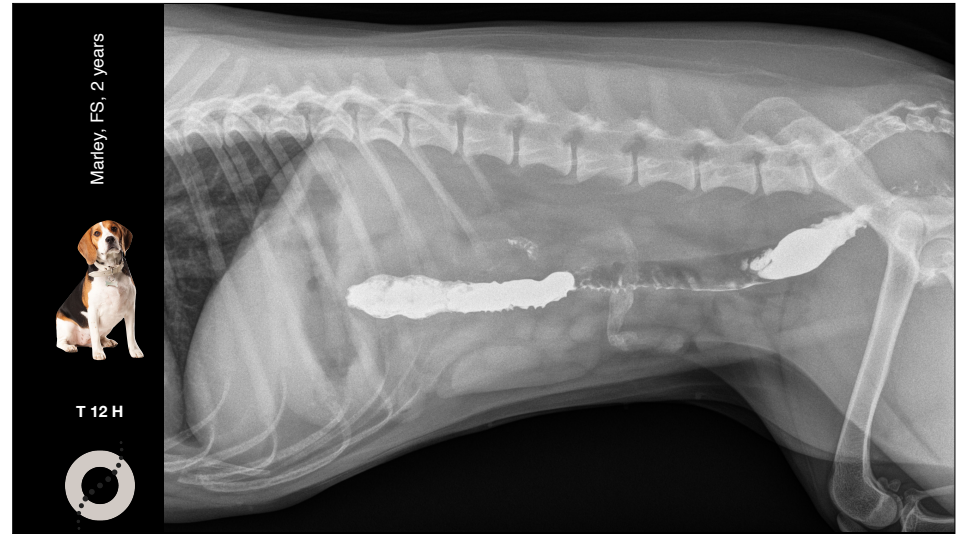
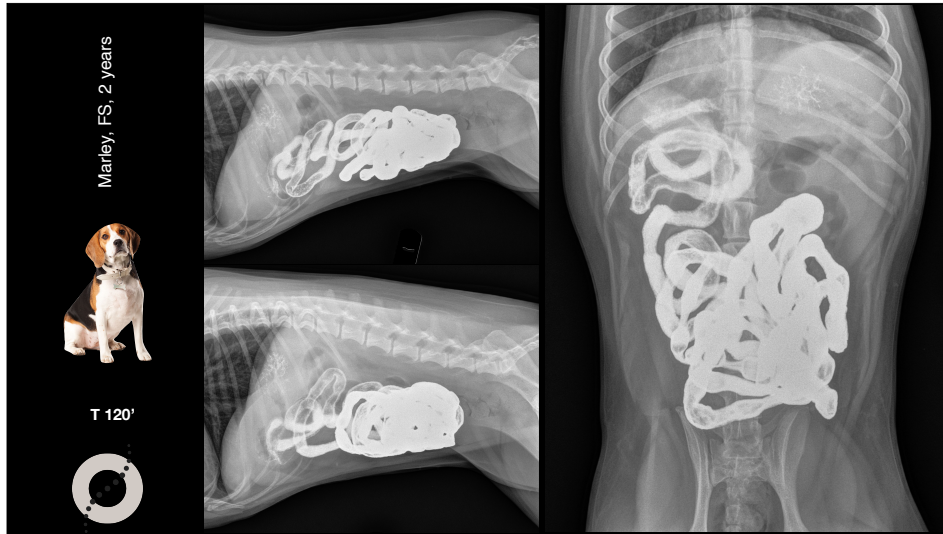
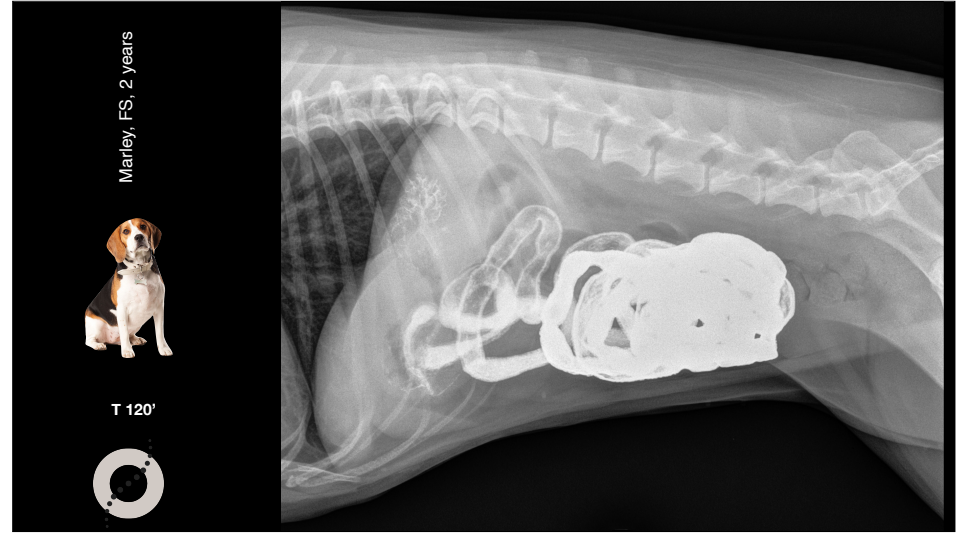
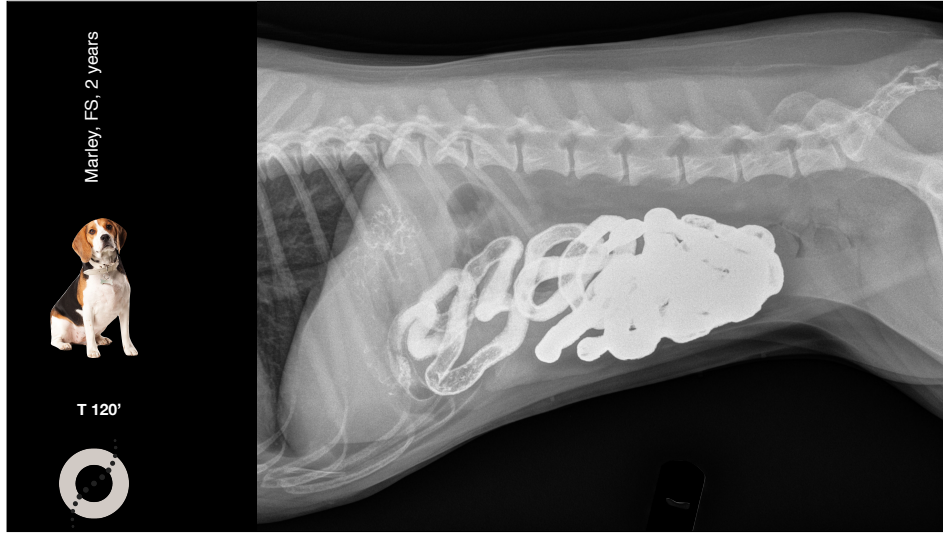
Giliola Spattini
DVM, PhD, DECVDI

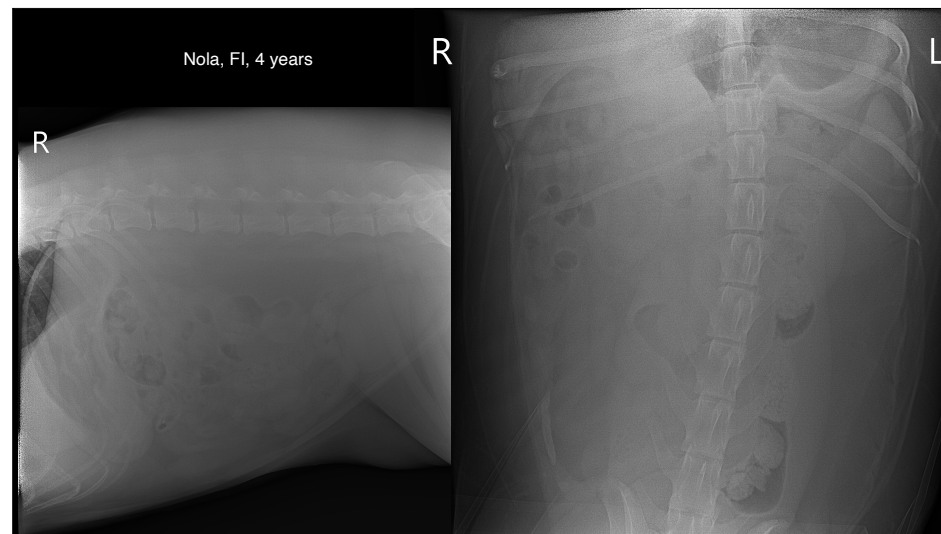
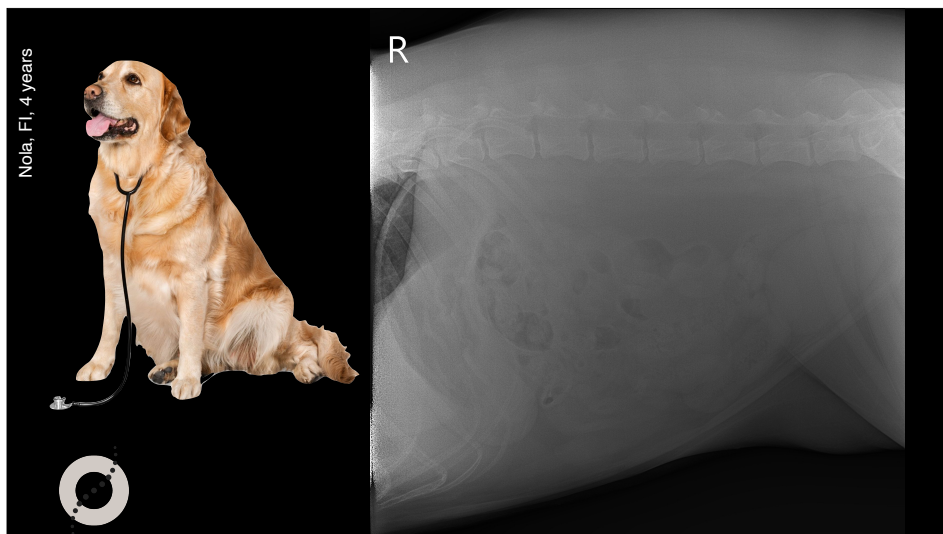
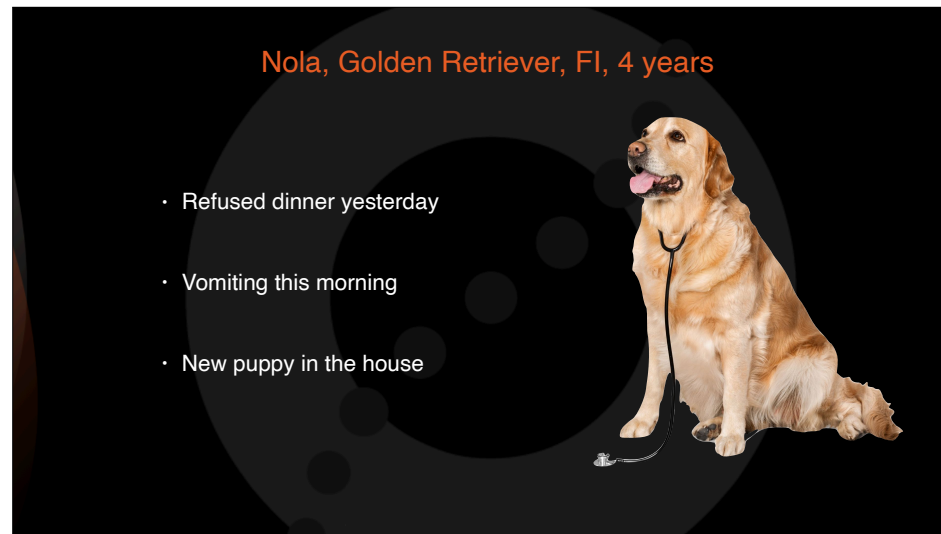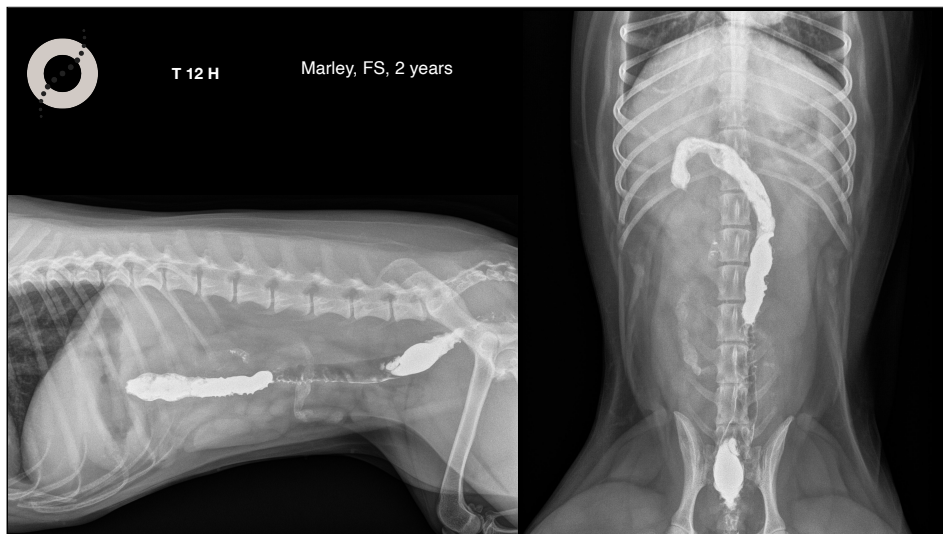
Marley, Beagle, FS, 2 years

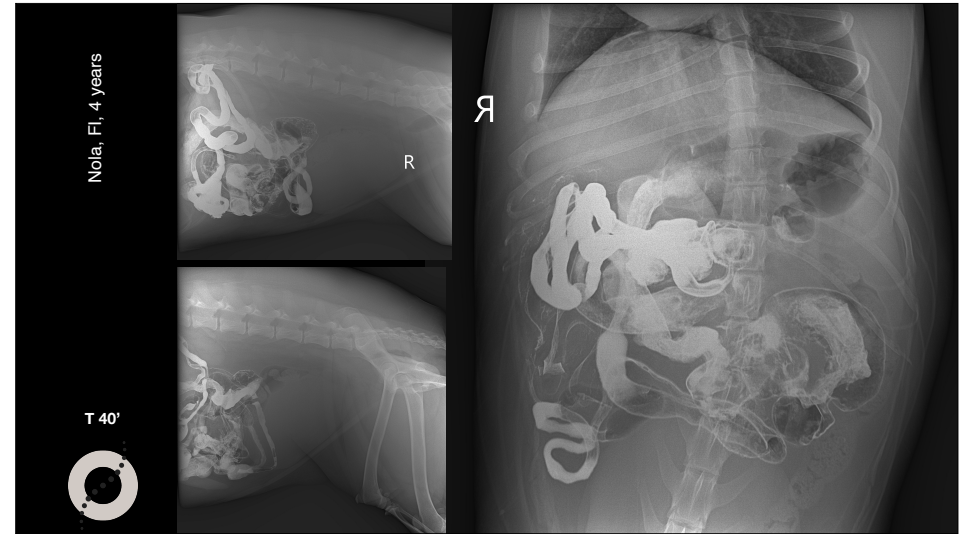
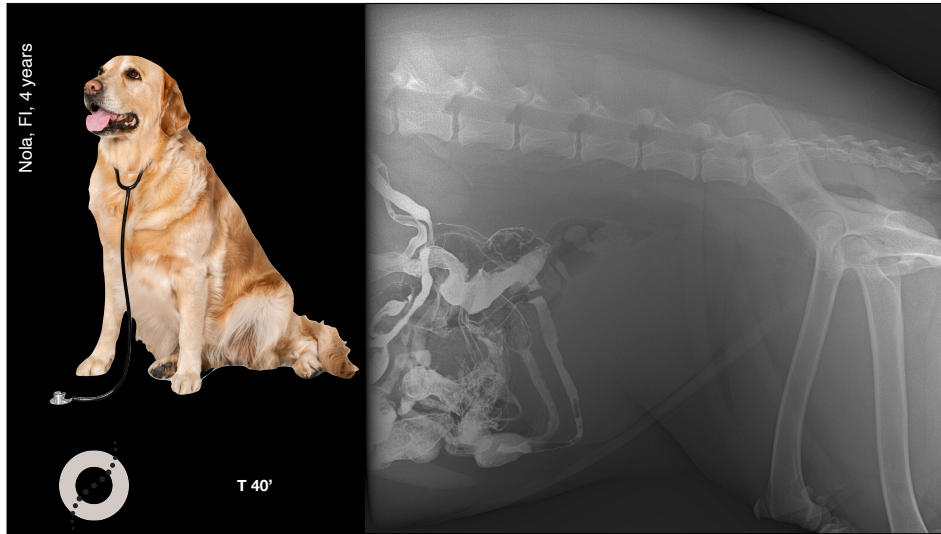
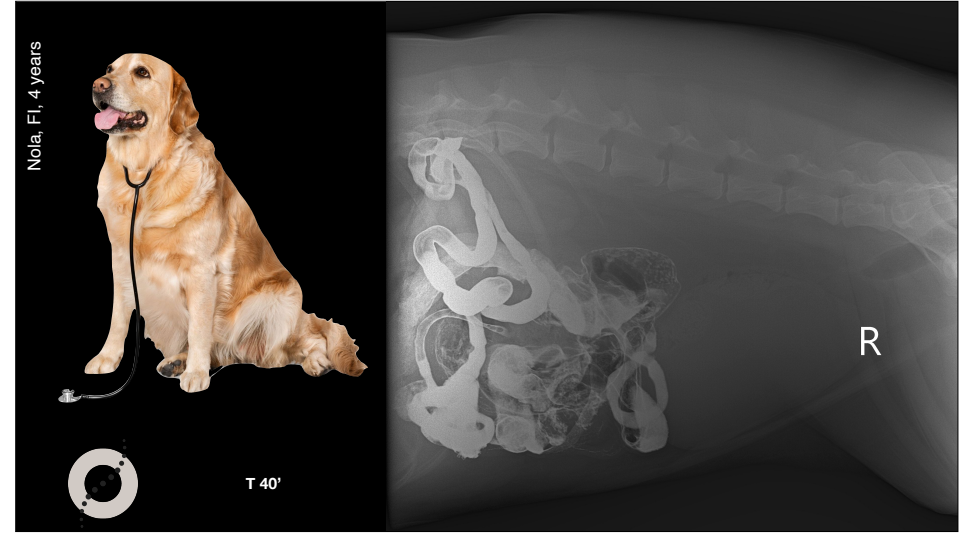
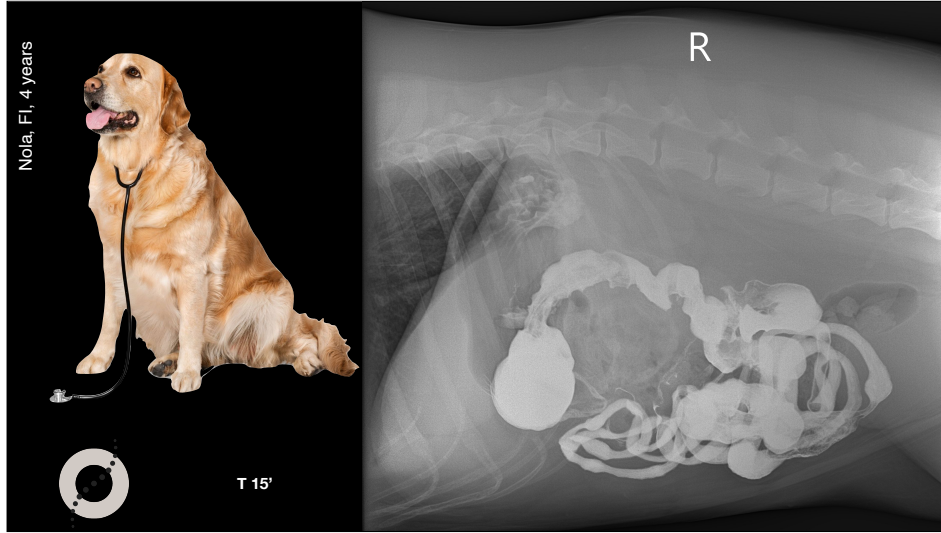
- Vomiting
- Ate mulch 2 weeks ago
- She is vomiting through Cerenia
- No pain on gastric palpation

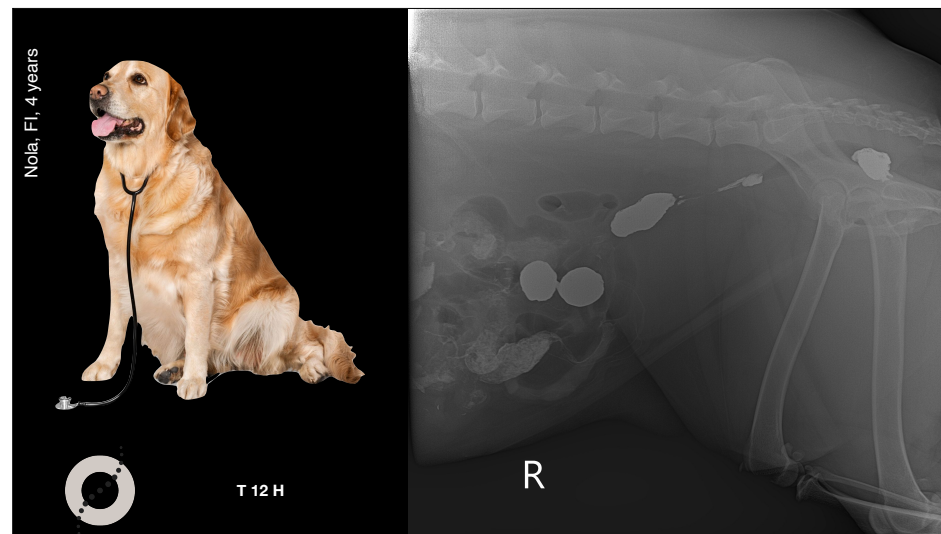
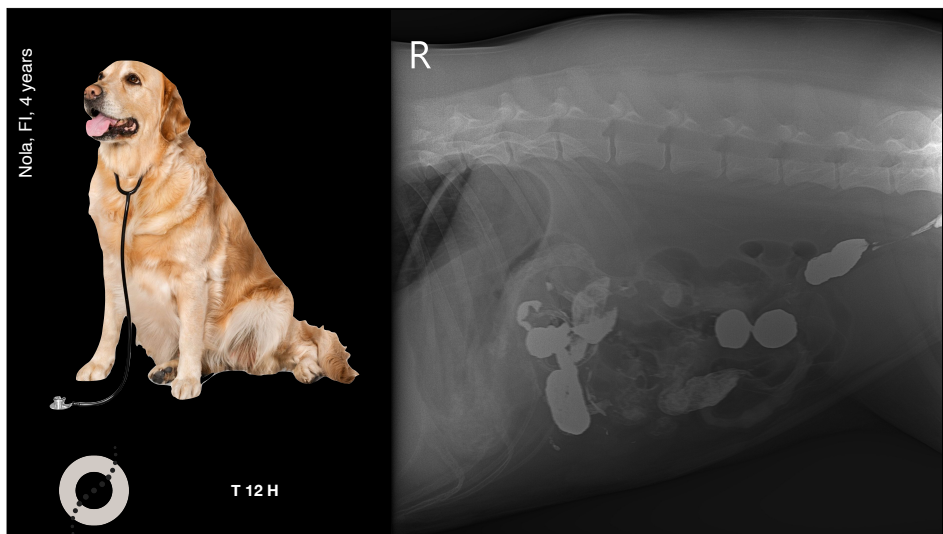
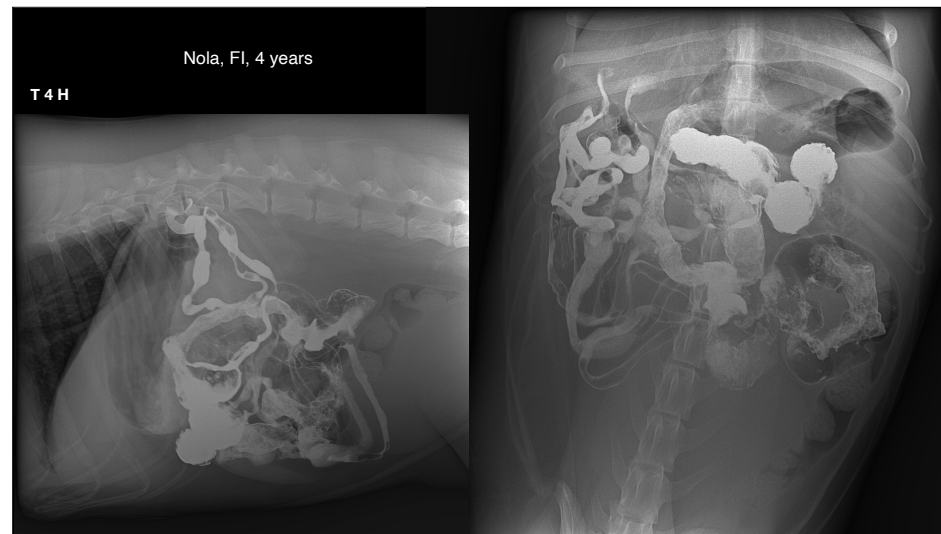
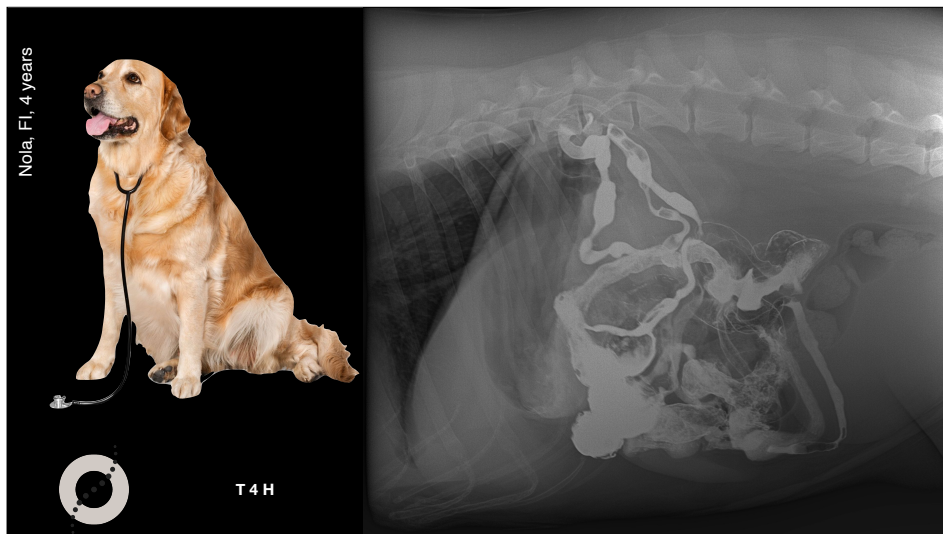



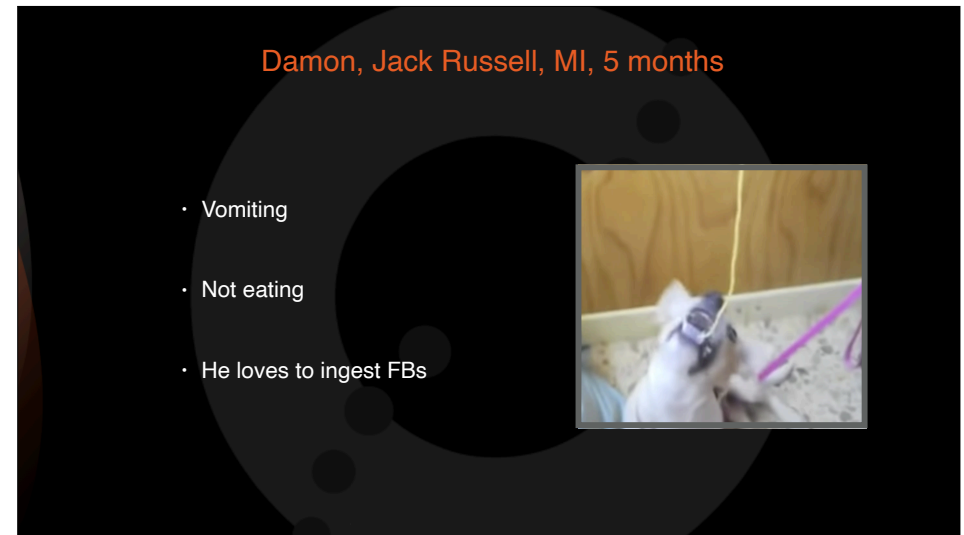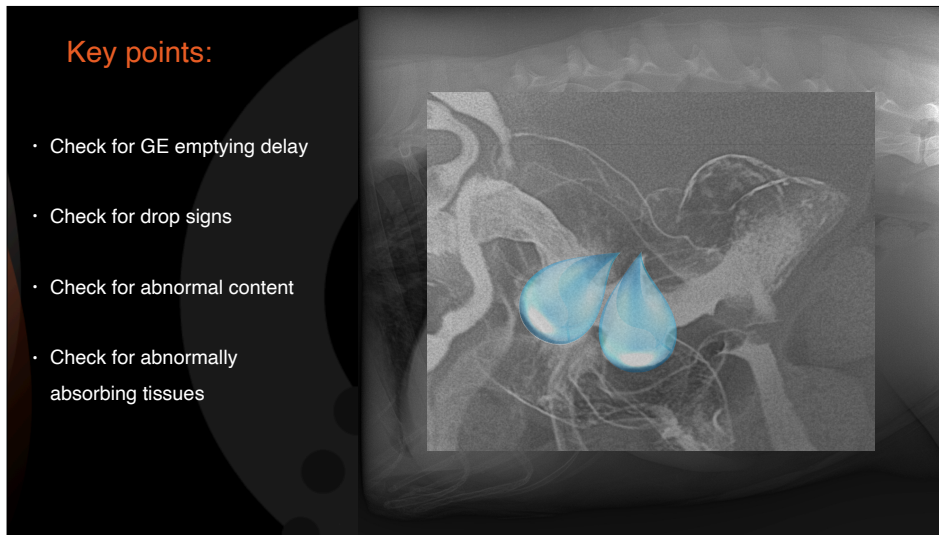
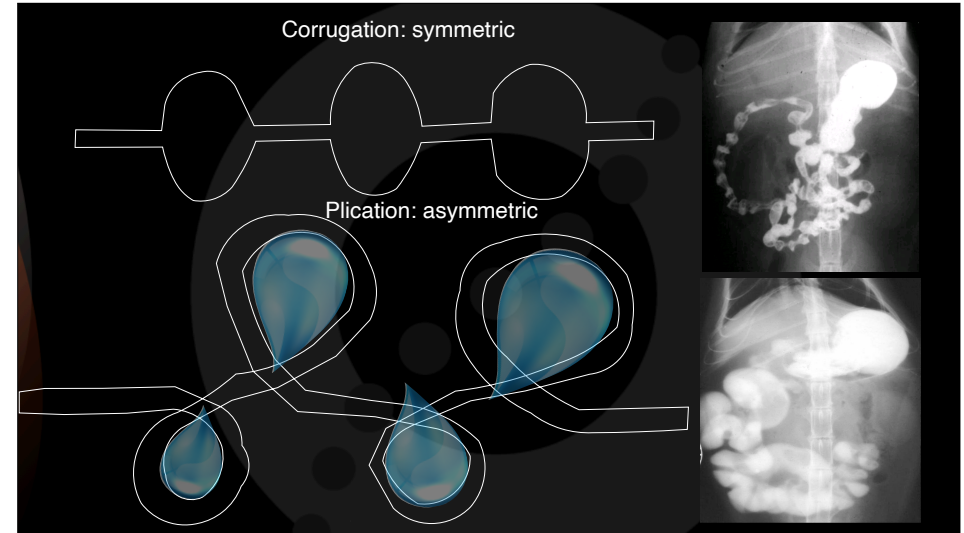
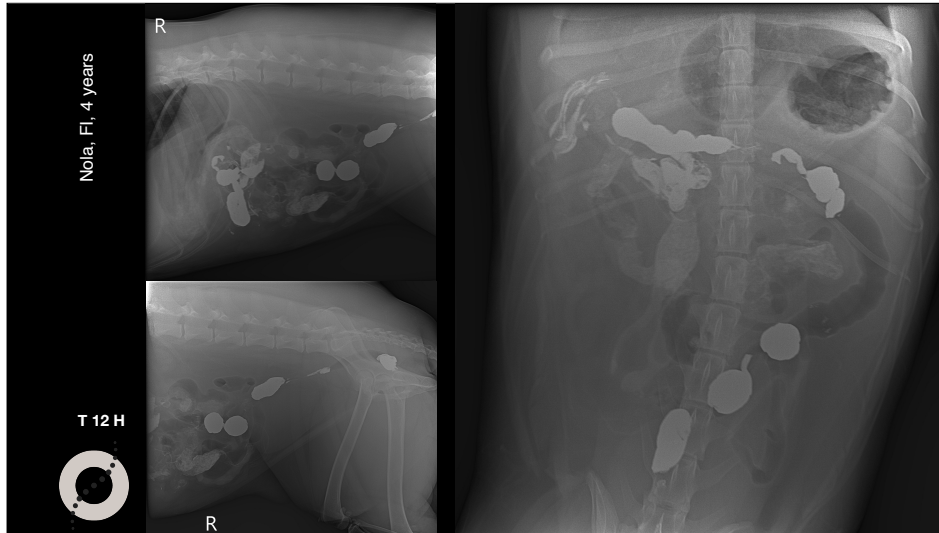


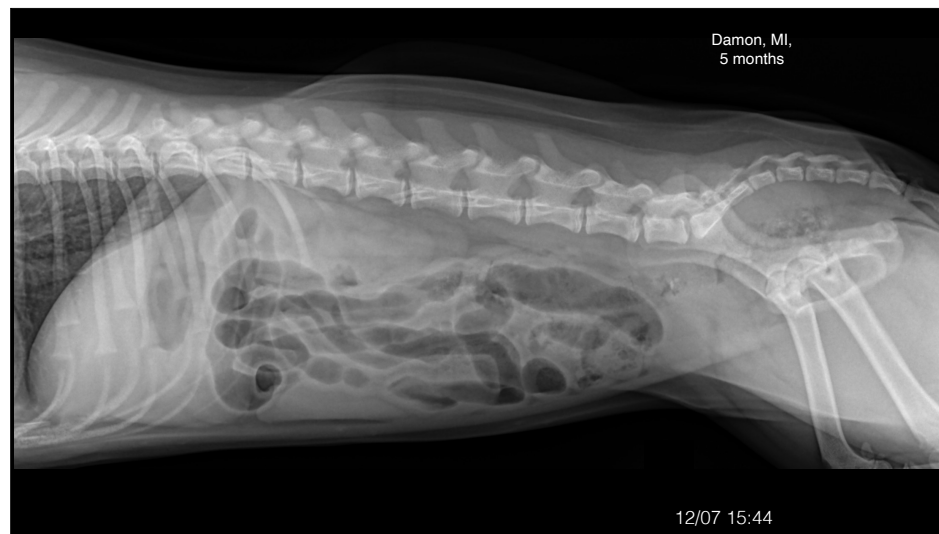
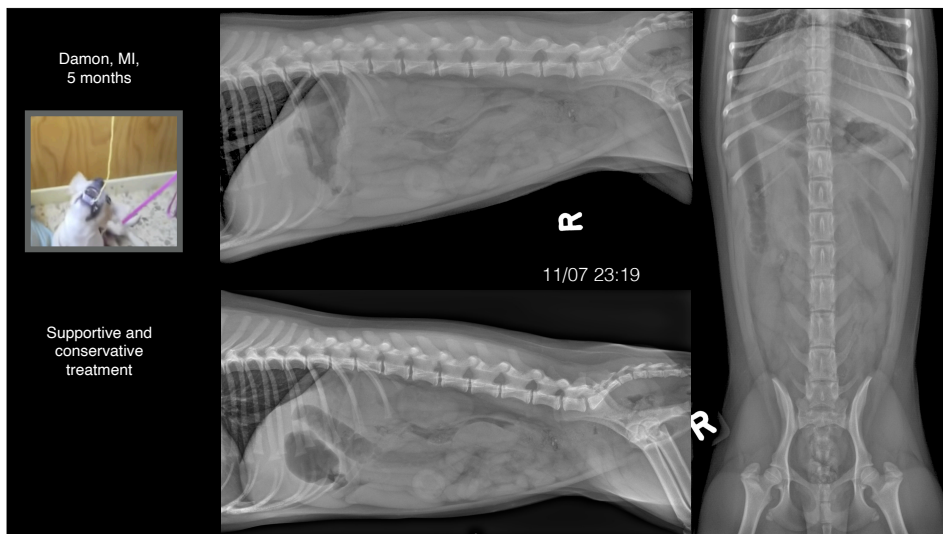

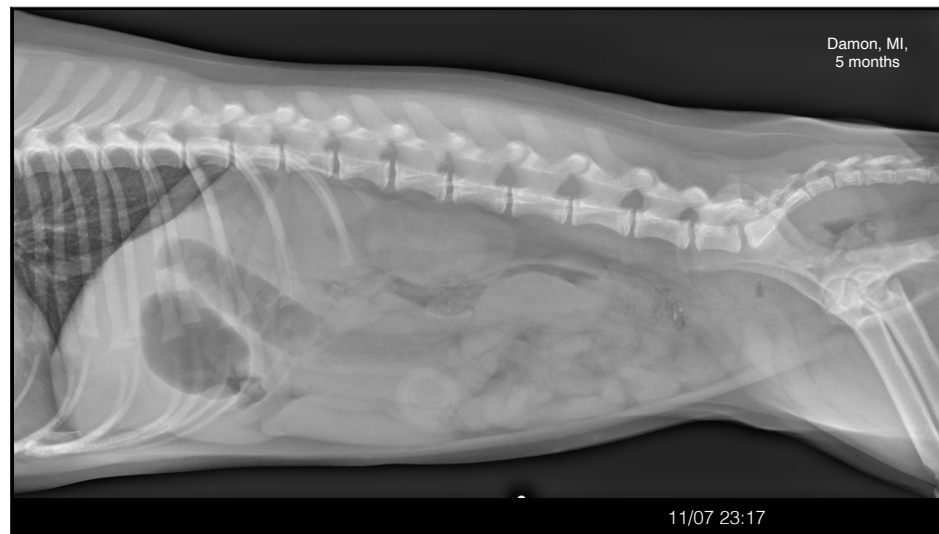
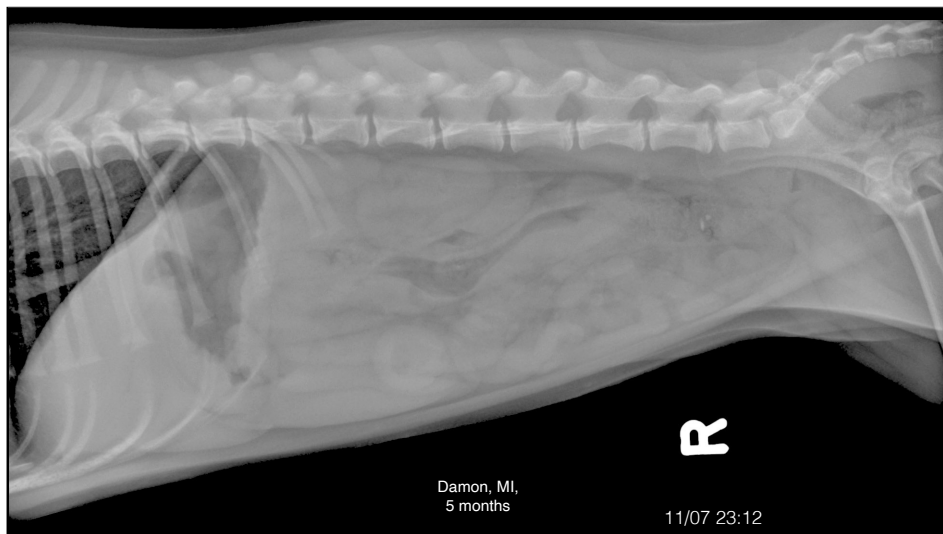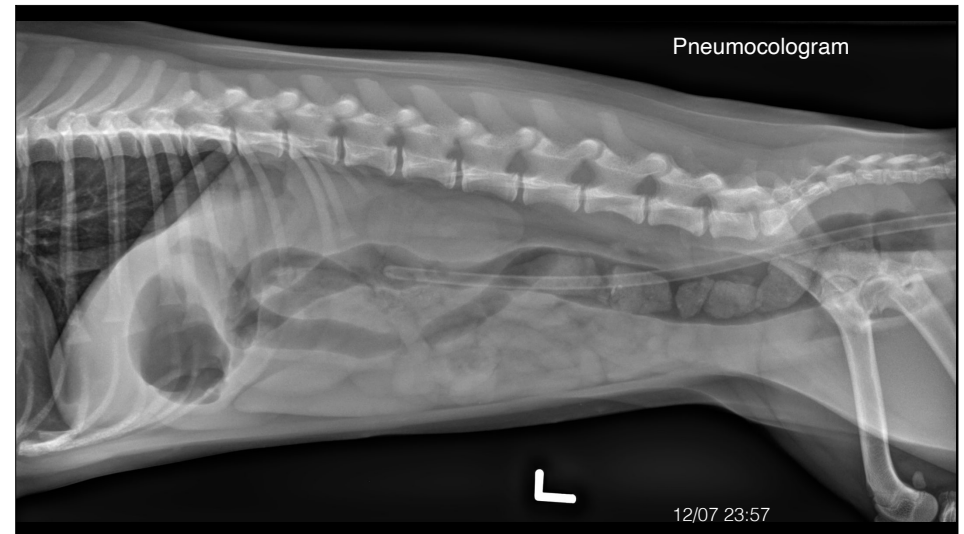
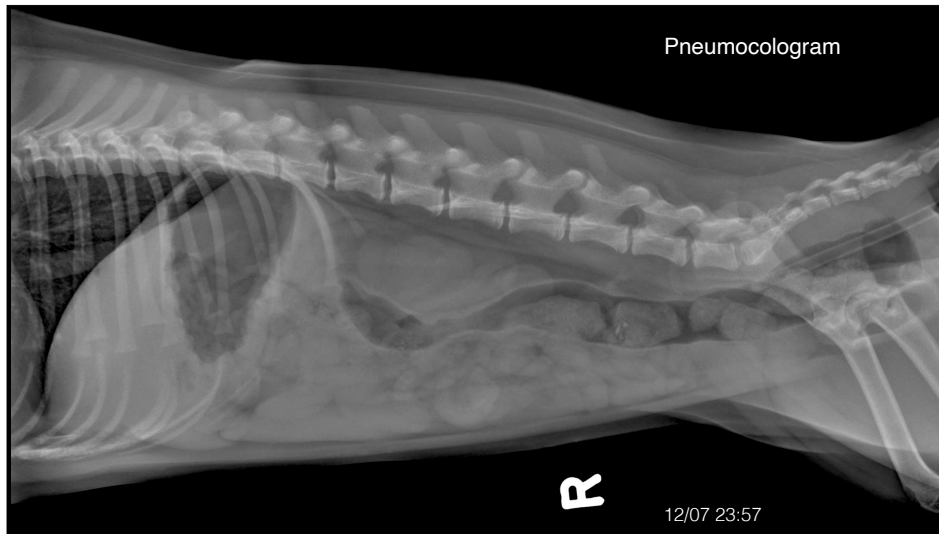
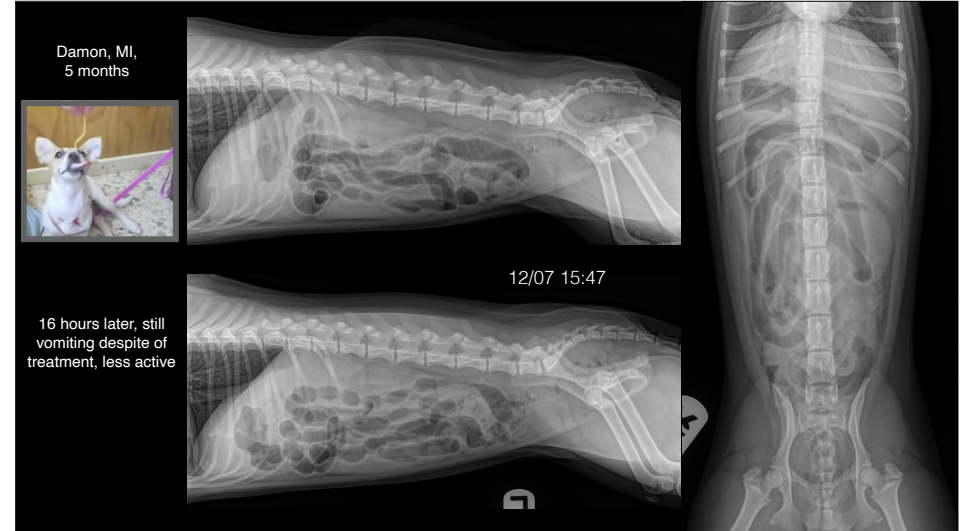


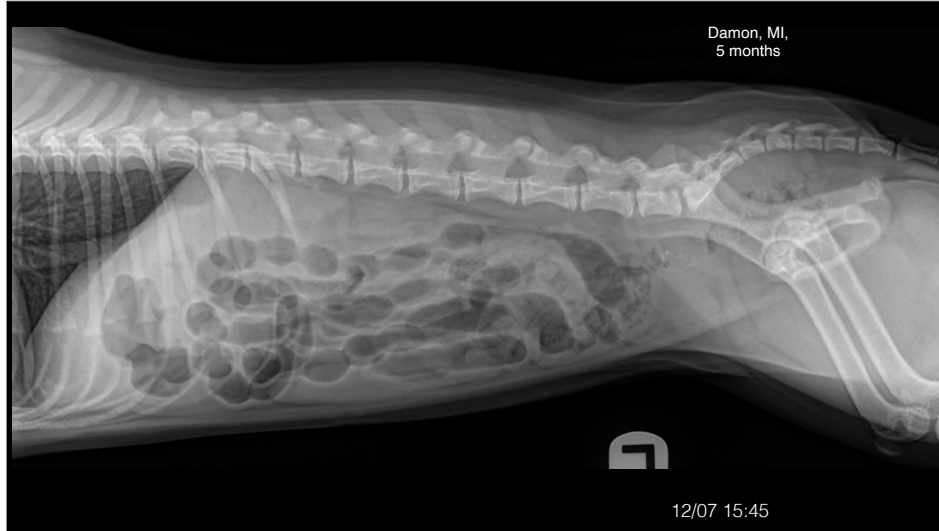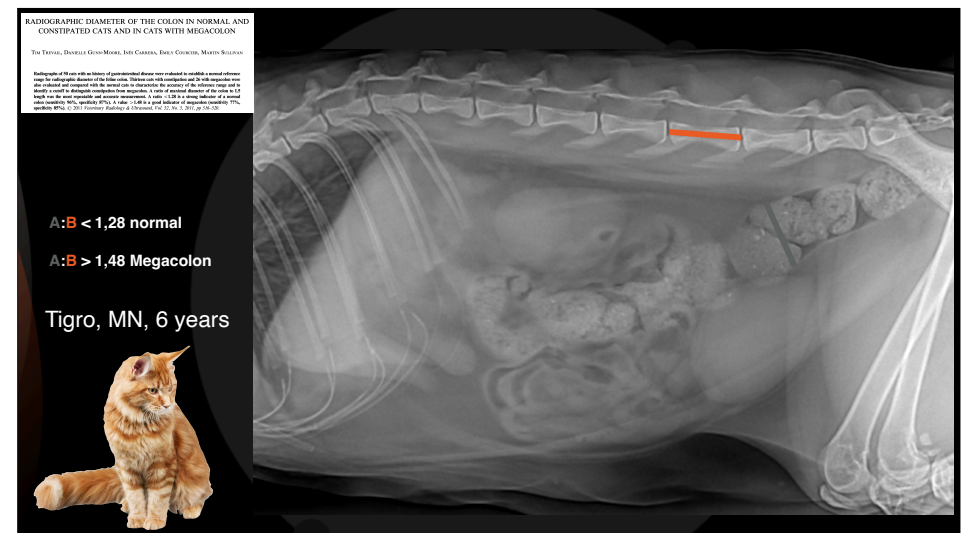
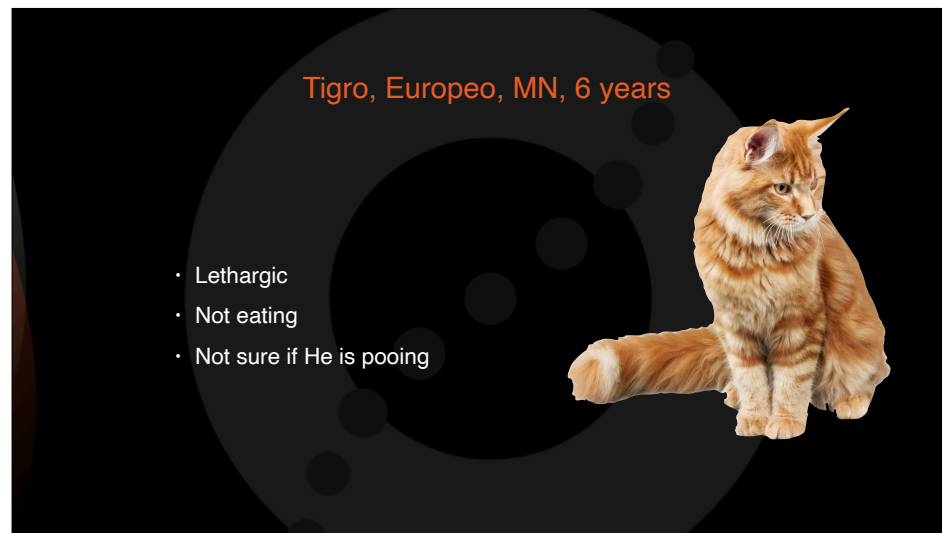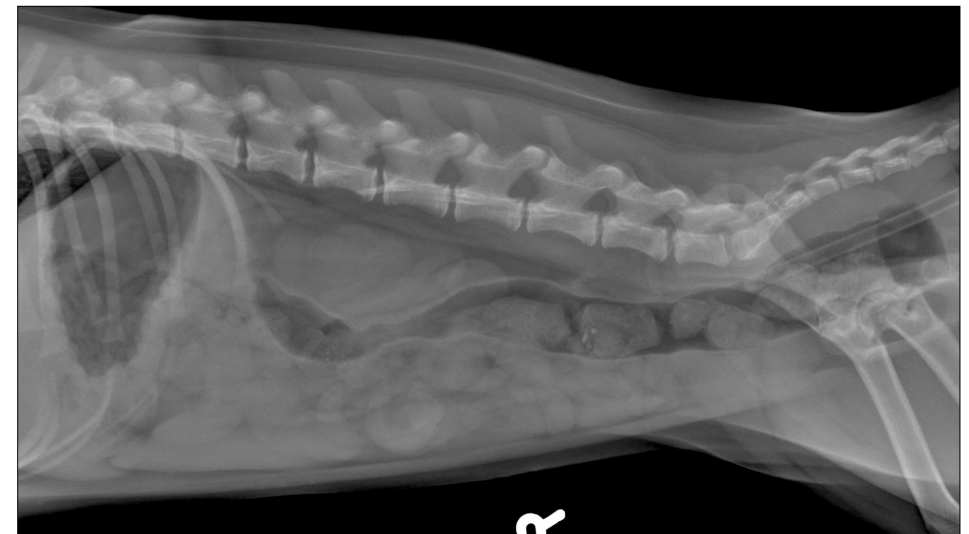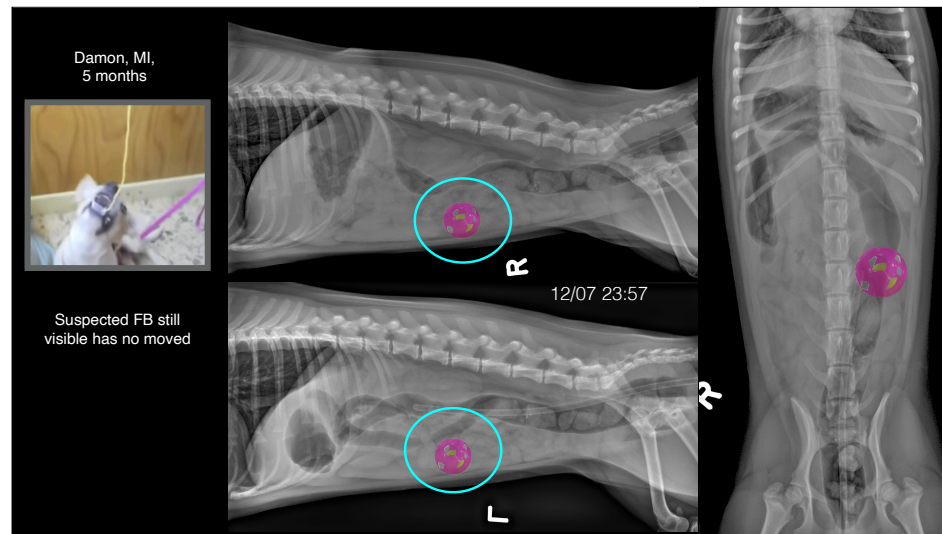








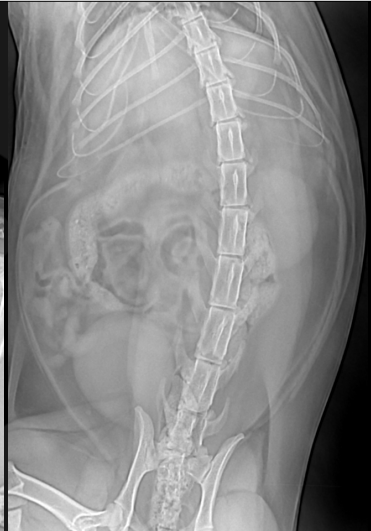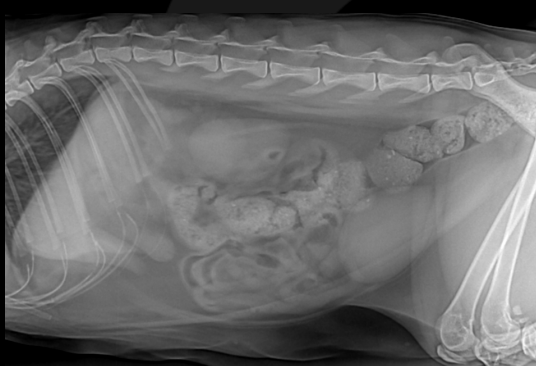




RADIOGRAPHIC DIAMETER OF THE COLON IN NORMAL AND CONSTIPATED CATS AND IN CATS WITH MEGACOLON

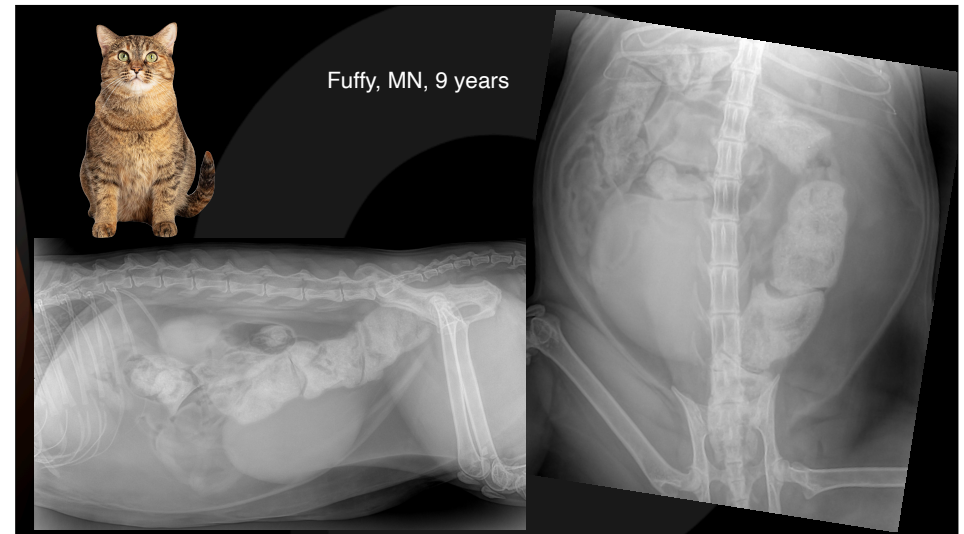
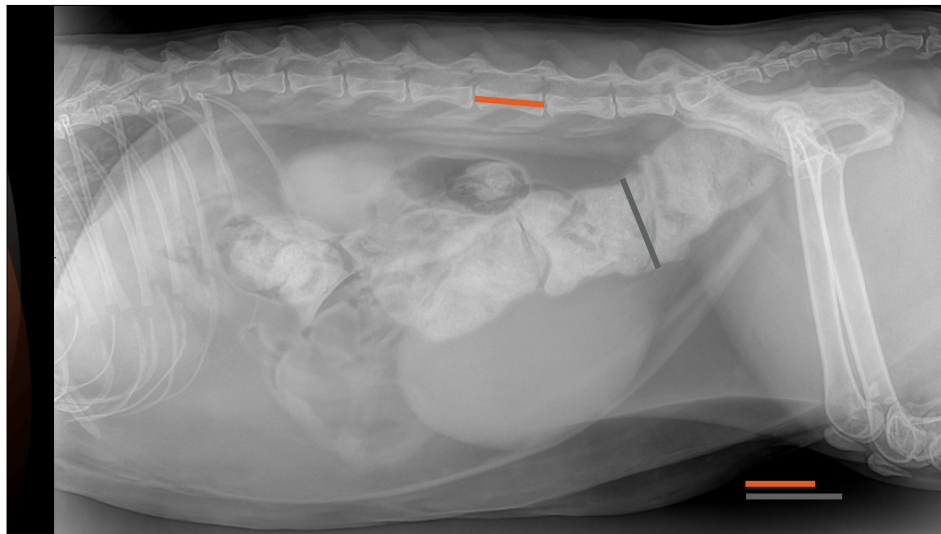
TIM TREVAIL, DANIELLE GUNN-MOORE, INÉS CABRERA, EMILY COURCIER, MARTIN SULLIVAN

Radiographs of 91 cats with no history of gastrointestinal disease were evaluated to establish a normal reference range for radiographic diameter of the feline colon. Thirteen cats with constipation and 26 with megacolon were also evaluated and compared with the normal cats to characterize the accuracy of the reference range and to identify a cutoff to distinguish constipation from megacolon. A ratio of maximal diameter of the colon to 1.5 length was the most repeatable and accurate measurement. A ratio < 1.28 is a strong indicator of a normal colon (sensitivity 96%, specificity 87%). A value > 1.48 is a good indicator of megacolon (sensitivity 77%, specificity 85%). © 2011 Veterinary Radiology & Ultrasound, Vol. 52, No. 5, 2011, pp 516-520.



Fuffy, Europeo, MN, 9 years

- Not pooing
- Not eating
- Lethargic



Fuffy, MN, 9 years

Thank you



Diagnostic Mindset

www.diagnosticmindset.com