



Most Common Sport related
Phalangeal Lesions Seen in Practice

MSK Ultrasonography - The Fore Limb
Canine Sport Medicine Espoo - Finland 2023

Alessandro Piras
DVM - ISVS


Clinical Examination




NAILS - PADS - WEBS




Clinical Examination



PHALANGES



Test Collateral Ligaments in Extension

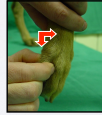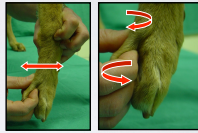


TRAKR.

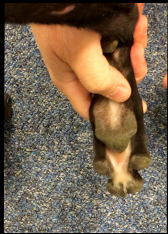
Clinical Examination




Metacarpo Phalangeal Joints



Clinical Examination



Sesamoids and Flexor T.



Check for crepitus over sesamoids



Palpate Sup. and Deep Flexor Tendons

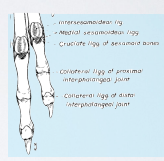
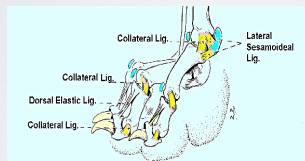
METACARPO / TARSO PHALANGEAL INSTABILITY

Different Types of Instability

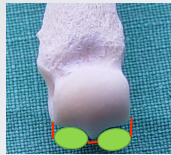
Simple collateral - partial & total

Simple sesamoid & flexor tendons

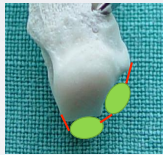
Complex multiplanar



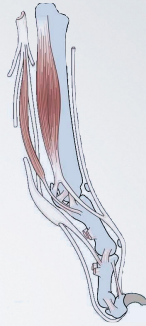
The Sesamoids Mechanism



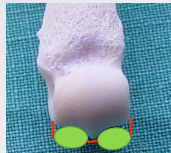
IV - III



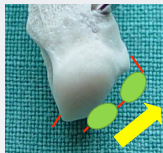II - V



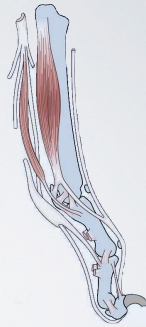The Sesamoids Mechanism



IV - III



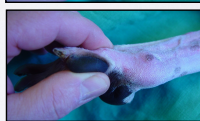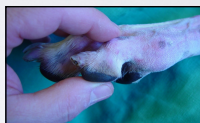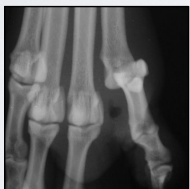II - V



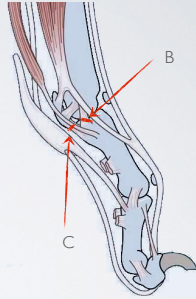
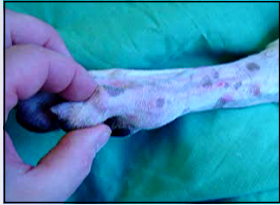Metacarpo / Tarso Phalangeal Instability

Subluxation: common injury in sporting dogs

Complete Luxation: Rare

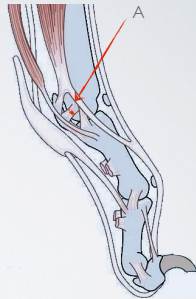
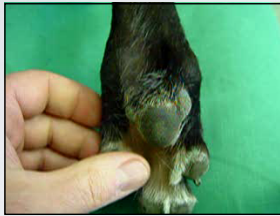

Simple Collateral



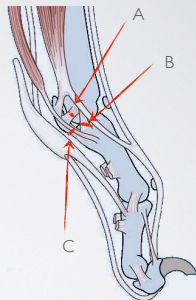
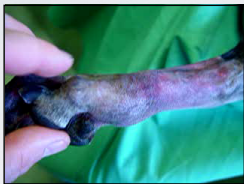C : Sesamoid - Phalangeal Ligament
B : Metacarpo - Phalangeal Ligament

Simple sesamoid & flexor tendons



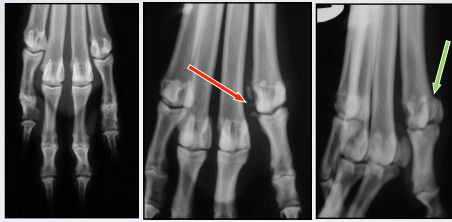
A : Metacarpo - Sesamoid Ligament
C : Sesamoid - Phalangeal Ligament

Complex Multiplanar



A : Metacarpo - Sesamoid Ligament
C : Sesamoid - Phalangeal Ligament
B : Metacarpo - Phalangeal Ligament

RADIOGRAPHIC EXAMINATION



DP Standard

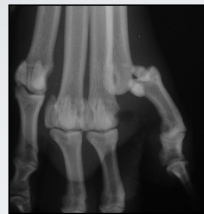DP Oblique

ML Oblique

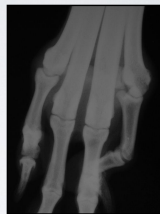Standard Lateral not sensitive

RADIOGRAPHIC EXAMINATION

Stress views

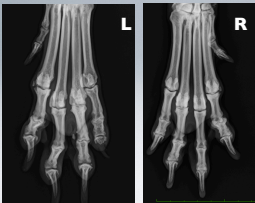

DP Stress View



DP Weight Bearing

SESAMOID INJURIES



5 Years of Age Border Collie
or AU Sheep Dog
Agility Champion
"A Classic"

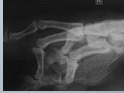

"Poldo" Dalmatian - Male 4 Y. of Age - Agility - CHRONICALLY LAME since 8 Months

Operated twice by "Top Gun"

First op: Surgical Inspection?? Founded that extensor tendons were "strange" (?)
Second Op: Surgical removal of "calcification" in extensor tendon (happened to be the dorsal sesamoid...)

Surgical Proposal: Hip Replacement (B grade), PAUL, Arthroscopy of Carpus & Shoulder; Limb Alignment, TTTT, BULL, TWID



Diagnostic Images guys Proposals: CT, MRI, Scintigraphy, Ultrasonography, Thermocamera, Fluoroscopy...

Other Second Opinions:

Chiropractic founded parasagittal cross patterns with cociceal abandon syndrome with "pop out disc" at C6- C7. Proposed 76 realignment therapeutic sessions for a total cost of a Lamborghini Kurstah

Aroma Therapist founded Calendula and Violet missing in his system. Proposed to give 3 liters of herbal tea (marijuana) a day in order to stimulate inner-soul creativity. Owners allowed to share the experience

Canine behaviorist founded classic signs of depression and attention sicker attitude. Proposed castration and

750 hours of reeducation therapy, total cost of a ticket for next Shuttle to Mars

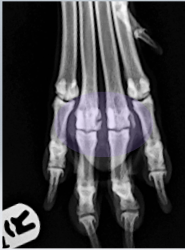
Acupuncturist found actually that the dog was lame in one of the front limbs and gave an appointment for treatment the 31 of February 3012, in her defense... they getting very busy lately

Physiotherapist 1 confirmed the presence of lameness and sold to the owner TECAR, LASER, Water Treadmill and 27 varieties of exercise balls and rolls


Physiotherapist 2 found a lack of functionally sound recruitment of the biomechanical receptors for cross balance that affected the equilibrium between tangible active restrains and secondary psychomotor skills promoting alternate feedback. The owners punch her in the nose....

Alternative proposals: Philippine faith healer; holy water from Lourdes (original Batch), sell the dog to the Circus, Hart Transplant.....

"Poldo" Dalmatian - Male 4 Y. of Age - Agility - CHRONICALLY LAME since 8 Months

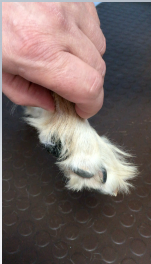

Mystery Sorted



Sesamoid Fragmented - Decreased ROM MTC-Ph Joint III and IV - Pain in flexion

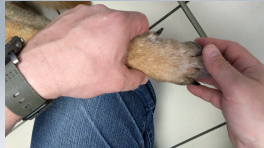Secret Weapon
Triamcinolone Acetonide



Warm Up Massages with Embrocation
Passive ROM
Balance Board



Instrumental Treatments- Laser, TECAR, Ultrasounds



INTERPHALANGEAL LUXATION

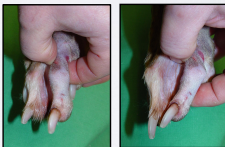
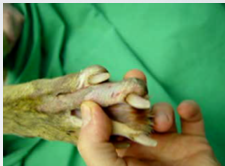Diagnosis

Clinical Examination

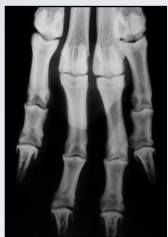Lameness + \ -

Swelling

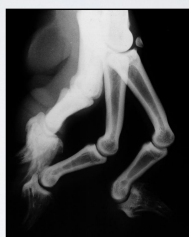Pain and joint instability



RADIOGRAPHIC EXAMINATION



DP or PD

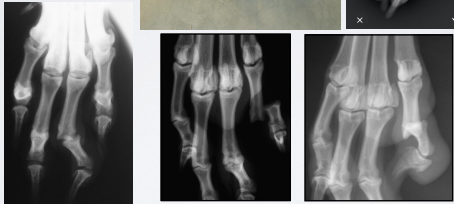

ML or LM

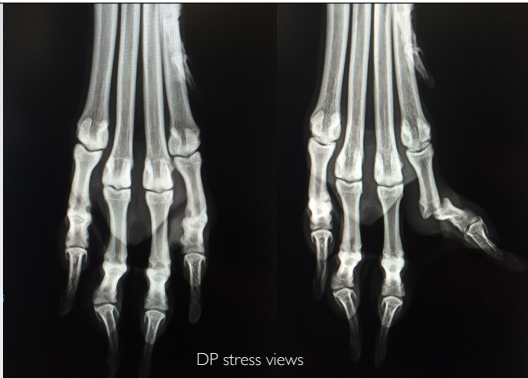Not sensitive

RADIOGRAPHIC EXAMINATION

DP stress views

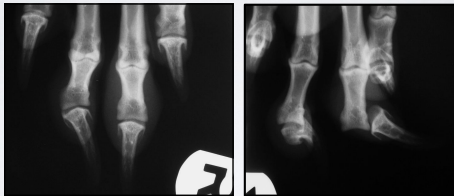


DP stress views



RADIOGRAPHIC EXAMINATION

DP stress views



SUPERFICIAL DIGITAL FLEXOR METACARPAL/TARSAL REGION

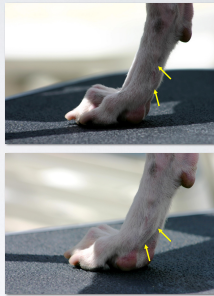
"bowed tendon" strain

Chronic injury - poor performance

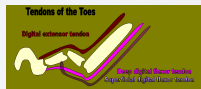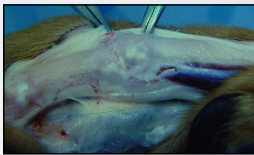
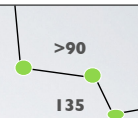
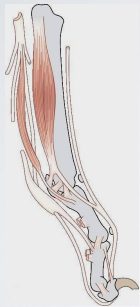Medical -time, rest, etc

Resect section of tendon

"flat toe" - return to work

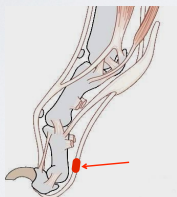


DIGITAL FLEXOR TENDONS



RUPTURE OF THE DEEP FLEXOR TENDON

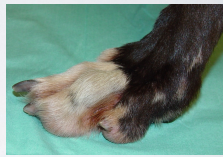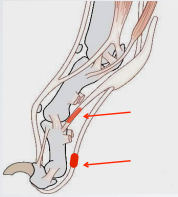
Intact Superficial flexor tendon



Third phalanx hyperextended

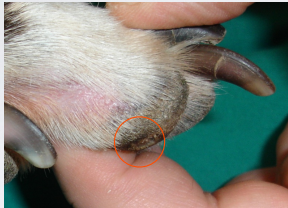RUPTURE OF THE DEEP FLEXOR TENDON TYPICAL EVOLUTION

Superficial flexor tendon start stretching



P1 – P2 hyperextend
P1 - P2 tend to "flatten"

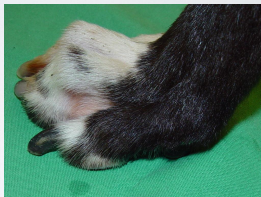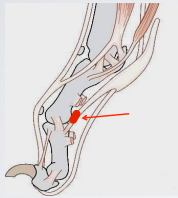
RUPTURE OF THE DEEP FLEXOR TENDON TYPICAL EVOLUTION



Abnormal pressure on digital pad
Development of corn and ankylosis of P2 – P3

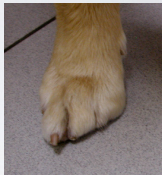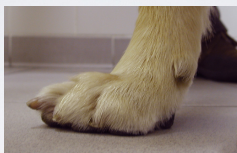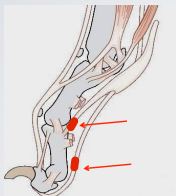
RUPTURE OF THE SUP. FLEXOR TENDON

Intact Deep flexor tendon



P1 – P2 extended
P2 – P3 normal angle, nail touching ground

RUPTURE OF THE SUP. AND DEEP FLEXOR TENDONS



P1 – P2 extended
P2 – P3 extended, nail up

Injuries to Feet

Foreign objects

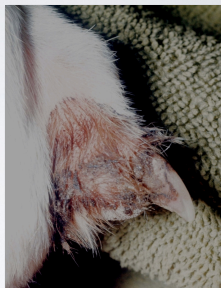Cuts

Paronychia

"pulled nail"

"split nail"

"corns"



Injuries to Feet

Foreign objects

Cuts

Paronychia

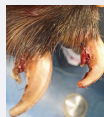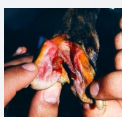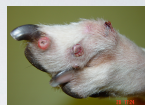"pulled nail"

Pemphigus AKA Symmetrical Lupoid Onchodystrophy

"split nail"

"Verrucas"

"corns"



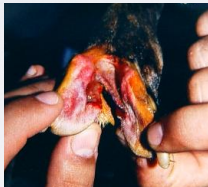NAIL CHEWING



INJURIES OF THE WEBBING

Small lacerations sutured in layers and supported

Larger splits are extended to the apex of the web and primarily sutured to create a permanent healed deficit



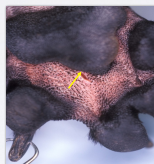
INJURIES OF THE PAD

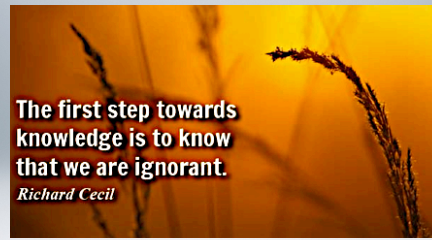Superficial injuries managed via good hygiene & medicated dressings

Lacerations sutured and coapted

Puncture wounds cleaned & evaluated for foreign material

Deep wounds may involve DDF tendon





**The first step towards
knowledge is to know
that we are ignorant.**

Richard Cecil
