

Persistent septic arthritis in a Golden Retriever

CASE DISCUSSION


Giliola Spattini
DVM, GP Cardio, CCRT, PhD, DECVDI



Diagnostic Mindset



Thank to www.imaios.com



Bombo, Golden, MI, six years

- Two months ago, acute and severe left front paw swelling and lameness
- Diagnosed pododermatitis
- Ultrasound saw carpal effusion - aseptic neutrophilic synovitis on cytology



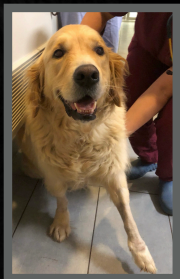

Bombo, Golden, MI, 6 years

- Lameness improves with AB but is still present
- Worsened as soon as AB is dismissed
- Second ultrasound examination was suggestive of cellulitis

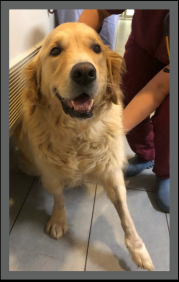

Bombo, MI, 6 years

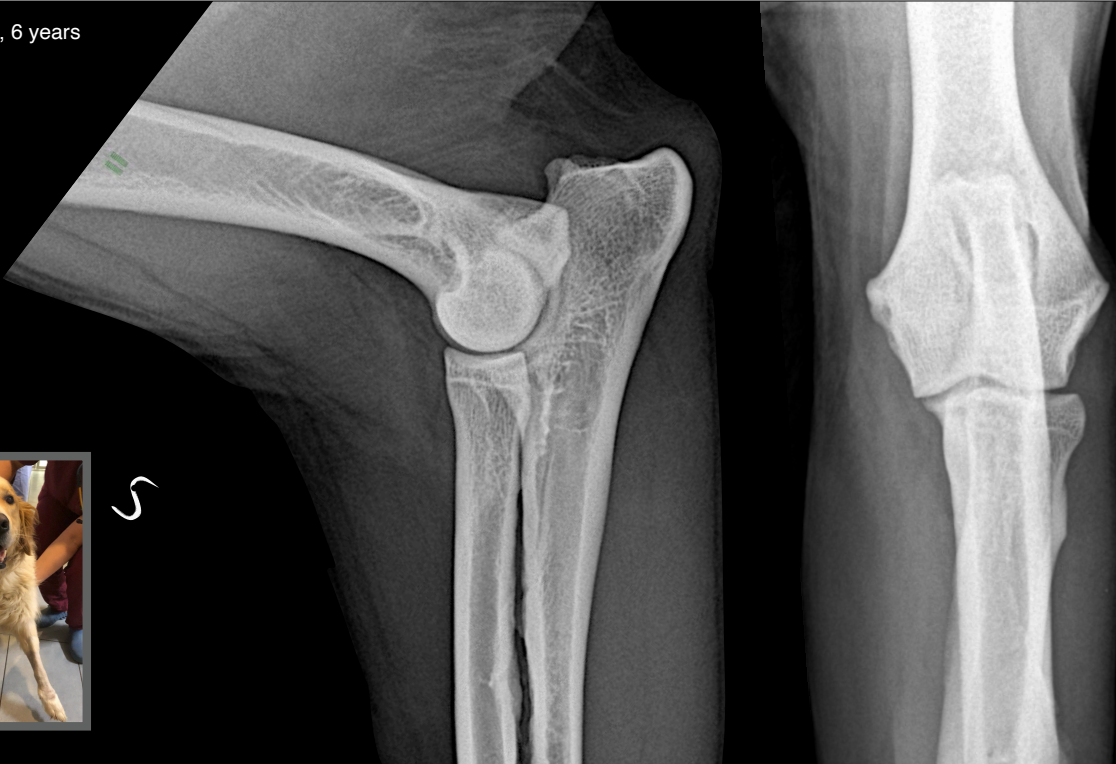

D

Bombo, MI, 6 years



S

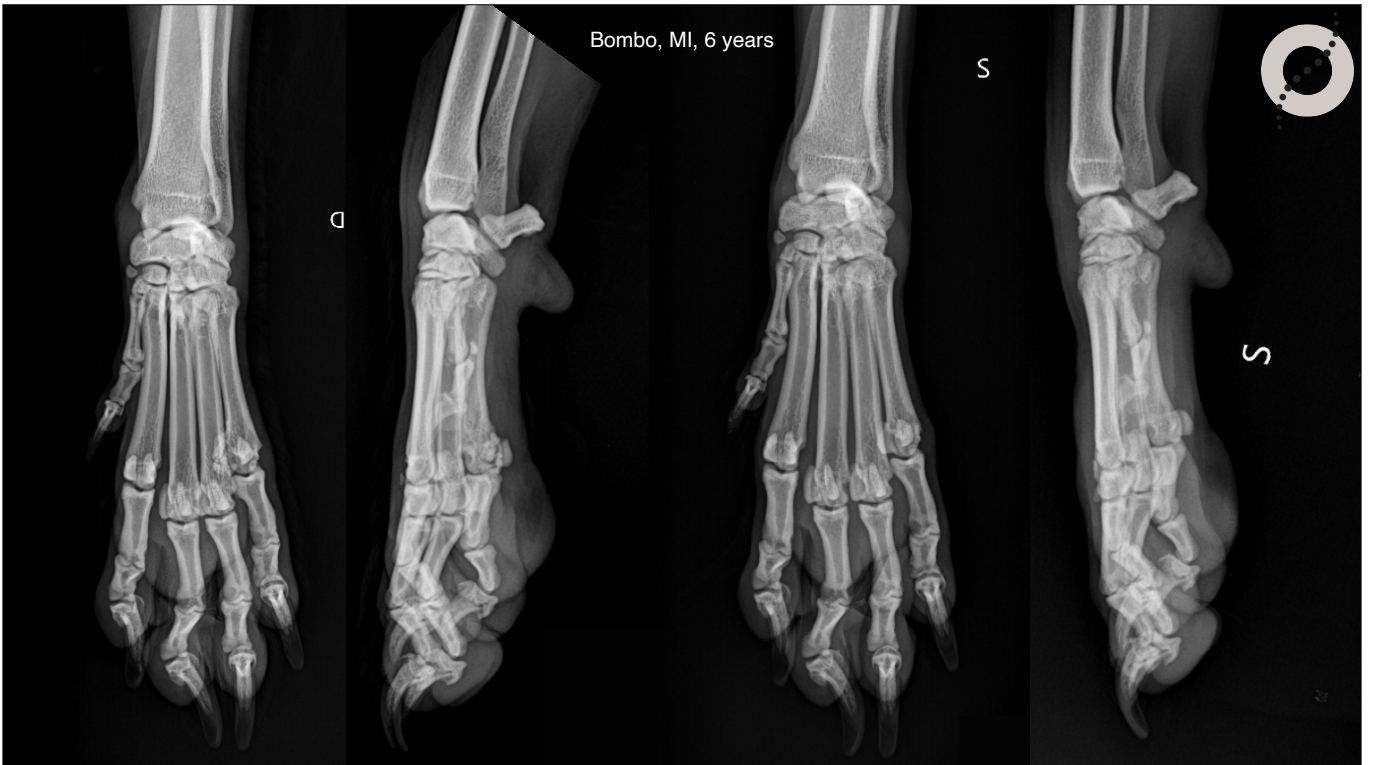

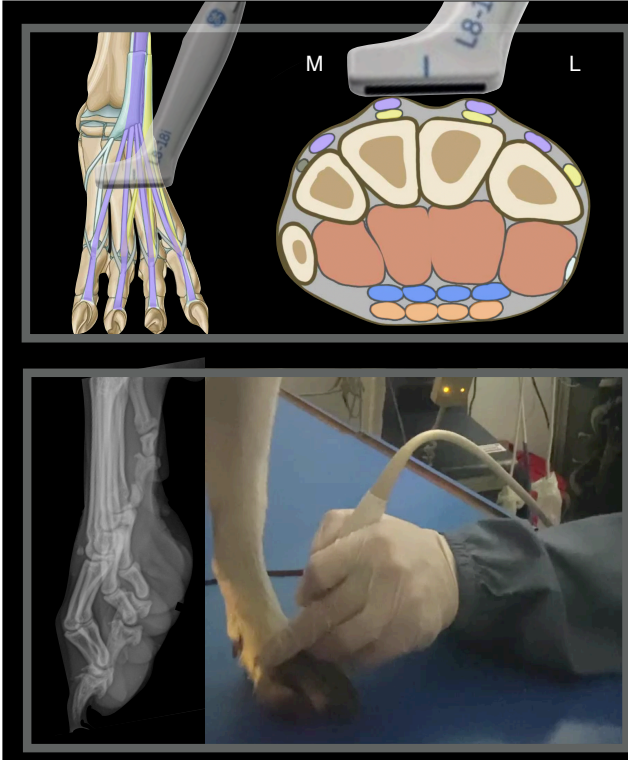
Bombo, MI, 6 years

D

S

S

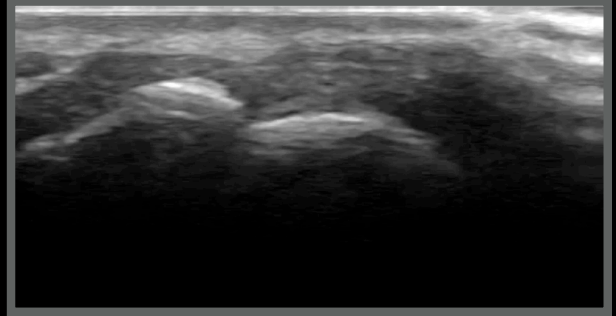




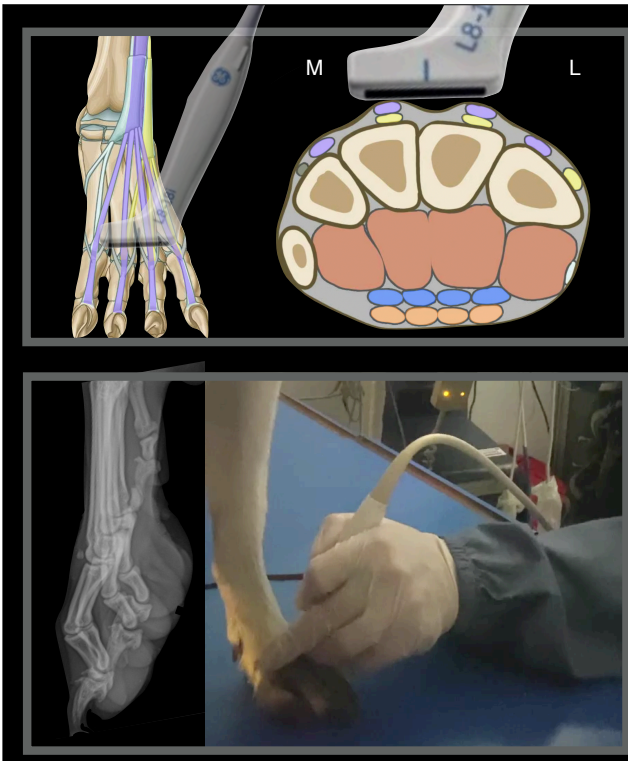
Bombo, MI, 6 years

Left metacarpus

Transverse scan plan, third and fourth left digits



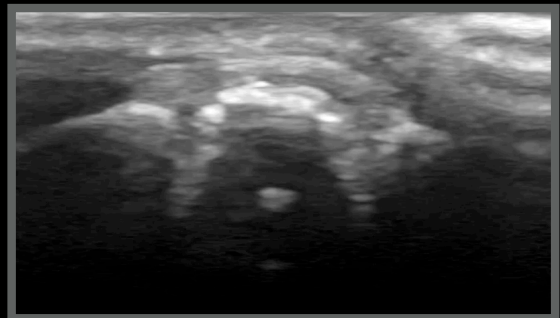
www.imaios.com



Bombo, MI, 6 years

Left metacarpus

Transverse scan plan, third and fourth left digits



www.imaios.com

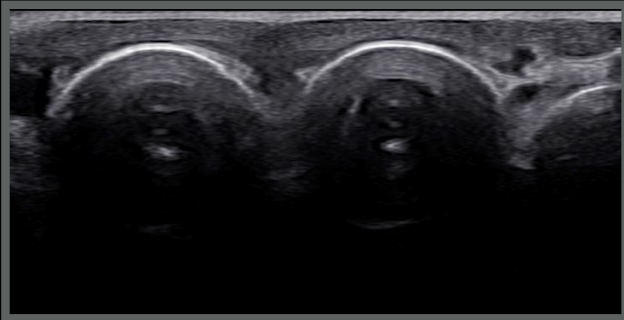




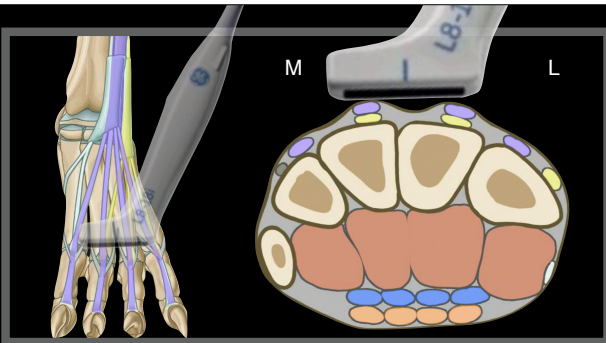
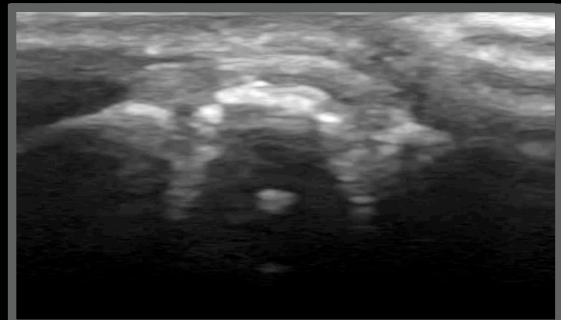
Bombo, Golden, MI, 6 years



Normal anatomy



Left metacarpus

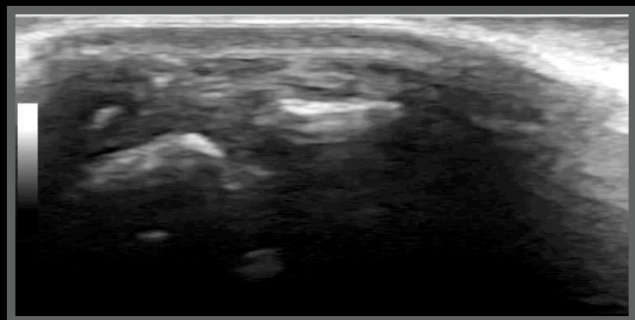


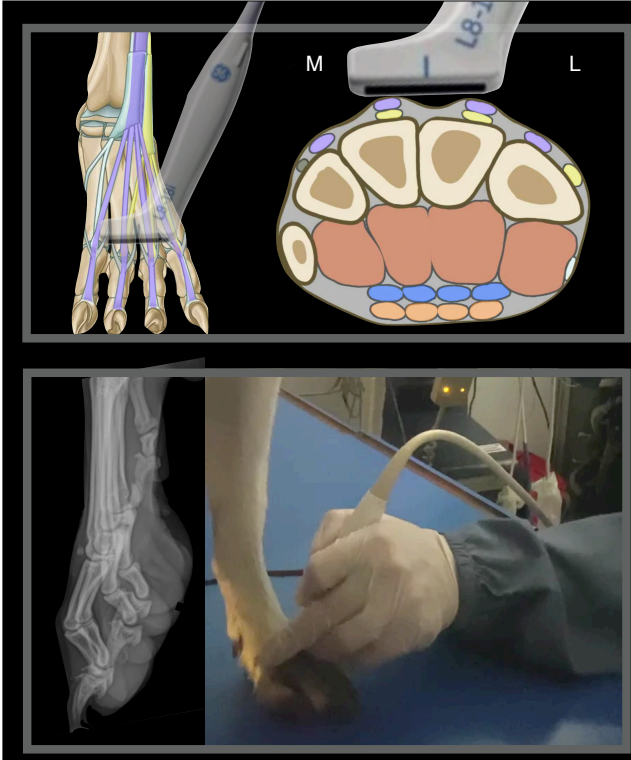
Bombo, MI, 6 years



Left metacarpus

Transverse scan plan, third and fourth left digits

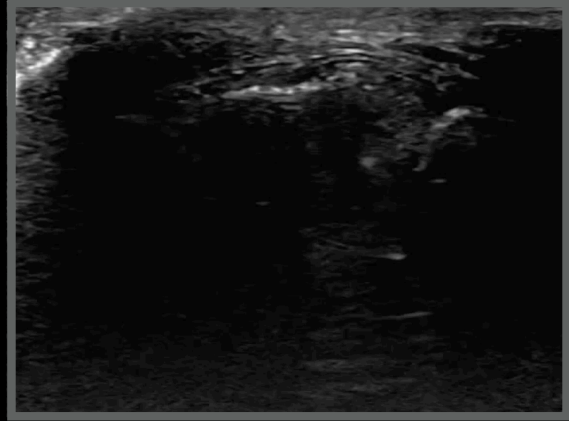




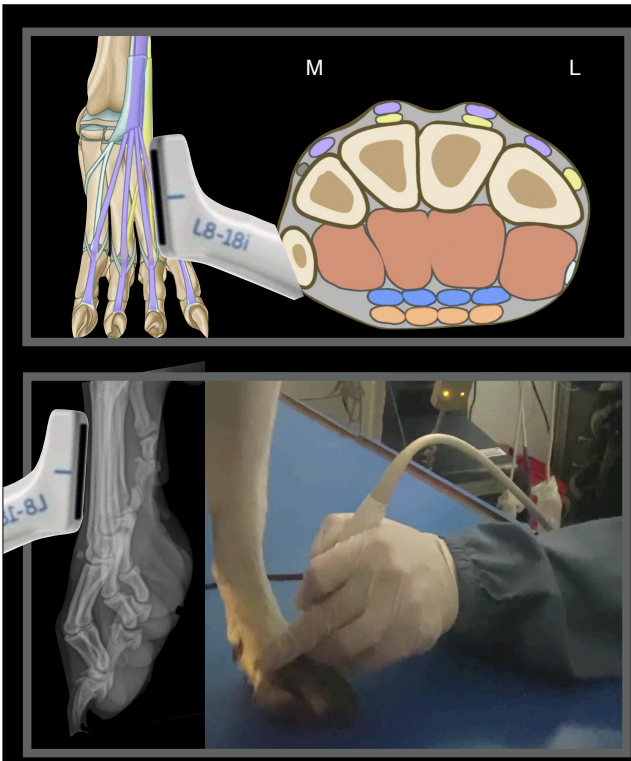
Bombo, MI, 6 years

Left metacarpus

Transverse scan plan, third and fourth left digits



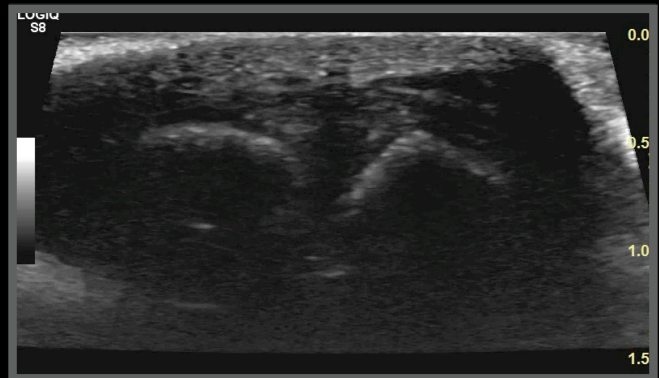
www.imaios.com



Bombo, MI, 6 years

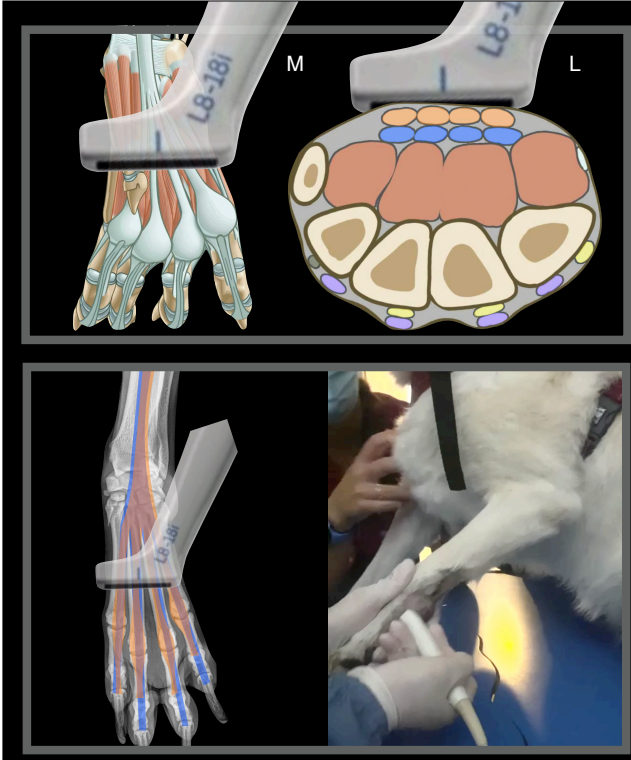
Left metacarpus

Longitudinal scan plan, third and fourth left digits



www.imaios.com

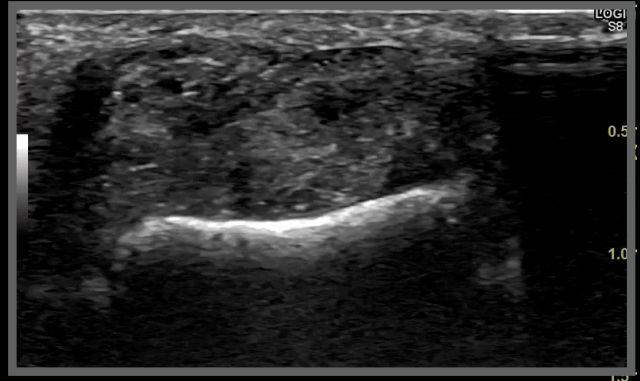




Bombo, MI, 6 years

Left metacarpus

Transverse scan plan



www.imaio.com

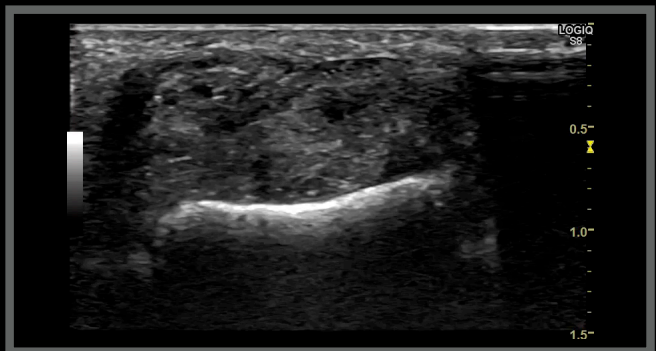
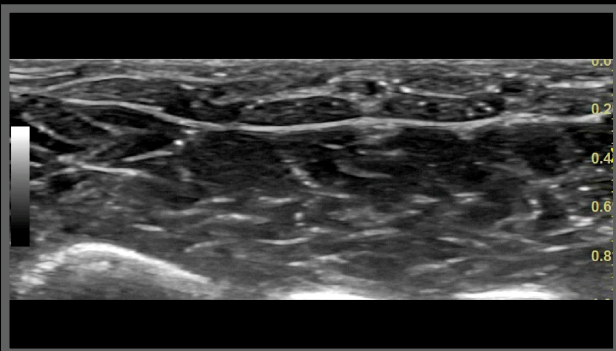


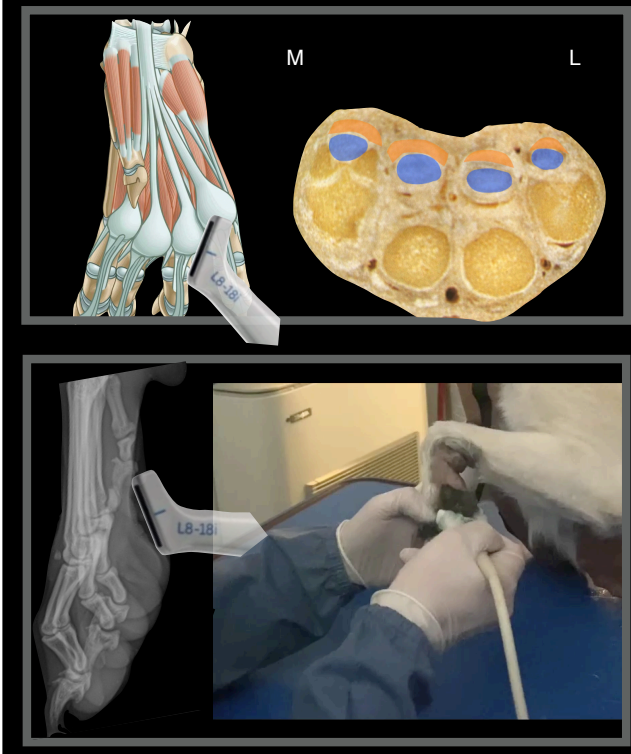
Bombo, Golden, MI, 6 years



Normal anatomy

Left metacarpus

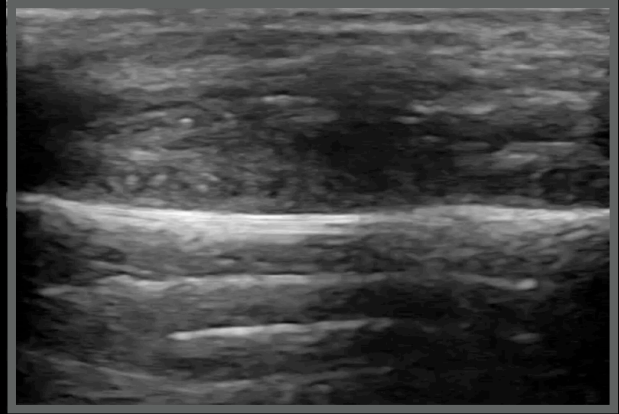




Bombo, MI, 6 years

Left metacarpus

Longitudinal scan plan



www.imaios.com

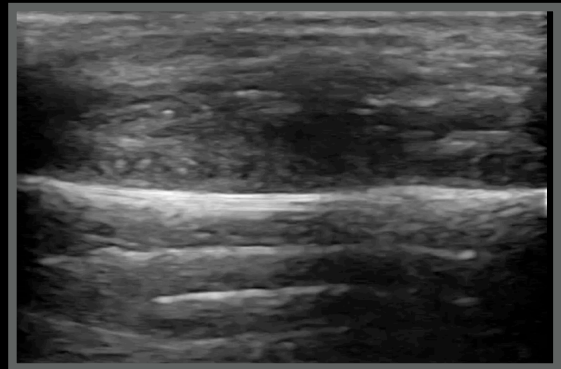
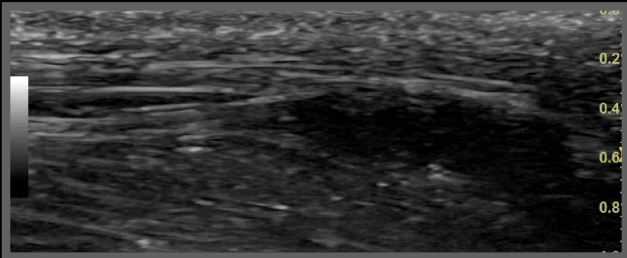


Bombo, Golden, MI, 6 years



Normal anatomy

Left metacarpus

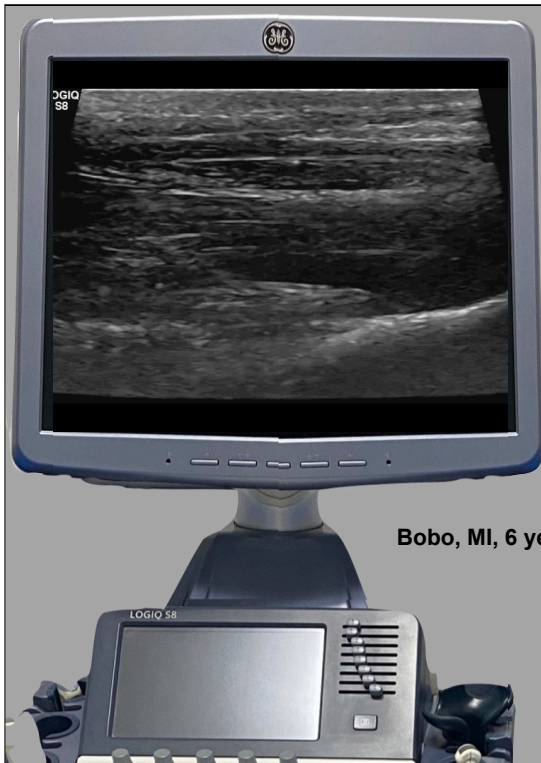
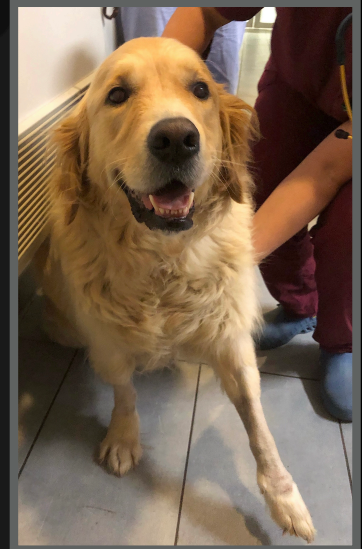
Bombo, Golden, MI, 6 years

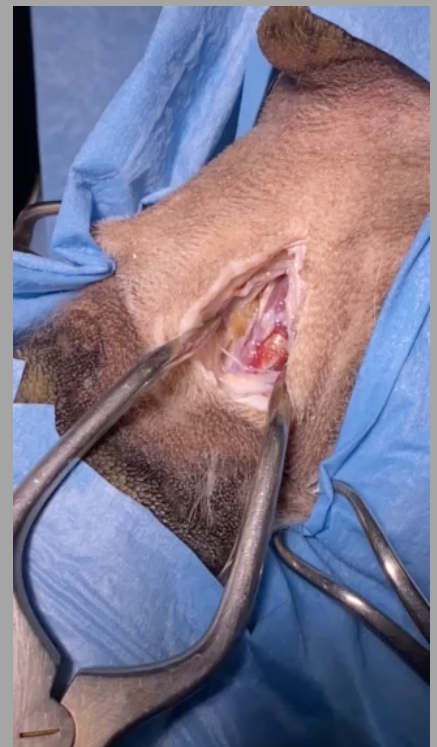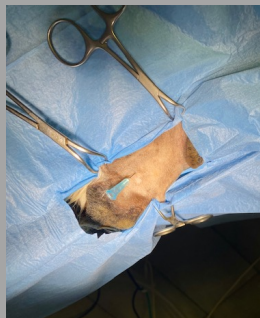Ultrasonographic diagnoses (left metacarpus):

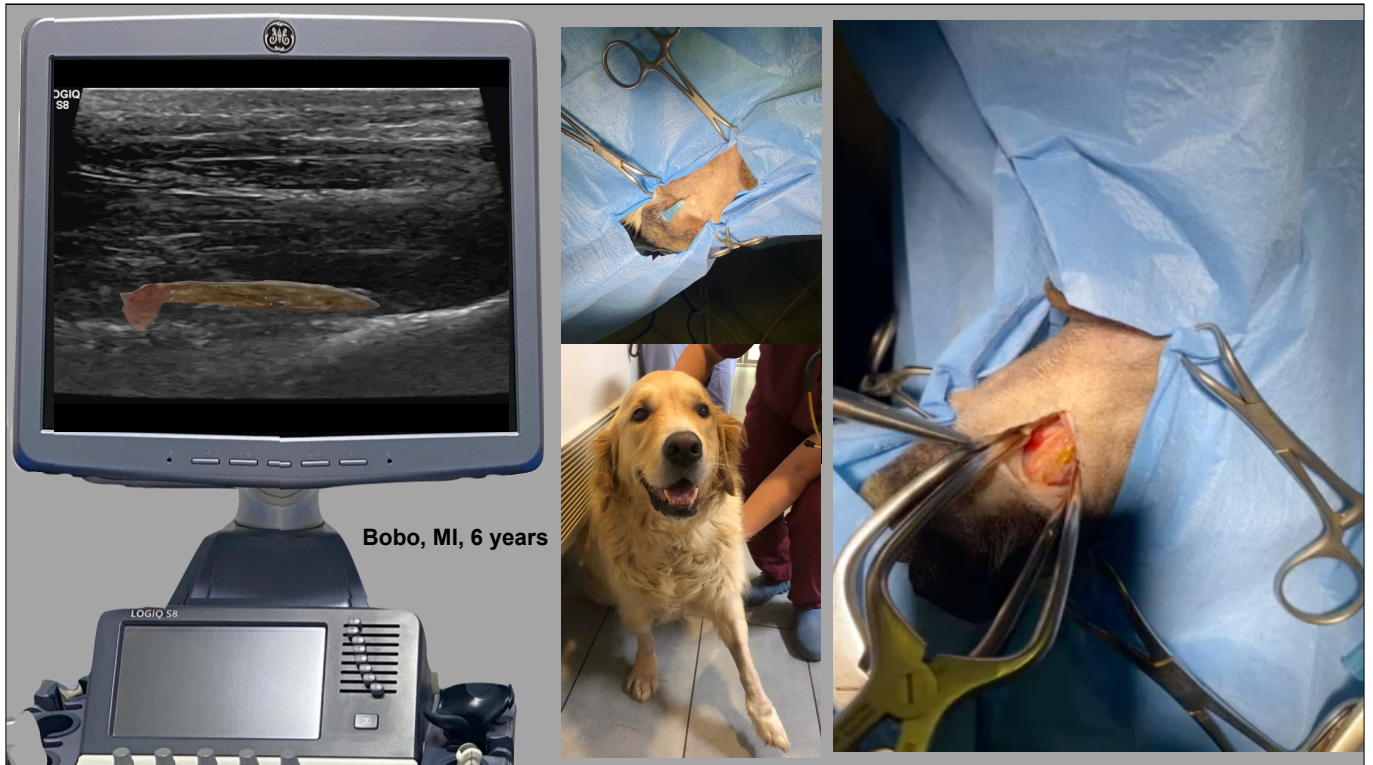- MCs osteomyelitis
- Vegetable FB

What next?



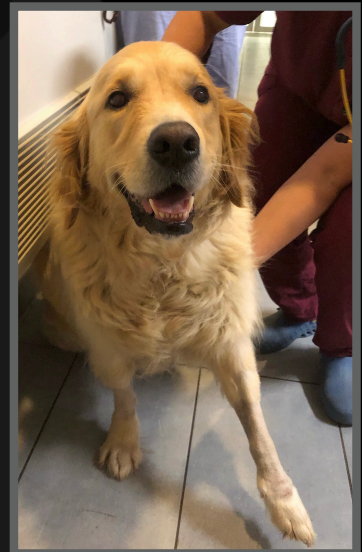Bobo, MI, 6 years





Bombo, Golden, MI, 6 years

- Dismissed with one week of AB treatment
- Never come back for recheck
- Doing fine for the last 2 years (phone)



Thank you



Diagnostic Mindset

www.diagnosticmindset.com

Severe lameness after a run in a dog

CASE DISCUSSION


Giliola Spattini
DVM, GP Cardio, CCRT, PhD, DECVDI



Diagnostic Mindset



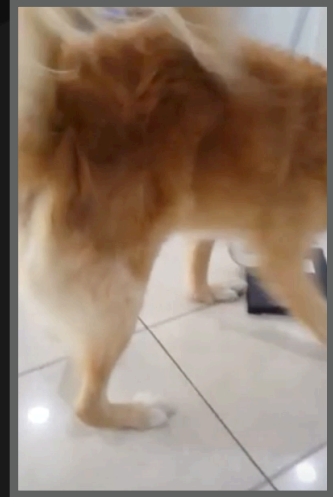
Clinica Veterinaria
CASTELLARANO



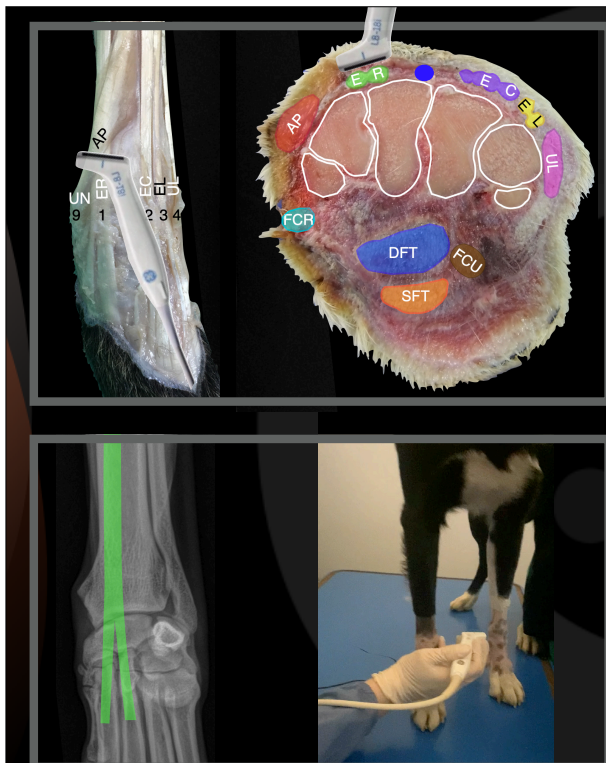
Thank to www.imaios.com

Buddy, Mongrel, MN, 5 years

- After running in a field, severely lame RF
- Rest and NSAID
- Worsening



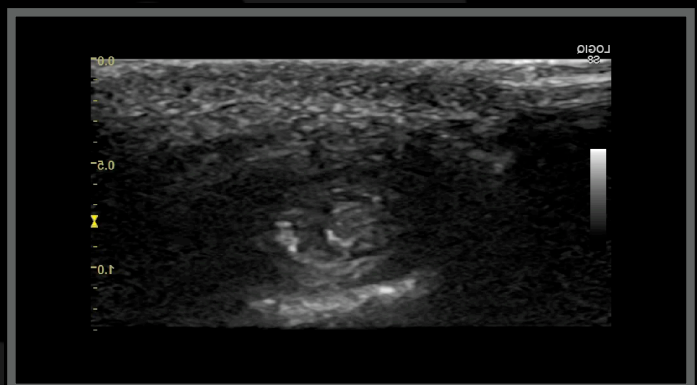
Radiographs performed but not available, reported WNL



Buddy, MN, 5 years

Right carpus

Extensor Carpi Radialis transverse scan

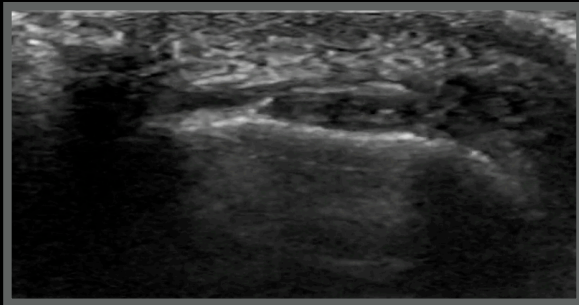




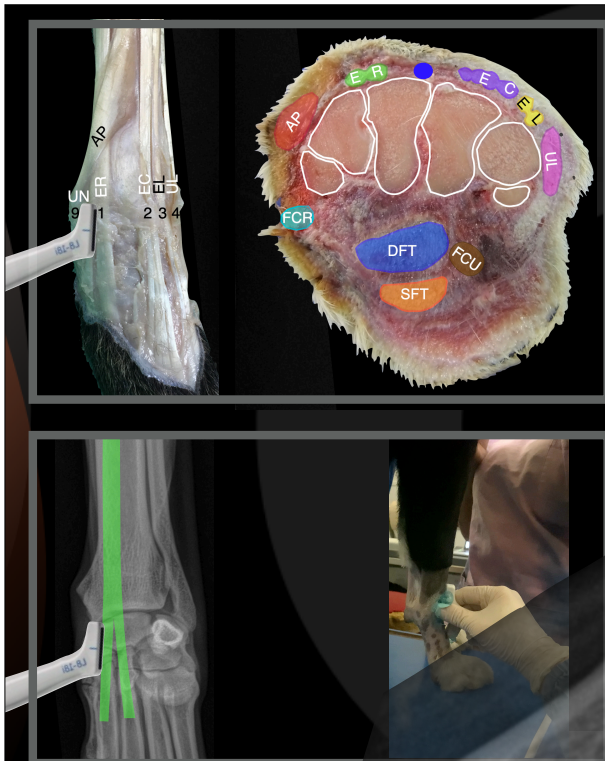
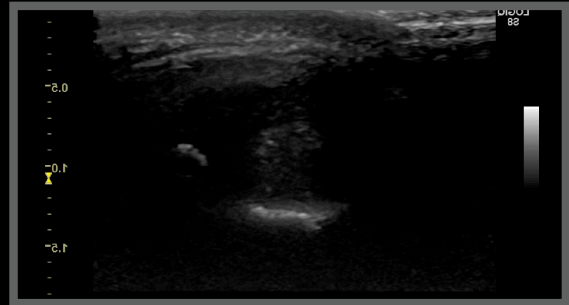
Buddy, Mongrel, MN, 5 years



Normal anatomy



Right carpus

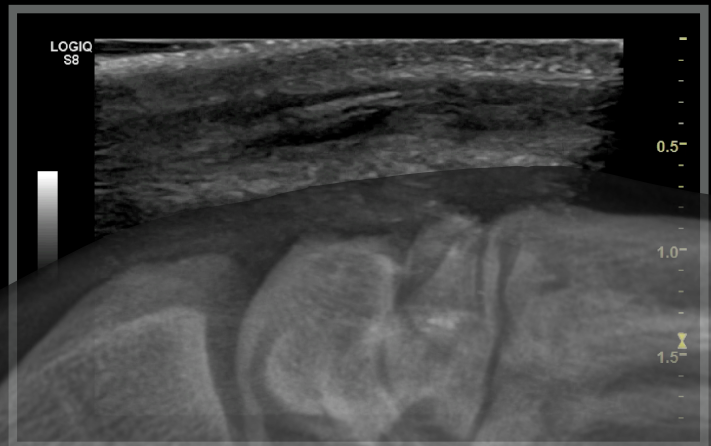


Buddy, MN, 5 years

Right carpus

Extensor Carpi Radialis longitudinal scan

1

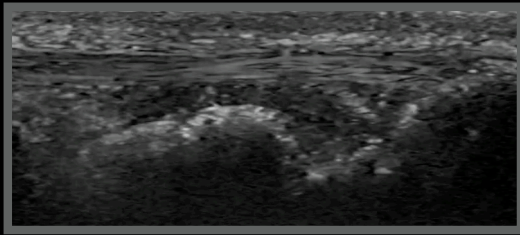




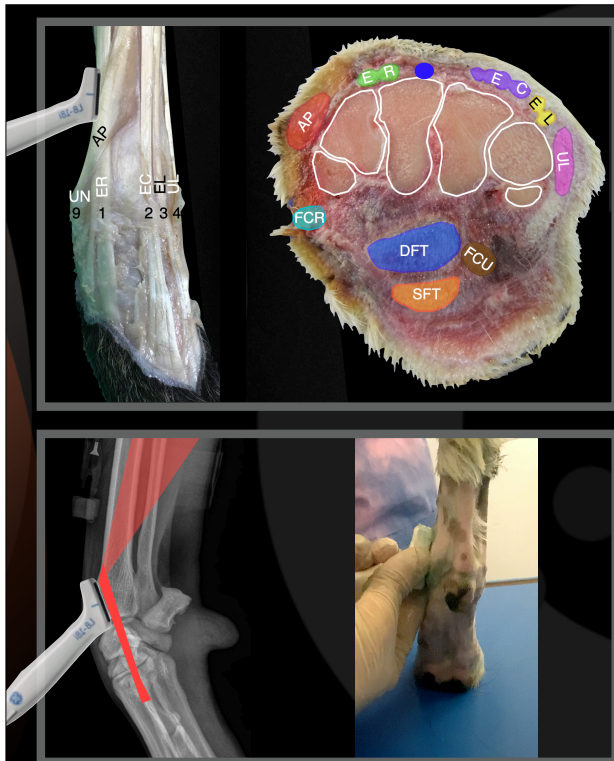
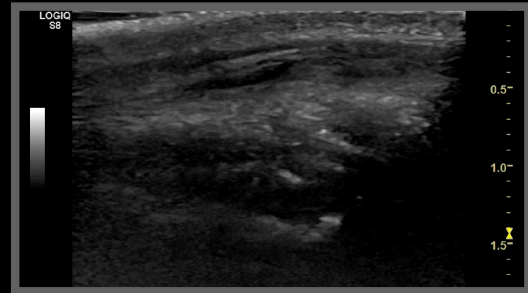
Buddy, Mongrel, MN, 5 years



Normal anatomy



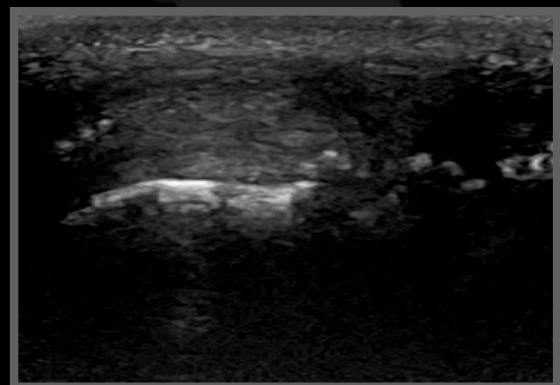
Right carpus



Buddy, MN, 5 years

Right carpus

Abductor Pollicis Longus longitudinal scan 9

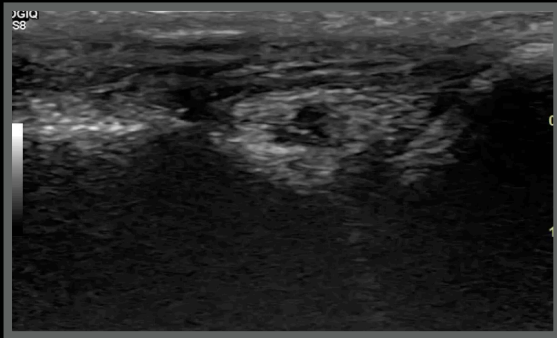




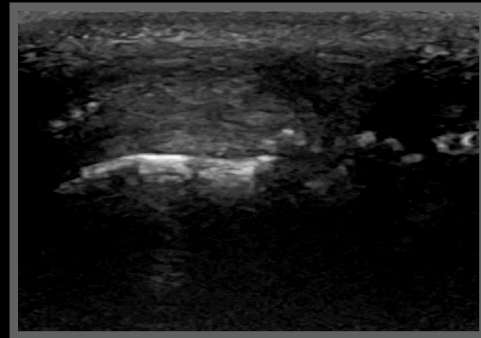
Buddy, Mongrel, MN, 5 years



Normal anatomy



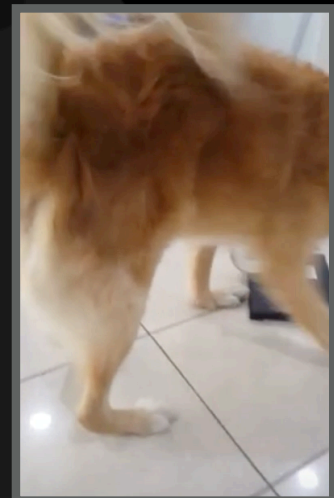
Right carpus



Buddy, Mongrel, MN, 5 years

Ultrasonographic diagnoses (right carpus):

- Severe thickening of the synovia of the right carpus
- Severe tendinopathy right extensor carpi radialis
- Irregular articular surfaces

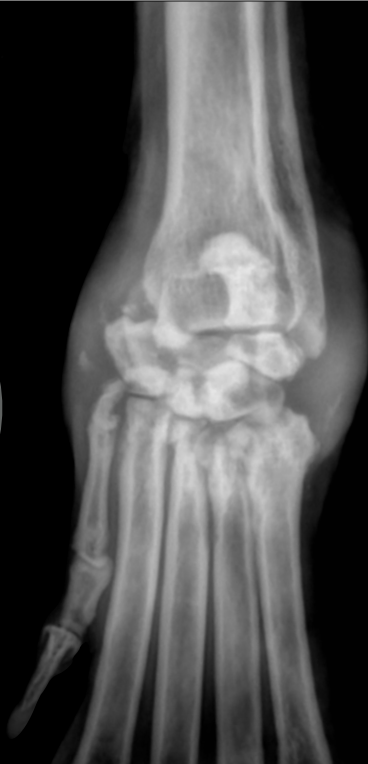

What next?

Buddy, MN, 5 years

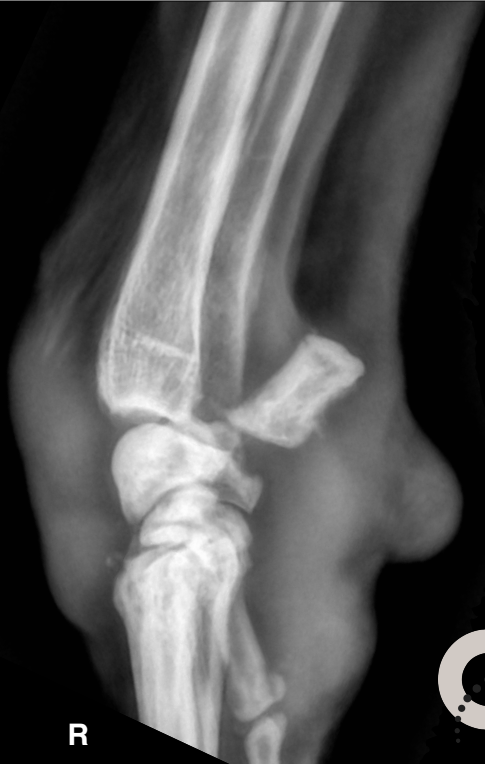

R



R

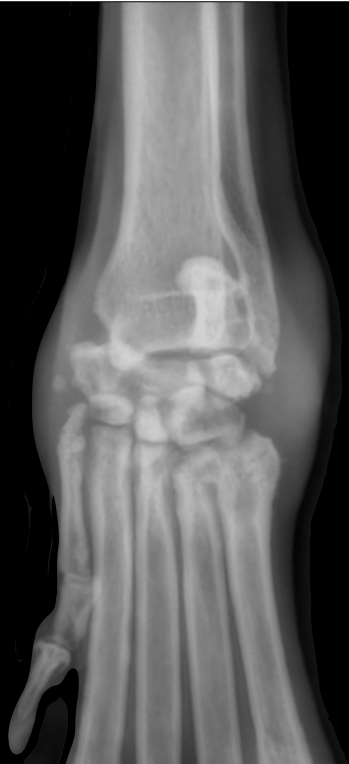R



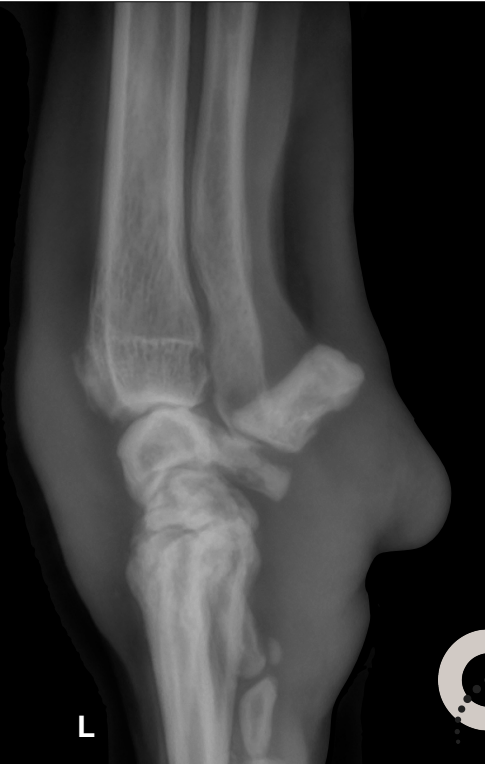Buddy, MN, 5 years

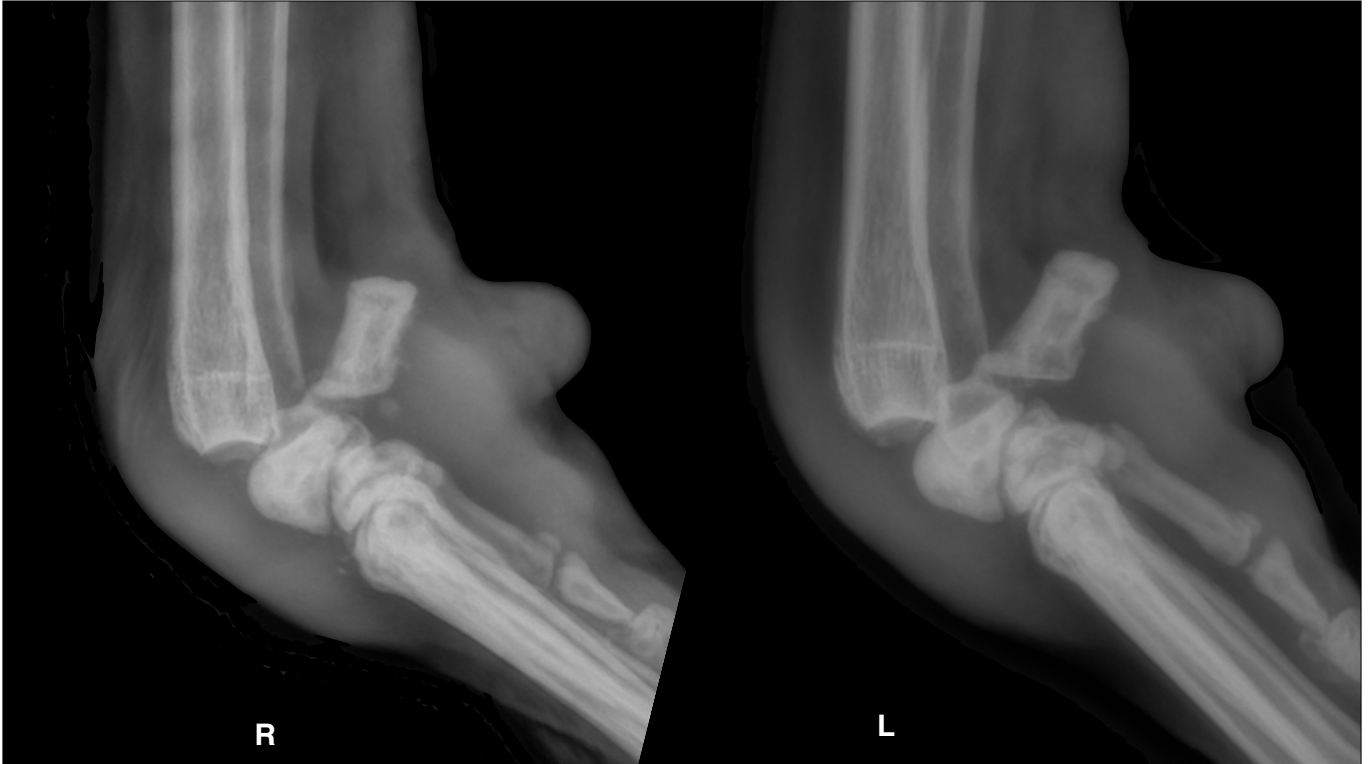


L



L

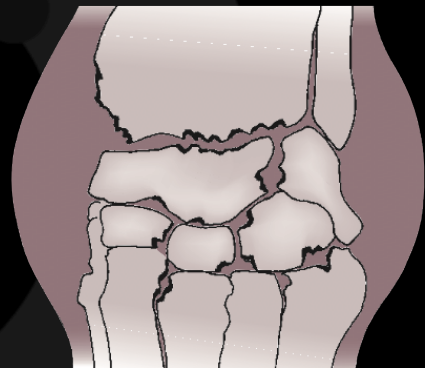




Buddy, Mongrel, MN, 5 years

Radiographic diagnoses

- Erosive polyarthritis
- Severe soft tissue swelling
- Carpal joints subluxation



Cytology of synovial effusion and blood works compatible with SLE

Thank you



Diagnostic Mindset

www.diagnosticmindset.com

Recurrent acute lameness in a Border Collie

CASE DISCUSSION

Giliola Spattini
DVM, GP Cardio, CCRT, PhD, DECVDI



Diagnostic Mindset



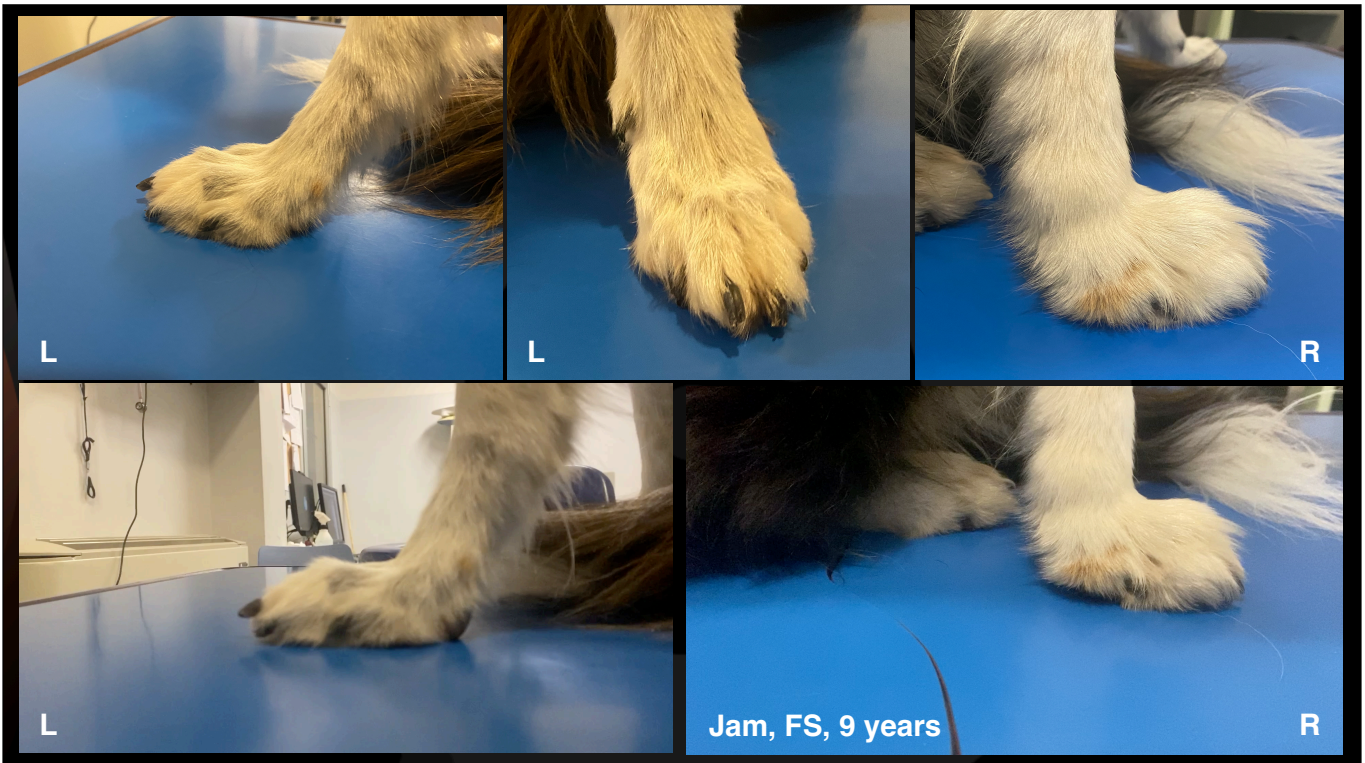Clinica Veterinaria
CASTELLARANO

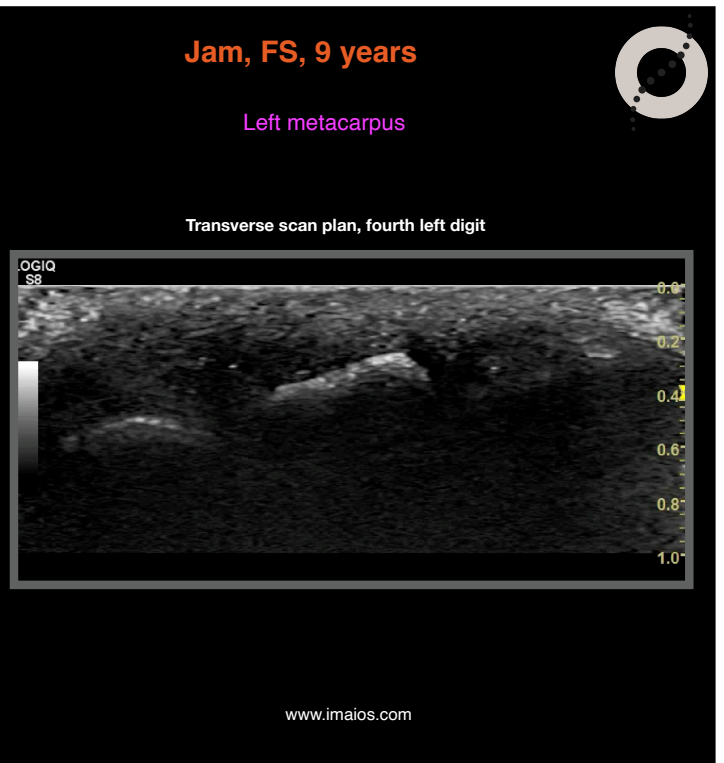
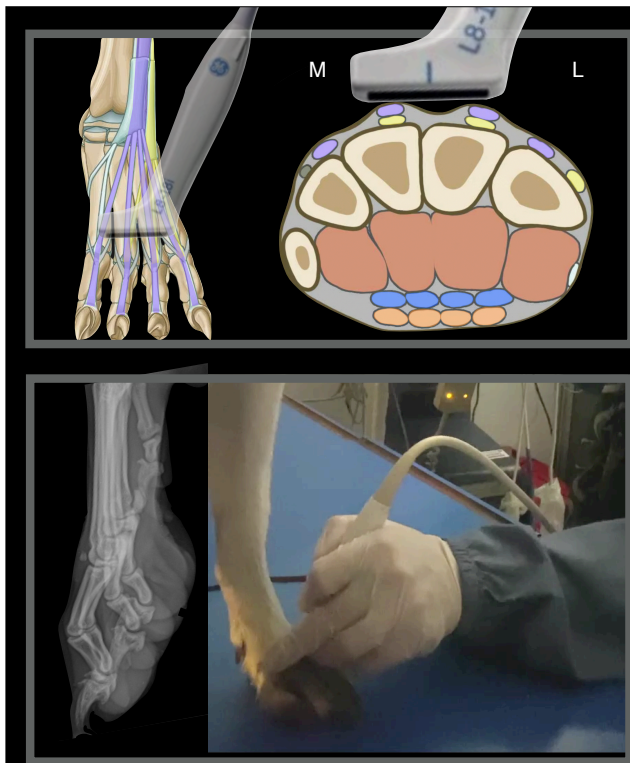
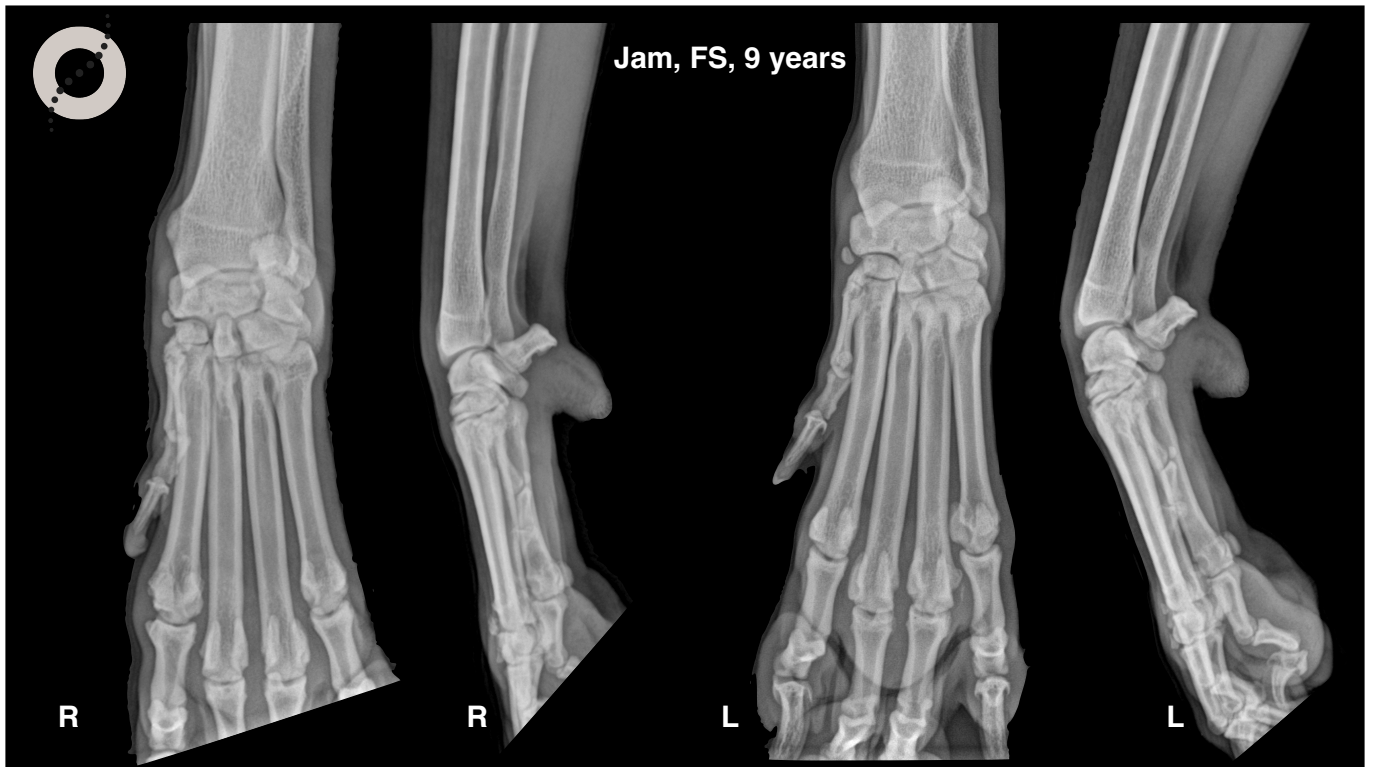


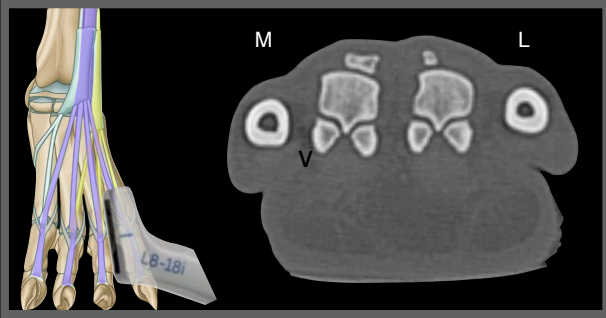
Thank to www.imaio.com

Jam, Border Collie, FS, 9 years

- Ex agility, now retiring
- Every time She plays, she is acutely lame LF
- Worsening if She walks on gravel
- Better when She uses shoes



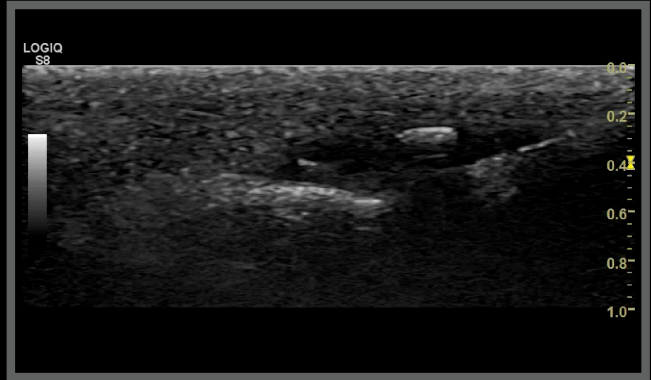
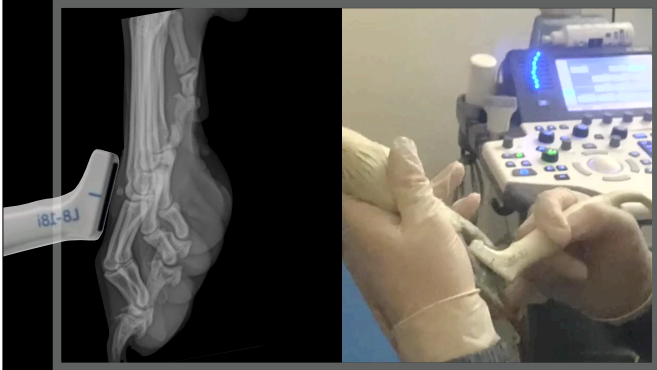



Jam, FS, 9 years

Left metacarpus

Longitudinal scan plan, fourth left digit



www.imaios.com



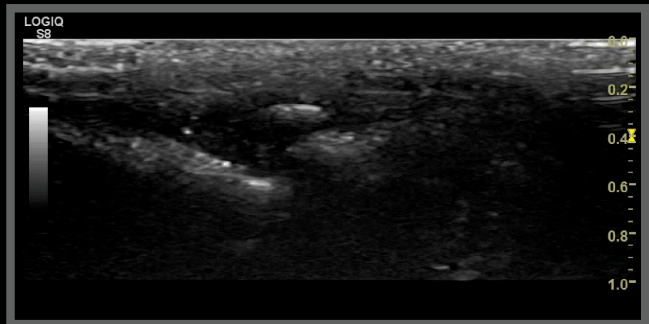
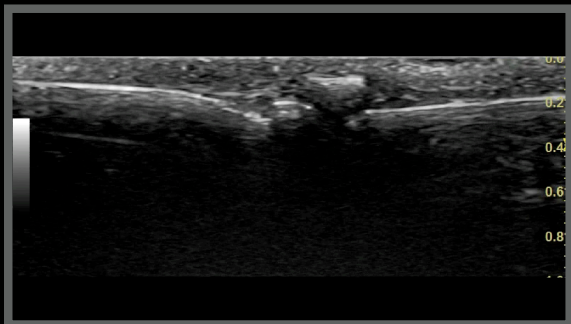
Jam, Border Collie, FS, 9 years

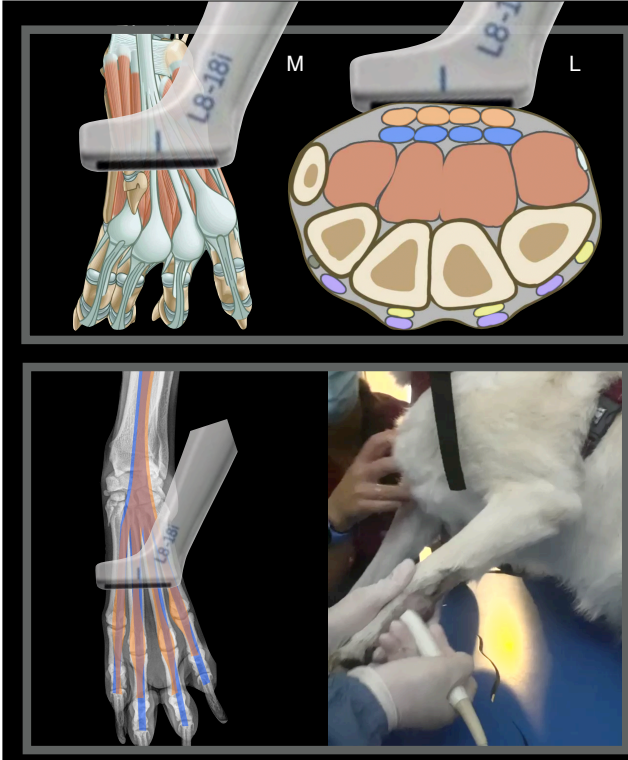
What will you do next?



Normal anatomy

Left metacarpus

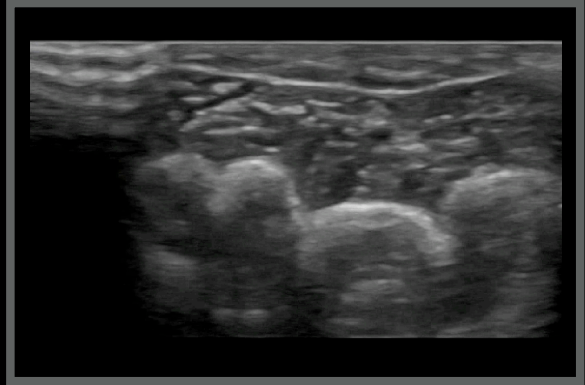




Jam, FS, 9 years

Left metacarpus

Transverse scan plan, fourth left digit



www.imaio.com

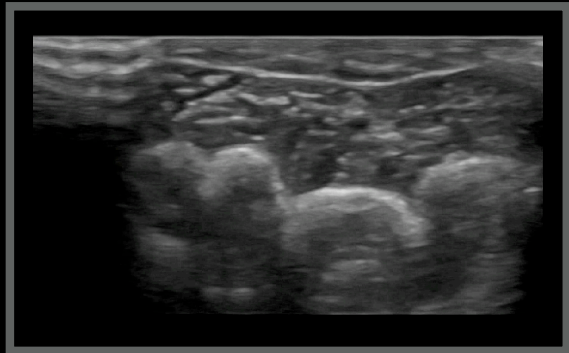
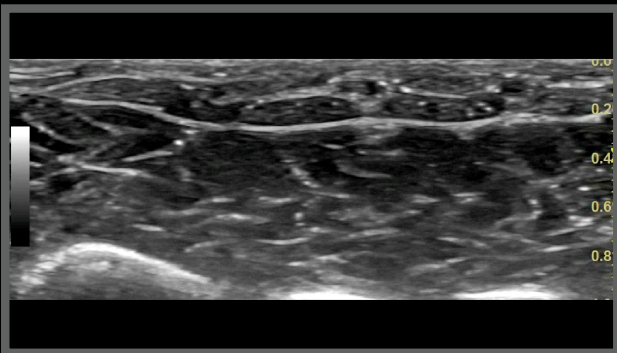


Jam, Border Collie, FS, 9 years



Normal anatomy

Left metacarpus



Jam, Border Collie, FS, 9 years

Ultrasonographic diagnoses (left fourth front digit):

- Severe MC-P1 joint subluxation + vacuum phenomenon
- Clinically incompetent deep flexor tendon



What next?

Thank you



Diagnostic Mindset

www.diagnosticmindset.com