

# Persistent septic arthritis in a Golden Retriever

## CASE DISCUSSION

Giliola Spattini  
DVM, GP Cardio, CCRT, PhD, DECVI



Diagnostic Mindset



Thank to [www.imaios.com](http://www.imaios.com)

---

---

---

---

---

---

---

---

## Bombo, Golden, MI, six years

- Two months ago, acute and severe left front paw swelling and lameness
- Diagnosed pododermatitis
- Ultrasound saw carpal effusion - aseptic neutrophilic synovitis on cytology



---

---

---

---

---

---

---

---



## Bombo, Golden, MI, 6 years

- Lameness improves with AB but is still present
- Worsened as soon as AB is dismissed
- Second ultrasound examination was suggestive of cellulitis



---

---

---

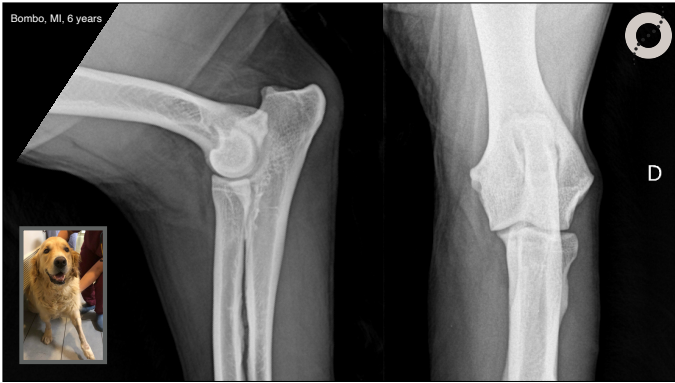---

---

---

---

---



---

---

---

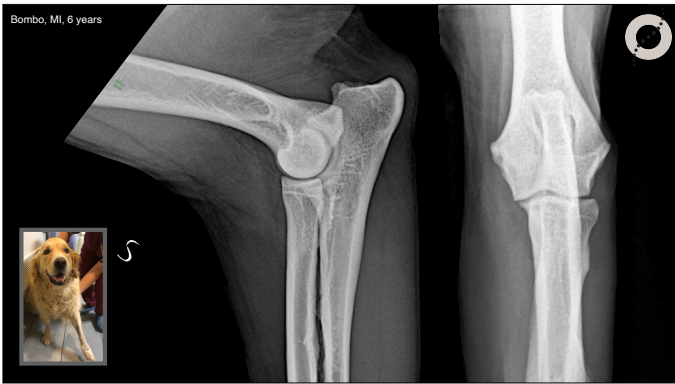---

---

---

---

---



---

---

---

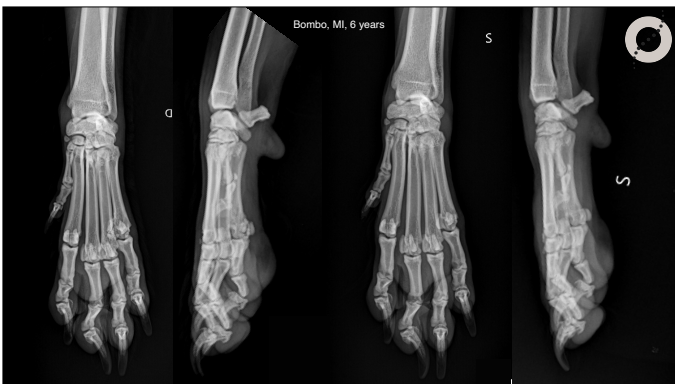---

---

---

---

---



---

---

---

---

---

---

---

---

**Bombo, MI, 6 years**

Left metacarpus

Transverse scan plan, third and fourth left digits

www.imaios.com

This slide contains anatomical diagrams and an ultrasound image. The top left shows a 3D skeletal model of a paw with 'M' and 'L' markers. The top right is a cross-sectional diagram of the paw. The bottom left shows a photograph of a paw being held. The bottom right is a grayscale ultrasound image showing a transverse scan of the third and fourth digits. A small circular icon is in the top right corner.

---

---

---

---

---

---

---

---

**Bombo, MI, 6 years**

Left metacarpus

Transverse scan plan, third and fourth left digits

www.imaios.com

This slide is identical to the one above, showing anatomical diagrams and an ultrasound image of the left metacarpus in Bombo, MI, 6 years old. A small circular icon is in the top right corner.

---

---

---

---

---

---

---

---

**Bombo, Golden, MI, 6 years**

Normal anatomy

Left metacarpus

This slide compares normal anatomy with the left metacarpus. The top right features a small photograph of a golden retriever. The bottom left is an ultrasound image labeled 'Normal anatomy' showing two distinct, rounded structures. The bottom right is an ultrasound image labeled 'Left metacarpus' showing a different, more irregular structure. A small circular icon is in the top left corner.

---

---

---

---

---

---

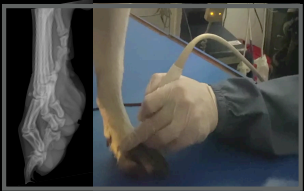
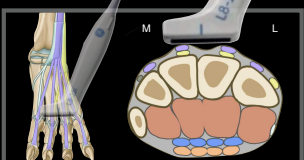
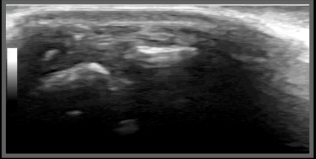
---

---

**Bombo, MI, 6 years**

Left metacarpus

Transverse scan plan, third and fourth left digits



www.imaios.com

---

---

---

---

---

---

---

---


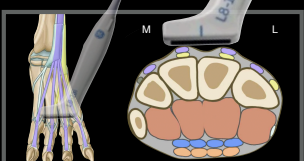
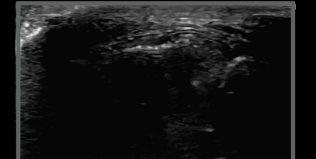
---

---

**Bombo, MI, 6 years**

Left metacarpus

Transverse scan plan, third and fourth left digits



www.imaios.com

---

---

---

---

---

---

---

---

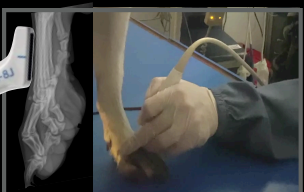
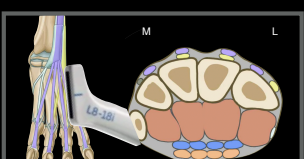
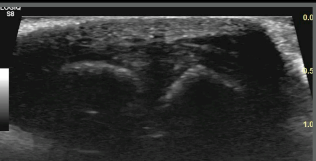
---

---

**Bombo, MI, 6 years**

Left metacarpus

Longitudinal scan plan, third and fourth left digits



www.imaios.com

---

---

---

---

---

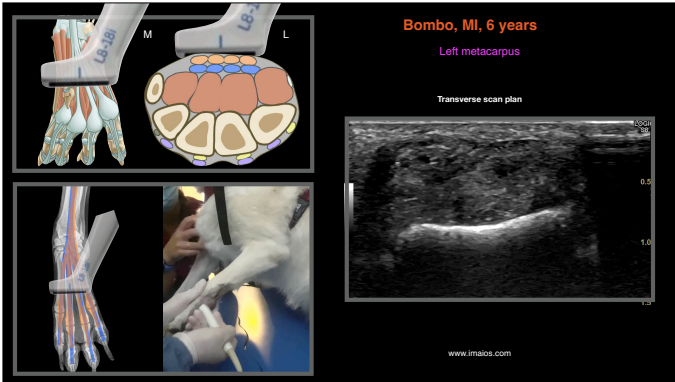
---

---

---

---

---



---

---

---

---

---

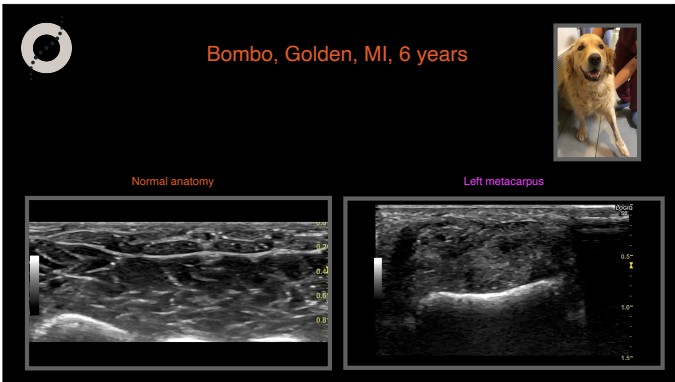
---

---

---

---

---



---

---

---

---

---

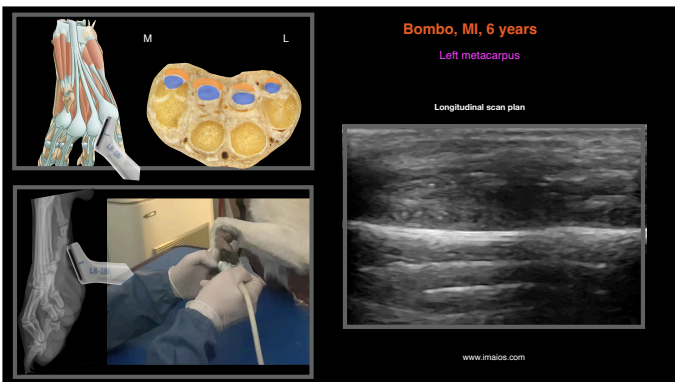
---

---

---

---

---



---

---

---

---

---

---

---

---

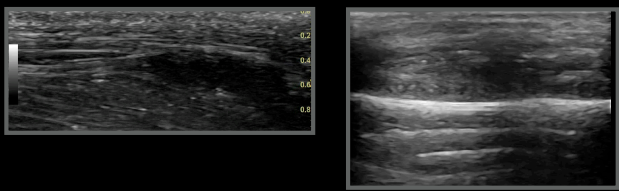
---

---

Bombo, Golden, MI, 6 years

Normal anatomy

Left metacarpus



This slide shows two side-by-side ultrasound images of a dog's metacarpus. The left image, labeled 'Normal anatomy', shows a clear, layered structure of the bone and surrounding soft tissue. The right image, labeled 'Left metacarpus', shows a significantly thickened and irregular structure, indicating a pathological condition. A small photograph of a golden retriever is in the top right corner.

---

---

---

---

---

---

---


---

Bombo, Golden, MI, 6 years

Ultrasonographic diagnoses (left metacarpus):

- MCs osteomyelitis
- Vegetable FB

What next?



This slide features a central circular graphic with a dark background and light-colored circles. To the right is a photograph of a golden retriever. The text lists two ultrasonographic diagnoses for the left metacarpus: MCs osteomyelitis and Vegetable FB. The text 'What next?' is at the bottom.

---

---

---

---

---

---

---

---

Bobo, MI, 6 years



This slide is a collage of three images. On the left is a computer monitor displaying an ultrasound image. In the center is a photograph of a golden retriever. On the right is a close-up photograph of a surgical procedure on a dog's paw, showing an incision and surgical instruments.

---

---

---

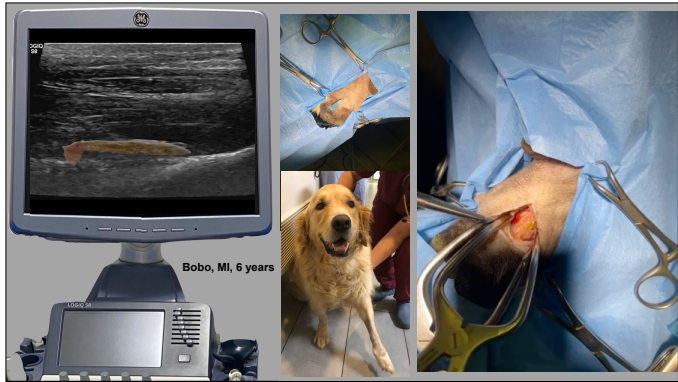---

---

---

---

---



Bobo, MI, 6 years

---

---

---

---

---

---

---

---

Boombo, Golden, MI, 6 years

- Dismissed with one week of AB treatment
- Never come back for recheck
- Doing fine for the last 2 years (phone)



---

---

---

---

---

---

---

---

Thank you



Diagnostic Mindset  
[www.diagnosticmindset.com](http://www.diagnosticmindset.com)

---

---

---

---

---

---

---

---

# Severe lameness after a run in a dog

## CASE DISCUSSION

Giliola Spattini  
DVM, GP Cardio, CCRT, PhD, DECVDI



Diagnostic Mindset



Thank to [www.imagoes.com](http://www.imagoes.com)

---

---

---

---

---

---

---

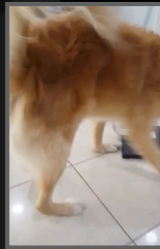
---

---

---

## Buddy, Mongrel, MN, 5 years

- After running in a field, severely lame RF
- Rest and NSAID
- Worsening



Radiographs performed but not available, reported WNL

---

---

---

---

---

---

---

---

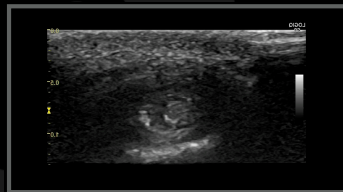
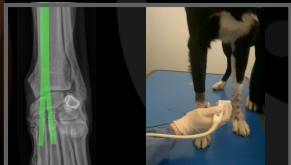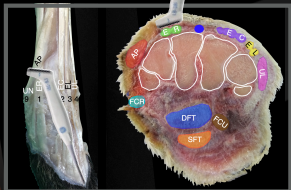
---

---

## Buddy, MN, 5 years

Right carpus

Extensor Carpi Radialis transverse scan



---

---

---

---

---

---


---

---

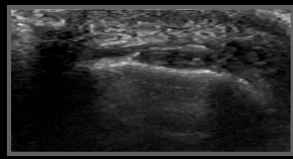
---

---

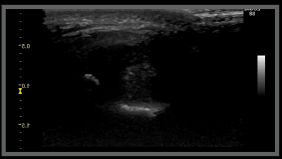
Buddy, Mongrel, MN, 5 years



Normal anatomy



Right carpus




---

---

---

---

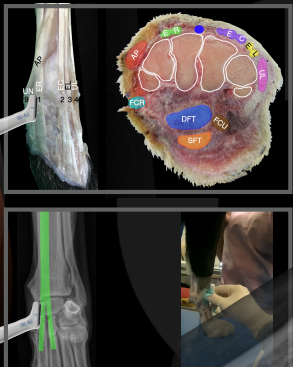
---

---

---

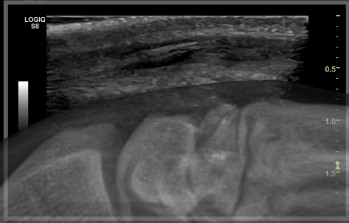
---

Buddy, MN, 5 years



Right carpus

Extensor Carpi Radialis longitudinal scan




---

---

---

---


---

---

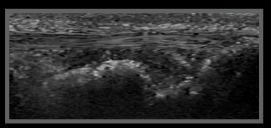
---

---

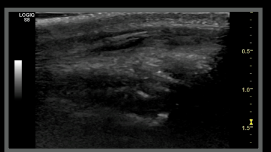
Buddy, Mongrel, MN, 5 years



Normal anatomy



Right carpus




---

---

---

---

---

---

---

---

Buddy, MN, 5 years

Right carpus

Abductor Pollicis Longus longitudinal scan 9

---

---

---

---

---

---

---

---

Buddy, Mongrel, MN, 5 years

Normal anatomy

Right carpus

---

---

---

---

---

---

---

---

Buddy, Mongrel, MN, 5 years

Ultrasonographic diagnoses (right carpus):

- Severe thickening of the synovia of the right carpus
- Severe tendinopathy right extensor carpi radialis
- Irregular articular surfaces

What next?

---

---

---

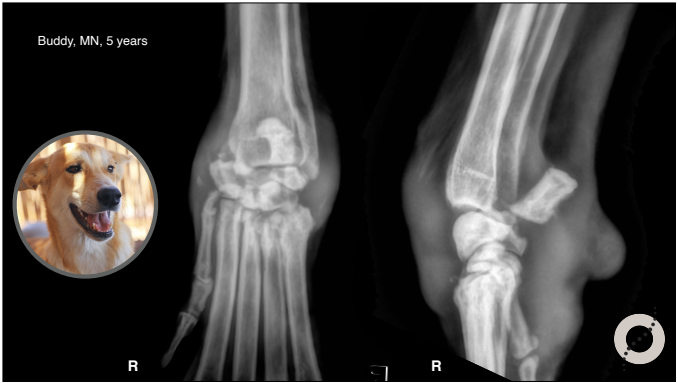---

---

---

---

---



---

---

---

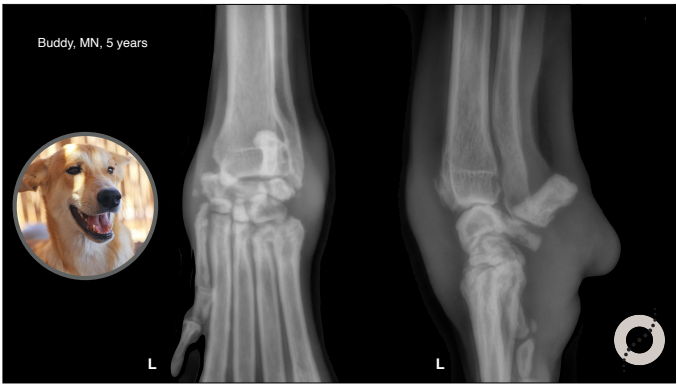
---

---

---

---

---



---

---

---

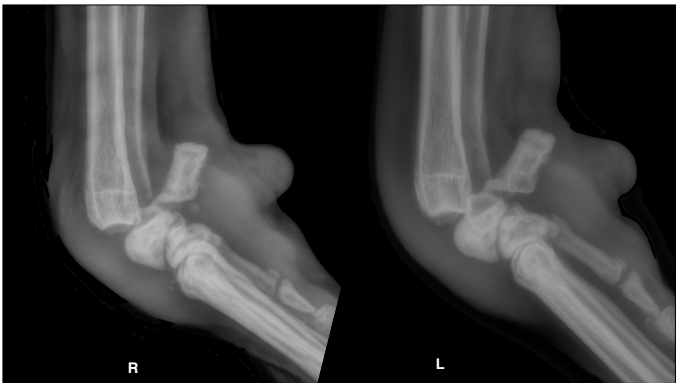
---

---

---

---

---



---

---

---

---

---

---

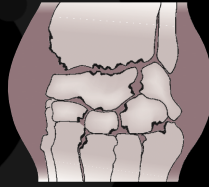
---

---

Buddy, Mongrel, MN, 5 years

Radiographic diagnoses

- Erosive polyarthritis
- Severe soft tissue swelling
- Carpal joints subluxation



Cytology of synovial effusion and blood works compatible with SLE

---

---

---

---

---

---

---

---

Thank you



Diagnostic Mindset

[www.diagnosticmindset.com](http://www.diagnosticmindset.com)

---

---

---

---

---

---

---

---

Recurrent acute lameness in a Border Collie

CASE DISCUSSION

Gliola Spattini  
DVM, GP Cardio, CCRT, PhD, DECVI



Thank to [www.imaios.com](http://www.imaios.com)

---

---

---

---

---

---

---

---

Jam, Border Collie, FS, 9 years

- Ex agility, now retiring
- Every time She plays, she is acutely lame LF
- Worsening if She walks on gravel
- Better when She uses shoes



---

---

---

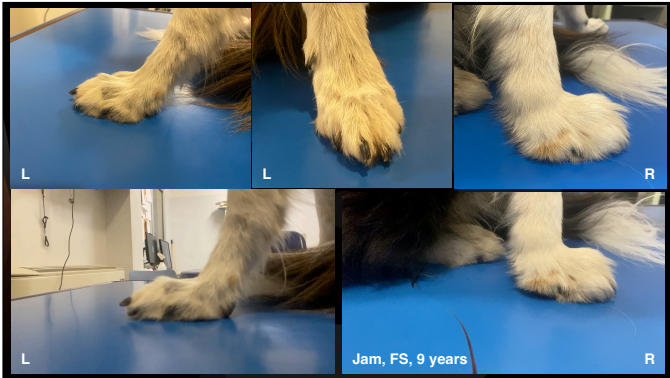---

---

---

---

---



---

---

---

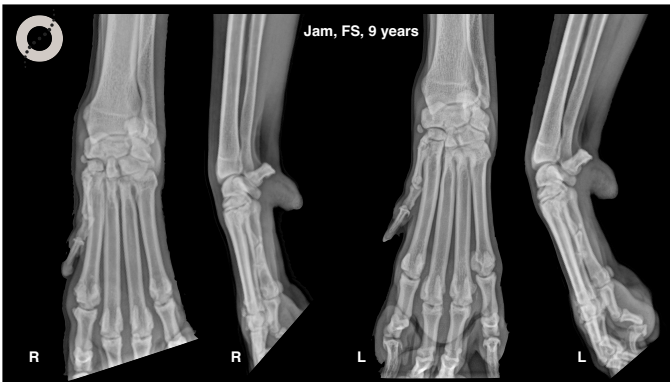
---

---

---

---

---



---

---

---

---

---

---

---

---

**Jam, FS, 9 years**

Left metacarpus

Transverse scan plan, fourth left digit

www.imaios.com

---

---

---

---

---

---

---

---

**Jam, FS, 9 years**

Left metacarpus

Longitudinal scan plan, fourth left digit

www.imaios.com

---

---

---

---

---

---

---

---

**Jam, Border Collie, FS, 9 years**

What will you do next?

Normal anatomy

Left metacarpus

---

---

---

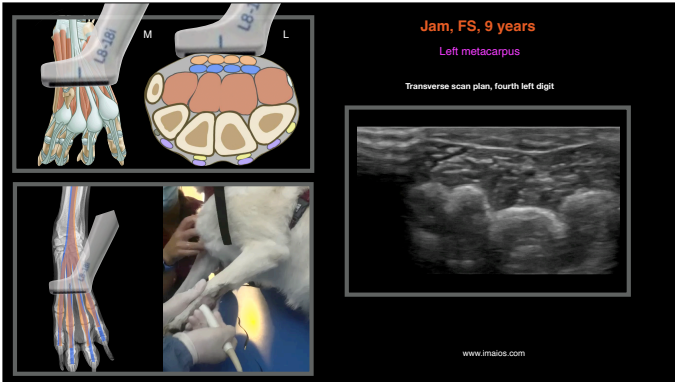
---

---

---

---

---




---

---

---

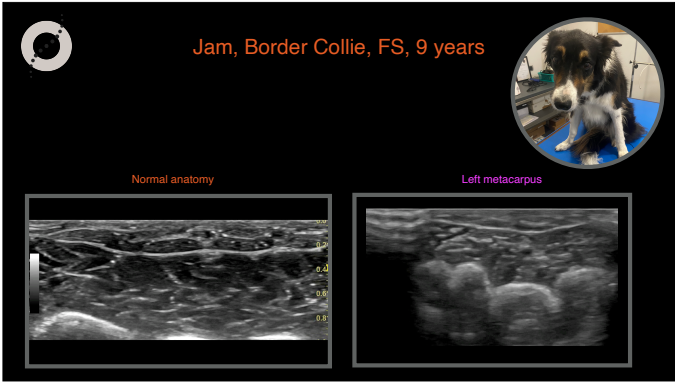
---

---

---

---

---




---

---

---

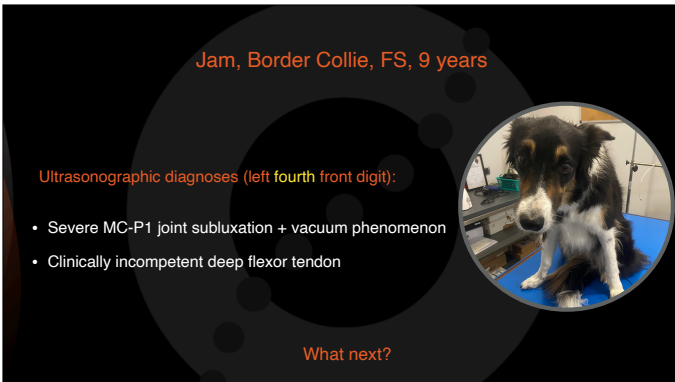---

---

---

---

---




---

---

---

---

---

---

---

---

Thank you



Diagnostic Mindset

[www.diagnosticmindset.com](http://www.diagnosticmindset.com)

---

---

---

---

---

---

---