Ultrasound of the lateral and medial aspect of the stifle

Giliola Spattini
DVM, GP Cardio, CCRT, PhD, DECVDI

Diagnostic Mindset

il loro benessere, il nostro obiettivo
Clinica Veterinaria
CASTELLARANO

Thank to www.imaios.com

Stifle joint: 1-8

Medial face

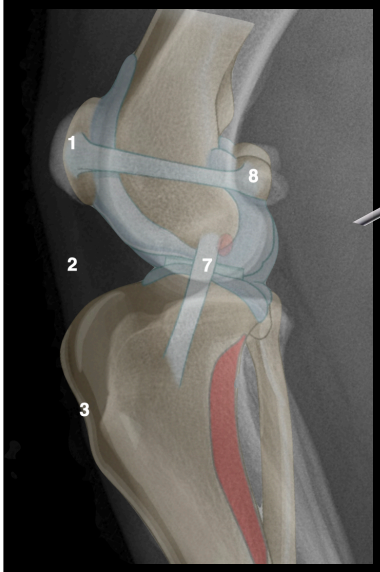

Cranial face

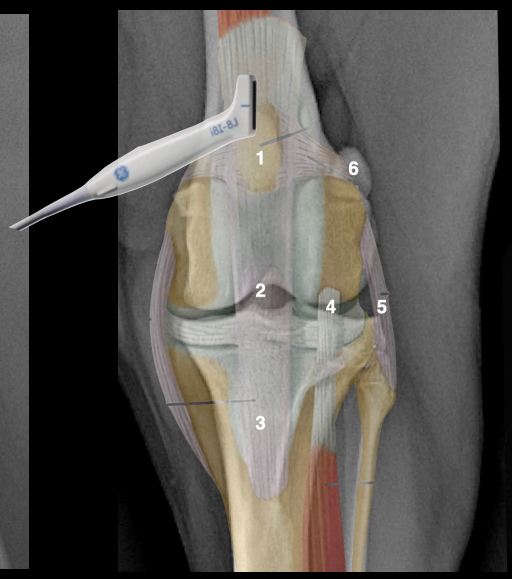

Lateral face

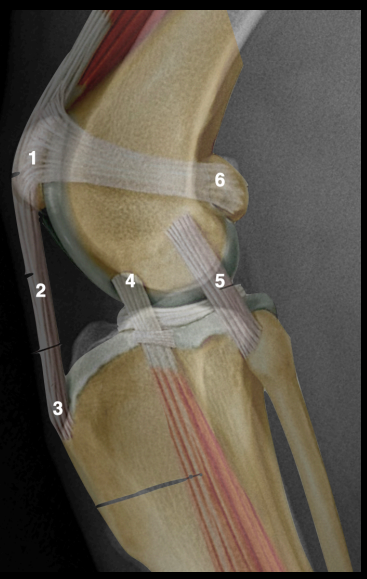

Chupito, Shetland , MI, 4 months

- The patient was in the garden alone for one hour
- Since then (one week), abnormal gait right hind limb

Chupito, Shetland , MI, 4 months

Right tarsus hyperextension

Focal swelling lateral aspect of the right stifle

Left tarsus

Right tarsus

Chupito, MI, 4 months

Chupito, MI, 4 months

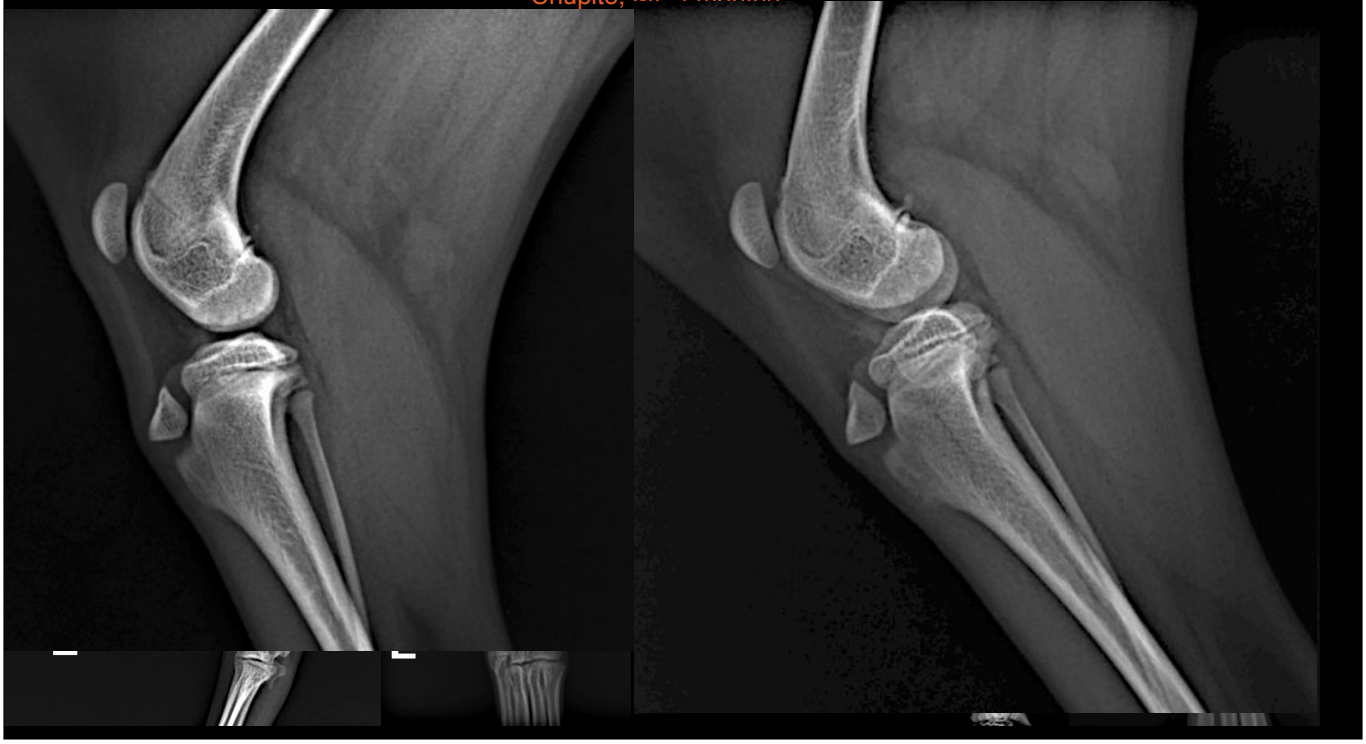

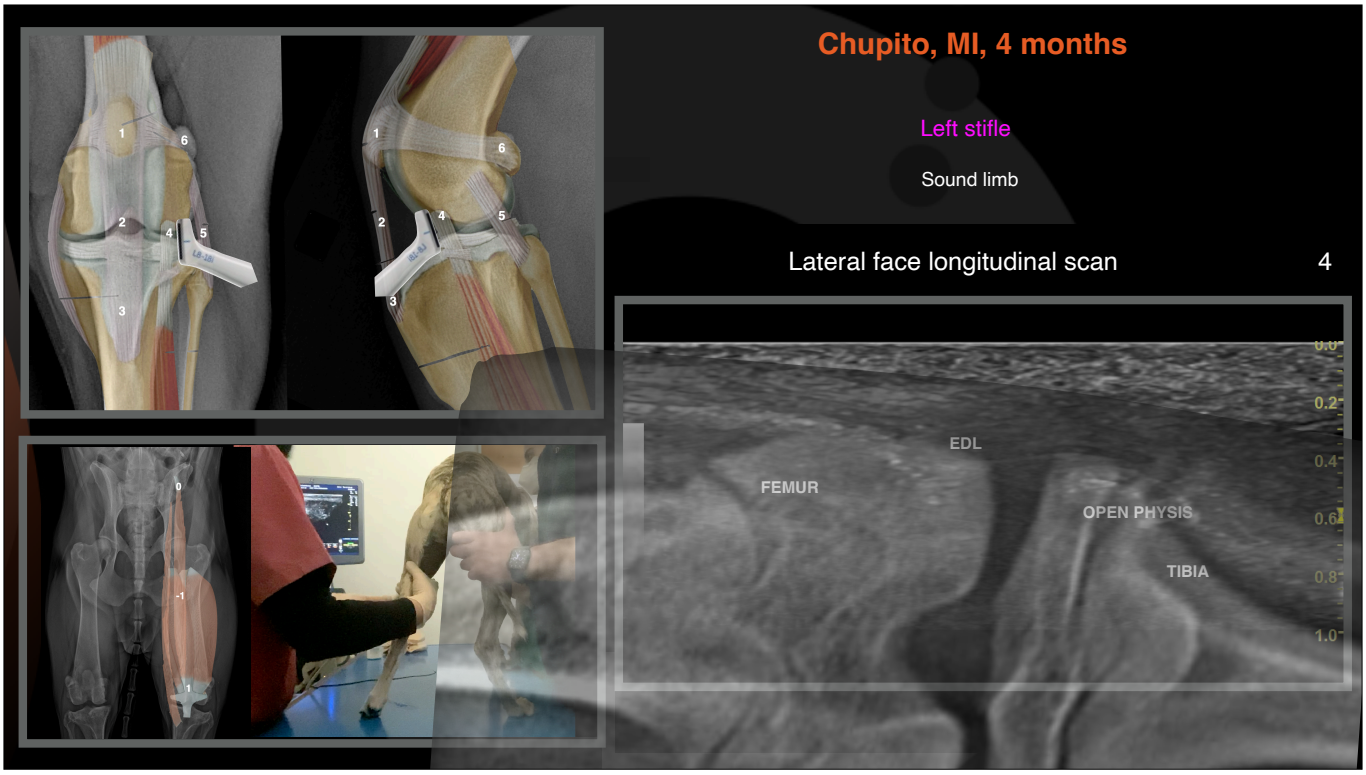
Chupito, MI, 4 months
Left stifle
Sound limb
Lateral face longitudinal scan
4
EDL
FEMUR
OPEN PHYSIS
TIBIA

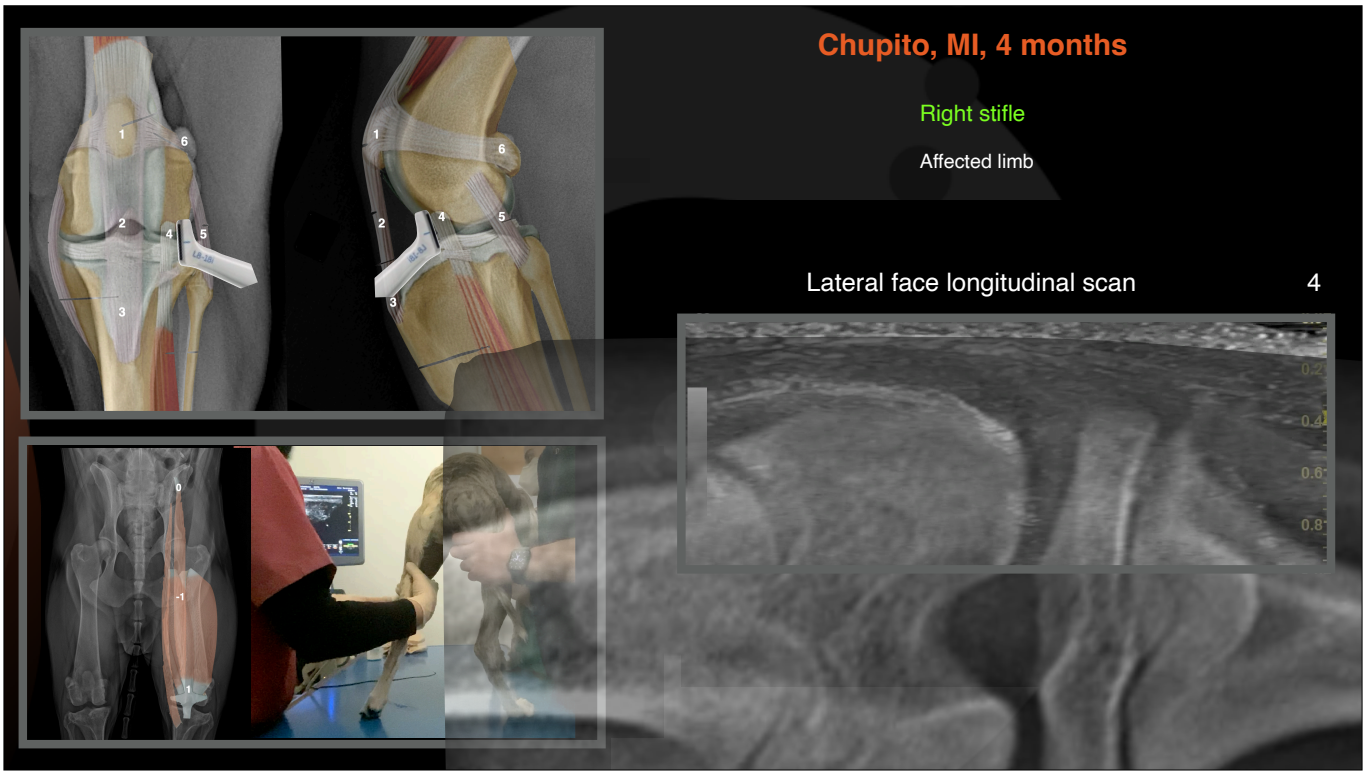
Chupito, MI, 4 months
Right stifle
Affected limb
Lateral face longitudinal scan
4

Chupito, MI, 4 months

Left stifle

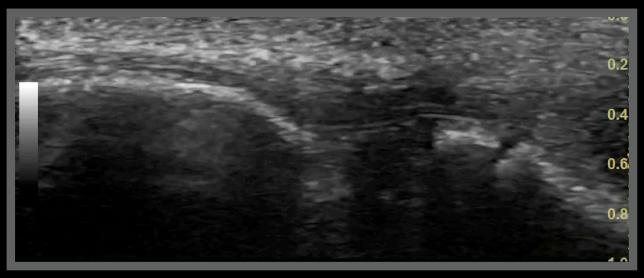

Right stifle

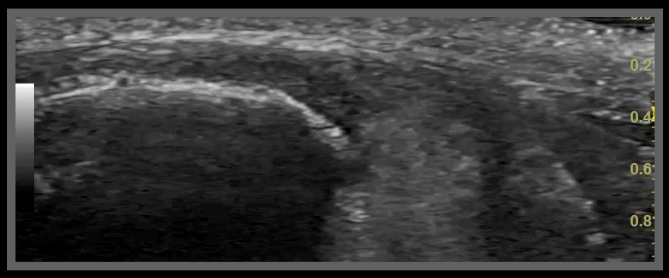

Chupito, Shetland , MI, 4 months

Ultrasonographic diagnoses:

- A suspected avulsed small fragment from the right extensor fossa
- Partial avulsion of the insertion of the right extensor digitorum longus

How to arrive to Conclusions:

- PE examination
- Blood works
- Ultrasonographic findings
- Literature

Literature

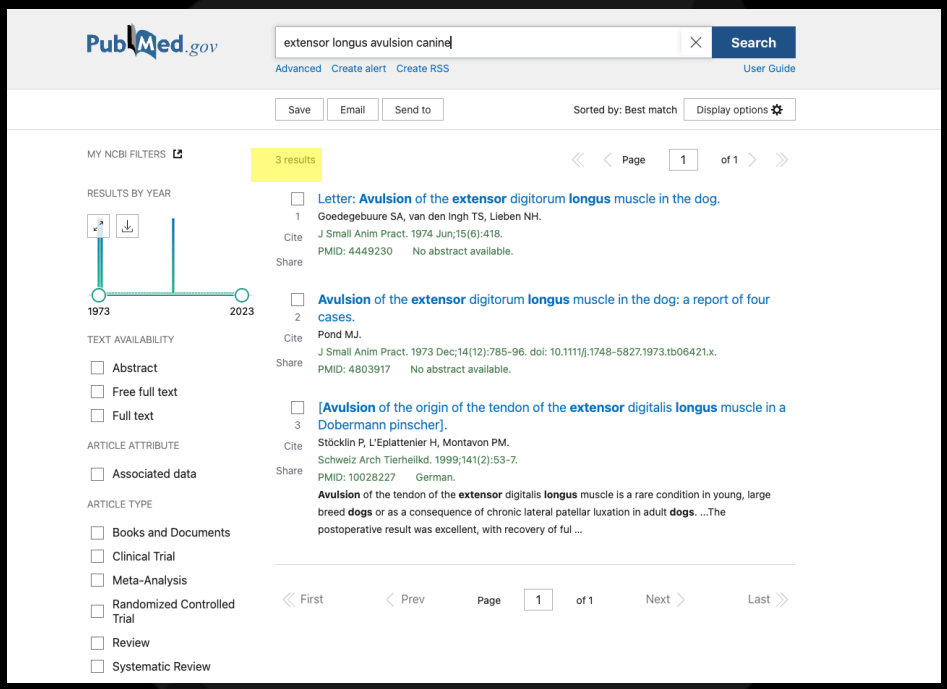

Literature

PubMed.gov

extensor longus dog | Search

Advanced Create alert Create RSS User Guide

Save Email Send to Sorted by: Best match Display options

MY NCBI FILTERS

RESULTS BY YEAR

1973 2023

TEXT AVAILABILITY

- Abstract
- Free full text
- Full text

ARTICLE ATTRIBUTE

- Associated data

ARTICLE TYPE

- Books and Documents
- Clinical Trial
- Meta-Analysis
- Randomized Controlled Trial
- Review
- Systematic Review

PUBLICATION DATE

37 results

Page 1 of 4

1 Letter: Avulsion of the **extensor** digitorum **longus** muscle in the **dog**.
Goedegebuure SA, van den Ingh TS, Lieben NH.
J Small Anim Pract. 1974 Jun;15(6):418.
PMID: 4449230 No abstract available.

2 Avulsion of the **extensor** digitorum **longus** muscle in the **dog**: a report of four cases.
Pond MJ.
J Small Anim Pract. 1973 Dec;14(12):785-96. doi: 10.1111/j.1748-5827.1973.tb06421.x.
PMID: 4803917 No abstract available.

3 **Extensor** Tendon Entrapment on Computed Tomography Imaging of Distal Radius Fractures.
Nigh ED, Emerson CP, To D, Barnhill S, Rizzo MG, Nguyen DM, Ugarte A, Muñera F, Greif DN, Jose J, Dodds SD.
J Wrist Surg. 2020 Apr;9(2):129-135. doi: 10.1055/s-0039-3402424. Epub 2019 Dec 24.
PMID: 32257614 Free PMC article.
Mechanism of injury included falls (n = 7), motor vehicle accidents (n = 6), **dog** bites (n = 2), and gunshot wound (n = 1). Entrapped tendons were limited to the **extensor** compartment and included the **extensor** pollicis **longus** (EPL; n = 11), **extens** ...

4 Ultrasonographic anatomy of the dorsal region of the carpus of the **dog**.
González-Rellán S, Fdz-de-Trocóniz P, Barreiro A.
Vet Radiol Ultrasound. 2021 Sep;62(5):591-601. doi: 10.1111/vru.13003. Epub 2021 Jul 26.
PMID: 34309128
The final study, based on the methodology developed in a pilot study performed in twenty-two carpi, comprised two phases: (a) identification phase, in which a correlation between ultrasound and dissection and anatomic slices was performed in forty-eight cadaver carpi and the ultr ...

438 **Case Report** Vlaams Diergeneeskundig Tijdschrift, 2007, 76

Unusual presentation of an avulsion of the long digital extensor tendon in a dog: radiographic, computed tomographic, arthroscopic, surgical and histological findings

Een ongewone vorm van avulsie van de pees van de m. extensor digitorum longus bij een hond: radiografische, computertomografische, artroscopische, chirurgische en histologische bevindingen

[1,2]G. Verhoeven, [1]B. Van Ryssen, [1]I. Gielen, [1]M. Risselada, [1]H. van Bree

[1]Department of Medical Imaging of Domestic Animals, Faculty of Veterinary Medicine, Ghent University, Salisburylaan 133, B-9820 Merelbeke

[2]Algemene Dierenkliniek Randstad, Frans Beirenslaan 155, B-2150 Borsbeek

Geertverhoeven@hotmail.com

ABSTRACT

A long digital extensor tendon avulsion is reported in a 15-month-old intact male Great Dane with a right pelvic limb lameness of 2-week duration. The orthopedic, radiographic, computed tomographic, arthroscopic, surgical and histological findings are described. Surgical excision of the avulsed bone fragment and re-attachment of the tendon to the lateral joint capsule of the stifle joint was successful and the dog was free of lameness 6 and 12 months after therapy.

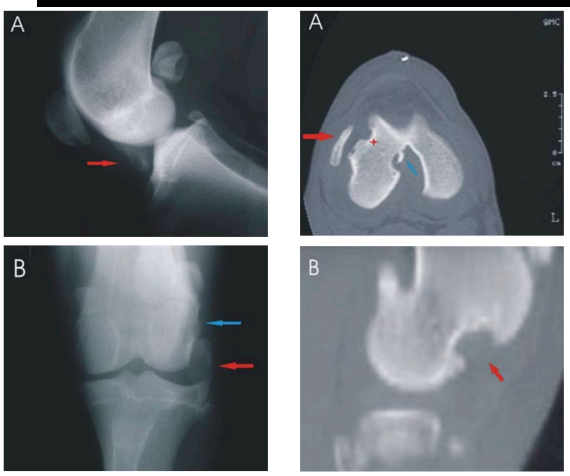

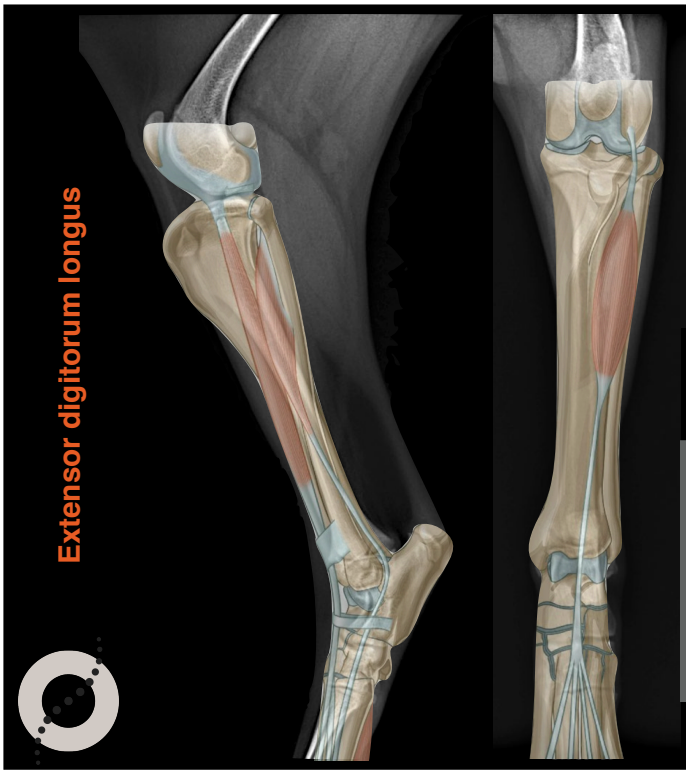

Key points to diagnose EPI avulsion

- Focal swelling lateral margin of stifle
- Tarsal hyperextension
- Scattering artefact and tendon detachment at the extensor fossa

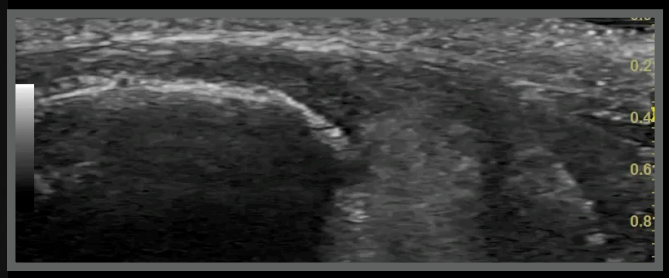

Chupito, Shetland, MI, 6 months

Two months recheck

- Clinically fine
- Housed in an active family

Drew, American Staffordshire, MI, 4 years

- Abnormal gait in the last two months
- Stable stifles on sedation
- Stoic patient
- Suspected pain on right stifle



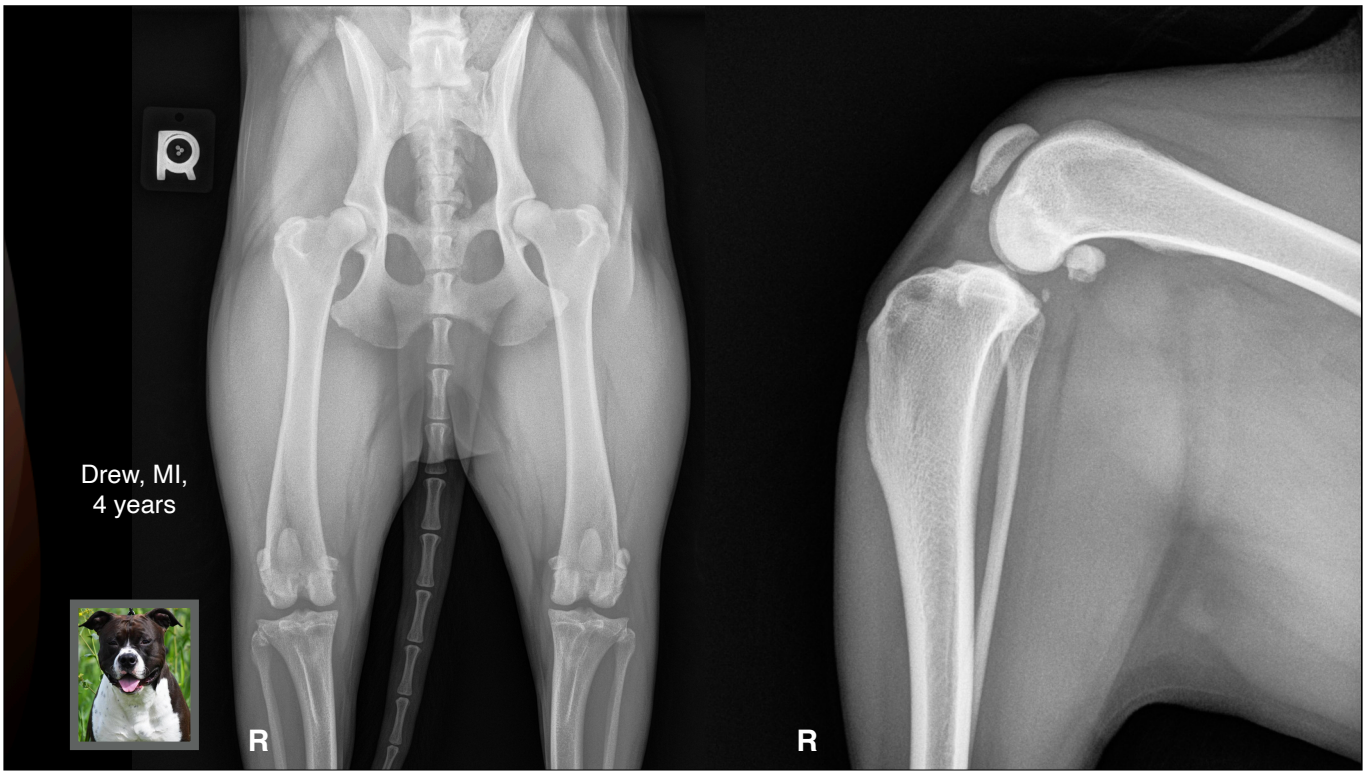

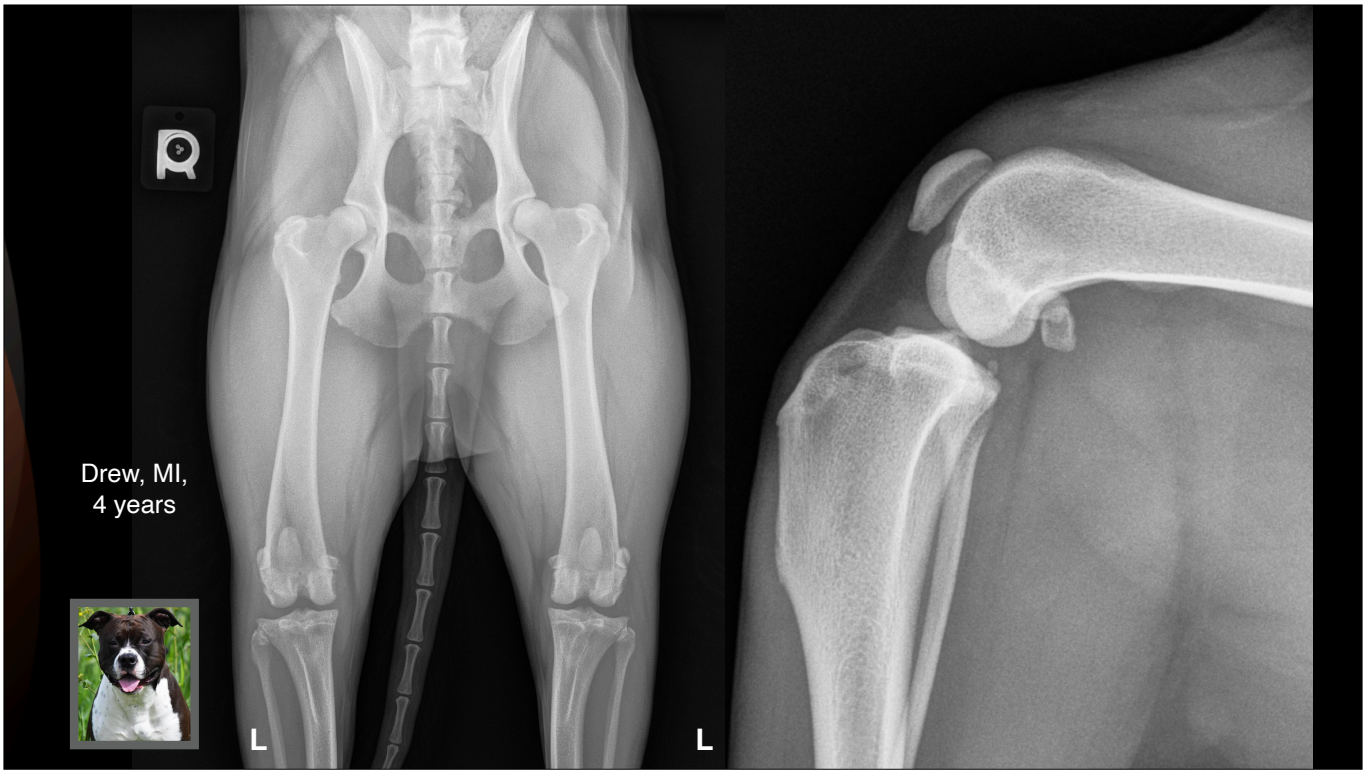
Drew, MI,
4 years
L
L

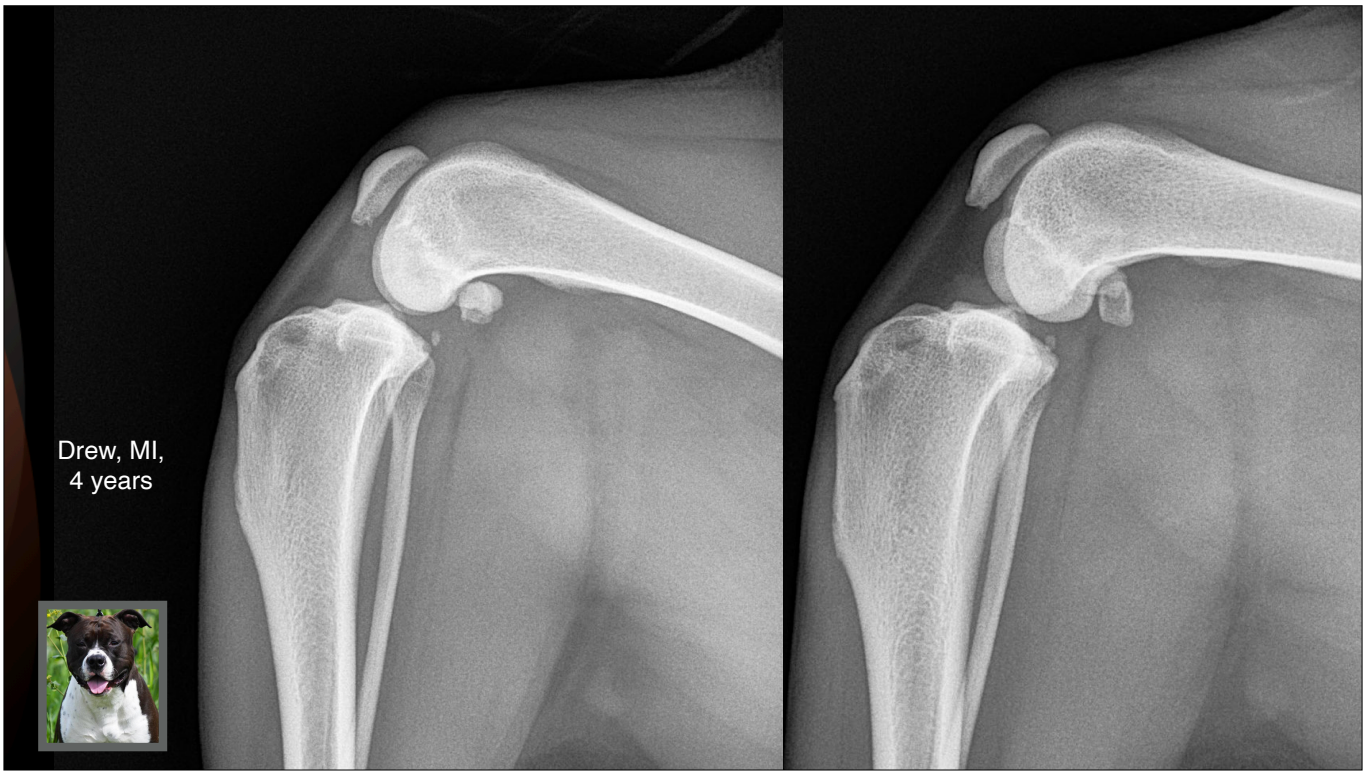
Drew, MI,
4 years

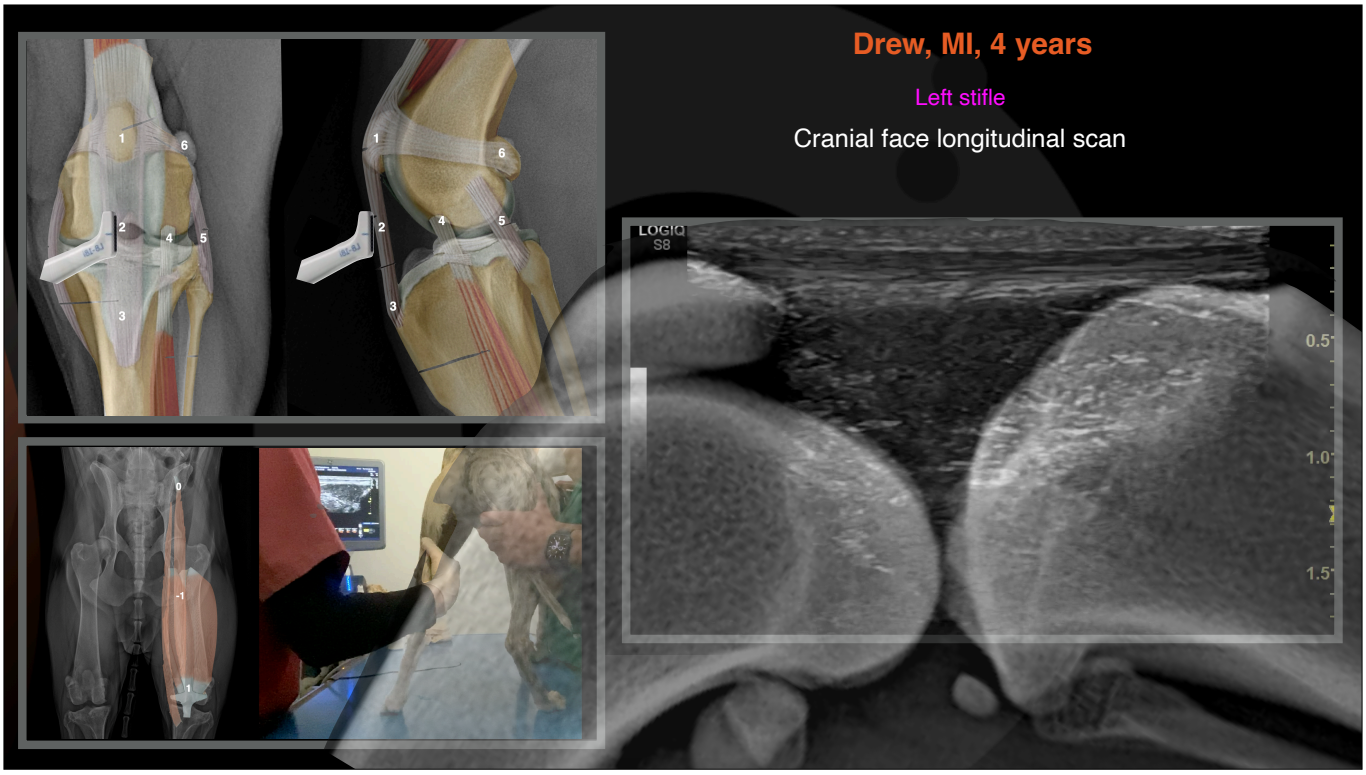
Drew, MI, 4 years
Left stifle
Cranial face longitudinal scan
LOGIQ
S8
0.5
1.0
1.5

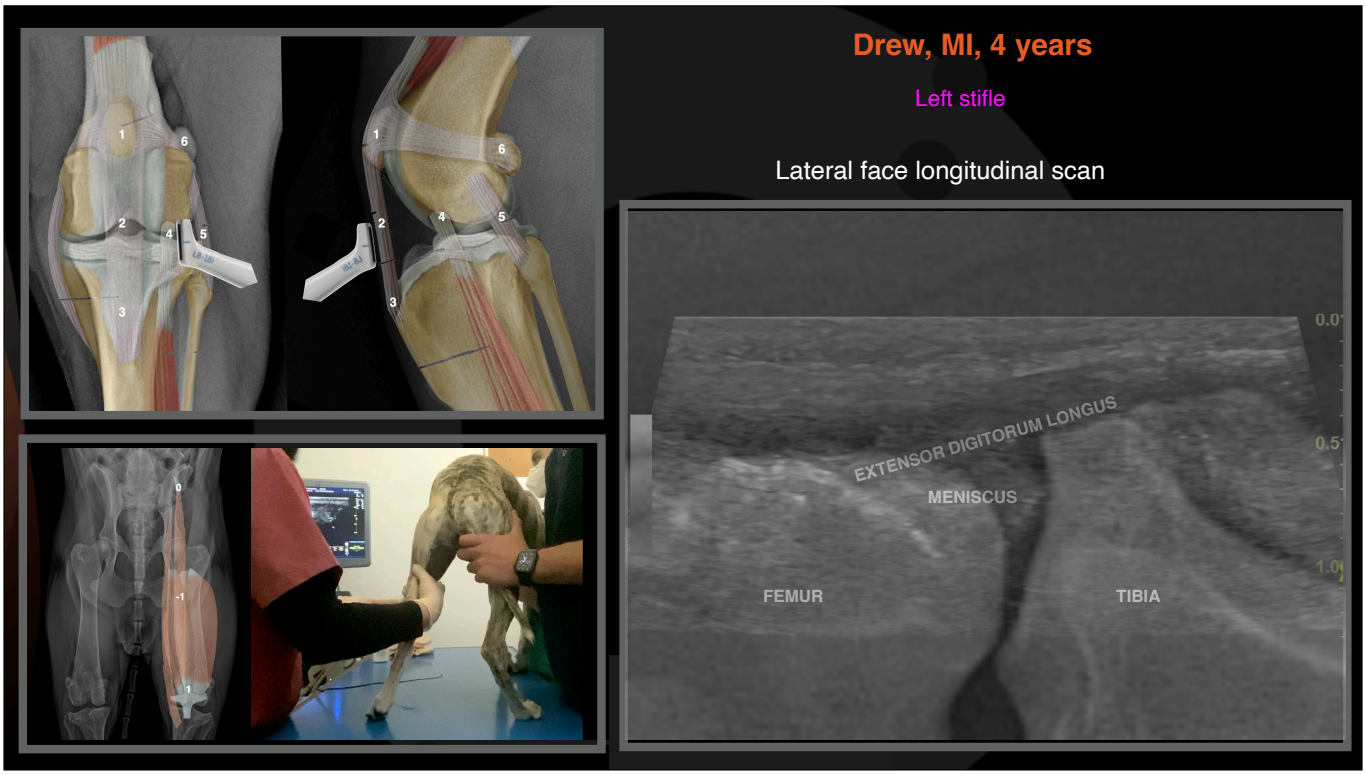
Drew, MI, 4 years
Left stifle
Lateral face longitudinal scan
EXTENSOR DIGITORUM LONGUS
MENISCUS
FEMUR
TIBIA
0.5

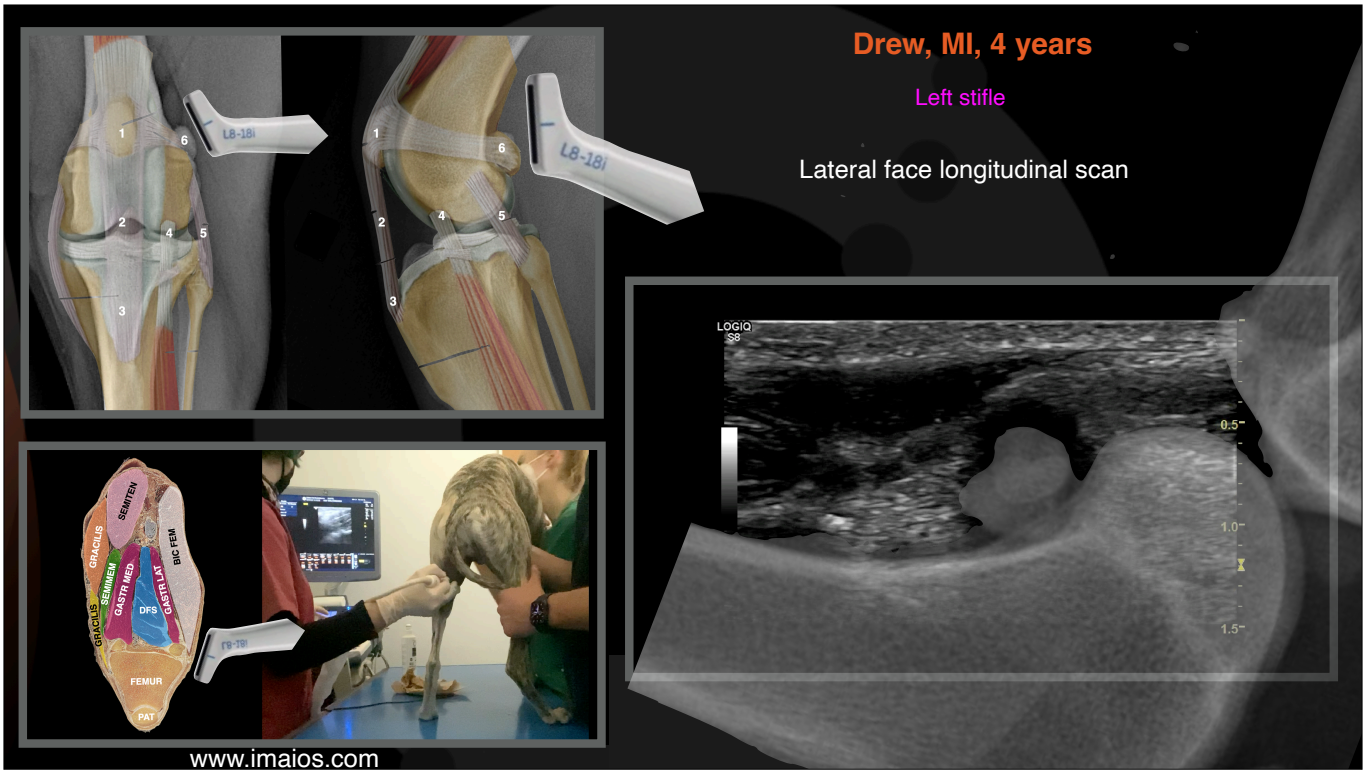
Drew, MI, 4 years
Left stifle
Lateral face longitudinal scan
LOGIQ
S8
SEMITEN
GRACILIS
SEMIMEM
GASTR MED
BIC FEM
GASTR LAT
DFS
FEMUR
PAT
www.imaios.com

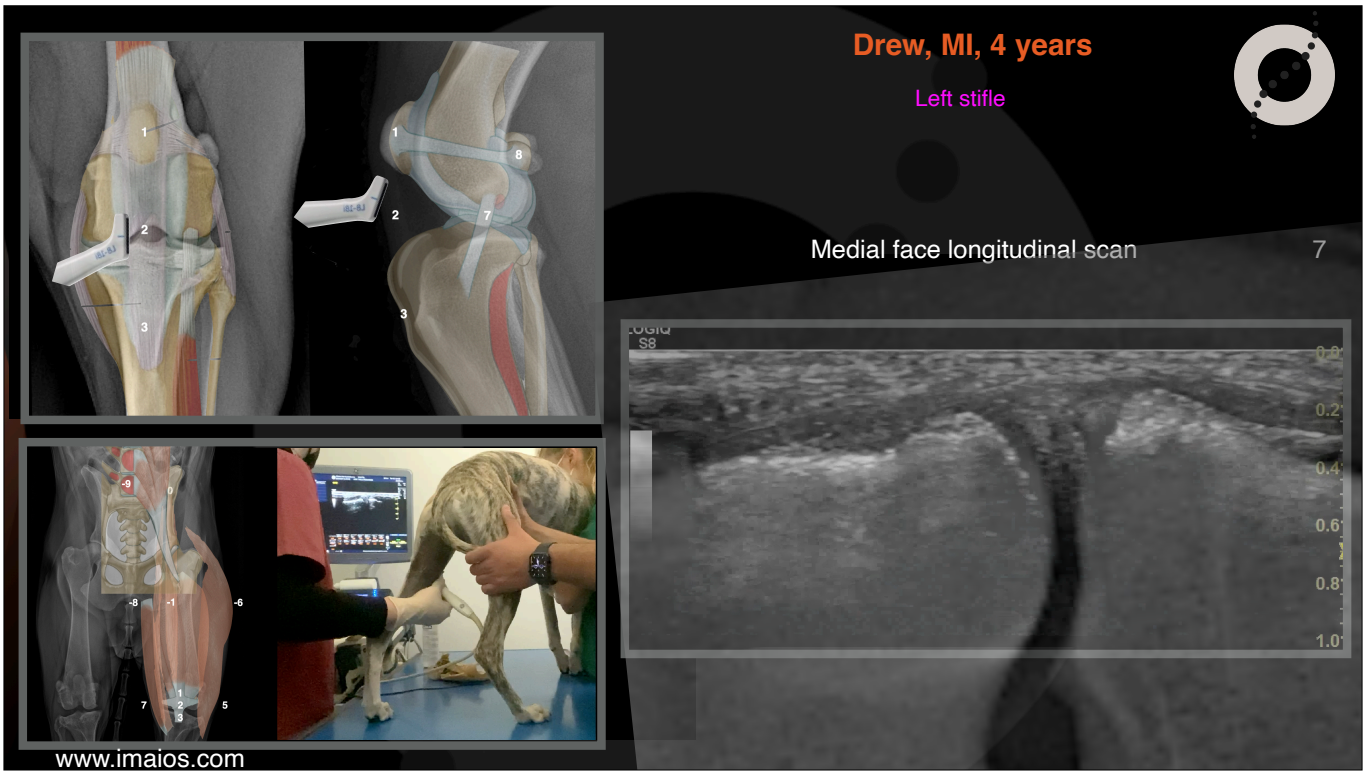
Drew, MI, 4 years
Left stifle
Medial face longitudinal scan
7
LOGIQ
S8
www.imaios.com

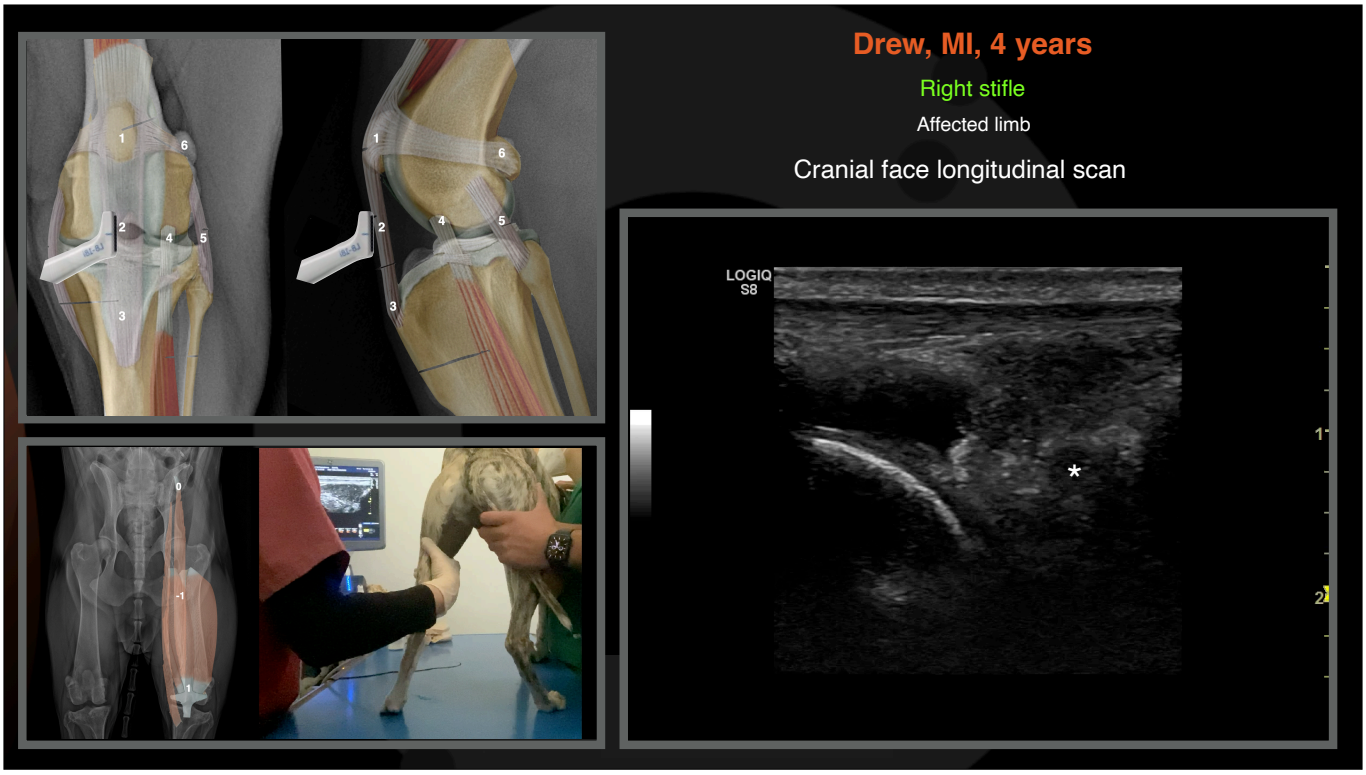
Drew, MI, 4 years
Right stifle
Affected limb
Cranial face longitudinal scan
LOGIQ
S8

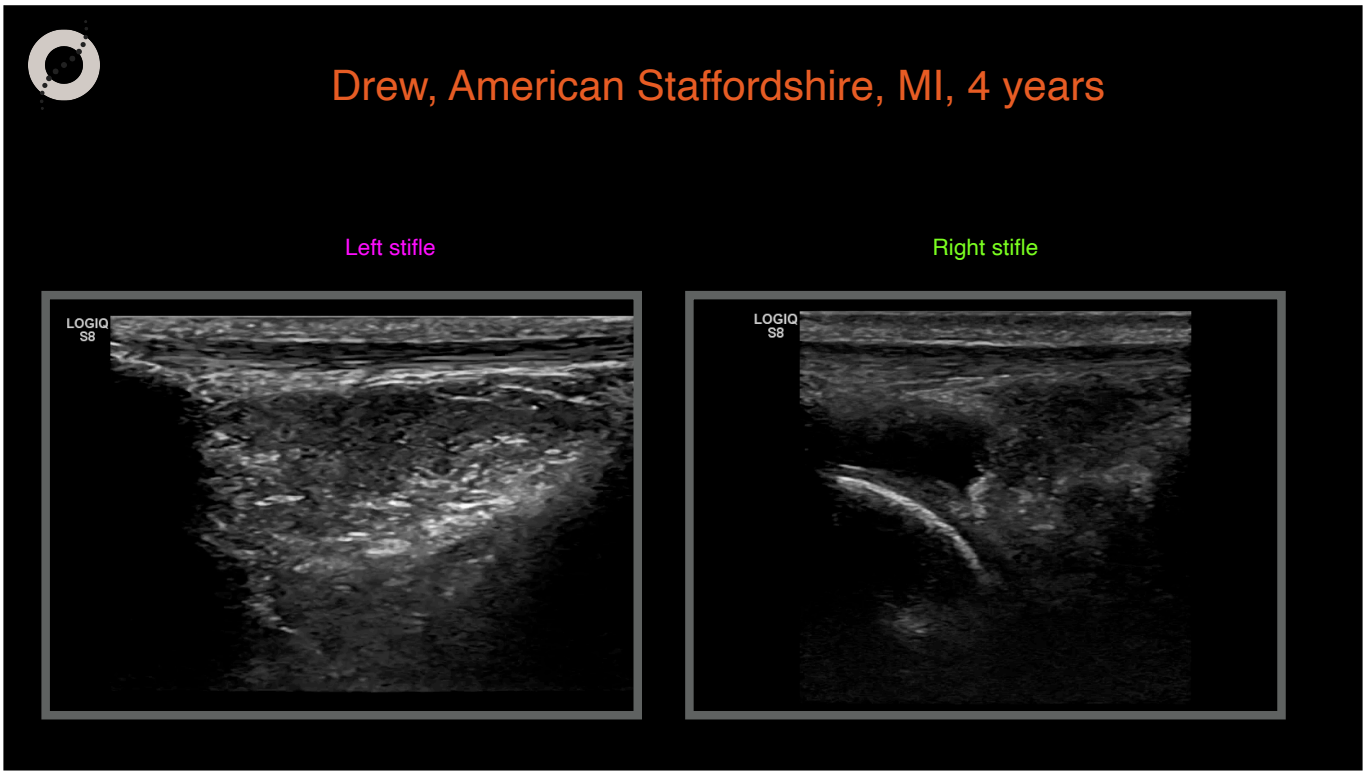
Drew, American Staffordshire, MI, 4 years
Left stifle
Right stifle
LOGIQ
S8
LOGIQ
S8

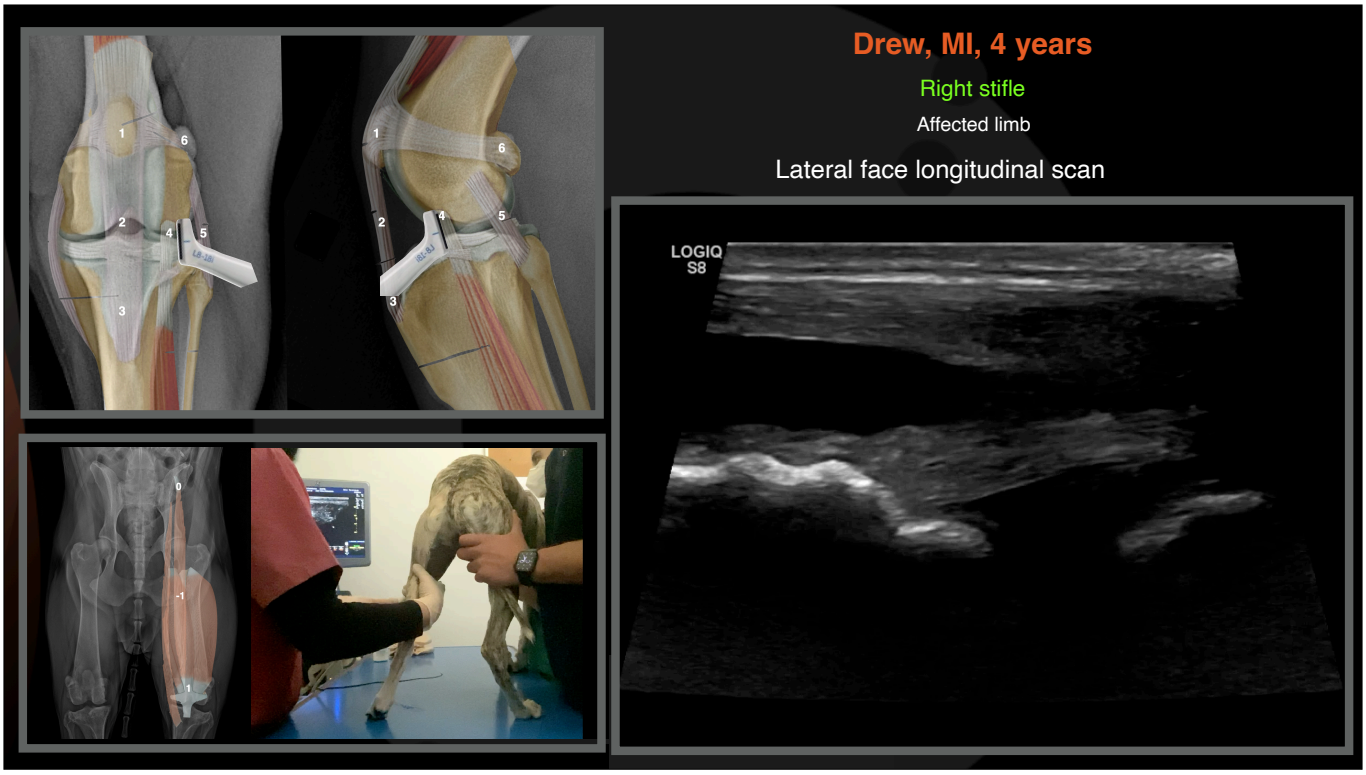
Drew, MI, 4 years
Right stifle
Affected limb
Lateral face longitudinal scan
LOGIQ
S8

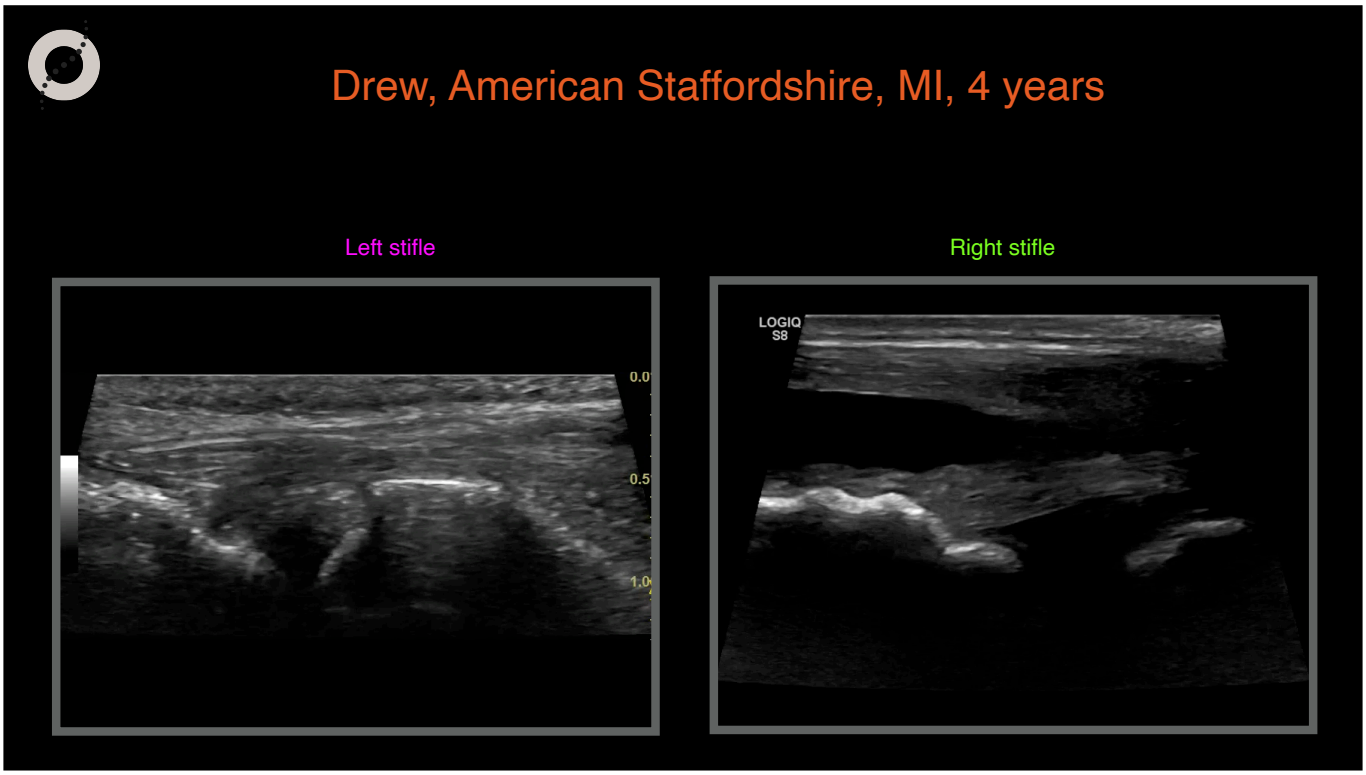
Drew, American Staffordshire, MI, 4 years
Left stifle
Right stifle
LOGIQ
S8

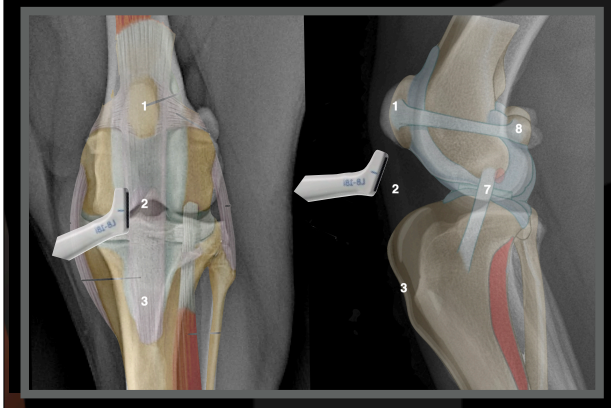

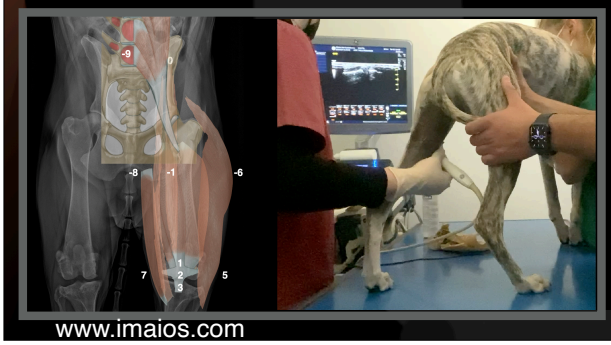

Drew, MI, 4 years

Right stifle

Affected limb

Medial face longitudinal scan 7

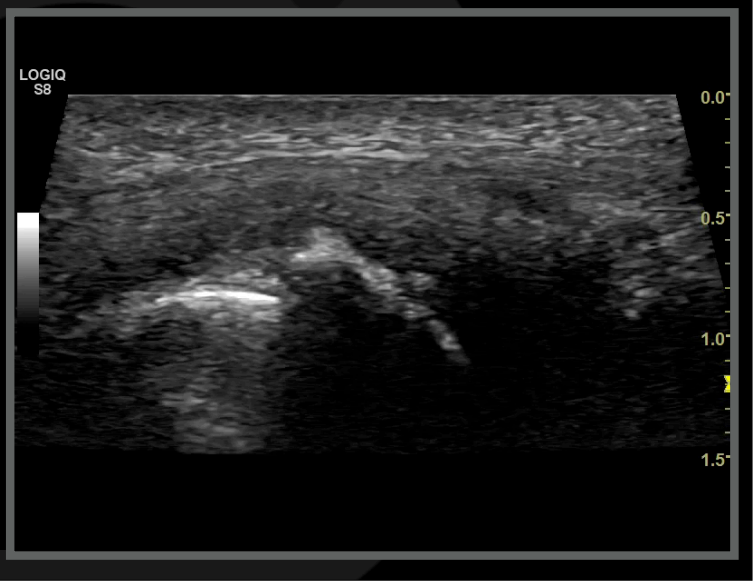

www.imaios.com

Drew, American Staffordshire, MI, 4 years

Left stifle

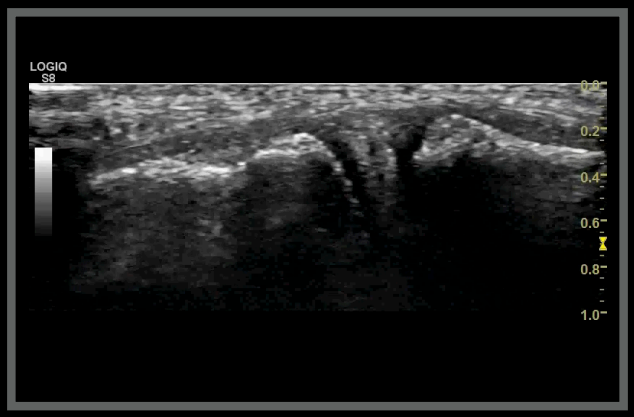

Right stifle

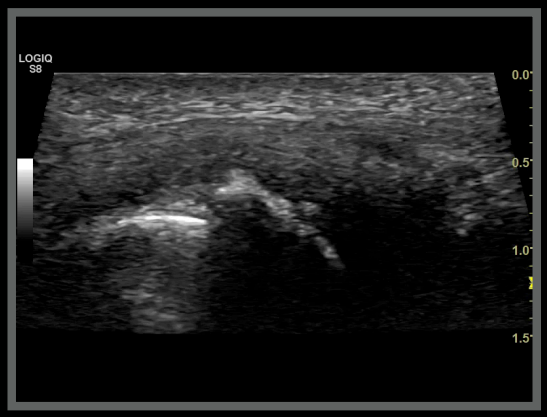

Drew, American Staffordshire, MI, 4 years



Ultrasonographic diagnoses:

- Right stifle effusion
- Distended right extensor digitorum longus
- Suspected medial meniscal tear

Conclusions:

- Partial CCL rupture and medial meniscus tear identified at surgery

US of the meniscus

Comparison of ultrasonography and magnetic resonance imaging to arthroscopy for diagnosing medial meniscal lesions in dogs with cranial cruciate ligament deficiency

JAVMA • Vol 251 • No. 1 • July 1, 2017

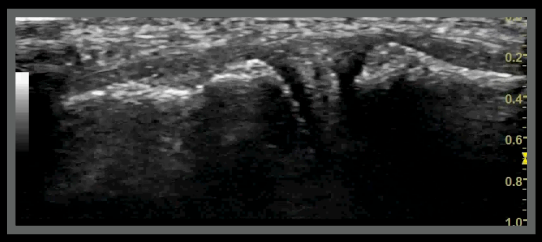

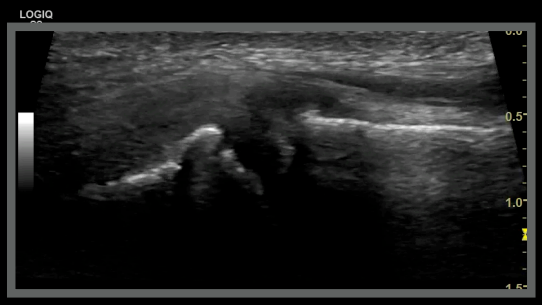

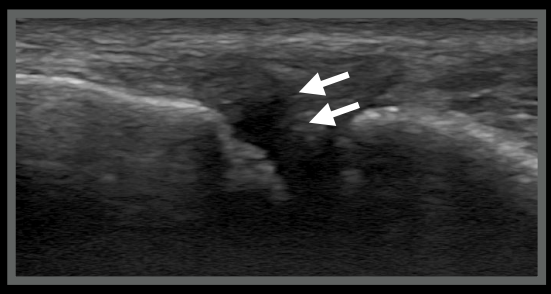

Thank you

Diagnostic Mindset

www.diagnosticmindset.com