

# Ultrasound of the hip and medio-caudal portion of the thigh

Giliola Spattini  
DVM, GP Cardio, CCRT, PhD, DECVDI



Diagnostic Mindset



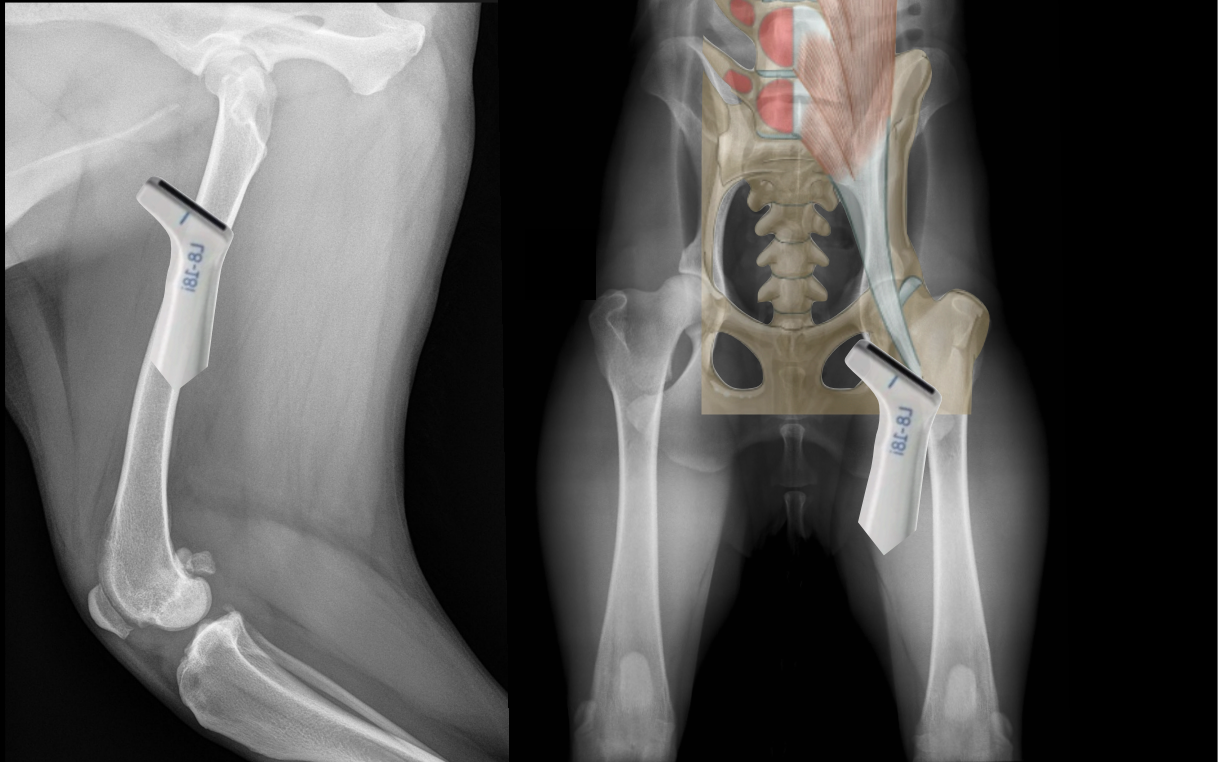
Thank to [www.imaios.com](http://www.imaios.com)

## Objectives

- Humans use ultrasound to screen for hip joint dysplasia
- Can we do so in canine patients?
- Can ultrasound be used on hip joints?

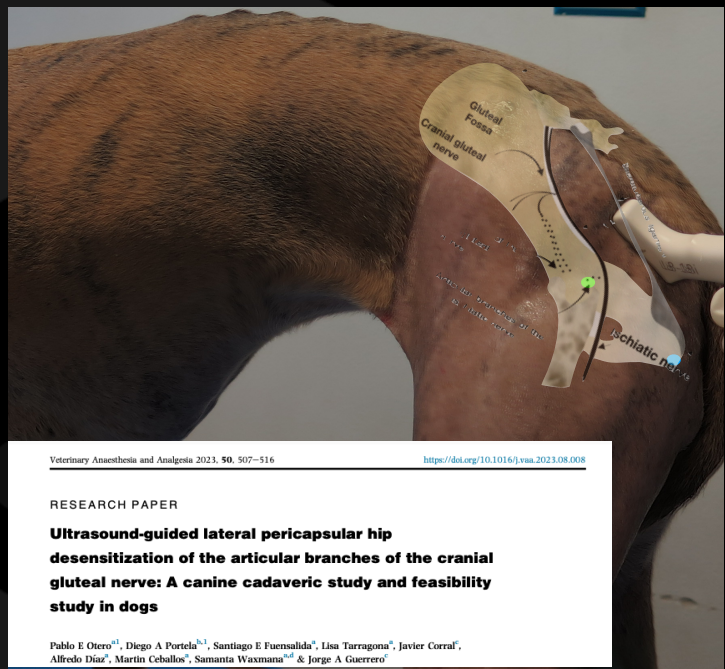

Ultrasonographic technique to the medial portion of the hip



Ultrasonographic technique for the lateral portion of the hip

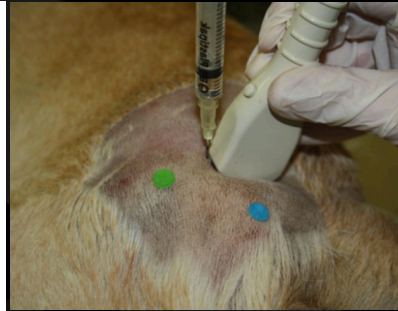- Greater trochanter
- Ischiatic tuberosity



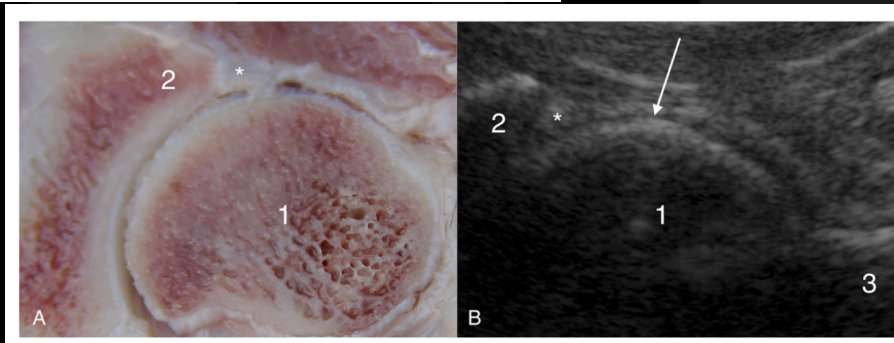
## DEVELOPING A TECHNIQUE FOR ULTRASOUND-GUIDED INJECTION OF THE ADULT CANINE HIP

CHIARA BERGAMINO, ANNE-LAURE ETIENNE, VALERIA BUSONI

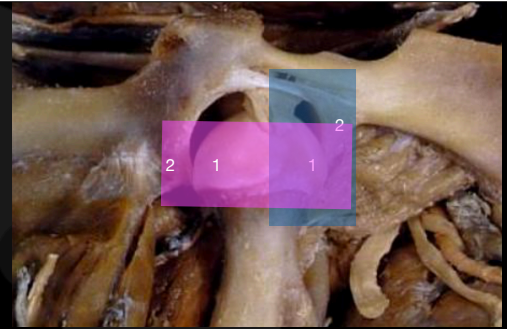
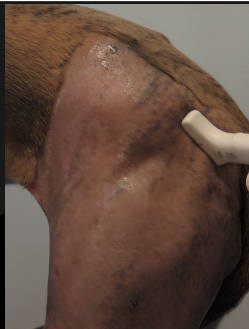An accurate method for guiding injections into the canine hip would facilitate diagnostic localization of lameness and targeted treatments. Ultrasound-guided hip injections are commonly used in humans and large animals. Aims of this prospective study were to describe ultrasound (US) anatomy of the adult canine hip and determine the feasibility and accuracy of intra-articular placement of injectate using US-guidance. Seven adult dogs were used to describe US anatomy, five dog cadavers were used to assess the feasibility of the injection technique and 11 dog cadavers were used to assess accuracy of injections. For the accuracy test, 22 joints were injected with iodinated contrast medium by three operators with different experience. With dogs in lateral recumbency, the hyperechoic femoral head surface was identified by following the femoral neck from the greater trochanter or the acetabular rim was localized by following caudally the ilium from the iliac wing. An anechoic gap between the femoral head and acetabular surface represented the joint. The capsule was visible as a triangular echoic structure and the femoral head articular cartilage appeared as an anechoic band. The needle was inserted axially to the greater trochanter and directed in a dorsolateral-ventromedial direction toward the joint space and then pushed through the capsule. Based on postinjection radiography, accuracy was 81.8% at first attempt and 100% at second attempt. This study indicated that US-guided injection is a feasible and accurate technique for injecting the adult canine hip. Future studies in live dogs are needed to assess safety and efficacy. © 2015 American College of Veterinary Radiology.



*Vet Radiol Ultrasound, Vol. 00, No. 0, 2015, pp 1-6.*

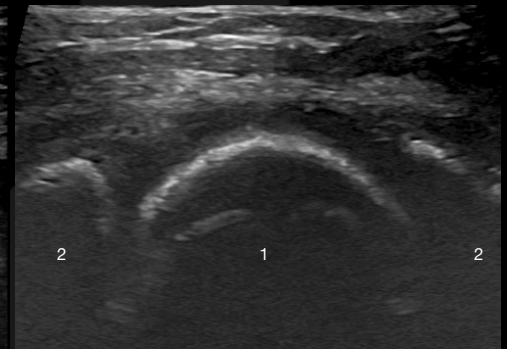
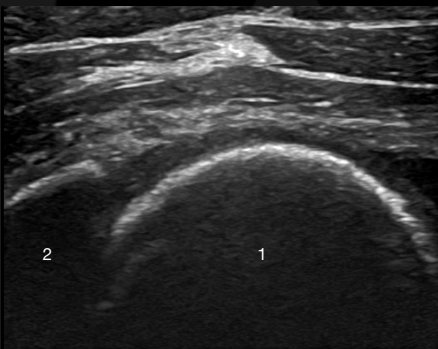
Can we use ultrasound for hip dysplasia in dogs?




Adams WM, Dueland RT, Daniels R, Fialkowski, JP, Nordheim EV. Comparison of two palpation, four radiographic and three ultrasound methods for early detection of mild to moderate canine hip dysplasia. *Vet Radiol Ultrasound* 2000;41:484-490.

Greshake RJ, Ackerman N. Ultrasound evaluation of the coxofemoral joints of the canine neonate. *Vet Radiol Ultrasound* 1992;33:99-104.

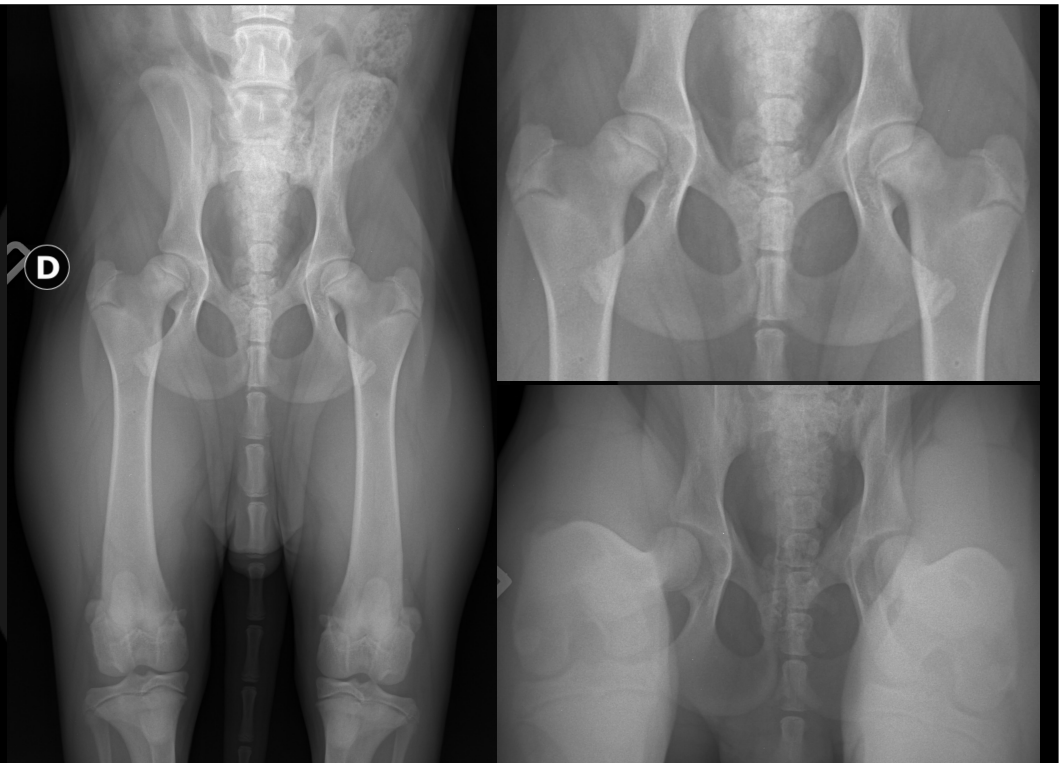



Dozer, Dogue de Bordeaux, MI, 6 Months

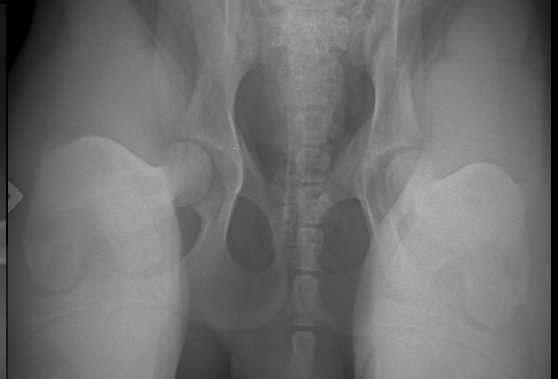
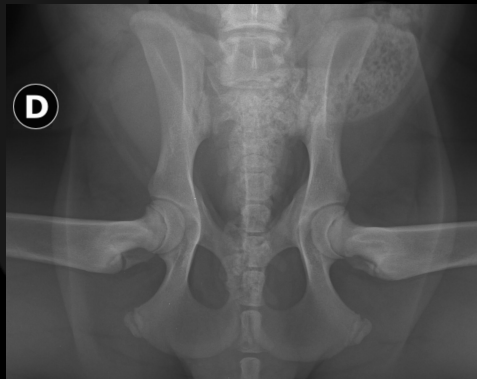
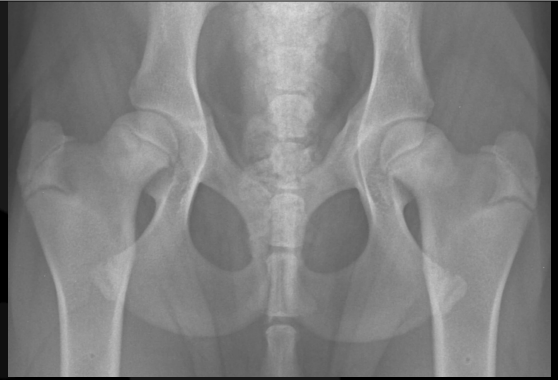
- After playing with a friend, left hind limb lameness
- Pain located on the left hip
- More severe on extension



Dozer, MI,  
6 months



Dozer, MI,  
6 months



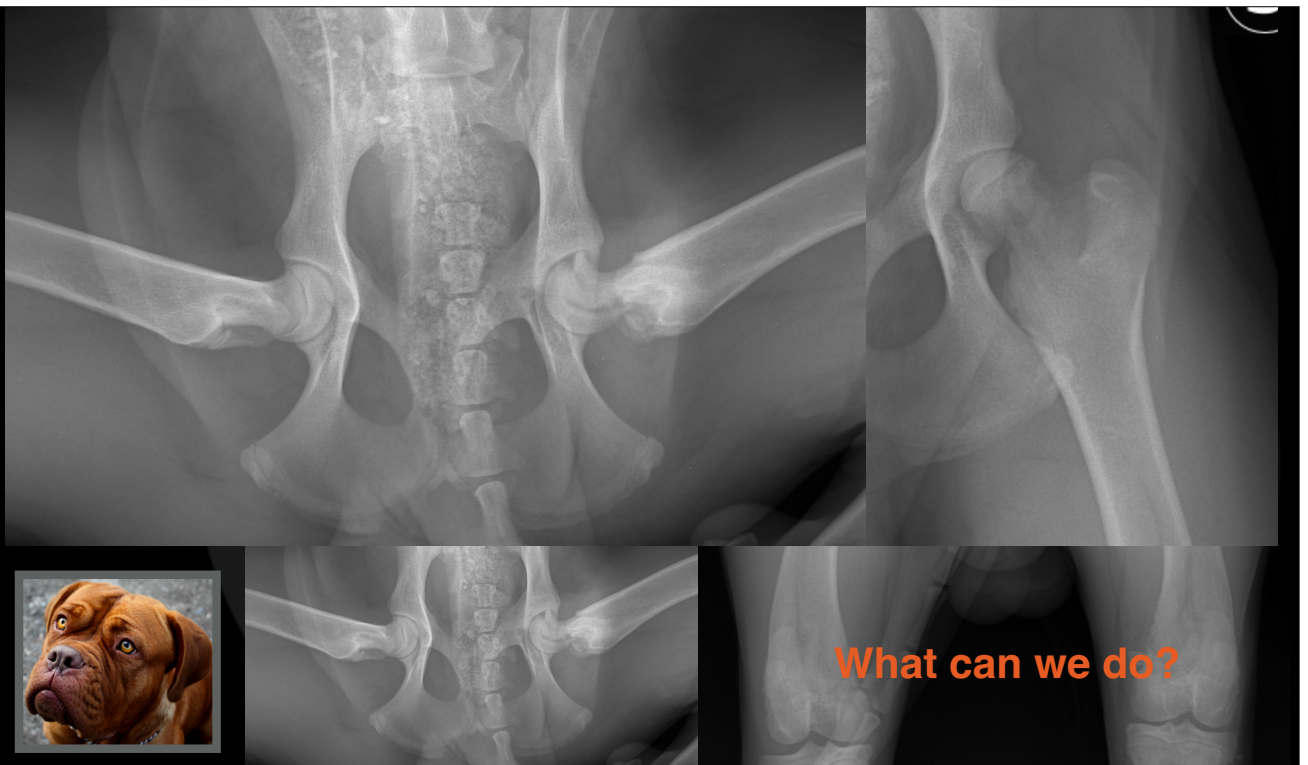
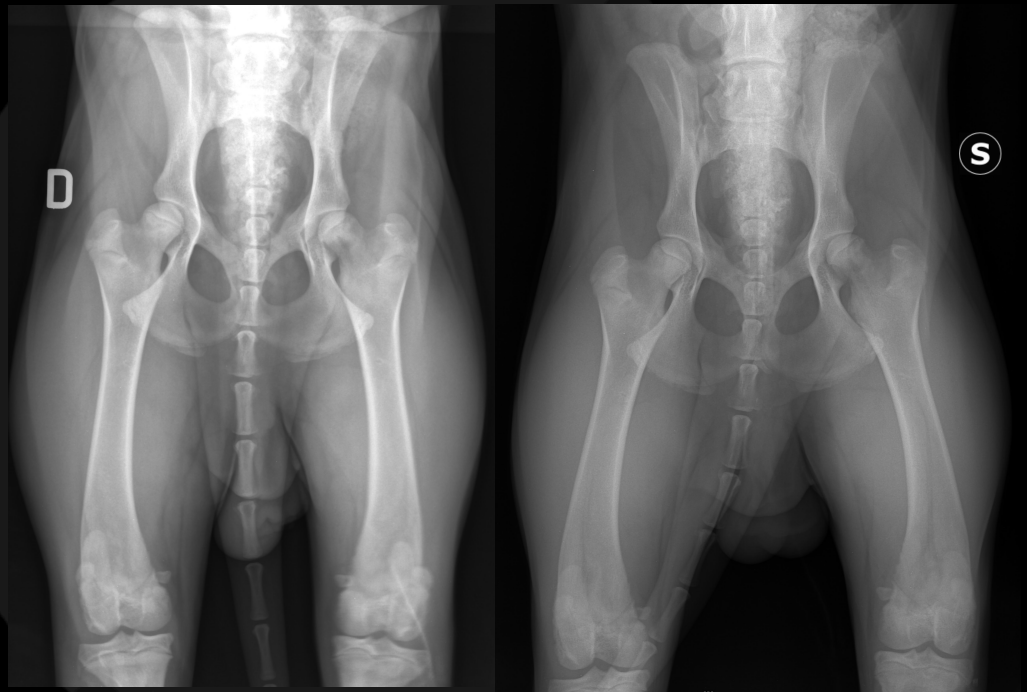

### Dozer, Dogue de Bordeaux, MI, 7 Months

- Relatively unremarkable radiographs
- Soft tissue trauma is suspected
- NSAID and recheck
- Still lame one month later



One month later

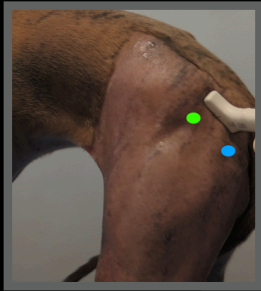Dozer, MI,  
6 months



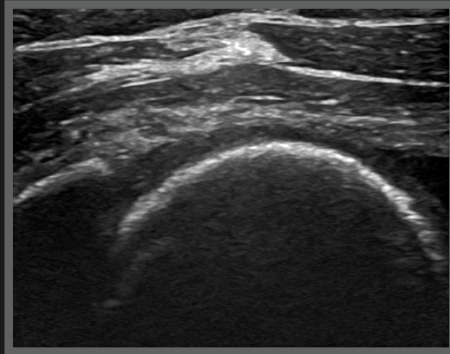
What can we do?

Ultrasonographically normal hip joint in an immature dog

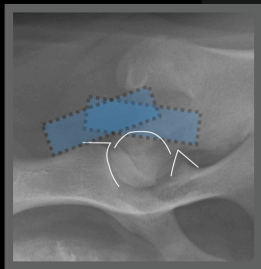
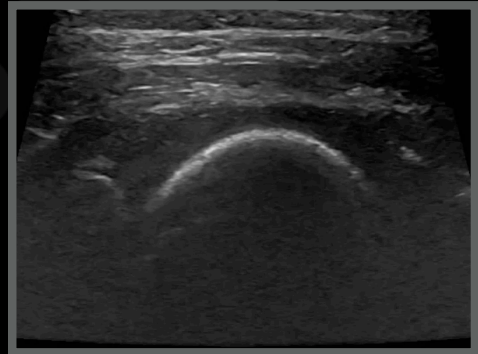
Dozer, MI, 6 months



Dorso-lateral window



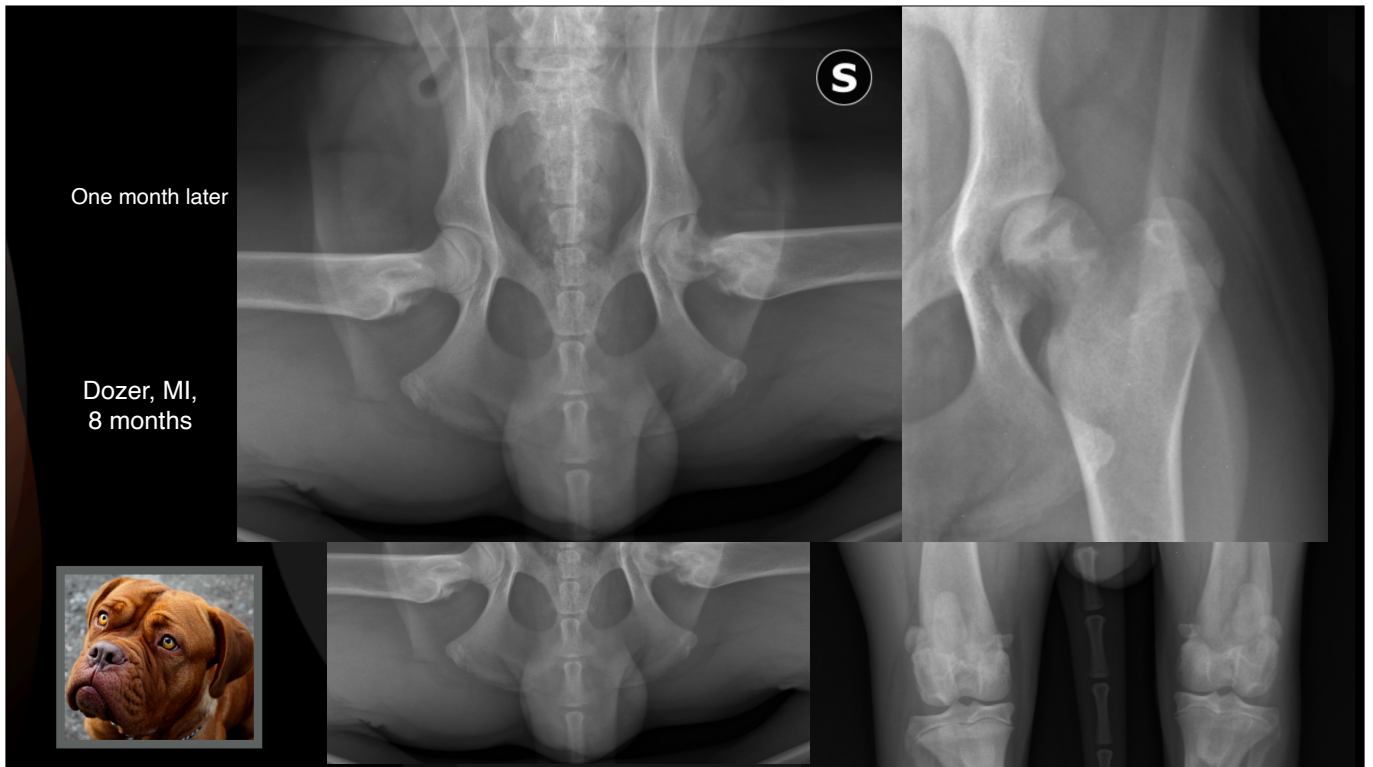
Dorso-lateral window



### Dozer, Dogue de Bordeaux, MI, 8 Months

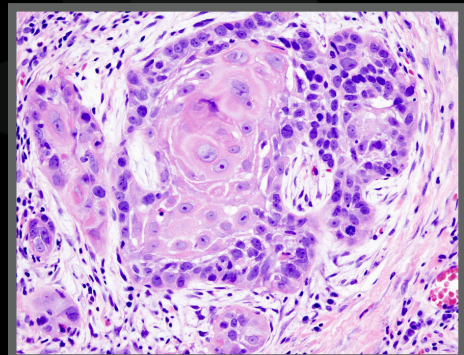
- Suspected septic arthritis
- Collected joint effusion, negative culture
- Cytological examination: scarce degenerated neutrophils and rare macrophages, no bacteria





**Dozer, Dogue de Bordeaux, MI, 8 Months**

- Histology report:
  - Degenerative change of the metaphysis
  - No inflammatory signs
  - No infection signs
  - Compatible with metaphyseal dysplasia

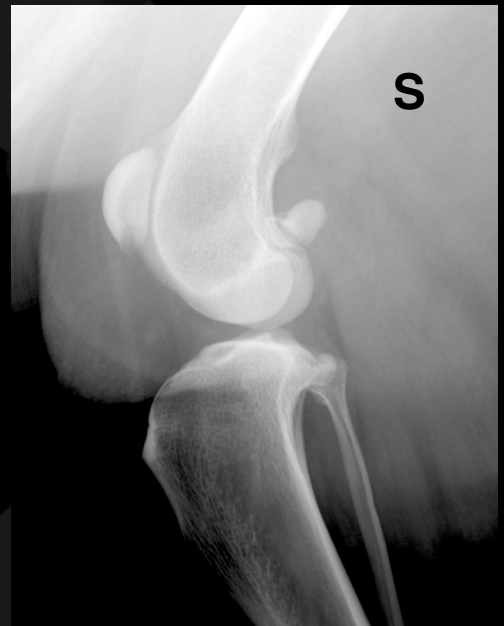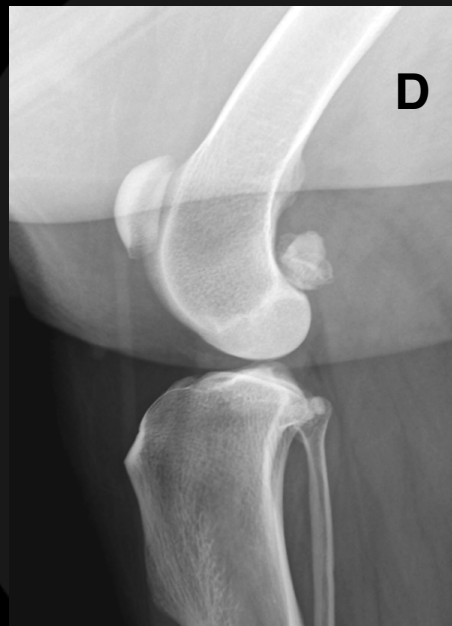


**Maya, Mongrel, FS, 11 years**

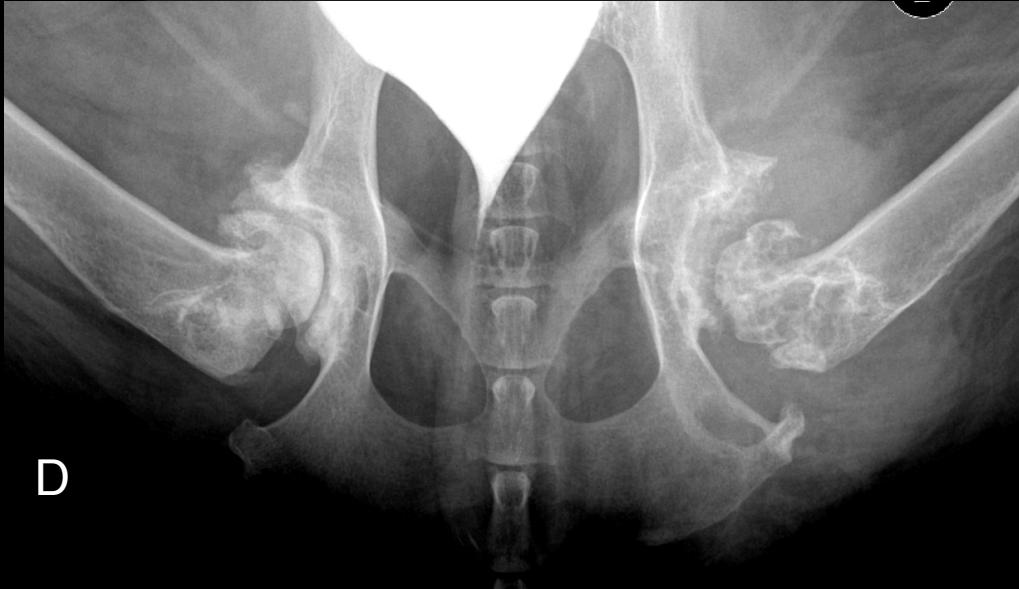- Intermittent lame left hind limb
- Pain to hip extension
- Left stifle mildly thickened



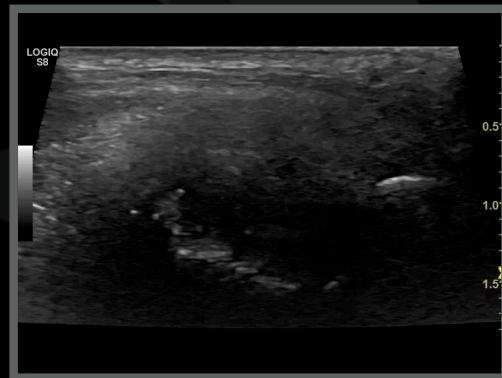
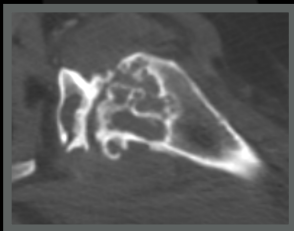
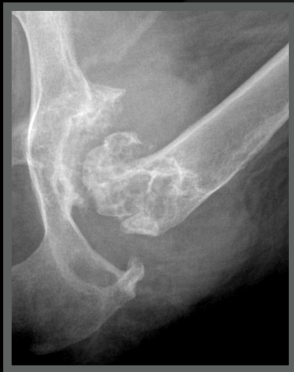Maya, FS,  
11 years



Maya, Mongrel, FS, 11 years



Maya, Mongrel, FS, 11 years

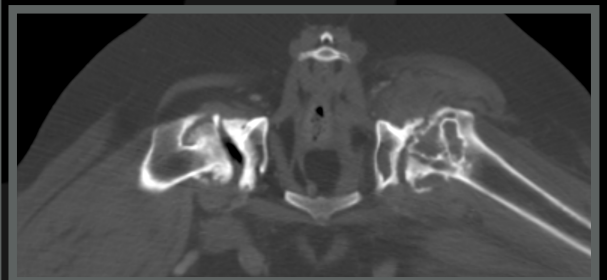
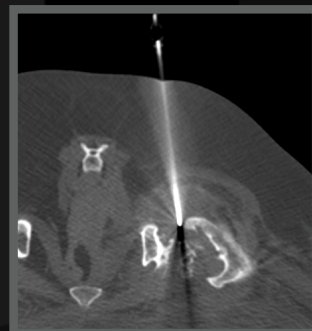
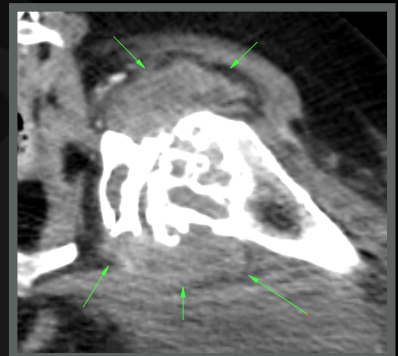
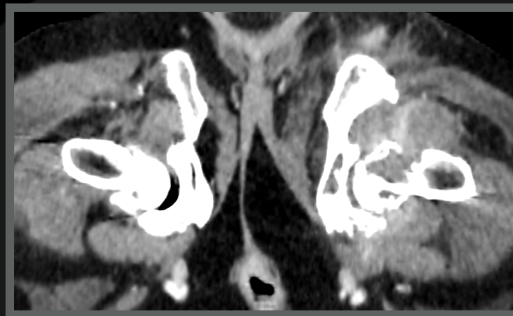
**Maya, Mongrel, FS, 11 years**

- Aggressive polyostotic lesion of the left hip joint
- Soft tissue mass
- Not diagnostic FNA sampling

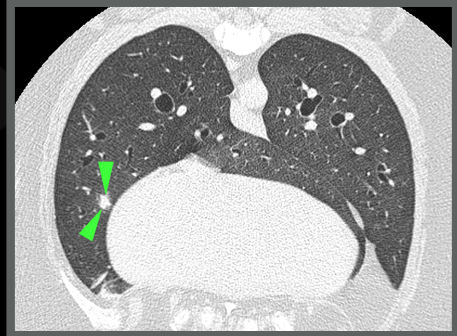

Maya, FS,  
11 years



**Maya, Mongrel, FS, 11 years**

- Final diagnosis:
  - Histiocytic sarcoma

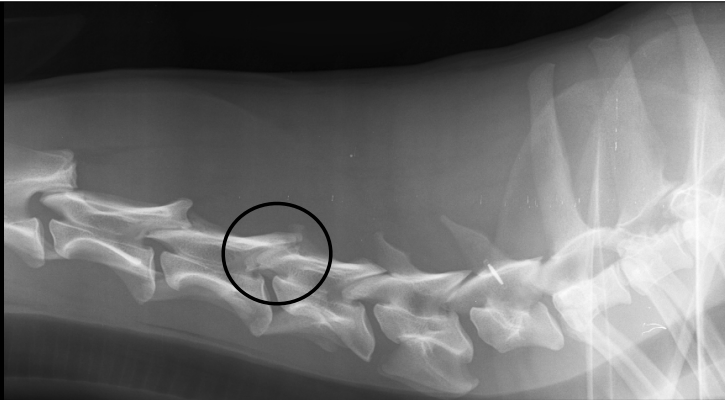
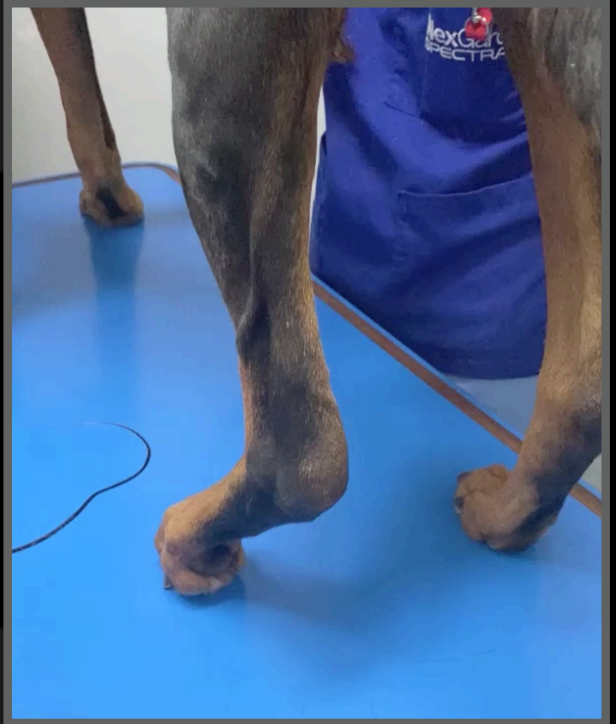
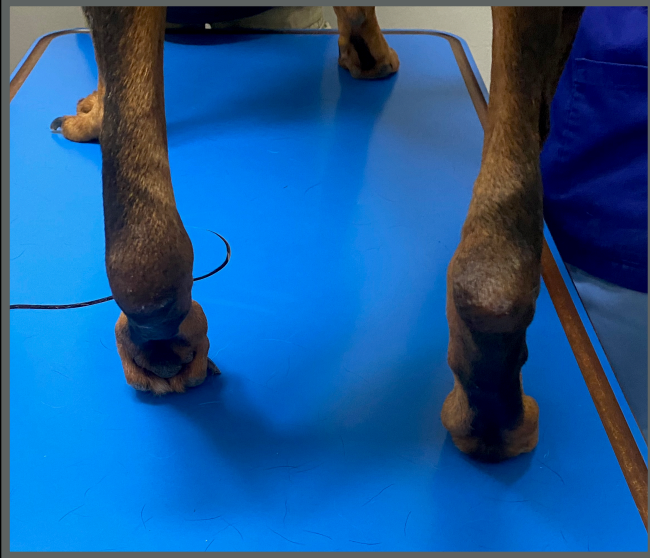
**Jack, Doberman, MN, 7 years**

- Progressive left hind limb lame-abnormal gait for three months
- Bilaterally thickened Achille's tendon

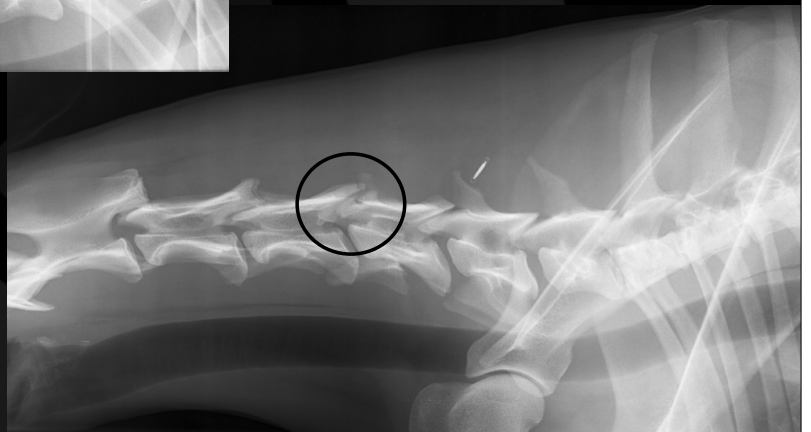

Jack MN, 7 years



- Negative neurological examination
- Abnormal cervical radiographs

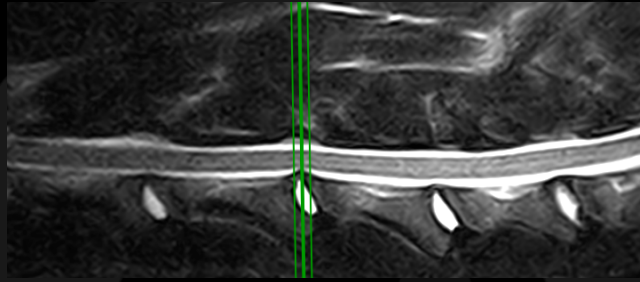
Jack MN, 7 years



Jack MN, 7 years



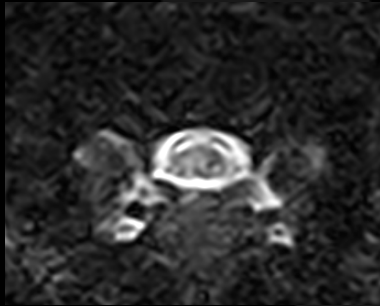
FSE T2 LONG



1-2-3

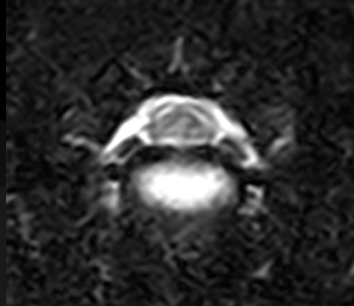
1

FSE T2 SAG



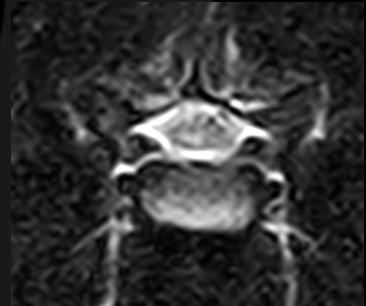
2

FSE T2 SAG



3

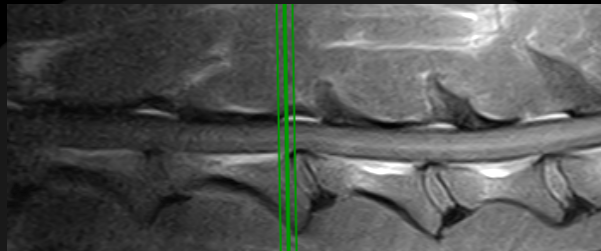
FSE T2 SAG



Jack MN, 7 years



FSE T1 LONG

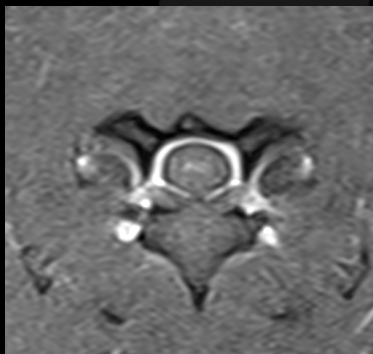


1-2-3

• Negative MRI

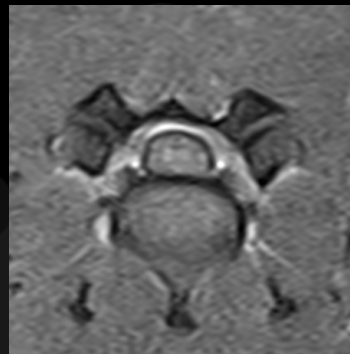
1

FSE T1 TRA



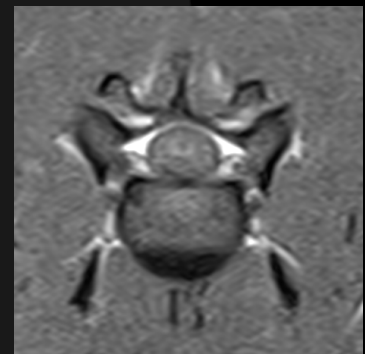2

FSE T1 TRA

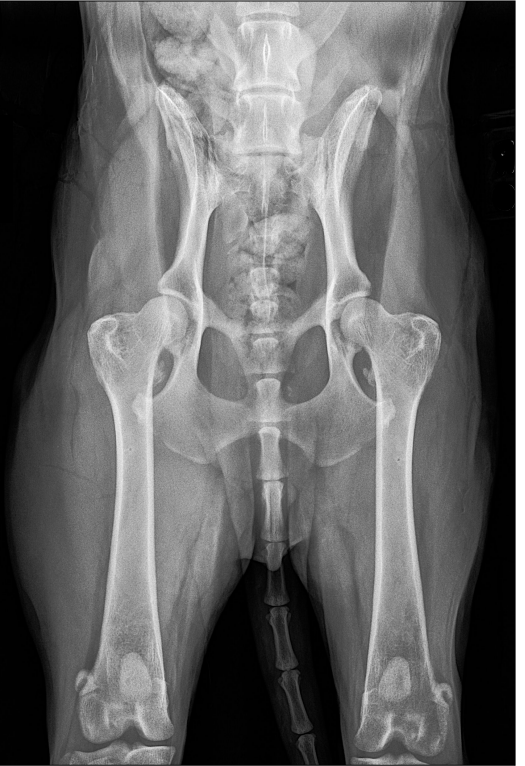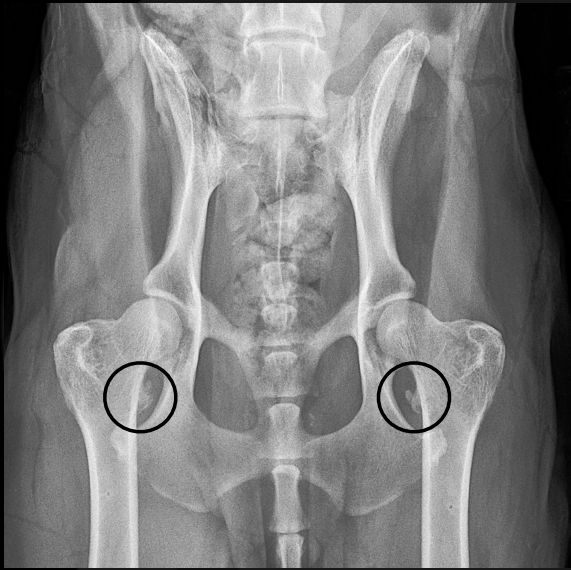


3

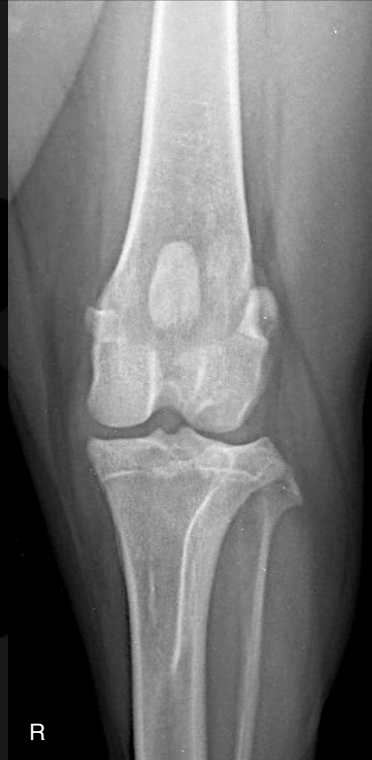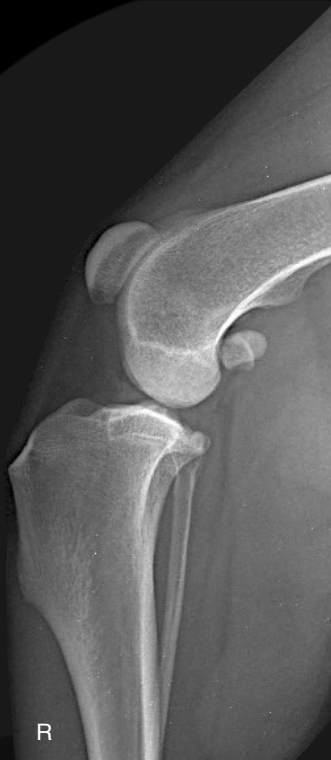FSE T1 TRA



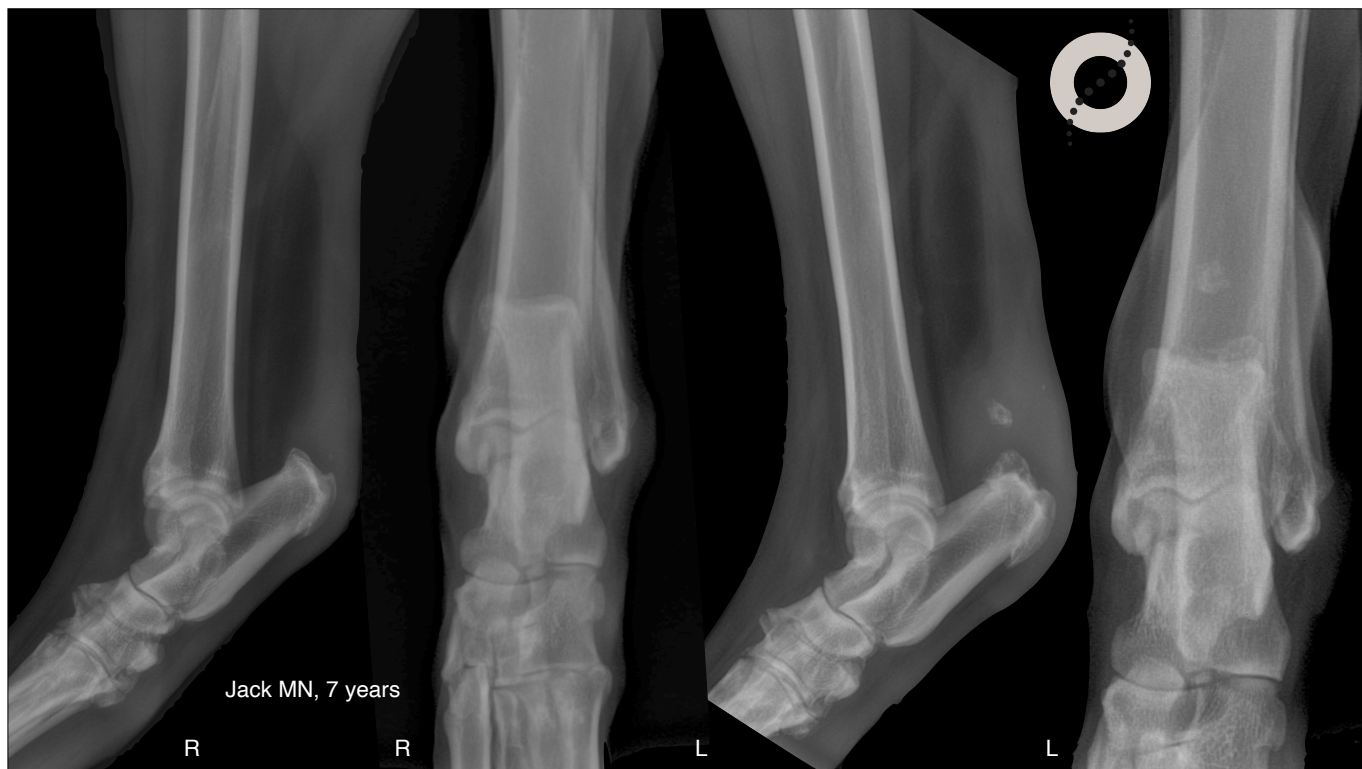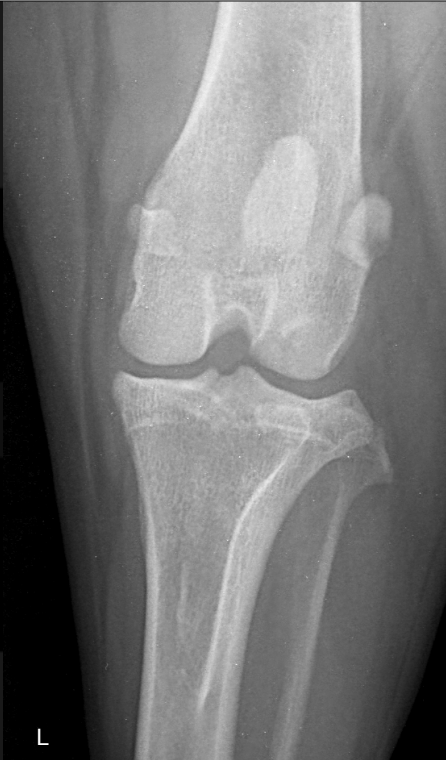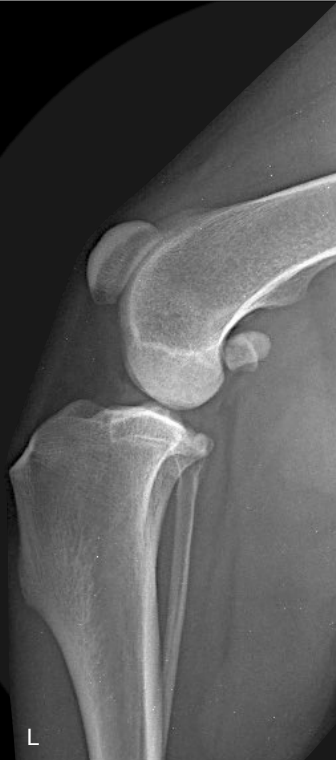Jack MN, 7 years



Jack MN, 7 years



Jack MN, 7 years



Jack MN, 7 years

R

R

L

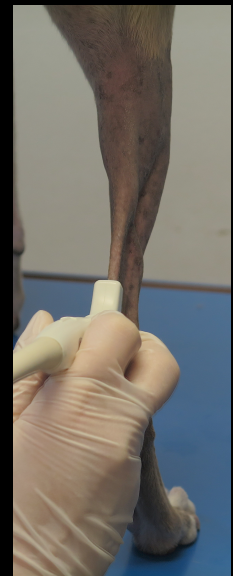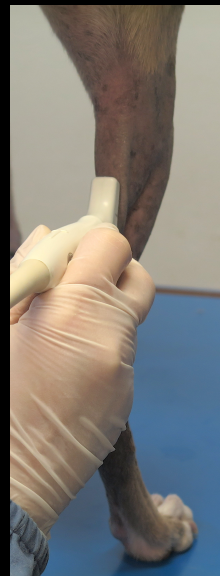L

## Jack, Doberman, MN, 7 years

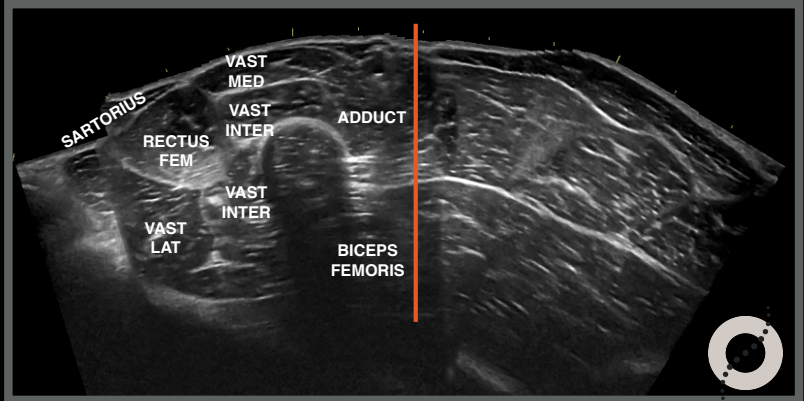
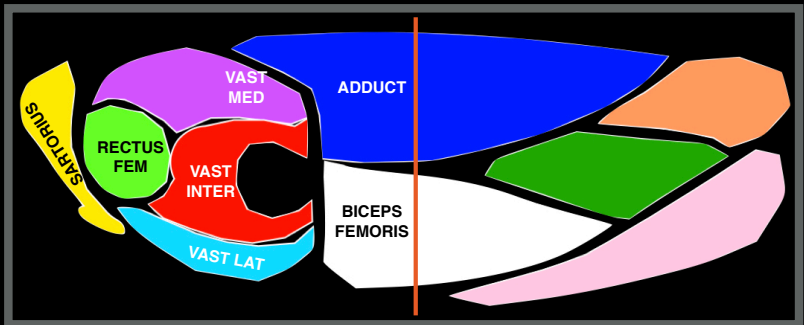
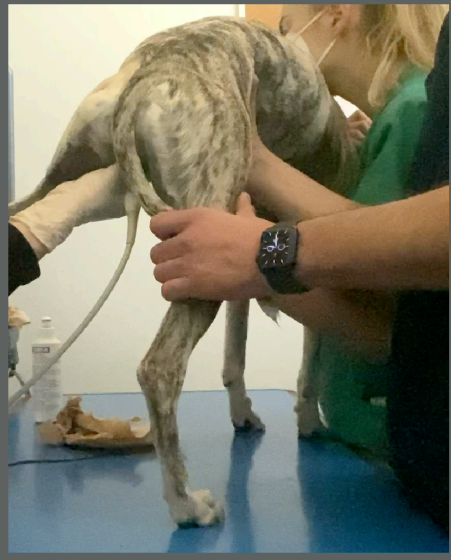- Possible chronic, bilateral iliopsoas injury
- Chronic Achille's tendon injury



## Ultrasonographic technique



**Cranial part of medial thigh**

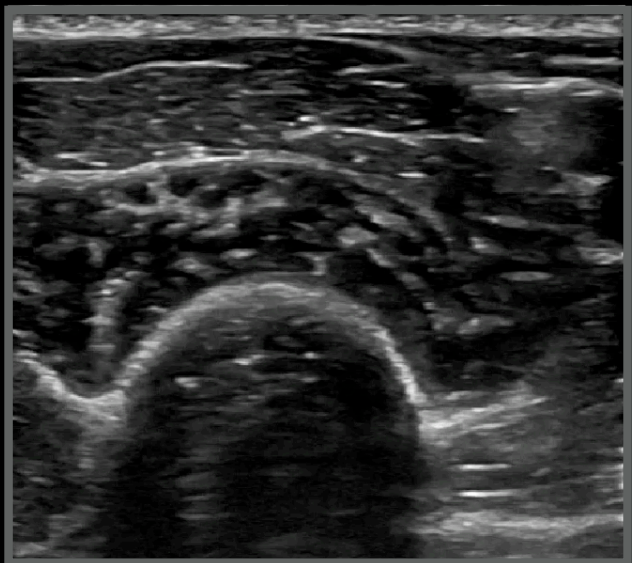
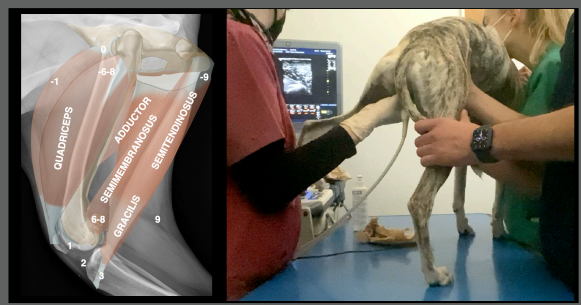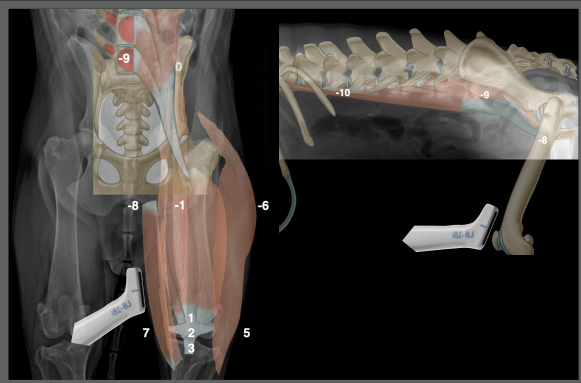


**Jack, MN, 7 years**

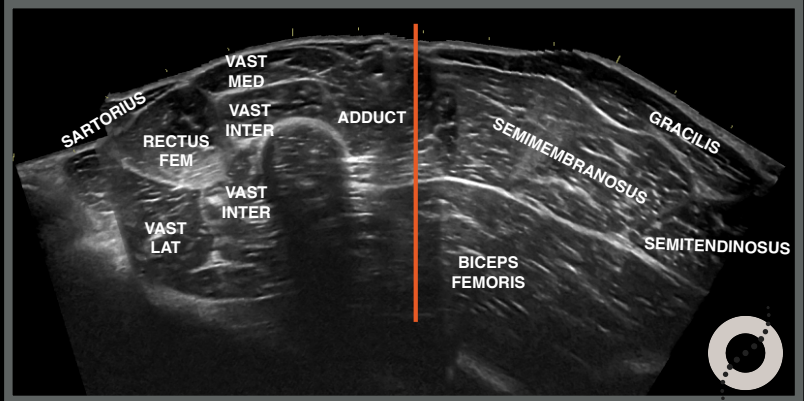
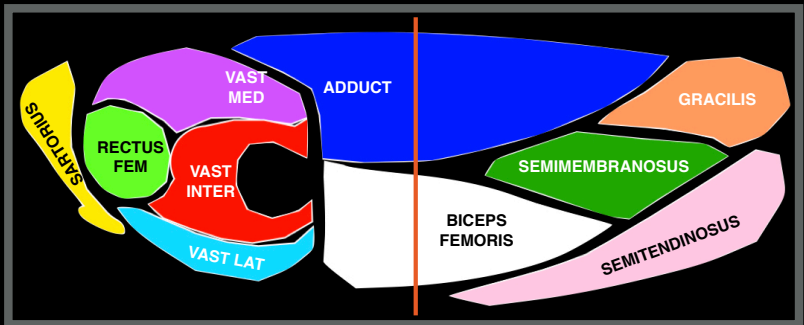
Left thigh

Medial face transverse scan

-8



### Caudal part of medial thigh



### Jack, Mn, 7 years

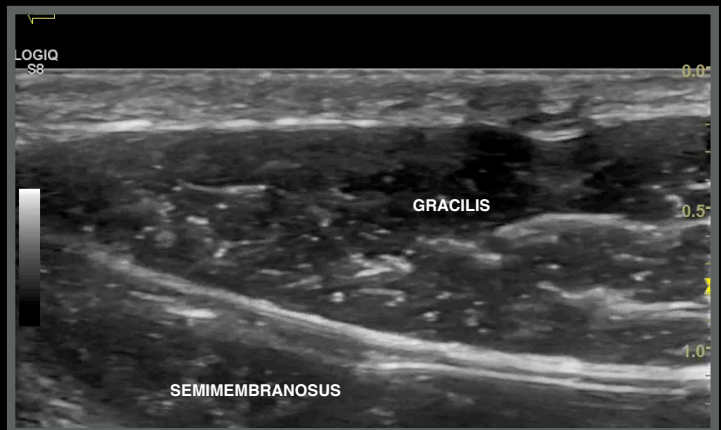
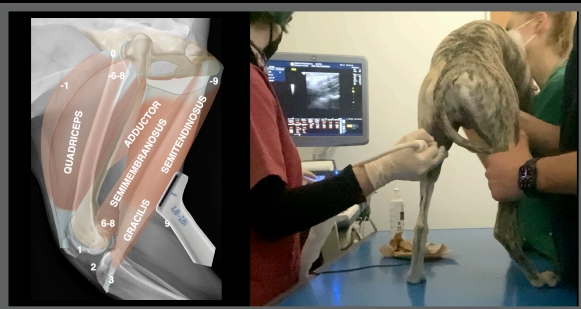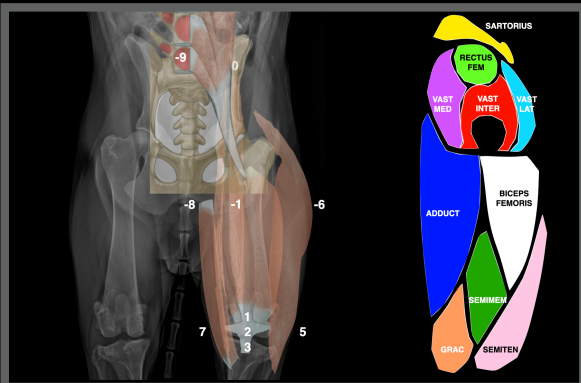
Right thigh

Sound limb



Caudal face longitudinal scan

-9-9



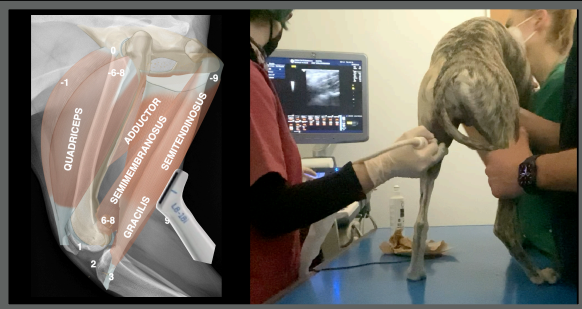
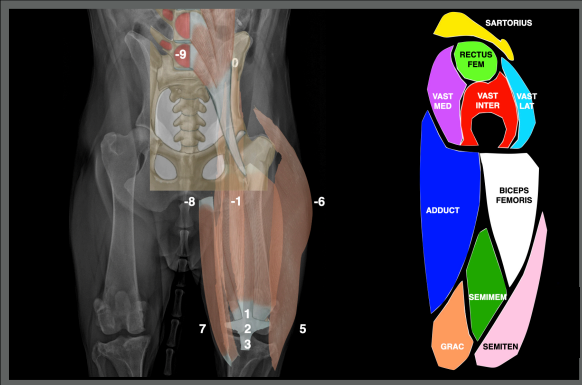
Jack, Mn, 7 years

Left thigh

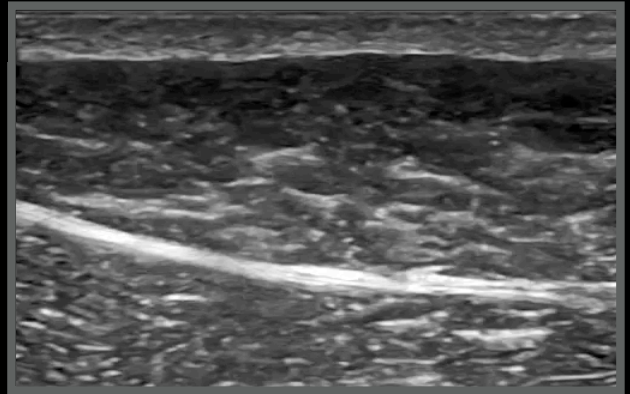
Affected limb



-9-9



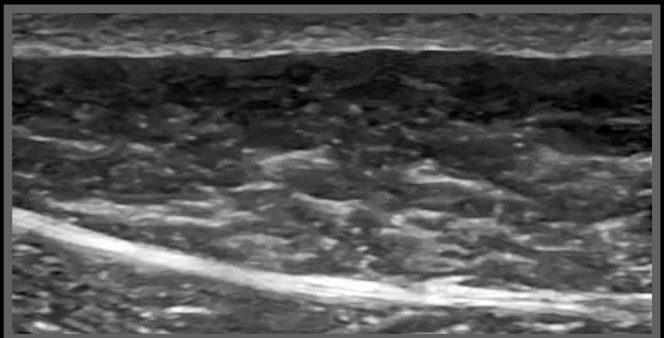
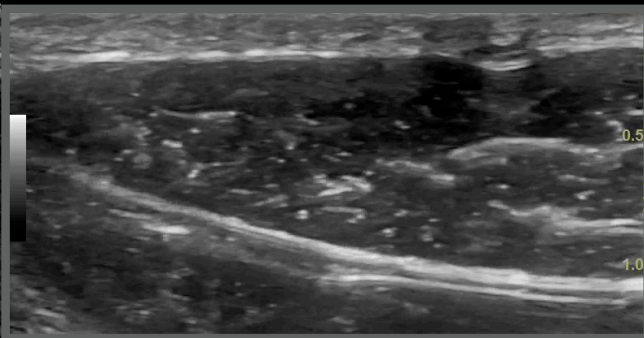
www.imaio.com



Jack, Doberman, MN, 7 years

Right gracilis

Left gracilis



## How to arrive at Conclusions:

- PE examination
- Blood works
- Xray and Ultrasonographic findings
- Literature



PubMed®

gracilis miopathy canine

Search

[Advanced](#) [Create alert](#) [Create RSS](#)

[User Guide](#)

[Save](#) [Email](#) [Send to](#)

Sorted by: Best match

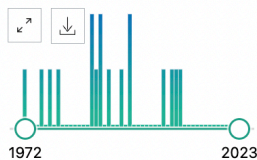
[Display options](#) ⚙️

MY NCBI FILTERS [🔗](#)

17 results

⏪ < Page 1 of 2 > ⏩

RESULTS BY YEAR



TEXT AVAILABILITY

- Abstract
- Free full text
- Full text

ARTICLE ATTRIBUTE

- Associated data

ARTICLE TYPE

Showing results for *gracilis myopathy canine*

Your search for *gracilis miopathy canine* retrieved no results

**Gracilis or semitendinosus myopathy in 18 dogs.**

1 Lewis DD, Shelton GD, Piras A, Dee JF, Robins GM, Herron AJ, Fries C, Ginn PE, Hulse DA, Simpson DL, Allen DA.

Cite J Am Anim Hosp Assoc. 1997 Mar-Apr;33(2):177-88. doi: 10.5326/15473317-33-2-177.

Share PMID: 9111730

The clinical findings in 18 **dogs** with **gracilis** (n = 17) or semitendinosus (n = 1) **myopathy** are described. ...Medical management prior to or in lieu of surgery was attempted (n = 8) with no apparent response. Fifteen **dogs** had one or multiple surgical pr ...

**Hypophosphatemia and rhabdomyolysis.**

2 Knochel JP, Barcenas C, Cotton JR, Fuller TJ, Haller R, Carter NW.

Cite J Clin Invest. 1978 Dec;62(6):1240-6. doi: 10.1172/JCI109244.

Share PMID: 748377 **Free PMC article.**

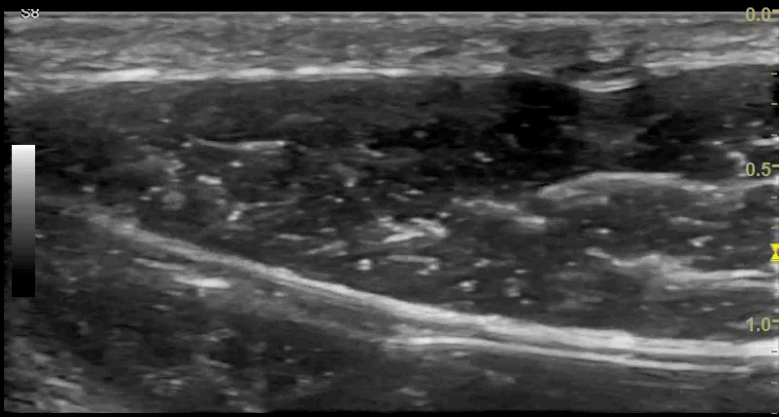
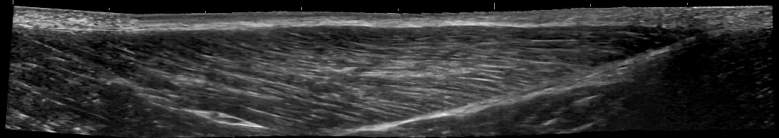
**Muscle** Na and Cl contents became higher (P <0.01). Sections of **gracilis muscle** showed frank rhabdomyolysis.6 of the 23 phosphorus- and calorie-deprived **dogs** were also given 140 kal/kg per day but in addition, each received 147 mmol of elemental phos ...



## Normal ultrasound of the gracilis muscle

www.diagnosticmindset.com

“Normal” walking



## Early phase of gracilis myopathy

www.diagnosticmindset.com

Left hind limb affected

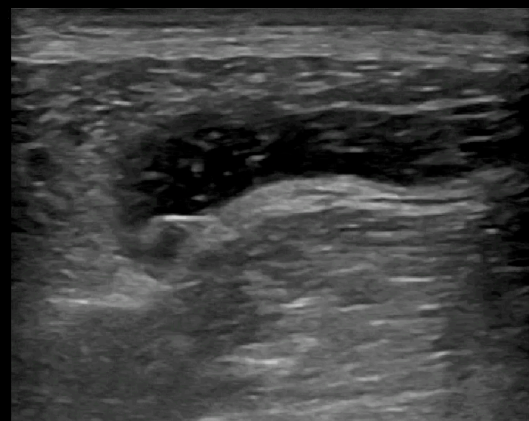
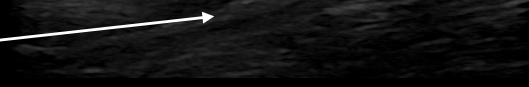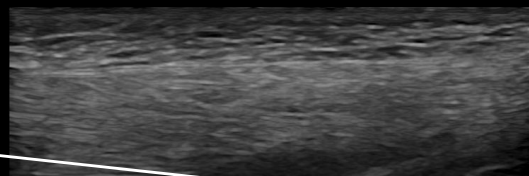


Hypochoic area with decreased fibrillar pattern

Irregularly thickened fascia

Often associated with mild muscle atrophy

Scattering artifact not present



## Middle phase of gracilis myopathy

www.diagnosticmindset.com

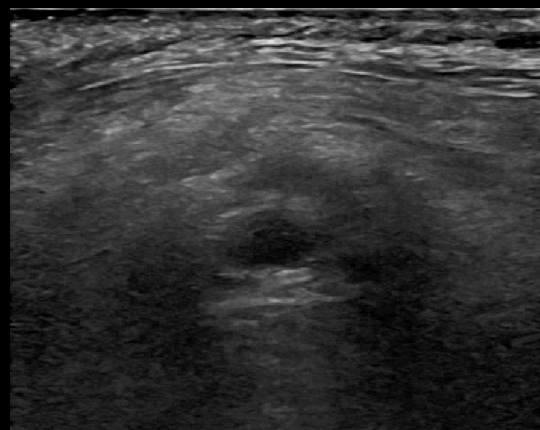
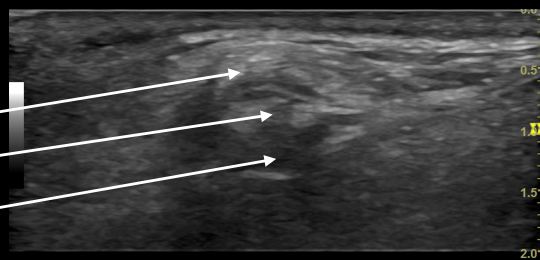


Left hind limb affected

Scattering artifact

Nodular like lesion

Not homogeneous echostructure



## Late phase of gracilis myopathy

www.diagnosticmindset.com

Left hind limb affected

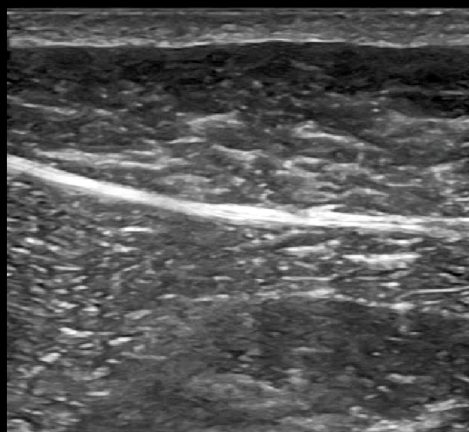
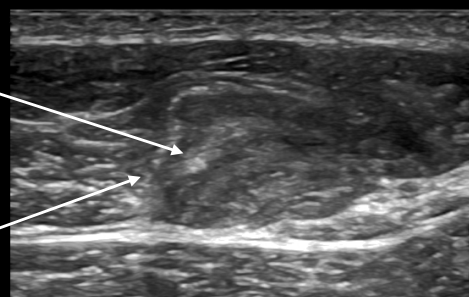
Well-defined  
echoic line-spots

No scattering  
artefacts

Well-defined  
margins

No signs of  
inflammation

Muscle fibrosis



Jack, Doberman, MN, 7 years

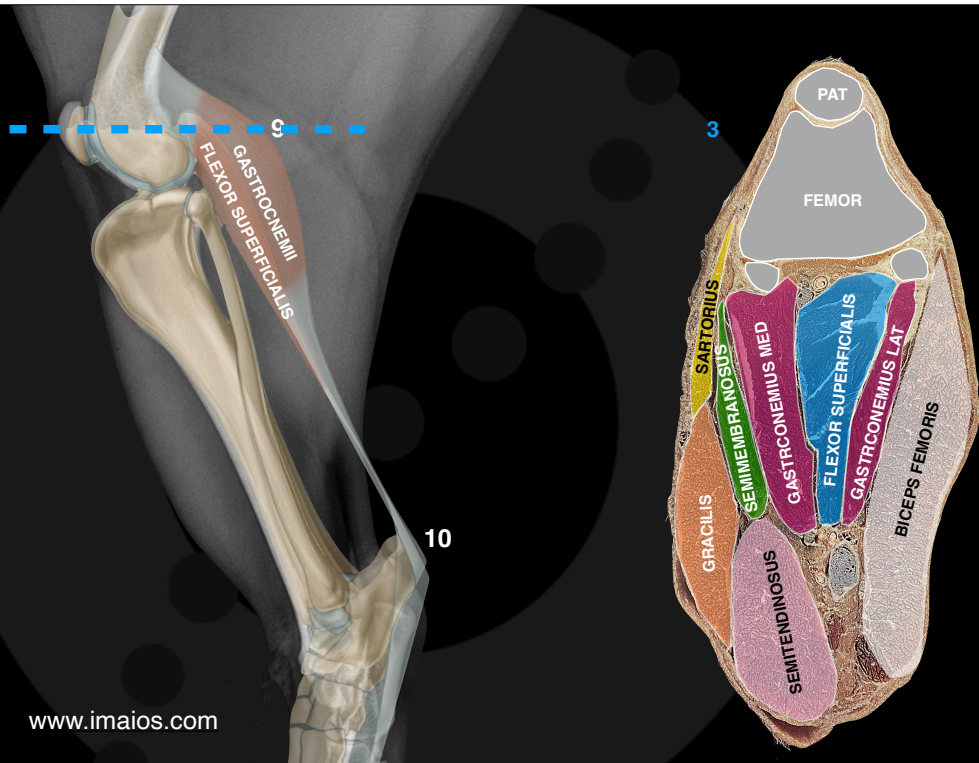
Ultrasonographic diagnoses:

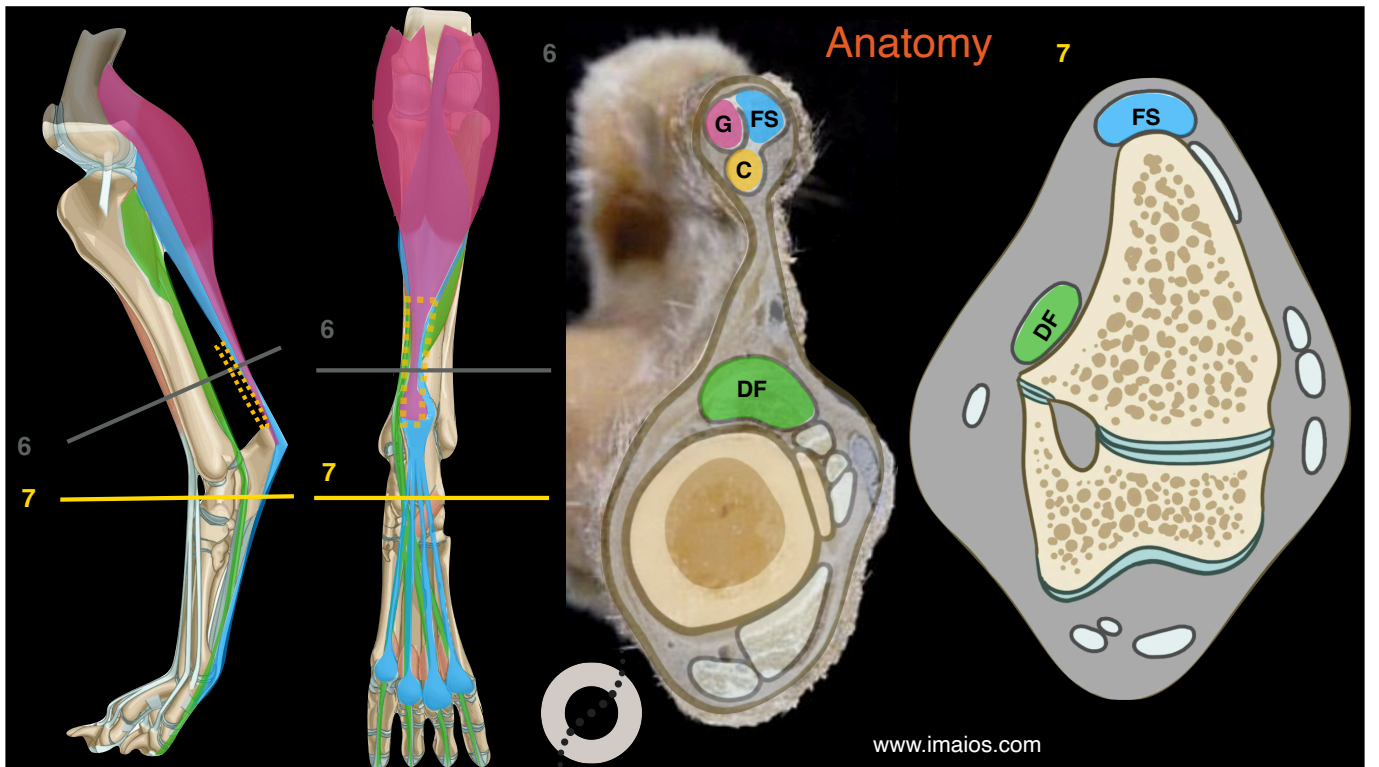
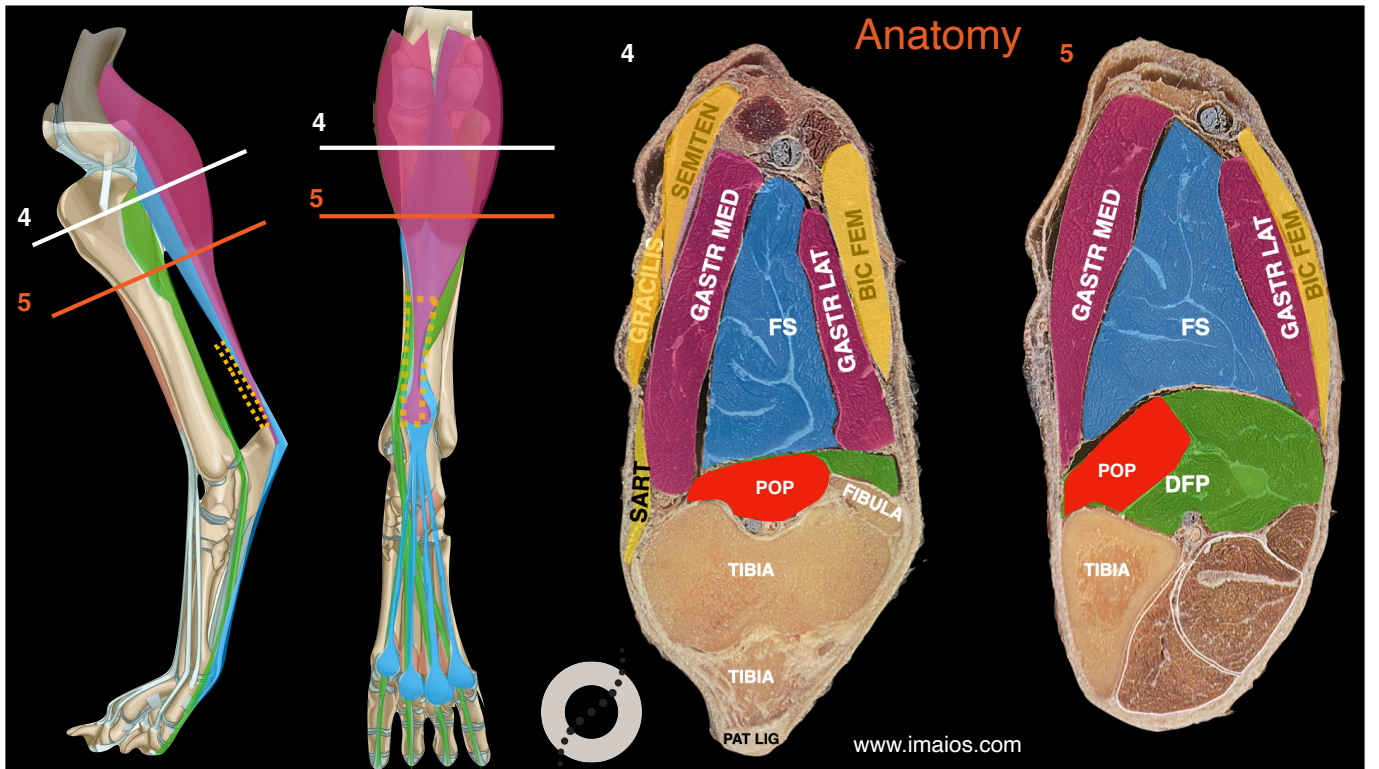
- Second degree left gracilis myopathy



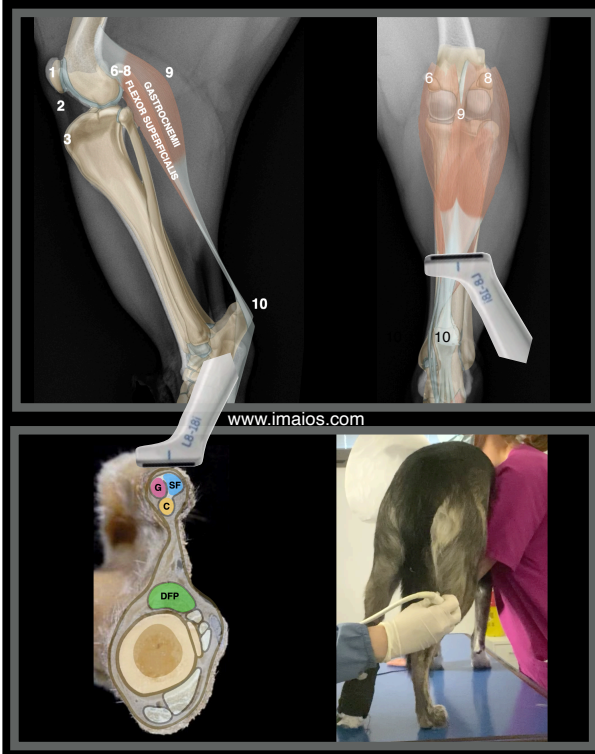
Have we finish?

Achille's tendon







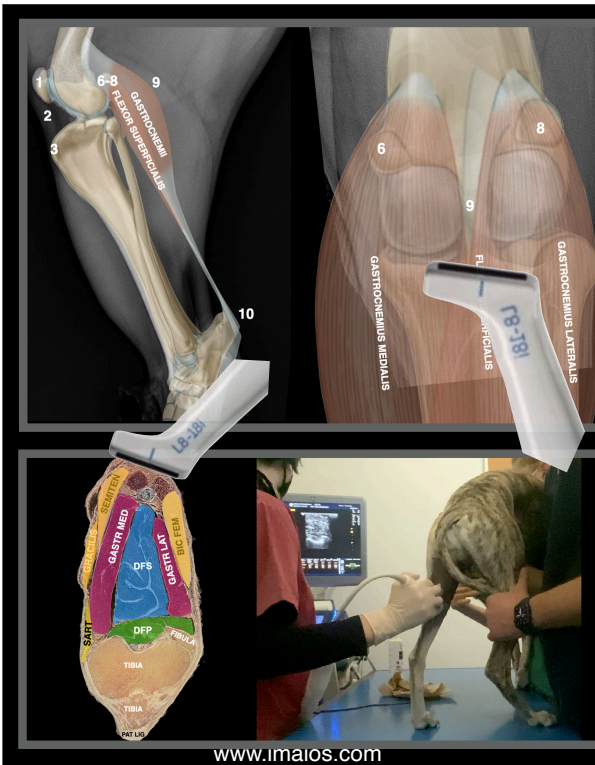
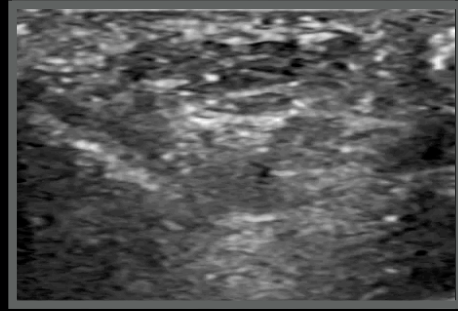


Jack, MN, 7 years

Right leg  
Sound limb



Caudal face transverse scan 9-10

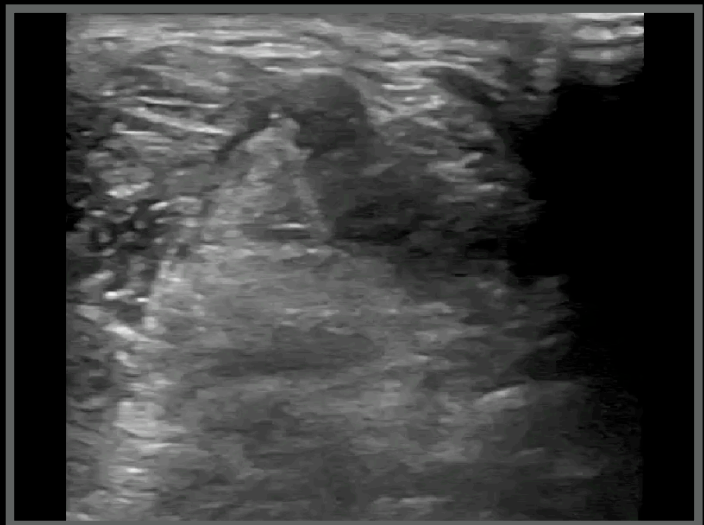


Jack, MN, 7 years

Left stifle

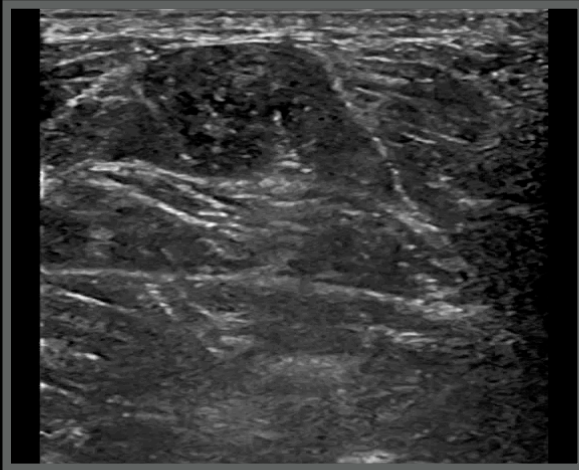


Caudal face transverse scan 9

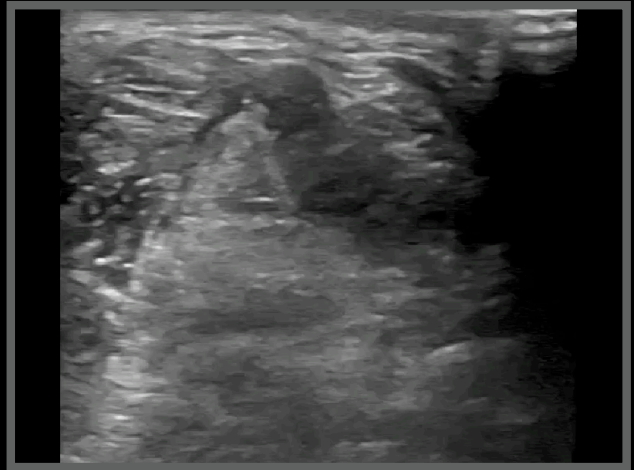


# Jack, Doberman, MN, 7 years

Right



Left



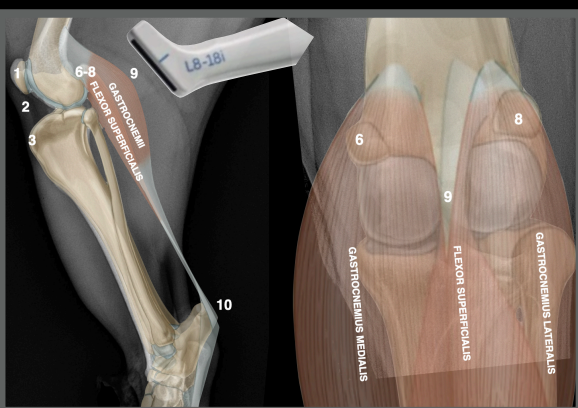
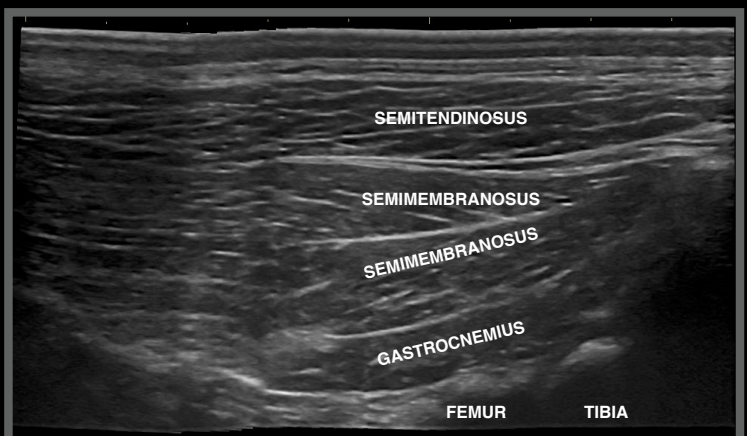
## Jack, MN, 7 years

Right stifle

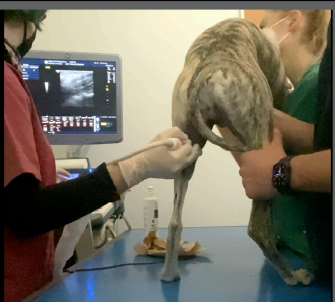
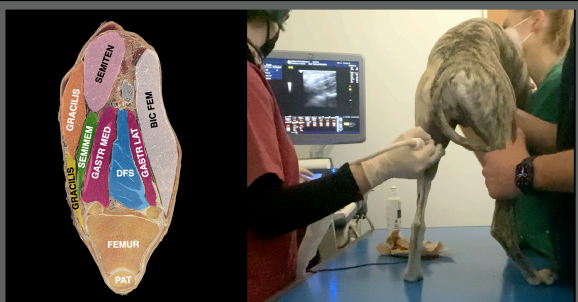
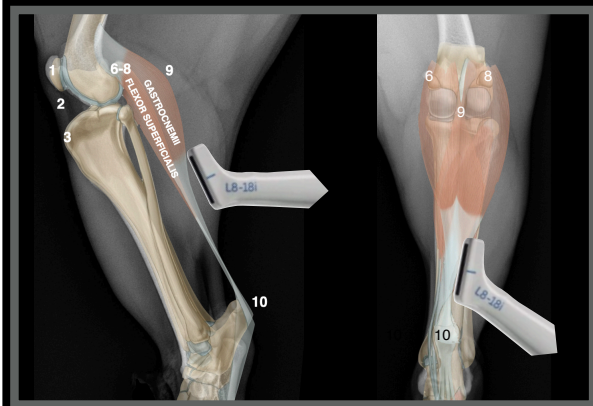
Caudal face longitudinal scan

9

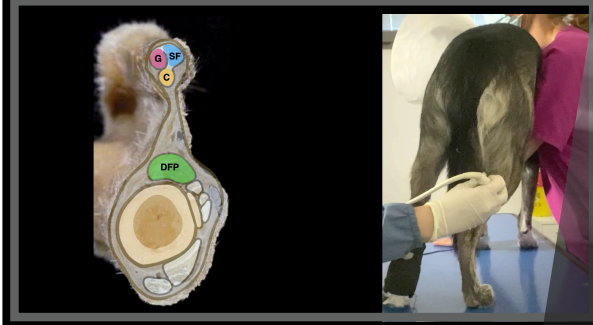


www.imaios.com





www.imaio.com




Jack, MN, 7 years

Right hock



Caudal face longitudinal scan

9-10

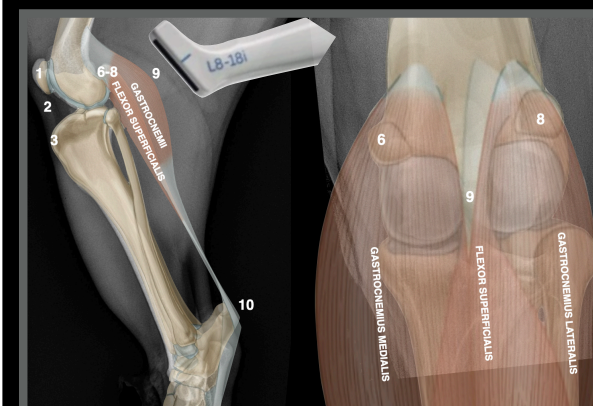


Jack, MN, 7 years

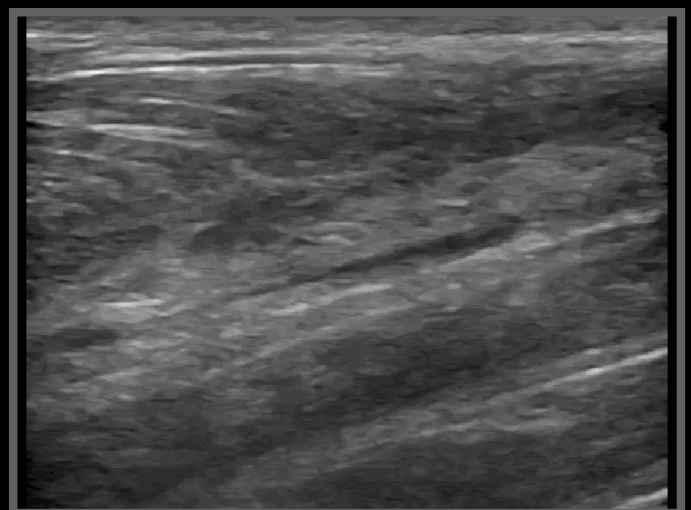
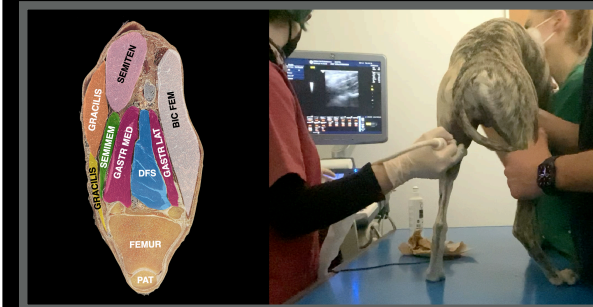
Left stifle

Caudal face longitudinal scan

9



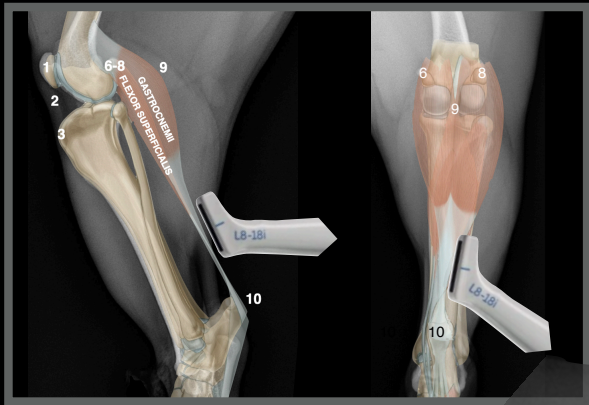
www.imaio.com



Jack, MN, 7 years

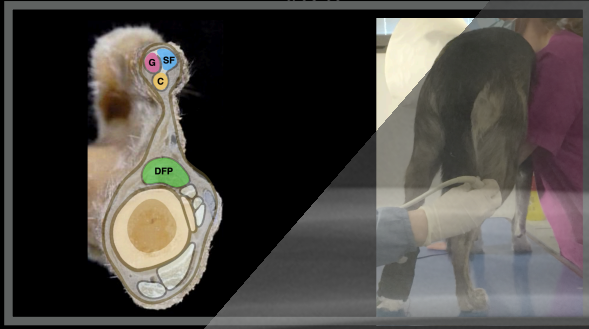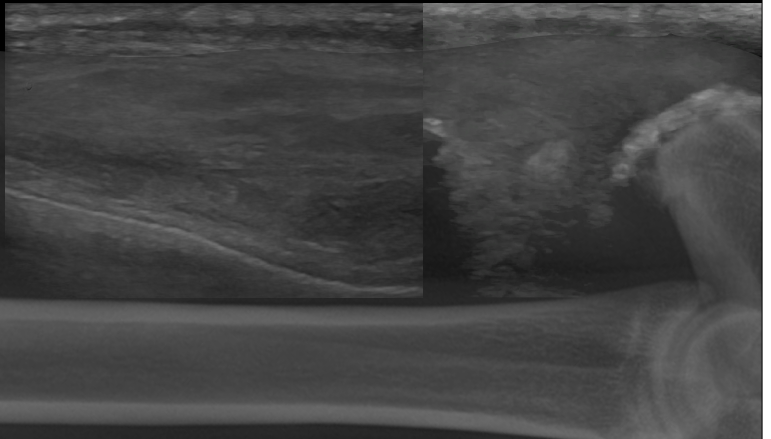


Left hock



www.imaios.com

Caudal face longitudinal scan 10



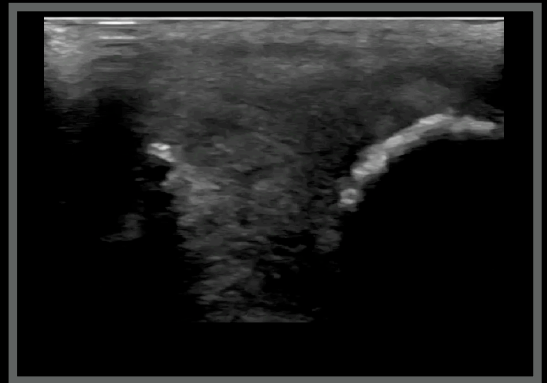
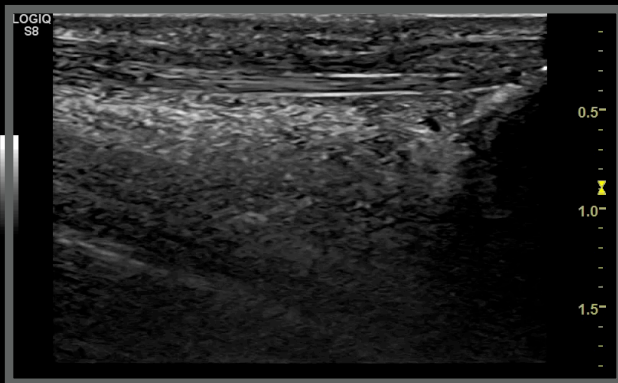
Jack, Doberman, MN, 7 years



Caudal face longitudinal scan 10

Right hock

Left hock



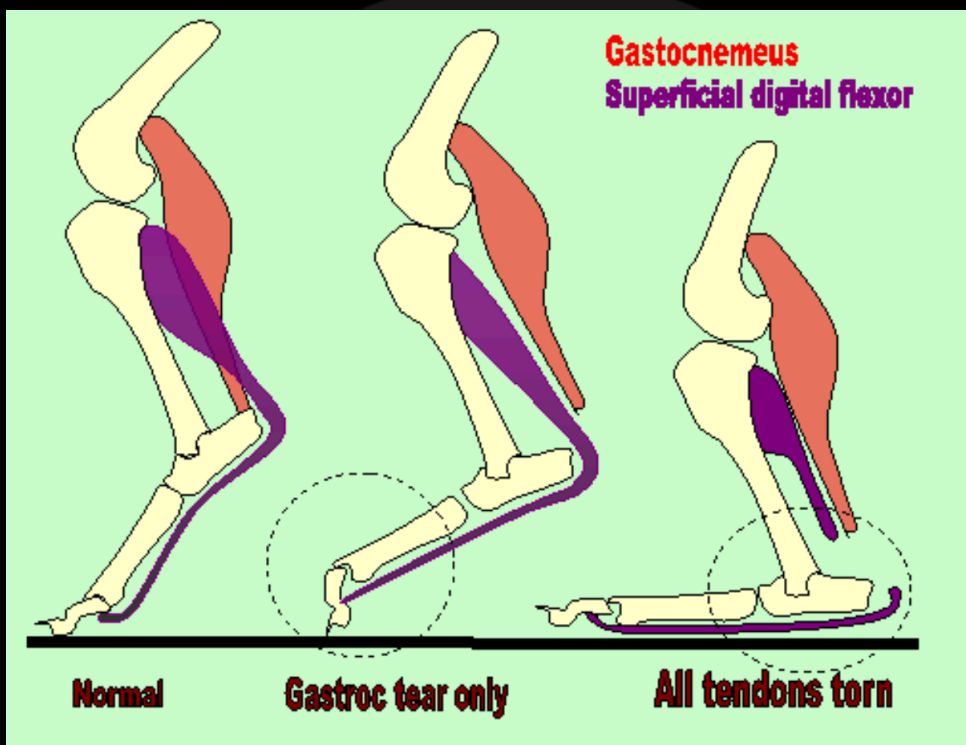
Jack, Doberman, MN, 7 years

Ultrasonographic diagnoses:

- Left-sided middle phase gracilis myopathy
- Severe third-degree chronic tendinopathy left Achille's tendon



What next?



## Jack, Doberman, MN, 7 years

### Follow up

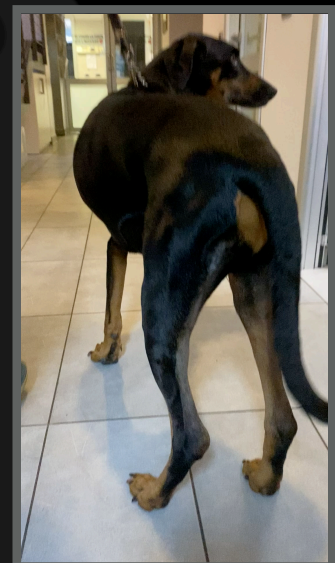
- Physiotherapy:
  1. Stop the progression of gracilis myopathy
  2. Reestablish competence of left gastrocnemius muscle



## Jack, Doberman, MN, 7 years

Three months later

- Much better for the last month
- Two treatment each week



# Jack, Doberman, MN, 7 years

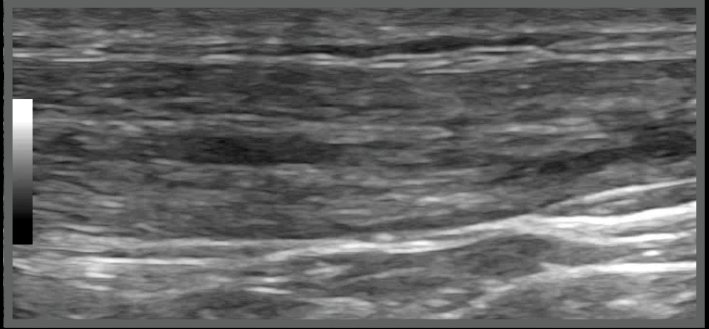
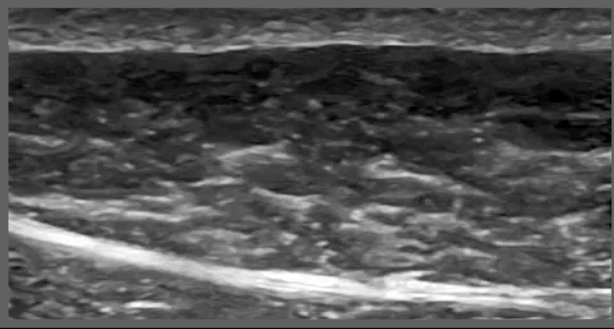
Caudal face longitudinal scan -9-9

Left gracilis

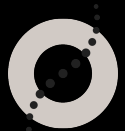
Time 0

Left gracilis

Three months later



# Jack, Doberman, MN, 7 years



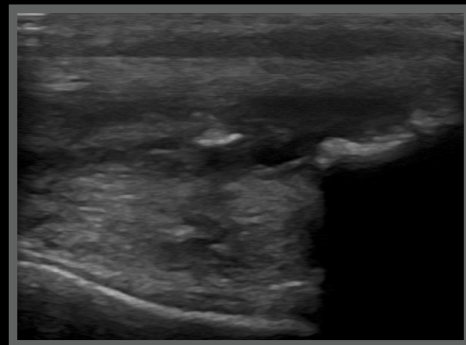
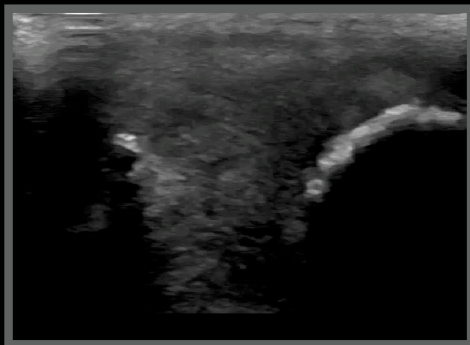
Caudal face longitudinal scan 10

Left hock

Time 0

Left hock

Three months later



## Conclusions



## Conclusions

- We cannot use ultrasound to diagnose early hp displasia in dogs
- A simplified anatomy makes the thigh and Achille's tendon fun!



Thank you



Diagnostic Mindset

[www.diagnosticmindset.com](http://www.diagnosticmindset.com)