

# The ultrasound examination of the hindlimb extremities

Giliola Spattini  
DVM, GP Cardio, CCRT, PhD, DECVDI



Diagnostic Mindset



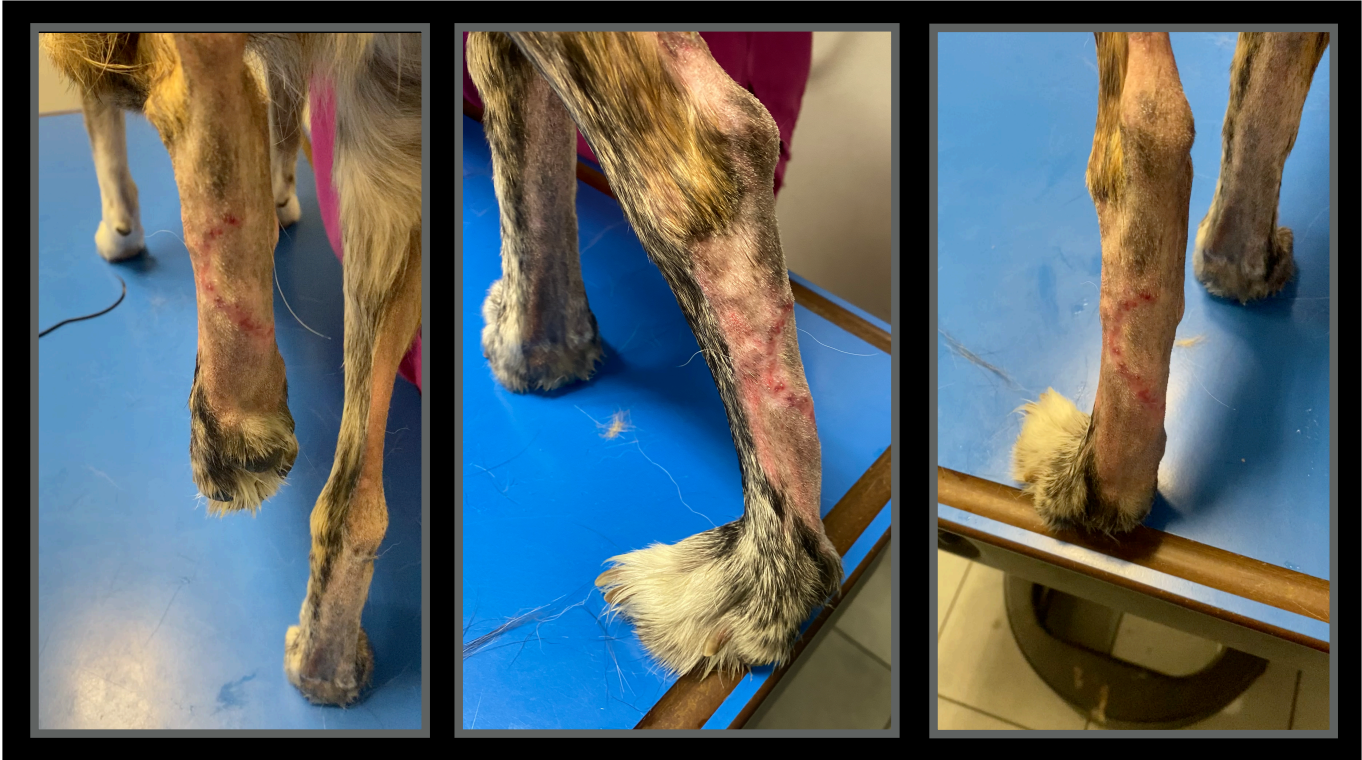Thank to [www.imaios.com](http://www.imaios.com)

## Barattolo, Mongrel, MI, 2 years

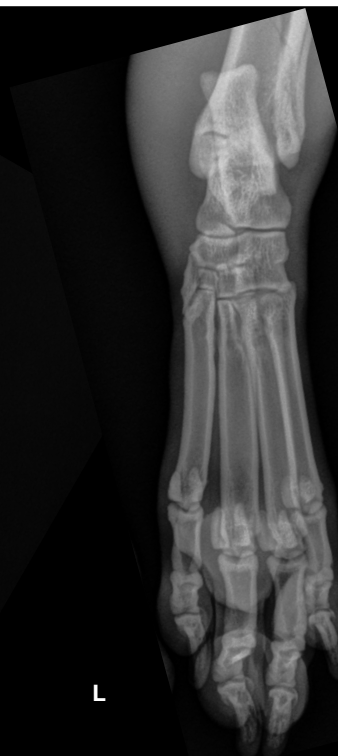
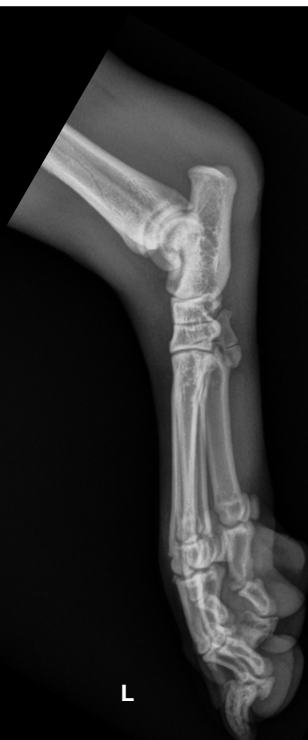
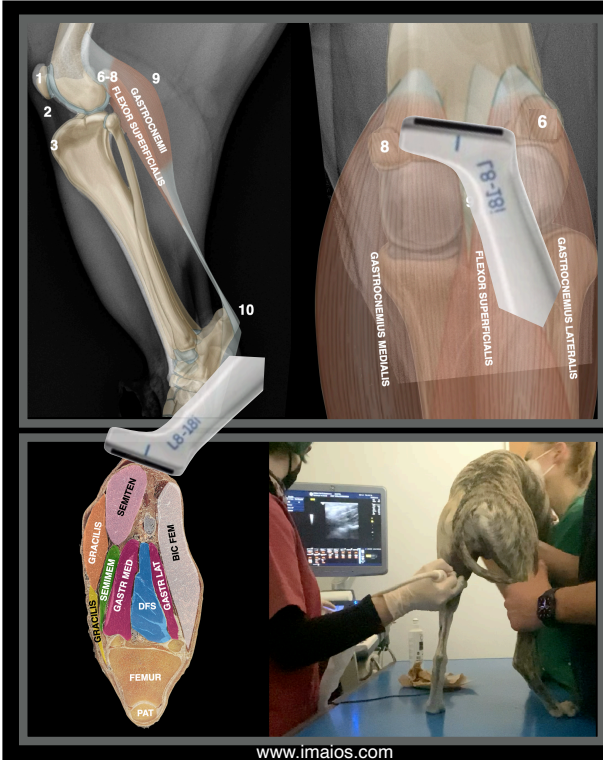
- He steps on a broken bottle
- Surgical repair of a deep cut left-metatarsal side
- Severe swelling of the left tarsus and paw at the time of trauma
- Still lame after two weeks





Barattolo, MI, 2 years





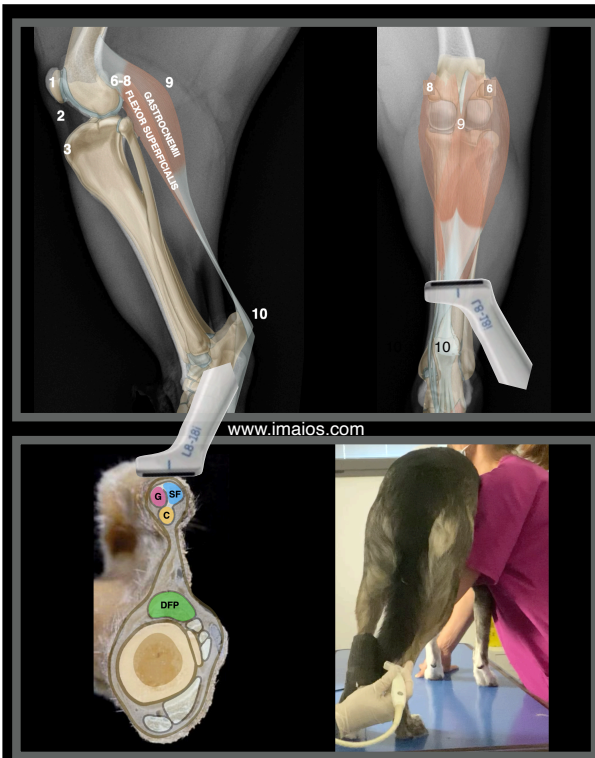
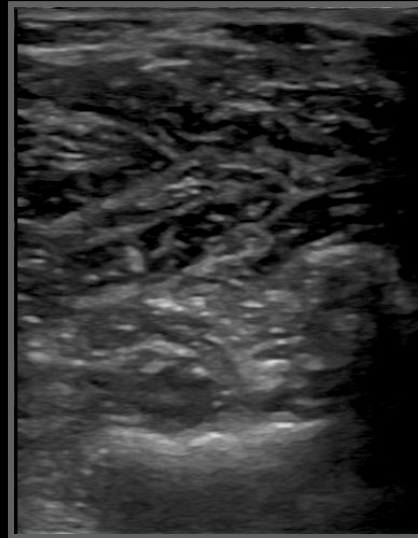
www.imaios.com

**Barattolo, MI, 2 years**

Left stifle

Affected limb

Caudal face transverse scan 9



www.imaios.com

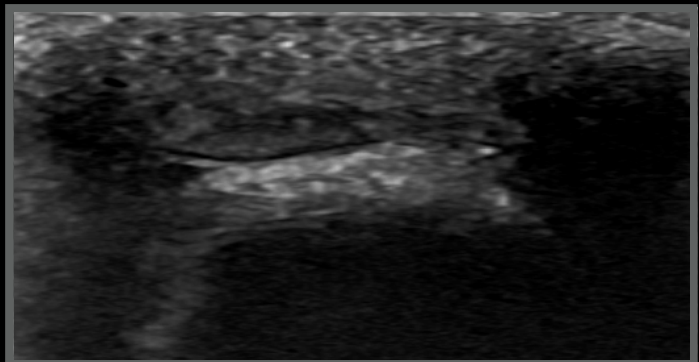
**Barattolo, MI, 2 years**

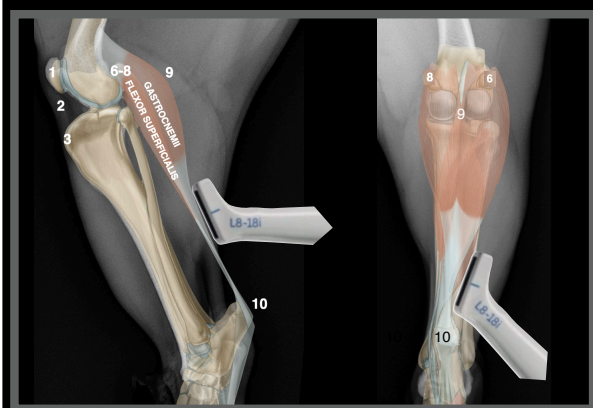
Left hock

Affected limb

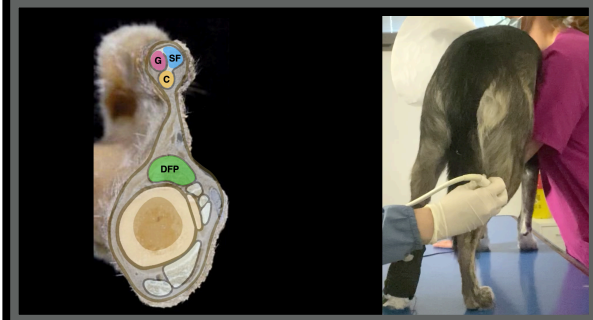
Caudal face transverse scan

10





www.imaios.com



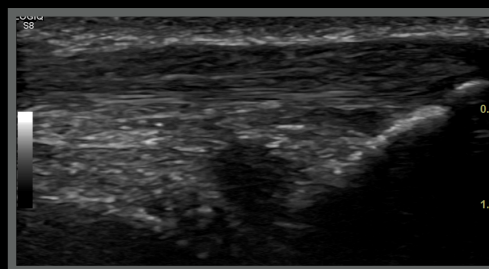
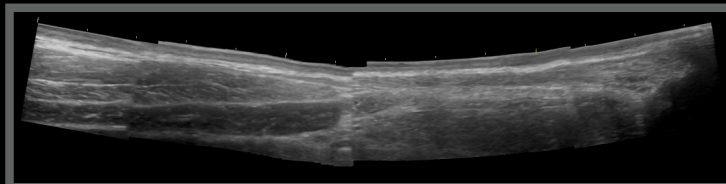
**Barattolo, MI, 2 years**

Left hock

Affected limb

Caudal face longitudinal scan

9-10



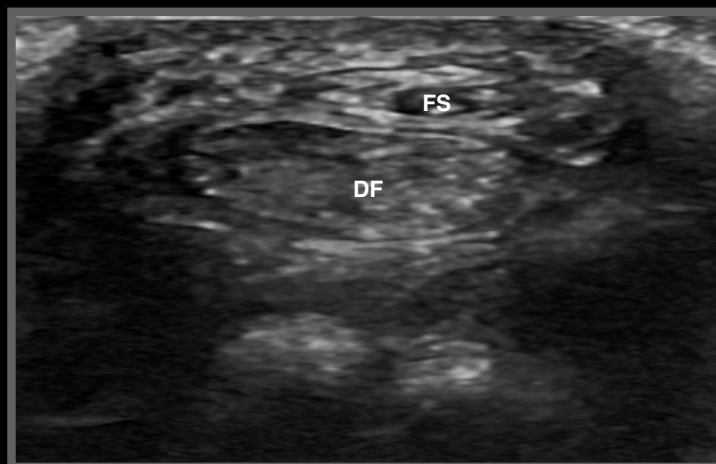
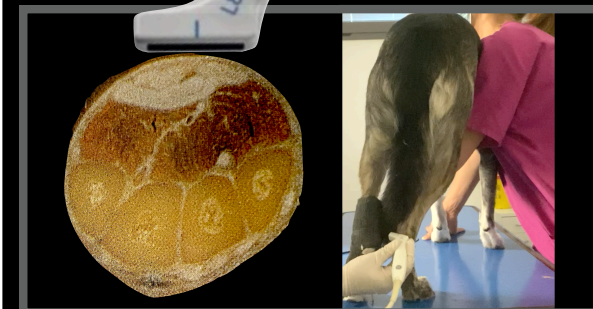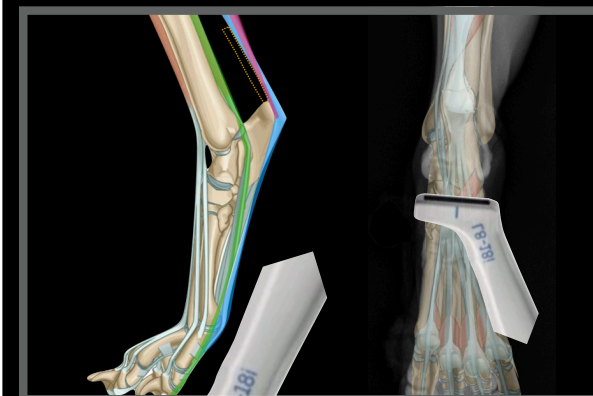
**Barattolo, MI, 2 years**

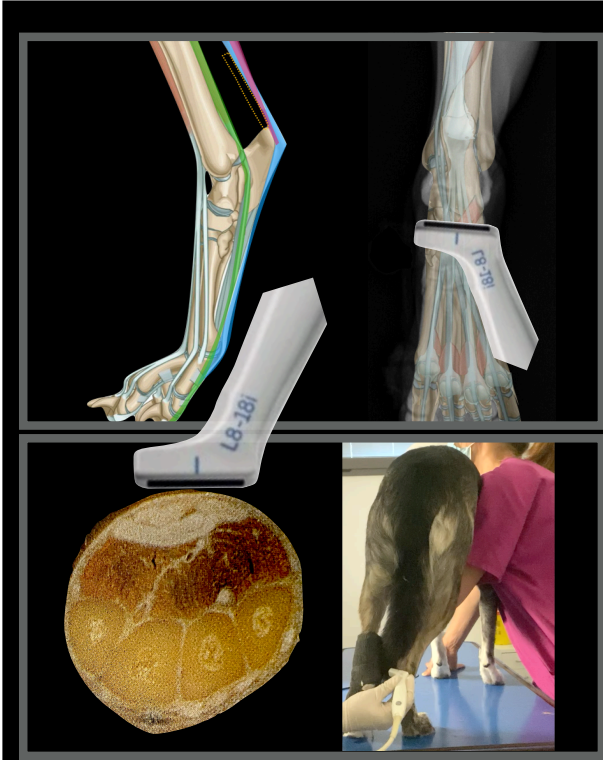Right paw

Sound limb

Caudal face transverse scan

10



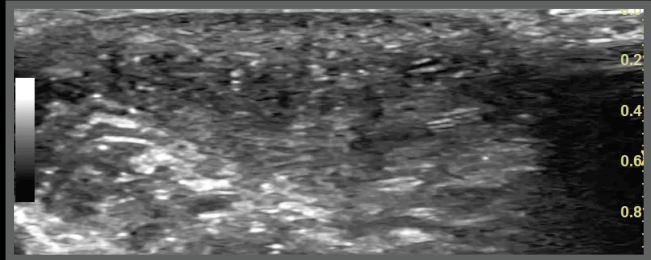


**Barattolo, MI, 2 years**

Left paw

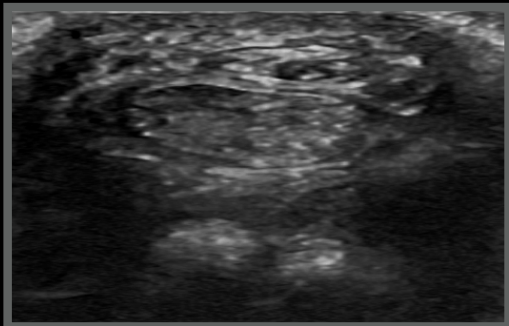
Affected limb

Caudal face transverse scan

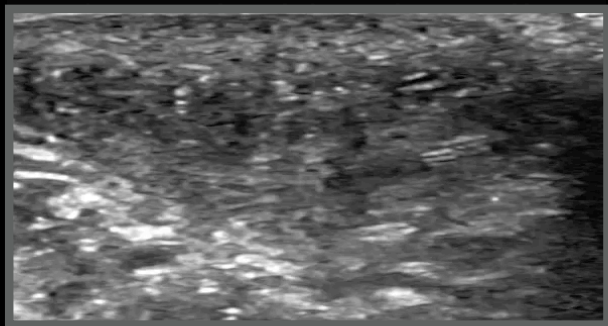


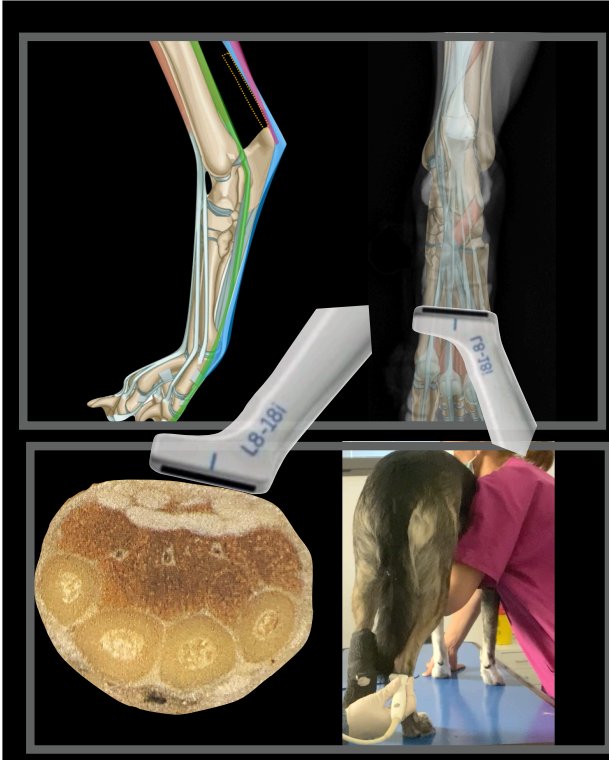**Barattolo, MI, 2 years**

Right paw



Left paw





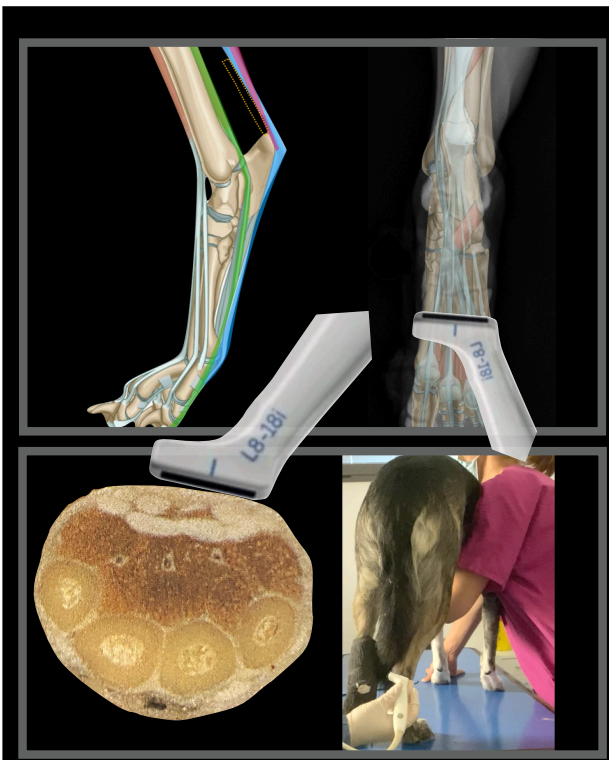
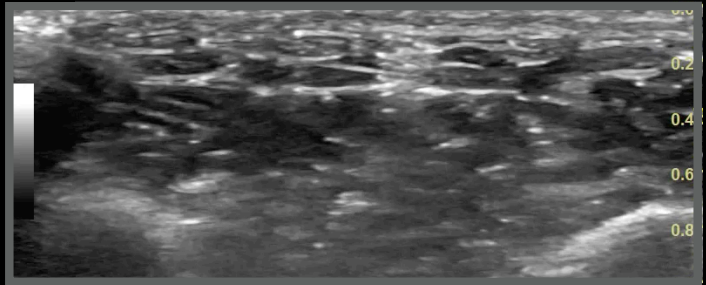
**Barattolo, MI, 2 years**

Right paw

Sound limb



Caudal face transverse scan



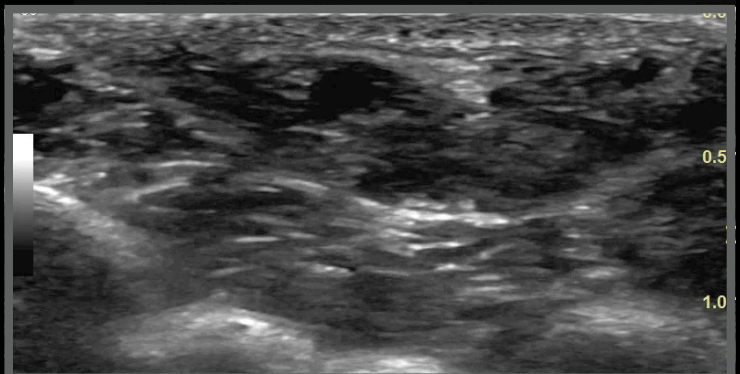
**Barattolo, MI, 2 years**

Left paw

Affected limb



Caudal face transverse scan



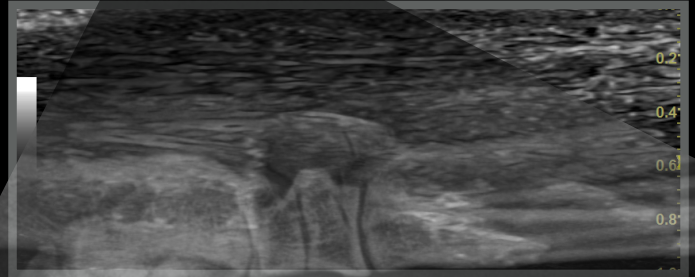
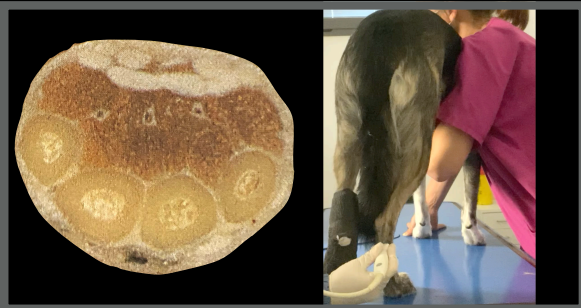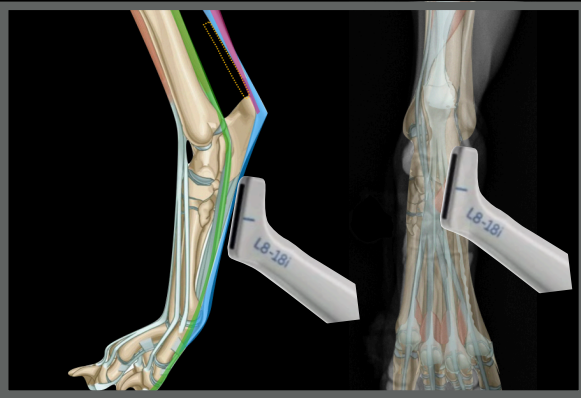


**Barattolo, MI, 2 years**

Right paw

Sound limb

Caudal face longitudinal scan



[www.imaios.com](http://www.imaios.com)

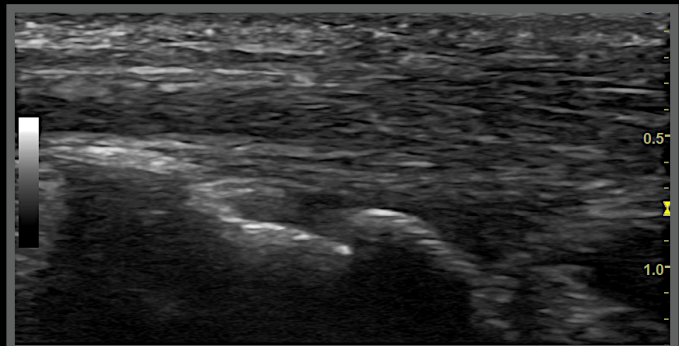
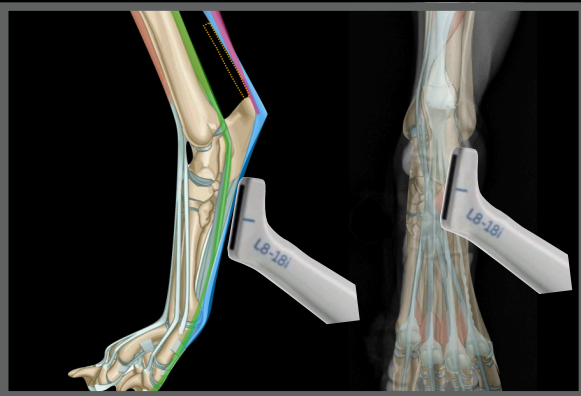


**Barattolo, MI, 2 years**

Left paw

Affected limb

Caudal face longitudinal scan



[www.imaios.com](http://www.imaios.com)

## Ultrasonographic diagnoses

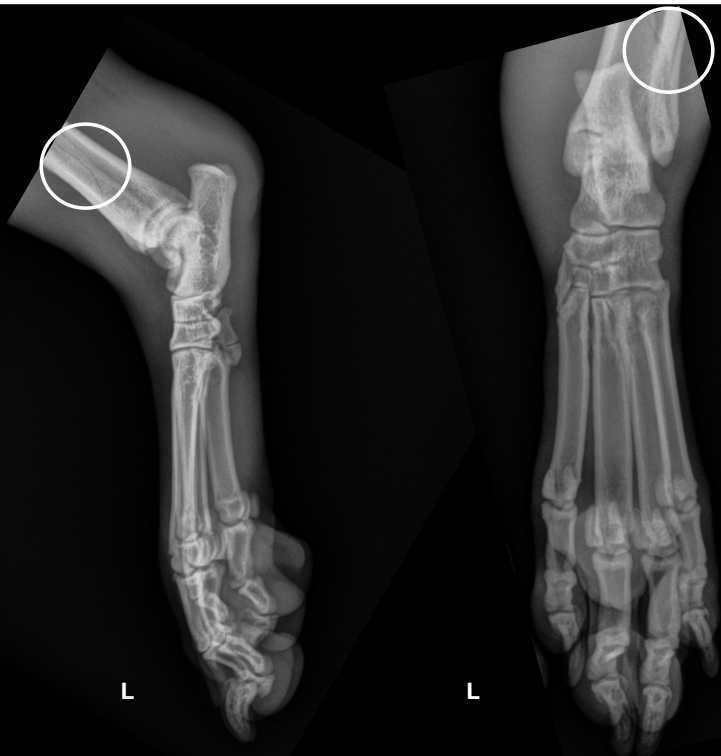- Minimal chronic tendonitis left Achille's tendon
- Healing suture of the left superficial and deep flexors tendons (no complications visible)



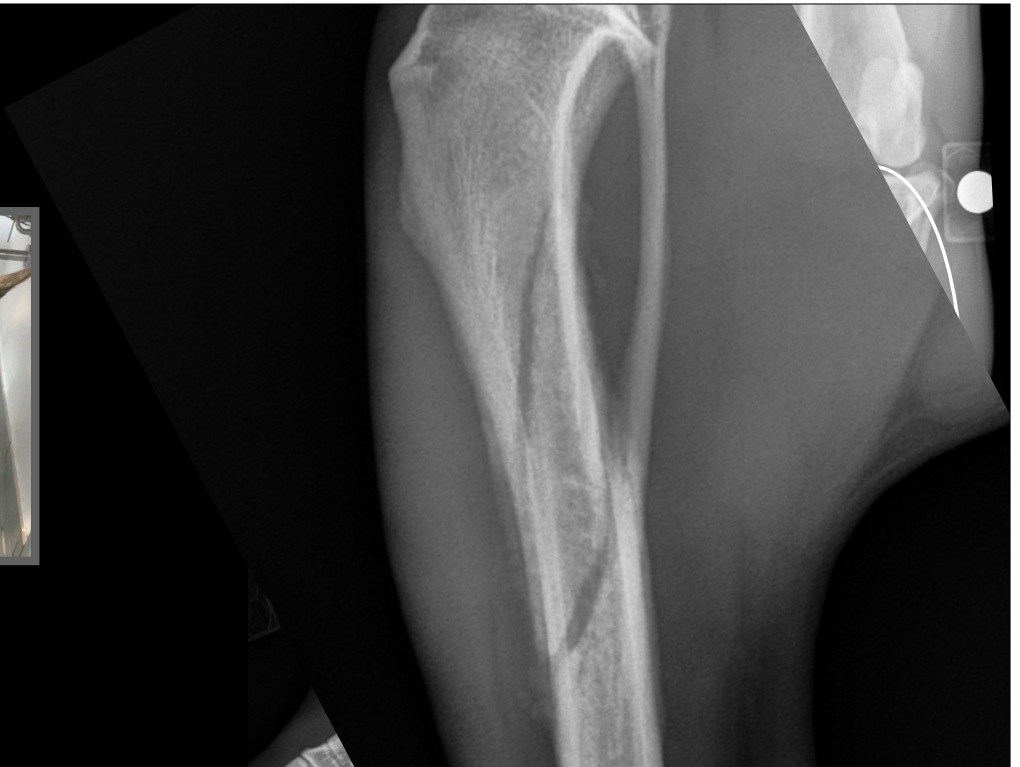
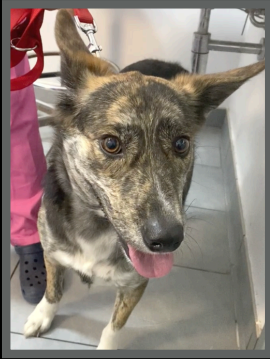## Next steps:

- Review the provided radiographs

Barattolo, MI, 2 years



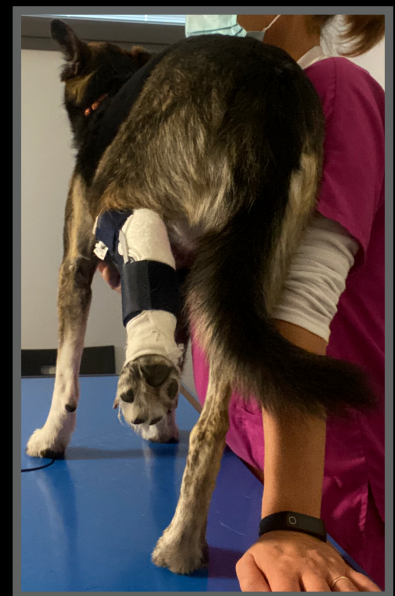Barattolo, MI, 2 years  
2 weeks later



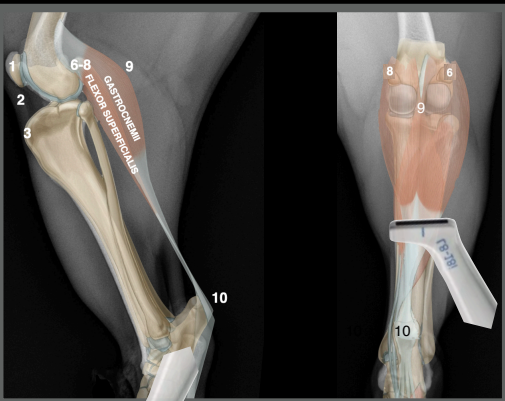
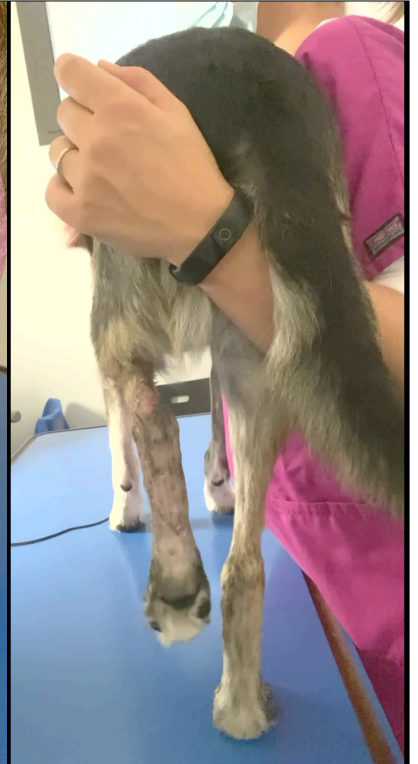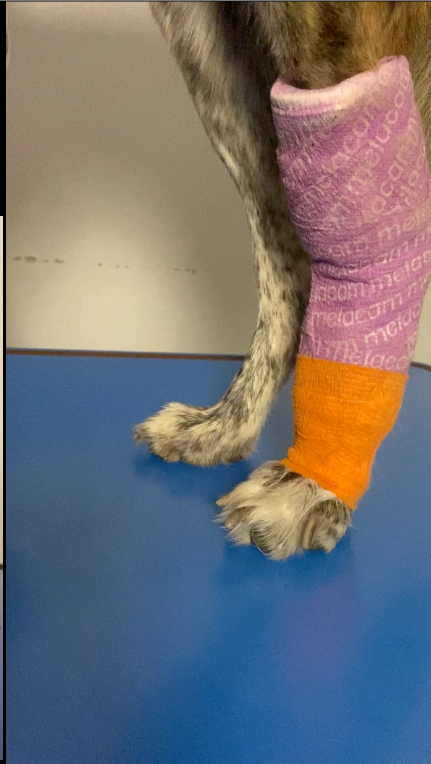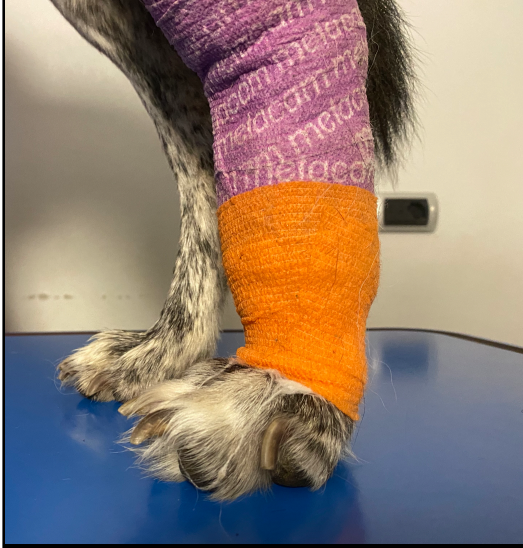## Barattolo, Mongrel, MI, 2 years

Two months later

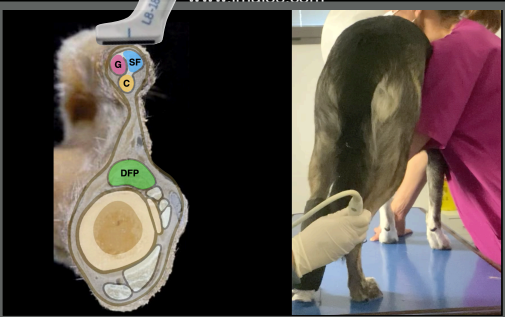
- He steps on a broken bottle deep cut surgically repaired
- He fractured the left tibia falling
- Conservative management of the fracture



Barattolo, MI, 2 years  
2 months later



www.imaio.com



### Barattolo, MI, 2 years

Two months later

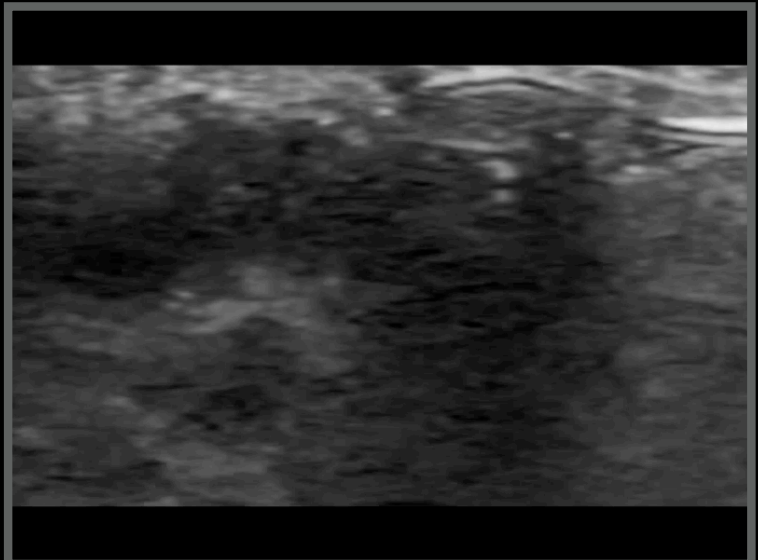
Right leg

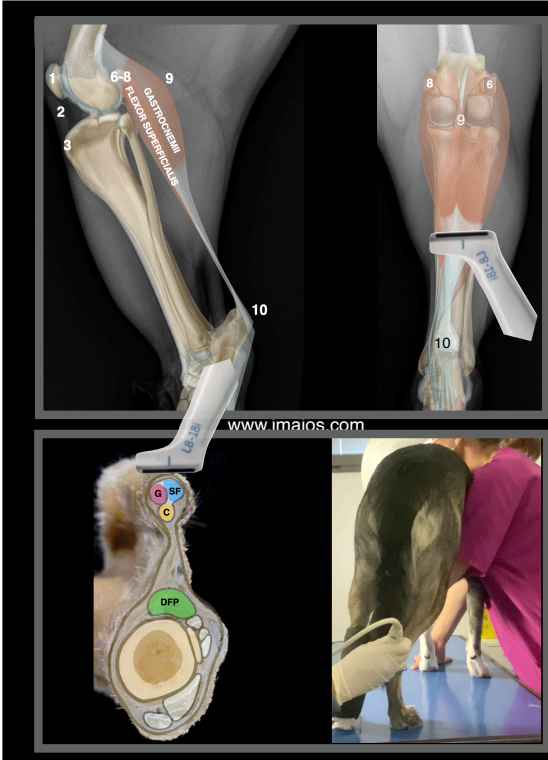
Sound limb

Caudal face transverse scan



10





**Barattolo, MI, 2 years**

Two months later

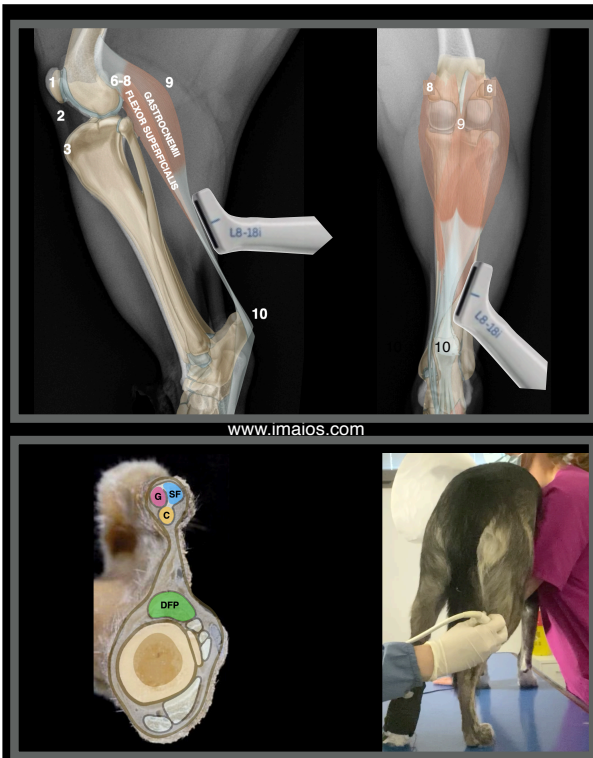
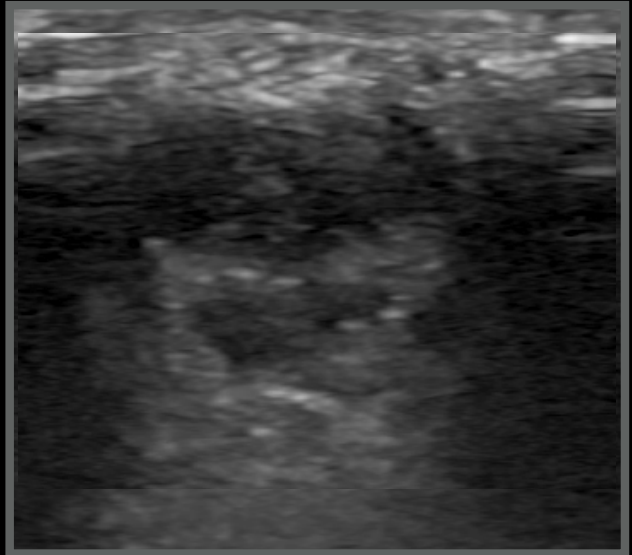
Left paw

Affected limb

Caudal face transverse scan



10

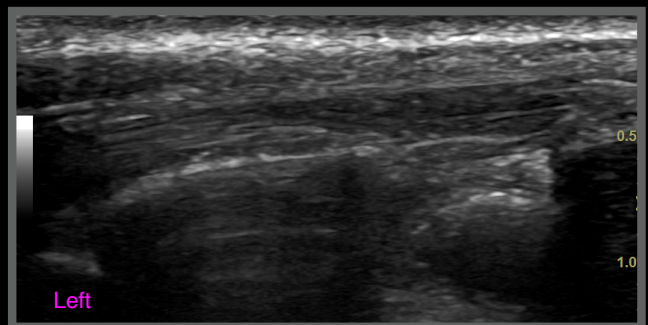
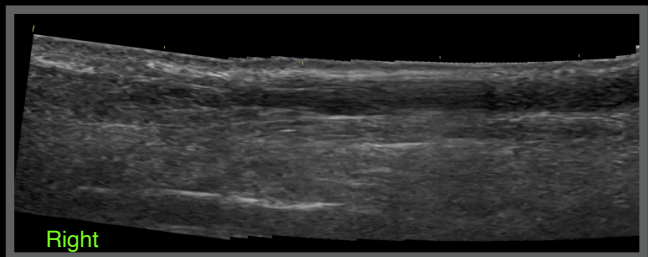


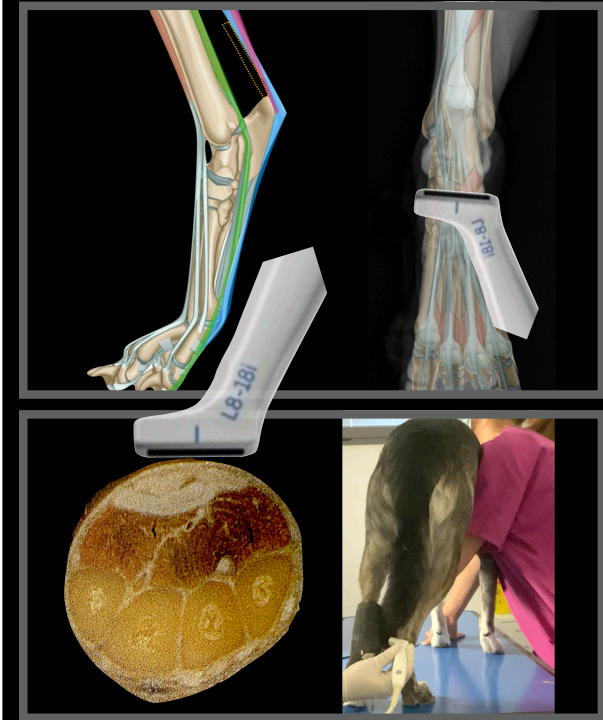
**Barattolo, MI, 2 years**

Two months later

Caudal face longitudinal scan

9-10



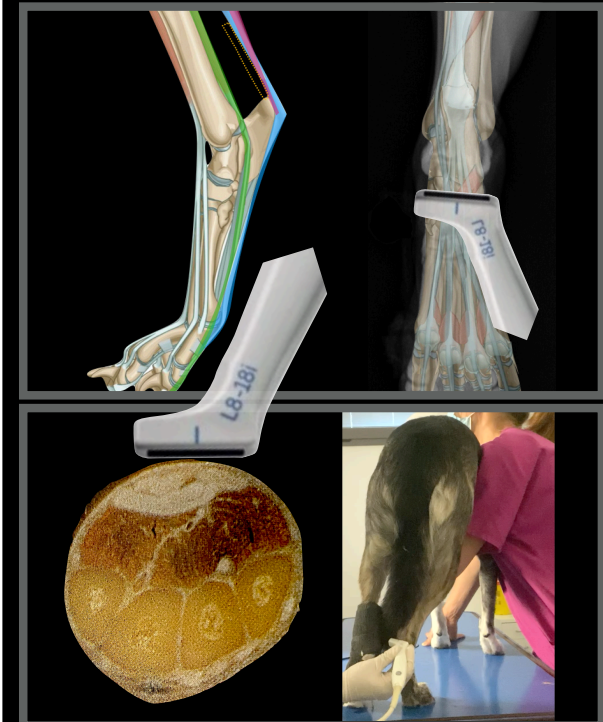
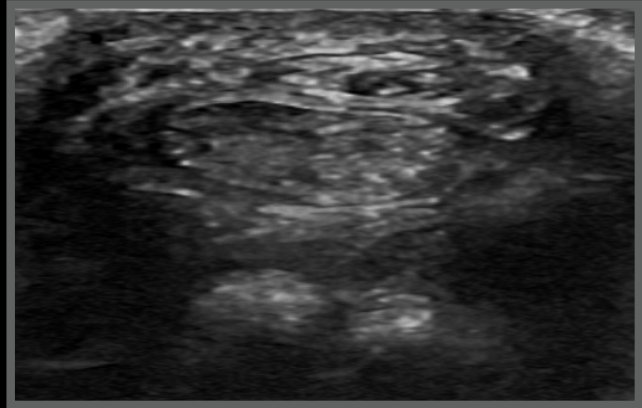


**Barattolo, MI, 2 years**

Two months later

Right paw

Caudal face transverse scan

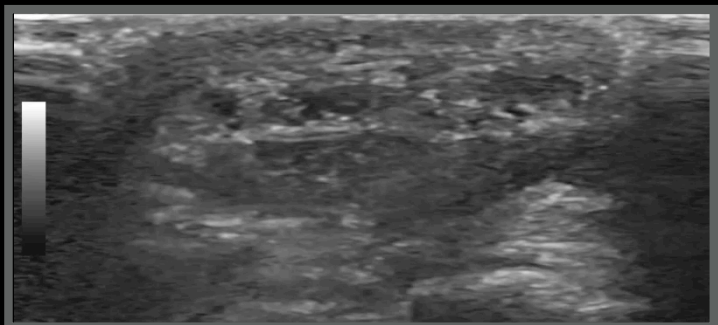


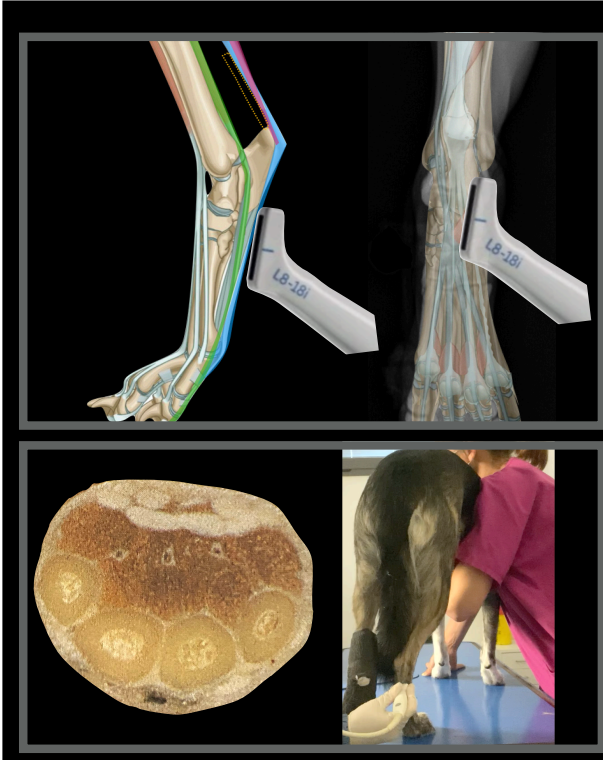
**Barattolo, MI, 2 years**

Left paw

Two months later      Affected limb

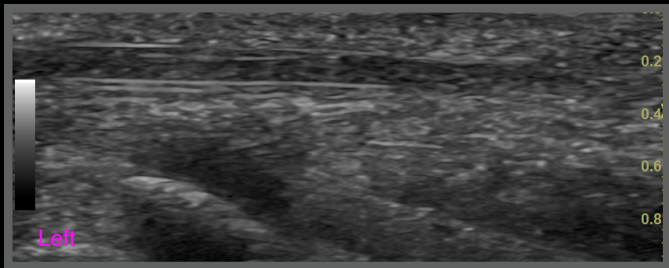
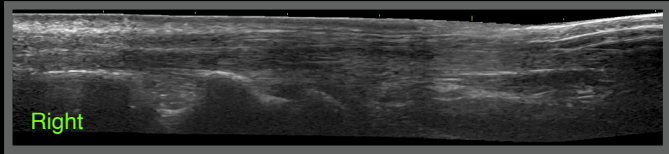
Caudal face transverse scan



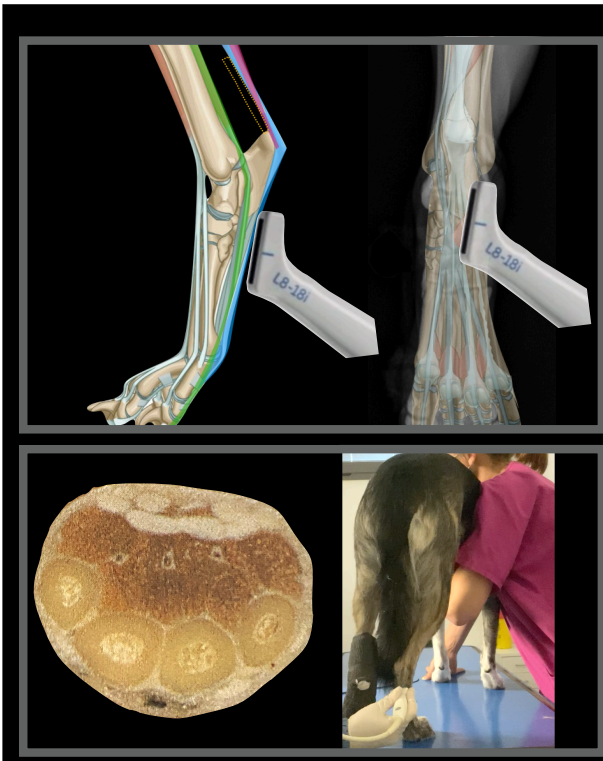


**Barattolo, MI, 2 years**

Caudal face longitudinal scan

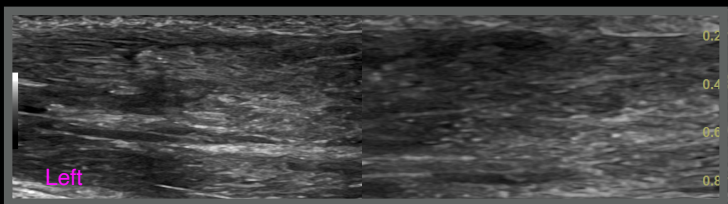
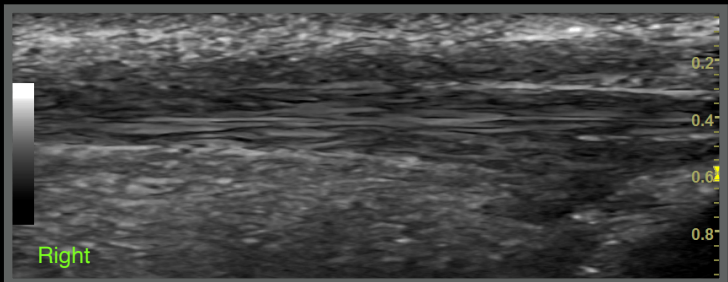


www.imaios.com



**Barattolo, MI, 2 years**

Caudal face longitudinal scan



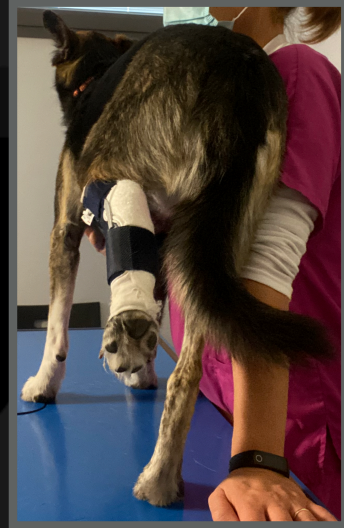www.imaios.com

## Barattolo, Mongrel, MI, 2 years

Two months later

### Ultrasonographic diagnoses

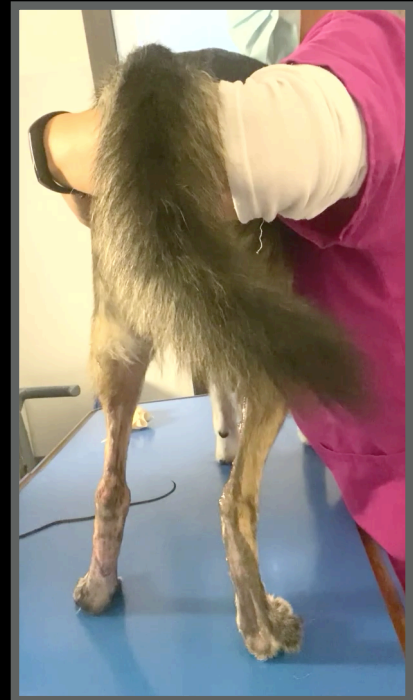- Improving healing of the tenomuscular structures
- Fracture stable
- Gradually reducing containment



## Barattolo, Mongrel, MI, 2 years

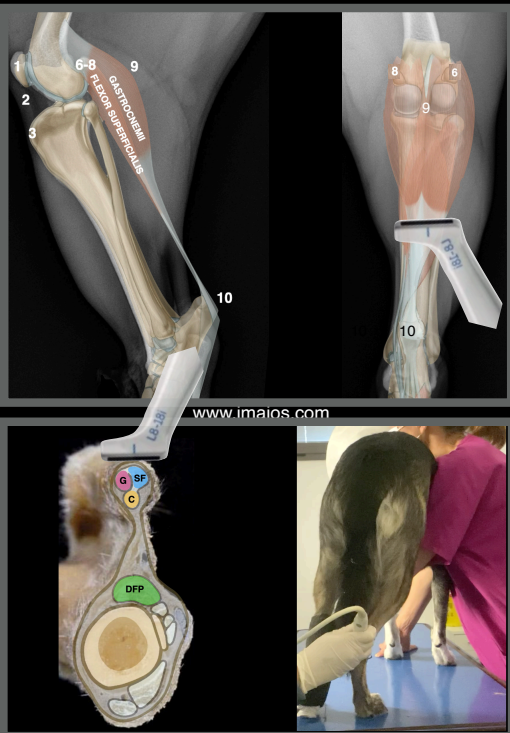
Four months later

- Weight-bearing and increasing muscle tone on the left hindlimb for the last four weeks



Barattolo, Mongrel, MI, 2 years

Four months later



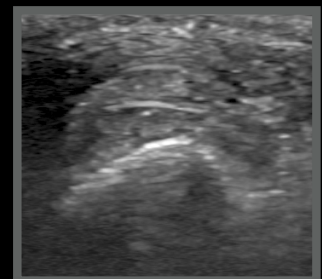
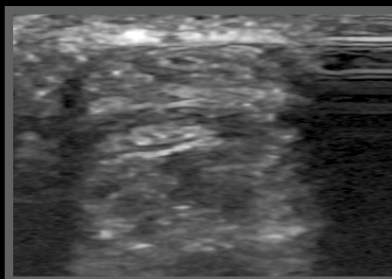
Barattolo, MI, 2 years

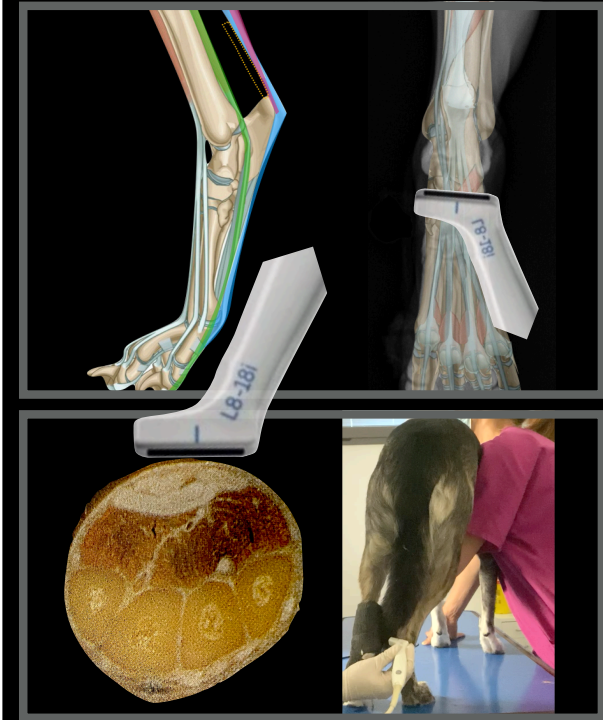
Four months later

Caudal face transverse scan

Right

Left





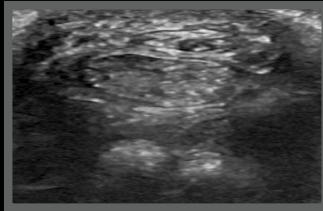
Barattolo, MI, 2 years



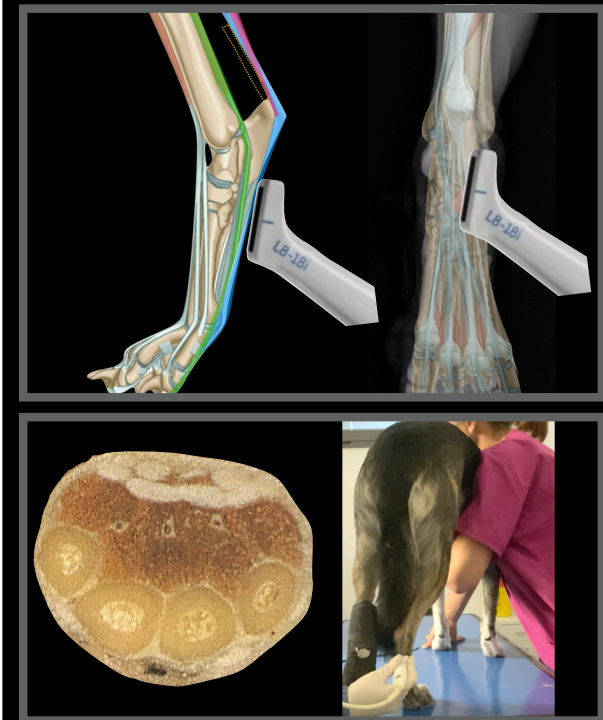
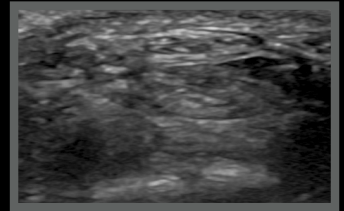
Four months later

Caudal face transverse scan

Right



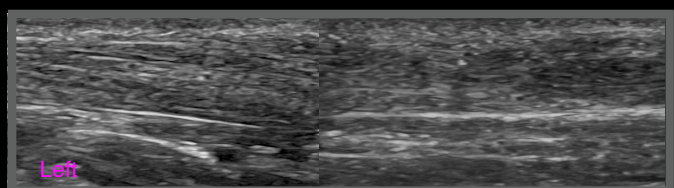
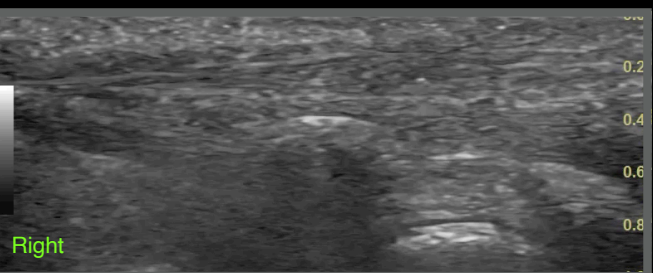
Left



Barattolo, MI, 2 years



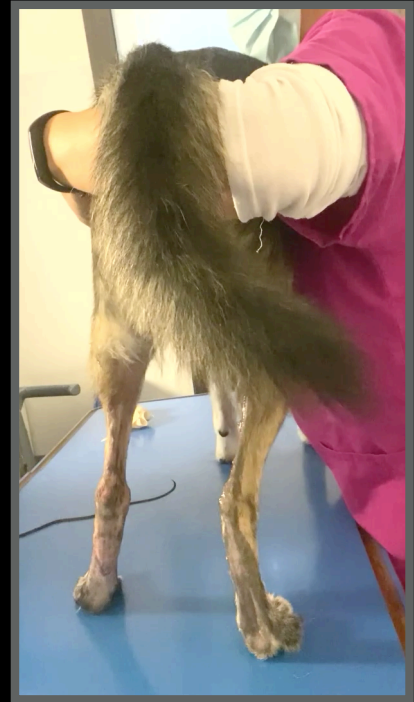Four months later



## Barattolo, Mongrel, MI, 2 years

Follow up

- He went back to normal activity after two months of controlled physical activity
- Sound for the last two years

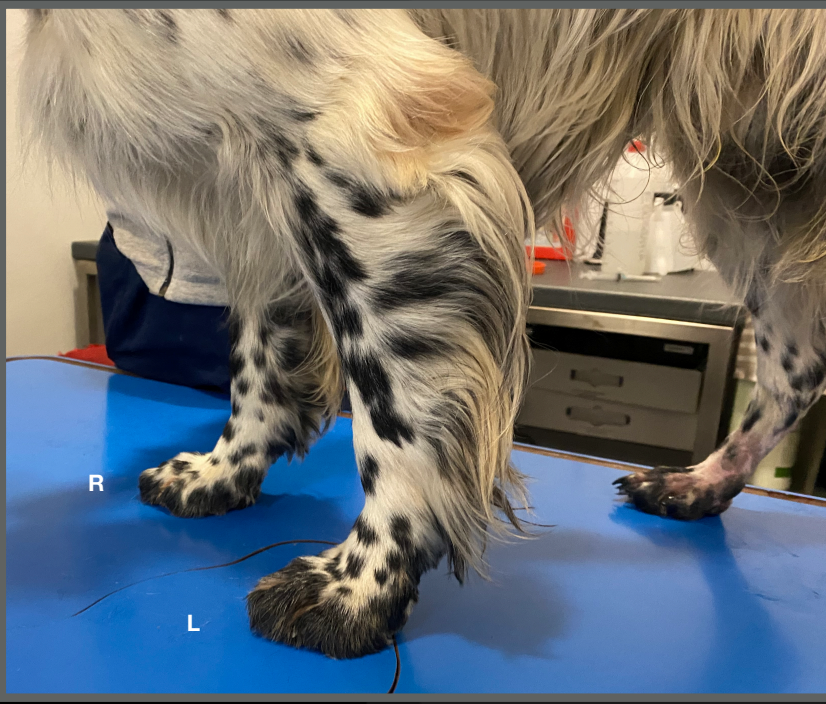

## Tuffo, English Setter, MI, 5 years

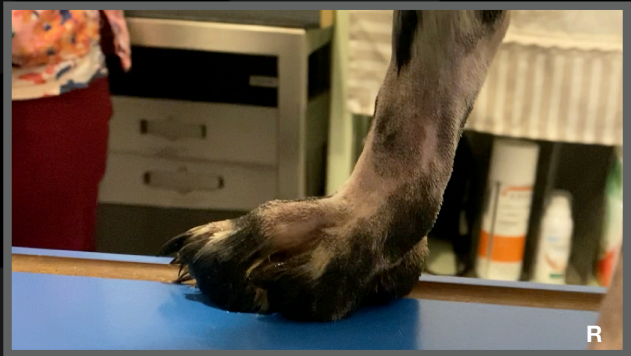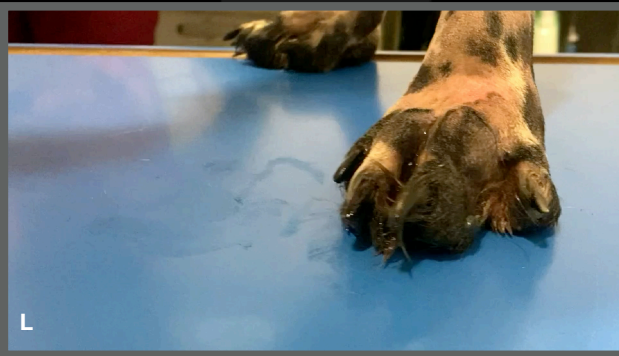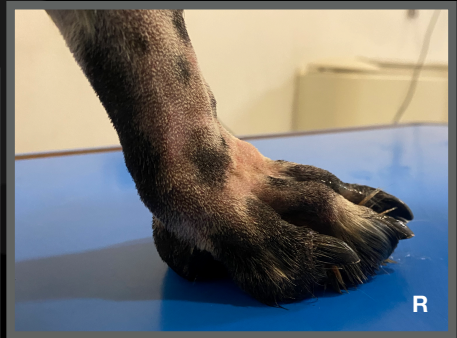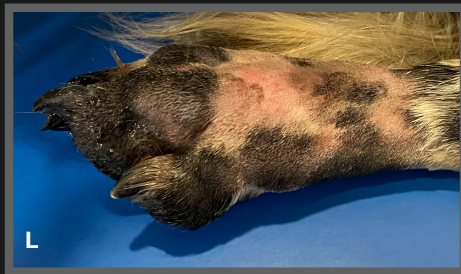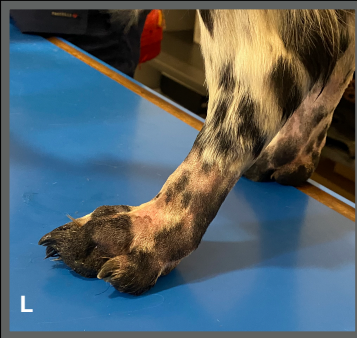- For the last seven months, recurrent left hindlimb lameness after hunting
- Fine during the exercise but severely lame after rest
- Swollen MT-P1 joint of the left fourth digit



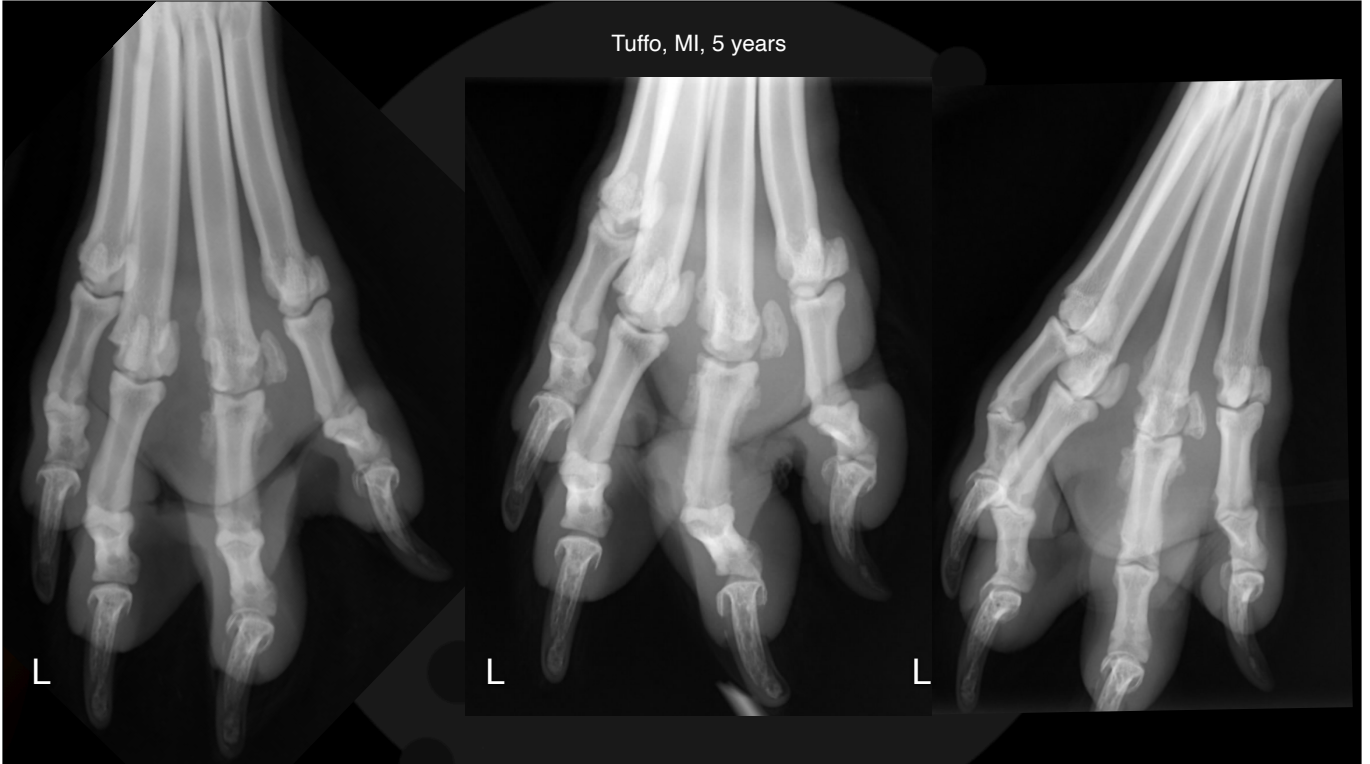
Tuffo,  
MI, 5 years



Tuffo,  
MI, 5 years



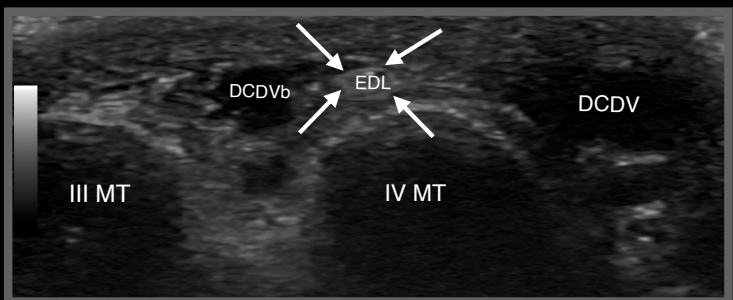
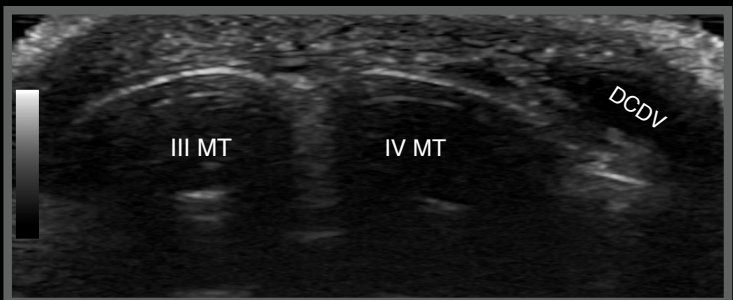
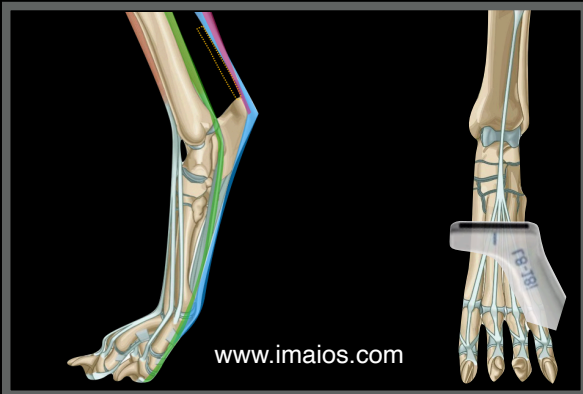
Tuffo, MI, 5 years



Tuffo, MI, 5 years

Right paw

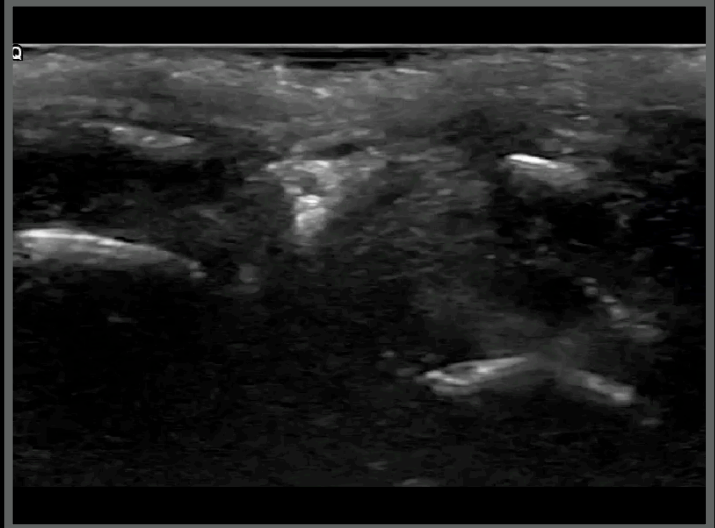
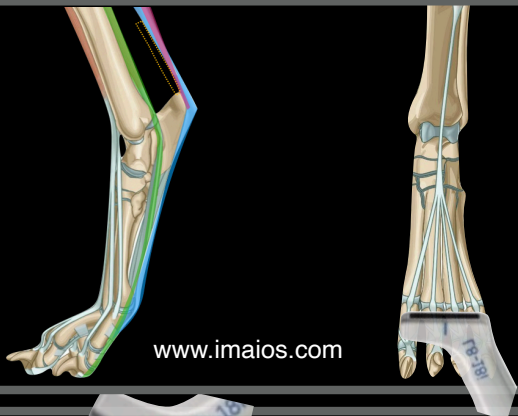
Cranial face transverse scan



**Tuffo, MI, 5 years**

Left paw

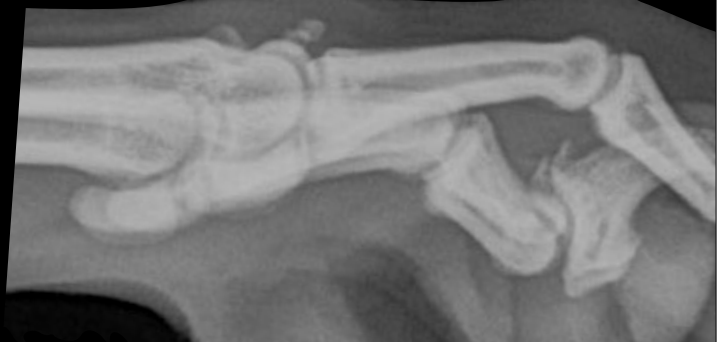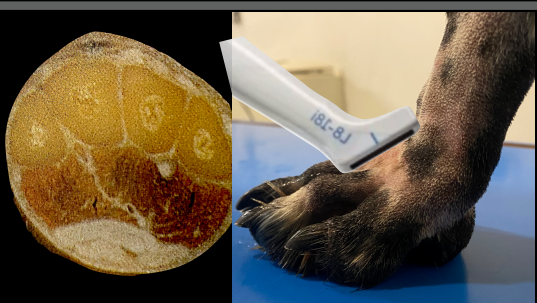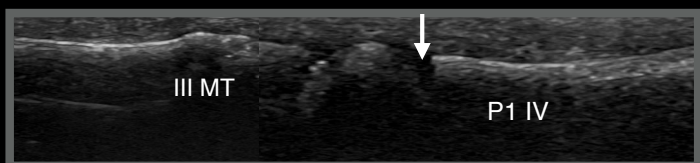
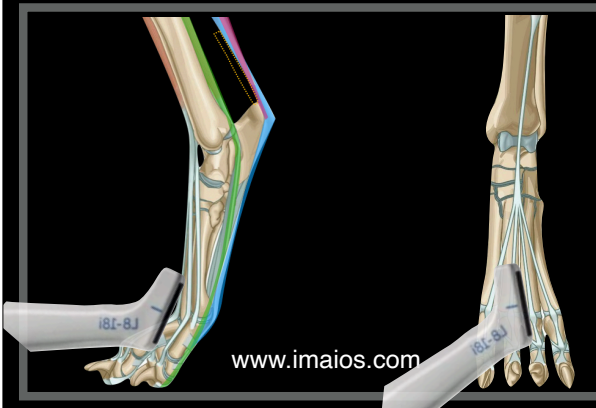
Cranial face transverse scan



**Tuffo, MI, 5 years**

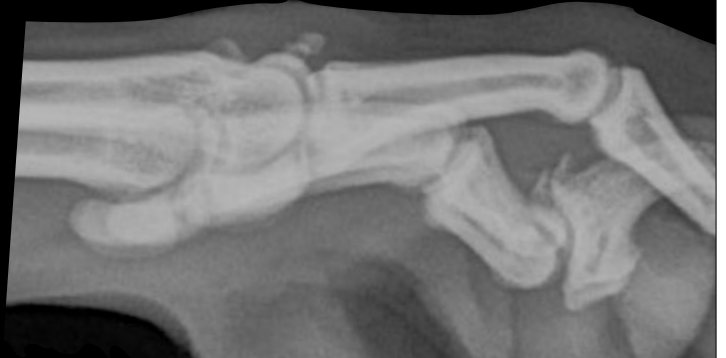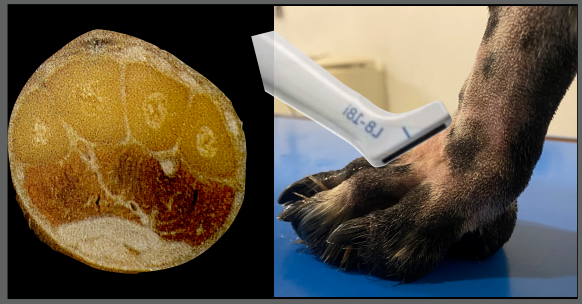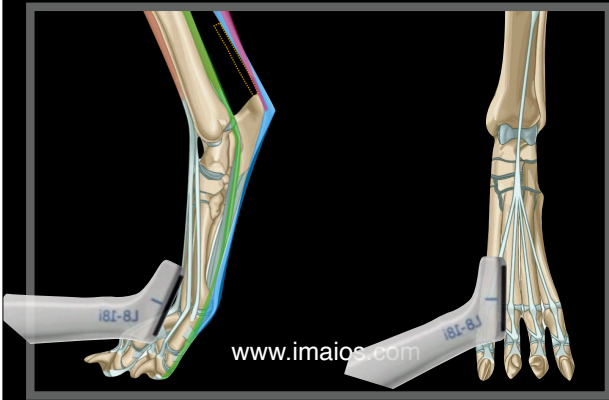
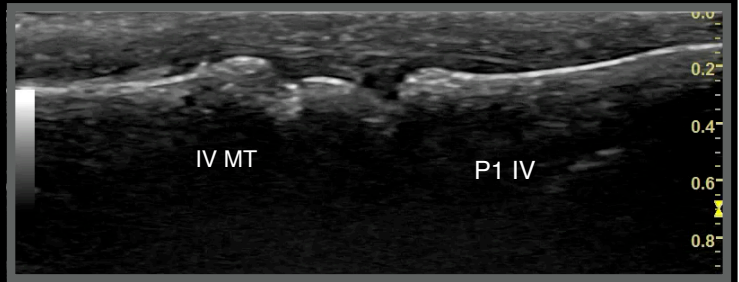
Right paw

Cranial face longitudinal scan



**Tuffo, MI, 5 years**

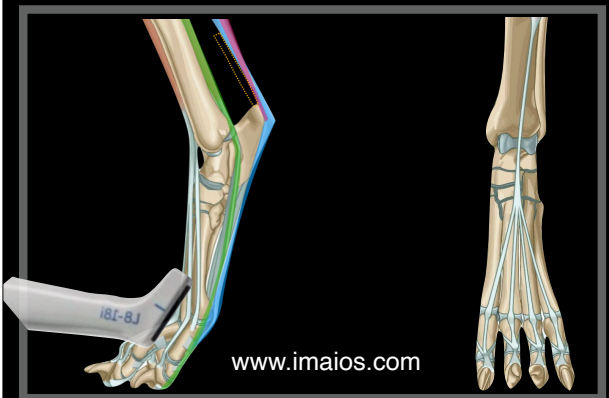
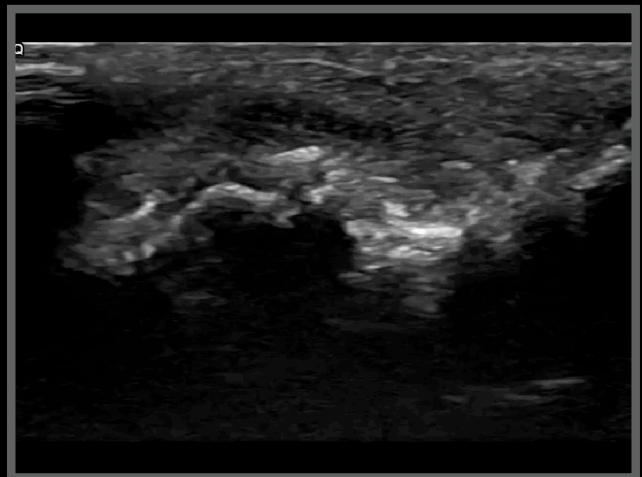
Right paw Cranial face longitudinal scan



**Tuffo, MI, 5 years**

Left paw

Cranial face longitudinal scan, IV digit

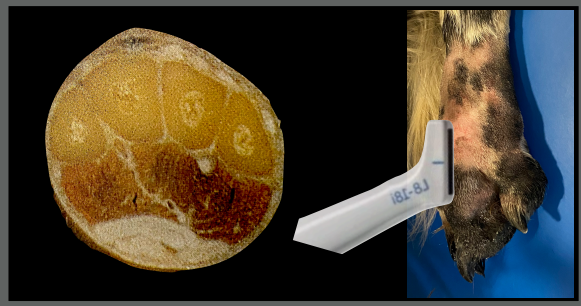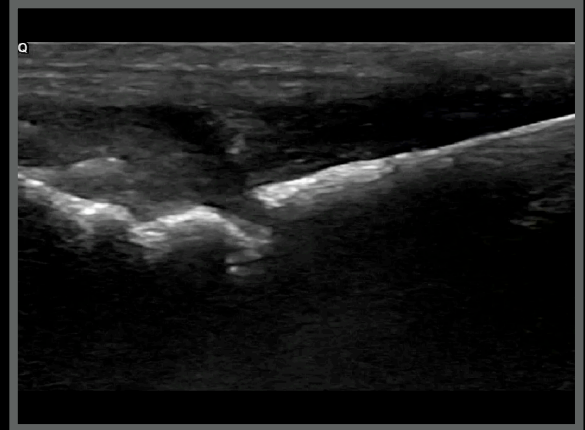
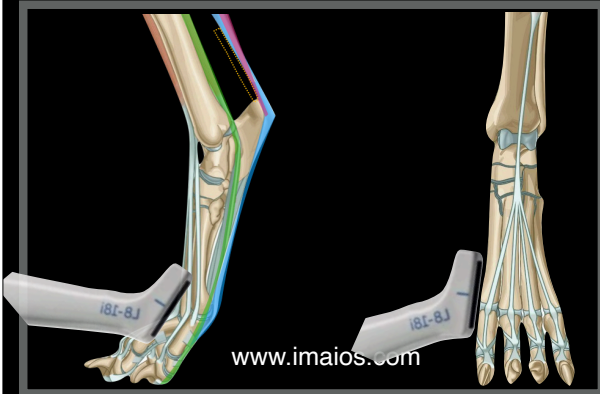




## Tuffo, MI, 5 years

Left paw

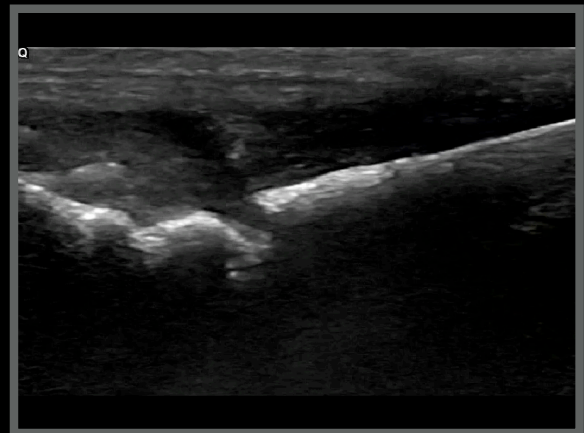
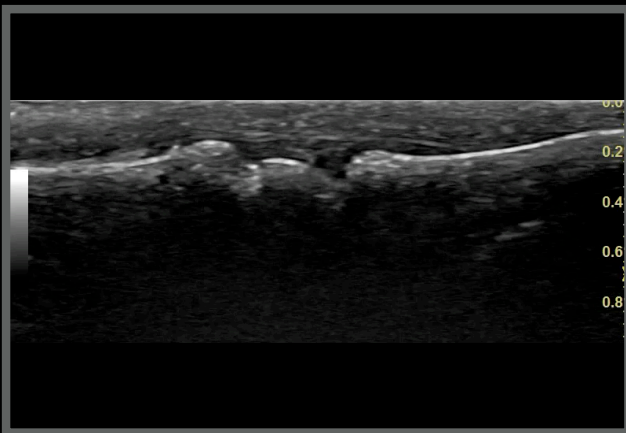
Cranial face longitudinal scan, IV digit



## Tuffo, English Setter, MI, 5 years

Cranial face longitudinal scan, right IV digit

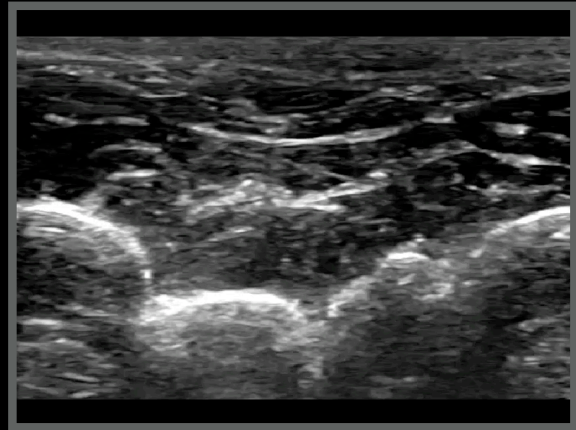
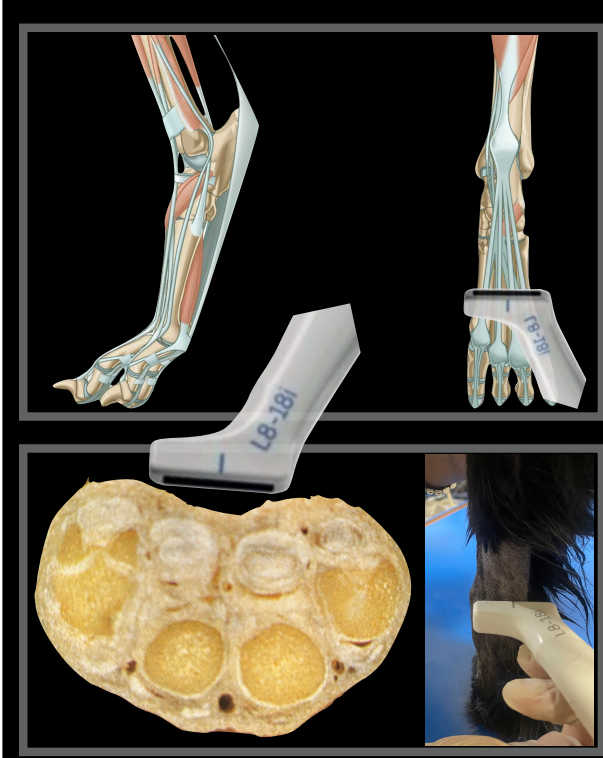Cranial face longitudinal scan, left IV digit



Tuffo, MI, 5 years

Right paw

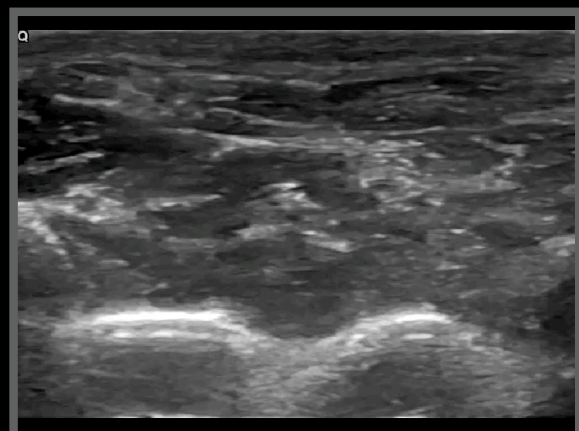
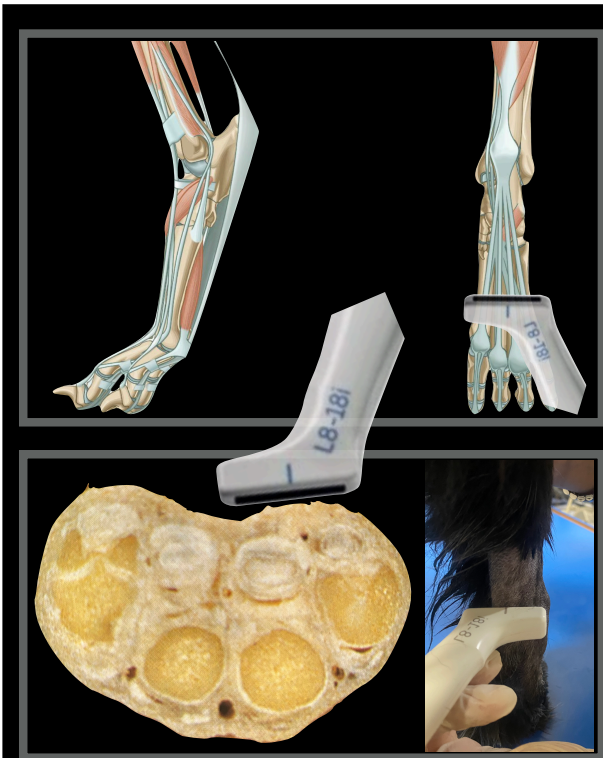
Plantar face transverse scan, IV digit



Tuffo, MI, 5 years

Left paw

Plantar face transverse scan, IV digit

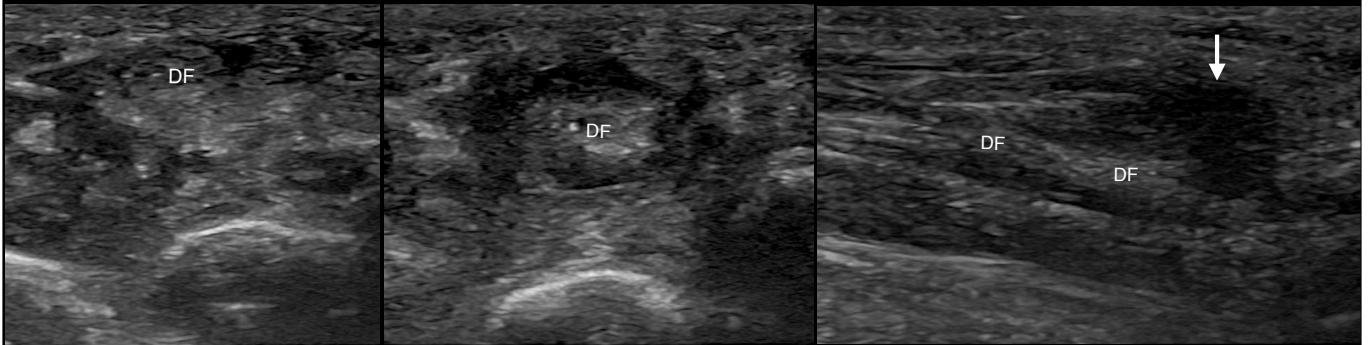




## Tuffo, English Setter, MI, 5 years

Cranial face longitudinal scan, right IV digit

Cranial face longitudinal scan, left IV digit



## Tuffo, English Setter, MI, 5 years

### Ultrasonographic diagnoses:

- Severe left MT-P1 OA and instability
- Loss of normal anatomy of the soft tissue surrounding the joint
- Lateral displacement of the sixth sesamoid bone
- Chronic extension and focal loss of the deep flexor tendon of the left fourth hindlimb digit
- Moderate, severe elongation of the right deep flexor tendon of the right fourth hindlimb digit



## Conclusions

US can be helpful in grading muscle and tendon acute and chronic conditions

It can be useful for surgical planning or for follow-up after surgery



Pietra Di Bismantova, (RE), Italy

# Thank you



Diagnostic Mindset

[www.diagnosticmindset.com](http://www.diagnosticmindset.com)