

# The ultrasound examination of the hindlimb extremities

Gliola Spattini  
DVM, GP Cardiol., CCRT, PhD, DECVI



Thank to [www.imaios.com](http://www.imaios.com)

---

---

---

---

---

---

---

---

---

---

## Barattolo, Mongrel, MI, 2 years

- He steps on a broken bottle
- Surgical repair of a deep cut left-metatarsal side
- Severe swelling of the left tarsus and paw at the time of trauma
- Still lame after two weeks



---

---

---

---

---

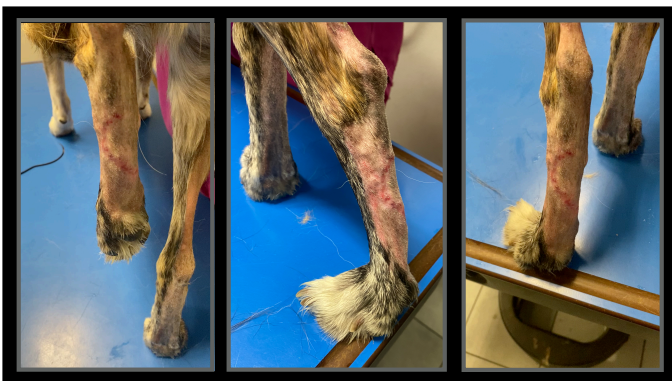---

---

---

---

---



---

---

---

---

---

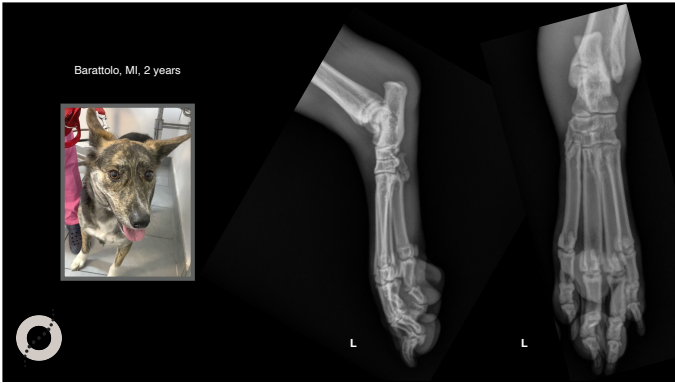
---

---

---

---

---



---

---

---

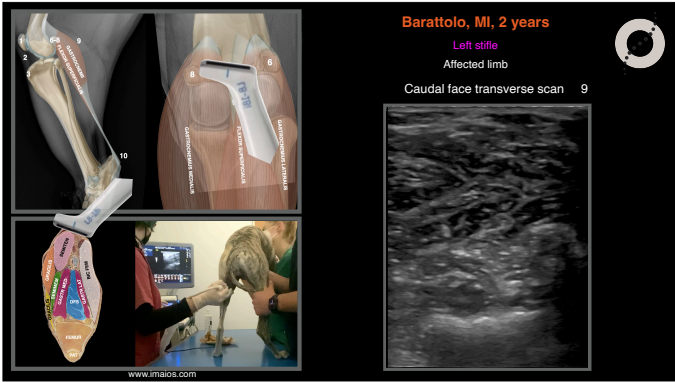
---

---

---

---

---



---

---

---

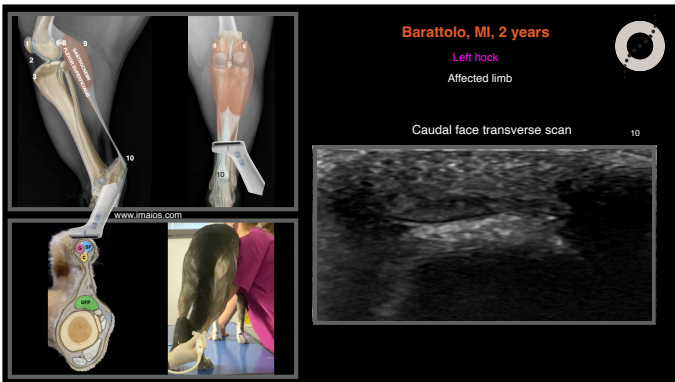
---

---

---

---

---



---

---

---

---

---

---

---

---

**Barattolo, MI, 2 years**  
 Left hock  
 Affected limb  
 Caudal face longitudinal scan 9-10

---

---

---

---

---

---

---

---

**Barattolo, MI, 2 years**  
 Right paw  
 Sound limb  
 Caudal face transverse scan 10

---

---

---

---

---

---

---

---

**Barattolo, MI, 2 years**  
 Left paw  
 Affected limb  
 Caudal face transverse scan

---

---

---

---

---

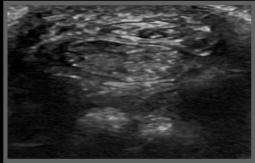
---

---

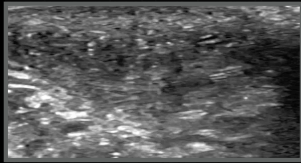
---

Barattolo, MI, 2 years

Right paw



Left paw



---

---

---

---

---

---

---

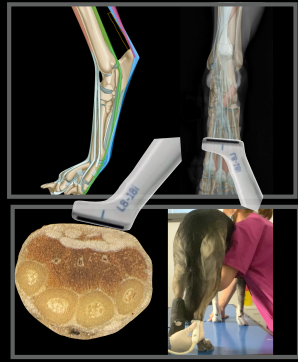
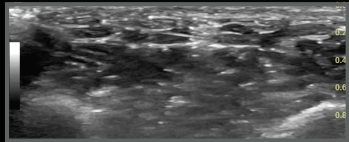
---

Barattolo, MI, 2 years

Right paw

Sound limb

Caudal face transverse scan



---

---

---

---

---

---

---

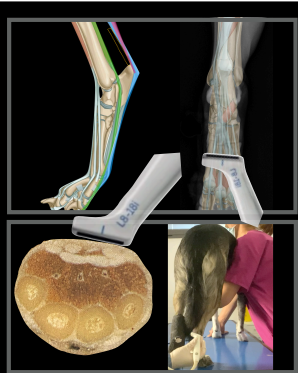
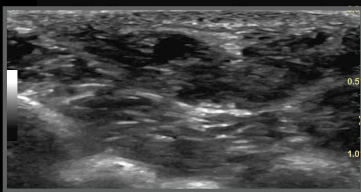
---

Barattolo, MI, 2 years

Left paw

Affected limb

Caudal face transverse scan



---

---

---

---

---

---

---

---

**Barattolo, MI, 2 years**

Right paw  
Sound limb

Caudal face longitudinal scan

www.imaios.com

---

---

---

---

---

---

---

---

**Barattolo, MI, 2 years**

Left paw  
Affected limb

Caudal face longitudinal scan

www.imaios.com

---

---

---

---

---

---

---

---

**Ultrasonographic diagnoses**

- Minimal chronic tendonitis left Achille's tendon
- Healing suture of the left superficial and deep flexors tendons (no complications visible)

**Next steps:**

- Review the provided radiographs

---

---

---

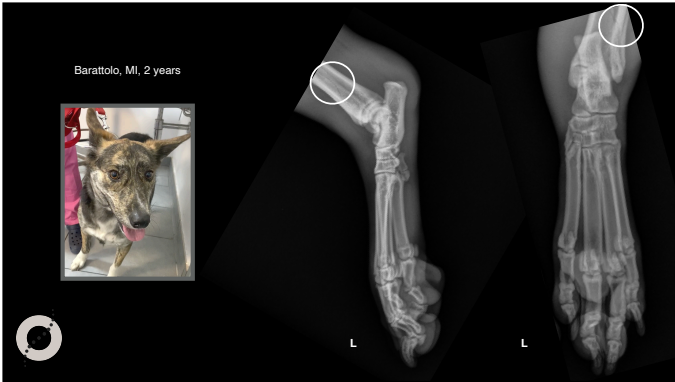
---

---

---

---

---



---

---

---

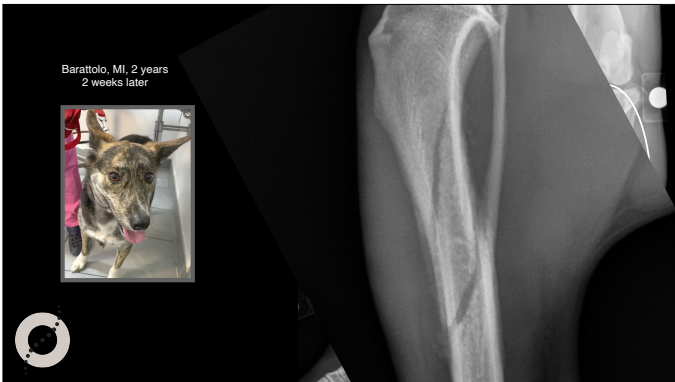---

---

---

---

---



---

---

---

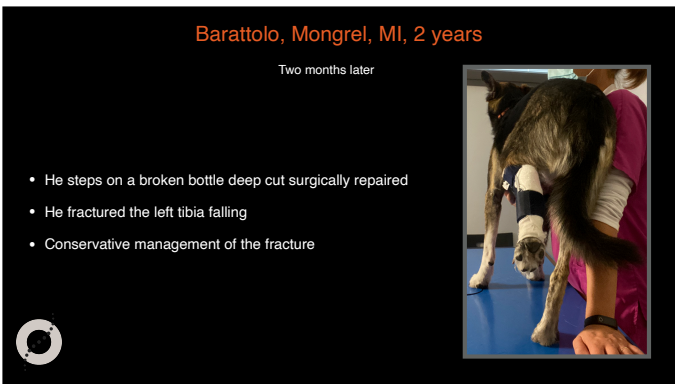---

---

---

---

---



---

---

---

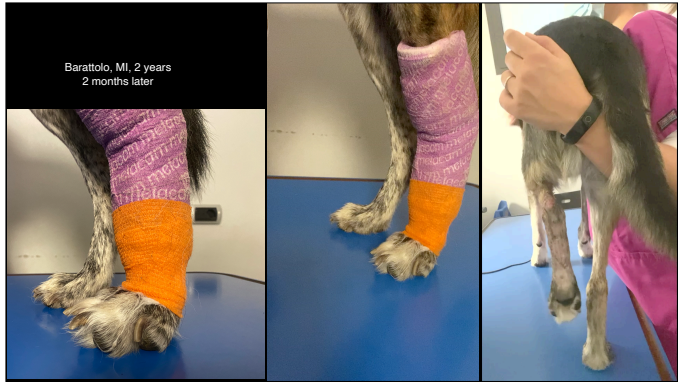---

---

---

---

---



---

---

---

---

---

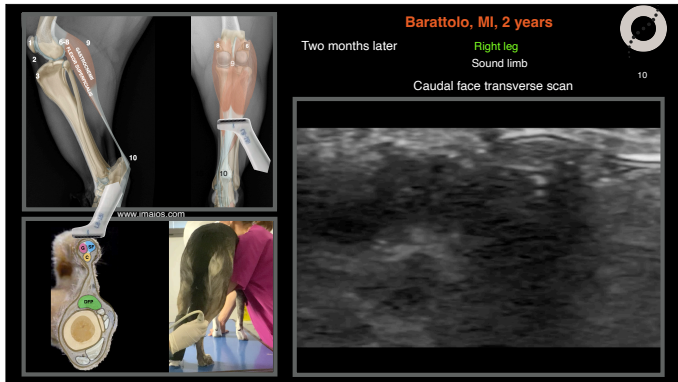
---

---

---

---

---



---

---

---

---

---

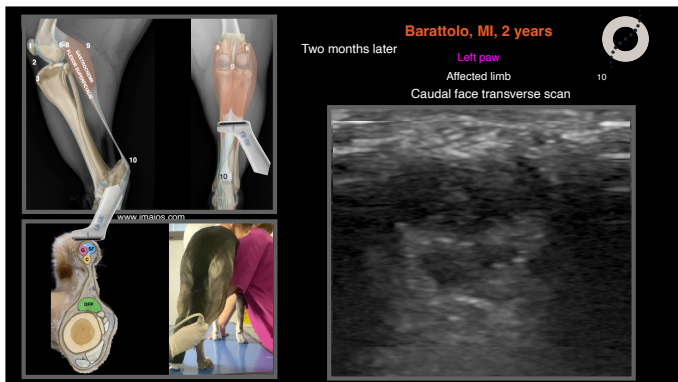
---

---

---

---

---



---

---

---

---

---

---

---

---

---

---

**Barattolo, MI, 2 years**

Two months later

Caudal face longitudinal scan 9-10

Right

Left

---

---

---

---

---

---

---

---

---

---

**Barattolo, MI, 2 years**

Two months later

Right paw

Caudal face transverse scan

---

---

---

---

---

---

---

---

---

---

**Barattolo, MI, 2 years**

Two months later

Affected limb

Left paw

Caudal face transverse scan

---

---

---

---

---

---

---

---

---

---

**Barattolo, MI, 2 years**  
Caudal face longitudinal scan

Right

Left

www.imaios.com

---

---

---

---

---

---

---

---

**Barattolo, MI, 2 years**  
Caudal face longitudinal scan

Right

Left

www.imaios.com

---

---

---

---

---

---

---

---

**Barattolo, Mongrel, MI, 2 years**  
Two months later

Ultrasonographic diagnoses

- Improving healing of the tenomuscular structures
- Fracture stable
- Gradually reducing containment

---

---

---

---

---

---

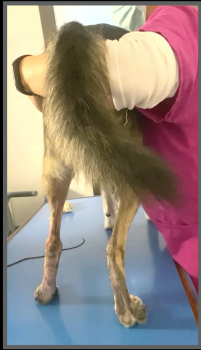---

---

Barattolo, Mongrel, MI, 2 years

Four months later

- Weight-bearing and increasing muscle tone on the left hindlimb for the last four weeks



---

---

---

---

---

---

---

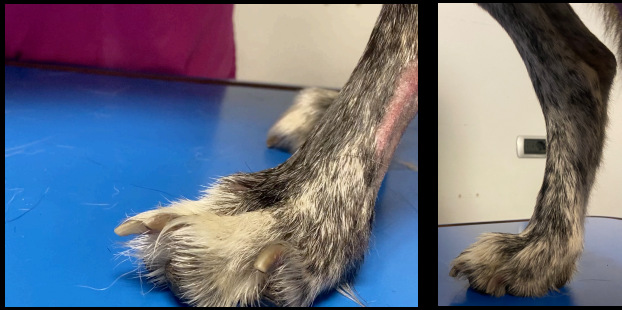---

---

---

Barattolo, Mongrel, MI, 2 years

Four months later



---

---

---

---

---

---

---

---

---

---

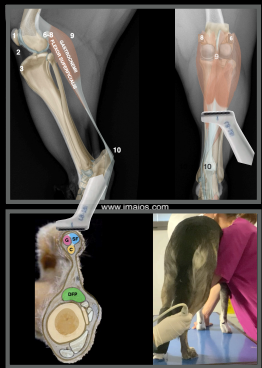
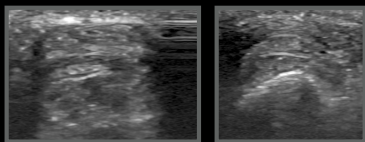
Barattolo, MI, 2 years

Four months later

Caudal face transverse scan

Right

Left



---

---

---

---

---

---

---

---

---

---

**Barattolo, MI, 2 years**

Four months later

Caudal face transverse scan

Right Left

This slide features anatomical diagrams of a dog's hindquarters, a cross-section of a vertebra, and a photograph of a dog on a table. The text includes the patient name 'Barattolo, MI, 2 years', the time point 'Four months later', and the scan type 'Caudal face transverse scan'. Two ultrasound images are shown, labeled 'Right' and 'Left'.

---

---

---

---

---

---

---

---

**Barattolo, MI, 2 years**

Four months later

Right Left

www.imaio.com

This slide shows two ultrasound images of the caudal face transverse scans, labeled 'Right' and 'Left'. It includes anatomical diagrams, a vertebra cross-section, and a photograph of the dog. The text includes the patient name 'Barattolo, MI, 2 years', the time point 'Four months later', and the website 'www.imaio.com'.

---

---

---

---

---

---

---

---

**Barattolo, Mongrel, MI, 2 years**

Follow up

- He went back to normal activity after two months of controlled physical activity
- Sound for the last two years

This slide features a photograph of a dog on a table. The text includes the patient name 'Barattolo, Mongrel, MI, 2 years', the time point 'Follow up', and two bullet points describing the dog's recovery and health status.

---

---

---

---

---

---

---

---

Tuffo, English Setter, MI, 5 years

- For the last seven months, recurrent left hindlimb lameness after hunting
- Fine during the exercise but severely lame after rest
- Swollen MT-P1 joint of the left fourth digit



---

---

---

---

---

---

---

---

Tuffo, MI, 5 years



---

---

---

---

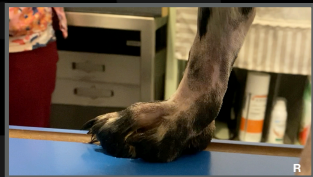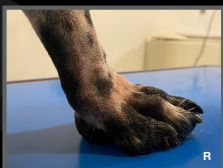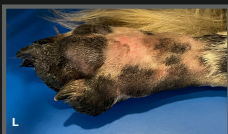---

---

---

---

Tuffo, MI, 5 years



---

---

---

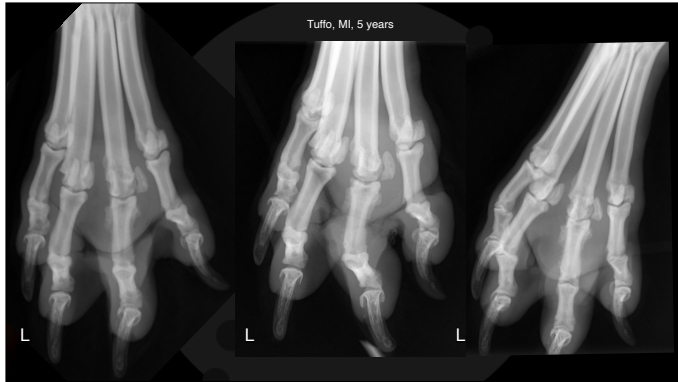
---

---

---

---

---




---



---



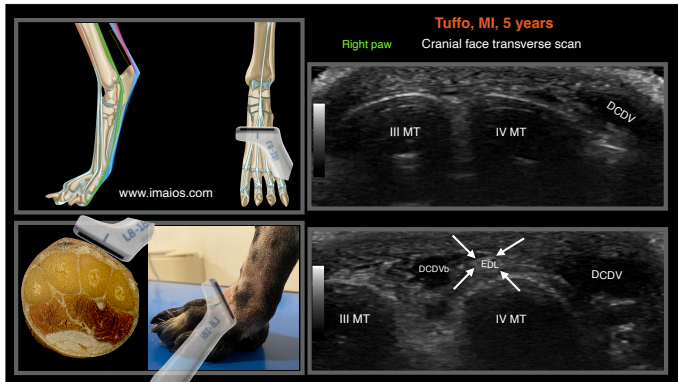
---



---



---




---



---



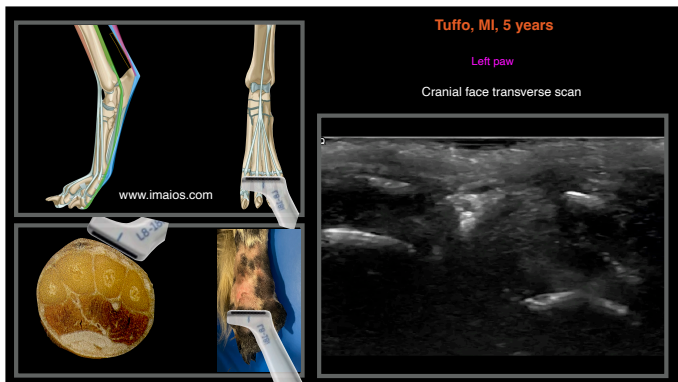
---



---



---




---



---



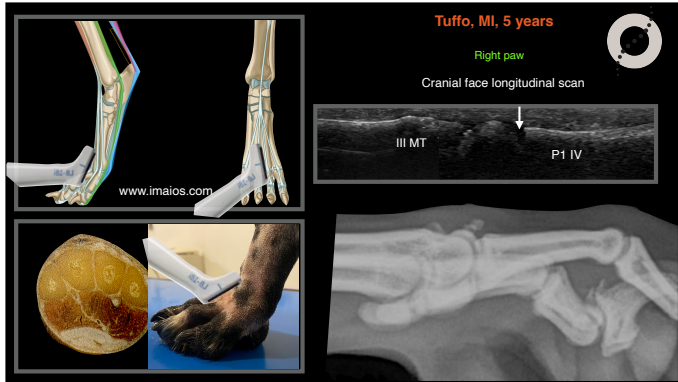
---



---



---



---

---

---

---

---

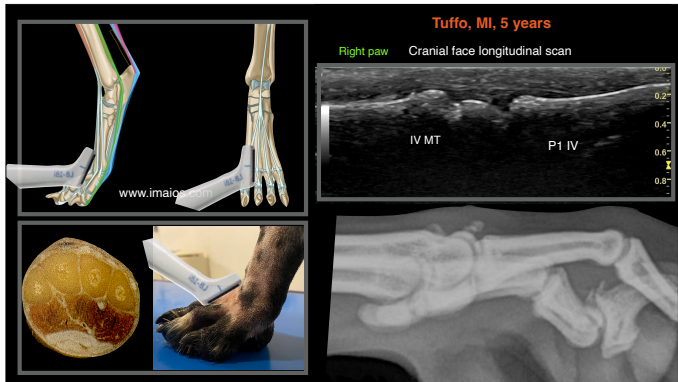
---

---

---

---

---



---

---

---

---

---

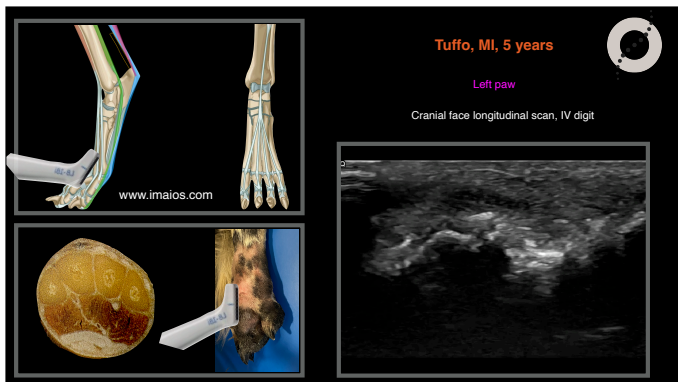
---

---

---

---

---



---

---

---

---

---

---

---

---

---

---

**Tuffo, MI, 5 years**

Left paw

Cranial face longitudinal scan, IV digit

---

---

---

---

---

---

---

---

**Tuffo, English Setter, MI, 5 years**

Cranial face longitudinal scan, right IV digit

Cranial face longitudinal scan, left IV digit

---

---

---

---

---

---

---

---

**Tuffo, MI, 5 years**

Right paw

Plantar face transverse scan, IV digit

---

---

---

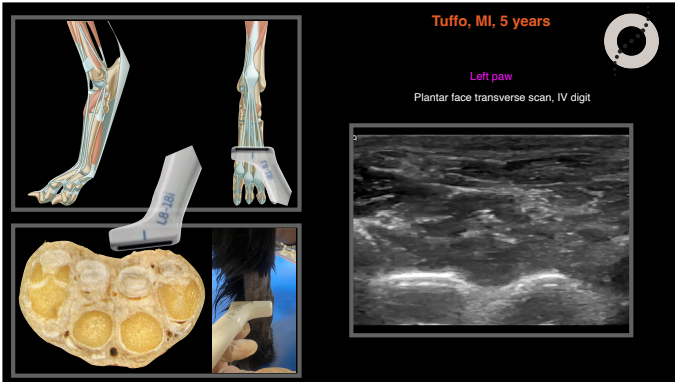
---

---

---

---

---




---

---

---

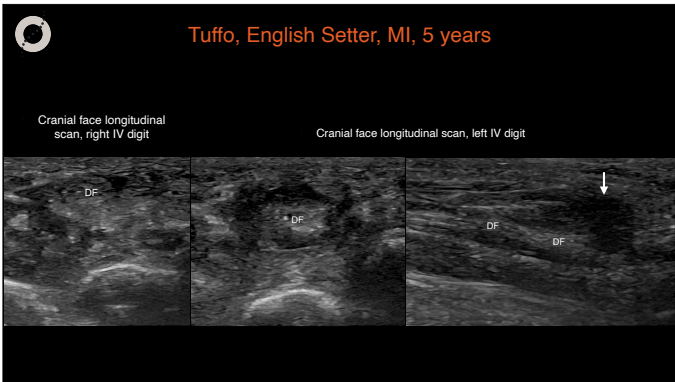
---

---

---

---

---




---

---

---

---

---

---

---

---

**Tuffo, English Setter, MI, 5 years**

Ultrasonographic diagnoses:

- Severe left MT-P1 OA and instability
- Loss of normal anatomy of the soft tissue surrounding the joint
- Lateral displacement of the sixth sesamoid bone
- Chronic extension and focal loss of the deep flexor tendon of the left fourth hindlimb digit
- Moderate, severe elongation of the right deep flexor tendon of the right fourth hindlimb digit

---

---

---

---

---

---

---

---

## Conclusions

US can be helpful in grading muscle and tendon acute and chronic conditions

It can be useful for surgical planning or for follow-up after surgery



Pietra Di Bismantova, (RE), Italy

---

---

---

---

---

---

---

---

# Thank you



Diagnostic Mindset

[www.diagnosticmindset.com](http://www.diagnosticmindset.com)

---

---

---

---

---

---

---

---