Why this dog is still lame six months after a trauma?

CASE DISCUSSION

Giliola Spattini
DVM, GP Cardio, CCRT, PhD, DECVDI

Diagnostic Mindset

il loro benessere, il nostro obiettivo
Clinica Veterinaria
CASTELLARANO

Thank to www.imaios.com

Marta, Bullmastiff, FI, 6 months

- After this trauma, subtle but progressive lameness in the right hind limb
- Not responding to NSAID
- Radiology performed at eight months of age

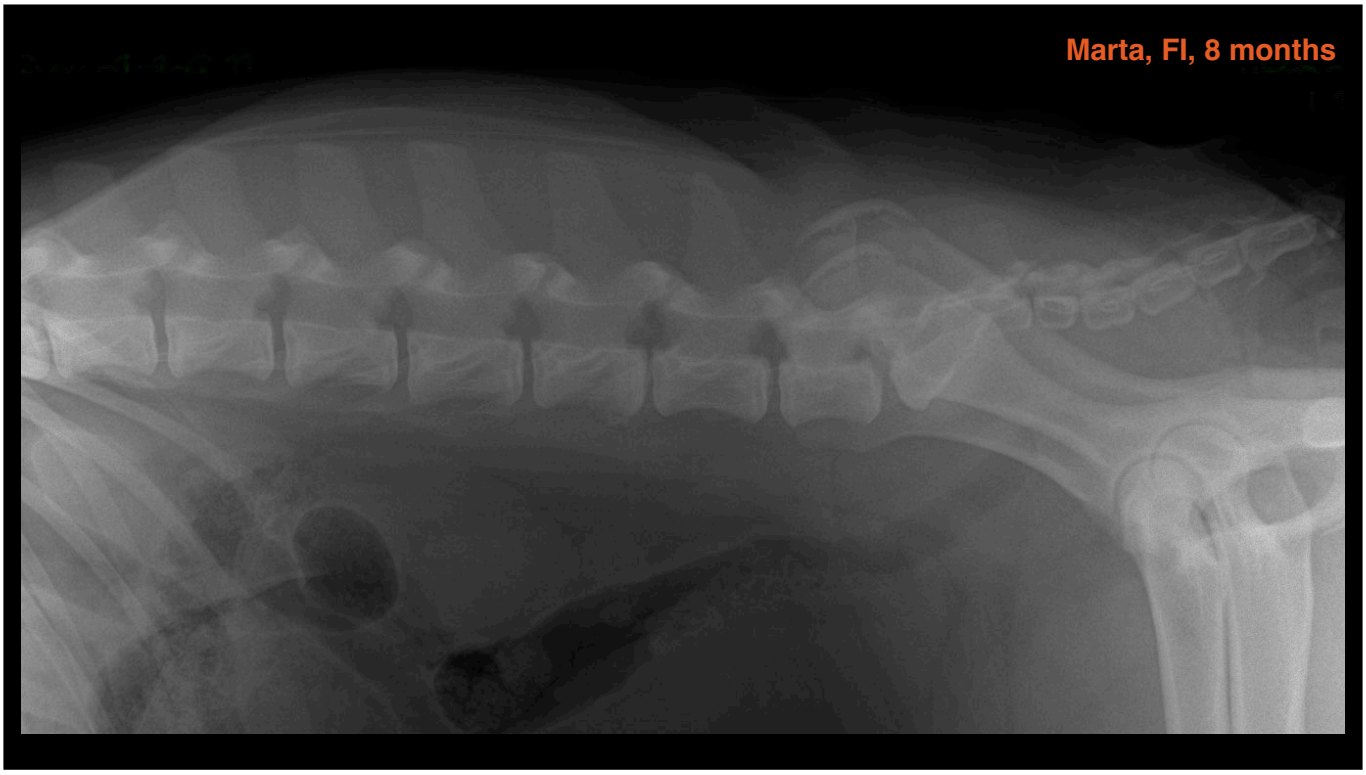
Marta, FI, 8 months

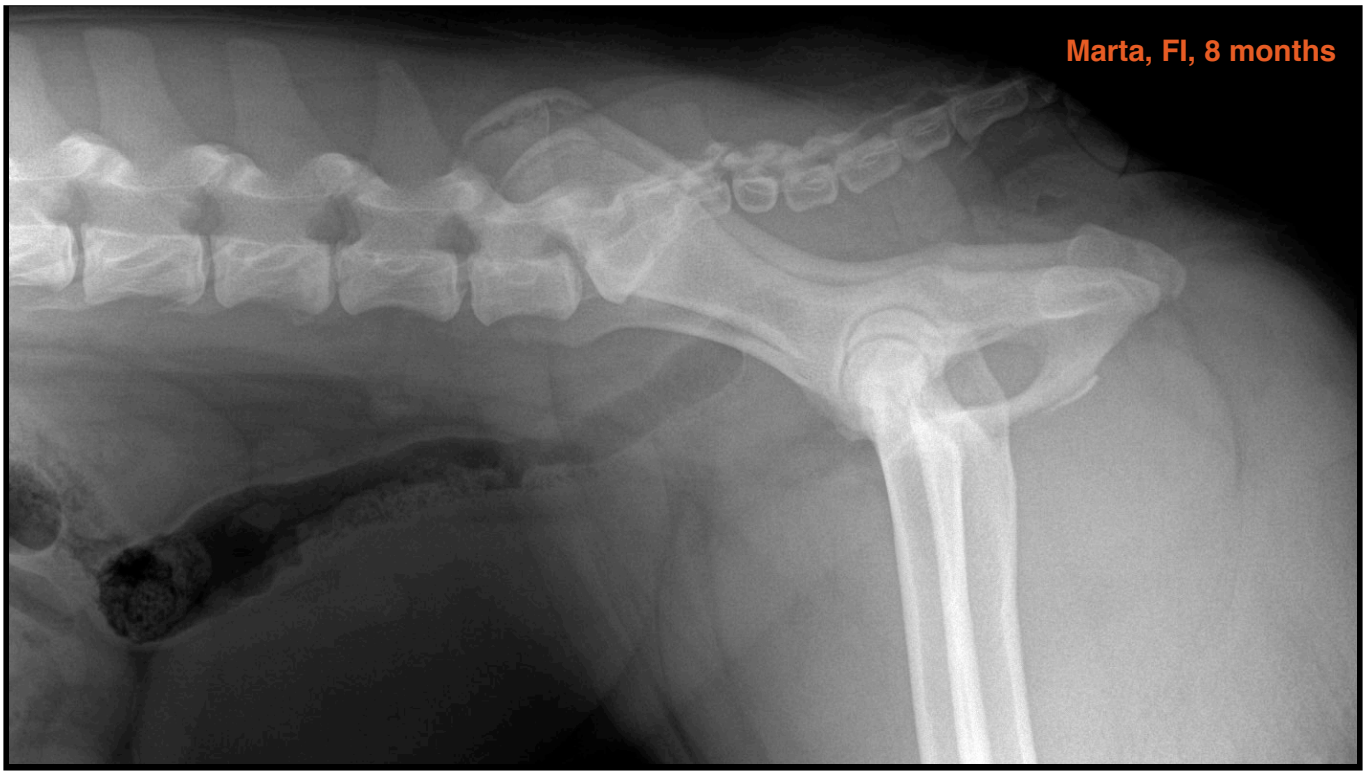
Marta, FI, 8 months

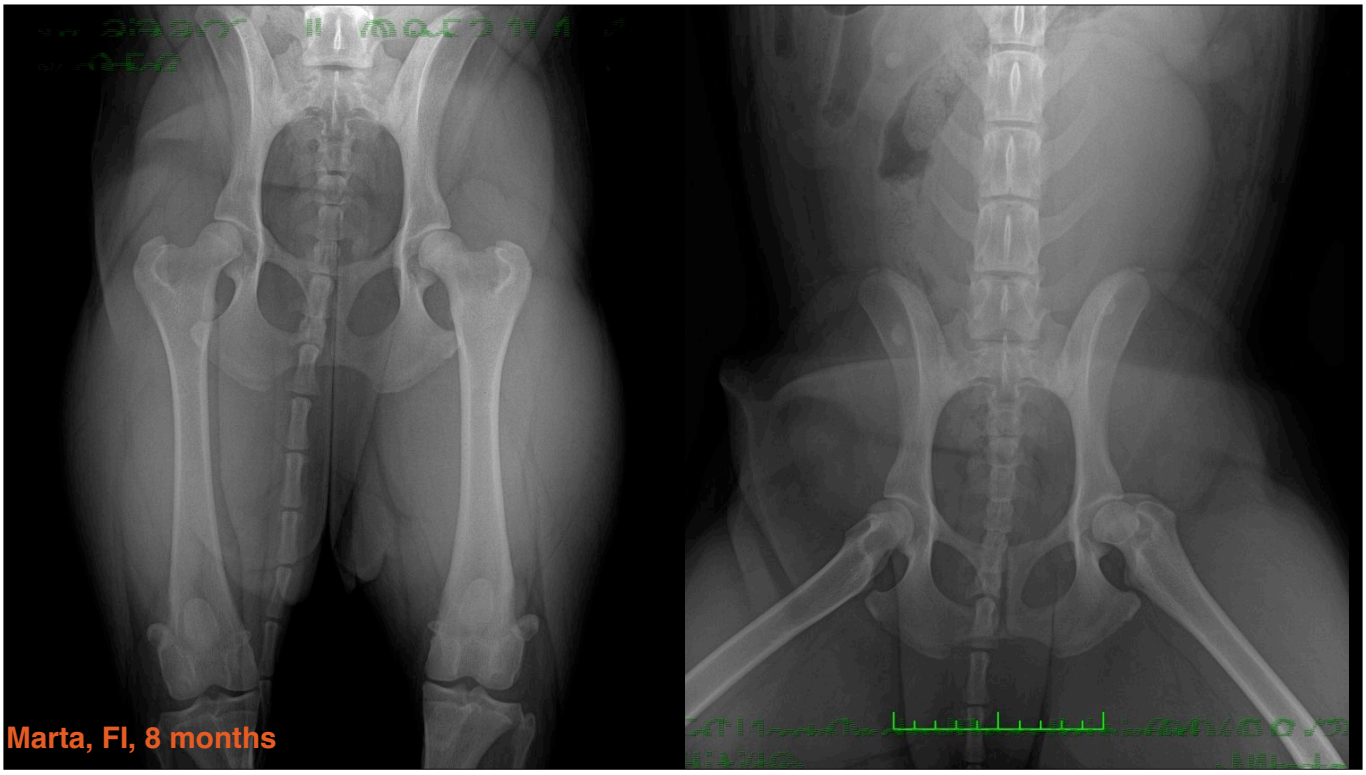

Marta, Bullmastiff, FI, 1 year

- Six months later still lame
- There is a “hole” on the right gluteal region
- Evident right hindlimb atrophy
- MRI performed

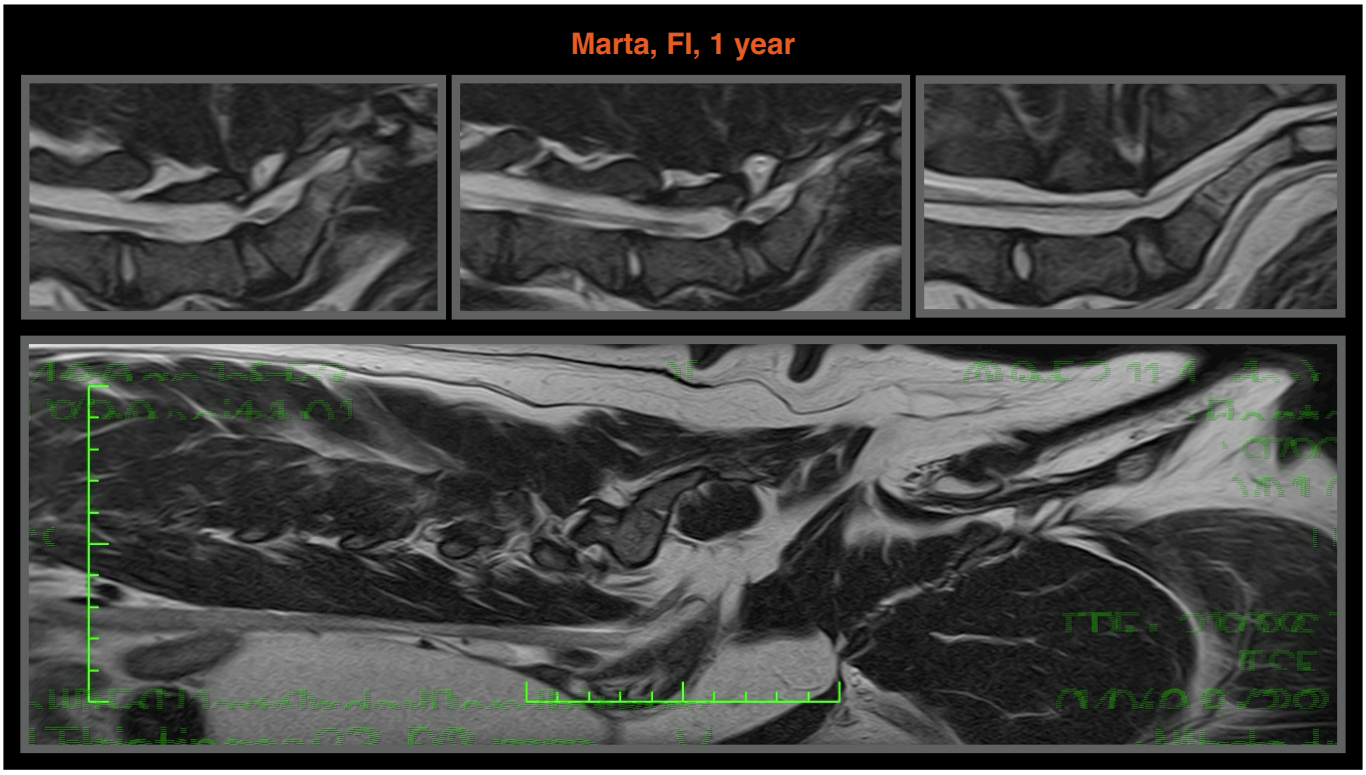
Marta, FI, 1 year

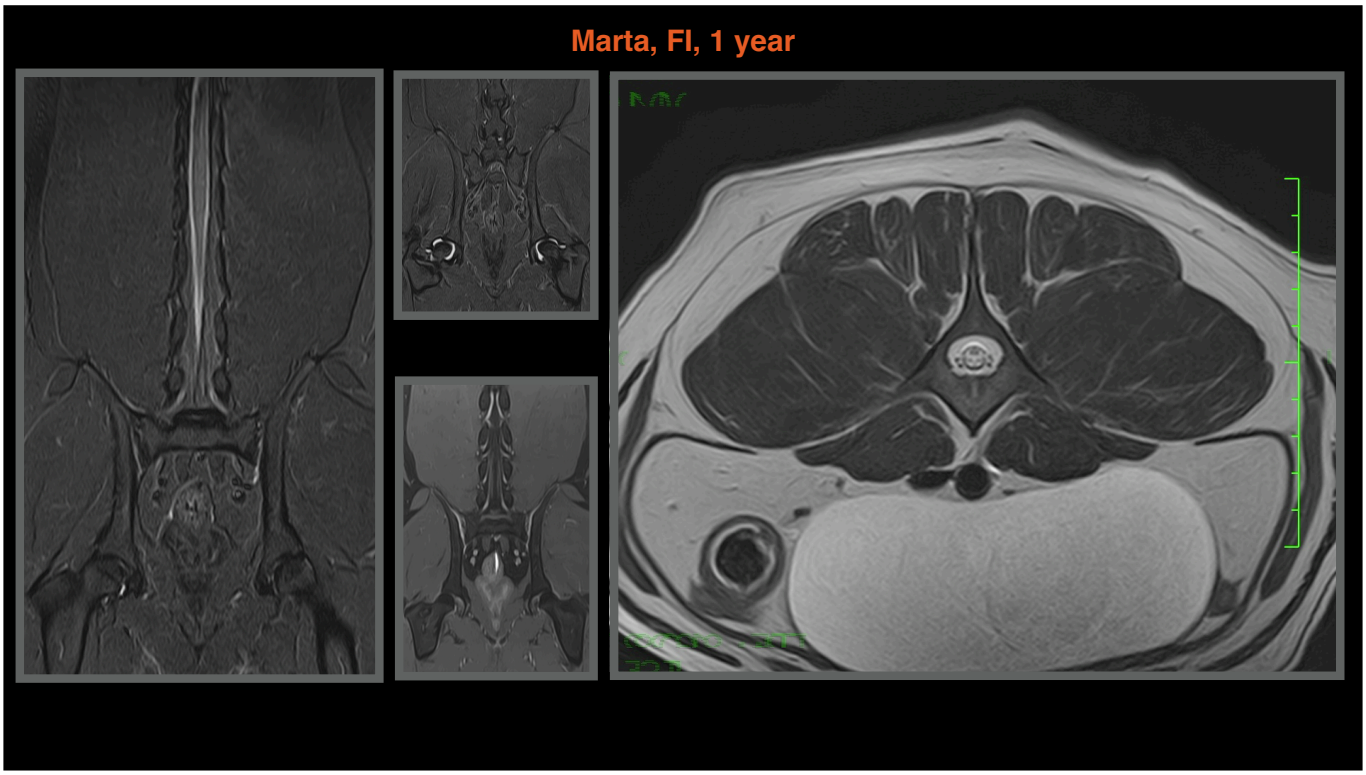
Marta, FI, 1 year

Marta, Bullmastiff, FI, 1 year

- Still lame
- Negative radiographs
- Negative MRI apart from right gluteal muscles atrophy

Marta, FI, 1 year

Marta, FI,
1 year

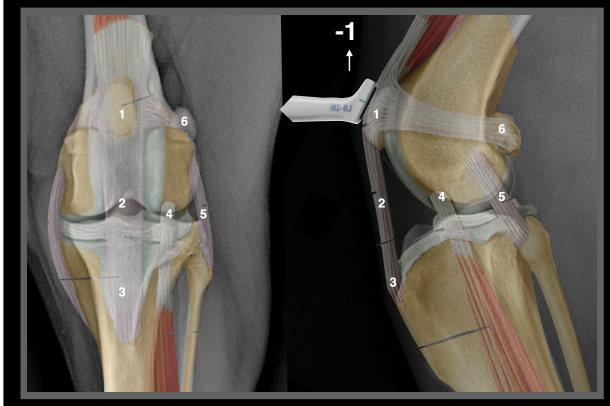

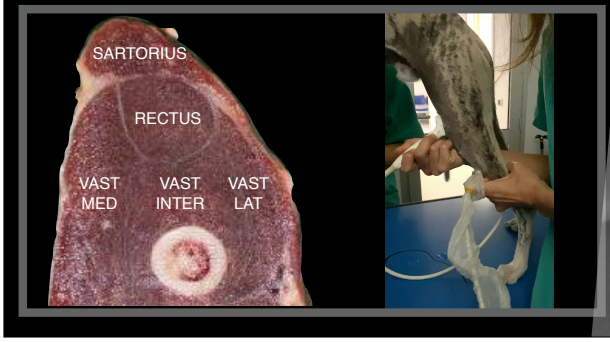

Marta, FI, 1 years

Right thigh

Cranial face longitudinal scan 1-1

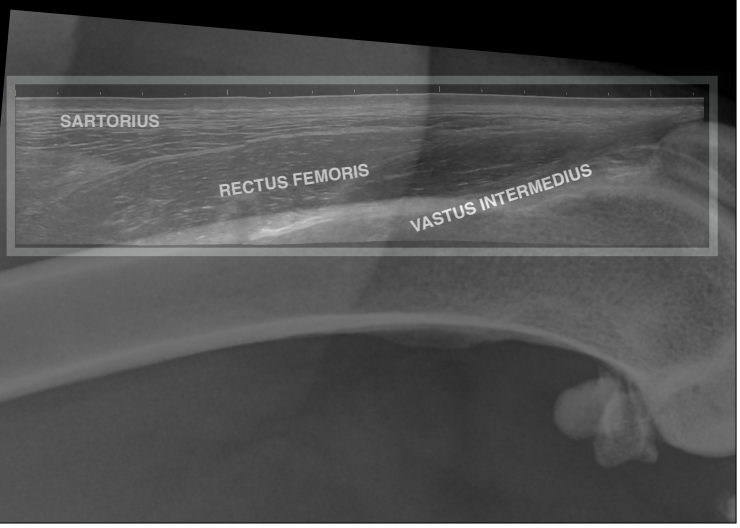

Marta, FI, 1 year

Left thigh

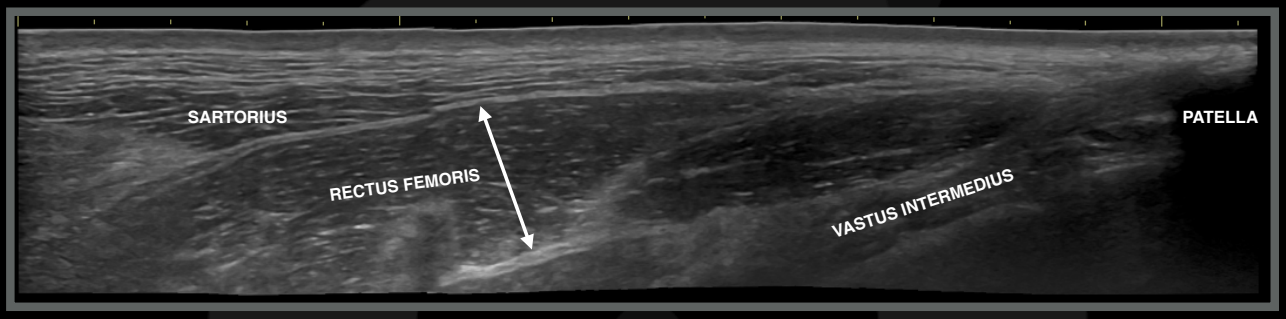

Right thigh

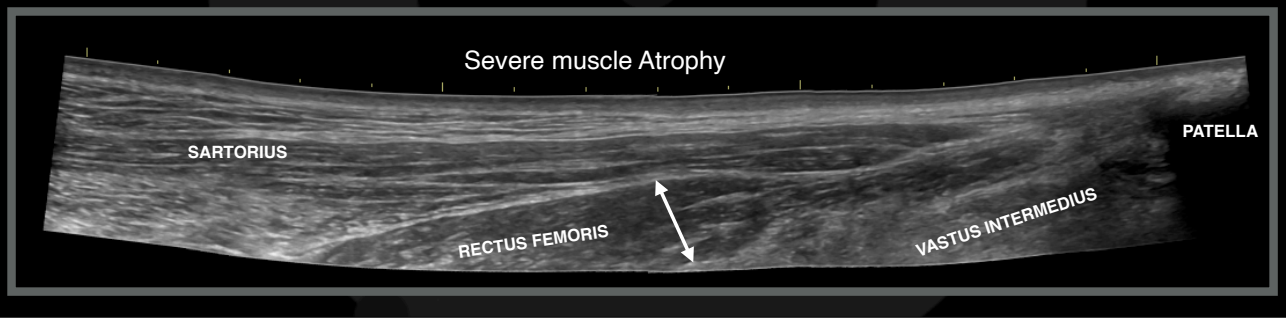

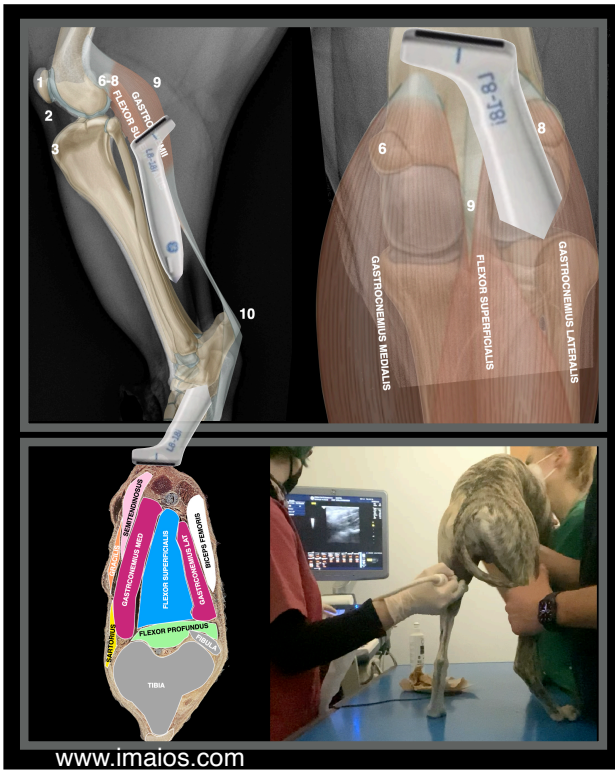

Marta, FI, 1 year

Left stifle

Caudal face transverse scan 9

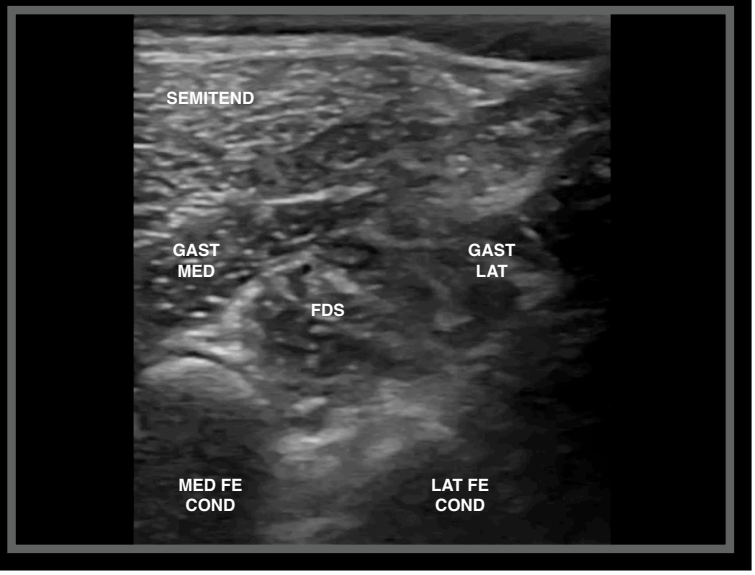

www.imaios.com

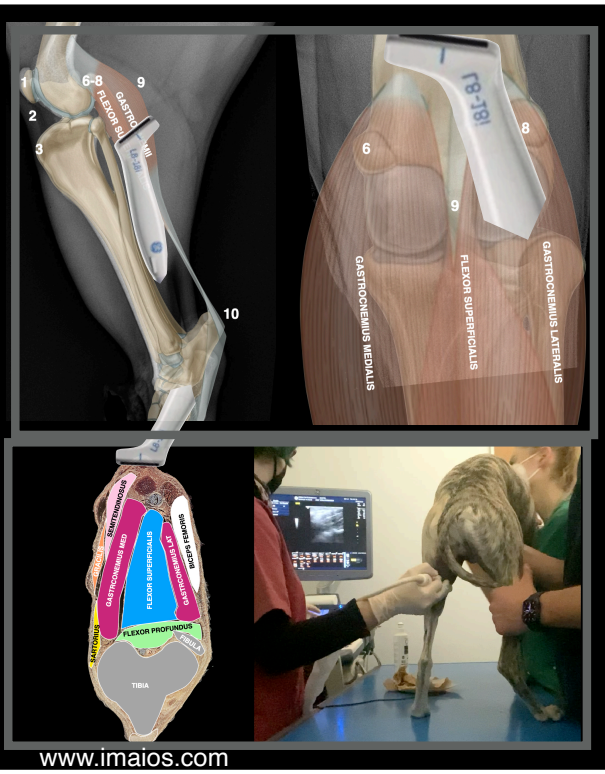

Marta, FI, 1 year

Right stifle

Caudal face transverse scan 9

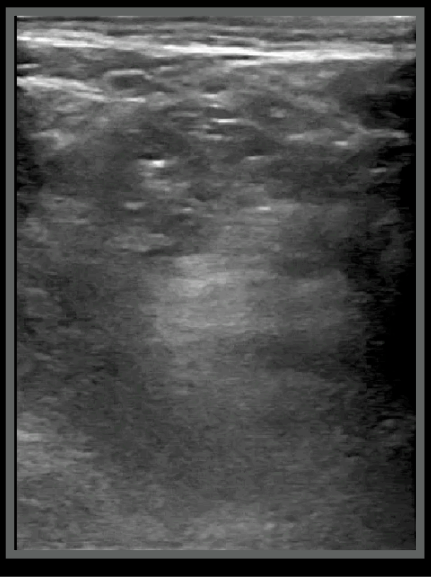

www.imaios.com

Marta, FI, 1 year

Transverse scan, caudal face, thighs

Left thigh 9

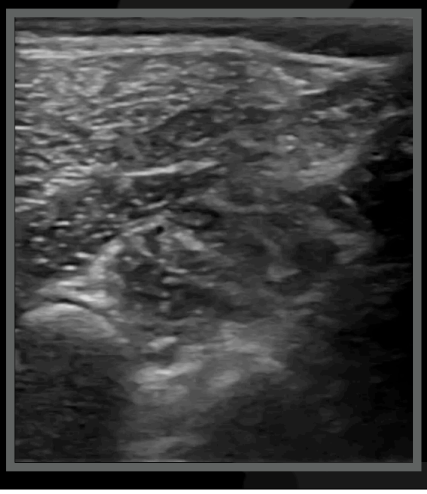

Right thigh 9

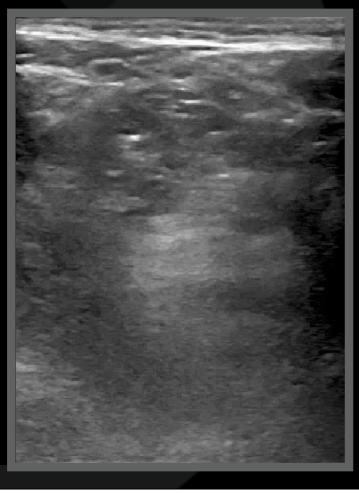

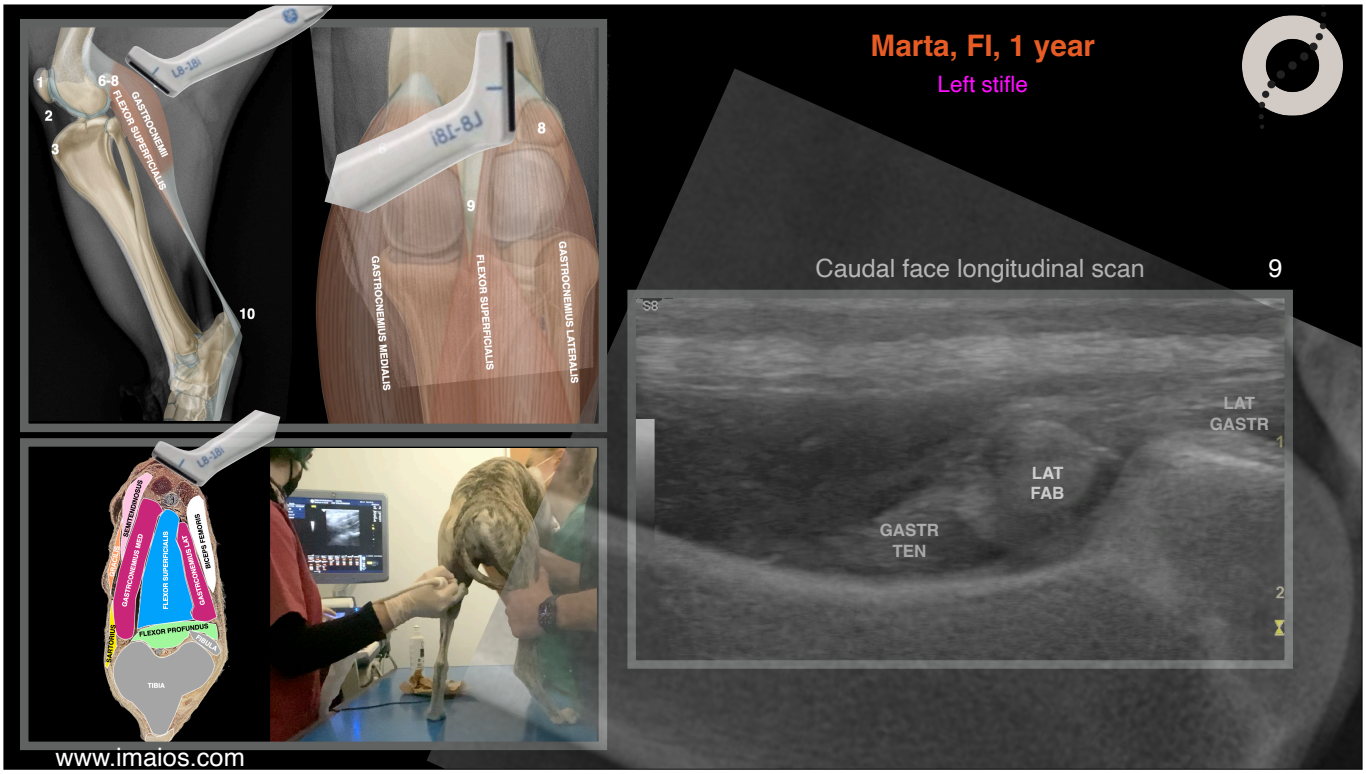
Marta, FI, 1 year
Left stifle
Caudal face longitudinal scan
9
LAT GASTR
LAT FAB
GASTR TEN
GASTROCNEMIUS MEDIALIS
FLEXOR SUPERFICIALIS
GASTROCNEMUS LATERALIS
FLEXOR PROFUNDUS
TIBIA
www.imaios.com

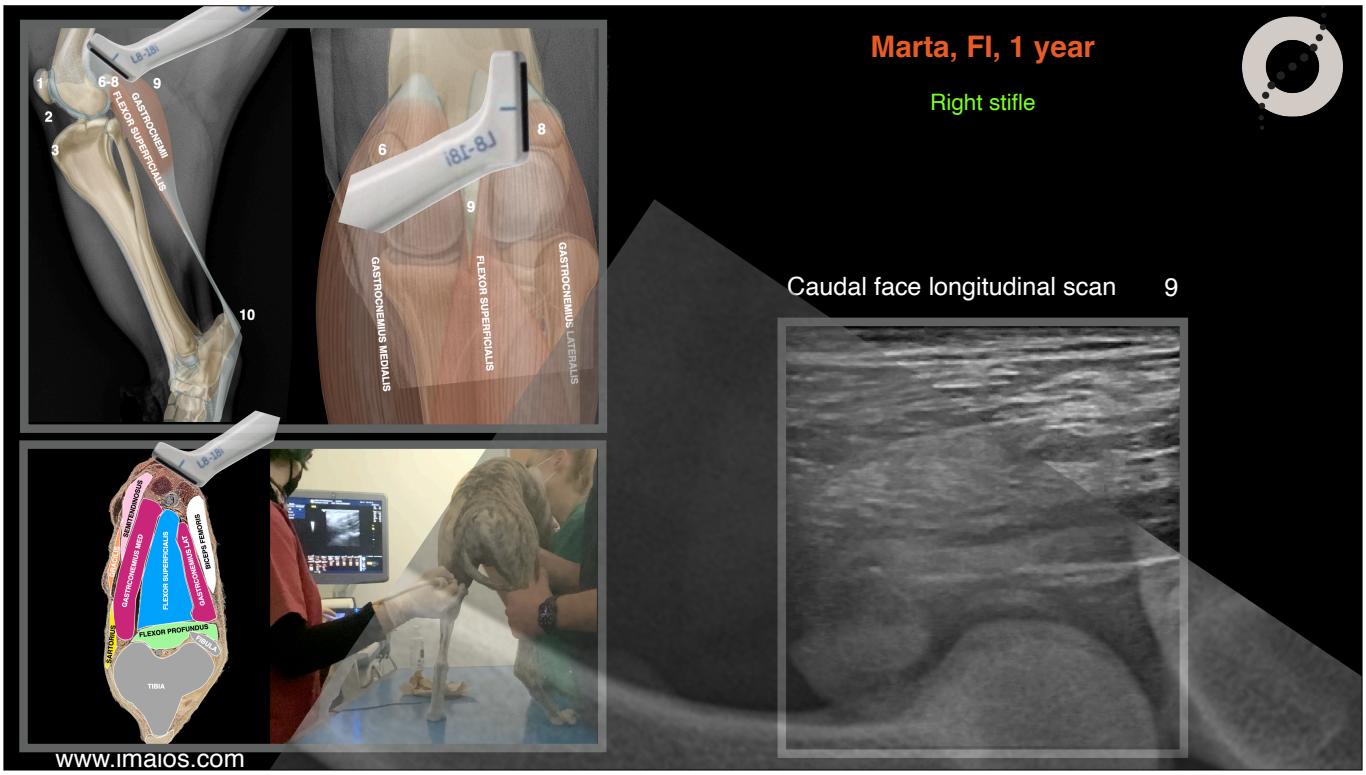
Marta, FI, 1 year
Right stifle
Caudal face longitudinal scan
9
GASTROCNEMIUS MEDIALIS
FLEXOR SUPERFICIALIS
GASTROCNEMIUS LATERALIS
FLEXOR PROFUNDUS
TIBIA
www.imaios.com

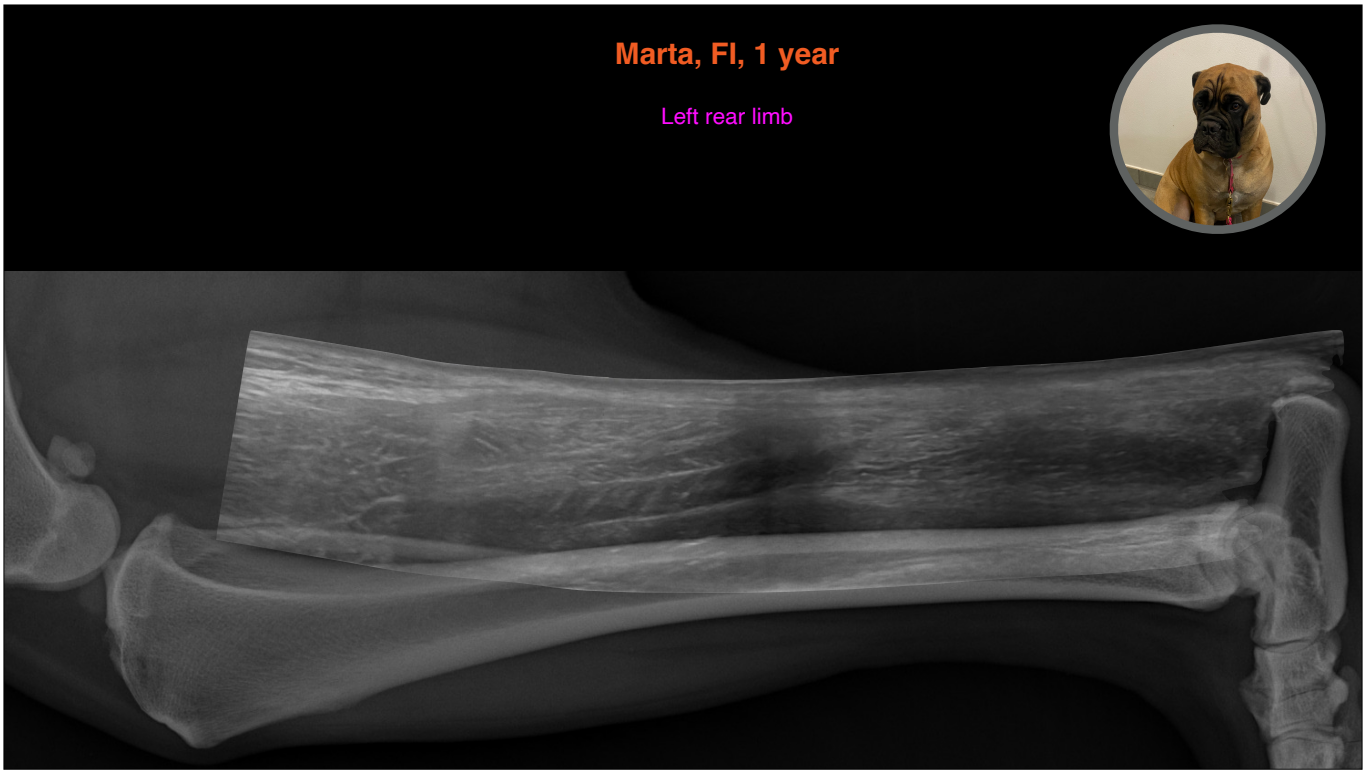
Marta, FI, 1 year
Left rear limb

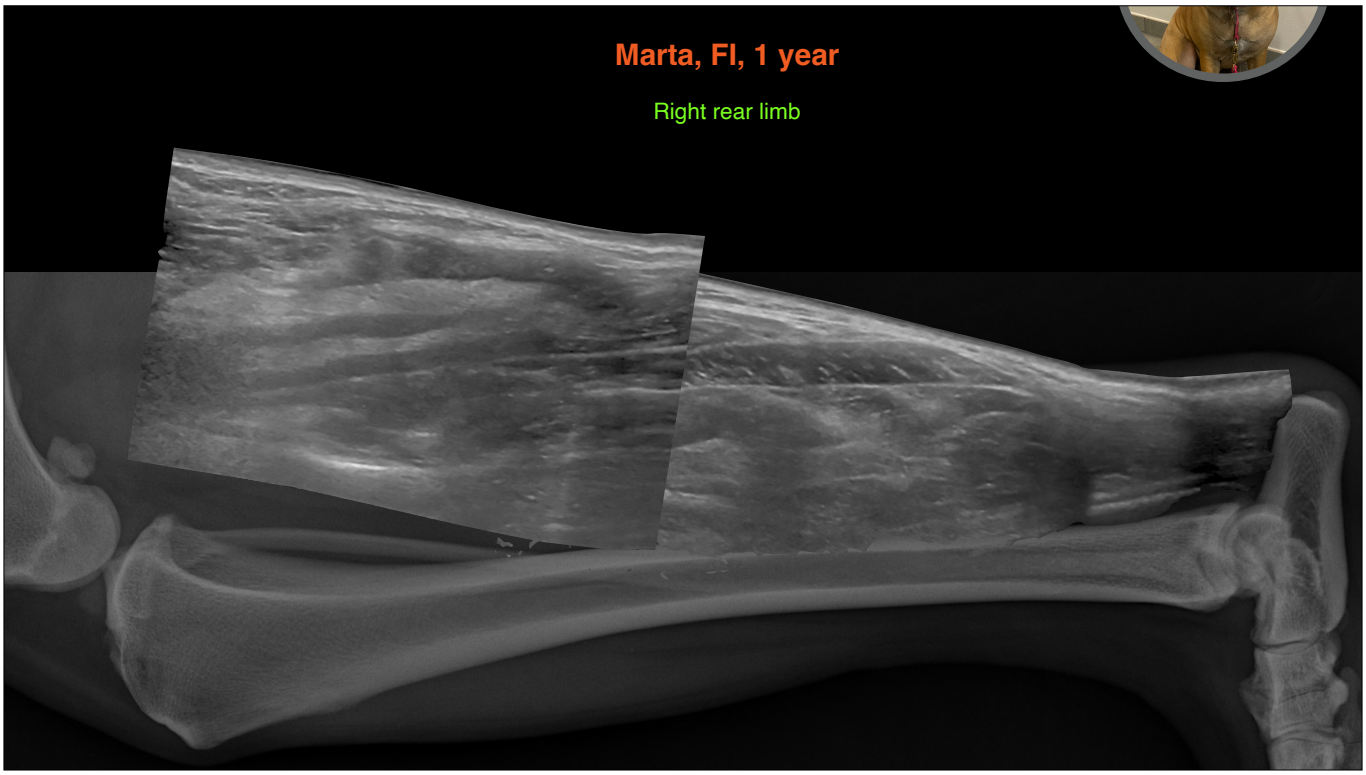
Marta, FI, 1 year
Right rear limb

Marta, FI, 1 year

Longitudinal scan, caudal face, thighs

Left thigh -9/+9

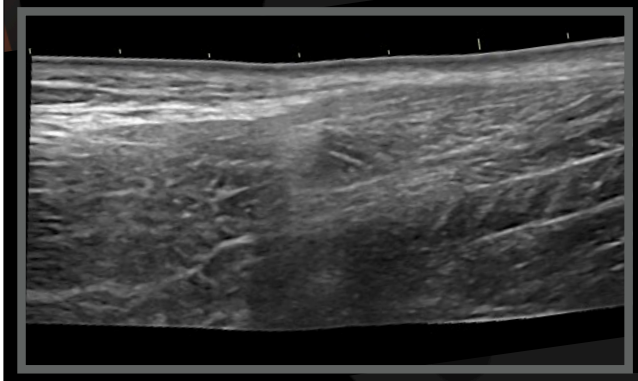

Right thigh -9/+9

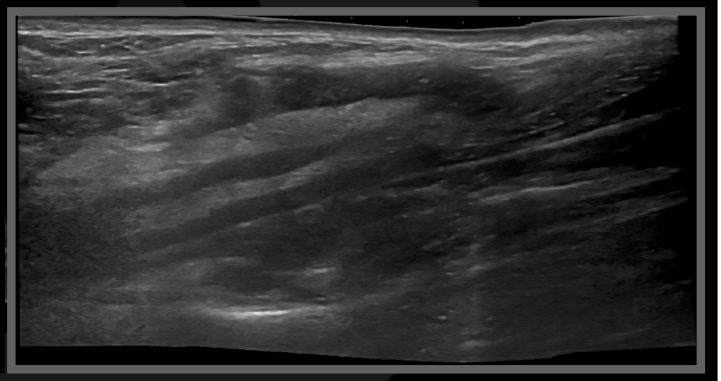

Your evaluation

- Is there tendonitis?
- Is there a ruptured muscle? Which one?
- Is there a not diagnosed fracture or luxation?

Marta, FI, 1 year

Transverse scan, caudal face, thighs

Left thigh 9

Right thigh 9

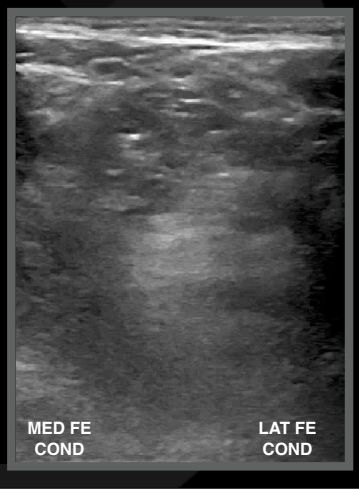

Marta, FI, 1 year

Longitudinal scan, caudal face, thighs

Hypoechoic band, loss of muscle structure

Scattering artifact

Left rear limb -9/+9

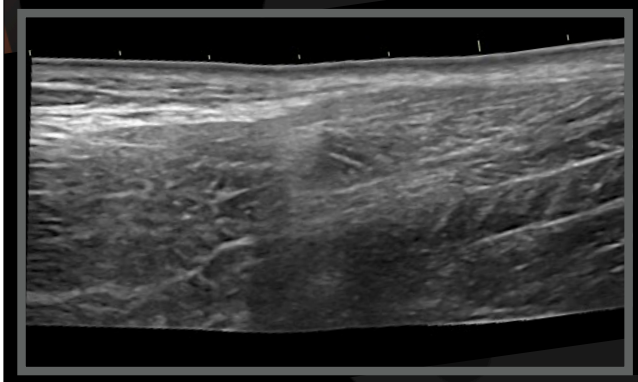

Right rear limb -9/+9

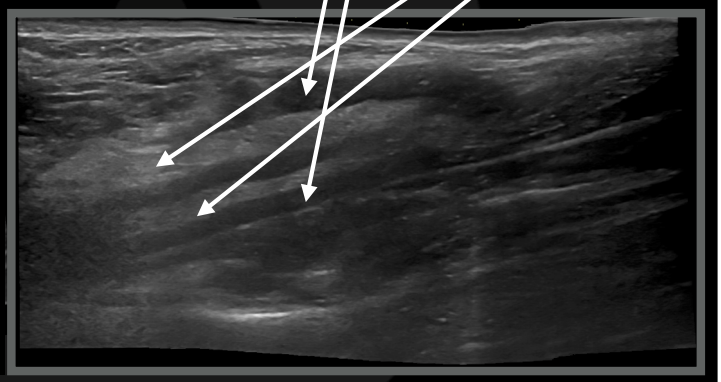

Marta, Bullmastiff, FI, 1 year

Ultrasonographic diagnoses:

- Suspected recurrent and acute rupture of the central portion of the right flexor digitorum muscle
- No ultrasonographic signs of scars or fibrosis

How to arrive to Conclusions:

- PE examination
- Blood works
- Ultrasonographic findings
- Literature

Literature

PubMed.gov

flexor digitorum superficialis dog | Search

Advanced Create alert Create RSS User Guide

Save Email Send to Sorted by: Best match Display options

MY NCBI FILTERS

RESULTS BY YEAR

1977 2023

TEXT AVAILABILITY

- Abstract
- Free full text
- Full text

ARTICLE ATTRIBUTE

- Associated data

ARTICLE TYPE

- Books and Documents
- Clinical Trial
- Meta-Analysis
- Randomized Controlled Trial
- Review
- Systematic Review

PUBLICATION DATE

- 1 year
- 5 years
- 10 years

17 results Page 1 of 2

1 High-Resolution Ultrasonographic Anatomy of the Carpal Tendons of Sporting Border Collies.
Entani MG, Franini A, Barella G, Saleri R, De Rensis F, Spattini G.
Animals (Basel). 2022 Aug 11;12(16):2050. doi: 10.3390/ani12162050.
PMID: 36009639 Free PMC article.
On the lateral face, the tendon of the Extensor Carpi Ulnaris was recognised and followed. On the palmar face, the two heads of the **Flexor** Carpi Ulnaris tendon ending on the accessory carpal bone, the adjacent **Flexor Digitorum** **Superficialis** ...

2 Gross and histological analysis of healing after **dog flexor** tendon repair with the Teno Fix device.
Su BW, Raia FJ, Quitkin HM, Parisien M, Strauch RJ, Rosenwasser MP.
J Hand Surg Br. 2006 Oct;31(5):524-9. doi: 10.1016/j.jhsb.2006.01.006. Epub 2006 Jun 9.
PMID: 16764973
The purpose of this study was to examine the in vivo characteristics of the stainless-steel Teno Fix device used for **flexor** tendon repair. The common **flexor digitorum superficialis** tendon was transected in 16 **dogs** and repaired with the device. . ...

3 Tensile strength of cross-stitch epitenon suture.
Kim PT, Aoki M, Tokita F, Ishii S.
J Hand Surg Br. 1996 Dec;21(6):821-3. doi: 10.1016/s0266-7681(96)80200-2.
PMID: 8982937
Using a computerized tensiometer, the mechanical properties of two types of repair in the canine **flexor digitorum superficialis** tendon were examined. The slope and ultimate tensile strength of a cross-stitch epitenon suture were compared to those of a simple ...

4 Angiogenesis in healing autogenous **flexor**-tendon grafts.
Gelberman RH, Chu CR, Williams CS, Seiler JG 3rd, Amiel D.
J Bone Joint Surg Am. 1992 Sep;74(8):1207-16.
PMID: 1383229
On the basis of recent evidence that **flexor** tendon grafts may heal without the ingrowth of vascular adhesions, eighteen autogenous donor tendons of intrasynovial and extrasynovial origin were transferred to the synovial sheaths in the forepaws of nine **dogs**, and cont ...

Literature

PubMed.gov

achille's tendon muscular rupture canine | Search

Advanced Create alert Create RSS User Guide

Save Email Send to Sorted by: Best match Display options

MY NCBI FILTERS

RESULTS BY YEAR

1997 2023

TEXT AVAILABILITY

- Abstract
- Free full text
- Full text

ARTICLE ATTRIBUTE

- Associated data

ARTICLE TYPE

- Books and Documents
- Clinical Trial
- Meta-Analysis
- Randomized Controlled Trial

3 results Page 1 of 1

1 Ultrasonographic examination of injuries to the **achilles tendon** in **dogs** and cats.
Kramer M, Gerwing M, Michele U, Schimke E, Kindler S.
J Small Anim Pract. 2001 Nov;42(11):531-5. doi: 10.1111/j.1748-5827.2001.tb06022.x.
PMID: 11721980 Clinical Trial.
The value of ultrasonography in the diagnosis of lesions of the **Achilles tendon** was investigated in 42 **dogs** and seven cats. A standardised four-part ultrasonographic examination was established. ...Ultrasonography therefore proved to be an excellent diagnosti ...

2 Sonography of the musculoskeletal system in **dogs** and cats.
Kramer M, Gerwing M, Hach V, Schimke E.
Vet Radiol Ultrasound. 1997 Mar-Apr;38(2):139-49. doi: 10.1111/j.1740-8261.1997.tb00829.x.
PMID: 9238783
Sonography of the musculoskeletal system in **dogs** and cats was undertaken to evaluate the application of this imaging procedure in orthopedics. ...Most of the diseases that are in the area of the biceps or the **achilles tendon**, such as dislocation of the **ten** ...

3 [Diseases of the **Achilles tendon** in **dogs** and cats].
Kramer M, Schimke E, Gerwing M, Schleich S, Michele U.
Tierarztl Prax Ausg K Kleintiere Heimtiere. 1998 Jul;26(4):238-46.
PMID: 9710932 German.
Dogs and cats rarely have problems with the **Achilles tendon** and if so, it usually results from a direct trauma. ...**Tendon** suture is advisable if the **rupture** is open, fresh and/or complete and in cases of luxation of the superficial digital flexo ...

Literature

PubMed.gov

soleus muscle rupture ultrasound | Search

Advanced Create alert Create RSS User Guide

Save Email Send to Sorted by: Best match Display options

MY NCBI FILTERS

RESULTS BY YEAR

1966 2023

TEXT AVAILABILITY

- Abstract
- Free full text
- Full text

ARTICLE ATTRIBUTE

- Associated data

ARTICLE TYPE

- Books and Documents
- Clinical Trial
- Meta-Analysis
- Randomized Controlled Trial
- Review

2,574 results Page 1 of 258

1 Cite Share
Shoulder Injuries in the Overhead-Throwing Athlete: Epidemiology, Mechanisms of Injury, and **Imaging** Findings.
Lin DJ, Wong TT, Kazam JK.
Radiology. 2018 Feb;286(2):370-387. doi: 10.1148/radiol.2017170481.
PMID: 29356641 Review.
The unparalleled velocity achieved by overhead throwers subjects the shoulder to extreme forces, resulting in both adaptive changes and pathologic findings that can be detected at **imaging**. A key biomechanical principle of throwing is achieving maximum external rotation, wh ...

2 Cite Share
Diagnosis and Management of Partial Thickness Rotator Cuff Tears: A Comprehensive Review.
Plancher KD, Shanmugam J, Briggs K, Petterson SC.
J Am Acad Orthop Surg. 2021 Dec 15;29(24):1031-1043. doi: 10.5435/JAAOS-D-20-01092.
PMID: 34520444 Review.
Optimal management of PRCTs continues to be controversial. Although advances in magnetic resonance **imaging** and **ultrasonography** have aided in early diagnosis, arthroscopic evaluation remains the benchmark for diagnosis. ...

3 Cite Share
Assessment of Functional Conservative Treatment of Acute Complete Achilles Tendon **Rupture**.
Steinfeld Y, Akian R, Rovitsky A, Puchkov N, Keren Y.
Isr Med Assoc J. 2021 Aug;23(8):510-515.
PMID: 34392629 Free article.
BACKGROUND: In recent years, treatment for Achilles tendon **rupture** (ATR) went through radical changes: from the conservative non-weight bearing approach to a functional protocol. ...There was statistically significant reduction in the calf circumference and **soleus** ...

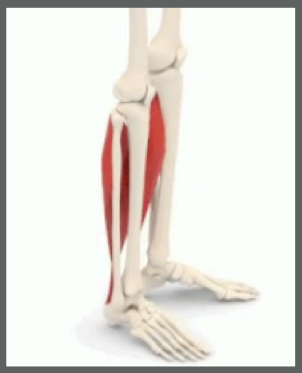

Books

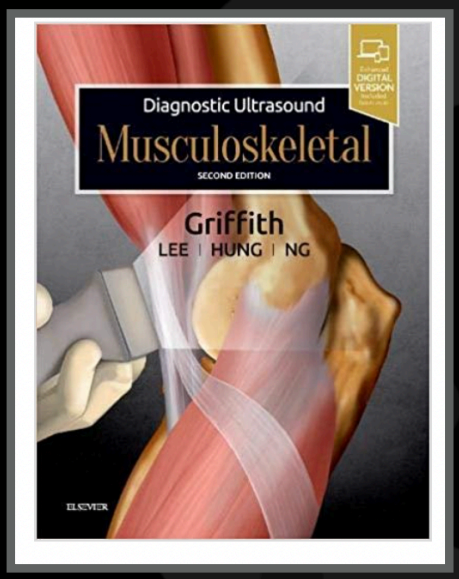

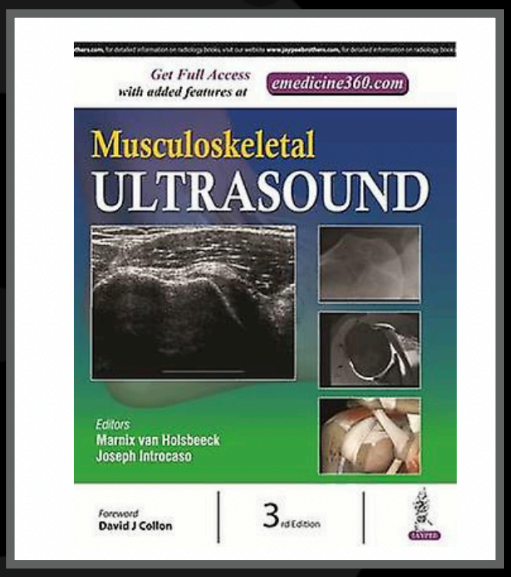

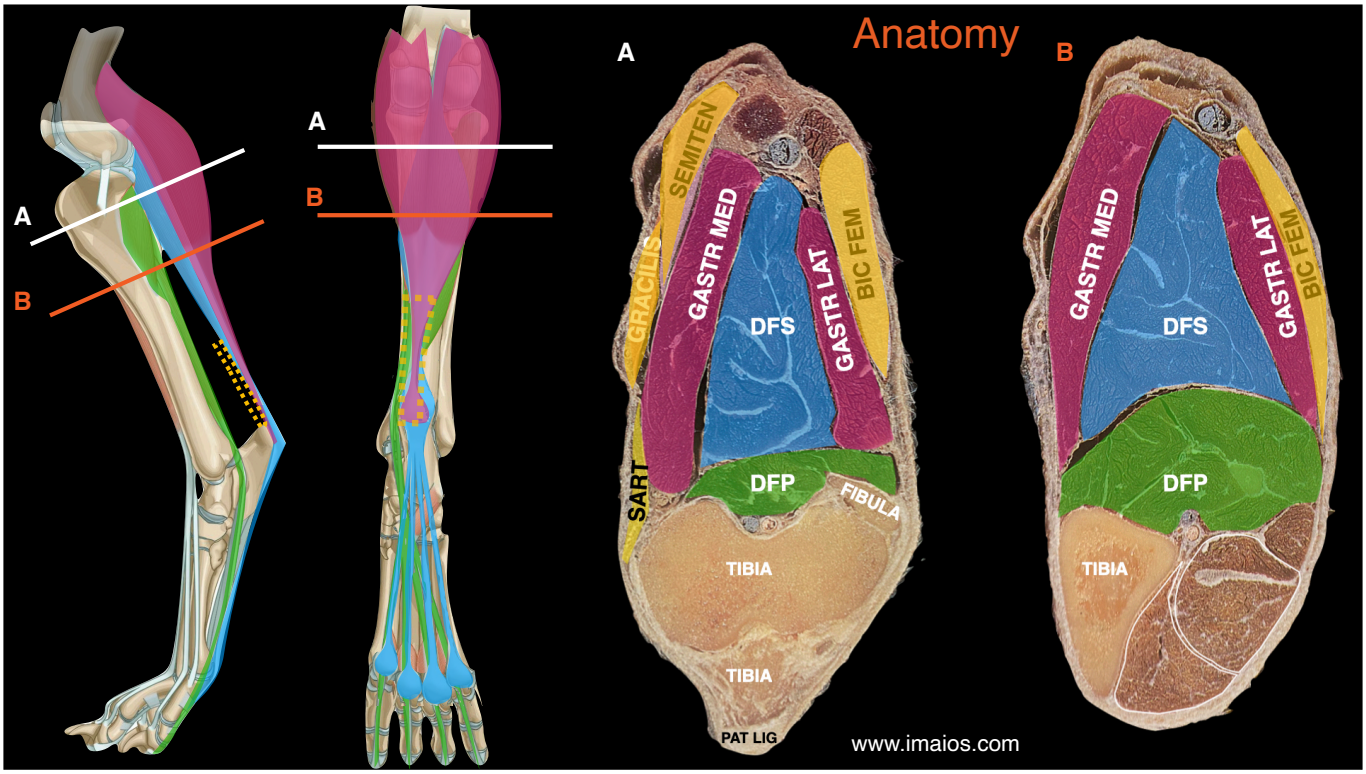

Marta, Bullmastiff, FI, 1 year

Conclusions:

- Recurrent rupture of the right flexor superficialis muscle
- Advised to discuss the case with a sports medicine specialist
- Follow up in three months

Marta, Bullmastiff, FI, 15 months

- Not lame but persistent right side mild muscle atrophy
- More active and happy
- One episode of acute lameness after playing for three hours with a puppy

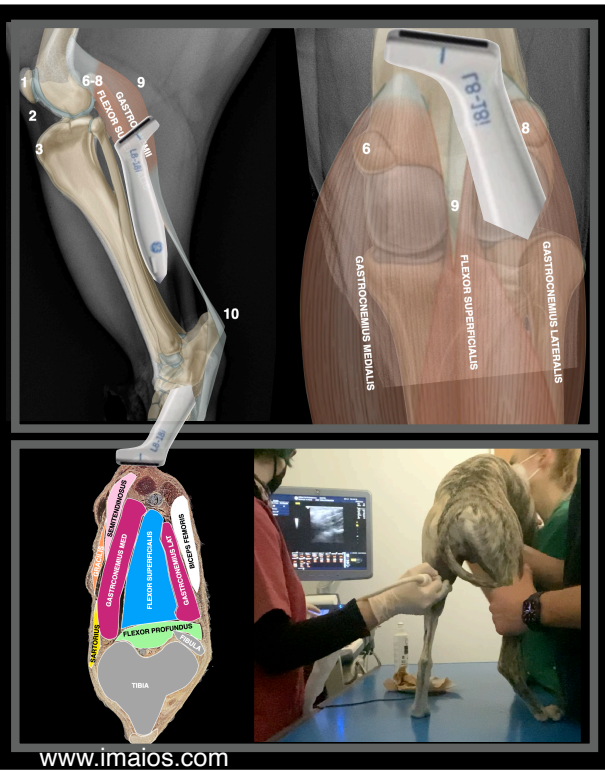

Marta, FI, 1 year

Right stifle

Three months later

Caudal face transverse scan 9

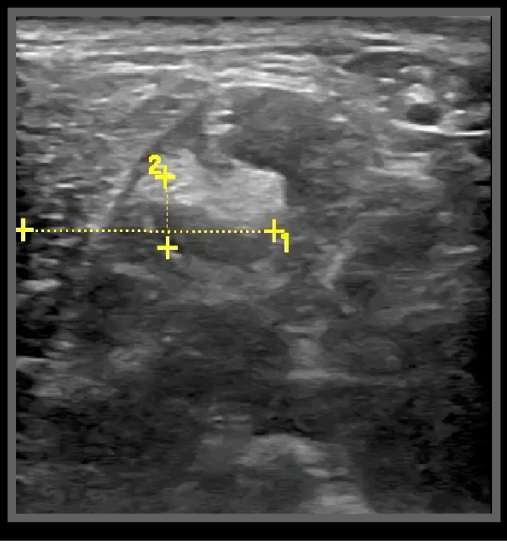

Marta, FI, 1 year

Transverse scan, caudal face, thighs

Right thigh Time zero

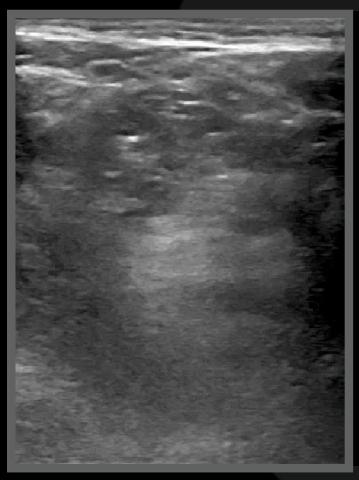

Right thigh Three months later

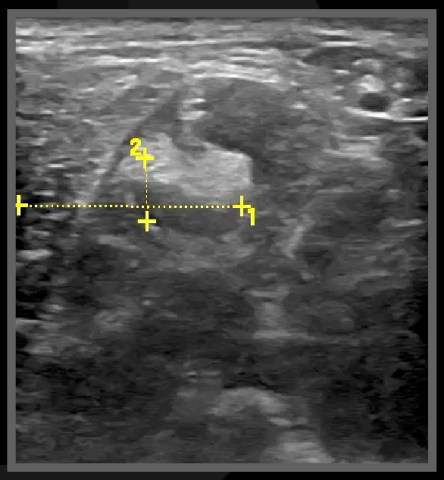

Marta, FI, 1 year

Longitudinal scan, caudal face, thighs

Right rear limb

Time zero

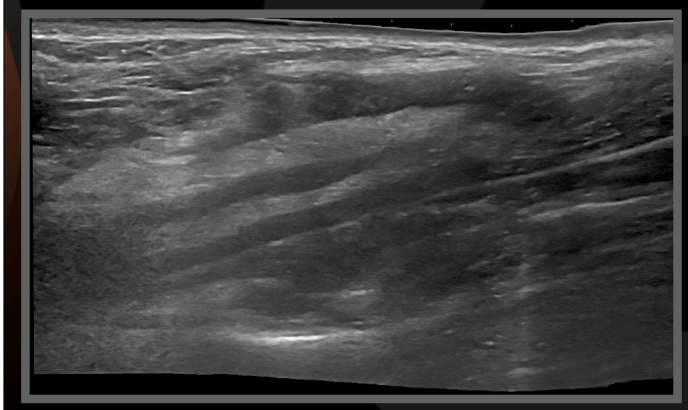

Right rear limb

Three months later

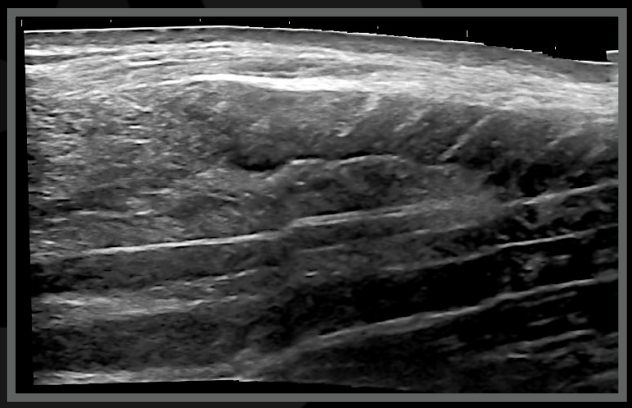

Marta, FI, 15 months

Time zero

Three months later

Key points to diagnose partial muscle avulsion

- Scattering artefact + clinical pain
- Mild displacement
- Different diameter
- Loss of fibrillar pattern

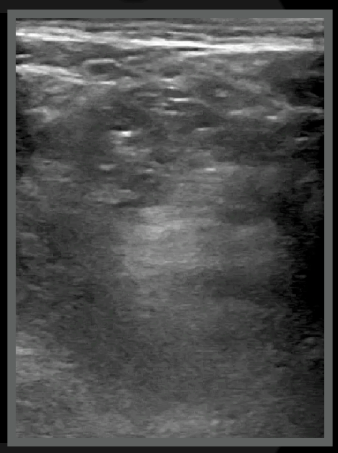

Marta, Bullmastiff, FI, 24 months

- She won her first beauty contest
- Nothing abnormal was detected

Mollie, Bearded Collies, FS, 6 years

- After playing with friends, toe touching lame left hindlimb
- She was lame for three days four months ago, same limb, responded well to NSAD
- This time still lame one week later and is only minimally responding to NSAD

Mollie, Bearded Collies, FS, 6 years

- Positive drawer sign left hindlimb on PE
- Thickened left stifle
- No other evident complains
- Today sedation and radiographs
- Unremarkable spine and hip joints

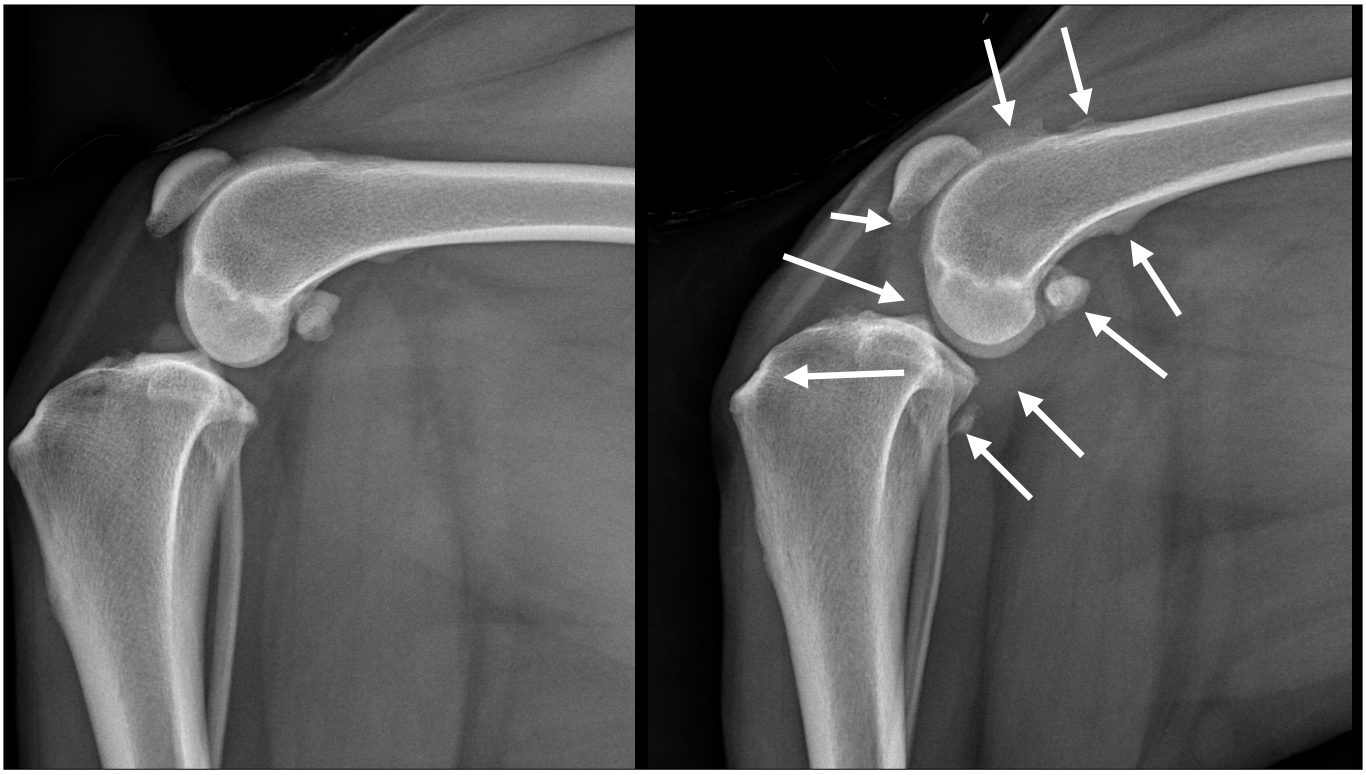

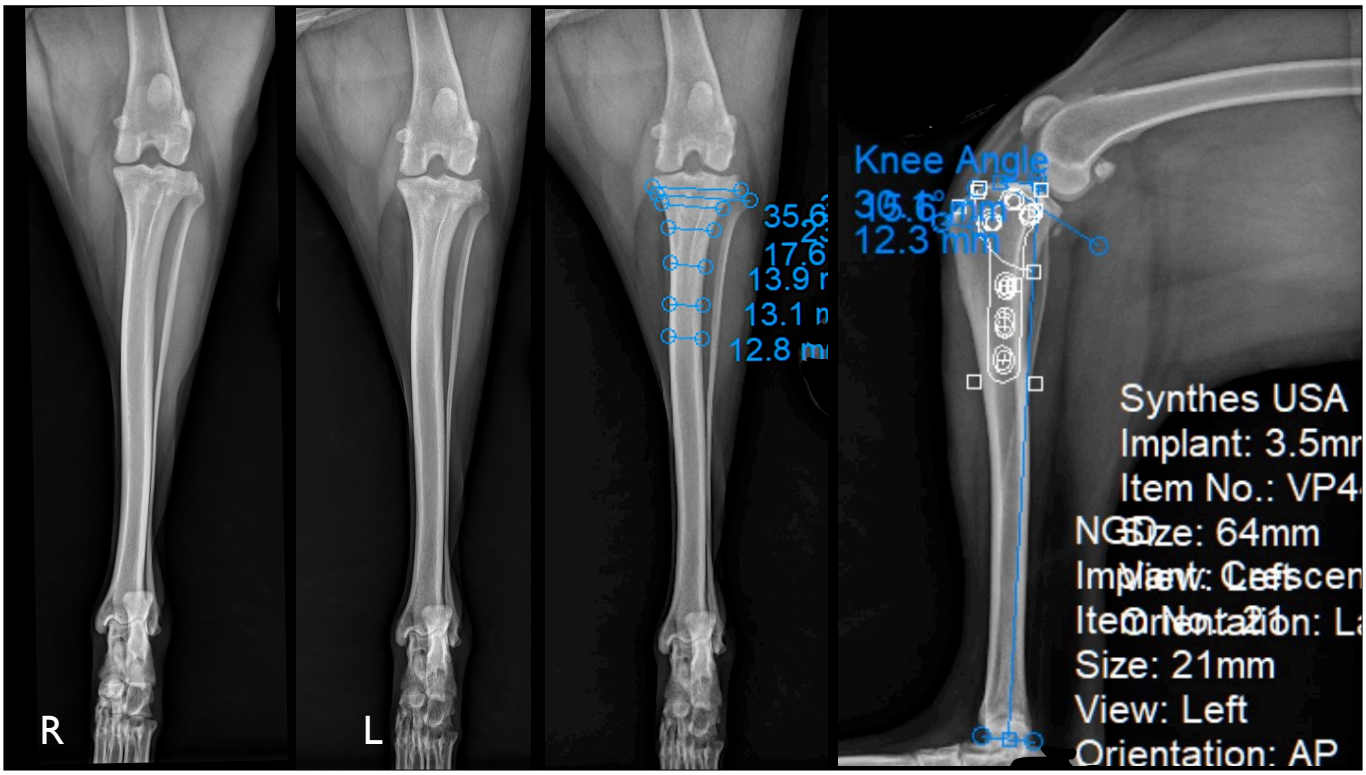
R
L
Knee Angle
12.3 mm
Synthes USA
Size: 64mm
Size: 21mm
View: Left
Orientation: AP

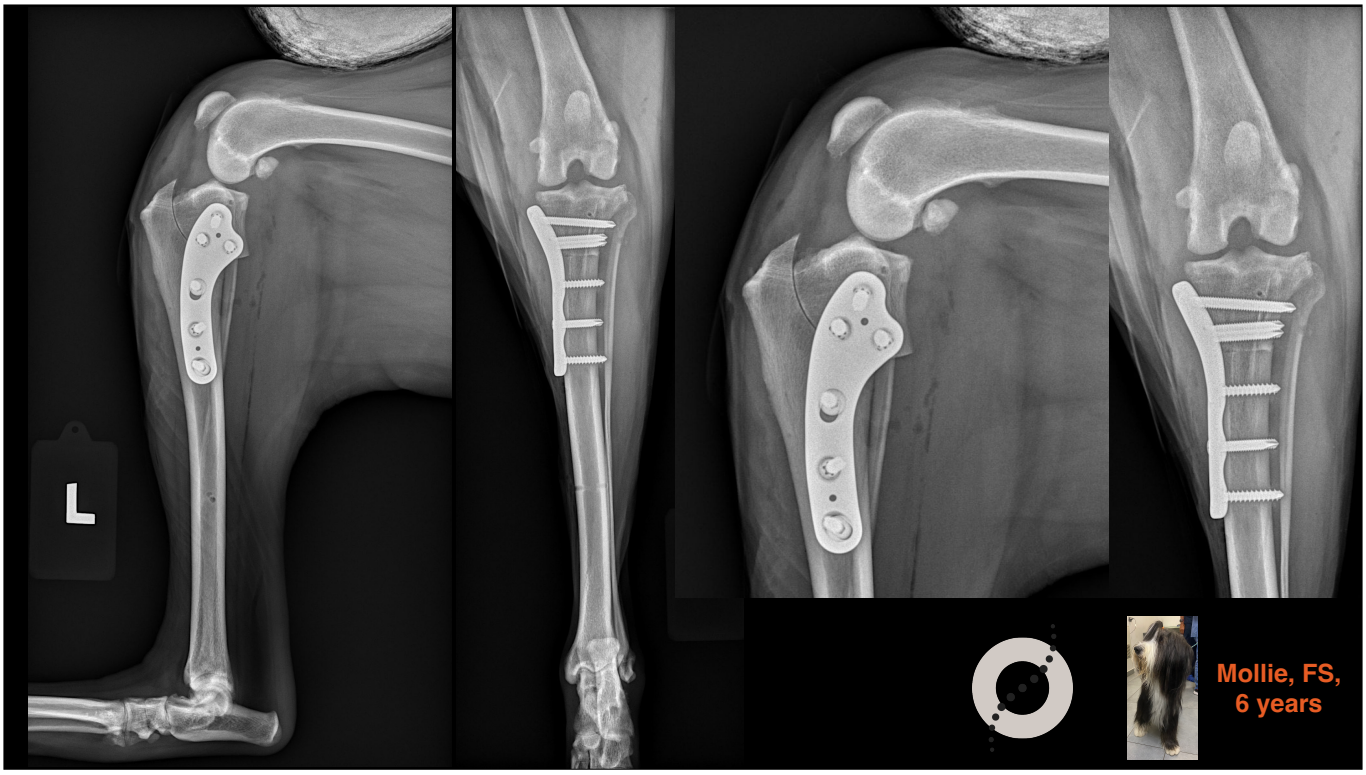
L
Mollie, FS,
6 years

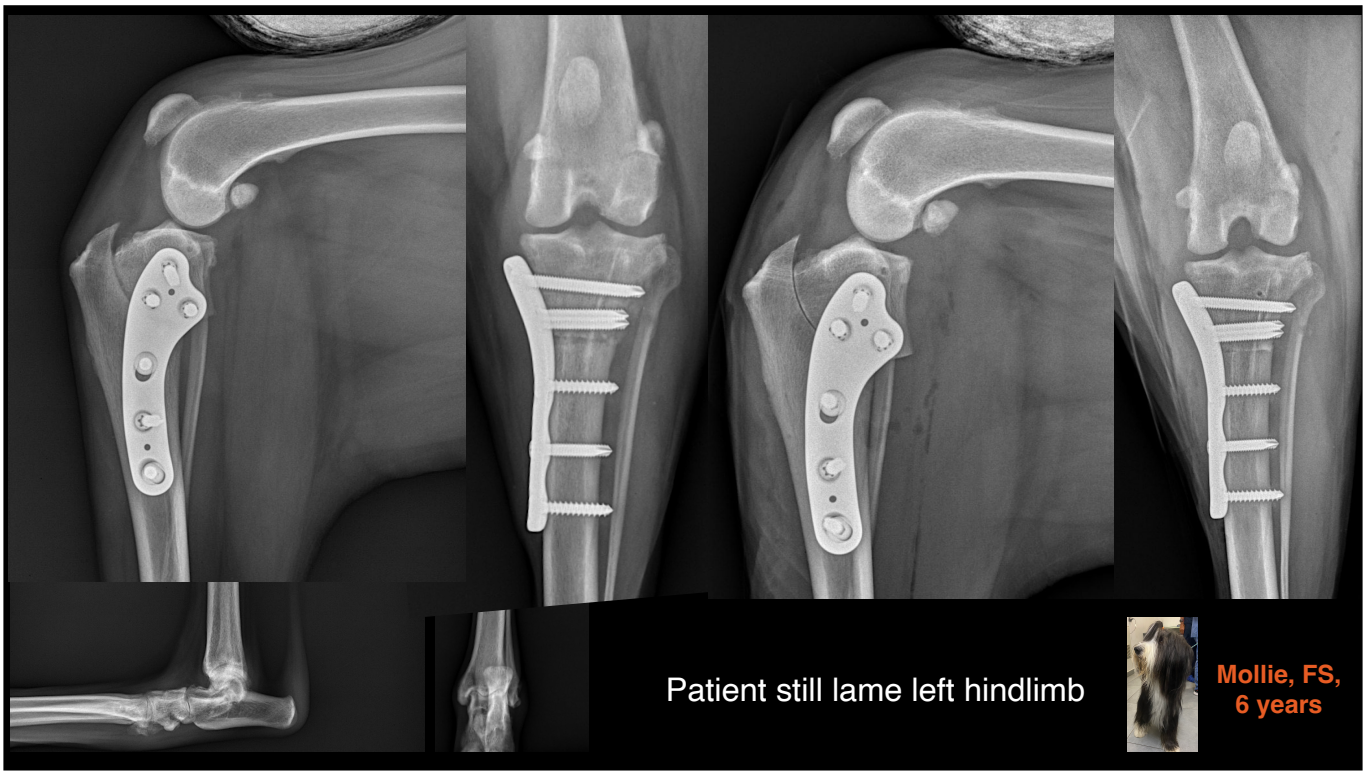
Patient still lame left hindlimb
Mollie, FS,
6 years

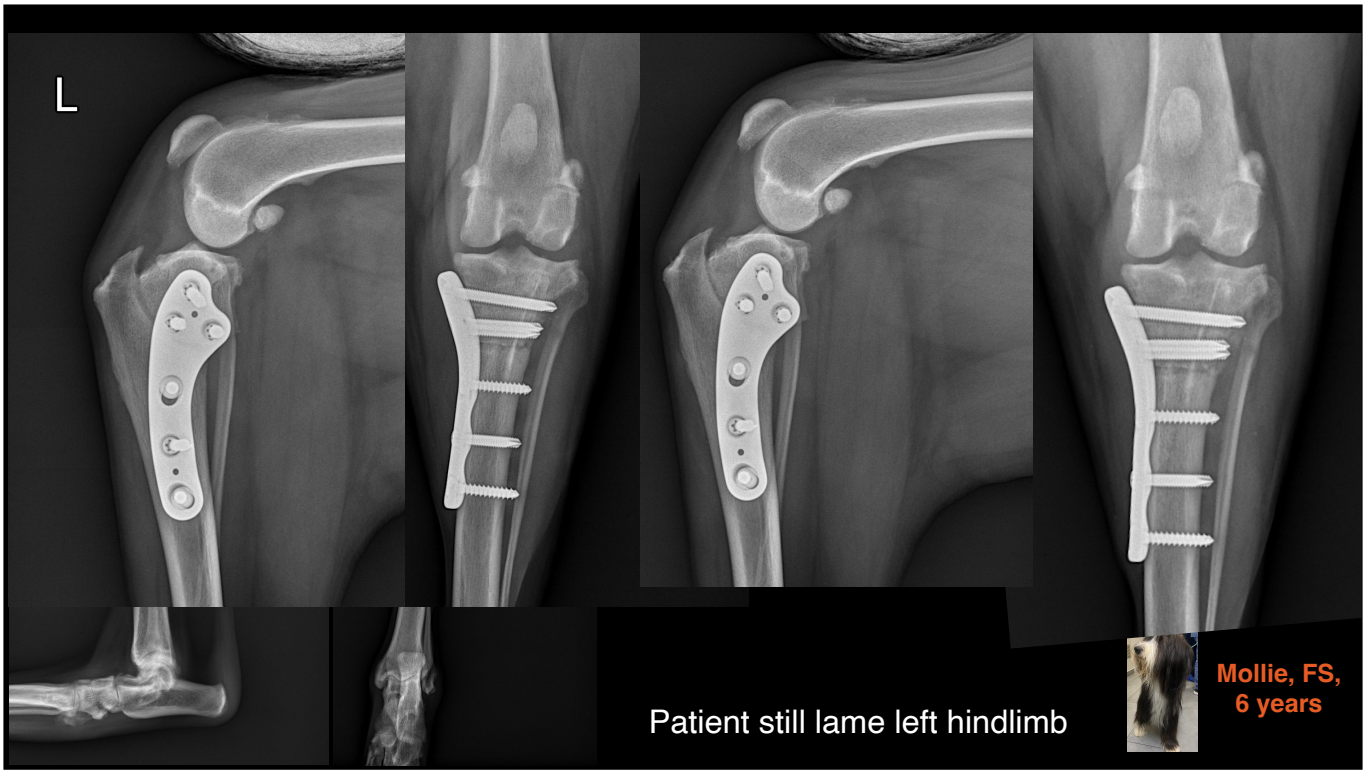

Mollie, Bearded Collies, FS, 6 years

- Satisfactory healing of the left TPLO
- Patient still lame especially when running
- Toe touching when standing
- Otherwise healthy
-

Next step:

Mollie, Bearded Collies, FS, 6 years

Next step:

- Blood works to rule out systemic inflammation/ check for infection/infective disease
- Synovial cytology/culture
- PE under anaesthesia - CdCr - Meniscus
- Arthroscopy
- More imaging
  - MRI
  - US

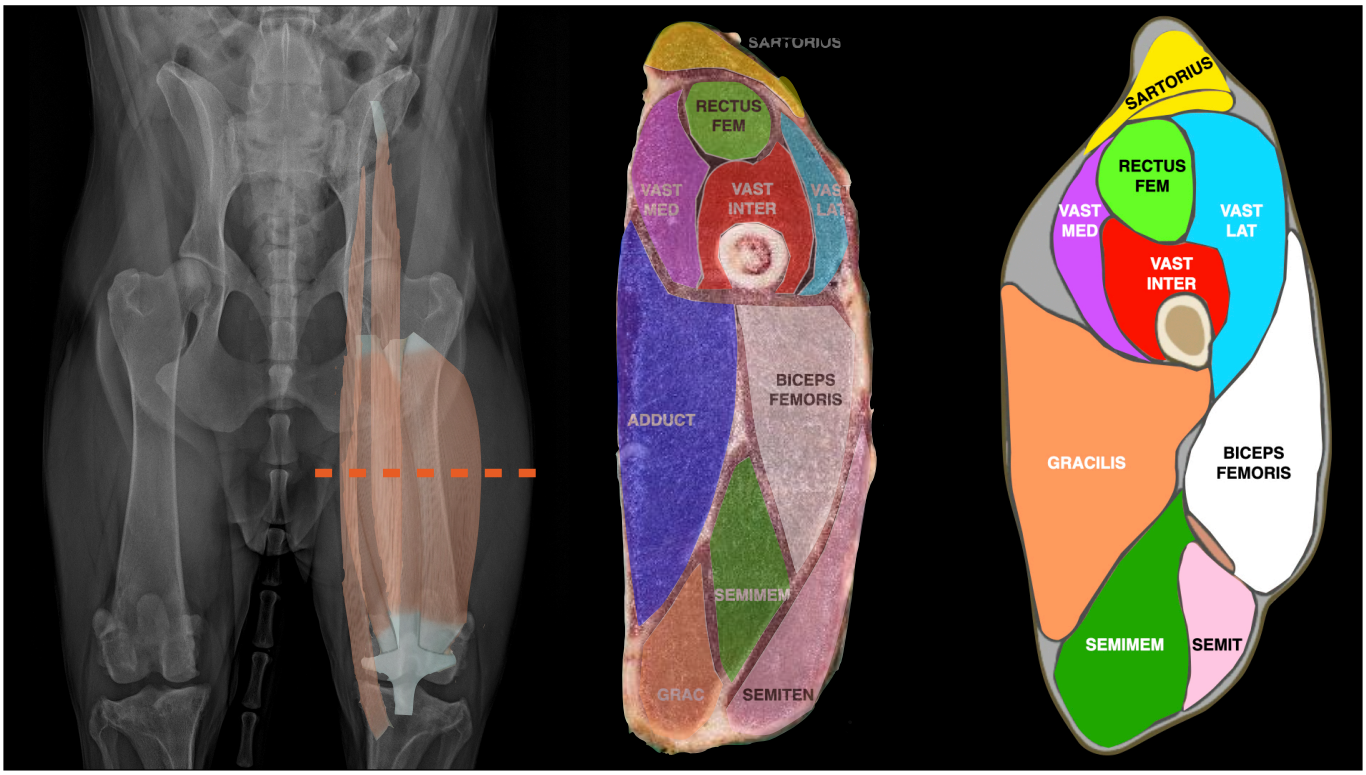

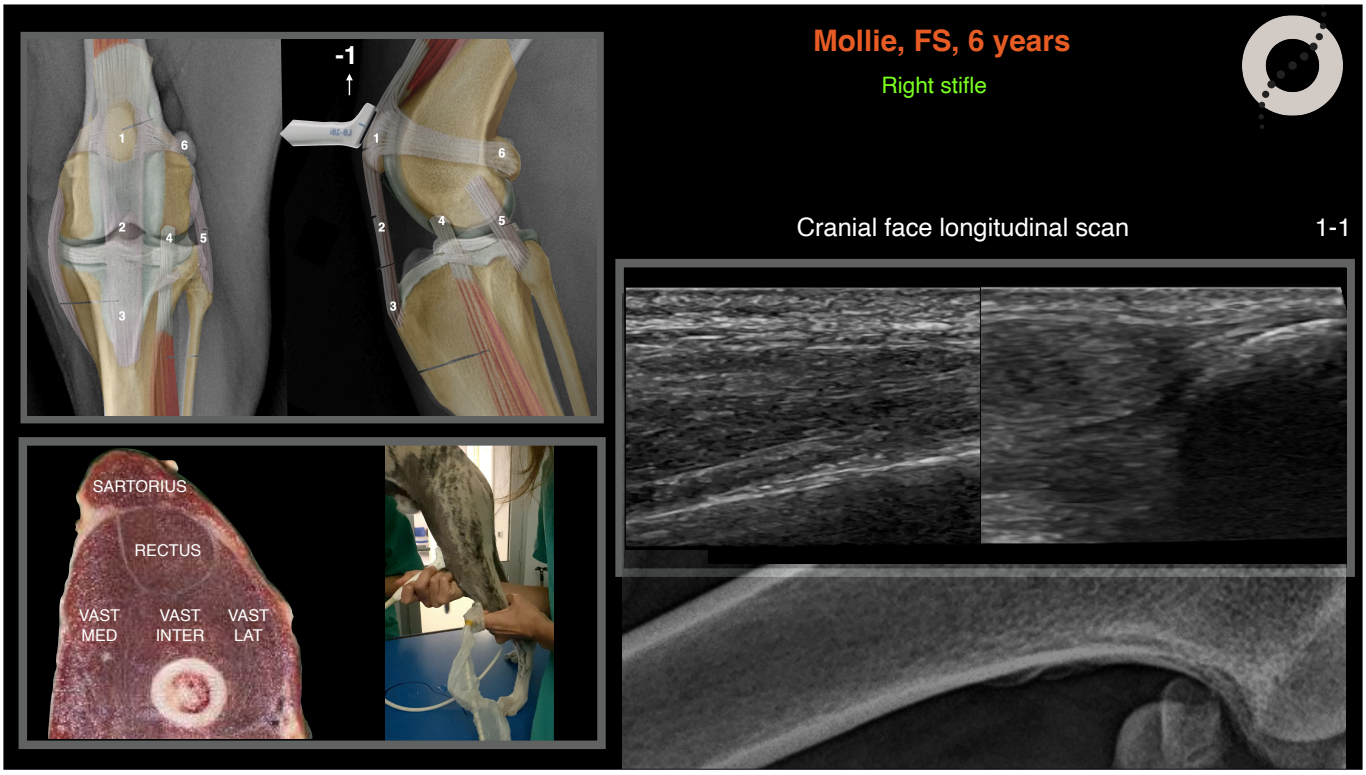
Mollie, FS, 6 years
Right stifle
Cranial face longitudinal scan
1-1
-1
SARTORIUS
RECTUS
VAST MED
VAST INTER
VAST LAT

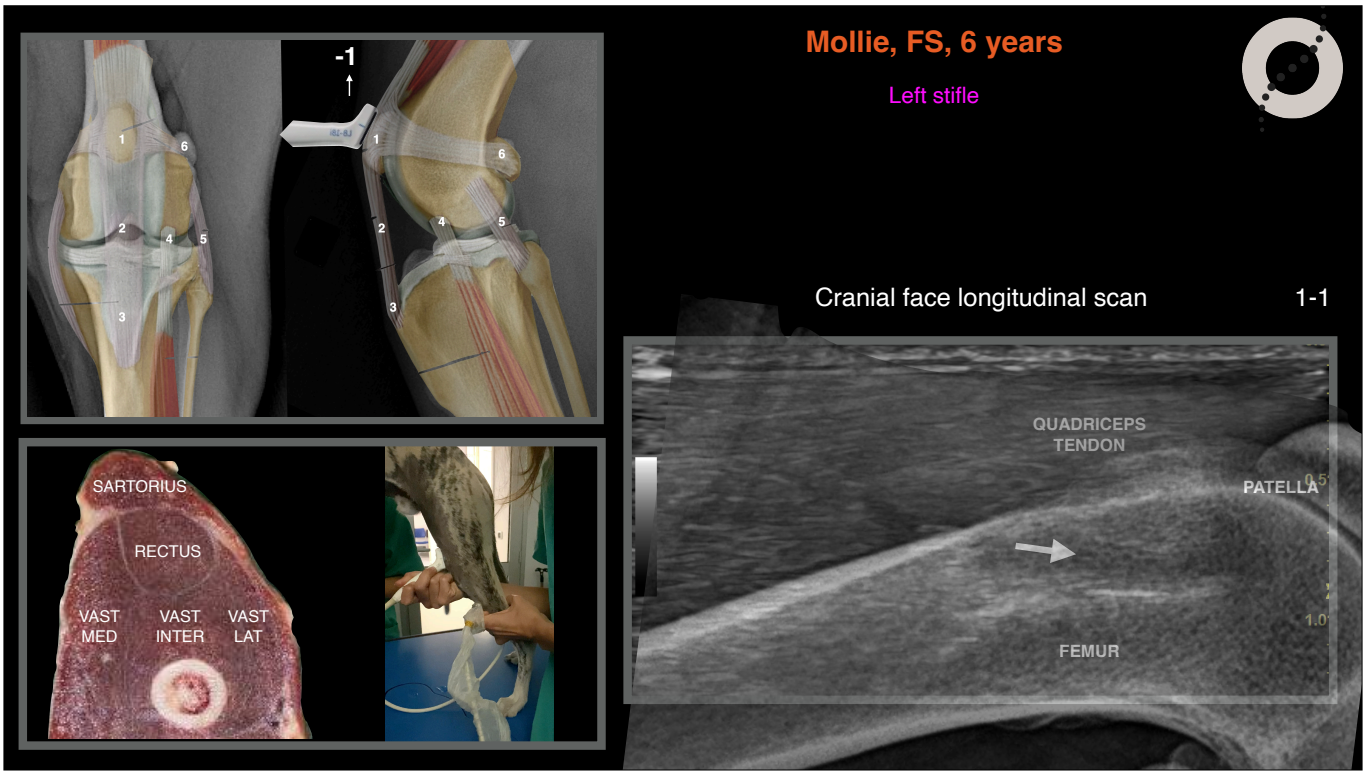
Mollie, FS, 6 years
Left stifle
Cranial face longitudinal scan
1-1
-1
SARTORIUS
RECTUS
VAST MED
VAST INTER
VAST LAT
QUADRICEPS TENDON
PATELLA
FEMUR

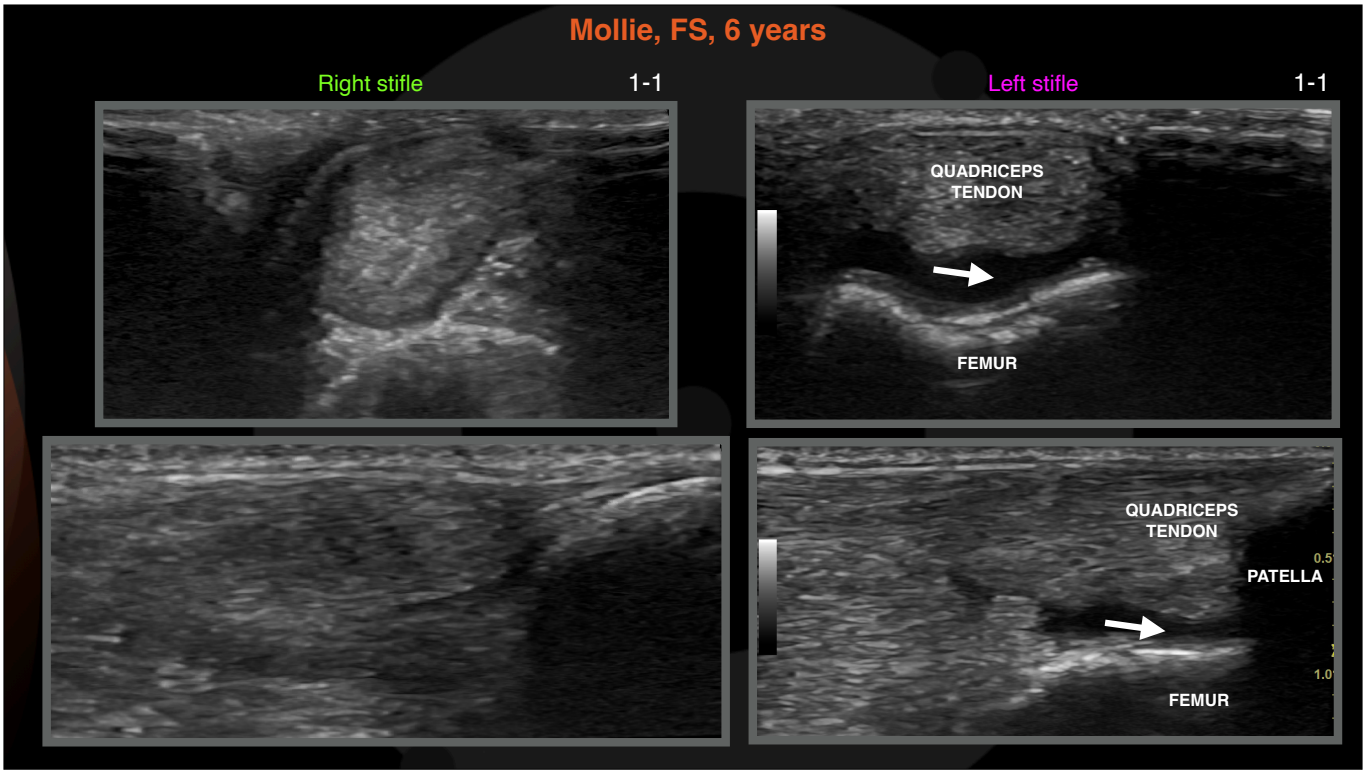
Mollie, FS, 6 years
Right stifle
1-1
Left stifle
1-1
QUADRICEPS
TENDON
FEMUR
QUADRICEPS
TENDON
PATELLA
FEMUR

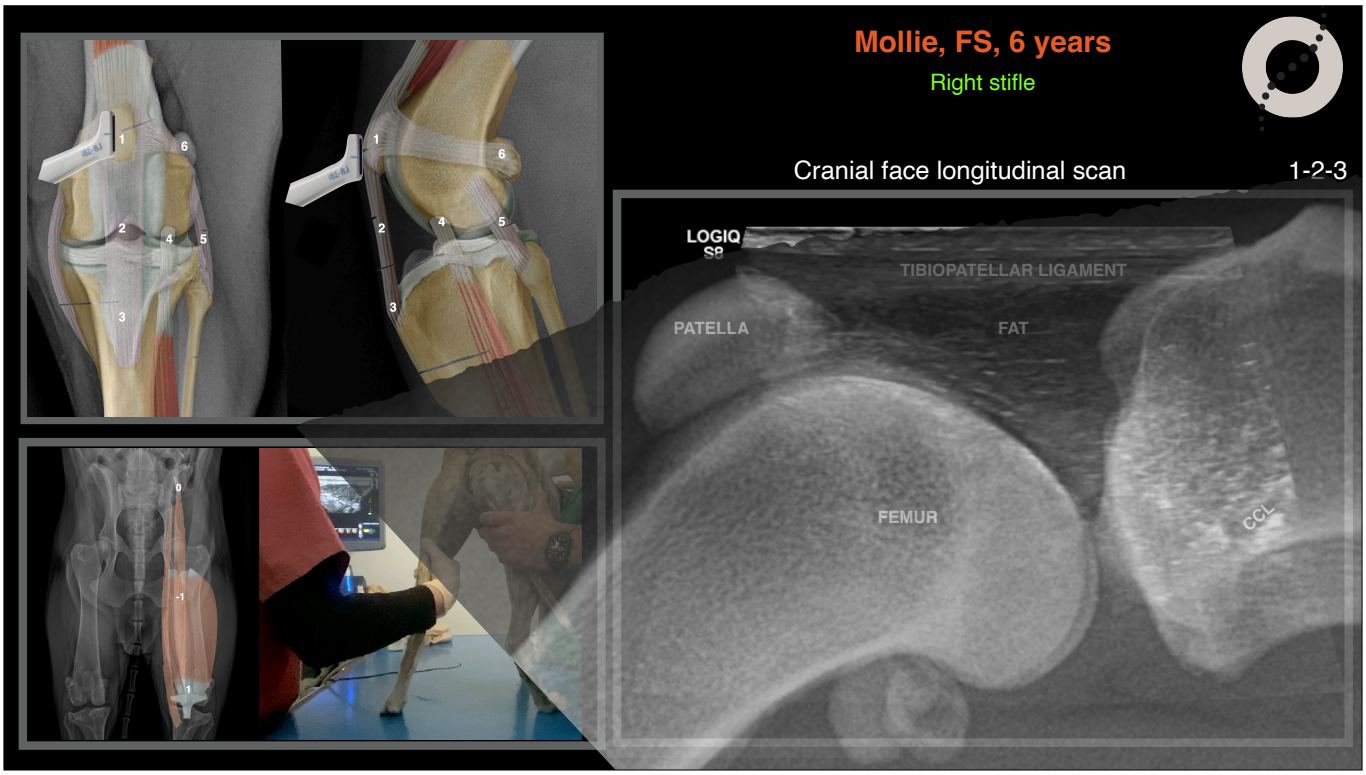
Mollie, FS, 6 years
Right stifle
Cranial face longitudinal scan
1-2-3
LOGIQ
S8
TIBIOPATELLAR LIGAMENT
PATELLA
FAT
FEMUR
CCL

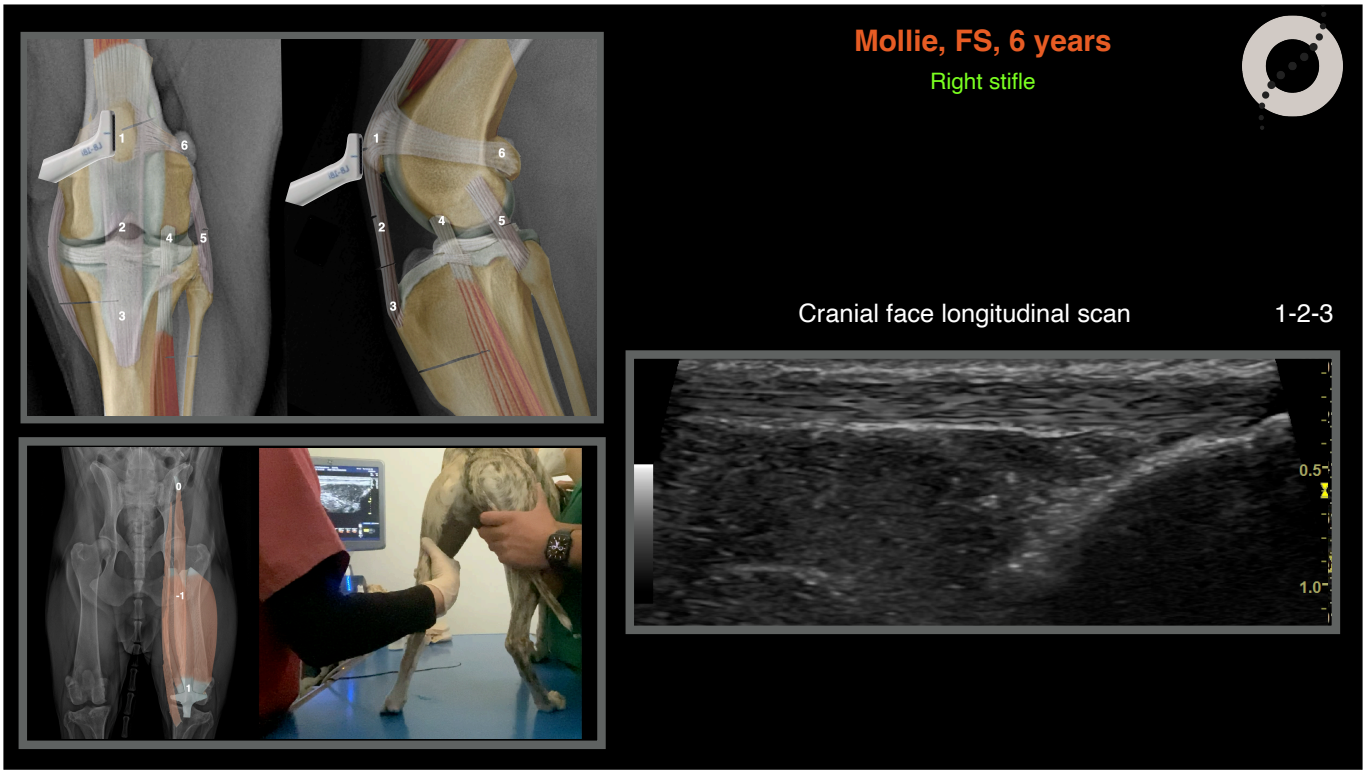
Mollie, FS, 6 years
Right stifle
Cranial face longitudinal scan
1-2-3
0.5
1.0

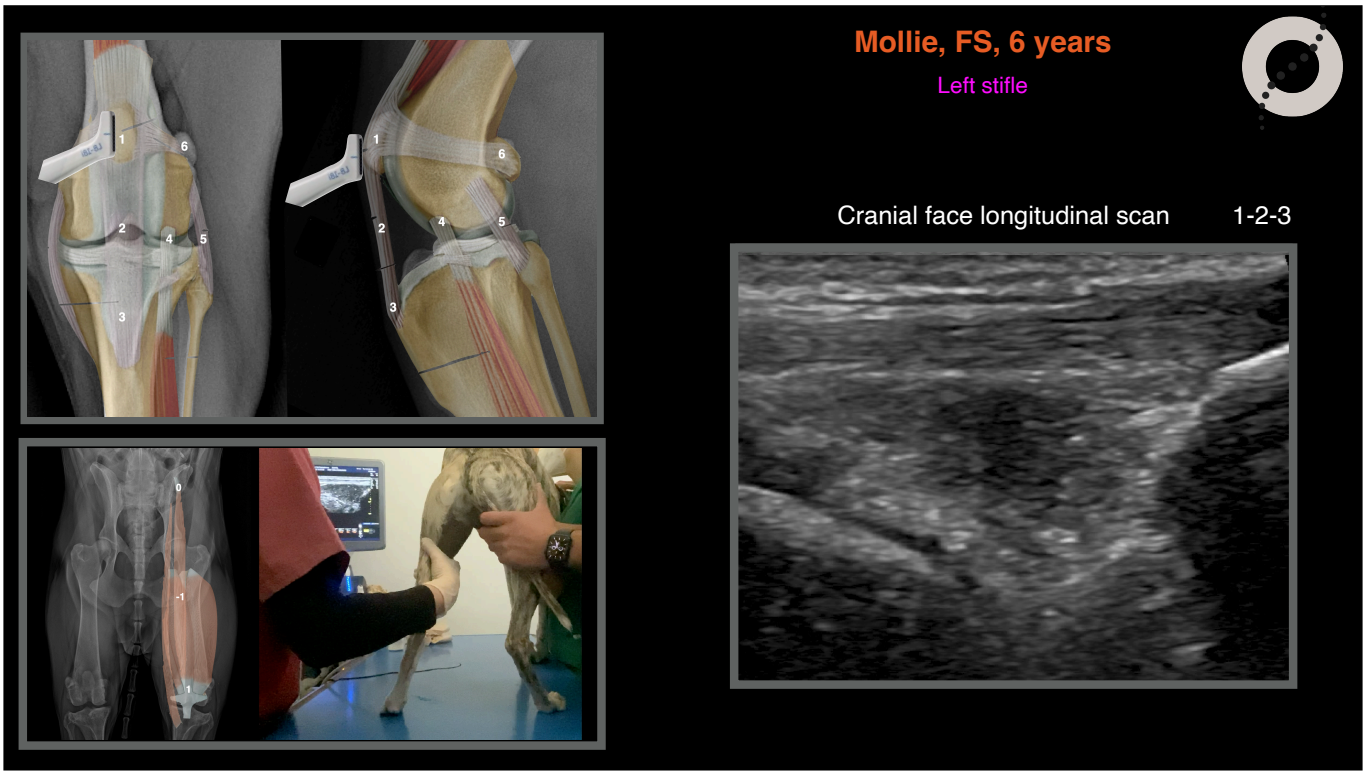
Mollie, FS, 6 years
Left stifle
Cranial face longitudinal scan
1-2-3

Mollie, FS, 6 years

Right stifle 1-1

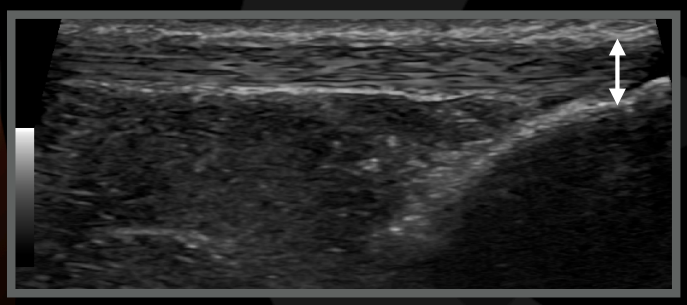

Left stifle 1-1

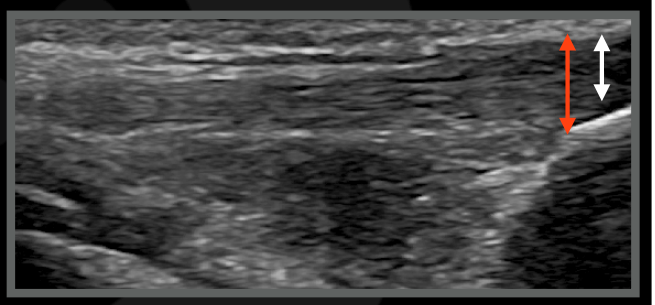

Patellar tendinopathy

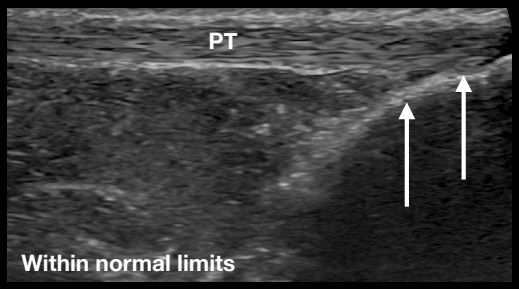

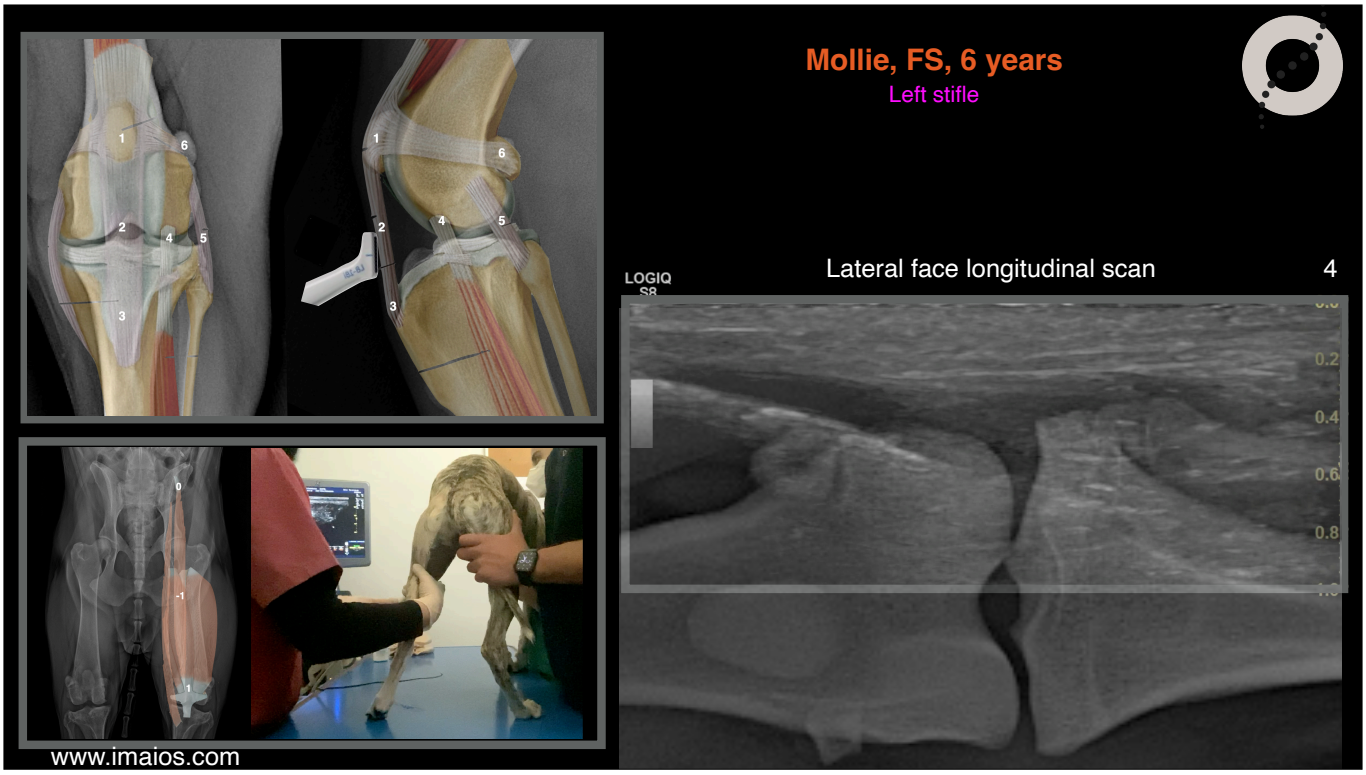
Mollie, FS, 6 years
Left stifle
Lateral face longitudinal scan
4
LOGIQ
www.imaios.com

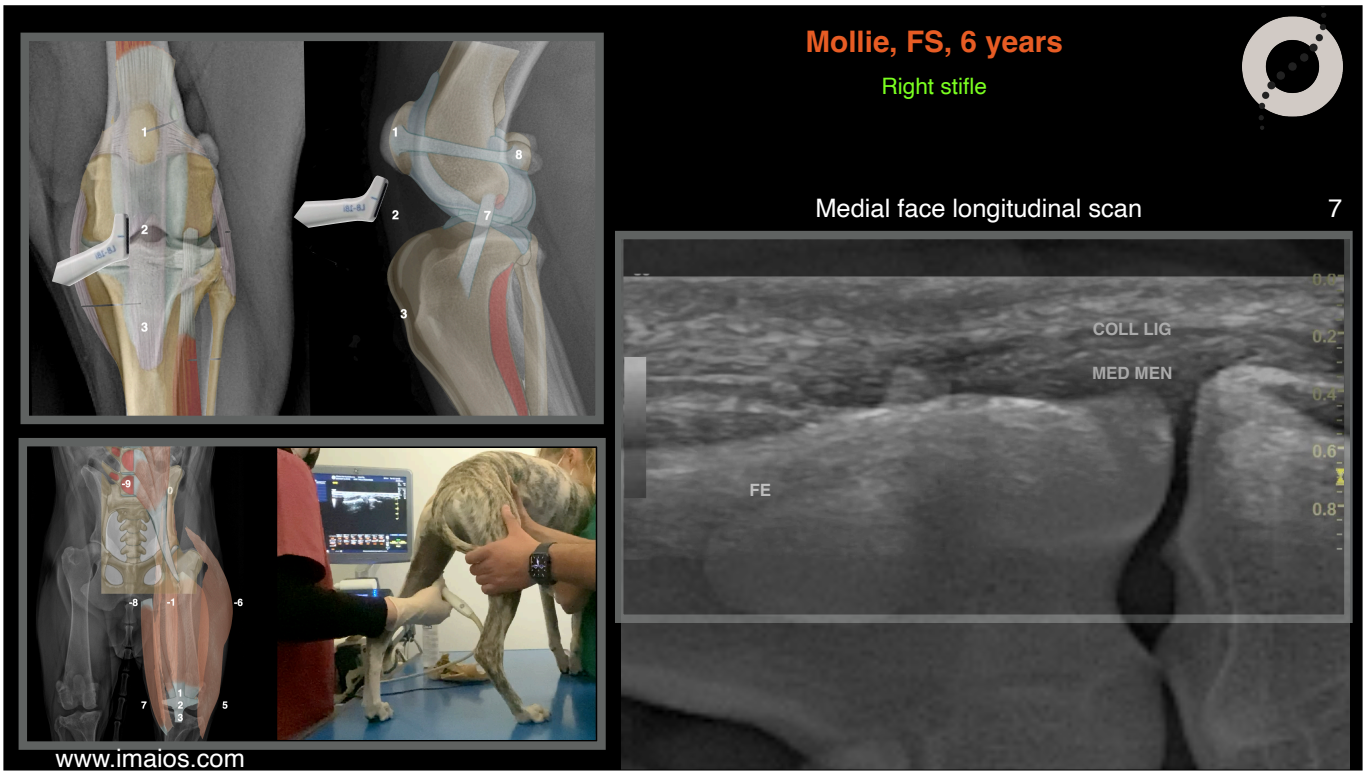
Mollie, FS, 6 years
Right stifle
Medial face longitudinal scan
7
COLL LIG
MED MEN
FE
www.imaios.com

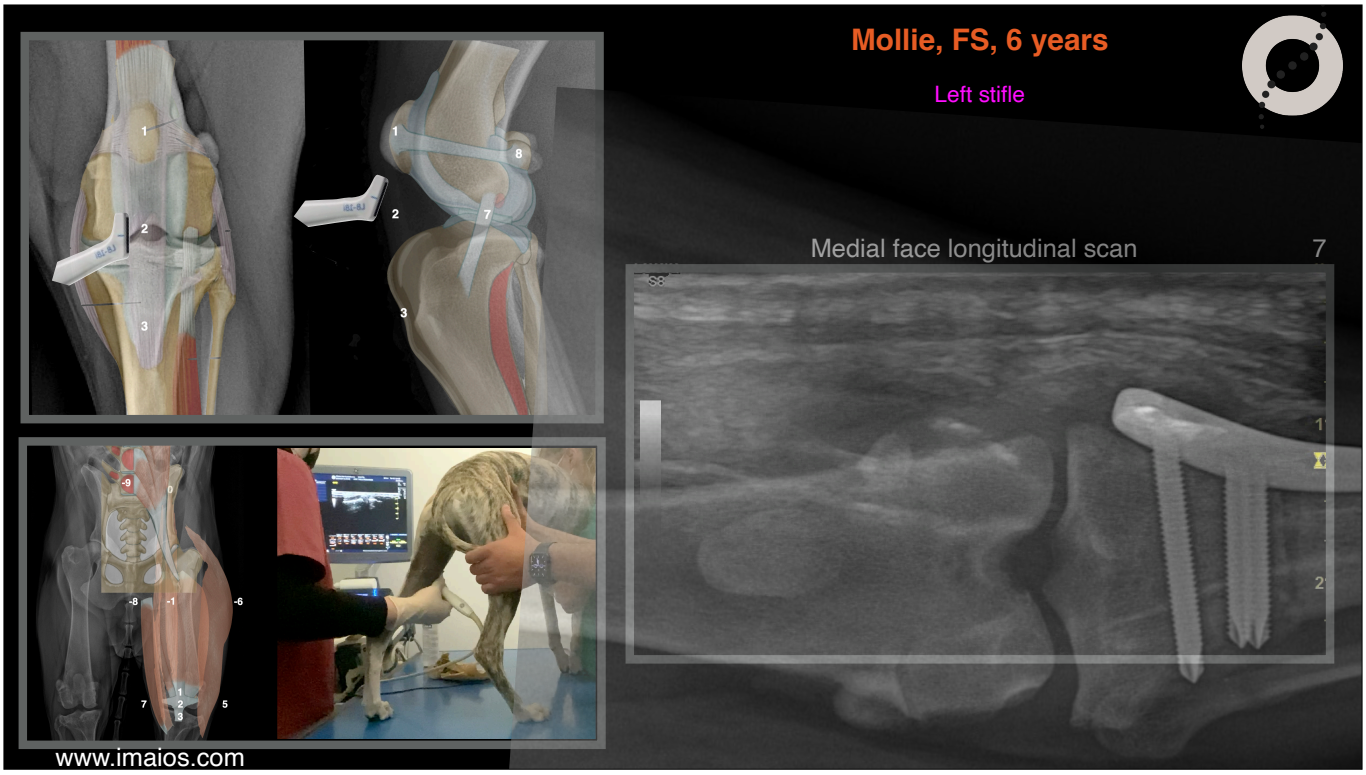
Mollie, FS, 6 years
Left stifle
Medial face longitudinal scan
7
www.imaios.com

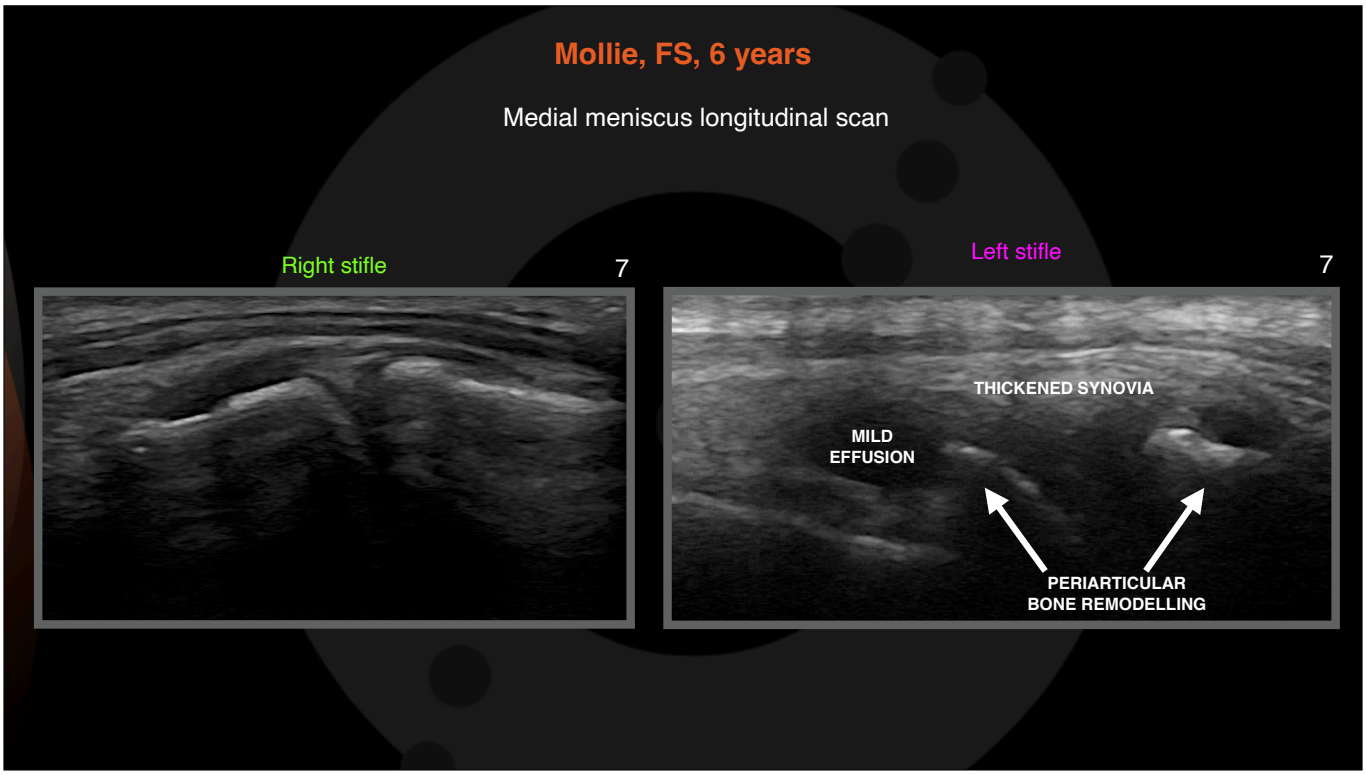
Mollie, FS, 6 years
Medial meniscus longitudinal scan
Right stifle
7
Left stifle
7
THICKENED SYNOVIA
MILD
EFFUSION
PERIARTICULAR
BONE REMODELLING

US of the meniscus

Comparison of ultrasonography and magnetic resonance imaging to arthroscopy for diagnosing medial meniscal lesions in dogs with cranial cruciate ligament deficiency

JAVMA • Vol 251 • No. 1 • July 1, 2017

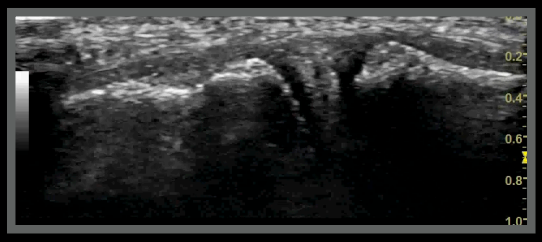

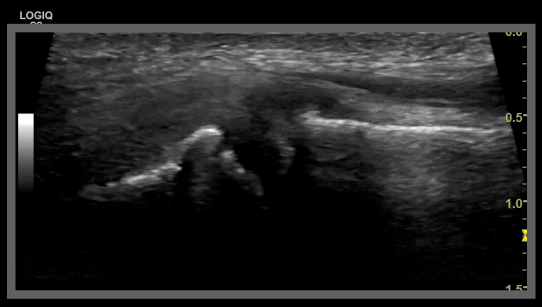

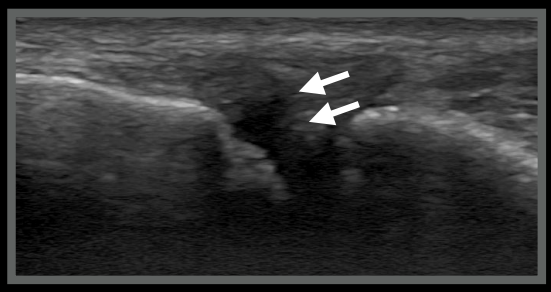

Mollie, FS, 6 years

Left stifle

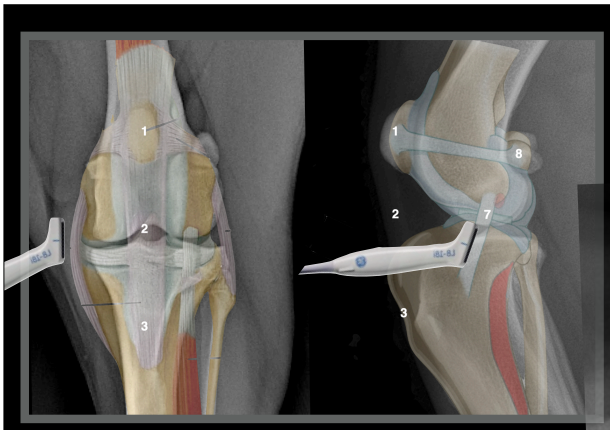

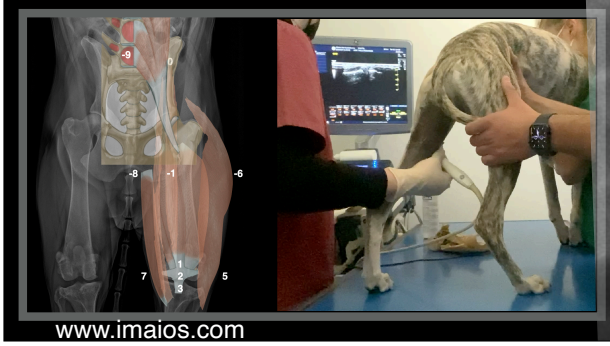

Medial face longitudinal scan 7

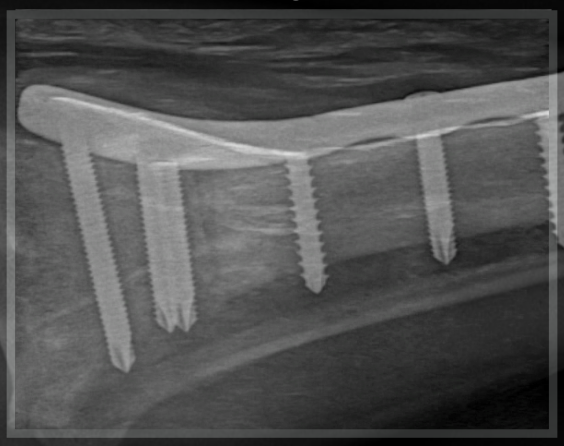

www.imaios.com

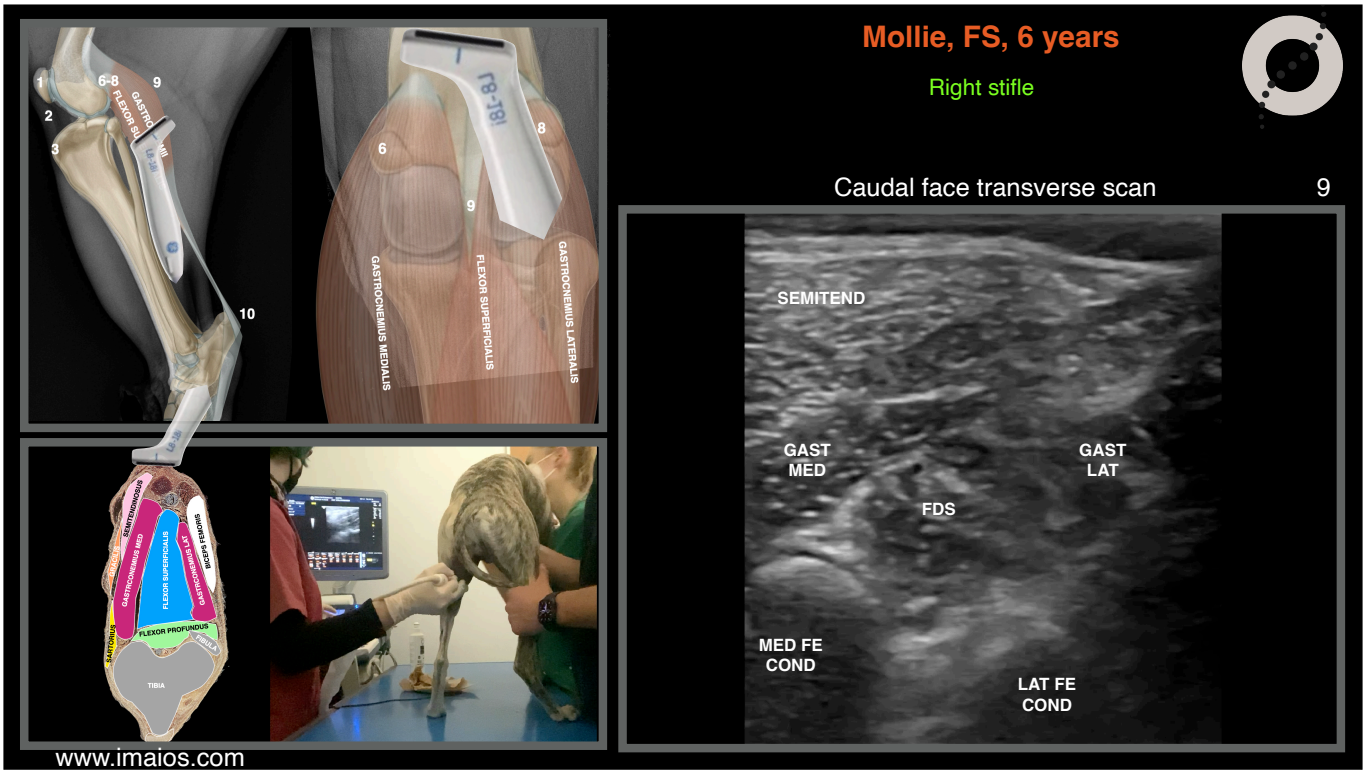
Mollie, FS, 6 years
Right stifle
Caudal face transverse scan 9
SEMITEND
GAST MED
GAST LAT
FDS
MED FE COND
LAT FE COND
GASTROCNEMIUS MEDIALIS
FLEXOR SUPERFICIALIS
GASTROCNEMIUS LATERALIS
FLEXOR PROFUNDUS
TIBIA
www.imaios.com

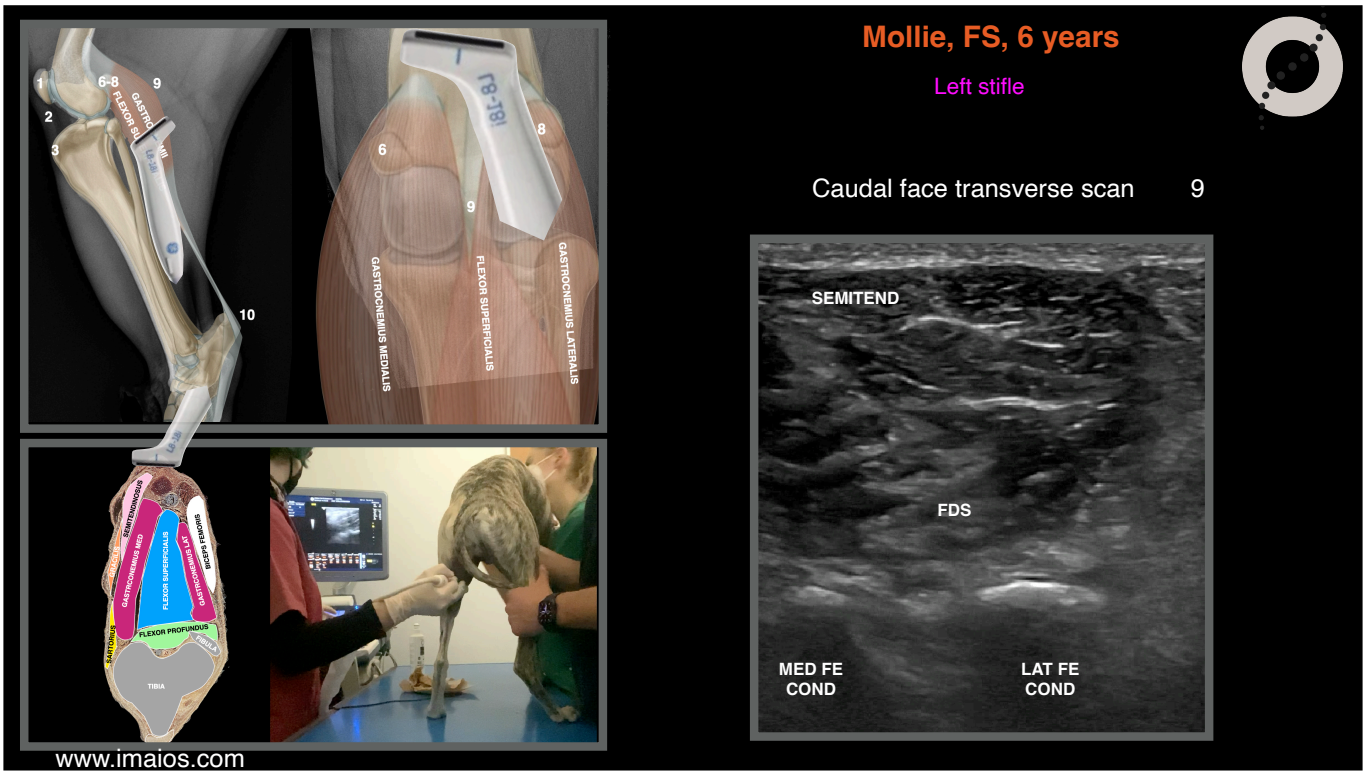
Mollie, FS, 6 years
Left stifle
Caudal face transverse scan 9
SEMITEND
FDS
MED FE COND
LAT FE COND
GASTROCNEMIUS MEDIALIS
FLEXOR SUPERFICIALIS
GASTROCNEMIUS LATERALIS
FLEXOR PROFUNDUS
TIBIA
www.imaios.com

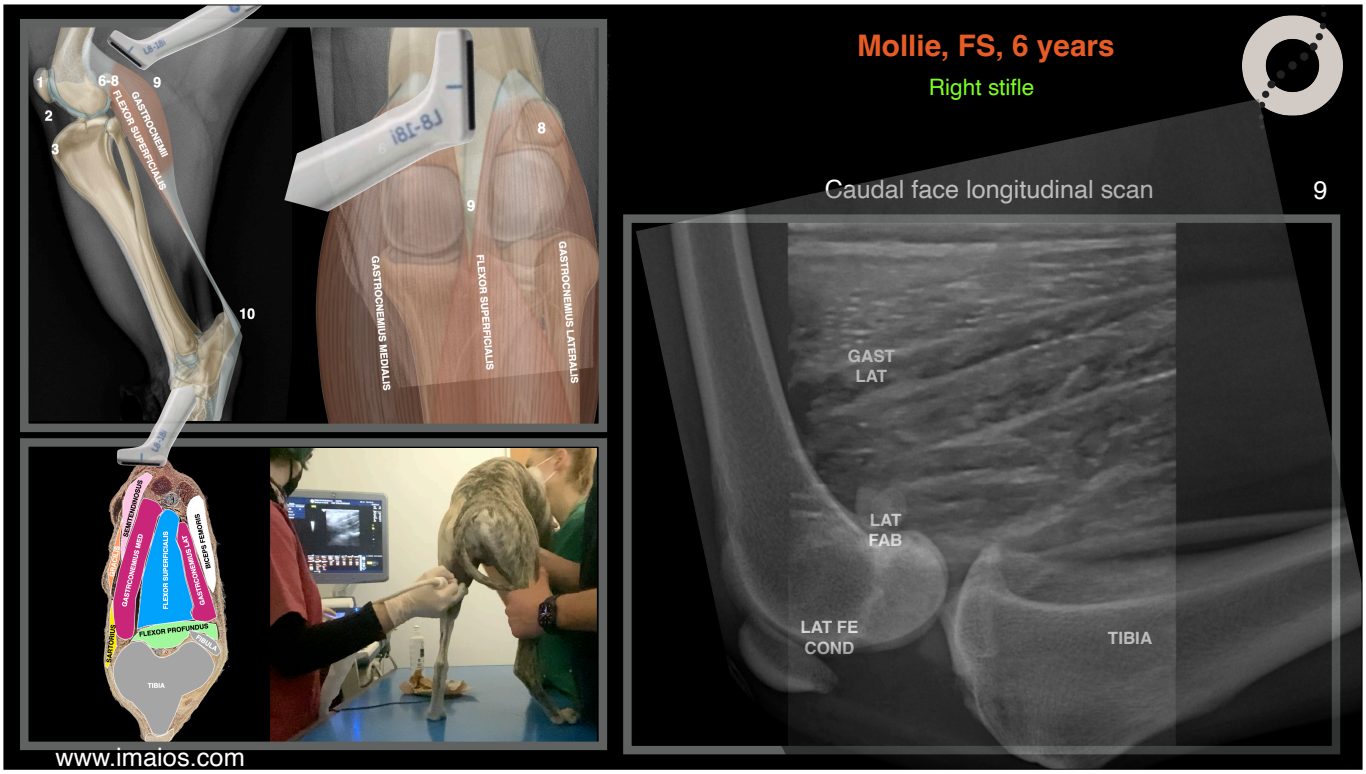
Mollie, FS, 6 years
Right stifle
Caudal face longitudinal scan
9
GAST
LAT
LAT
FAB
LAT FE
COND
TIBIA
GASTROCNEMIUS MEDIALIS
FLEXOR SUPERFICIALIS
GASTROCNEMIUS LATERALIS
FLEXOR PROFUNDUS
TIBIA
www.imaios.com

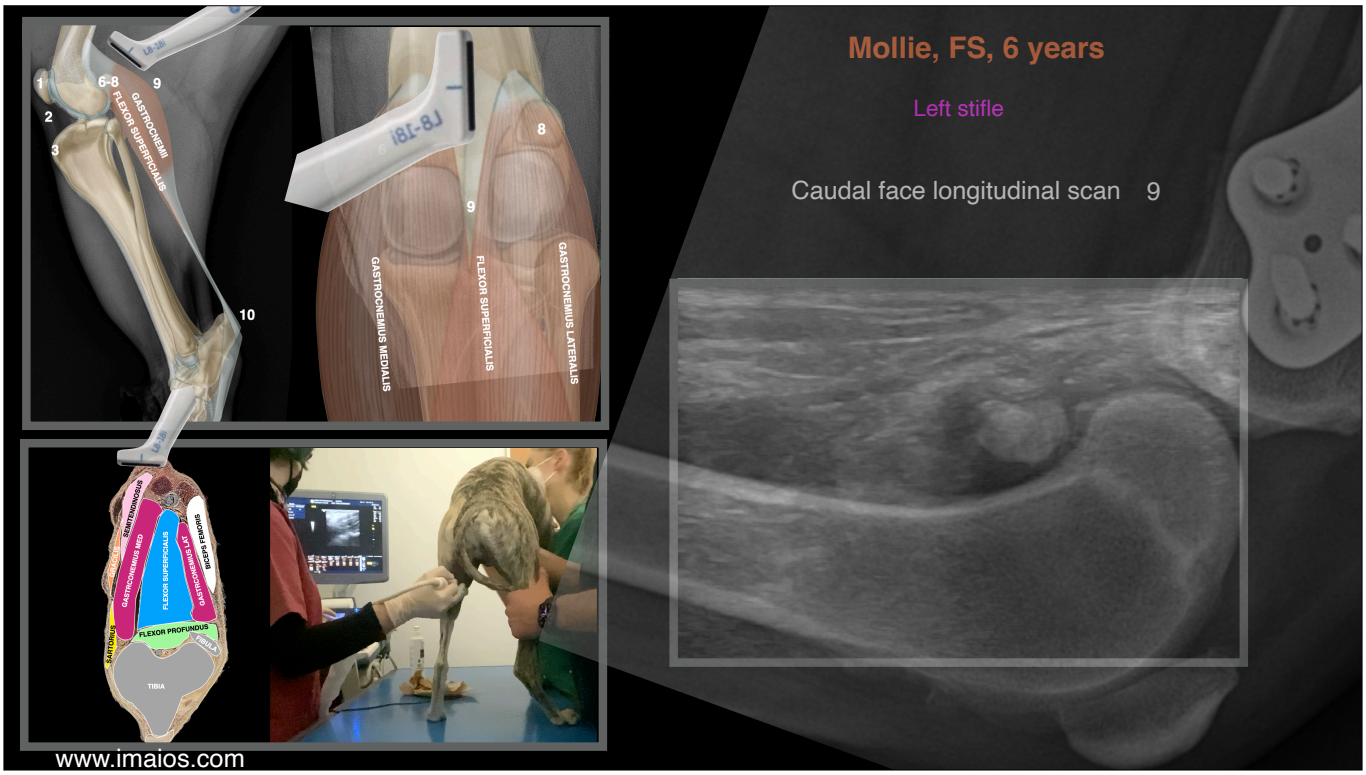
Mollie, FS, 6 years
Left stifle
Caudal face longitudinal scan
9
GASTROCNEMIUS MEDIALIS
FLEXOR SUPERFICIALIS
GASTROCNEMIUS LATERALIS
FLEXOR PROFUNDUS
TIBIA
www.imaios.com

Mollie, FS, 6 years

Medial meniscus longitudinal scan

Right stifle 7

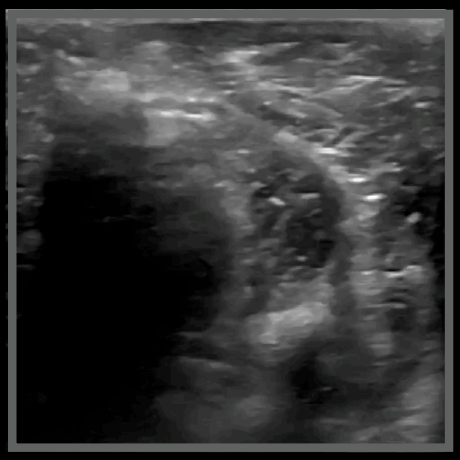

Left stifle 7

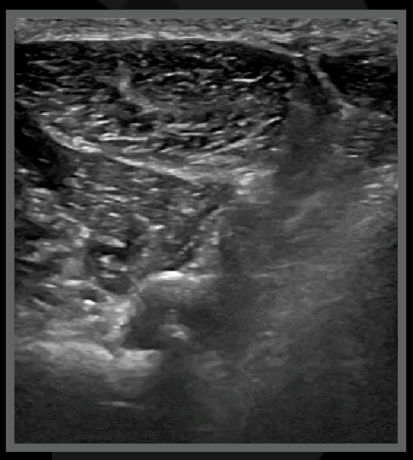

Mollie, FS, 6 years

Ultrasonographic diagnoses:

- Left quadriceps peritendineous effusion
- Thickened left tibio-patellar ligament
- Irregular and thickened synovia left stifle
- Effusion and inflammation of the left lateral fabella

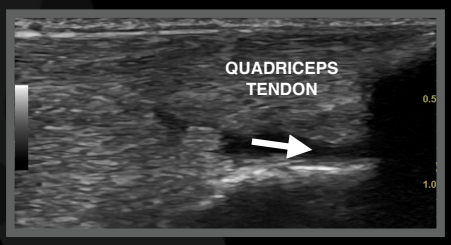

Conclusions

Check the distribution of the forces!

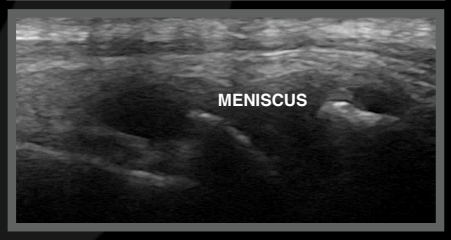

Thank you

Diagnostic Mindset

www.diagnosticmindset.com