

Ultrasound of the hindlimb in a shaking Siberian Husky

CASE DISCUSSION

Giliola Spattini
DVM, GP Cardio, CCRT, PhD, DECVDI



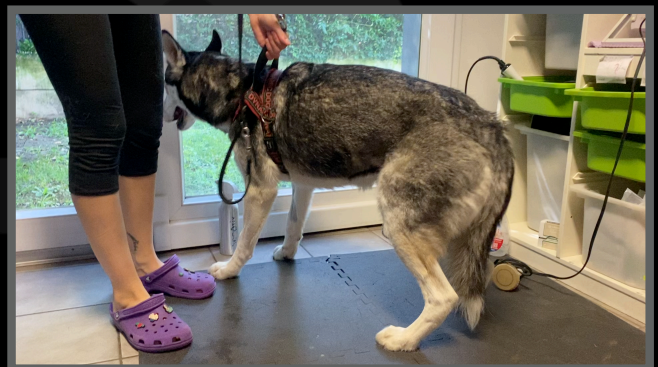Diagnostic Mindset



Thank to www.imaios.com

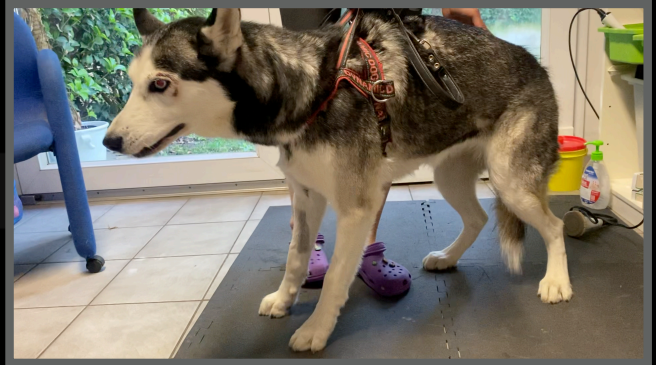Akira, Siberian Husky, FS, 4 years

- Since two years of age, immediately after spaying, progressive and worsening shivering of the hind limbs when sitting and standing

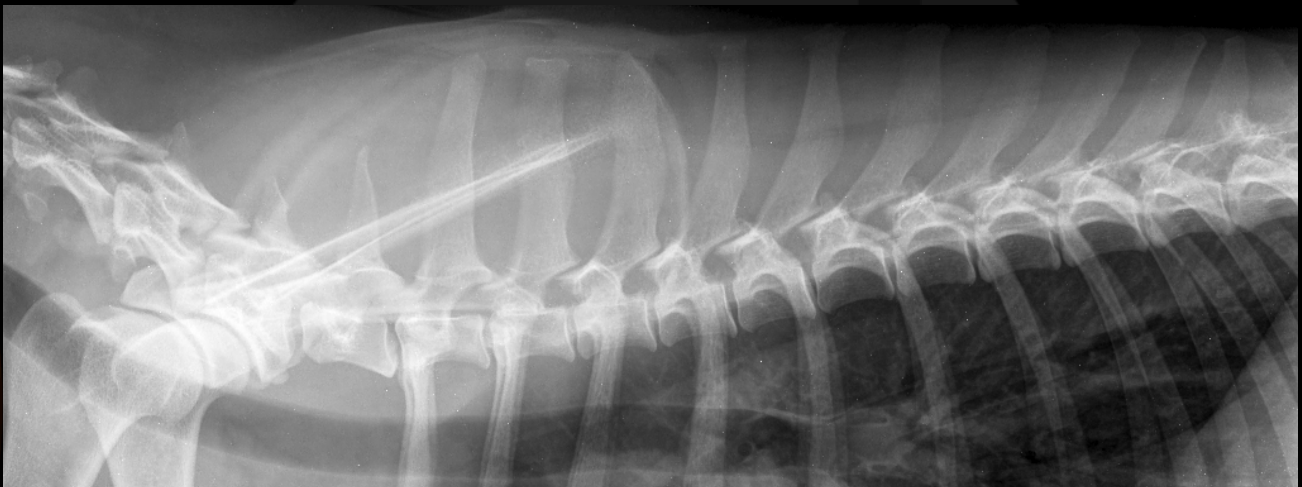


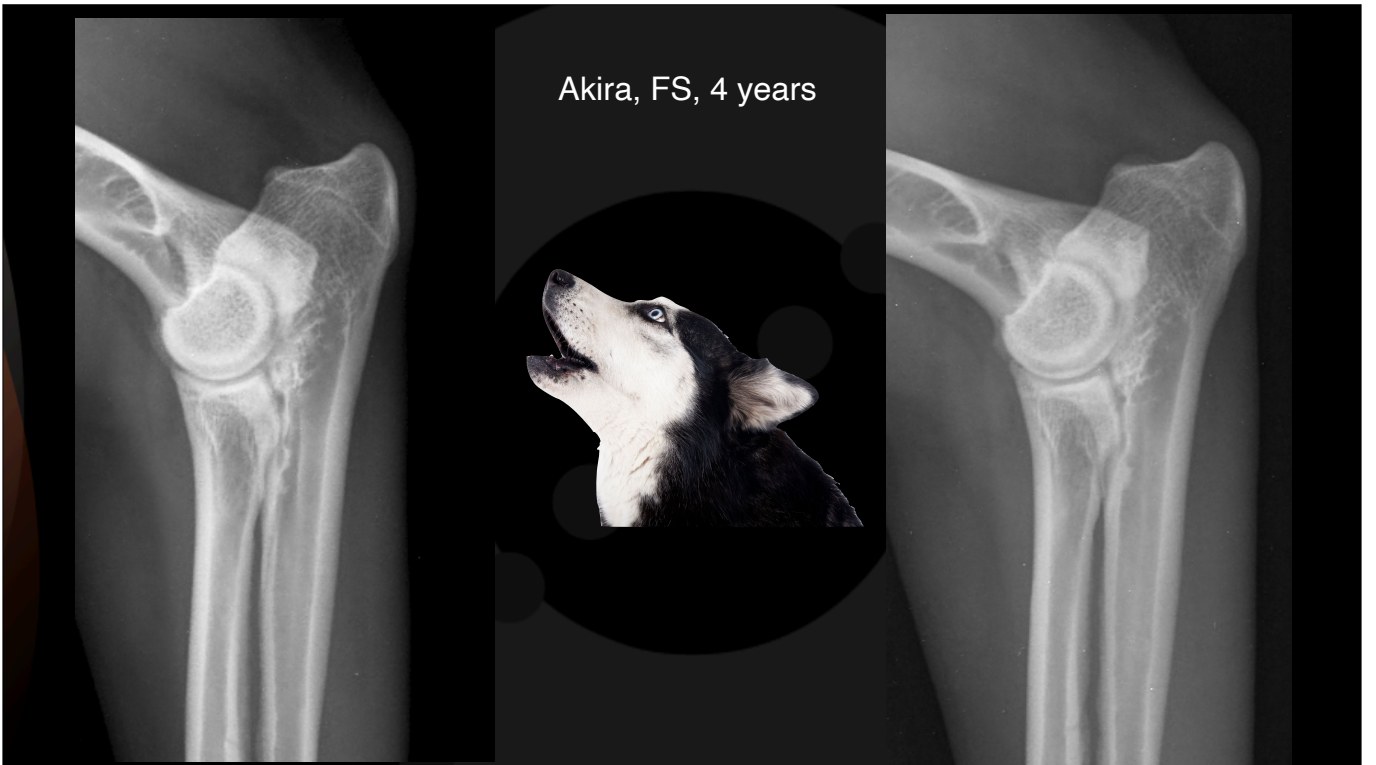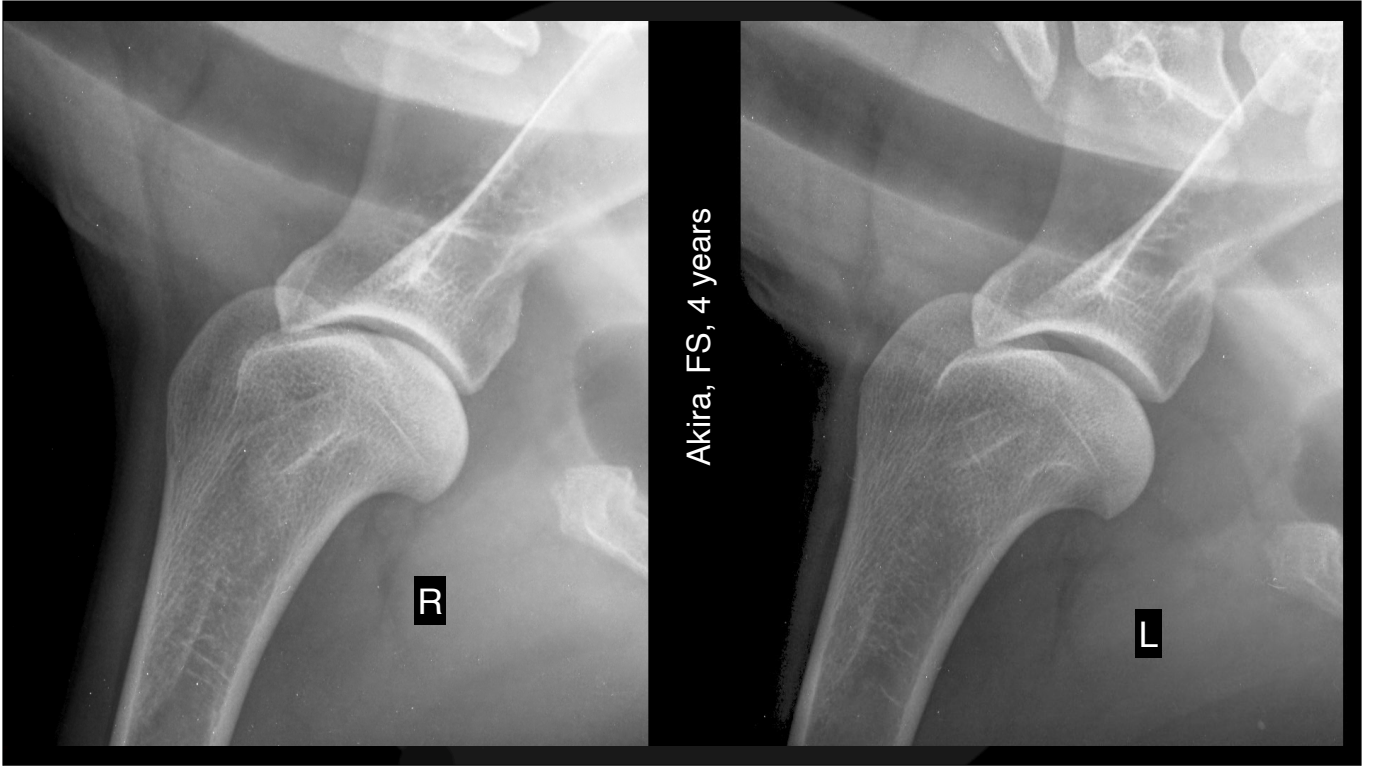
Akira, Siberian Husky, FS, 4 years

- The orthopaedic examination was unremarkable, and a radiographic study was requested and performed

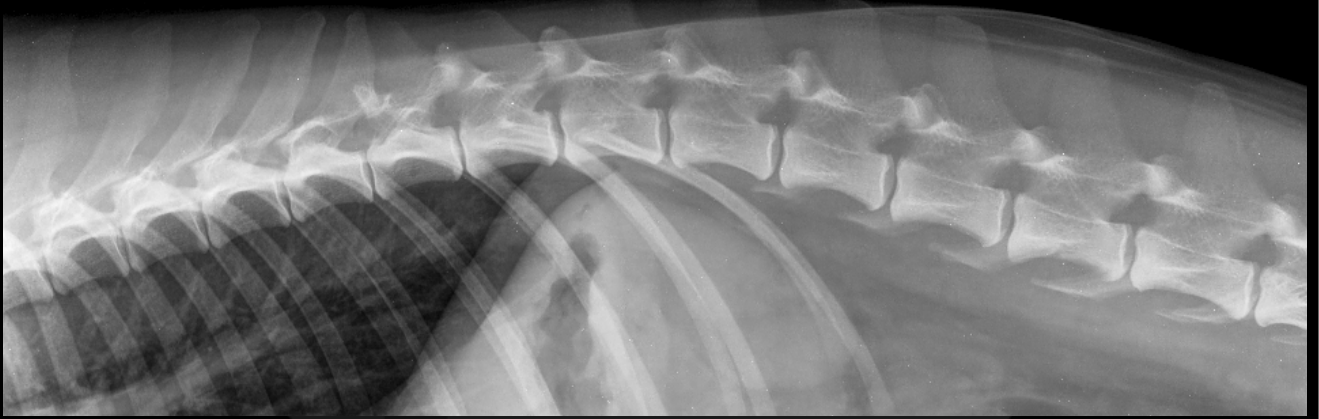


Akira, FS, 4 years

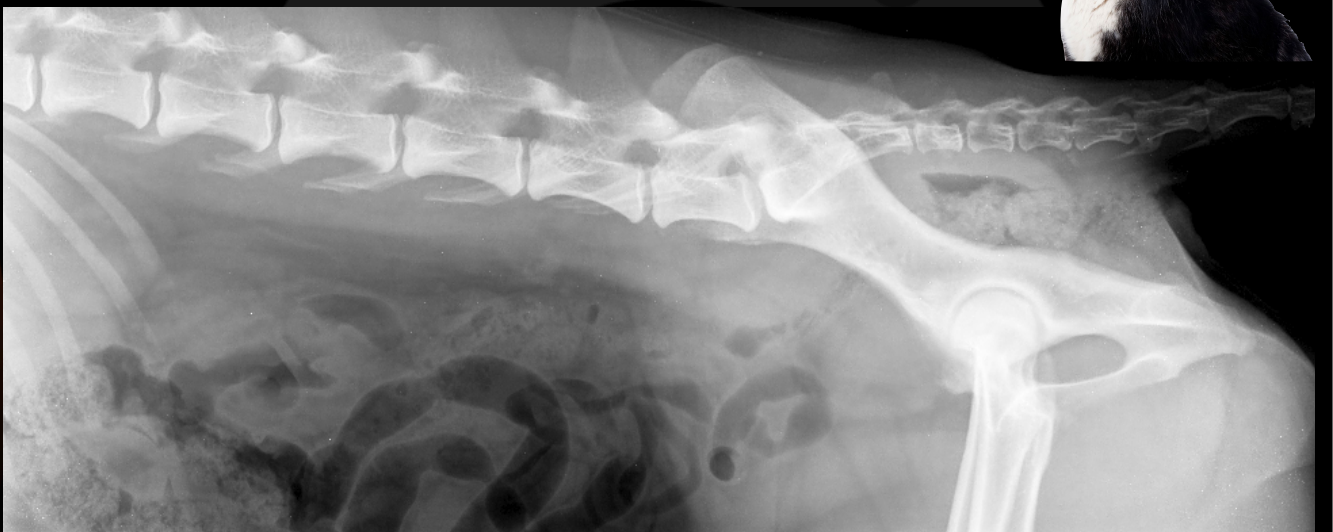



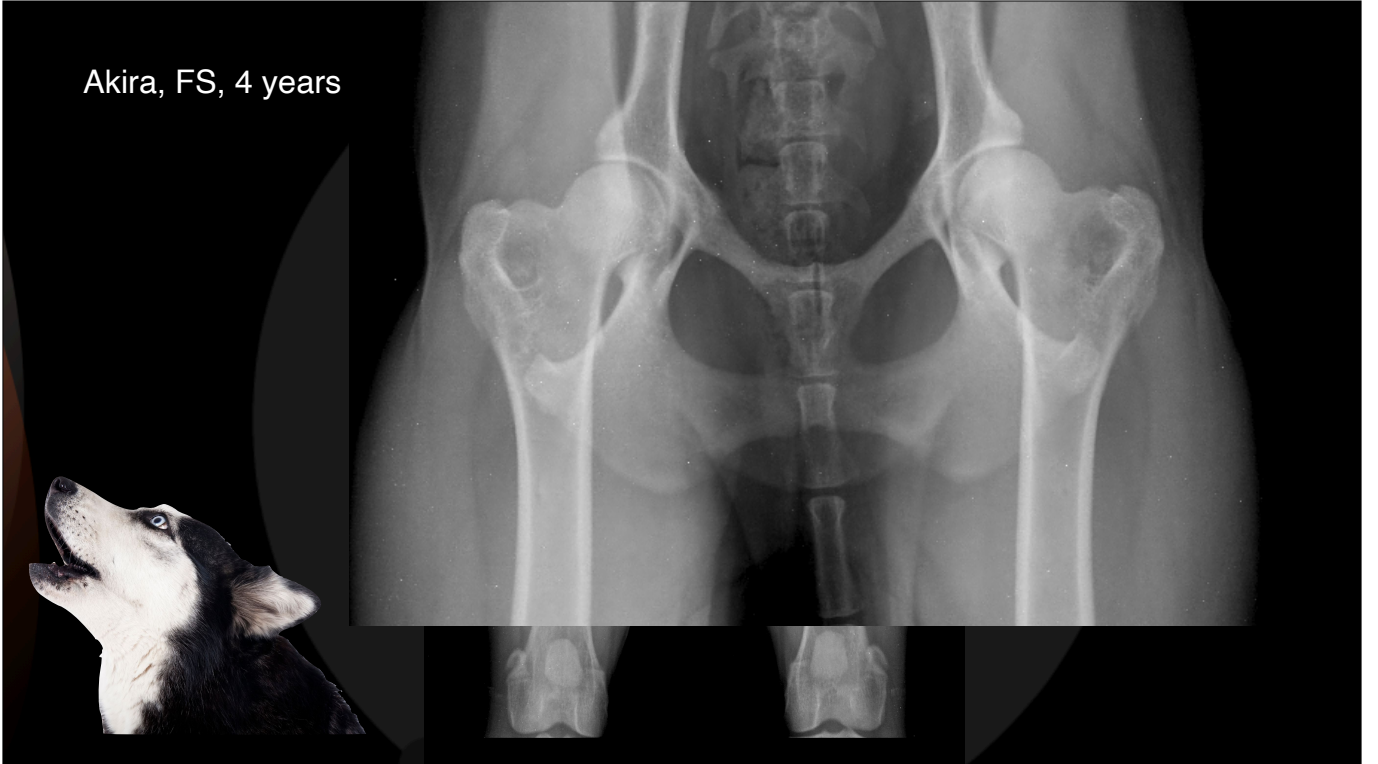
Akira, FS, 4 years



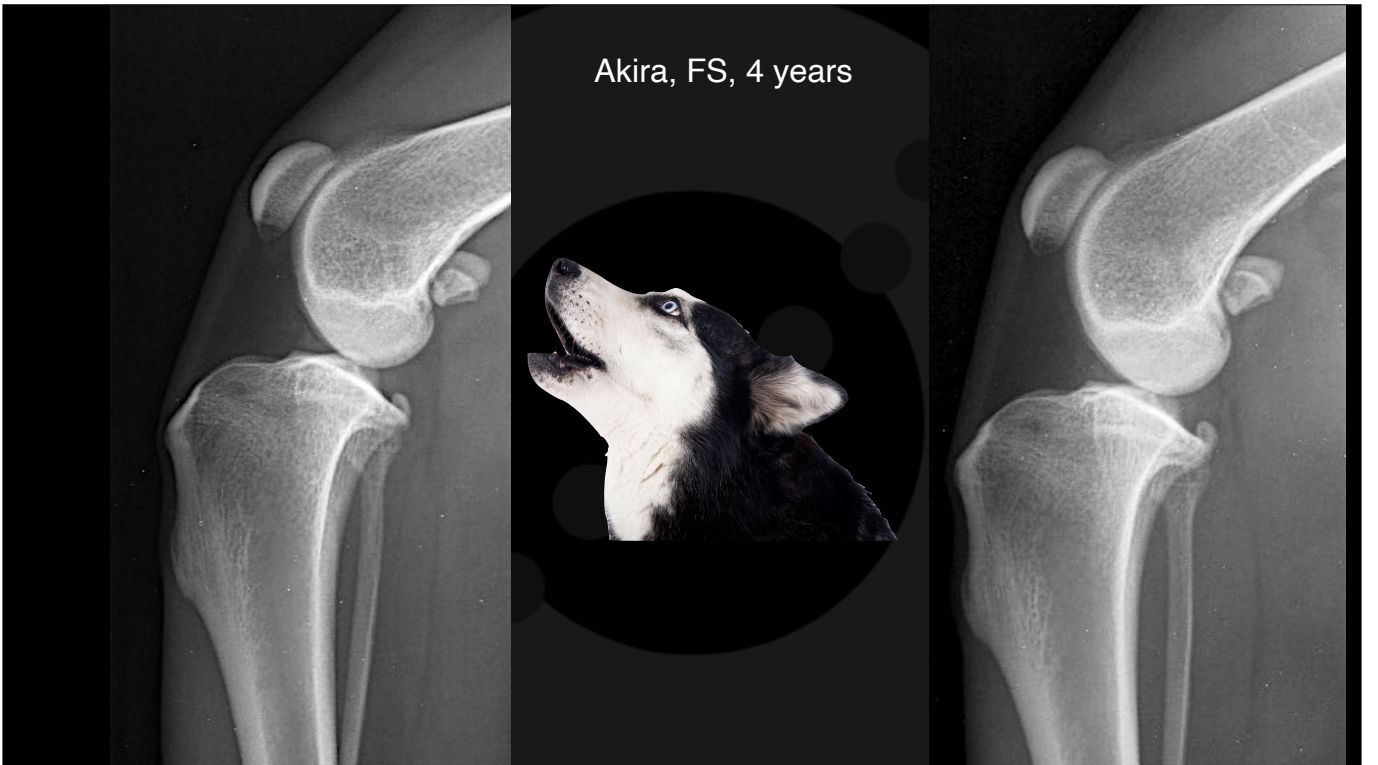Akira, FS, 4 years



Akira, FS, 4 years

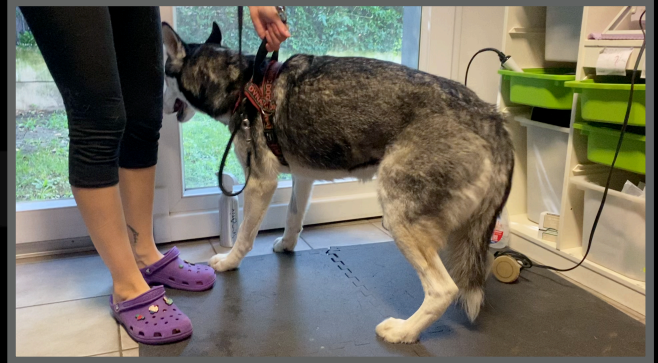

Akira, FS, 4 years



Akira, Siberian Husky, FS, 4 years

- Orthopaedic and radiographic evaluation were unremarkable
- Requested a neurologic evaluation



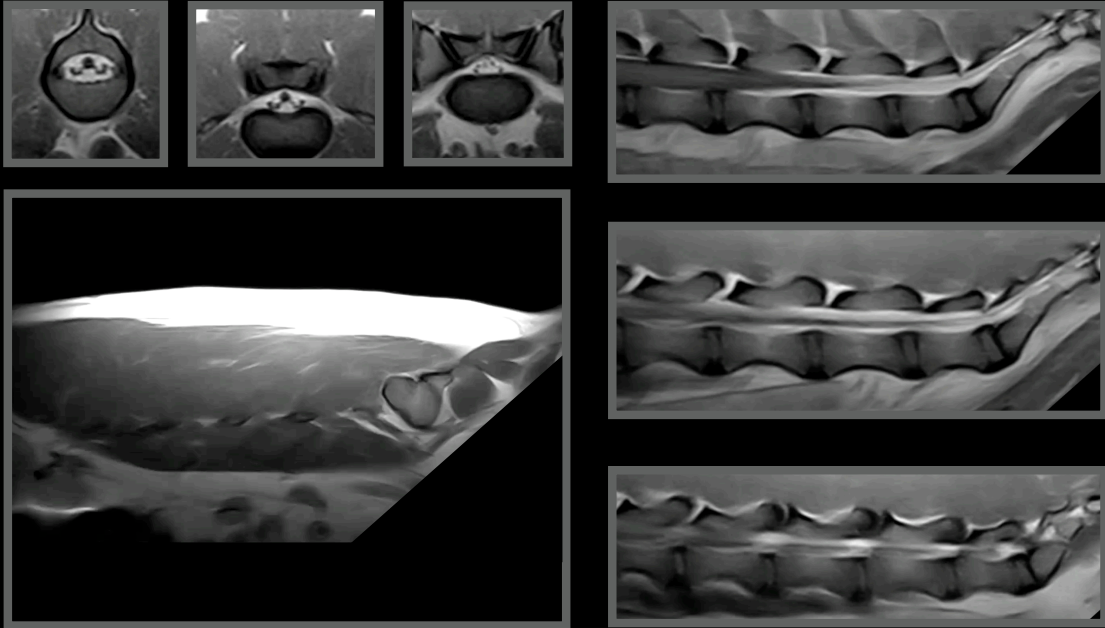
Akira, Siberian Husky, FS, 4 years

- No proprioceptive deficits
- Unremarkable cranial and spinal reflexes
- Repetitive pain L5-7 - MRI





Akira, FS, 4 years



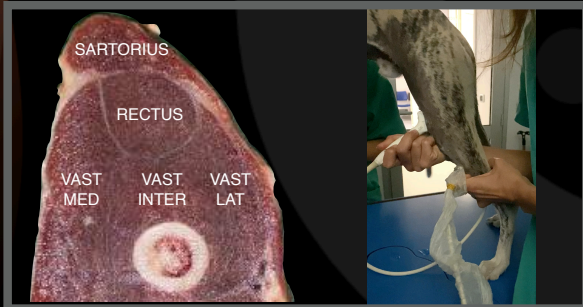
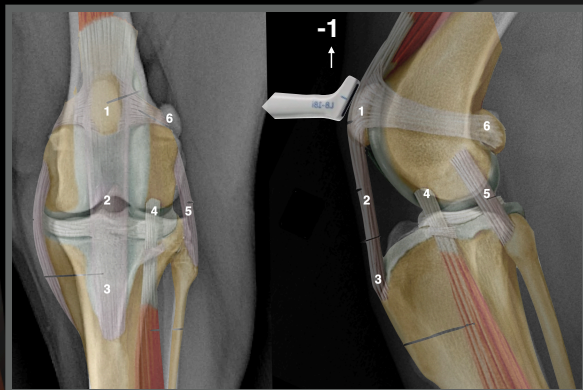
Akira, Siberian Husky, FS, 4 years

- No pathologies detected at LS spine and nerve roots at this level
- No evidence of cauda equina syndrome
- Suggested physical rehabilitation



Akira, Siberian Husky, FS, 4 years

- Three months after physical rehabilitation treatment, improved but not resolved shaking
- Requested an ultrasound

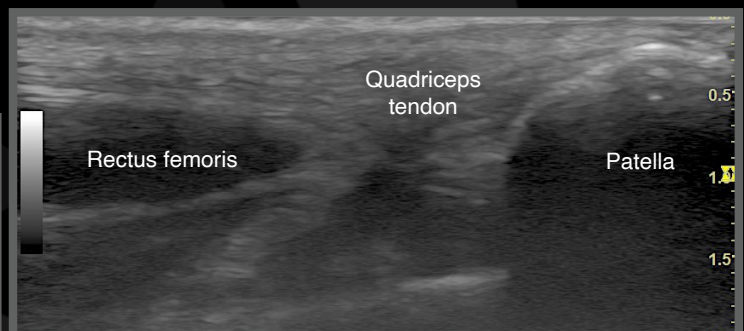


Akira, FS, 4 years

Right stifle

Cranial face longitudinal scan

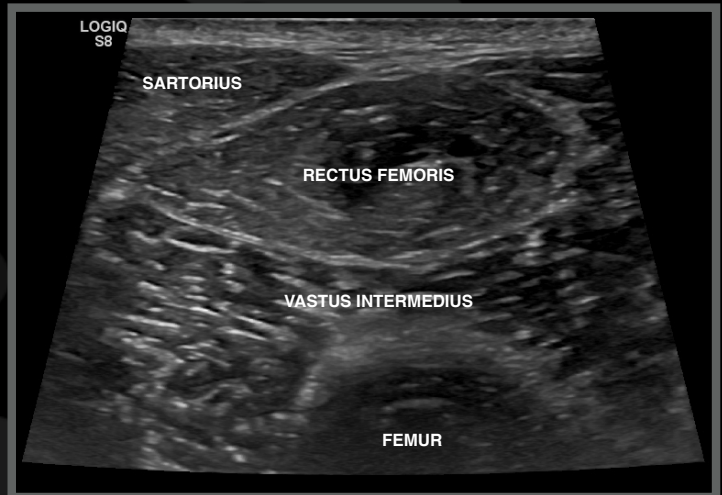
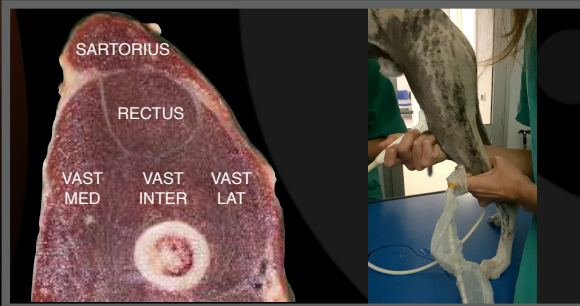
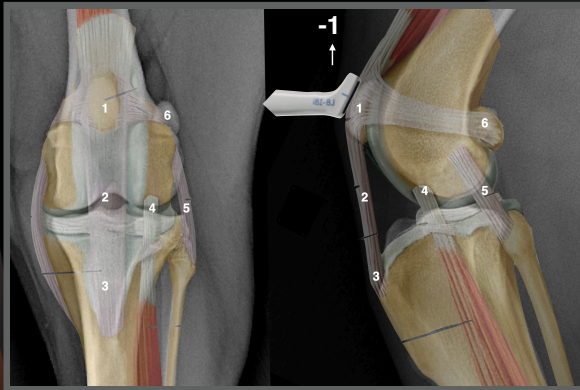
1-1



Normal US anatomy cranial thigh

Cranial face transverse scan

1-1

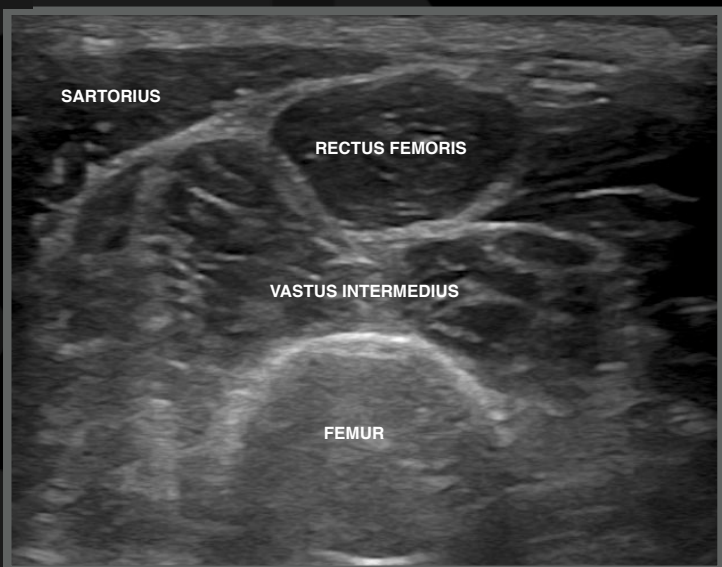
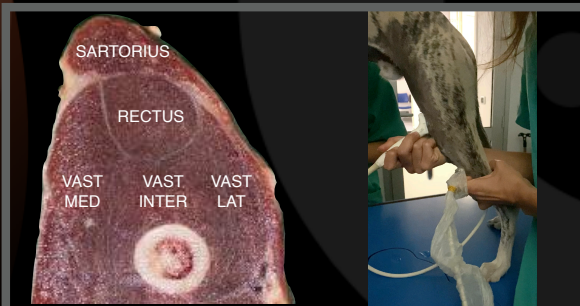
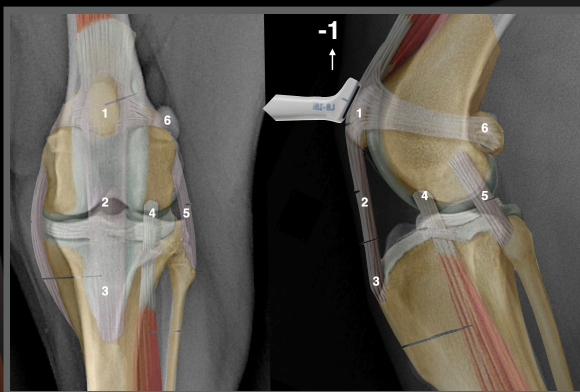


Akira, FS, 4 years

Left thigh

Cranial face transverse scan

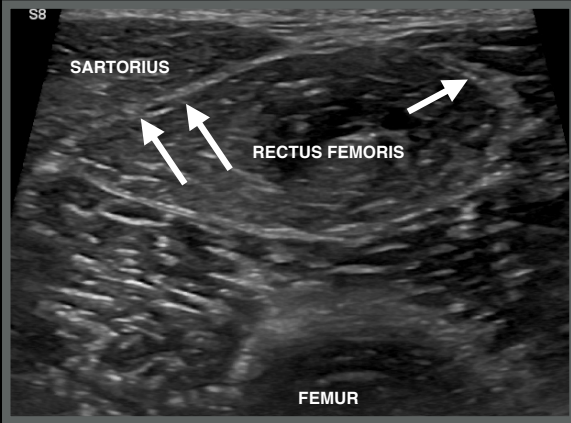
1-1



NorMal VS Akira

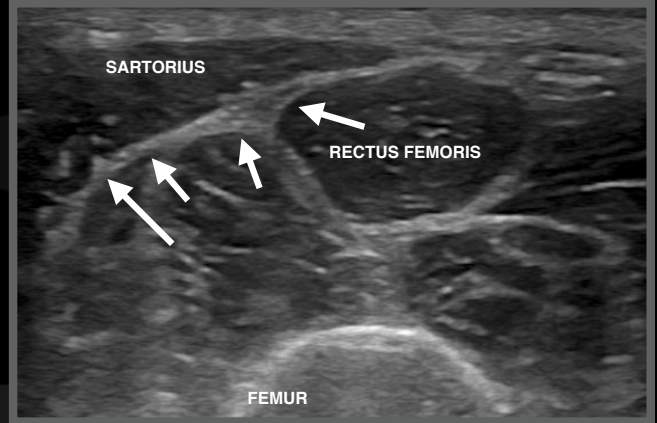
Normal range

1-1



Akira

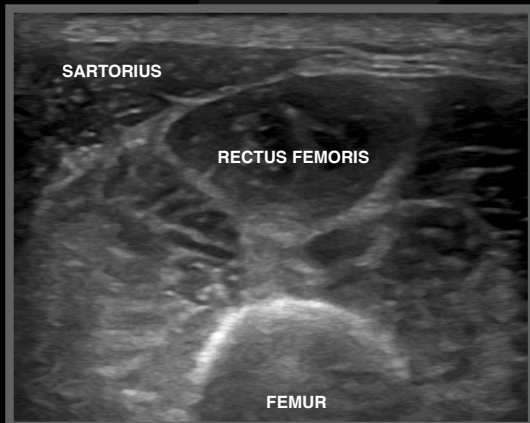
1-1



Akira, FS, 4 years

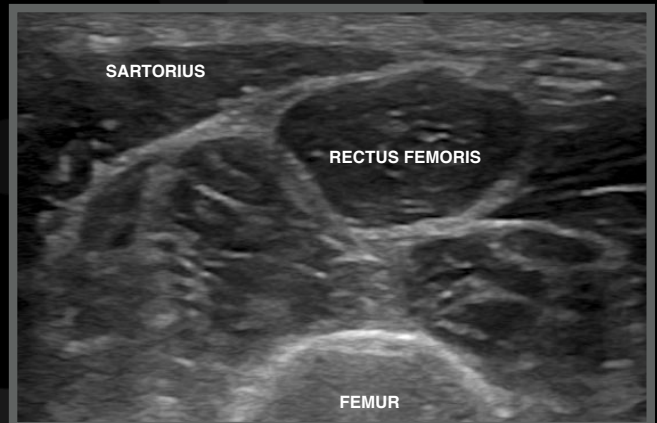
Right thigh

1-1



Left thigh

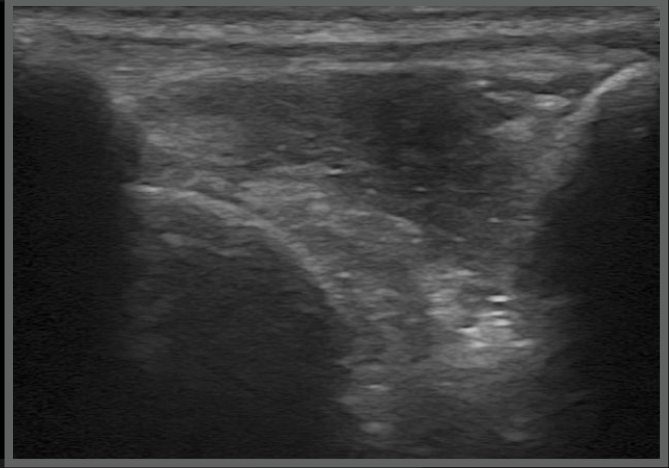
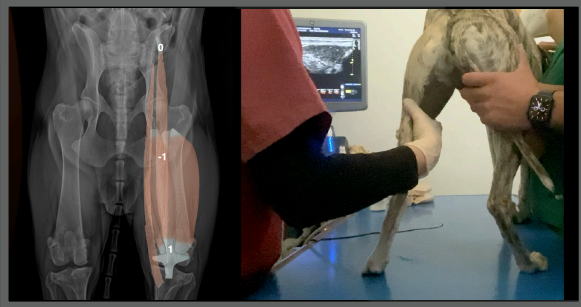
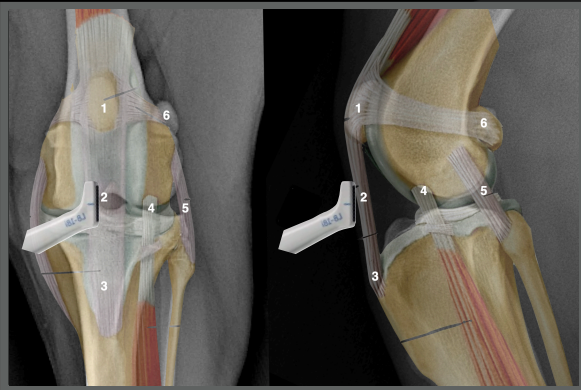
1-1



Akira, FS, 4 years

Right stifle

Cranial face longitudinal scan

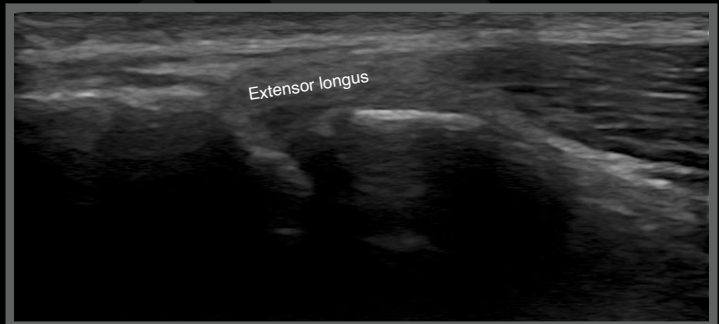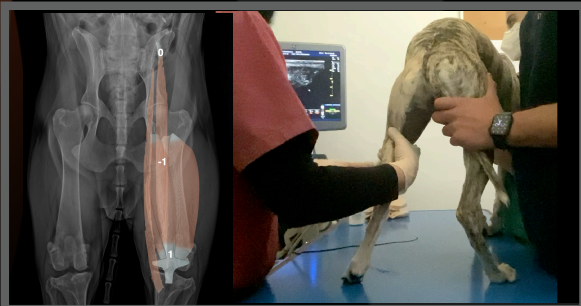
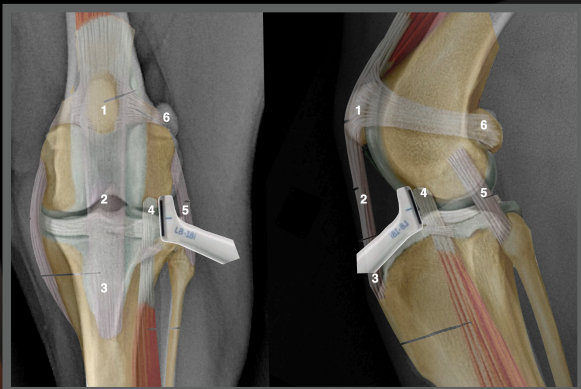


Akira, FS, 4 years

Right stifle

Lateral face longitudinal scan

4

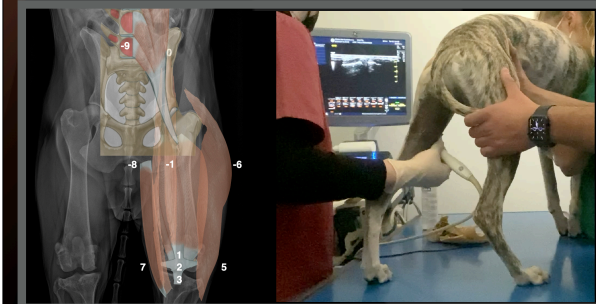
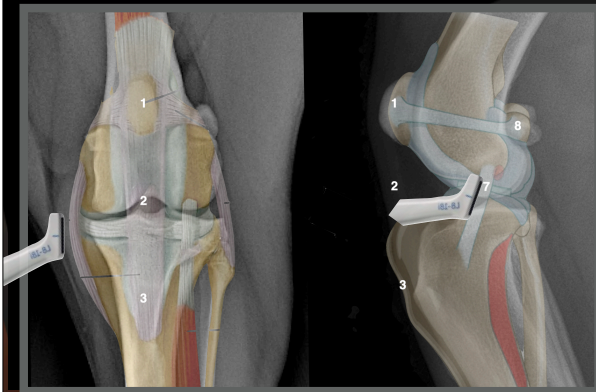


Akira, FS, 4 years

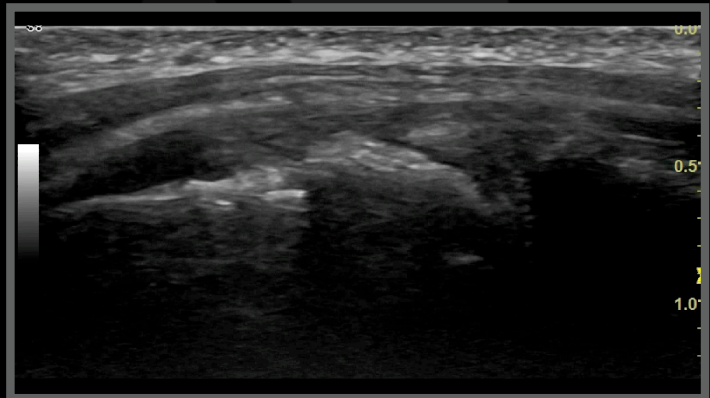
Right stifle

Medial face longitudinal scan

7



www.imaios.com

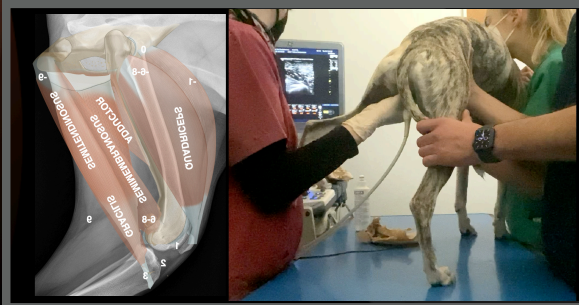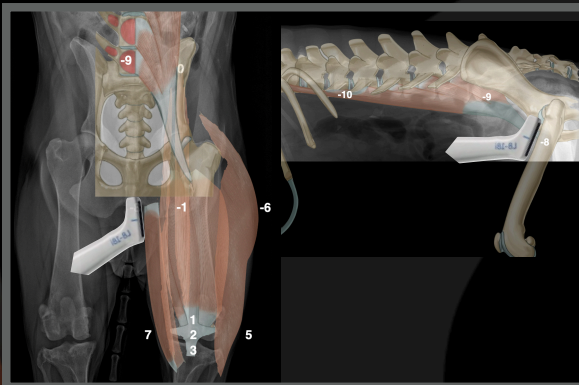


Akira, FS, 4 years

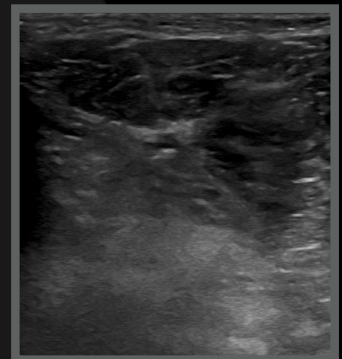
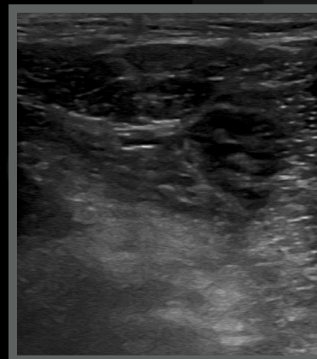
Right thigh

Medial face transverse scan

-8



www.imaios.com



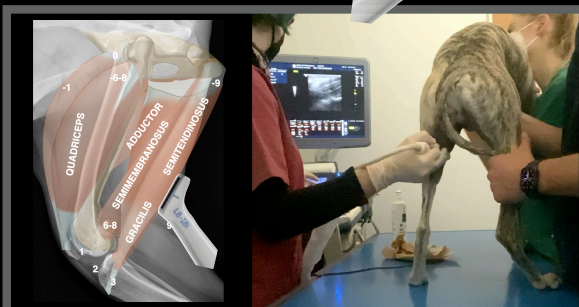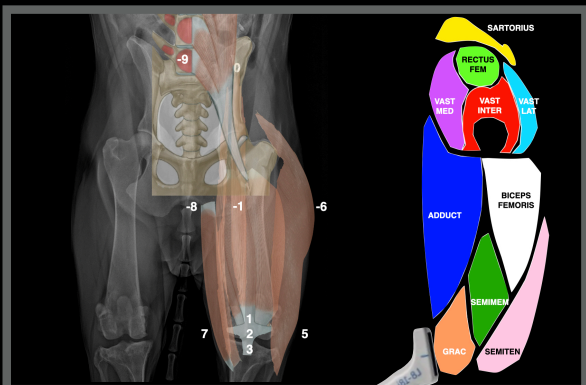
Akira, FS, 4 years

Right thigh

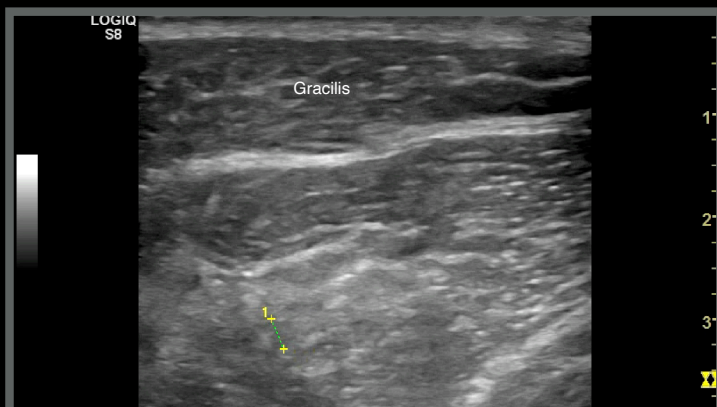


Caudal face transverse scan

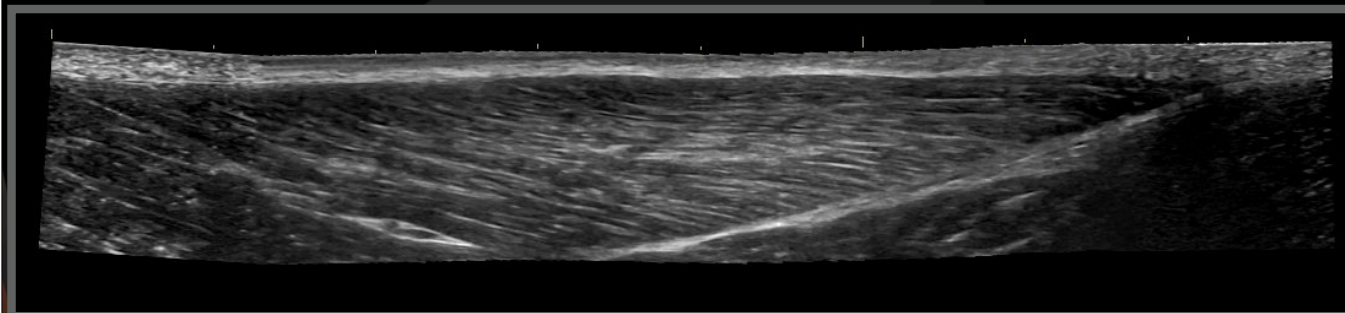
-9-9



www.imaios.com

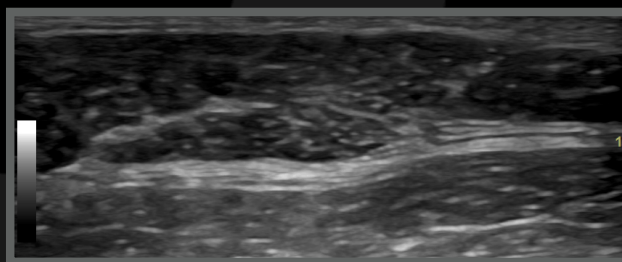
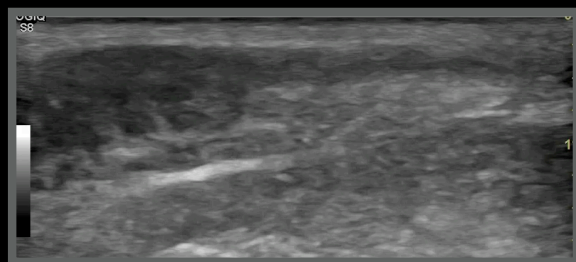


Gracilis, Normal VS Akira



Left thigh

Right thigh



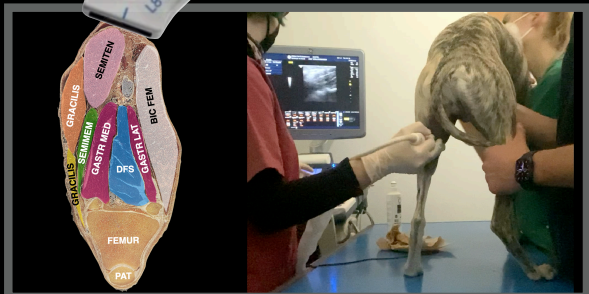
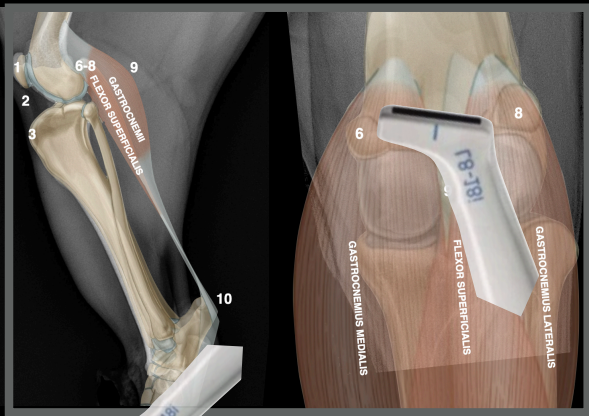
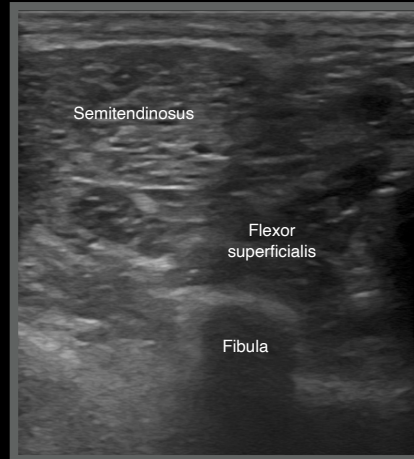


Akira, FS, 4 years

Right stifle

Caudal face transverse scan

9



www.imaios.com

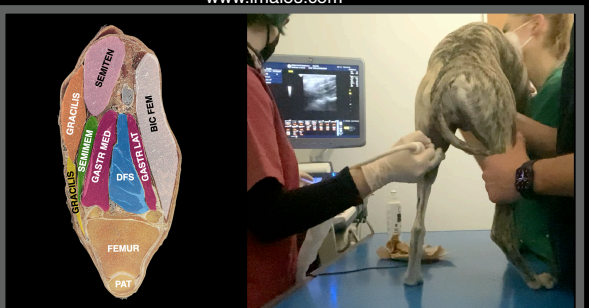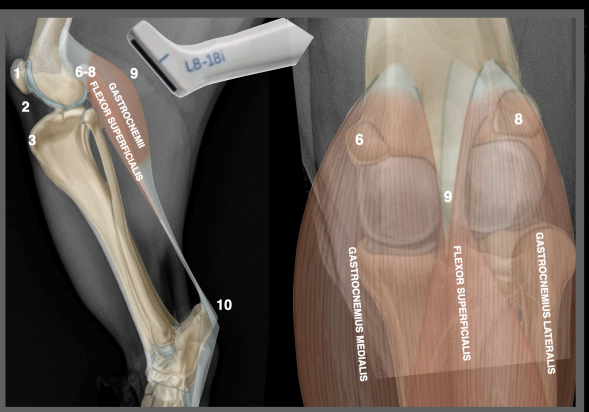
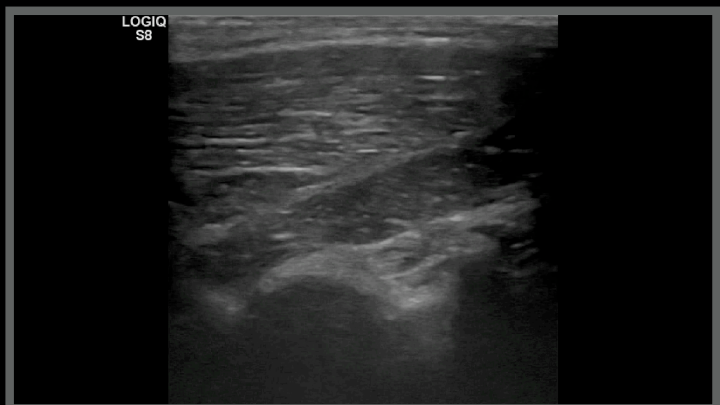


Akira, FS, 4 years

Right stifle

Caudal face longitudinal scan

9



www.imaios.com

Akira, Siberian Husky, FS, 4 years

Ultrasonographic diagnoses:

- Thickened fascia sartorius-quadiceps
- Chronically altered iliopsoas
- Thickened gracilis-adductor fascia

Conclusions:

- Secondary changes are not considered the cause of the condition of the patient
- Advised electromyography



Akira, Siberian Husky, FS, 4 years

Six months later

- Better but not perfect
- Worst when sitting



Akira, Siberian Husky, FS, 5 years

Eight months later

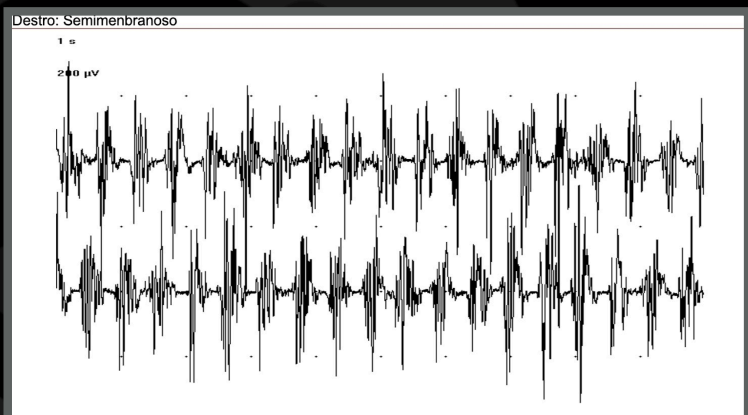
- Three weeks without physiotherapy for Summer break



Akira, Siberian Husky, FS, 5 years

Eight months later

- Electromyography consistent with primary orthostatic tremor



STANDARD ARTICLE

Primary orthostatic tremor and orthostatic tremor-plus in dogs: 60 cases (2003-2020)

Theofanis Liatis¹ | Rodrigo Gutierrez-Quintana¹ | Lorenzo Mari^{2,3} | Michał Czopowicz⁴ | Dakir Polidoro⁵ | Sofie F. M. Bhatti⁵ | Francesca Cozzi⁶ | Federica Tirrito⁶ | Josep Brocal^{1,3} | Roberto José-López¹ | Adriana Kaczmariska¹ | Rodolfo Cappello⁷ | Georgina Harris⁸ | Lisa Alves⁸ | Clare Rusbridge^{9,10} | John H. Rossmeisl¹¹

Semiology of orthostatic tremor in dogs

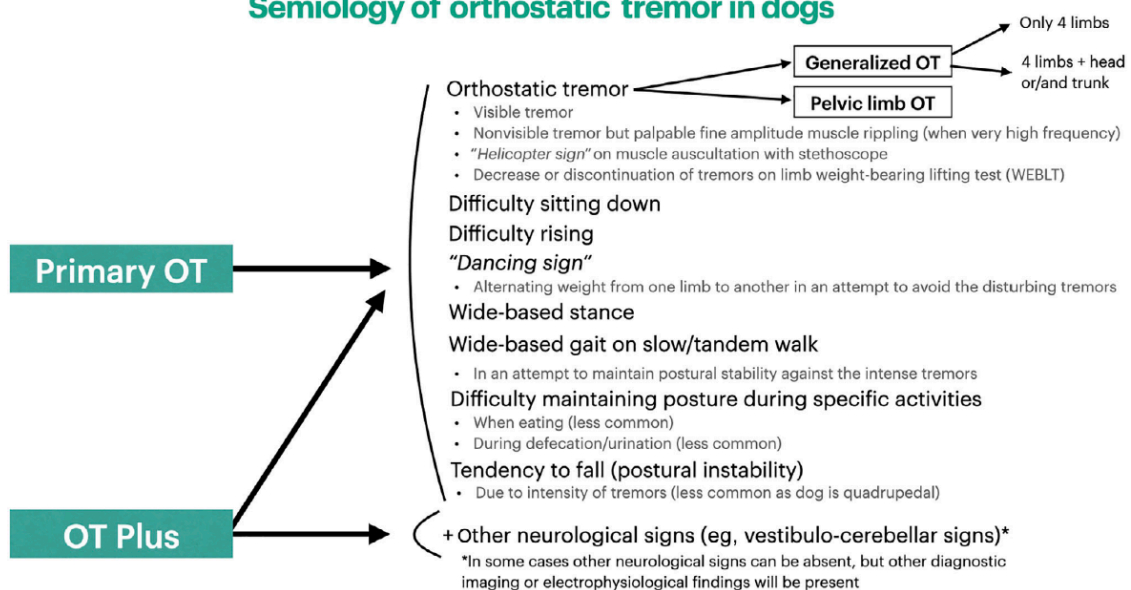



FIGURE 1 Flowchart of semiology of orthostatic tremor in dogs

Primary orthostatic tremors

- 83% large to giant breed
- 79% tremors before 2 years, Golden Retrievers after 3,5 years
- 85% limbs tremor when standing, 45% when sitting
- They do better but not back to normal with gabapentin 20 mg/kg BID, phenobarbital, clonazepam



On ultrasound control, all the changes are back to normal

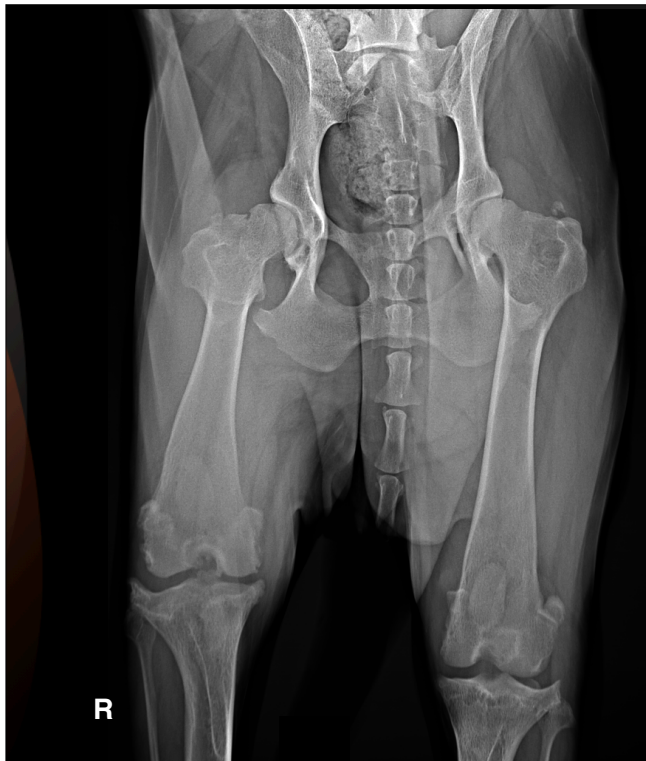
Makarena, Bernese Mountain Dog, FS, 9 years

- Two days ago yelped and collapsed on the floor
- Refuse to stand



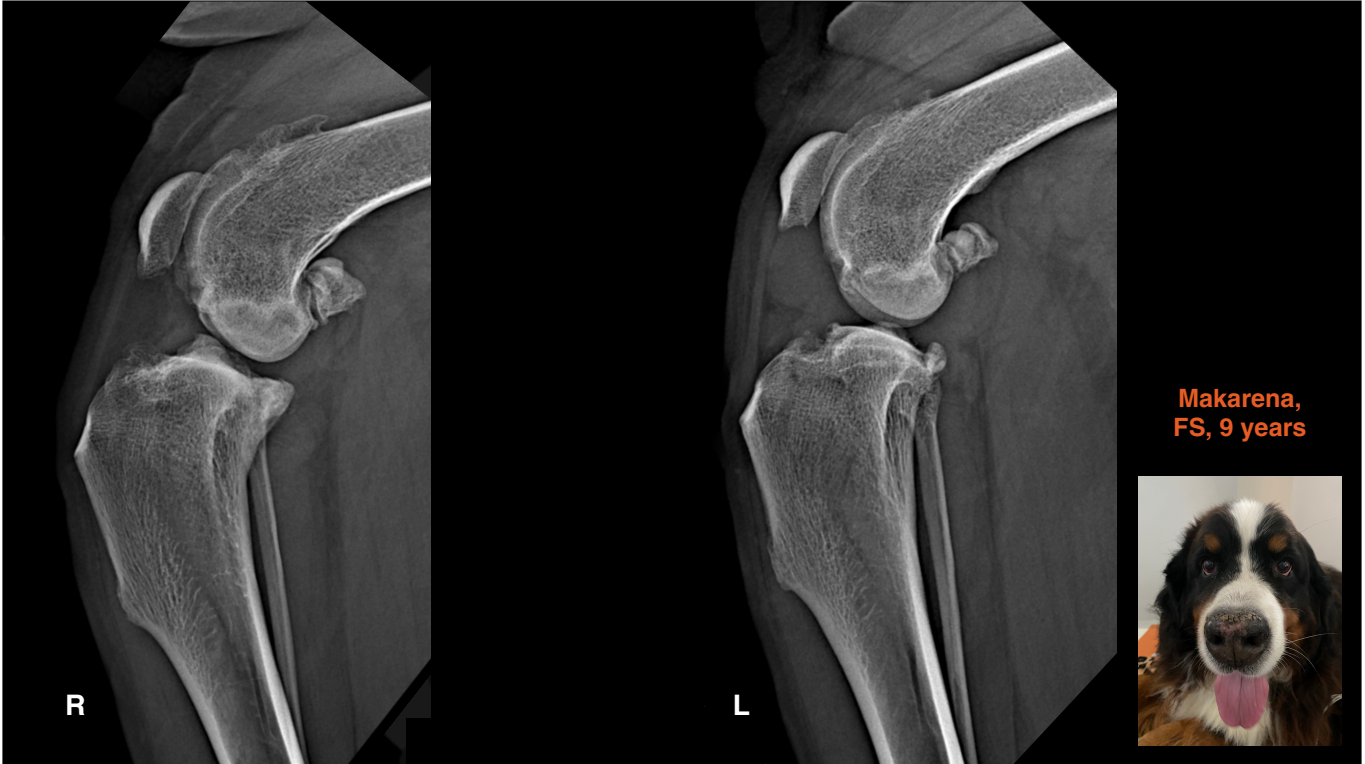Makarena, Bernese Mountain Dog, FS, 9 years

- PE mild lumbar-sacral pain
- Pain hip joint extension
- Swollen left stifle reduced ROM
- Medial buttress right stifle

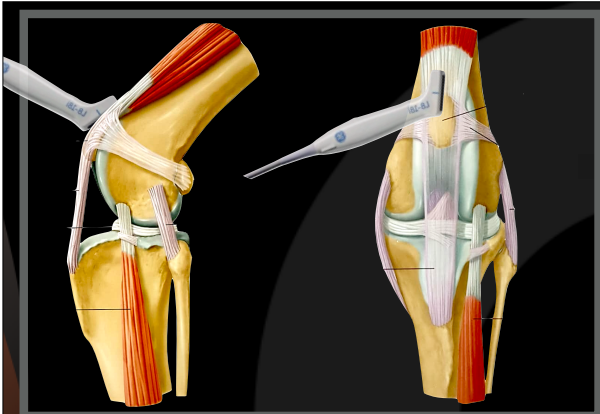


Makarena, FS, 9 years





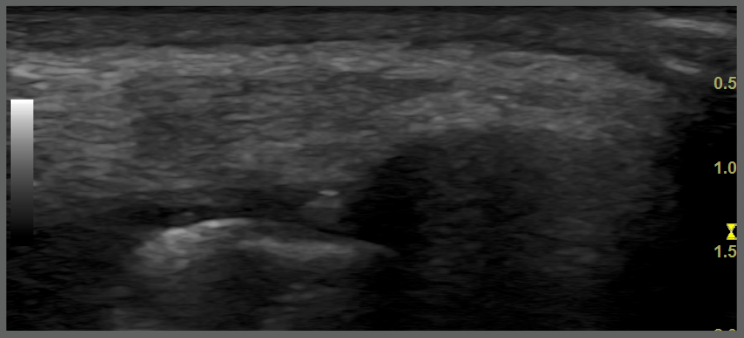
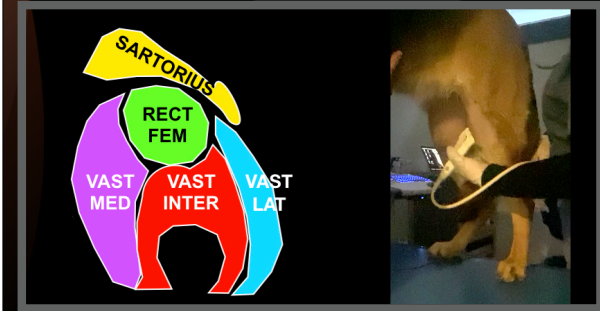
Makarena,
FS, 9 years



Makarena,
FS, 9 years

Right stifle

Cranial face longitudinal scan

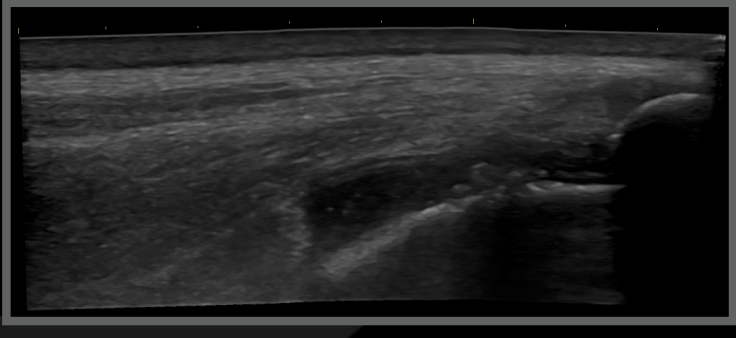
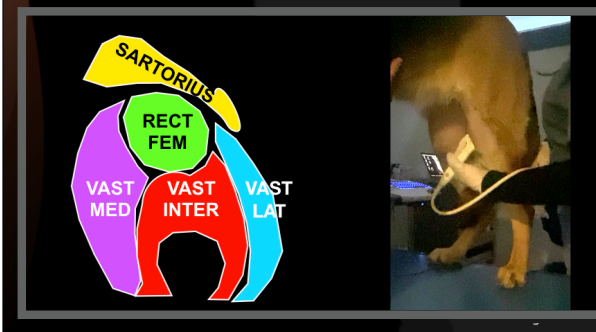
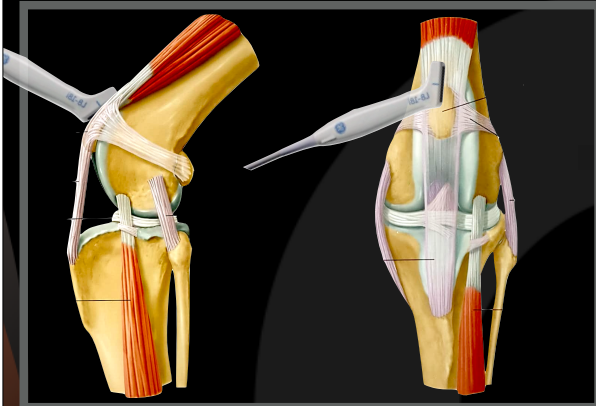


Makarena,
FS, 9 years

Left stifle



Cranial face longitudinal scan

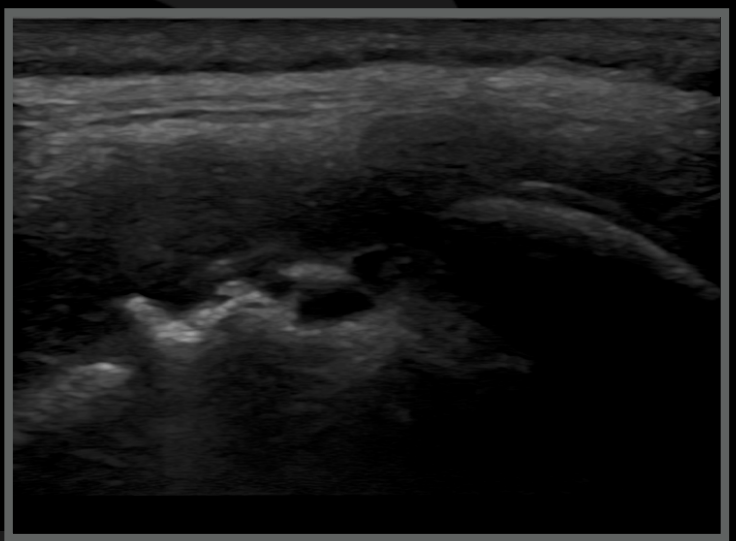
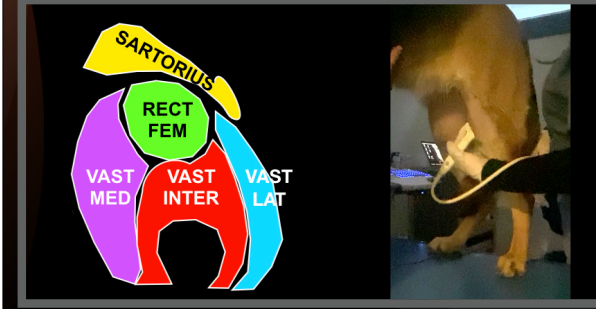
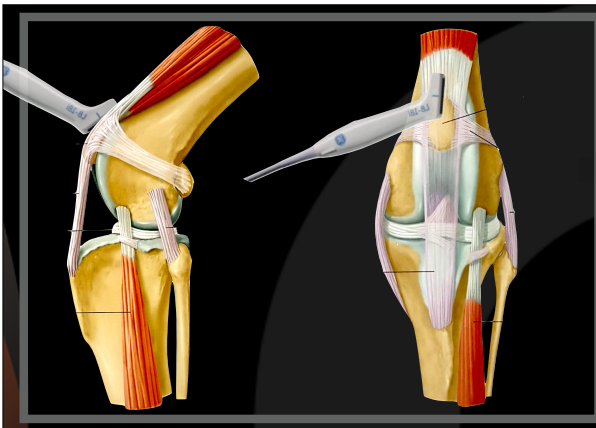


Makarena,
FS, 9 years

Left stifle



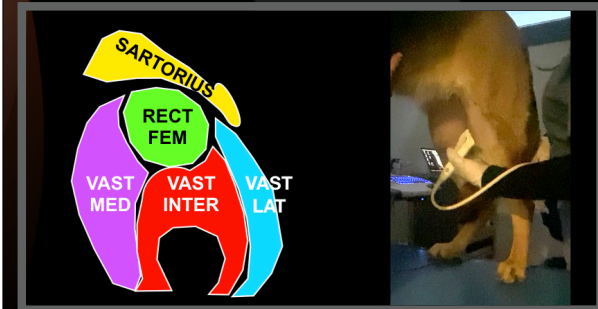
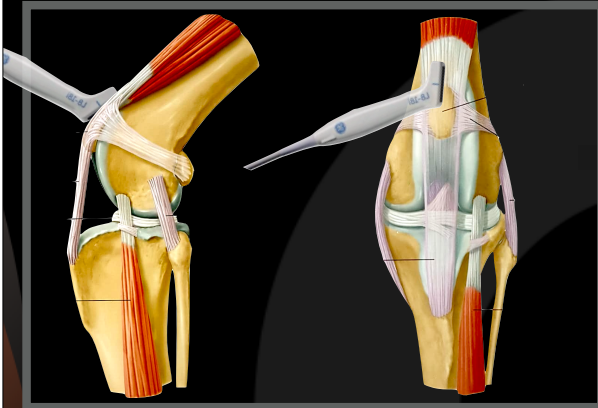
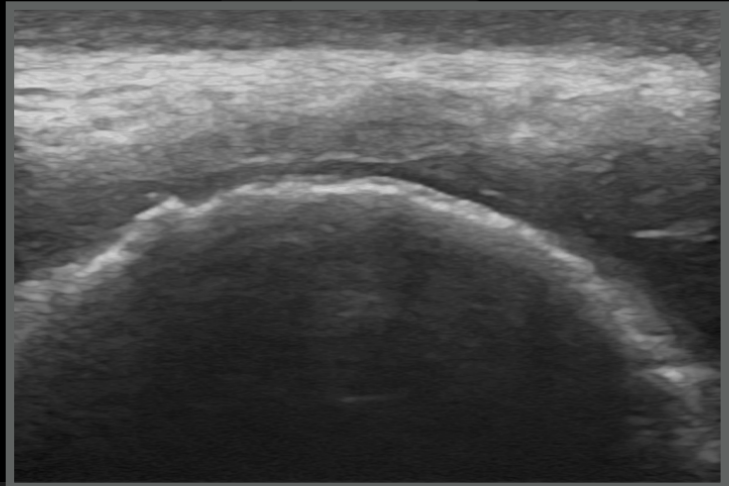
Cranial face longitudinal scan



Makarena,
FS, 9 years
Right stifle



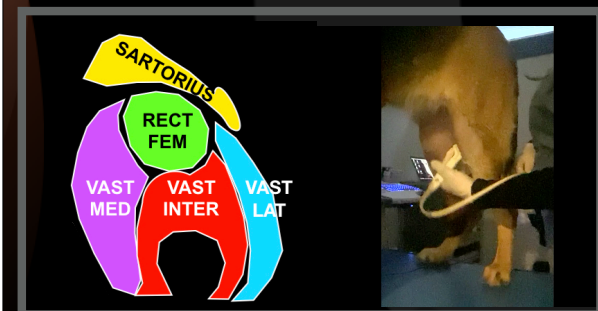
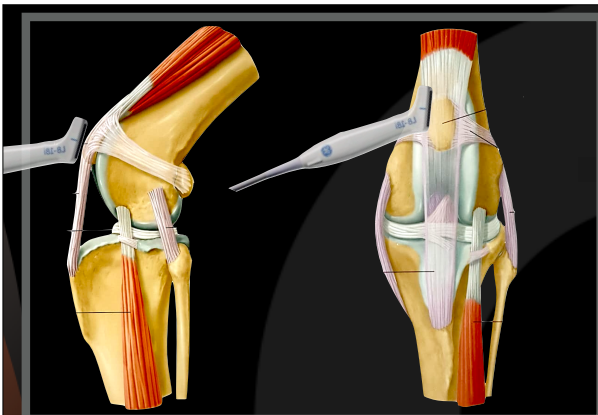
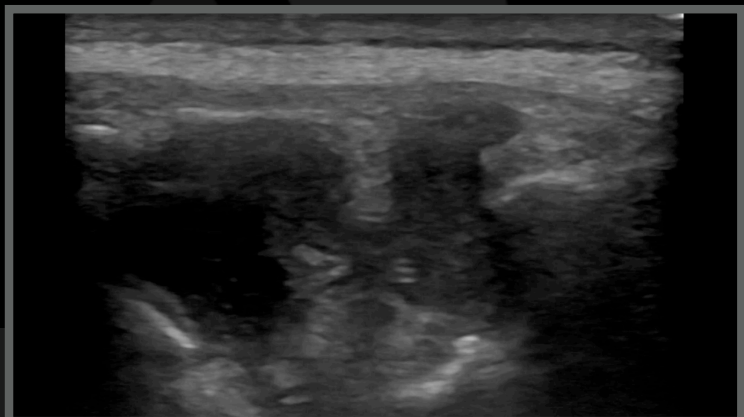
Cranial face longitudinal scan



Makarena, FS, 9 years
Left stifle



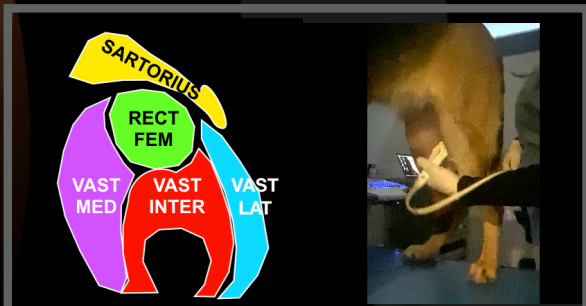
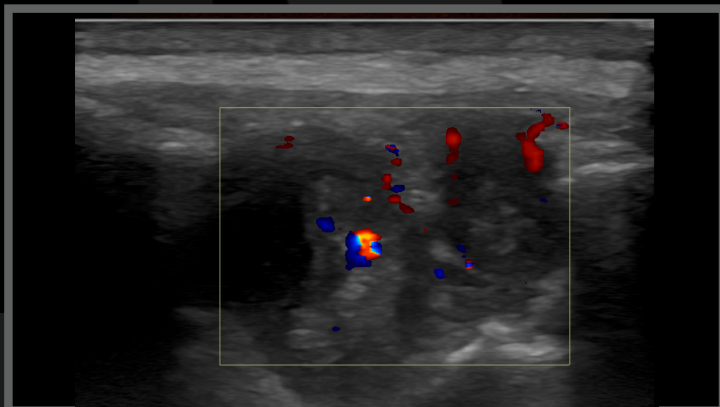
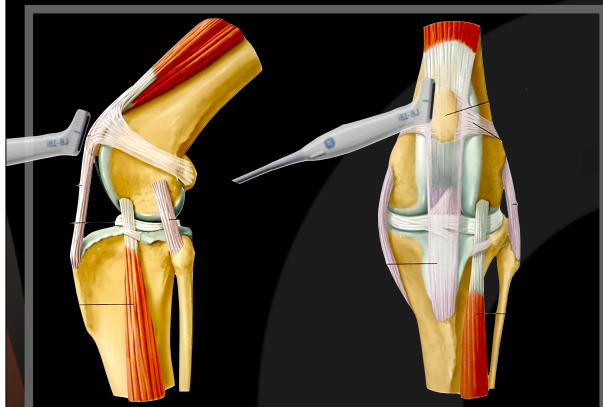
Cranial face longitudinal scan



Makarena, FS, 9 years

Left stifle



Cranial face longitudinal scan

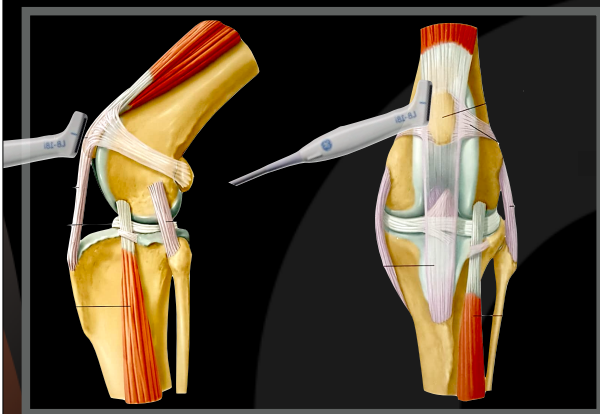


Makarena, FS, 9 years

Right stifle

Left stifle

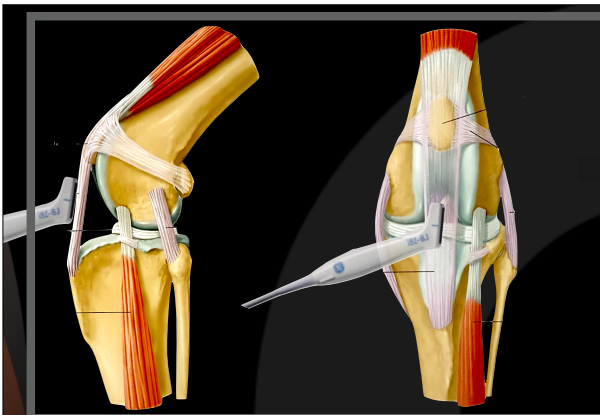
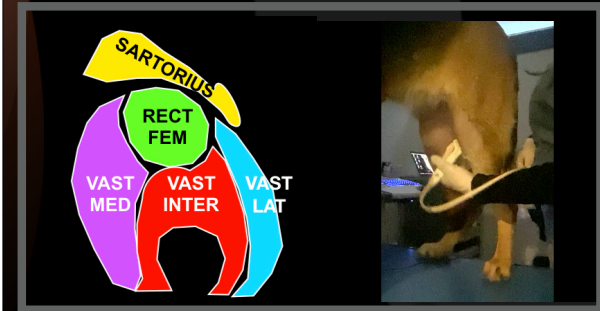
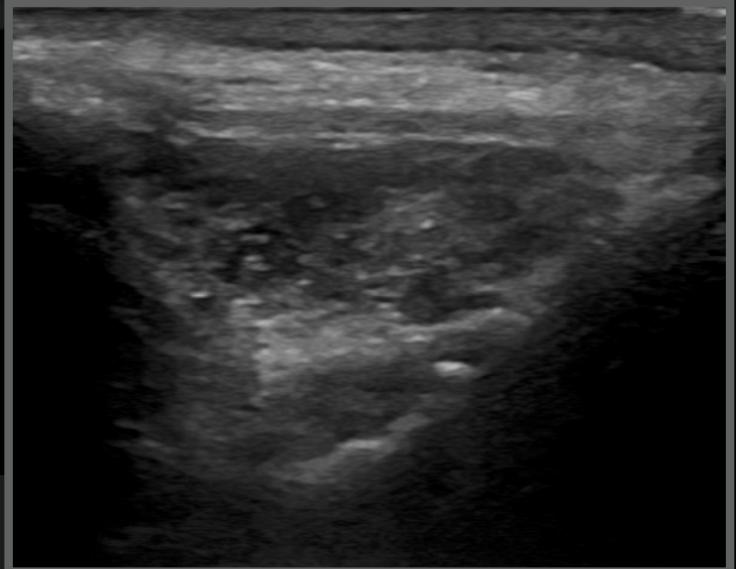




Makarena, FS, 9 years

Right stifle


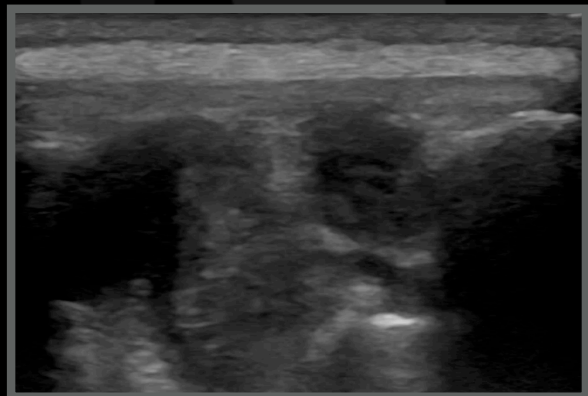
Cranial face longitudinal scan

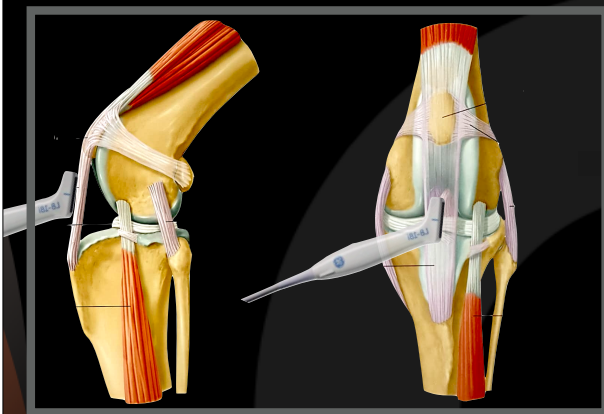


Makarena, FS, 9 years

Left stifle

Cranial to lateral face longitudinal scan

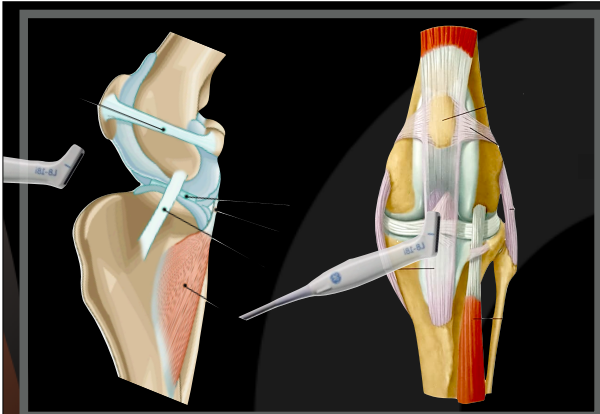
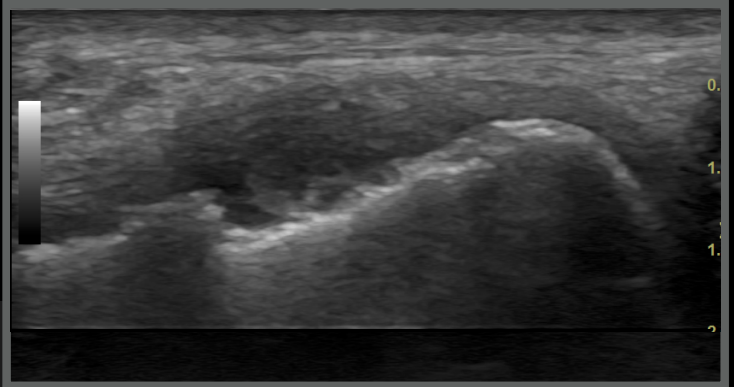




Makarena, FS, 9 years

Right stifle

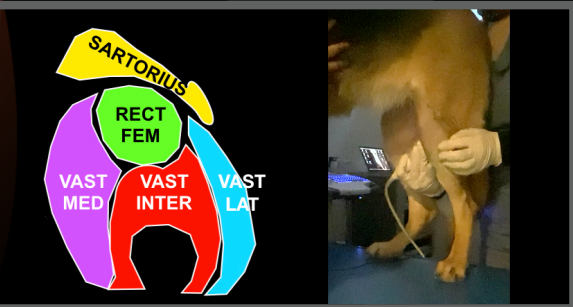
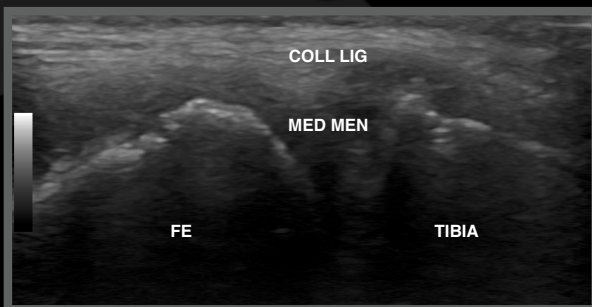
Cranial to lateral face longitudinal scan



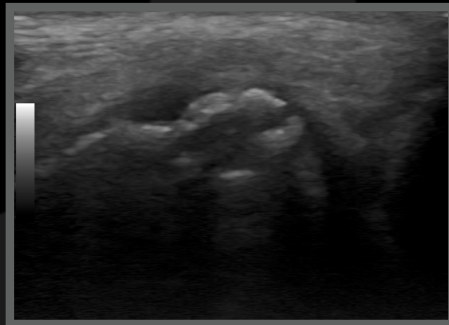
Makarena, FS, 9 years

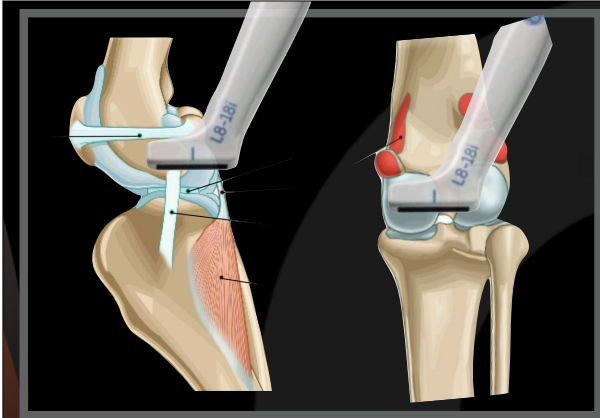
Right stifle

Medial face longitudinal scan



Left stifle





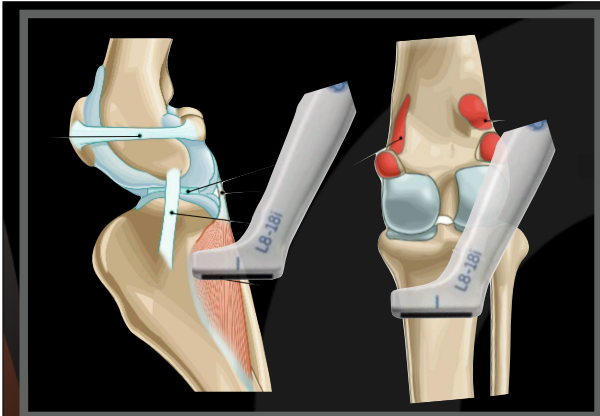
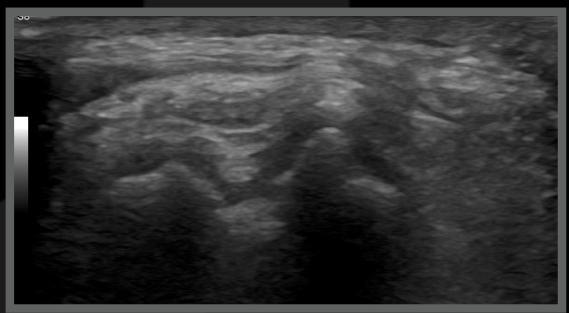
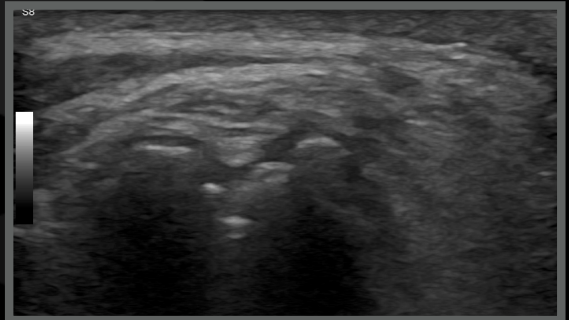
Right stifle



Left stifle

Makarena, FS, 9 years

Caudal face transverse scan



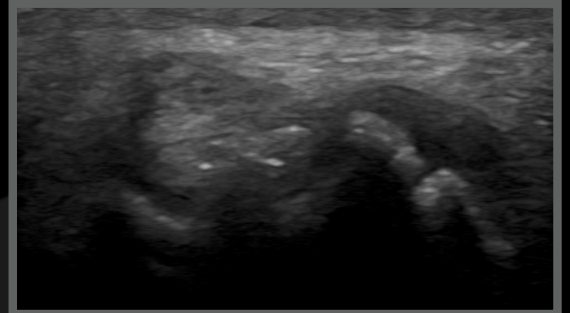
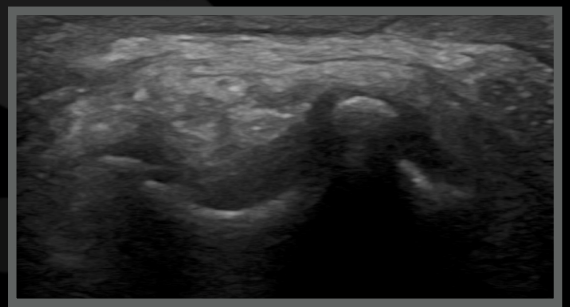
Right stifle



Left stifle

Makarena, FS, 9 years

Caudal face transverse scan

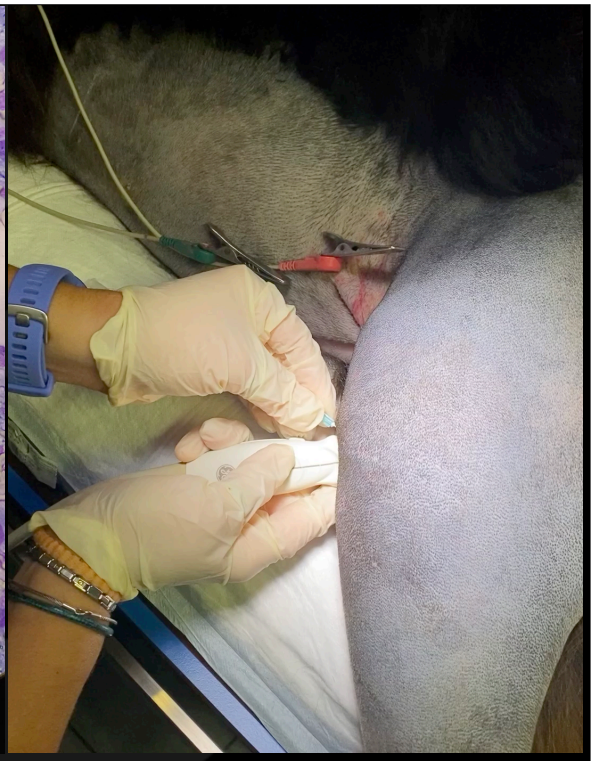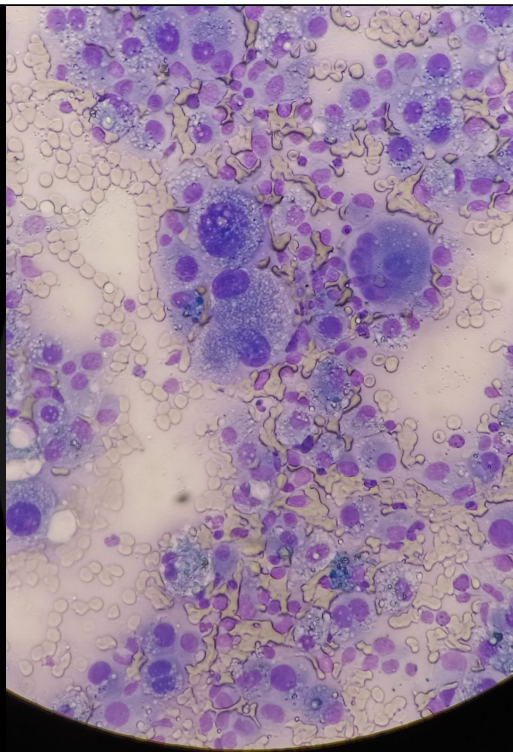


Makarena, Bernese Mountain Dog, FS, 9 years

- Severe thickening of the left stifle synovia
- What next?



Makarena,
FS, 9 years



Descrizione microscopica

Il tessuto fibroadiposo periarticolare nelle sezioni esaminate appare espanso e sostituito da una proliferazione neoplastica densamente cellulare, infiltrante, non capsulata, che raggiunge i margini di escissione esaminati. Le cellule sono disposte in aree solide con scarso stroma fibrovascolare. Le cellule neoplastiche hanno forma rotonda o vagamente globosa-poliedrica, margini non ben distinti, rapporto nucleo/citoplasmatico elevato ed una moderata quantità di citoplasma eosinofilo. Il nucleo è rotondo, con cromatina finemente granulata o marginata ed 1-3 nucleoli prominenti. Anisocariosi ed anisocitosi sono gravi con macrocariosi, macrocitosi e cellule giganti multinucleate. Sono presenti fino ad 8 mitosi per campo a 400X. La neoplasia è multifocalmente infiltrata da linfociti e plasmacellule.

Diagnosi

Il quadro istomorfologico è indicativo per la diagnosi di neoplasia maligna di alto grado.

Commento: in diagnosi differenziale, per la morfologia cellulare prevalente e la presenza di cellule multinucleate, si pone in prima istanza un sarcoma istiocitario. In diagnosi differenziale, anche se meno probabile, un sarcoma di altro tipo. È possibile eseguire sul campione già inviato al laboratorio un'indagine immunohistochimica (IBA1, CD18) per confermare la natura **istiocitaria** della neoplasia. In caso di negatività sarà possibile ampliare il pannello.

Thank you



Diagnostic Mindset

www.diagnosticmindset.com