

## Cases Discussion

Gliola Spattini  
DVM, GP Cardio, CCRT, PhD, DECVI



Diagnostic Mindset



Thank to [www.imaios.com](http://www.imaios.com)

---

---

---

---

---

---

---

---

### Tia, Poodle, FI, 14 months

- The owner thinks that the dog walks "funny"
- Quite for a puppy
- Difficult standing in the morning
- First consultation diagnoses hip dysplasia
- Second consultation disagreed



---

---

---

---

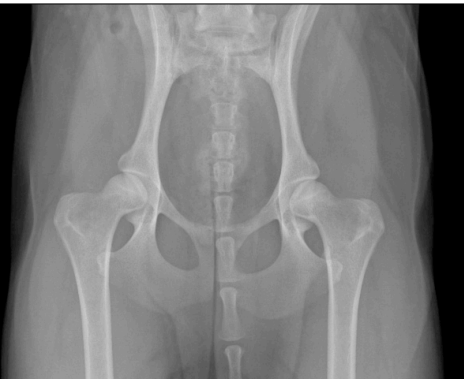
---

---

---

---

Tia, FI, 14 months



---

---

---

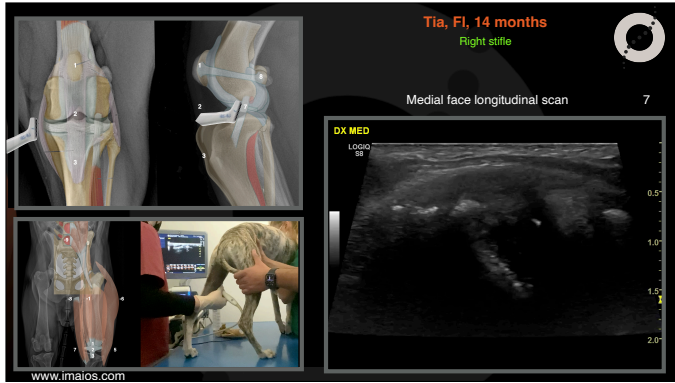
---

---

---

---

---



---

---

---

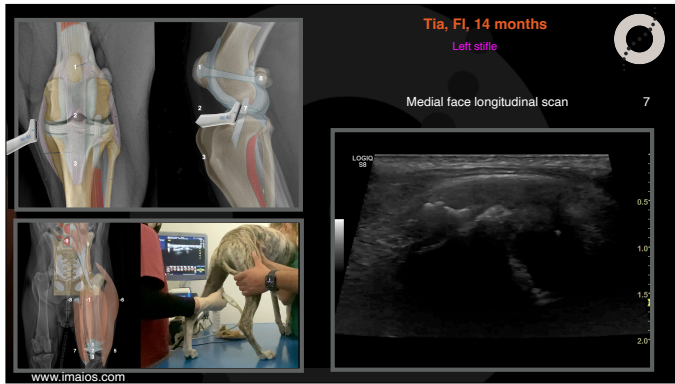
---

---

---

---

---



---

---

---

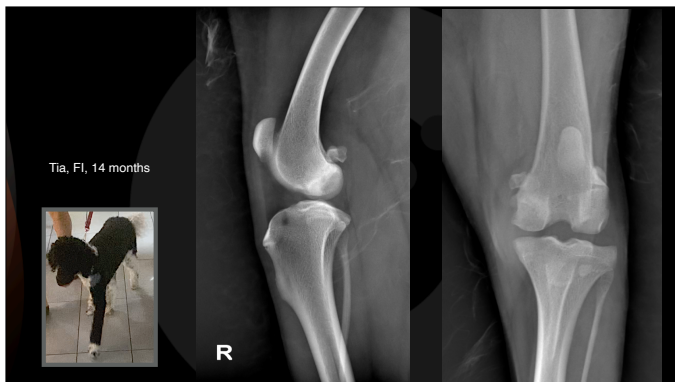---

---

---

---

---



---

---

---

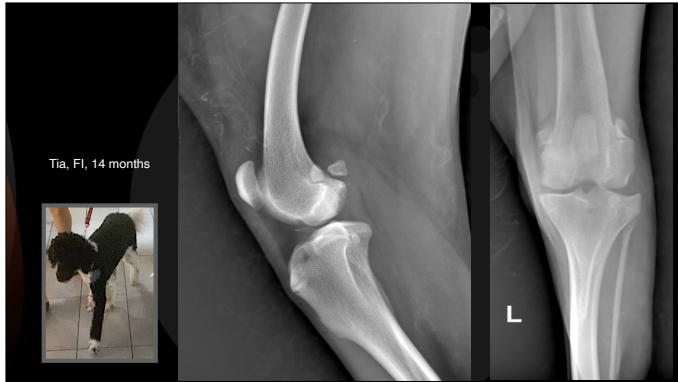---

---

---

---

---



---

---

---


---

---

---

---

---



---

---

---

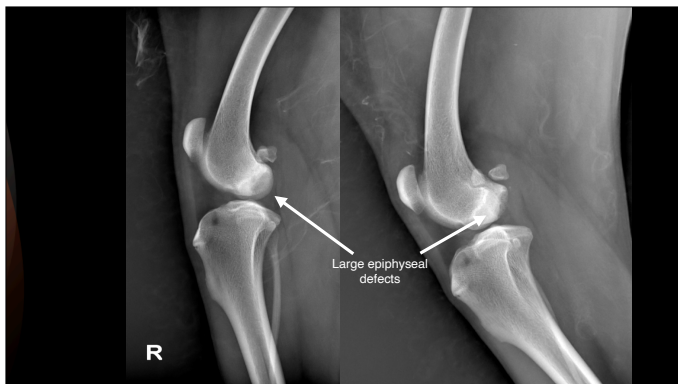---

---

---

---

---



---

---

---

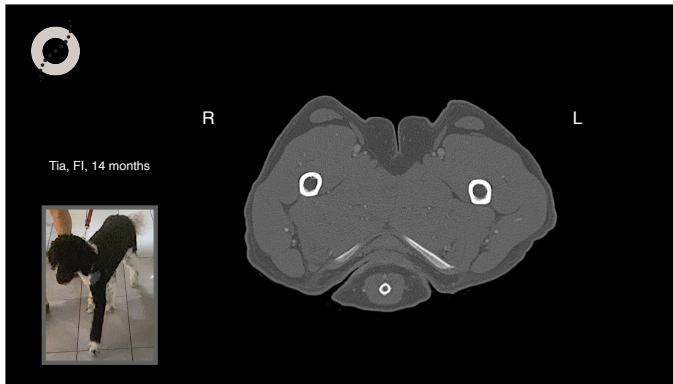
---

---

---

---

---




---

---

---

---

---

---

---

---

---

---

**Treatment of Osteochondrosis Dissecans of the Canine Stifle Using Synthetic Osteochondral Resurfacing**

Pádraig Egan<sup>1</sup> Susan Murphy<sup>1</sup> Jelena Jovanovic<sup>1</sup> Russell Tucker<sup>2</sup> Noel Fitzpatrick<sup>1</sup>

<sup>1</sup> Department of Orthopaedics and Neurology, Fitzpatrick Referrals, Easing, Surrey, United Kingdom  
<sup>2</sup> Department of Radiology, Washington State University, Pullman, Washington, United States

Address for correspondence: Pádraig Egan, BVMS, CertAVP (GSAS), MRCVS, Department of Orthopaedics and Neurology, Fitzpatrick Referrals, Easing, Surrey GU7 2QQ, United Kingdom (e-mail: padraig@fitzpatrickreferrals.co.uk).

Vet Comp Orthop Traumatol 2018;31:144-152.

---

---

---

---

---

---

---

---

---

---

Tia, Poodle, FI, 14 months

- Bilateral and severe stifle OC
- Partial stifles prosthesis installed

---

---

---

---

---

---

---

---

---

---

Tia, Poodle, FI, 24 months

- Control
- She is doing fine



---

---

---

---

---

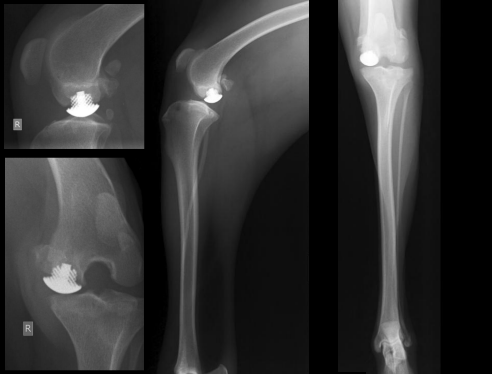---

---

---



Tia, FI, 24 months



---

---

---

---

---

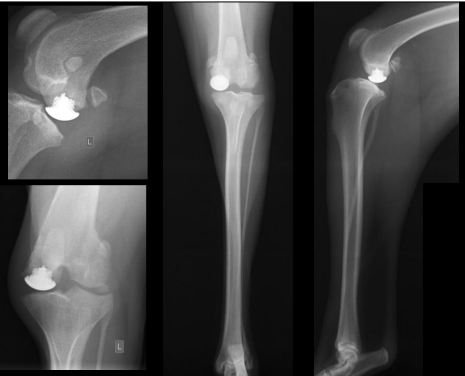---

---

---



Tia, FI, 24 months



---

---

---

---

---

---

---

---

Tia, Poodle, FI, 5 years

• Still doing fine!



---

---

---

---

---

---

---

---

Ginevra, Whippet, FI, 5 years

- Right stifle swinging lameness last three months
- Resolved with NSAID
- Relapse when medication is stopped
- Radiographs performed: suspected ruptured CCL



---

---

---

---

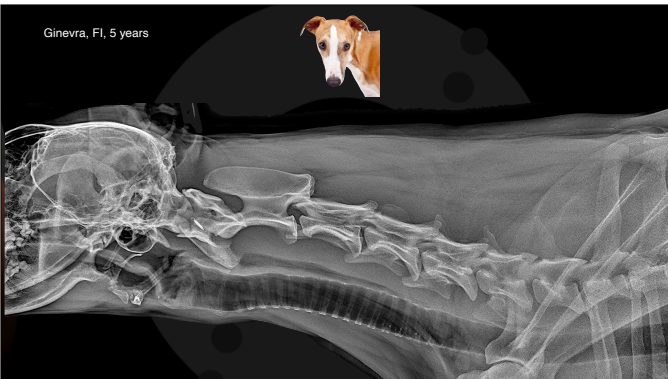---

---

---

---

Ginevra, FI, 5 years



---

---

---

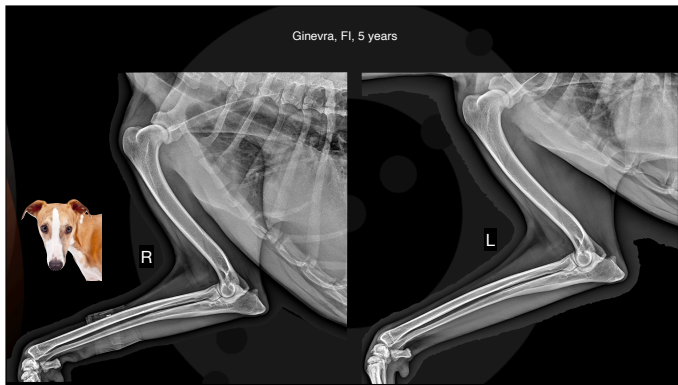
---

---

---

---

---



---

---

---

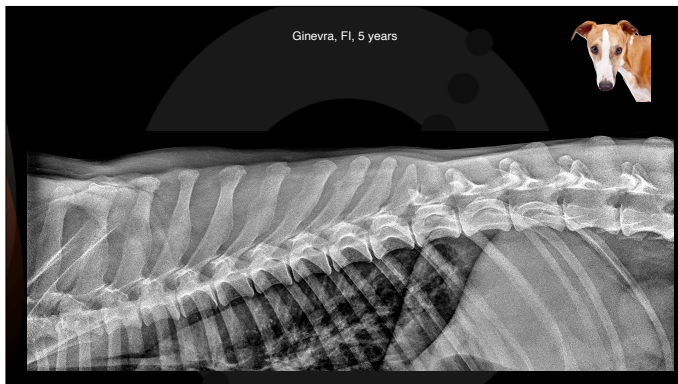
---

---

---

---

---



---

---

---

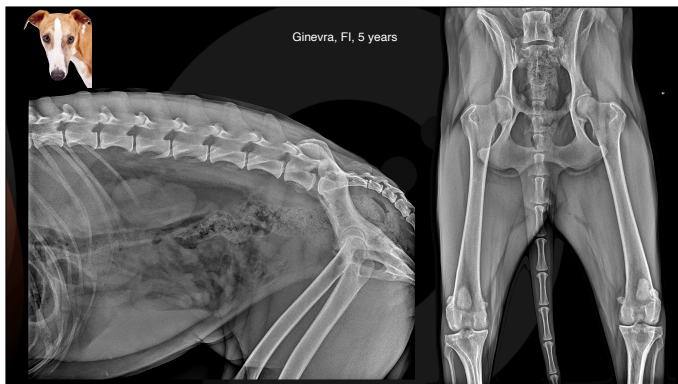
---

---

---

---

---



---

---

---

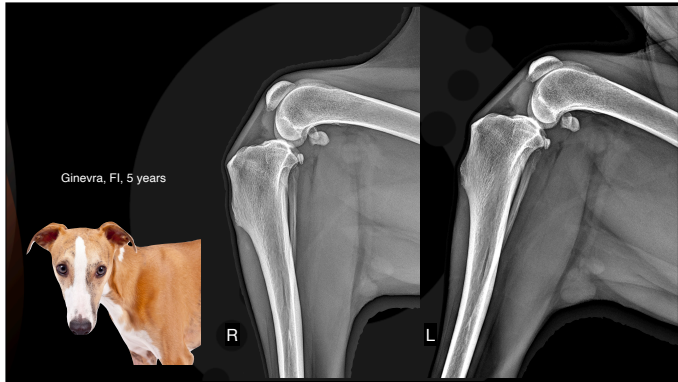
---

---

---

---

---



---

---

---

---

---

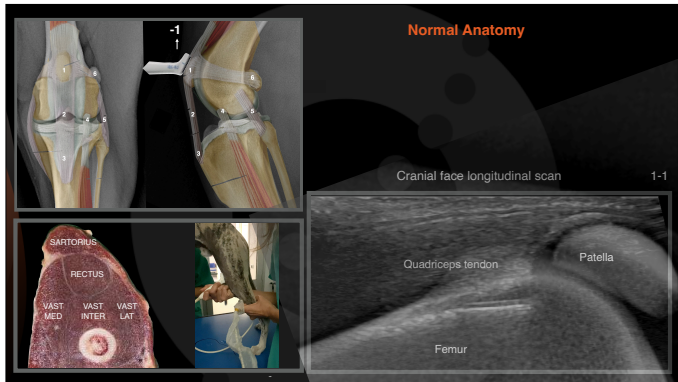
---

---

---

---

---



---

---

---

---

---

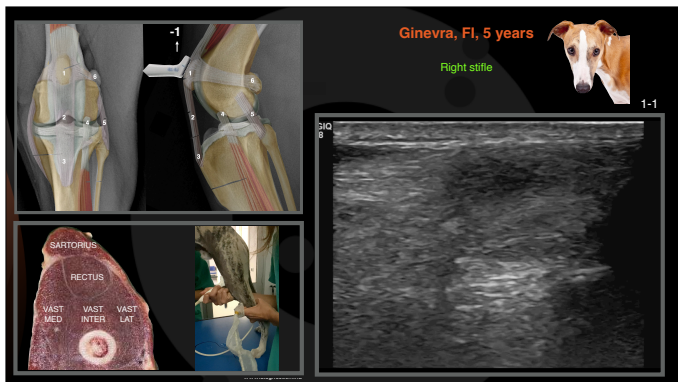
---

---

---

---

---



---

---

---

---

---

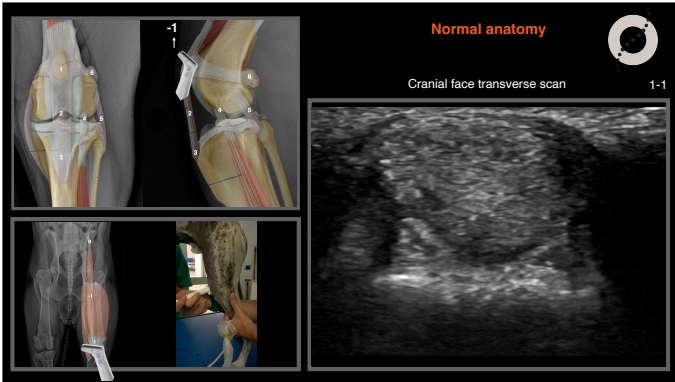
---

---

---

---

---



---

---

---

---

---

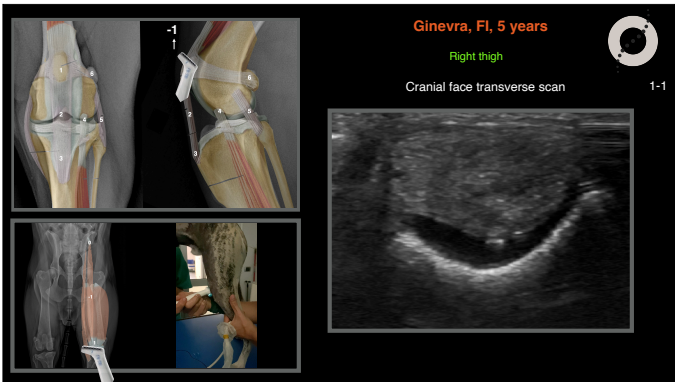---

---

---

---

---



---

---

---

---

---

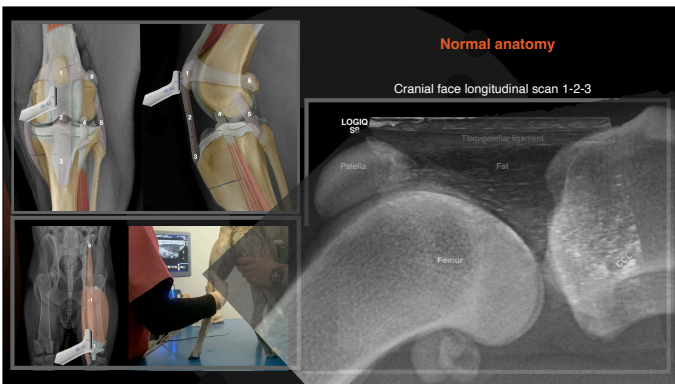
---

---

---

---

---



---

---

---

---

---

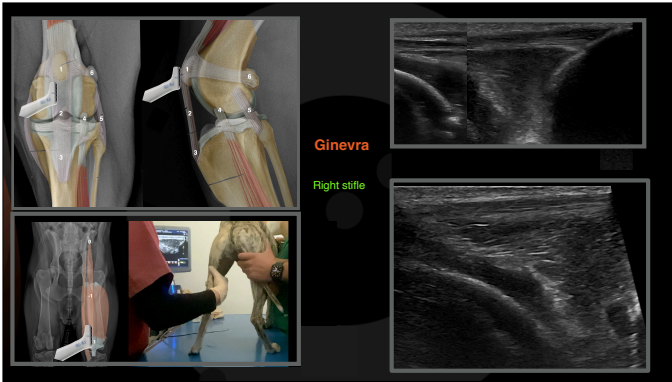
---

---

---

---

---



---

---

---

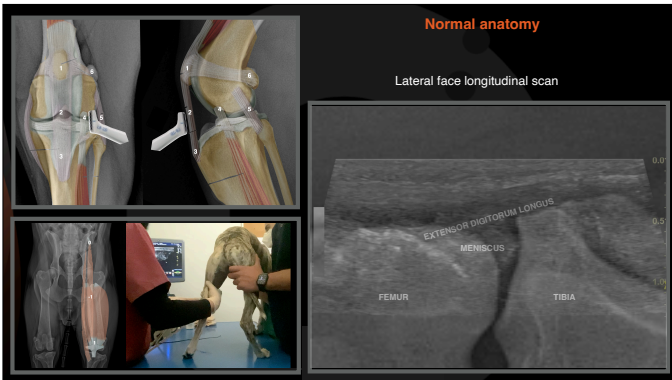---

---

---

---

---



---

---

---

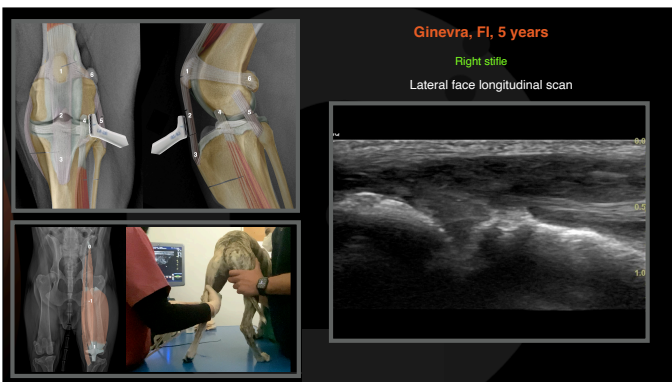---

---

---

---

---



---

---

---

---


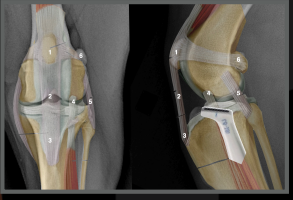
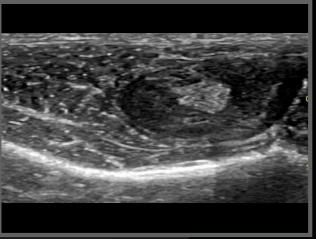
---

---

---

---

**Ginevra, FI, 5 years**  
Right stifle  
Lateral face transverse scan



---

---

---

---


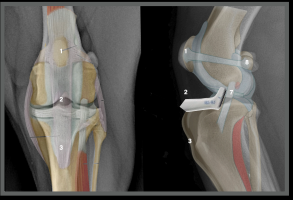
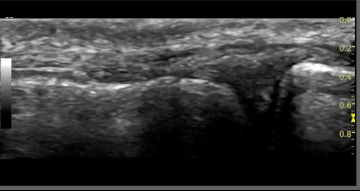
---

---

---

---

**Normal anatomy**



---

---

---

---


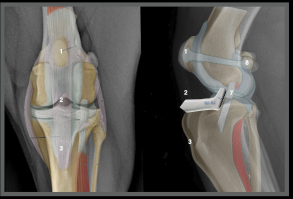
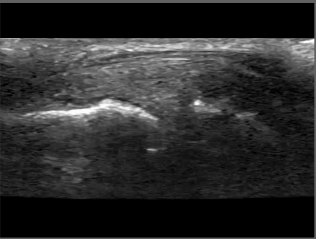
---

---

---

---

**Ginevra, FI, 5 years**  
Right stifle  
Medial face longitudinal scan



---

---

---

---

---

---

---

---





Thank you



Diagnostic Mindset

[www.diagnosticmindset.com](http://www.diagnosticmindset.com)

---

---

---

---

---

---

