

Partial rupture of the Achille's tendon in a Galgo

Can ultrasound help to decide the
best treatment for this patient?



Diagnostic Mindset



Giliola Spattini
DVM, PhD, DECVDI

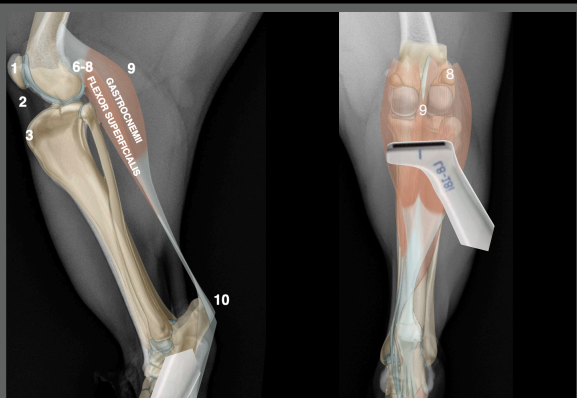
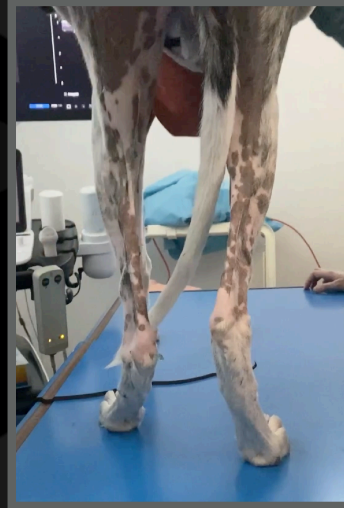Jamaal, Galgo, MN, 5 years

- Partial resection by a glass of the left Achille's tendon
- Immediately repaired by the vet
- Two weeks later, at the first run, the dog became acutely 4th-degree lame

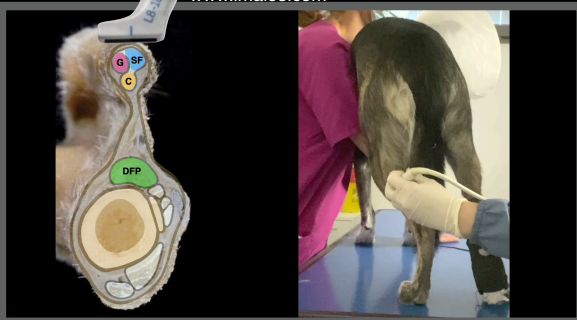


Jamaal, Galgo, MN, 5 years

- Still second degree lame three weeks later
- Check to decide on conservative or surgical repair
- Thickened left Achille's tendon at the calcaneal insertion



www.imaios.com

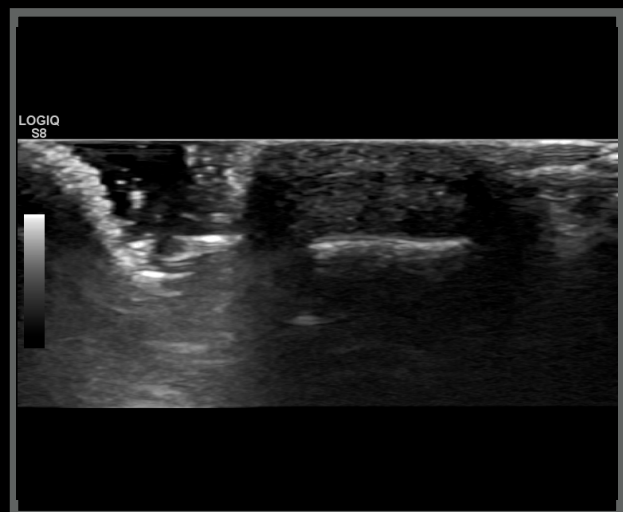


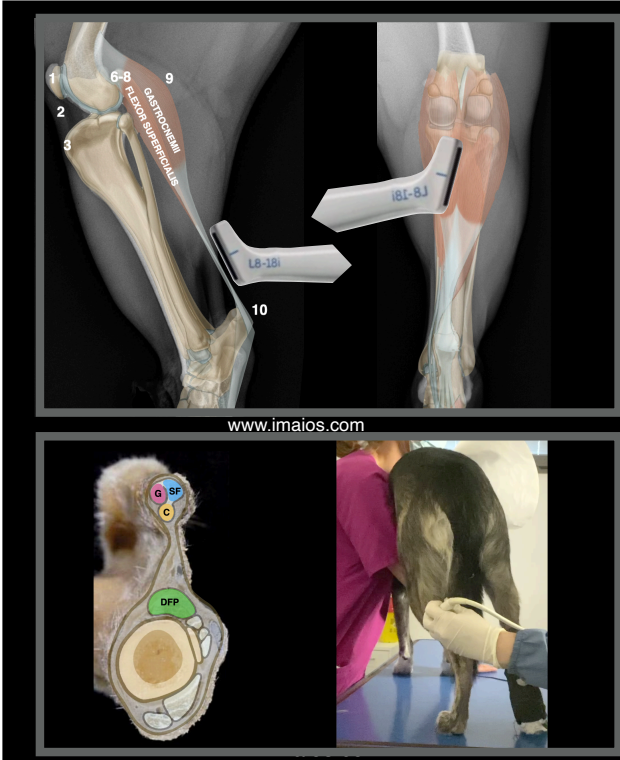
Jamaal, MN, 5 years

Left thigh

Caudal face transverse scan

9





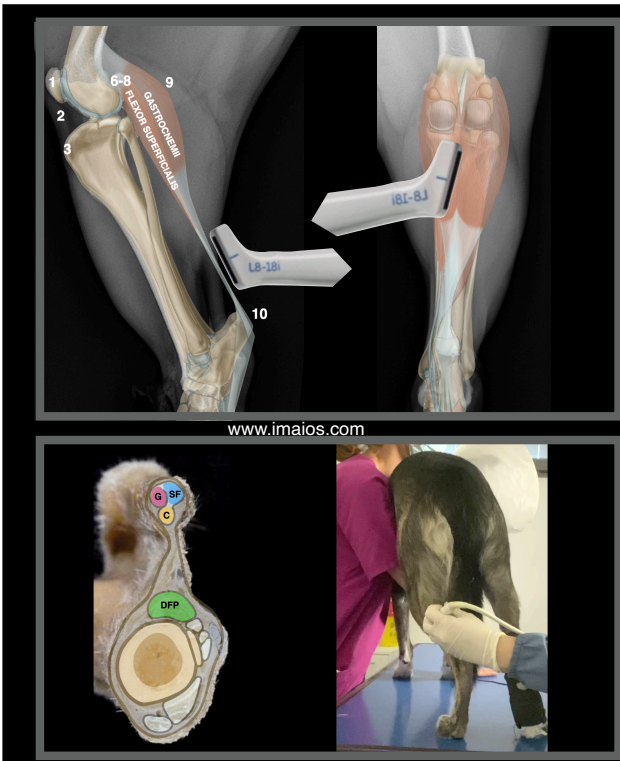
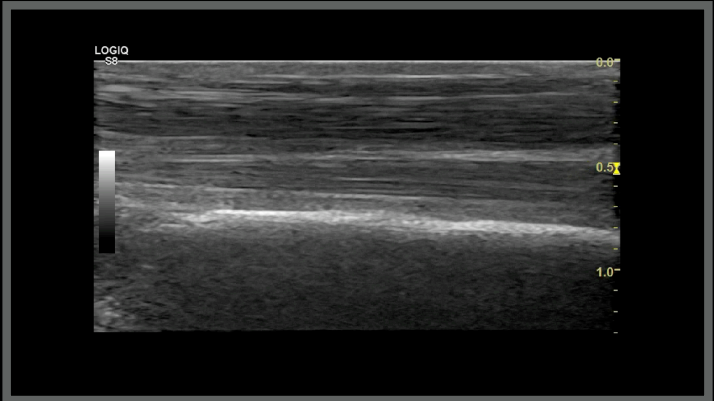
Jamaal, MN, 5 years

Left thigh

Caudal face longitudinal scan



9



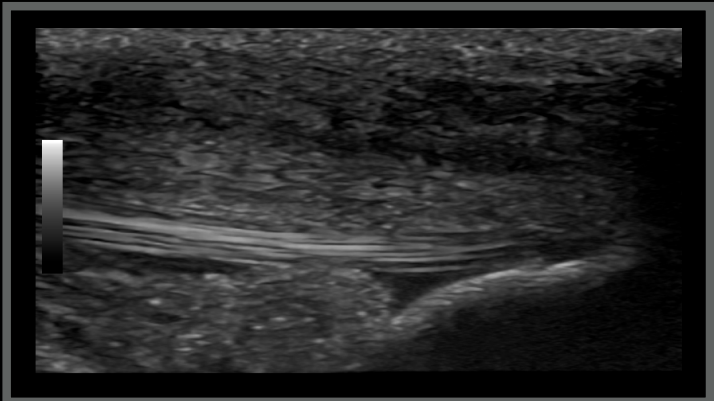
Jamaal, MN, 5 years

Left thigh

Caudal face longitudinal scan

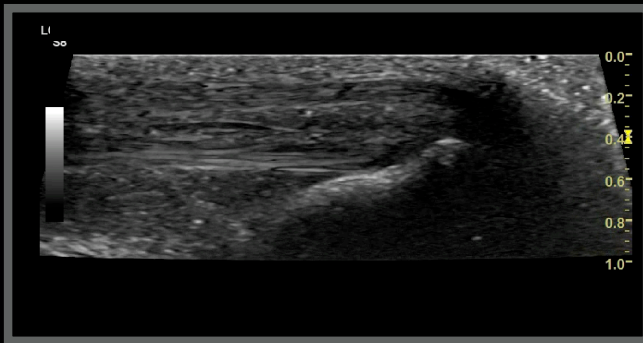


9

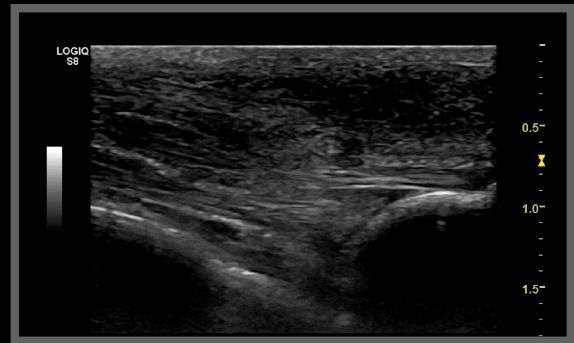


Jamaal, Galgo, MN, 5 years

Right Achille's tendon



Left Achille's tendon



Jamaal, Galgo, MN, 5 years

Ultrasonographic diagnoses

- Ruptured flexor superficialis tendon
- Partially affected gastrocnemius tendon
- Unremarkable communis tendon

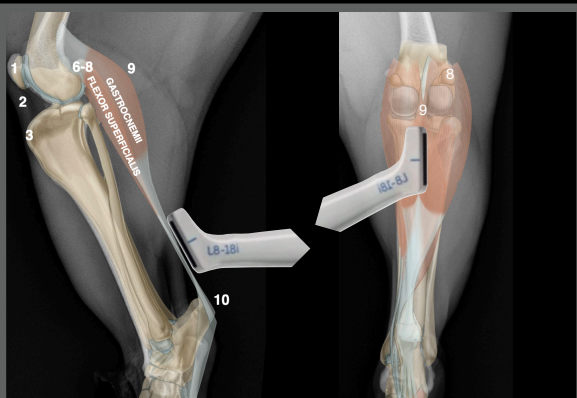


Next steps?

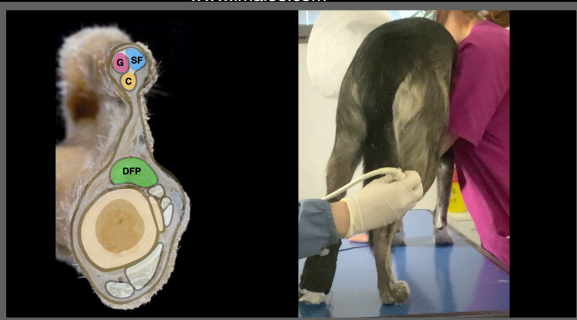
Jamaal, Galgo, MN, 5 years

Three months later

- Started physiotherapy
- Initially soft brace and leash
- Then treadmill and home exercise



www.imaios.com

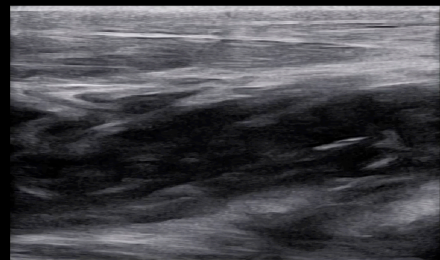


Jamaal, MN, 5 years

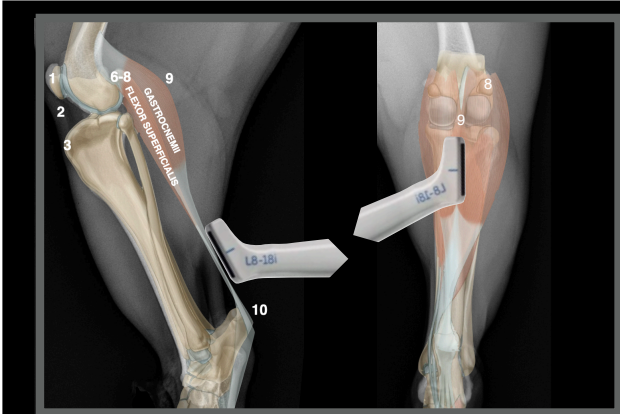
Three months later

Right limb

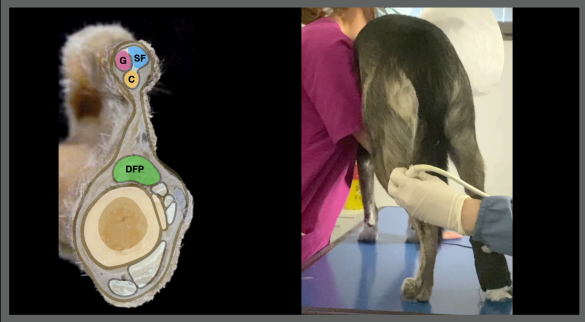
Caudal face longitudinal scan



9



www.imaios.com



Jamaal, MN, 5 years

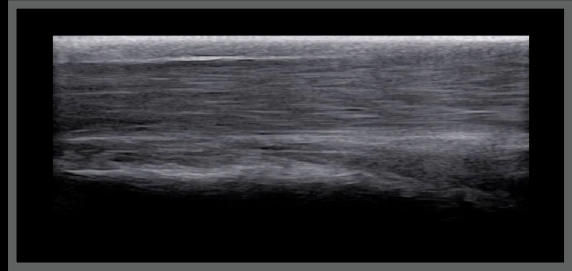
Three months later

Left limb

Caudal face longitudinal scan



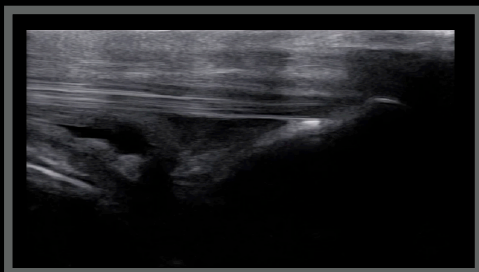
9



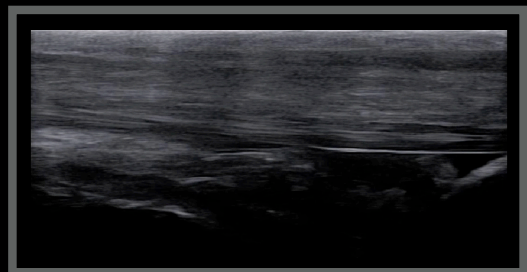
Jamaal, Galgo, MN, 5 years

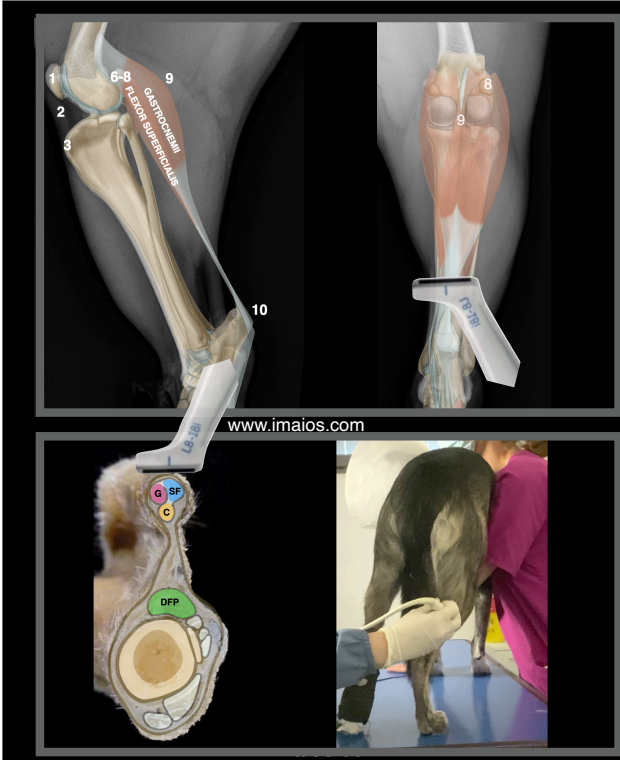


Right Achille's tendon



Left Achille's tendon





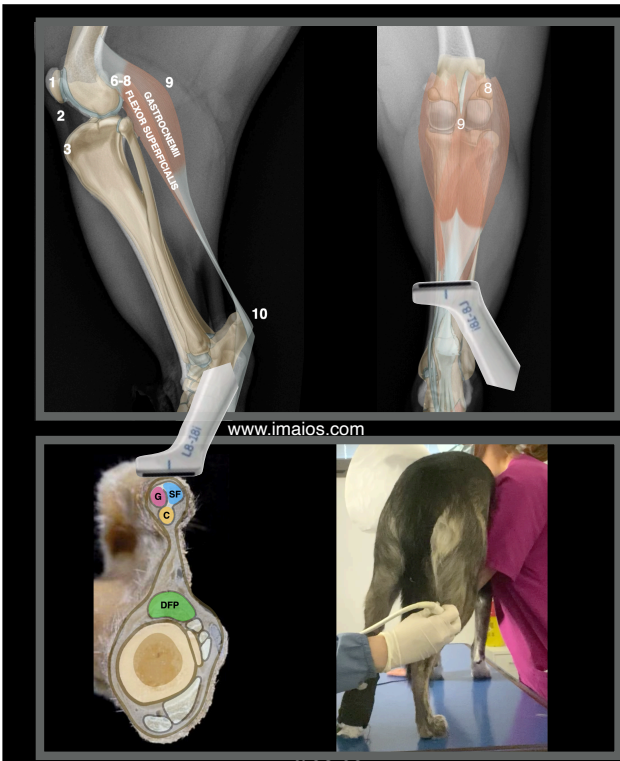
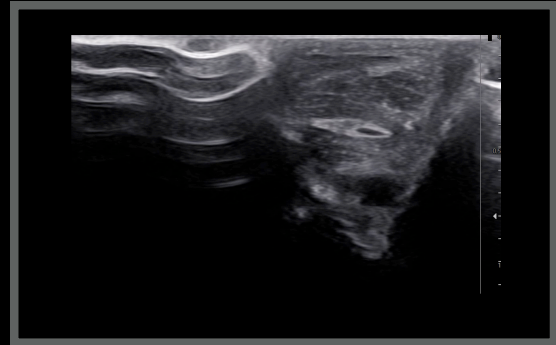
Jamaal, MN, 5 years



Right limb

10

Caudal face transverse scan



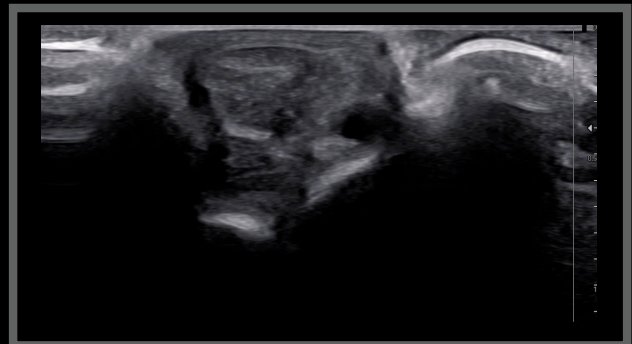
Jamaal, MN, 5 years



Left limb

10

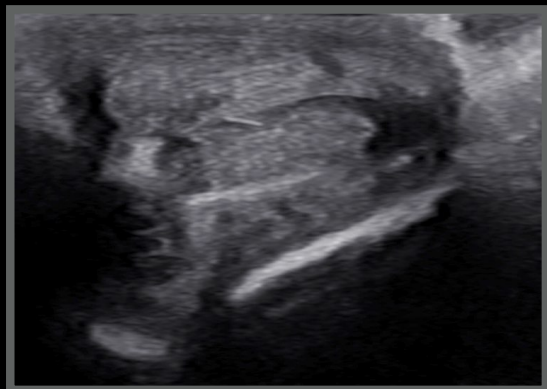
Caudal face transverse scan



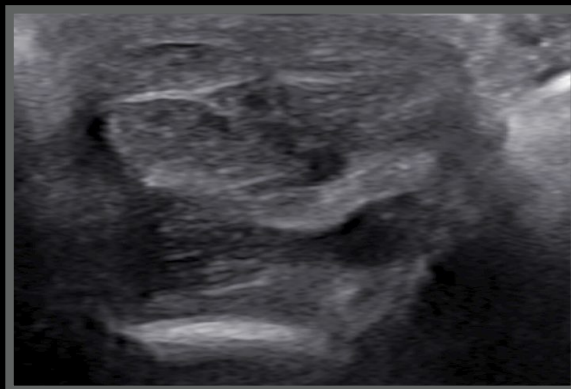Jamaal, Galgo, MN, 5 years



Right Achille's tendon



Left Achille's tendon



Jamaal, Galgo, MN, 5 years

Three months later

Ultrasonographic diagnoses

- More uniformly echoic left superficial tendon
- Morphologic healing
- Functional healing???

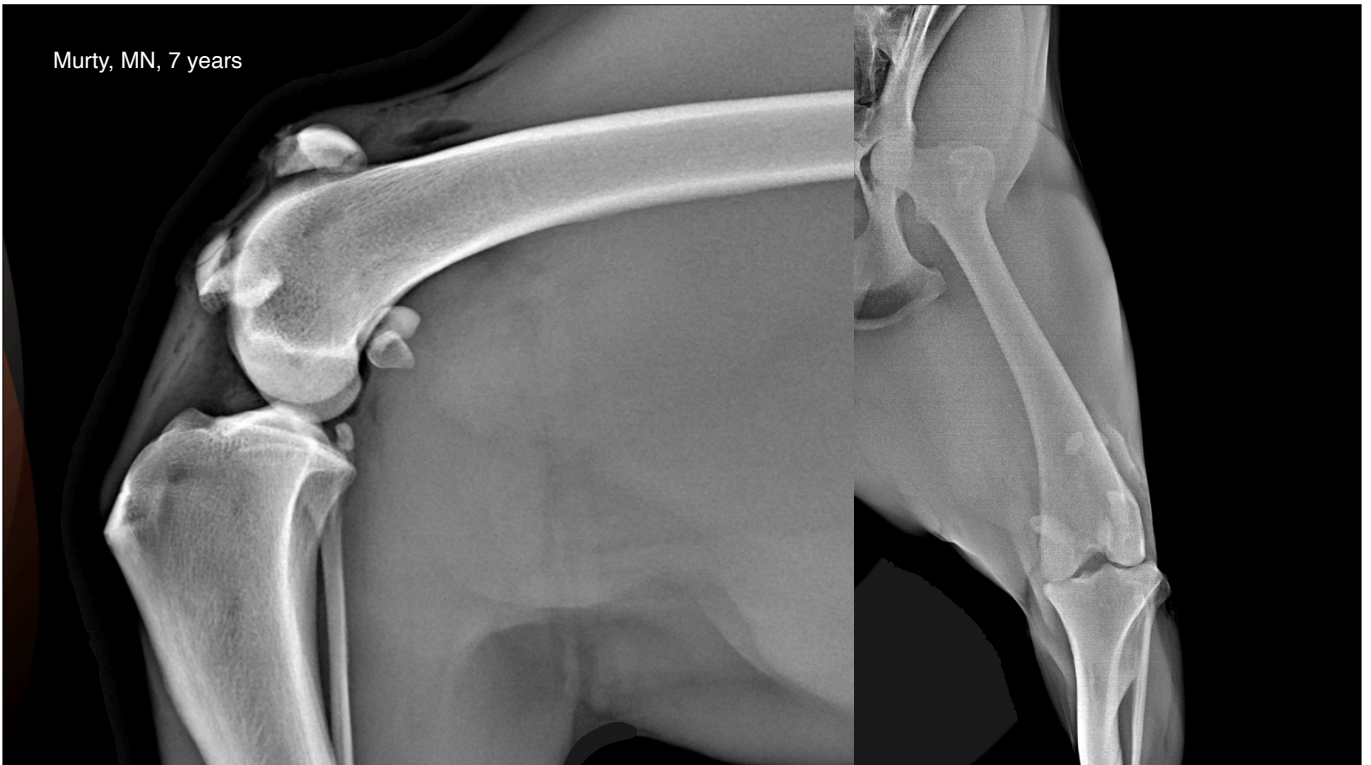


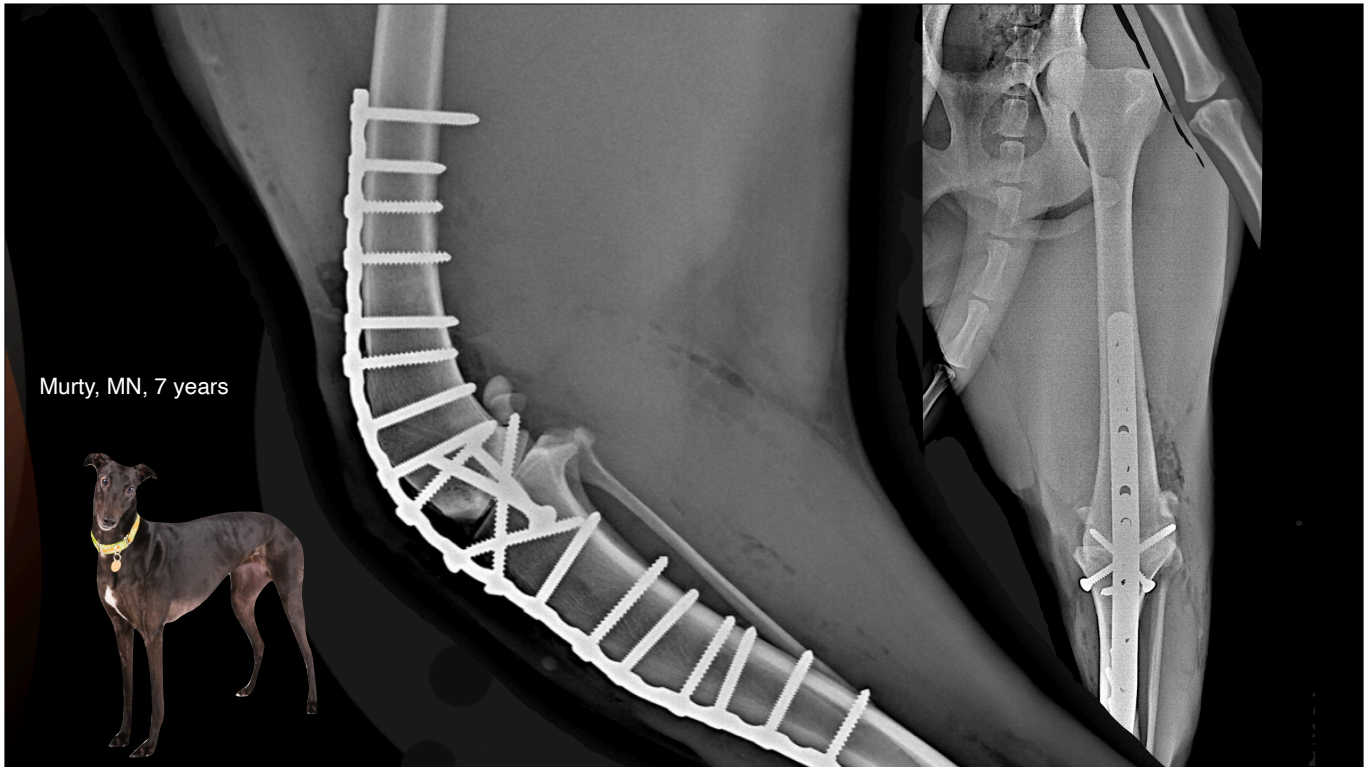
Murty, Greyhound, MN, 7 years

- After running acutely lame
- A trauma was considered likely



Murty, MN, 7 years





Murty, MN, 7 years

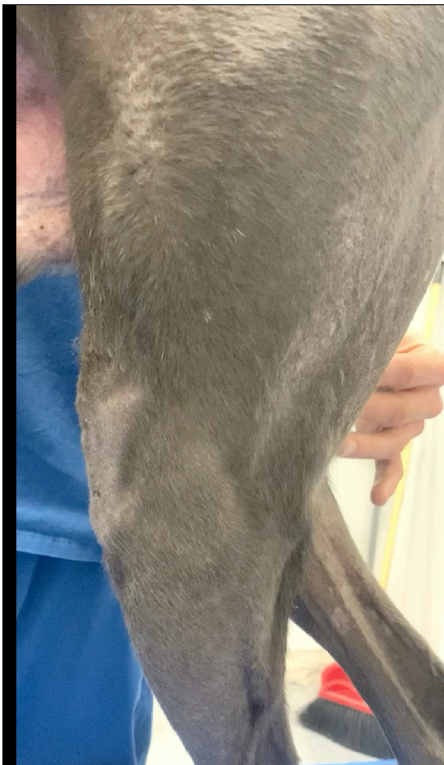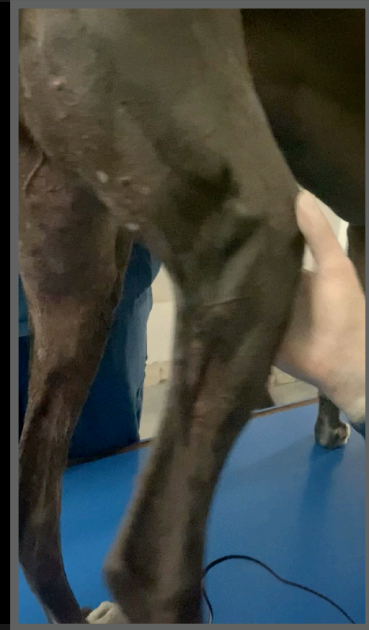
Murty, Greyhound, MN, 7 years

- Immediately after surgery, mild improvement
- After two months progressively worsening lameness

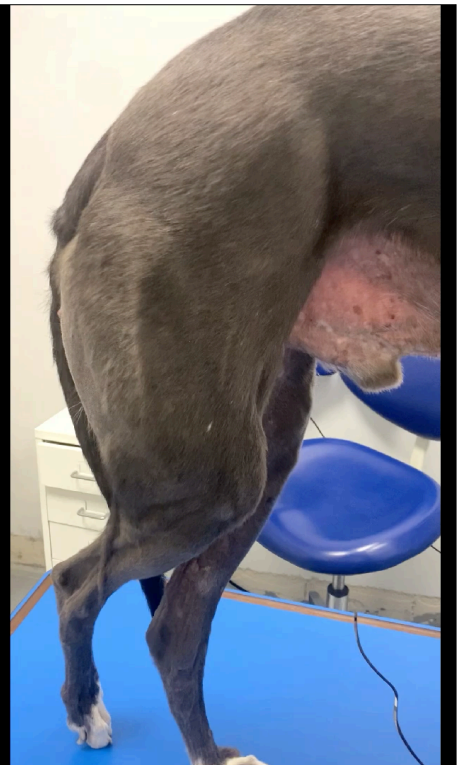

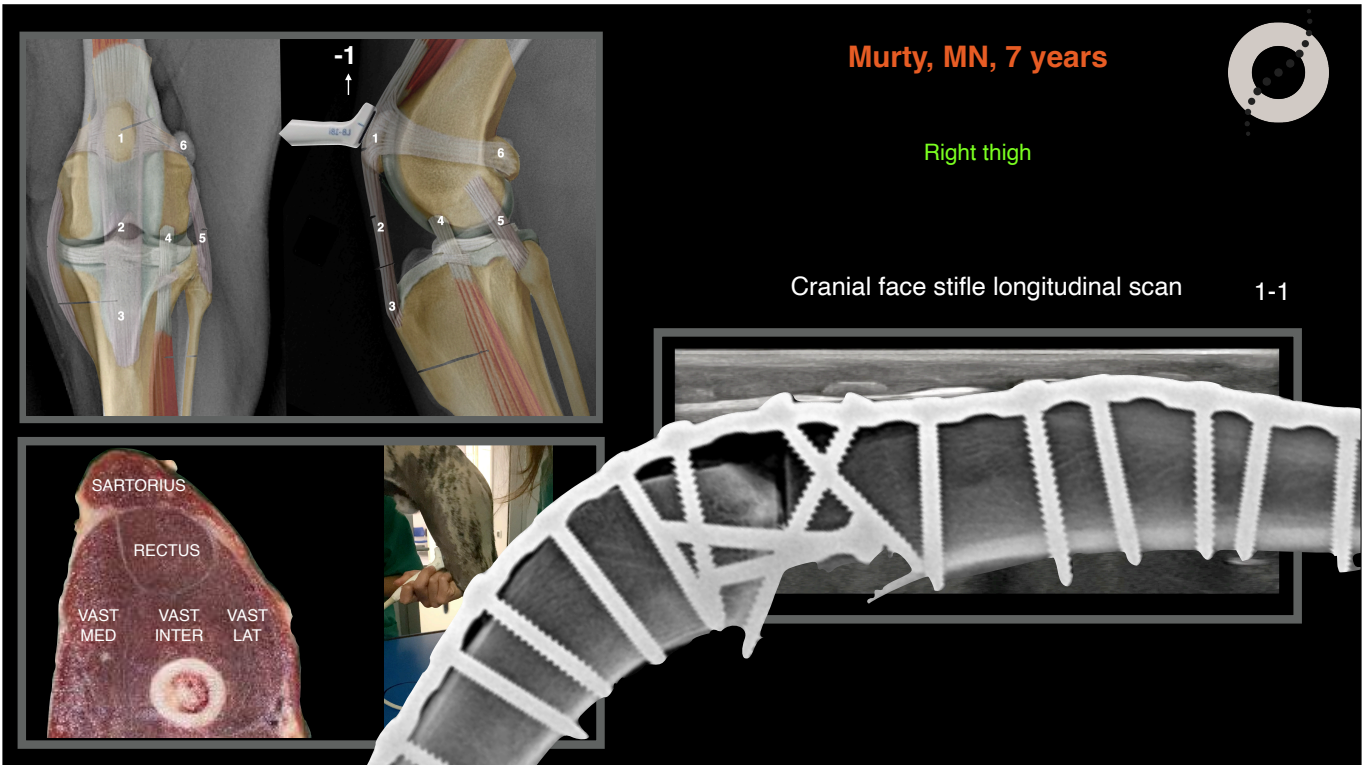
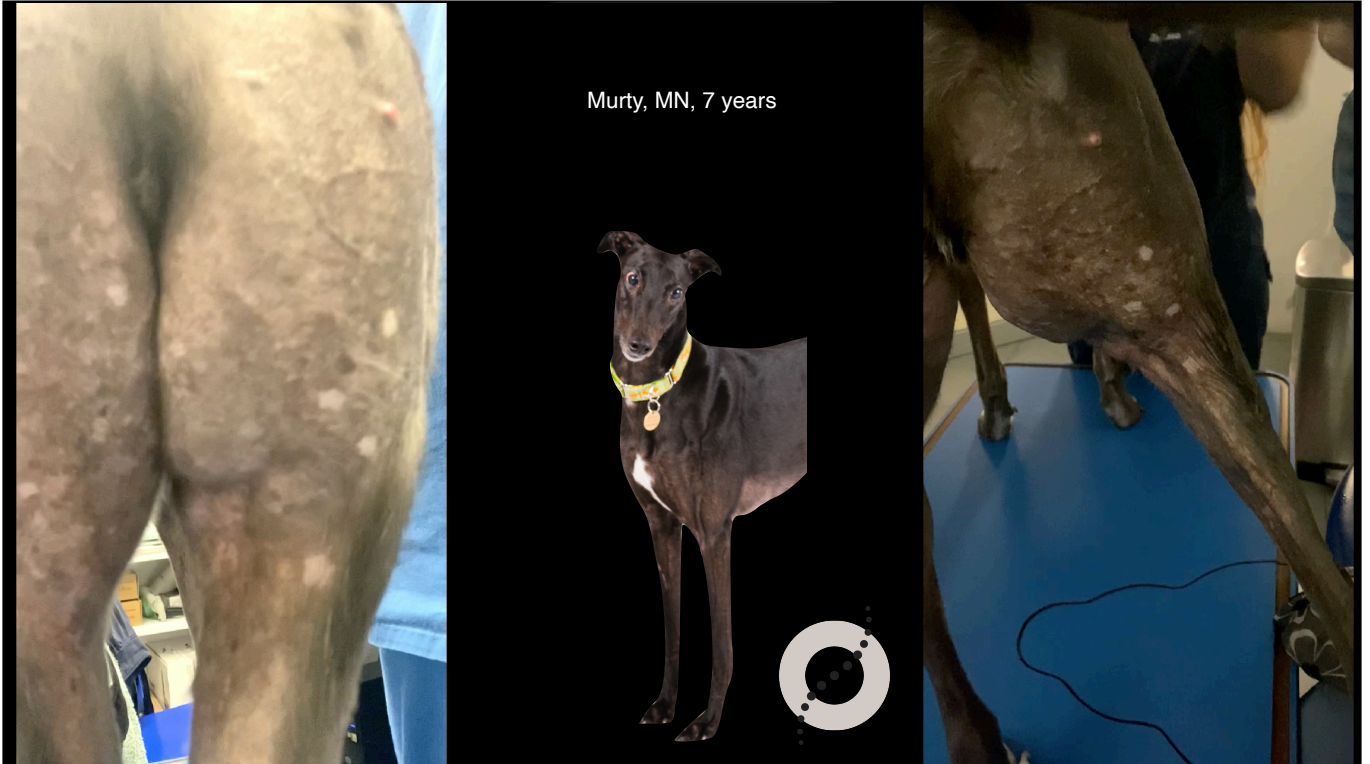Murty, Greyhound, MN, 7 years

- Now, 8 months later, He cries if accidentally touched
- The orthopaedic surgeon suggests amputation



Murty, MN, 7 years





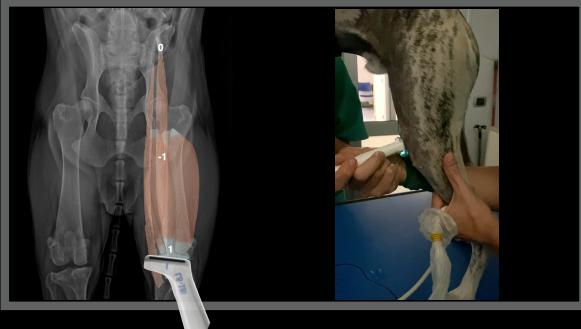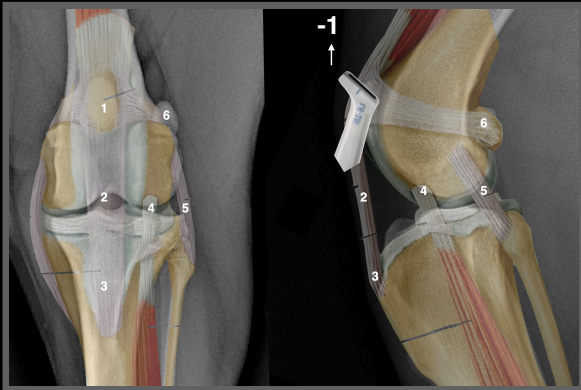
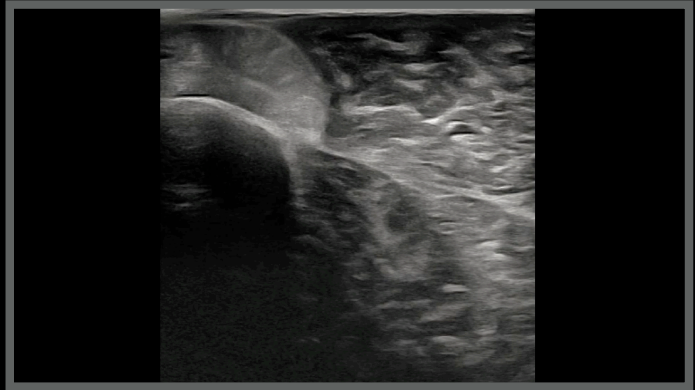
Murty, MN, 7 years



Right thigh

1-1

Cranio-lateral face thigh transverse scan

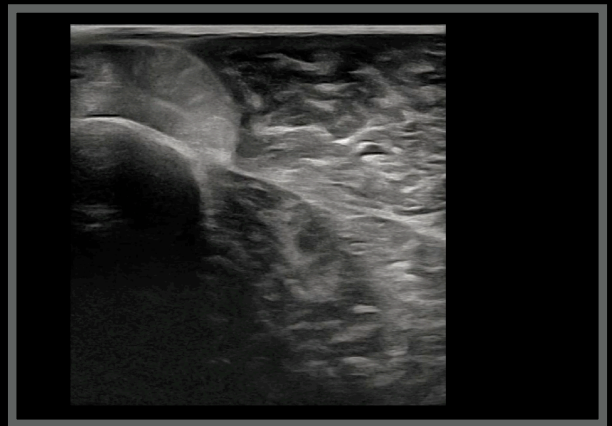
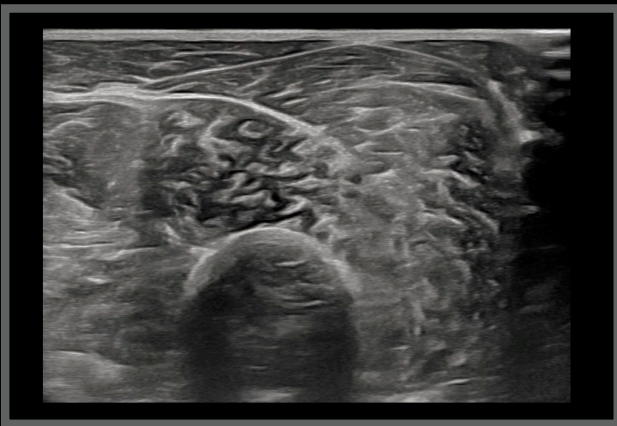


Murty, Greyhound, MN, 7 years

Cranio-lateral face thigh transverse scan

Left thigh

Right thigh



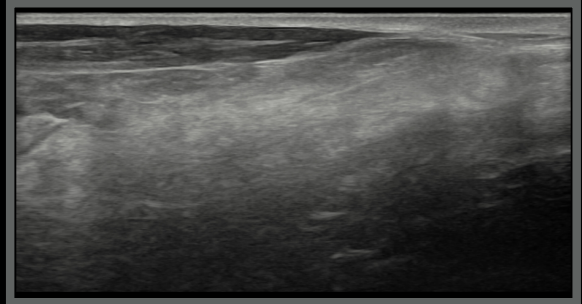
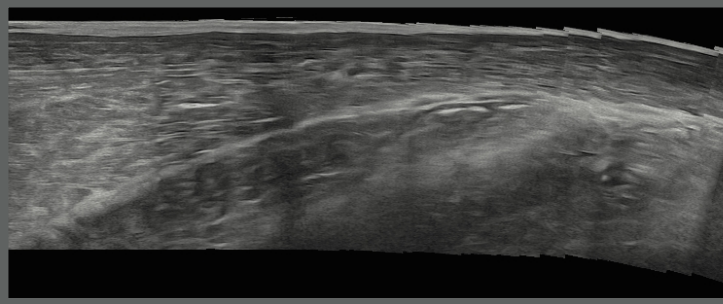
Murty, Greyhound, MN, 7 years



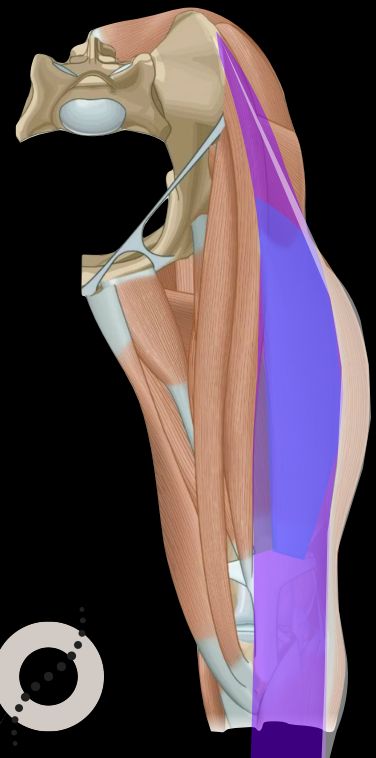
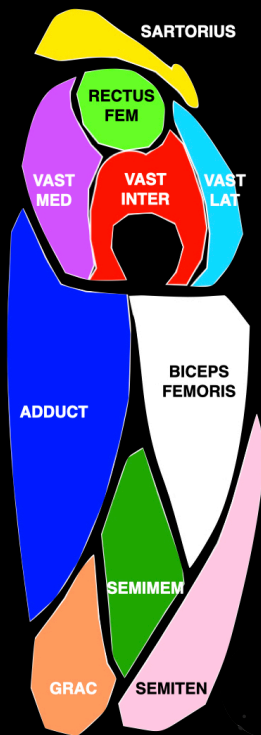
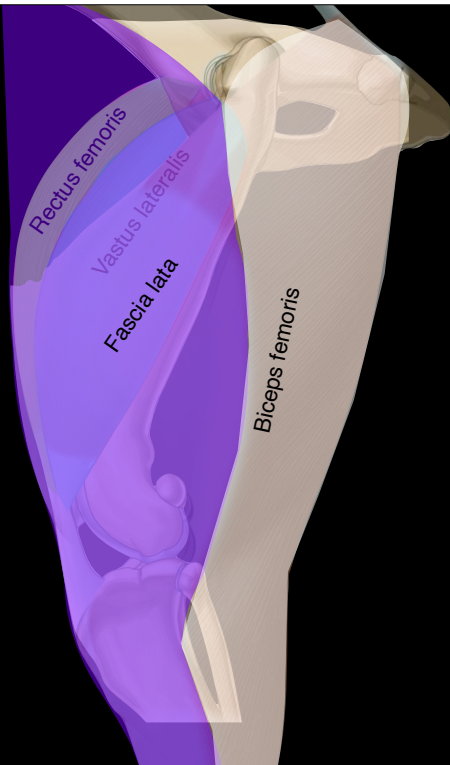
Craniomedial face thigh longitudinal scan

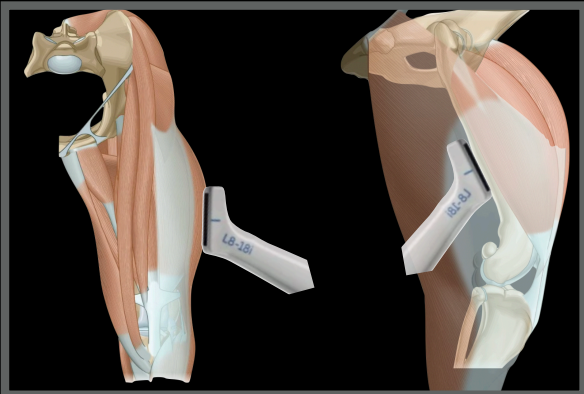
Vastus medialis

Vastus medialis



Lateral face of the thigh

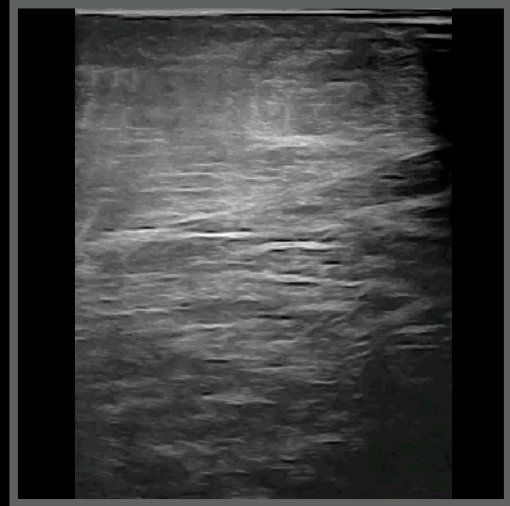
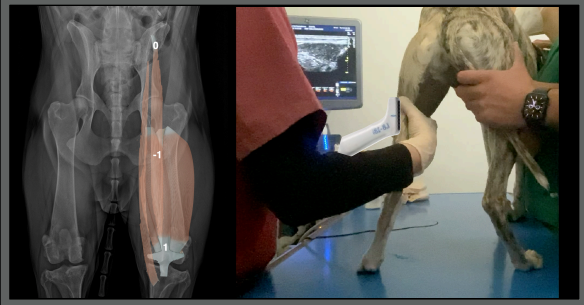




Murty, MN, 7 years



Right thigh



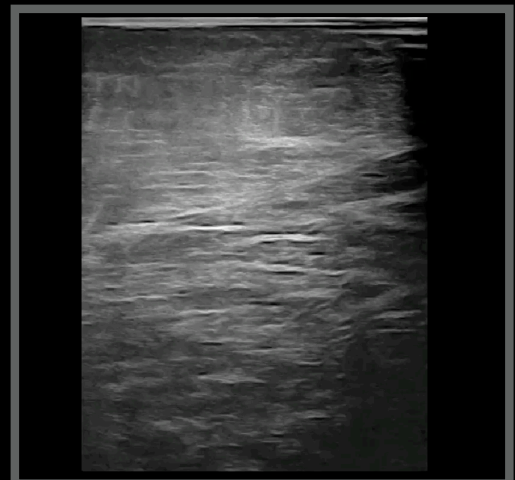
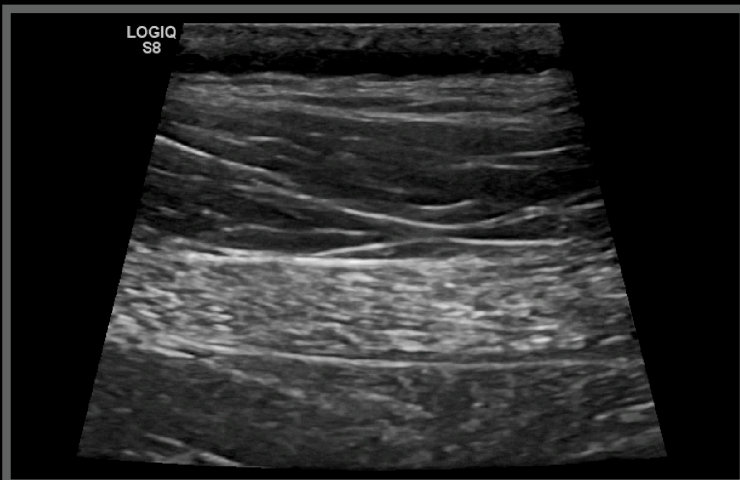
Murty, Greyhound, MN, 7 years



Lateral face thigh longitudinal scan

Normal anatomy

sciatic nerve

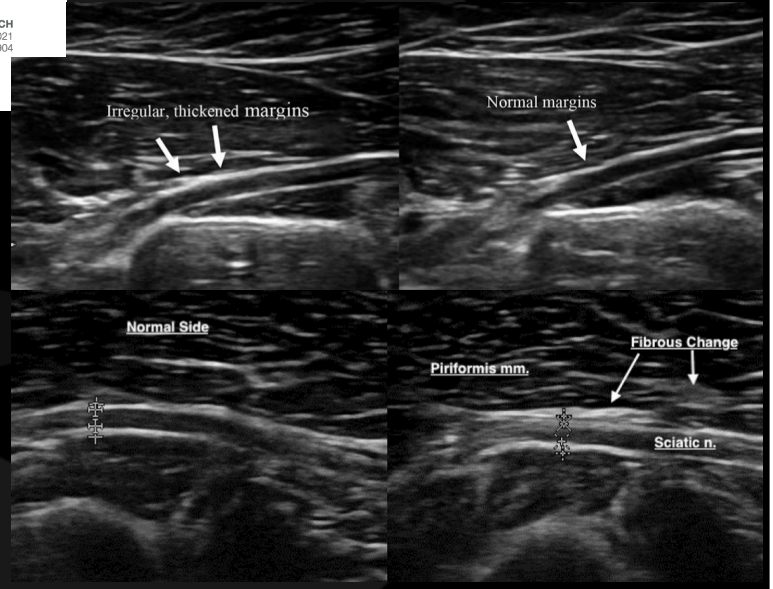


Ultrasonography Findings in the Proximal Sciatic Nerve and Deep Gluteal Muscles in 29 Dogs With Suspected Sciatic Neuritis

Tiiu M. Toijala^{1*}, Debra A. Canapp² and Sherman O. Canapp²

ORIGINAL RESEARCH
published: 27 August 2021
doi: 10.3389/fvets.2021.704904

¹ Sporting Dogs Clinic Evidensia, Espoo, Finland, ² Veterinary Orthopedic and Sports Medicine Group, Annapolis Junction, MD, United States



Murty, Greyhound, MN, 7 years

Ultrasonographic diagnoses

- Fibrosis of the vastus lateralis and vastus medialis
- Severely thickened fascias
- Suspected sciatic nerve neuritis



Thank you



Diagnostic Mindset

www.diagnosticmindset.com