

Partial rupture of the Achille's tendon in a Galgo

Can ultrasound help to decide the
best treatment for this patient?



Diagnostic Mindset



Giliola Spattini
DVM, PhD, DECVI

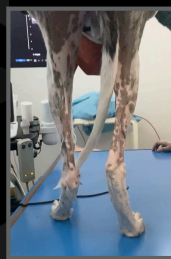Jamaal, Galgo, MN, 5 years

- Partial resection by a glass of the left
Achille's tendon
- Immediately repaired by the vet
- Two weeks later, at the first run, the dog
became acutely 4th-degree lame



Jamaal, Galgo, MN, 5 years

- Still second degree lame three weeks
later
- Check to decide on conservative or
surgical repair
- Thickened left Achille's tendon at the
calcaneal insertion



Jamaal, MN, 5 years
 Left thigh

Caudal face transverse scan 9

www.maiiaa.com

Jamaal, MN, 5 years
 Left thigh

Caudal face longitudinal scan 9

www.maiiaa.com

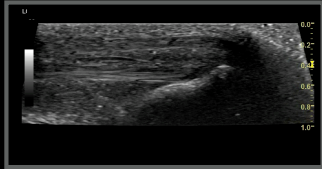
Jamaal, MN, 5 years
 Left thigh

Caudal face longitudinal scan 9

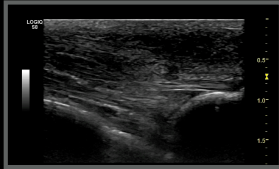
www.maiiaa.com

Jamaal, Galgo, MN, 5 years

Right Achille's tendon



Left Achille's tendon



Jamaal, Galgo, MN, 5 years

Ultrasonographic diagnoses

- Ruptured flexor superficialis tendon
- Partially affected gastrocnemius tendon
- Unremarkable communis tendon



Next steps?

Jamaal, Galgo, MN, 5 years

Three months later

- Started physiotherapy
- Initially soft brace and leash
- Then treadmill and home exercise



Jamaal, MN, 5 years

Three months later

Right limb

Caudal face longitudinal scan

Jamaal, MN, 5 years

Three months later

Left limb

Caudal face longitudinal scan

Jamaal, Galgo, MN, 5 years

Right Achille's tendon

Left Achille's tendon

Jamaal, MN, 5 years

Right limb

Caudal face transverse scan

www.maiac.com

Jamaal, MN, 5 years

Left limb

Caudal face transverse scan

www.maiac.com

Jamaal, Galgo, MN, 5 years

Right Achille's tendon

Left Achille's tendon

www.maiac.com

Jamaal, Galgo, MN, 5 years

Three months later

Ultrasonographic diagnoses

- More uniformly echogenic left superficial tendon
- Morphologic healing
- Functional healing???

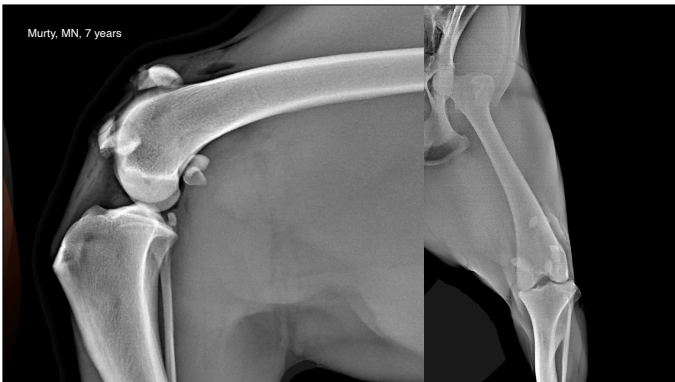

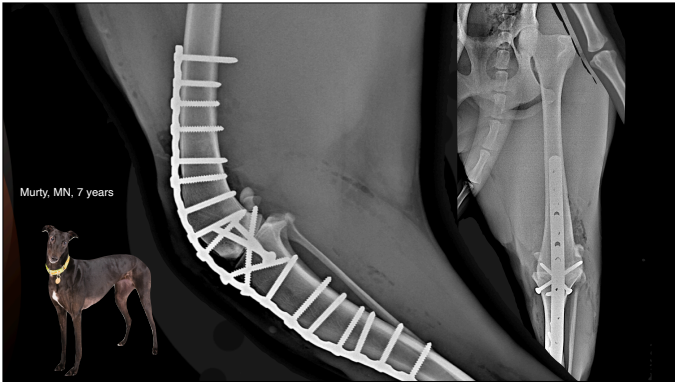
Murty, Greyhound, MN, 7 years

- After running acutely lame
- A trauma was considered likely



Murty, MN, 7 years





Murty, Greyhound, MN, 7 years

- Immediately after surgery, mild improvement
- After two months progressively worsening lameness



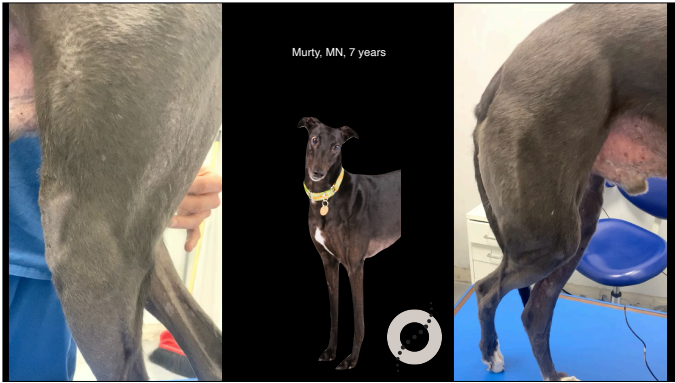
A photograph showing a greyhound dog standing in a hallway. A person in blue scrubs is partially visible in the background. The floor is tiled.

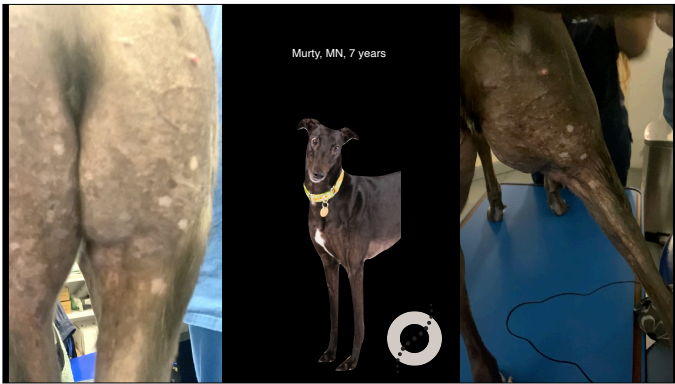
Murty, Greyhound, MN, 7 years

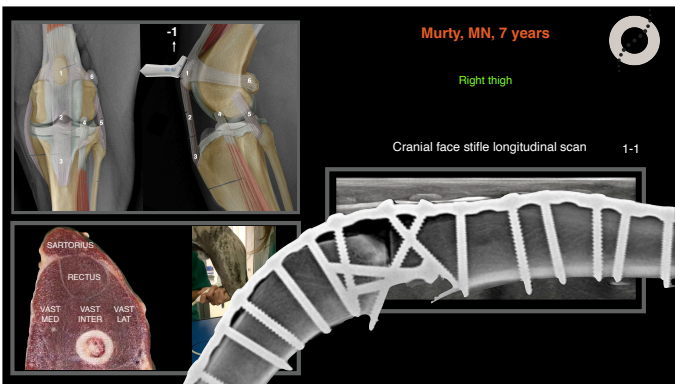
- Now, 8 months later, He cries if accidentally touched
- The orthopaedic surgeon suggests amputation

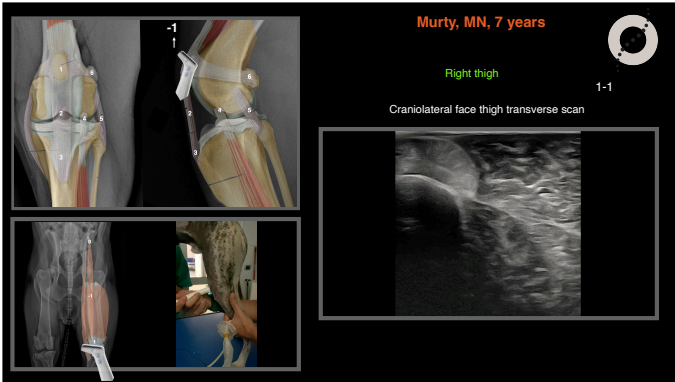

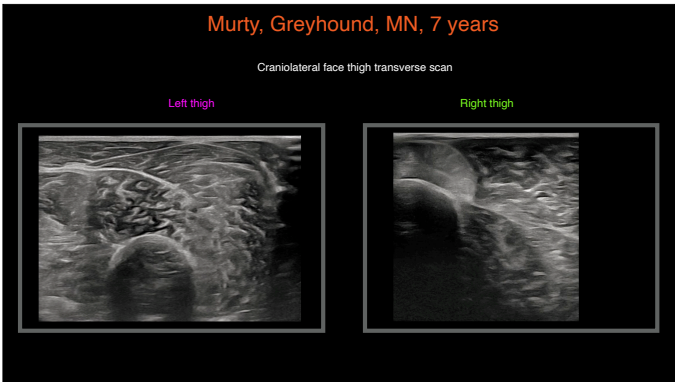
A close-up photograph of a dog's lower leg and paw. The leg appears to be in a cast or brace, and the dog is standing on a blue surface.

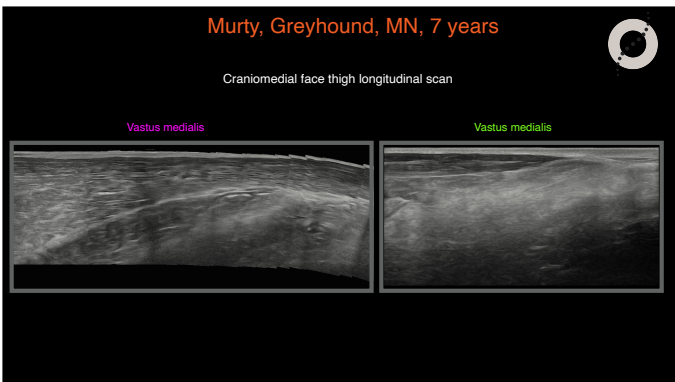


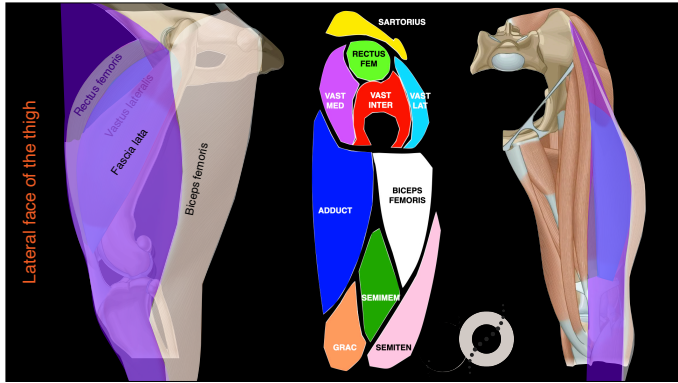


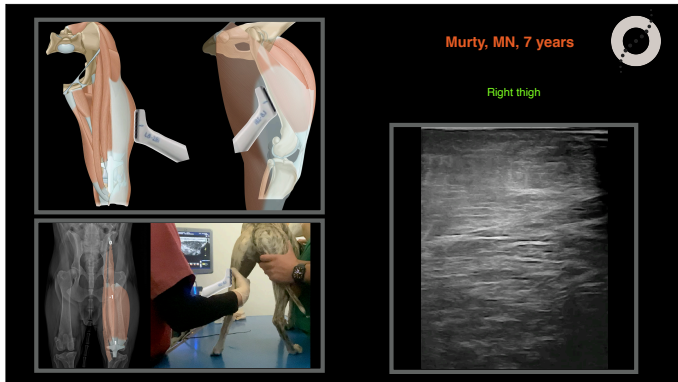


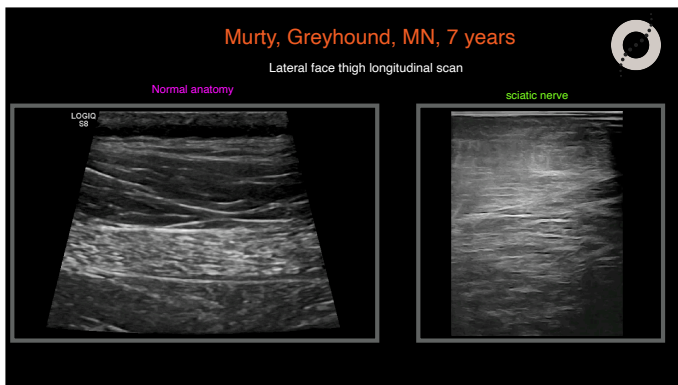












frontiers
in Veterinary Science

Ultrasonography Findings in the Proximal Sciatic Nerve and Deep Gluteal Muscles in 29 Dogs With Suspected Sciatic Neuritis

Thibault M. Tojales^{1*}, Debra A. Canapp² and Sherman D. Canapp¹

ORIGINAL RESEARCH
published: 02 July 2021
doi: 10.3389/fvets.2021.671021

¹Spangley Dog Clinic-Following, Evans, France; ²Hennepin Orthopaedic and Sports Medicine Group, Annapolis, London, MD, United States

Murty, Greyhound, MN, 7 years

Ultrasonographic diagnoses

- Fibrosis of the vastus lateralis and vastus medialis
- Severely thickened fascias
- Suspected sciatic nerve neuritis

Thank you

Diagnostic Mindset
www.diagnosticmindset.com
