

# CASES DISCUSSION

Giliola Spattini  
DVM, GP Cardio, CCRT, PhD, DECVDI



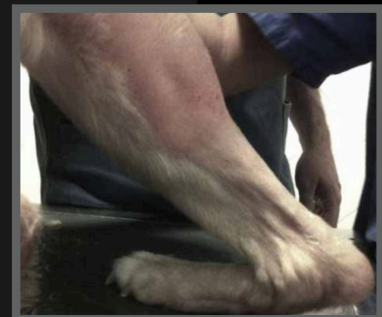Diagnostic Mindset



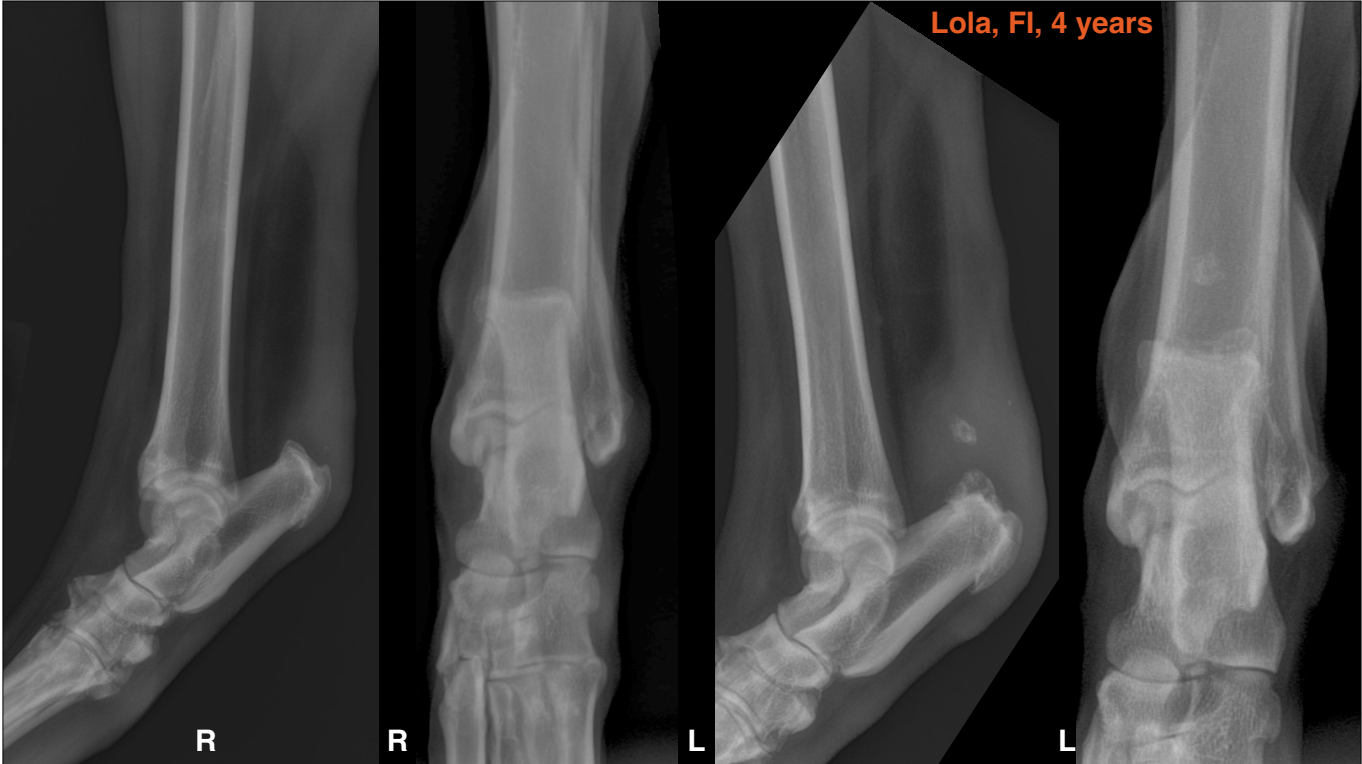
Thank to [www.imaios.com](http://www.imaios.com)

## Lola, English Setter, FI, 4 years

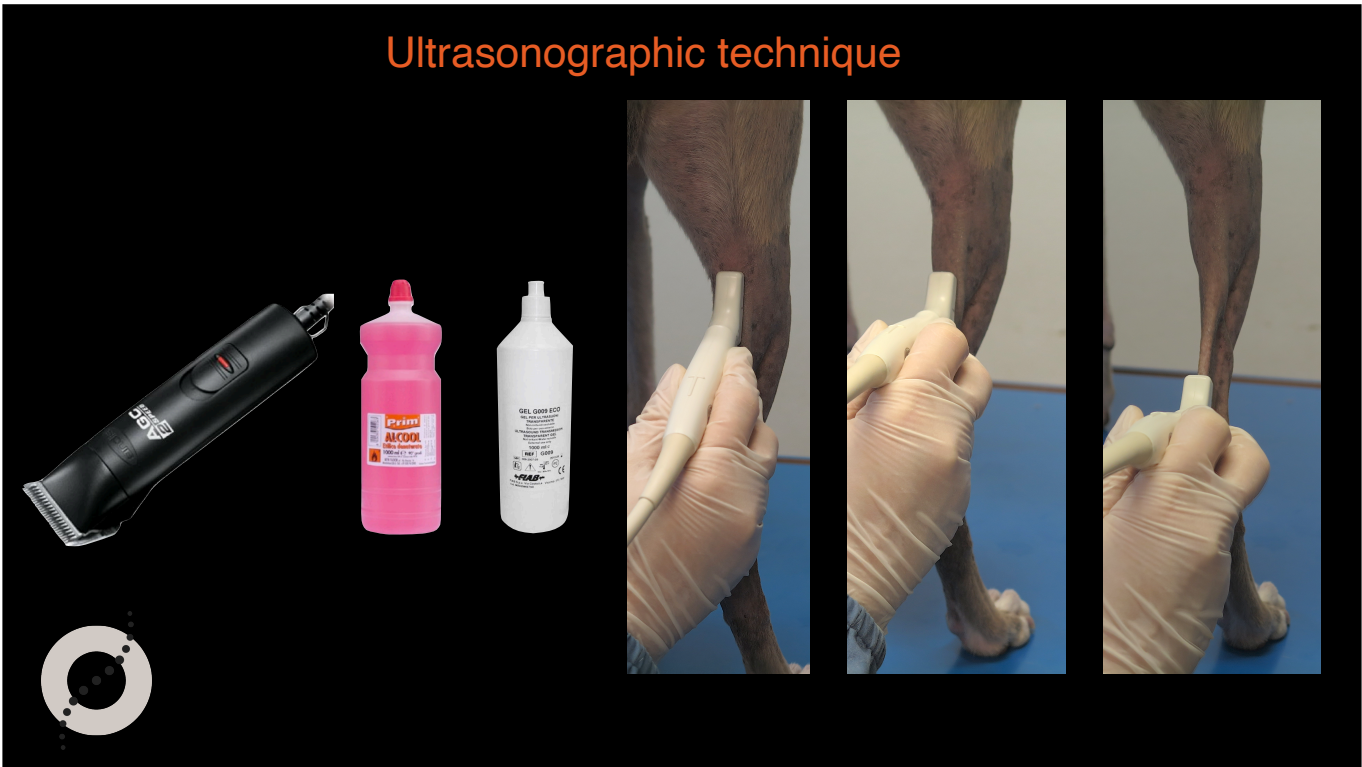- After hunting, She came back left hindlimb lame
- Plantigrade
- Planning surgical repair of Achille's tendon

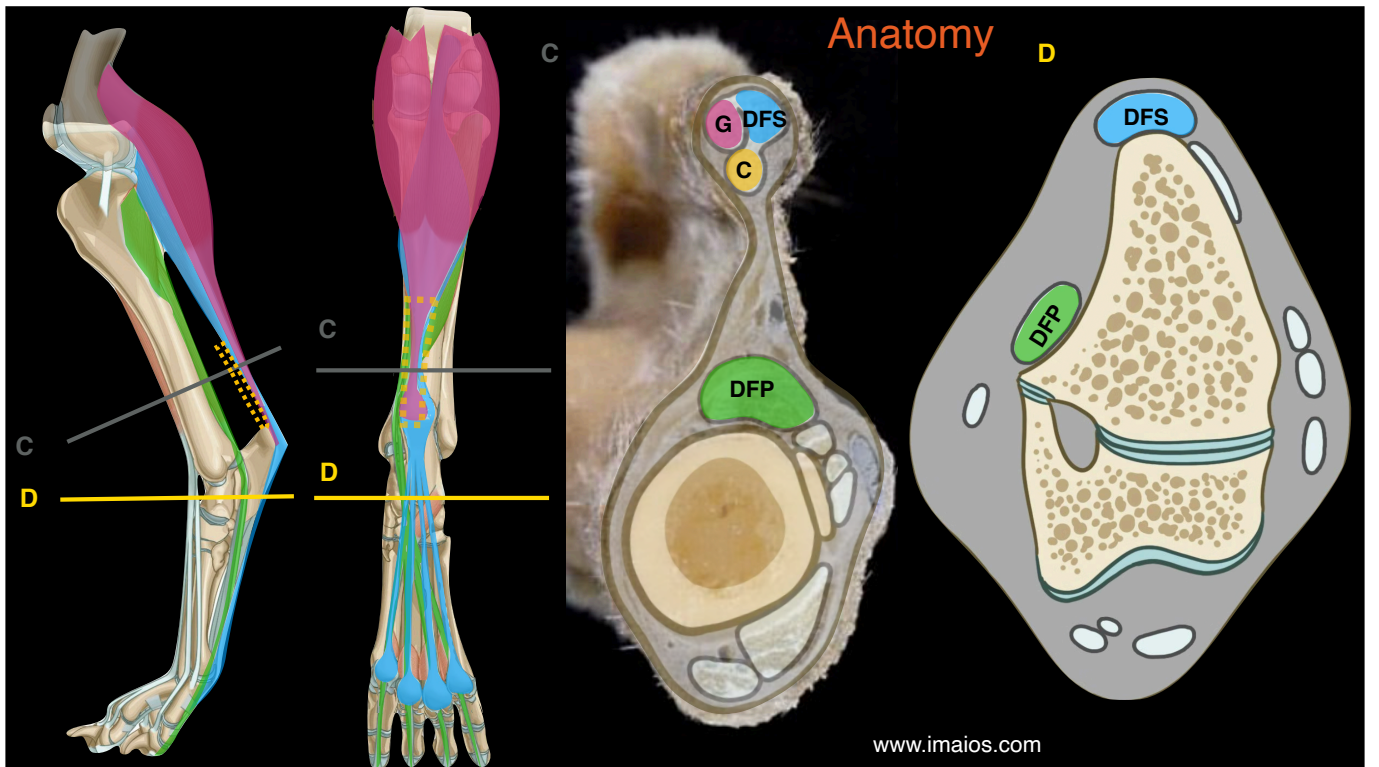
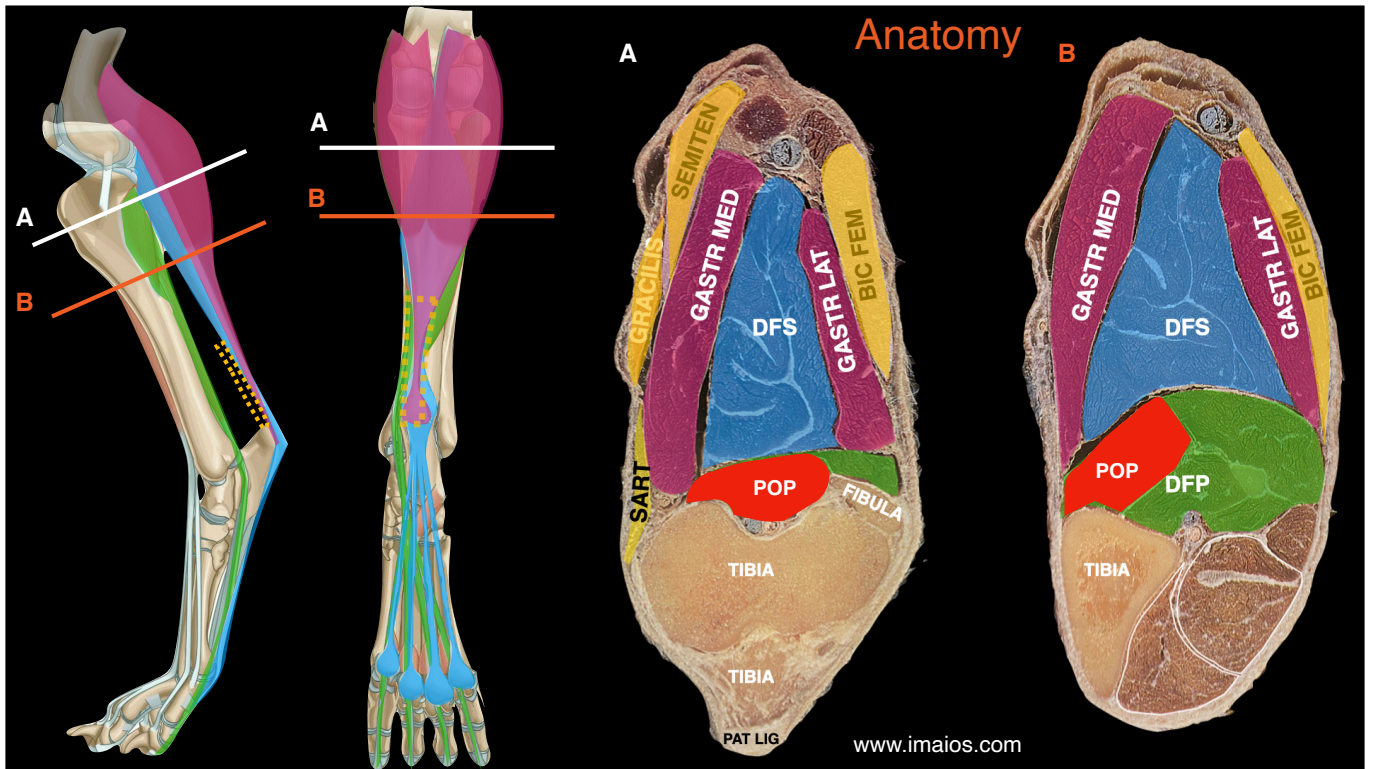


Lola, FI, 4 years



### Ultrasonographic technique





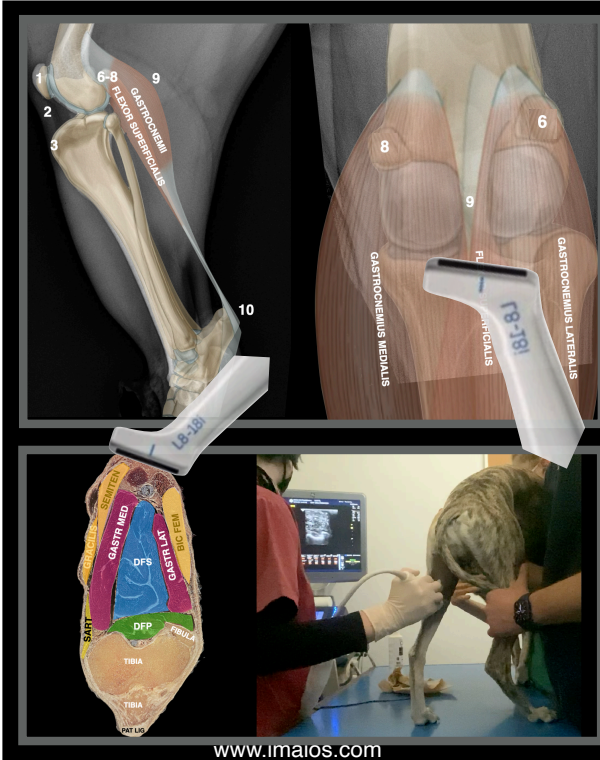
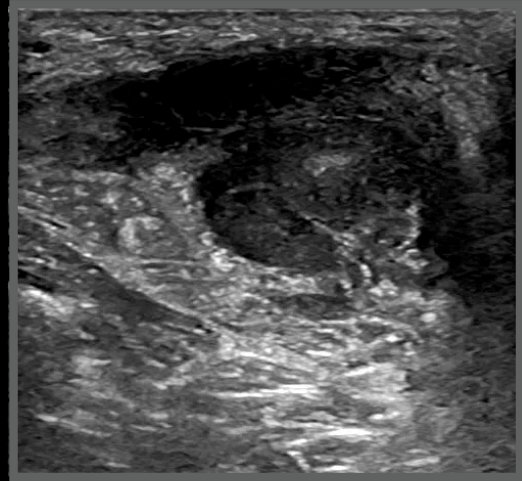


Lola, FI, 4 years

Left stifle

Caudal face transverse scan

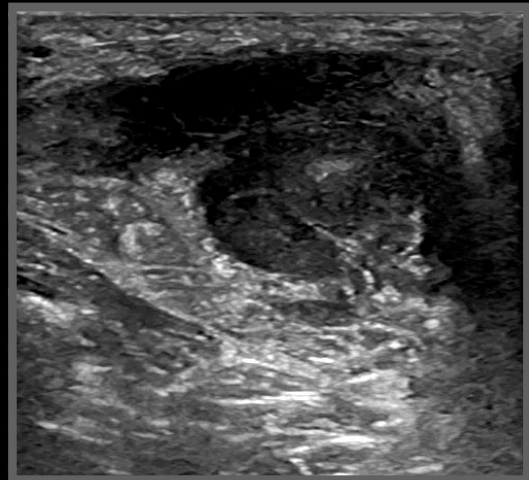
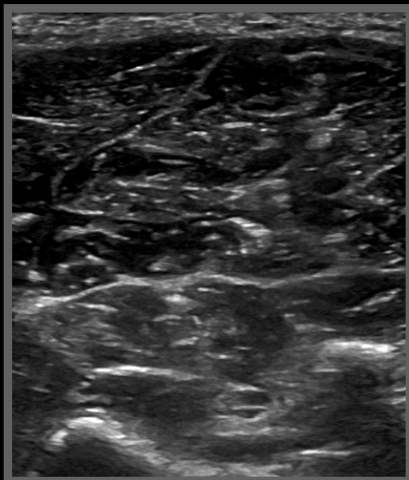
9

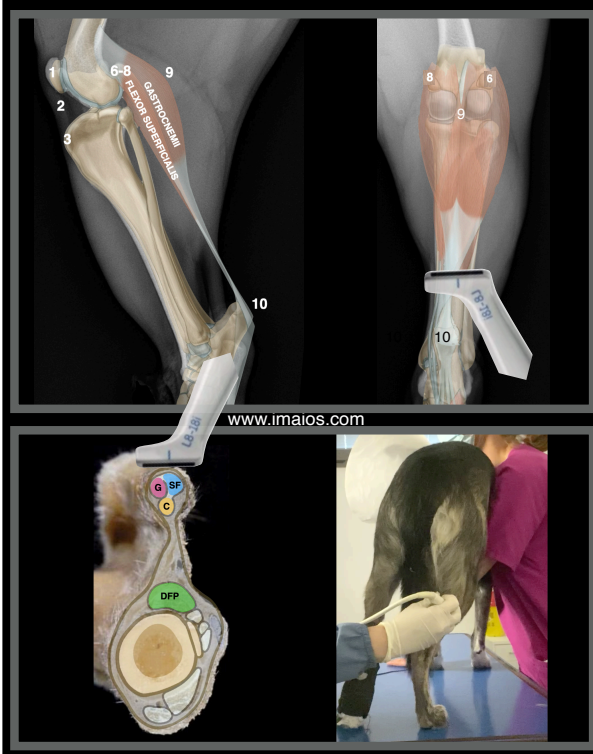


Lola, FI, 4 years

Right stifle

Left stifle

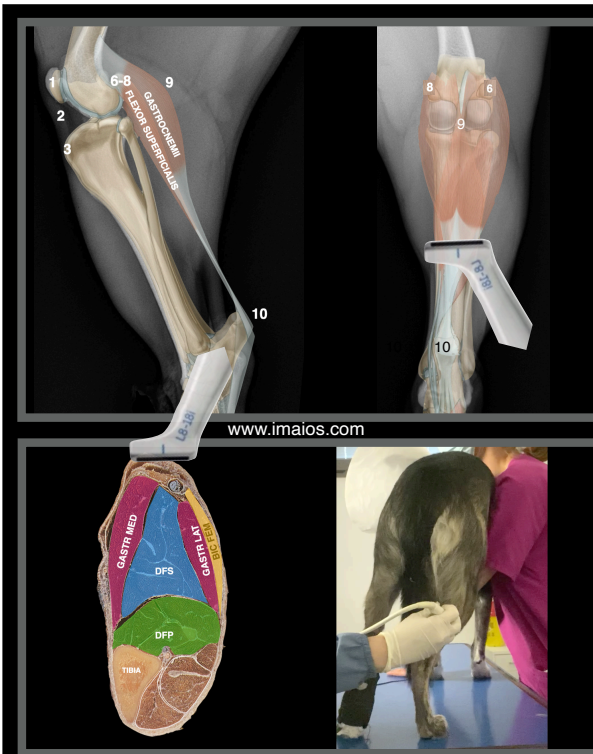
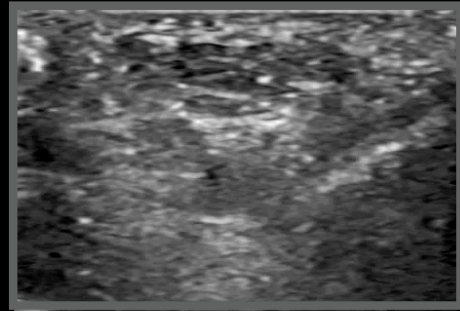




Lola, FI, 4 years

Right leg

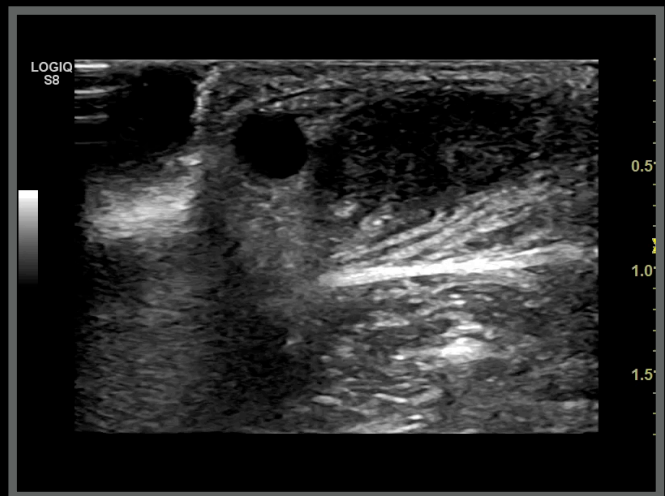
Caudal face transverse scan 9

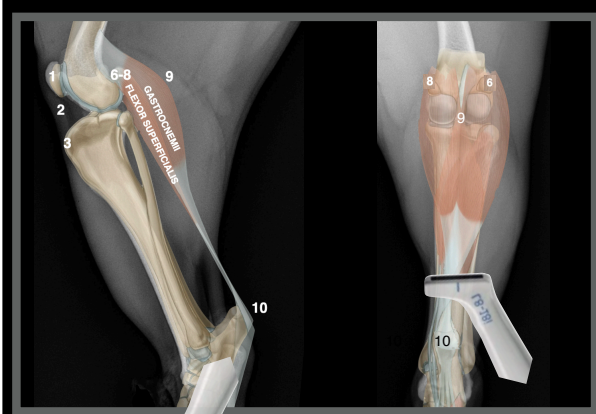


Lola, FI, 4 years

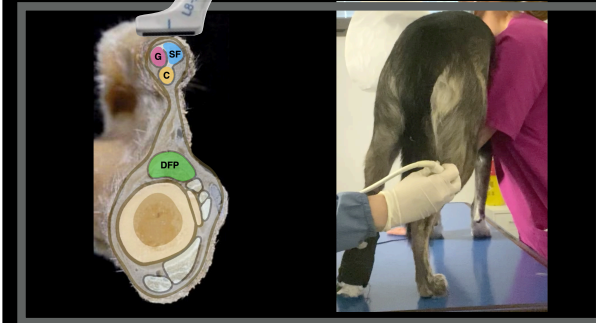
Left leg

Caudal face transverse scan 9





www.imaios.com

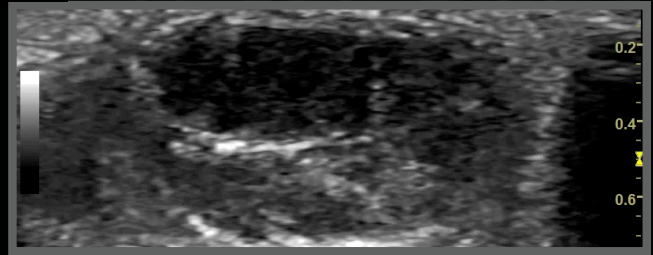


Lola, FI, 4 years

Left leg

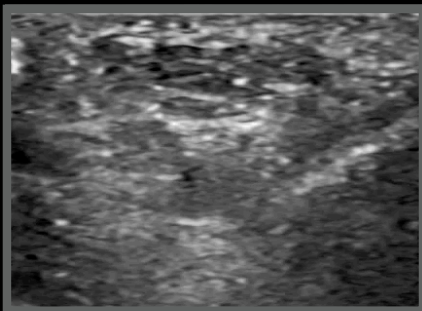
Caudal face transverse scan

9

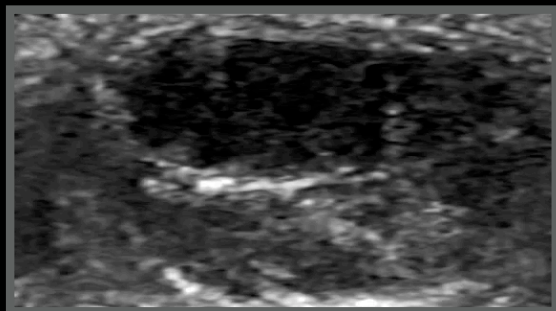


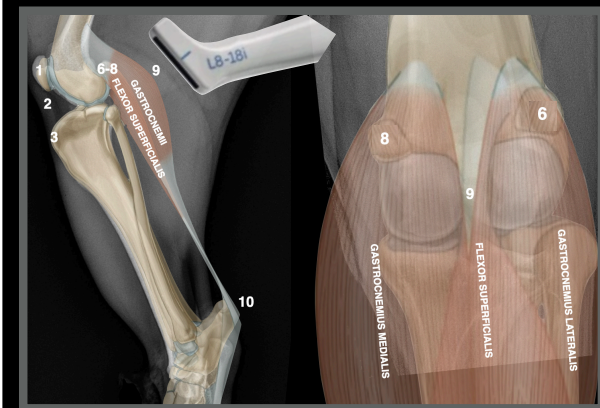
Lola, FI, 4 years

Right leg

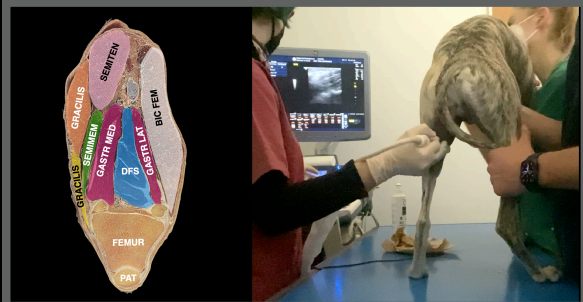

Left leg





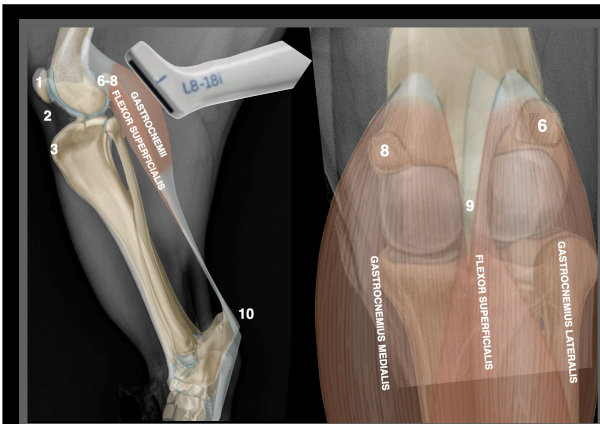
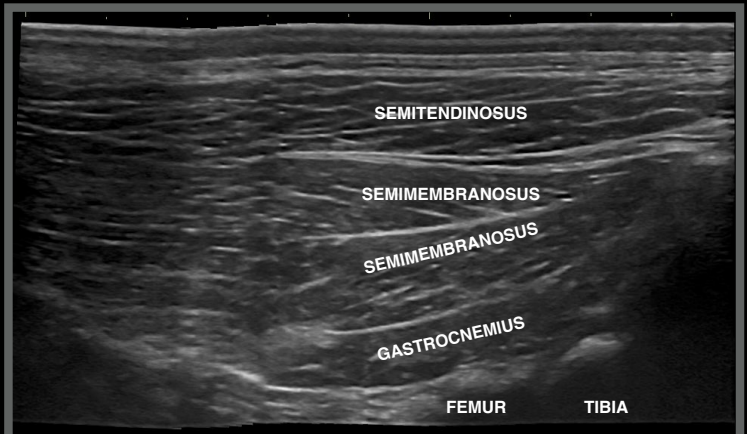
www.imaaios.com



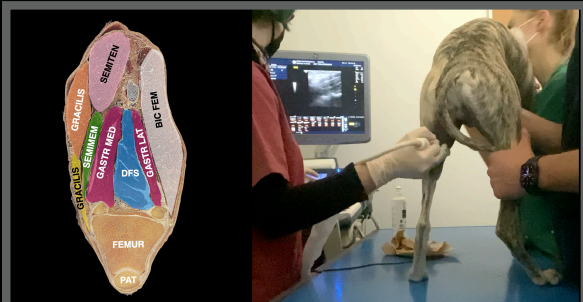Lola, FI, 4 years  
Right stifle

Caudal face longitudinal scan

9



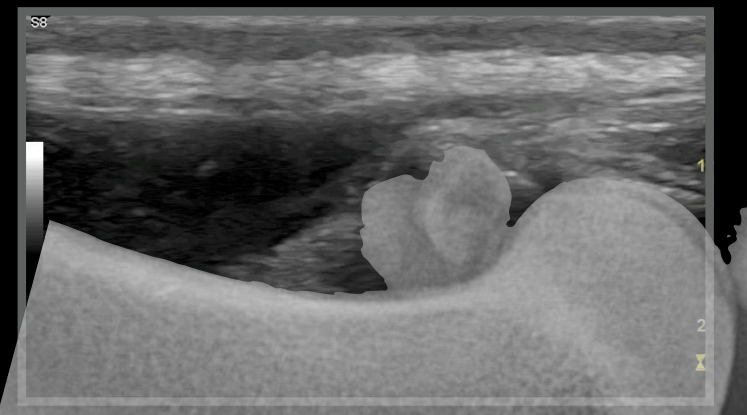
www.imaaios.com

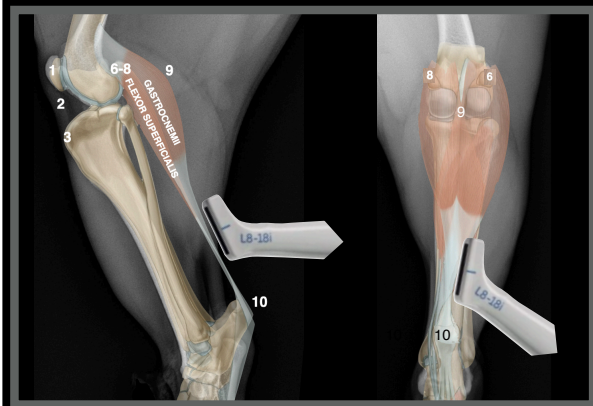


Lola, FI, 4 years  
Right stifle

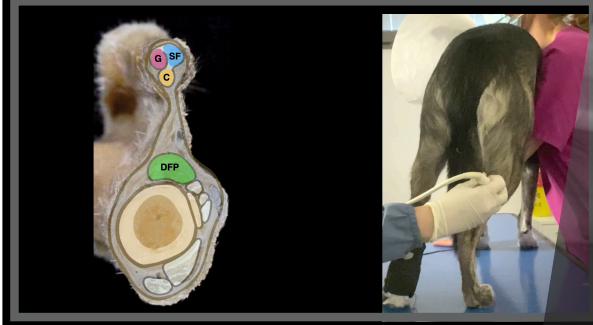
Caudal face longitudinal scan

9





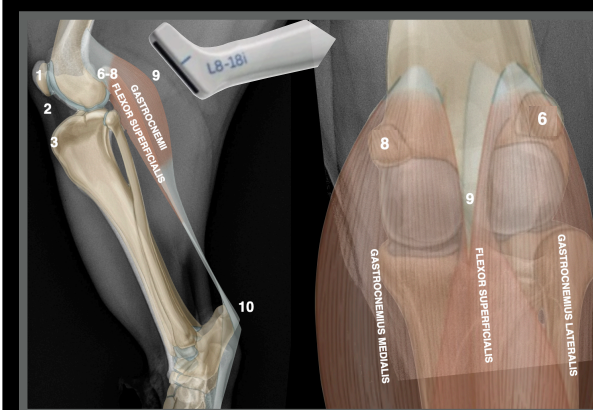

www.imaio.com



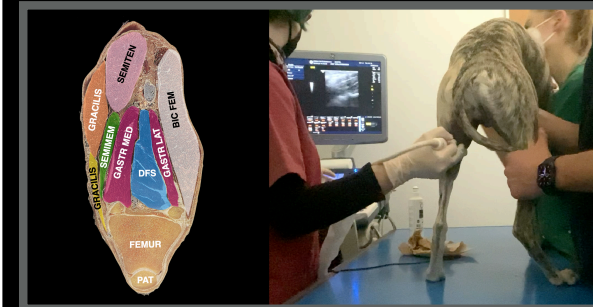
Lola, FI, 4 years

Right hock

Caudal face longitudinal scan 9-10



www.imaio.com

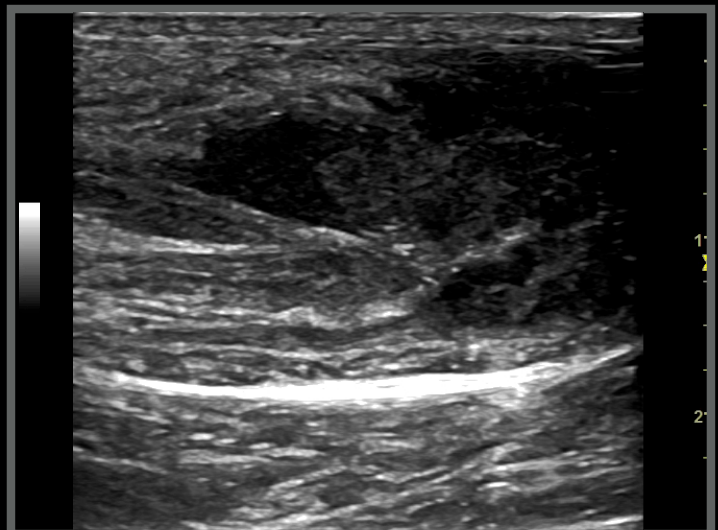


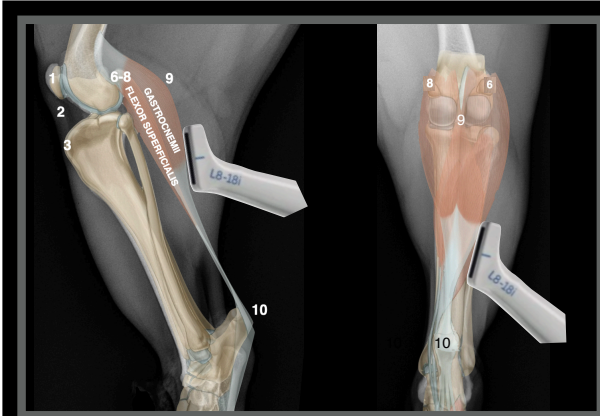
Lola, FI, 4 years

Left leg

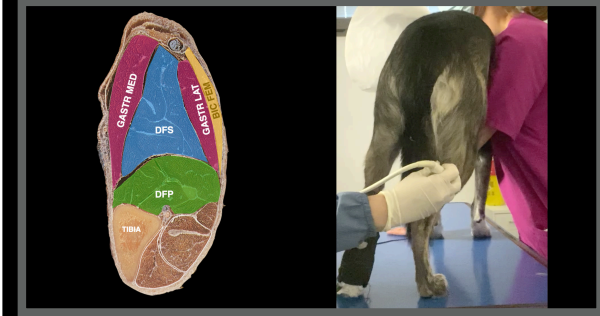
Caudal face longitudinal scan

9





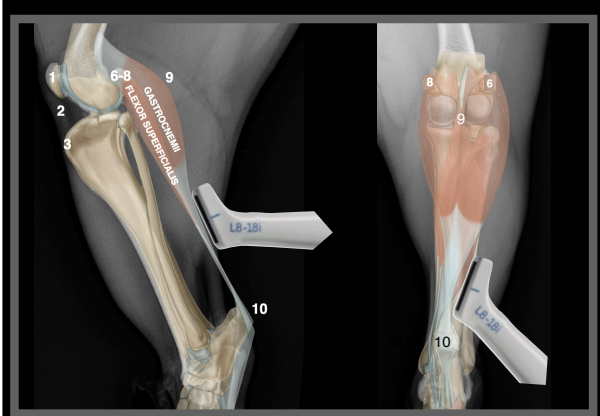
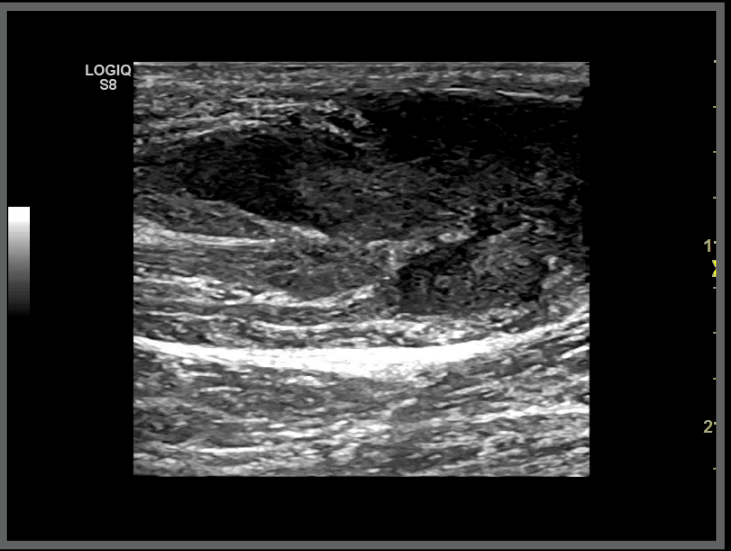
www.imaio.com



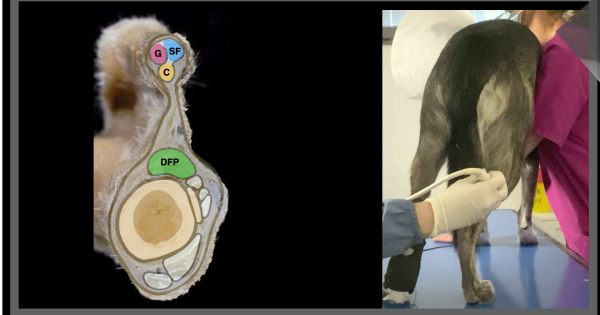
**Lola, FI, 4 years**

Left leg

Caudal face longitudinal scan 9



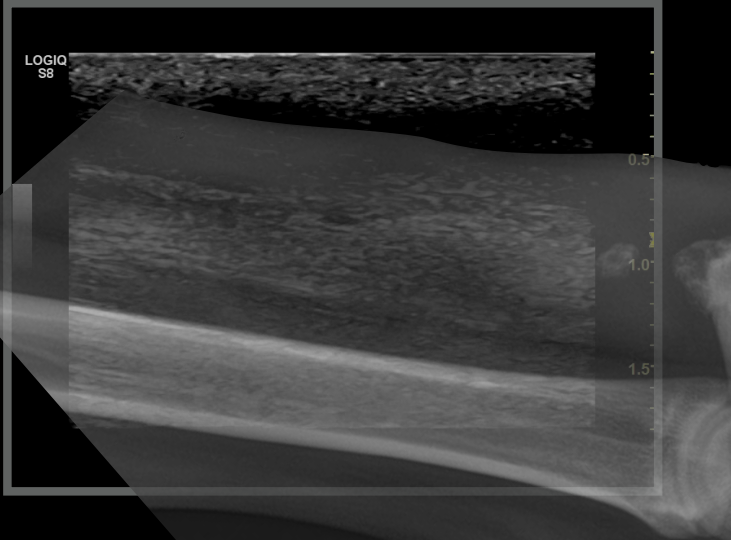
www.imaio.com

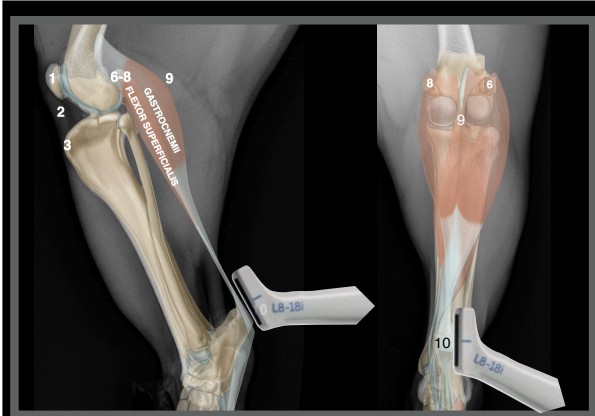


**Lola, FI, 4 years**

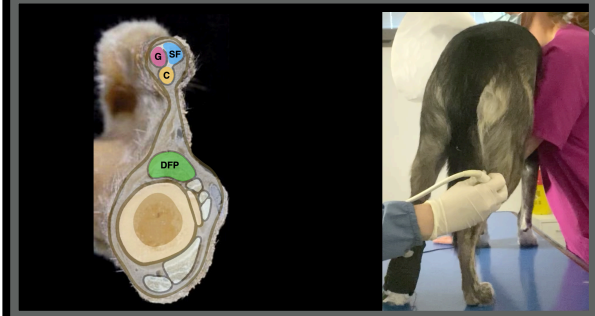
Left hock

Caudal face longitudinal scan 9-10





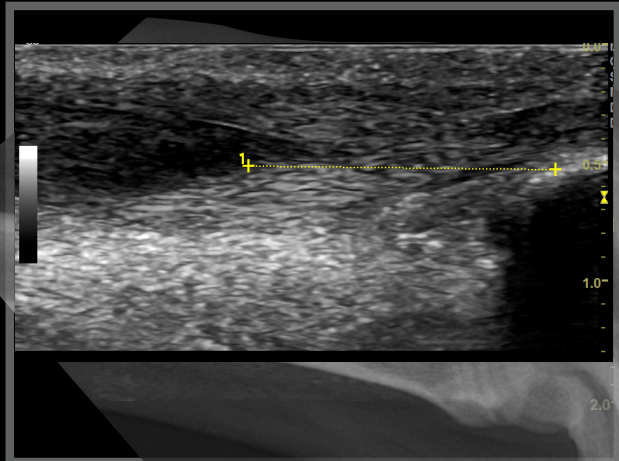
www.imaios.com



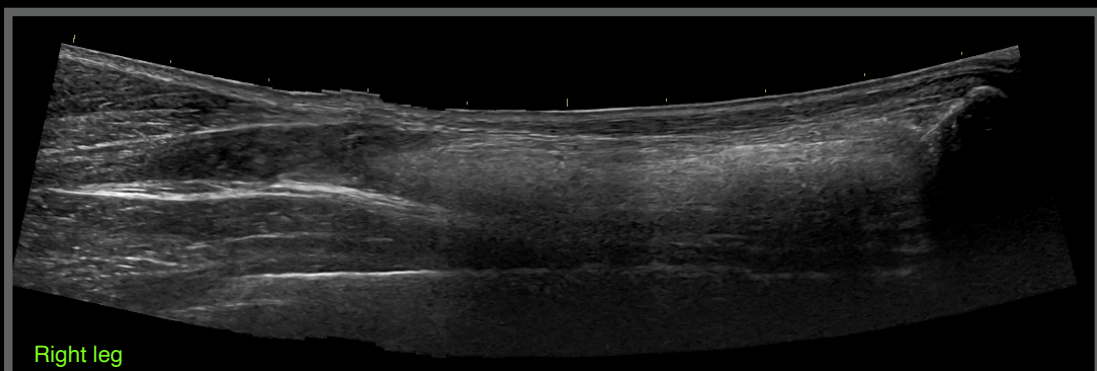
### Lola, Fi, 4 years

Left hock

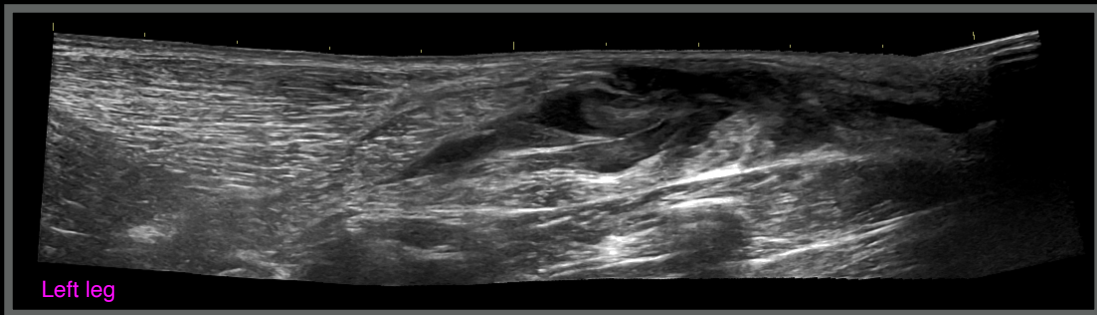
Caudal face longitudinal scan 9-10



### Lola, Fi, 4 years



Right leg



Left leg

## Lola, English Setter, FI, 4 years

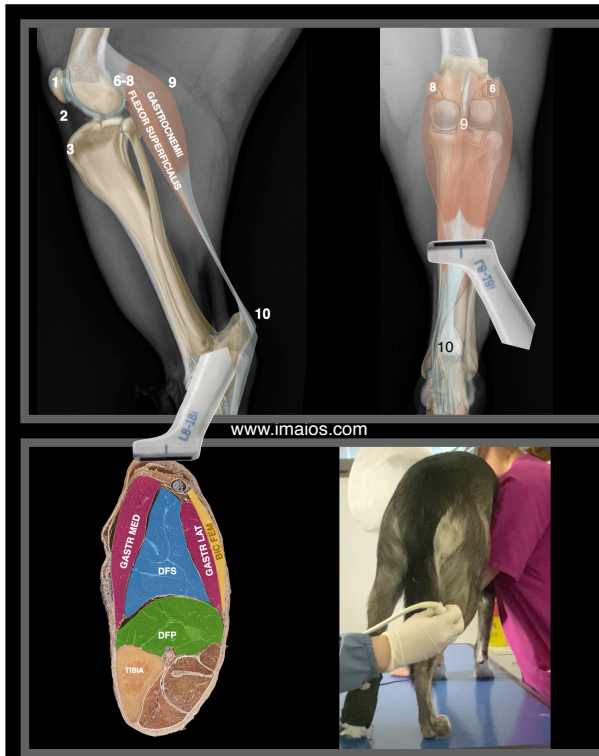
### Ultrasonographic diagnoses

- Left-sided rupture of the DFS muscle
- Focal rupture of the left Gastrocnemius muscle
- Extensive rupture of the left Gastrocnemius and Communis tendon
- Chronic left-sided Achille's tendonitis



### Next steps:

- Removable cast and physiotherapy
- Surgery after three months
- Is back to hunting, light work

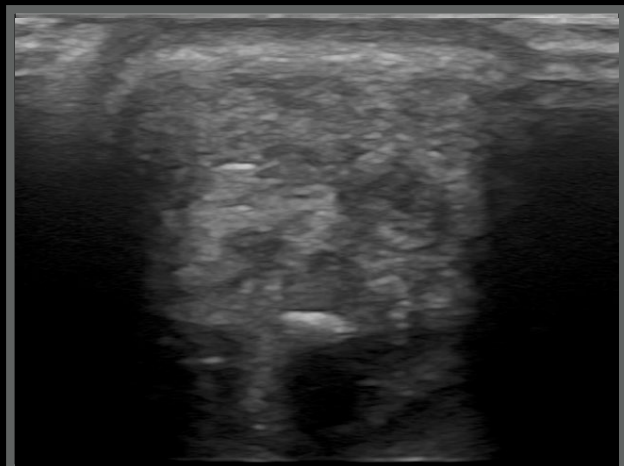


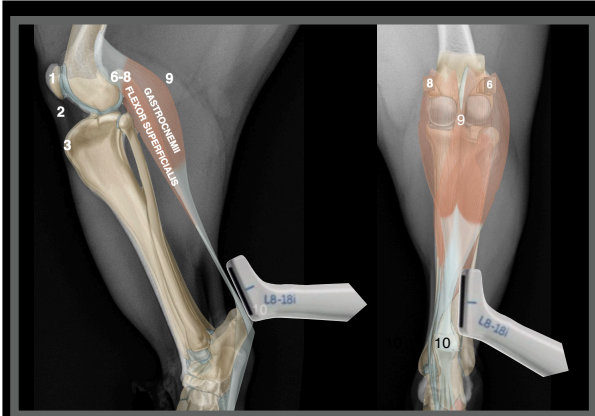
## Lola, FI, 4 years

Left leg

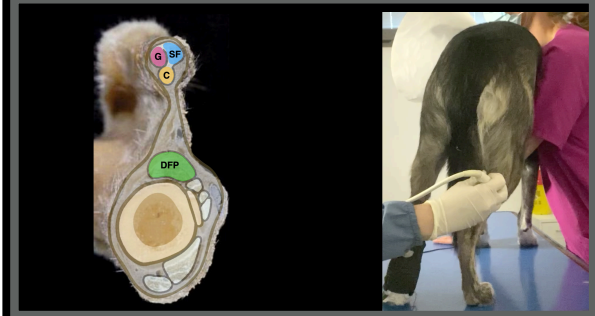
Six months later

Caudal face transverse scan 9





www.imaios.com

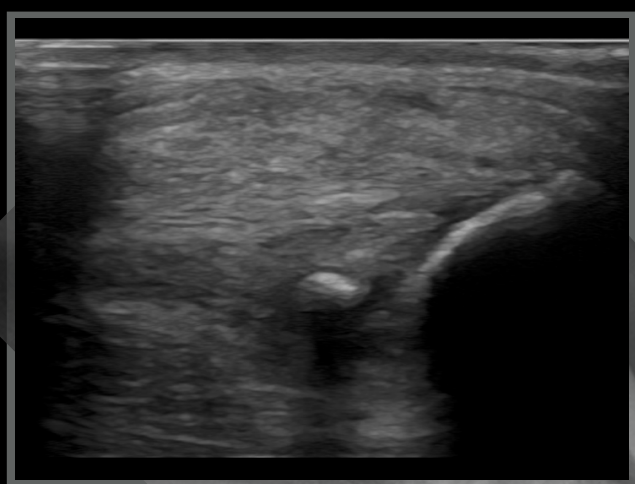


Lola, Fi, 4 years

Left hock

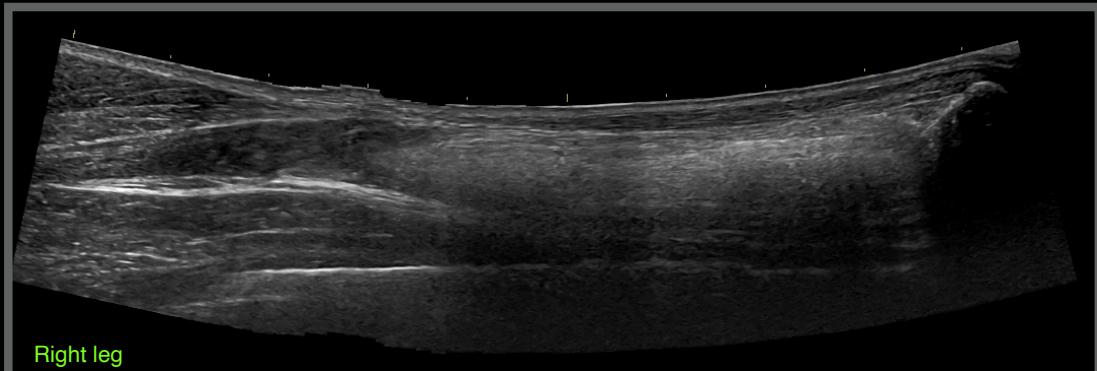
Six months later

Caudal face longitudinal scan 10

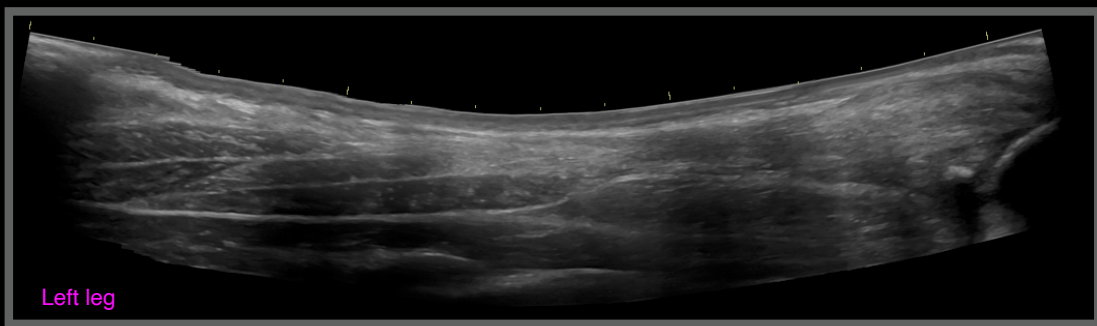


Lola, Fi, 4 years

Six months later



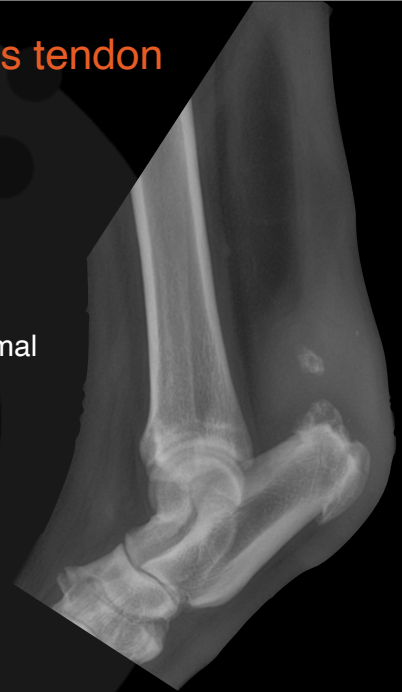Right leg



Left leg

## Key point ultrasound of the Achille's tendon

- Often chronic changes
- Healing usually doesn't involve going back to normal
- Underlying chronic predisposition
- Chronic management



Thank you



Diagnostic Mindset

[www.diagnosticmindset.com](http://www.diagnosticmindset.com)