


CASES DISCUSSION

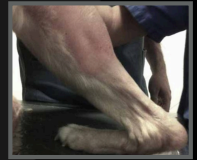Giliola Spattini
DVM, GP Cardio, CCRT, PhD, DECVI



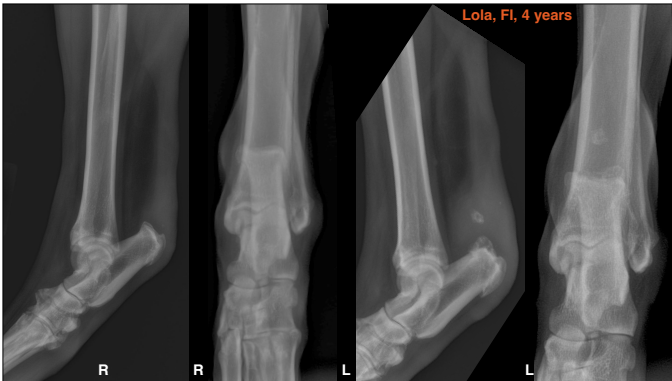
Thank to www.imagos.com

Lola, English Setter, FI, 4 years

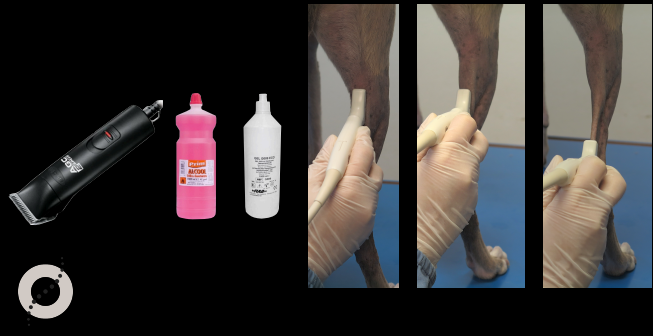- After hunting, She came back left hindlimb lame
- Plantigrade
- Planning surgical repair of Achille's tendon

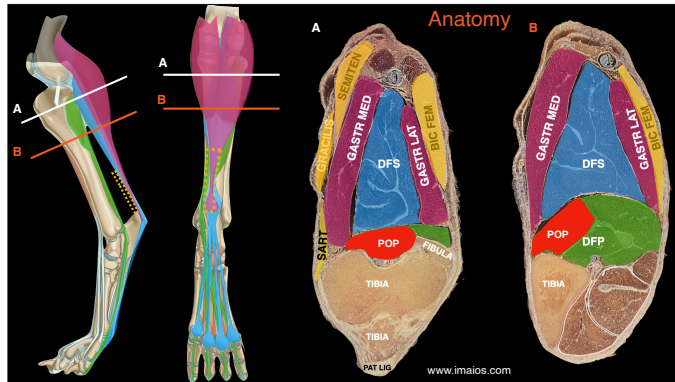


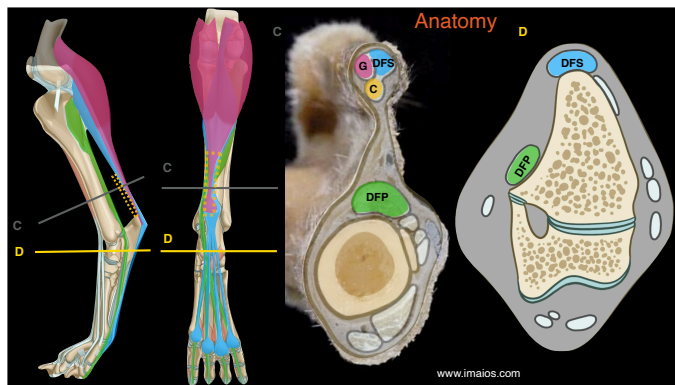
Lola, FI, 4 years



Ultrasonographic technique







Lola, FI, 4 years
Right stifle

Caudal face transverse scan 9

www.imaio.com

Lola, FI, 4 years
Right stifle

Caudal face transverse scan 9

GAS MED
DIFS
POPLITEAL
Sesamoid
TIBIA

www.imaio.com

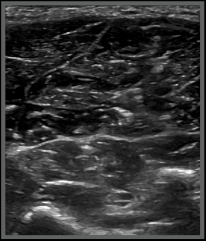
Lola, FI, 4 years
Left stifle

Caudal face transverse scan 9

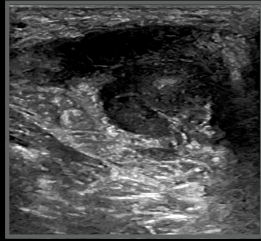
www.imaio.com

Lola, FI, 4 years

Right stifle

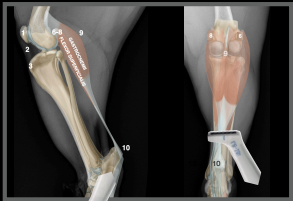


Left stifle

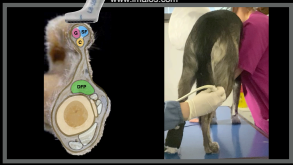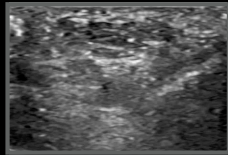


Lola, FI, 4 years

Right leg

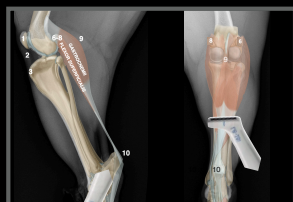


Caudal face transverse scan 9

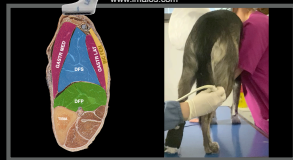
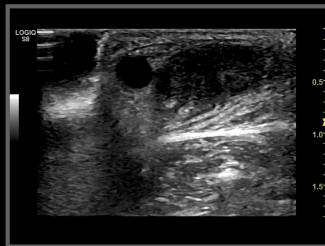


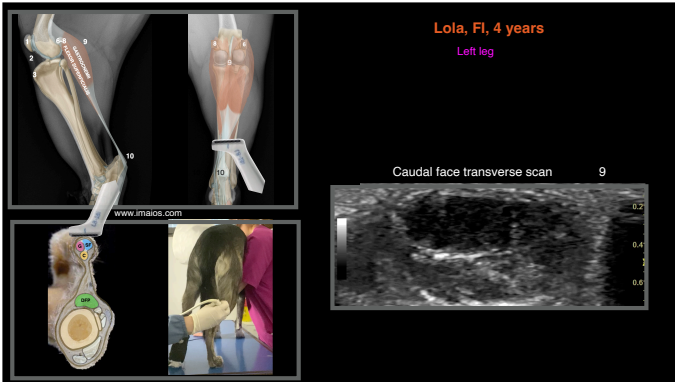
Lola, FI, 4 years

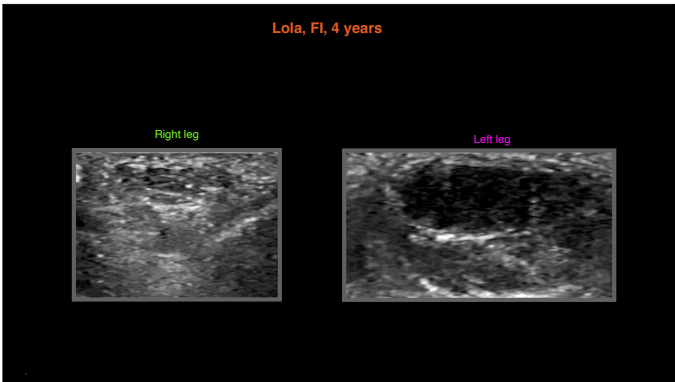
Left leg

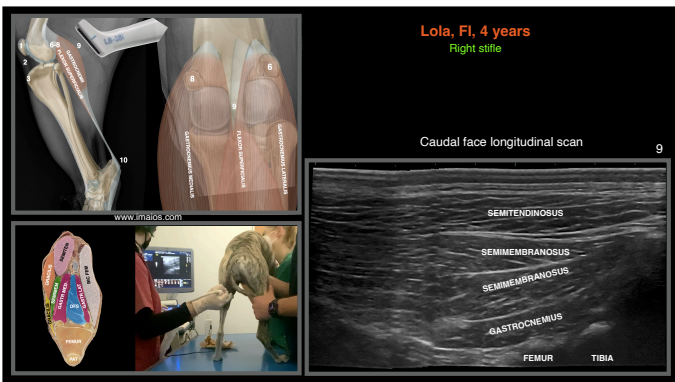


Caudal face transverse scan 9









Lola, FI, 4 years
Right stifle

Caudal face longitudinal scan 9

www.imaicos.com

Lola, FI, 4 years
Right hock

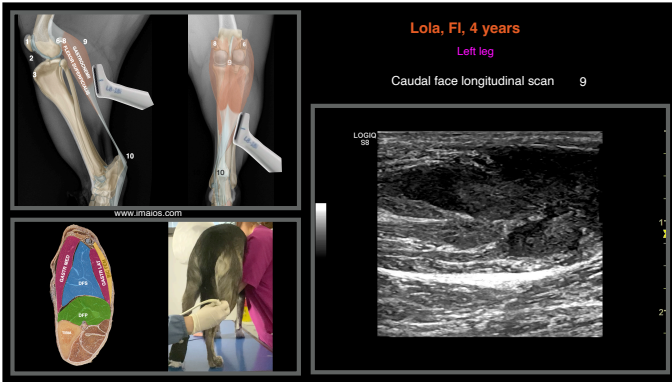
Caudal face longitudinal scan 9-10

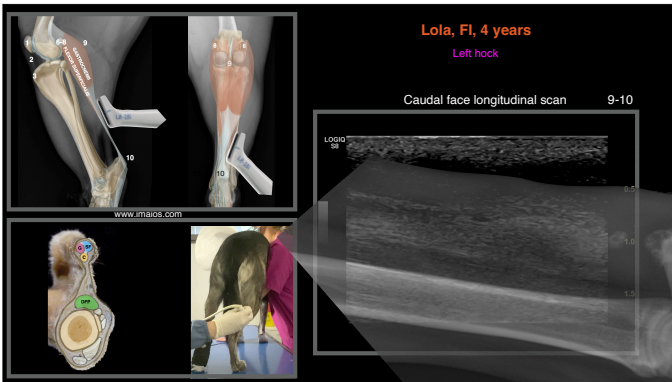
www.imaicos.com

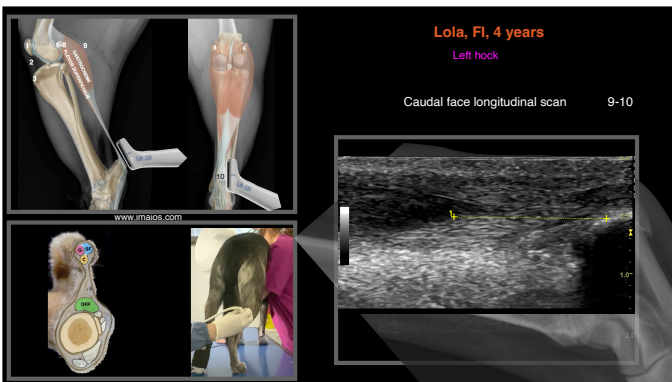
Lola, FI, 4 years
Left leg

Caudal face longitudinal scan 9

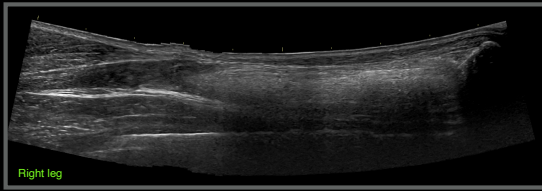
www.imaicos.com



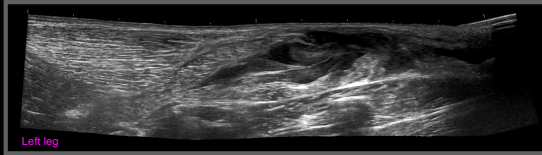




Lola, Fi, 4 years



Right leg



Left leg

Lola, English Setter, FI, 4 years

Ultrasonographic diagnoses

- Left-sided rupture of the DFS muscle
- Focal rupture of the left Gastrocnemius muscle
- Extensive rupture of the left Gastrocnemius and Communis tendon
- Chronic left-sided Achille's tendonitis



Next steps:

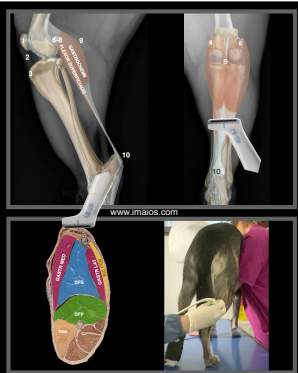
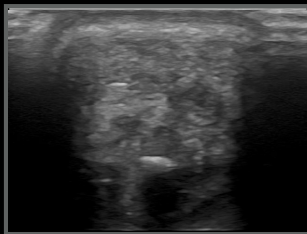
- Removable cast and physiotherapy
- Surgery after three months
- Is back to hunting, light work

Lola, FI, 4 years

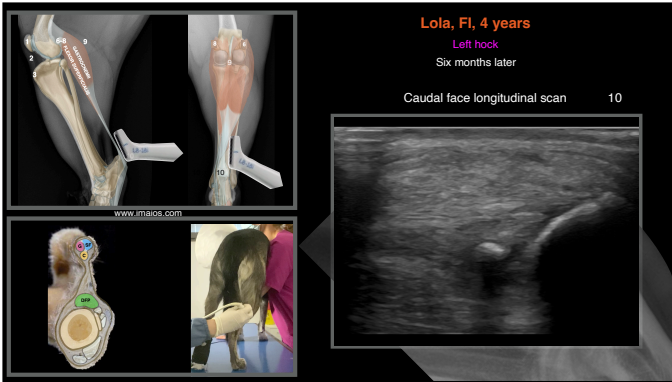
Left leg

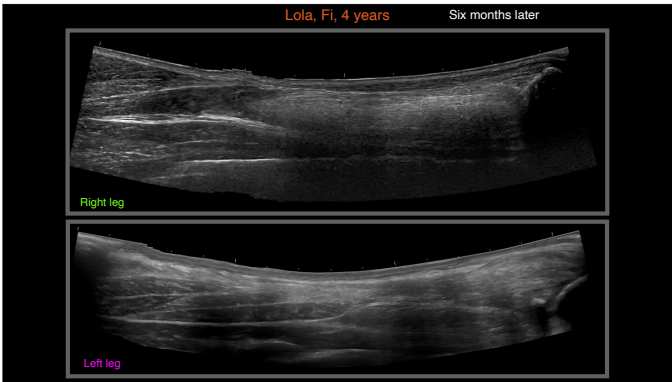Six months later

Caudal face transverse scan 9



www.maiosa.com





Key point ultrasound of the Achille's tendon

- Often chronic changes
- Healing usually doesn't involve going back to normal
- Underlying chronic predisposition
- Chronic management

Thank you



Diagnostic Mindset

www.diagnosticmindset.com
