

# Morpho-functional approach of shoulder and elbow ultrasound in 12 scan planes

## Supraspinatus Brachiocephalicus

Giliola Spattini  
DVM, GP Cardio, CCRT, PhD, DECVDI



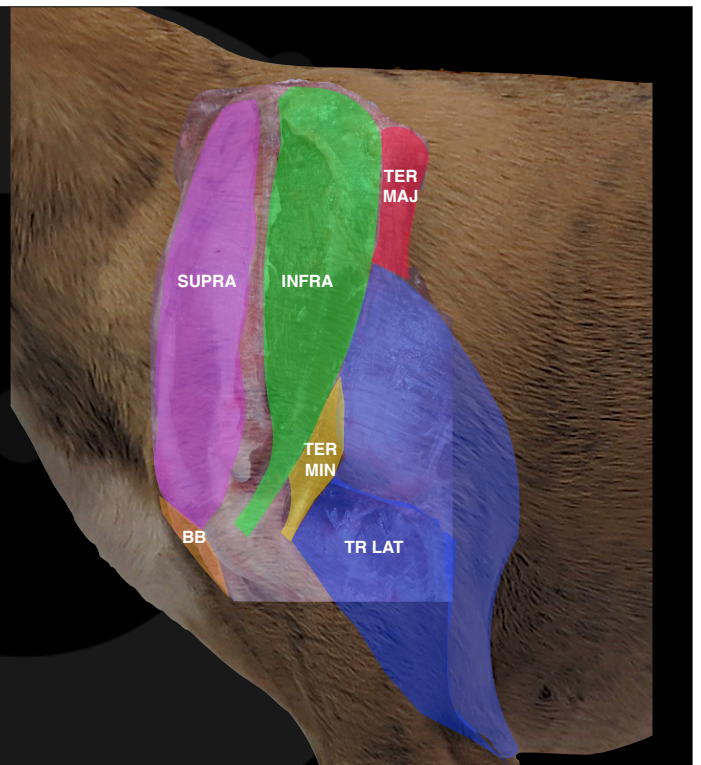
Diagnostic Mindset



Thank to [www.imaio.com](http://www.imaio.com)

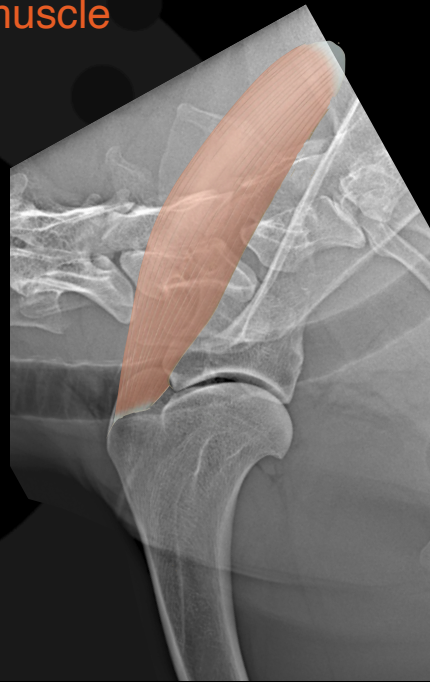### Gross anatomy of the shoulder

- Deltoideus
- Infraspinatus
- Teres Major
- Triceps
- **Supraspinatus**
- BB
- Teres Minor



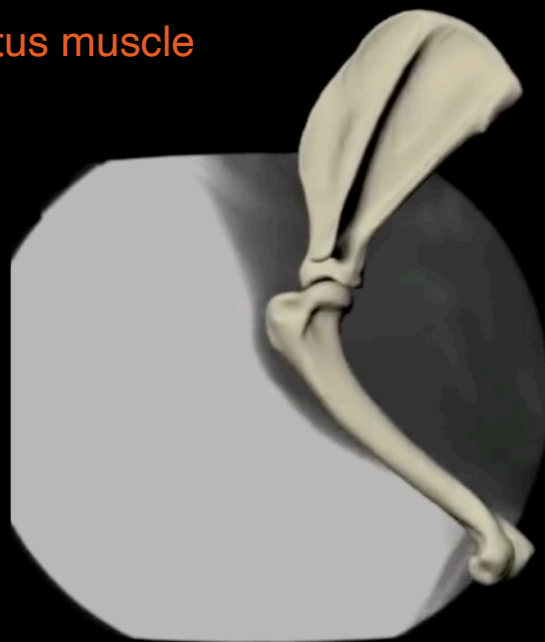## The supraspinatus muscle

- Carries the weight of the head
- Fibro-cartilagineous aponeurosis
- Low pain receptors density



## The supraspinatus muscle


- Stop the humer from displacing cranially
- Carry the weight of the head





## Cin, Greyhound, FS, 10 years

- She ran against the door three days ago
- Since then, third-degree lameness left front limb
- Mild improvement on NSAID and pain killers

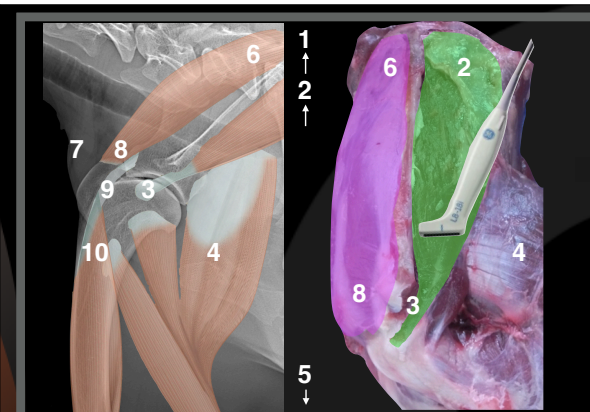
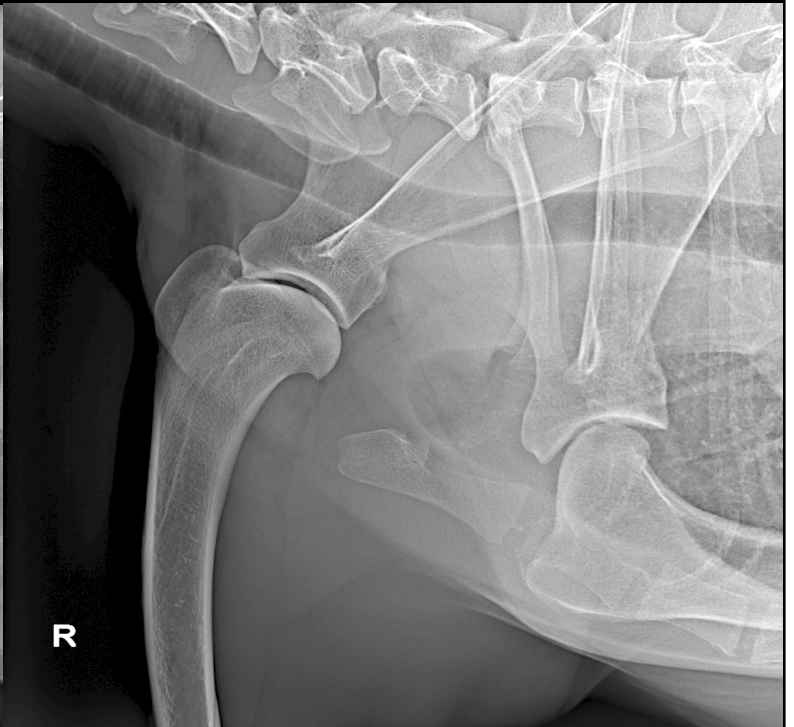
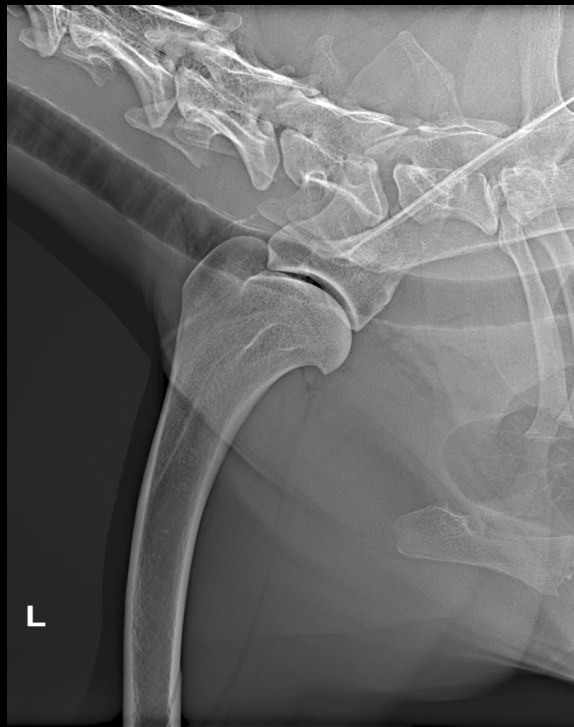

## Cin, Greyhound, FS, 10 years

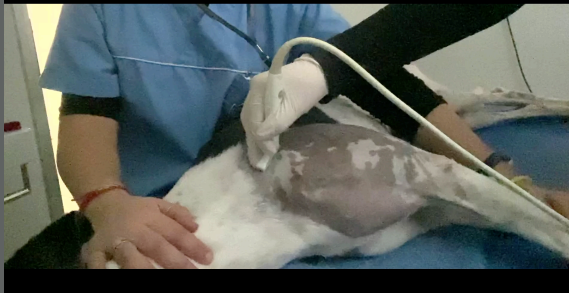- She cries if touched
- Neurologic problem?
- Not possible to localise the pain



Cyn, FS, 10 ys



[www.imaio.com](http://www.imaio.com)

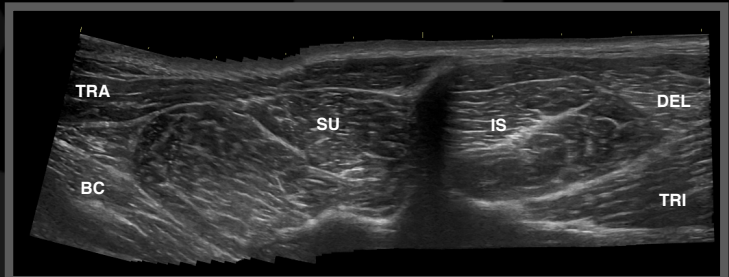
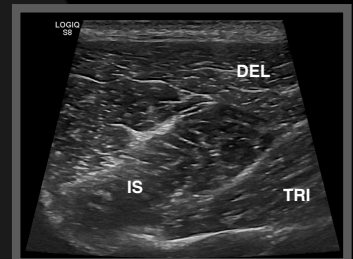
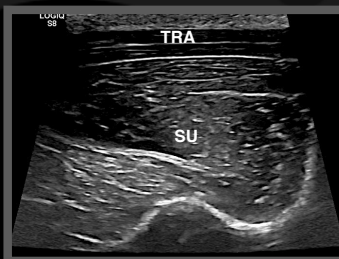


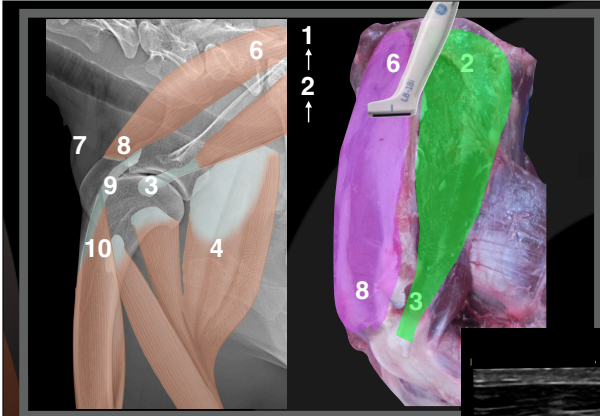
Cyn, FS, 10 years

Right shoulder

6-8

2-3

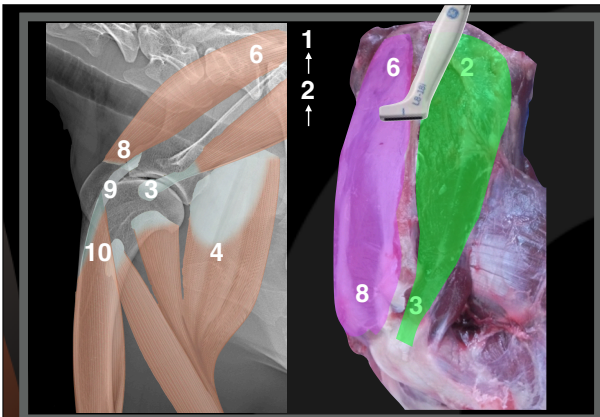
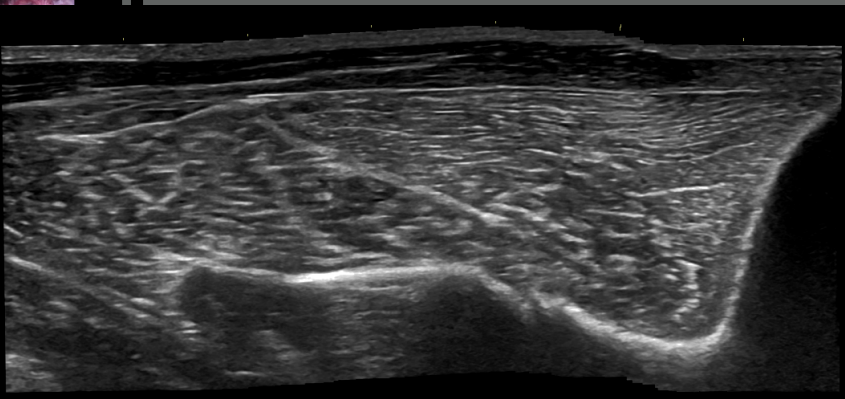
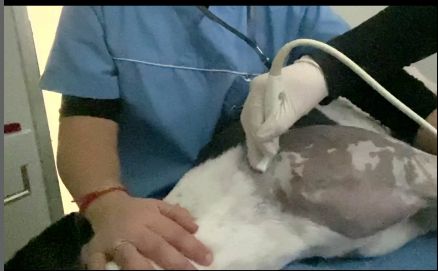



Cyn, FS, 10 years

Right shoulder

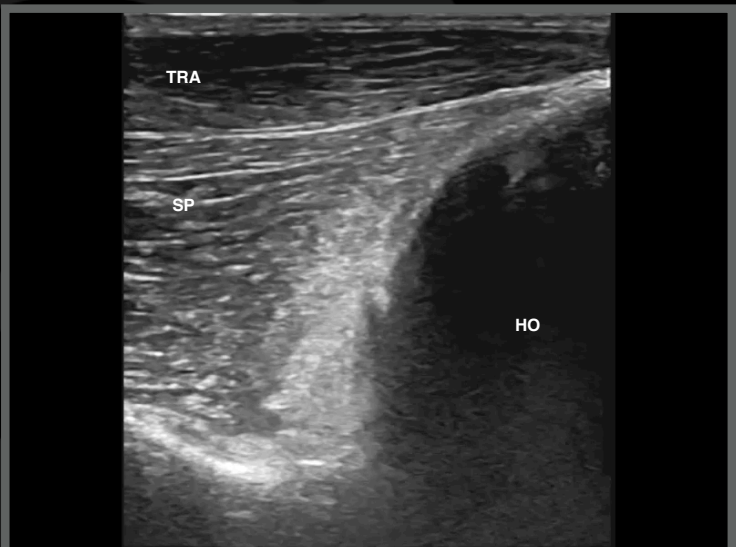
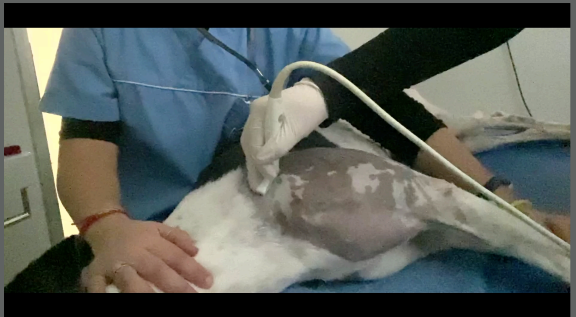Supraspinatus muscle transverse scan

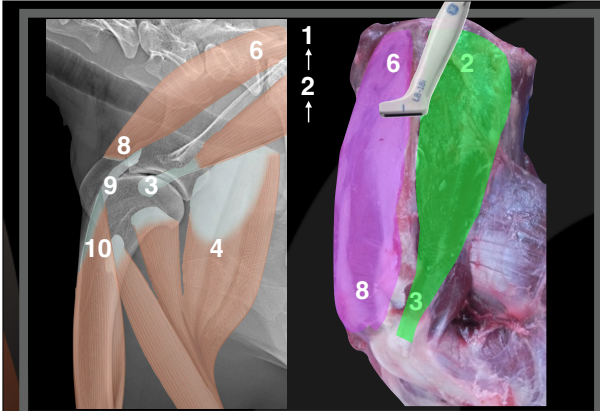


Cyn, FS, 10 years

Left shoulder

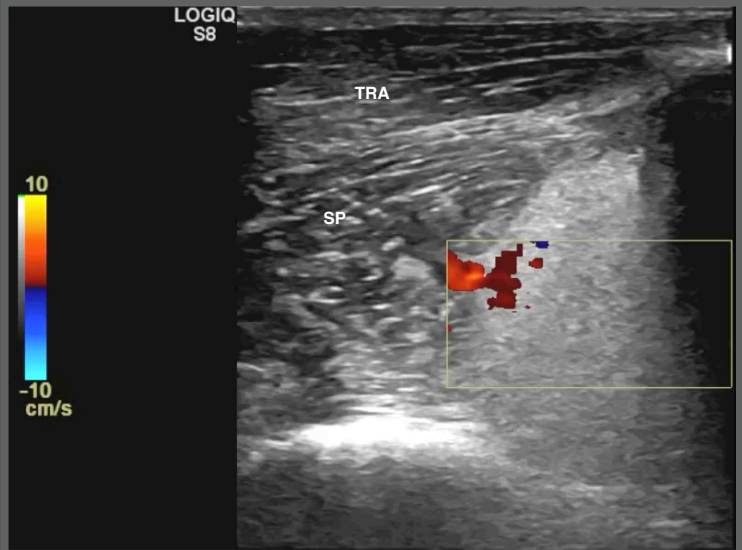
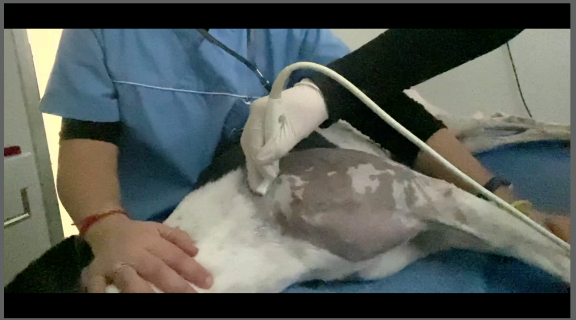
Supraspinatus muscle transverse scan





Cyn, FS, 10 years  
Left shoulder

Supraspinatus muscle transverse scan



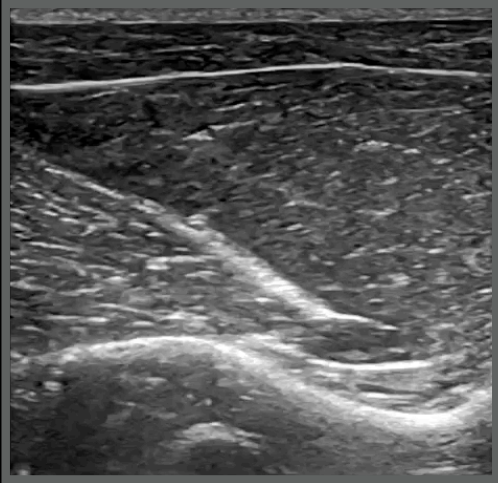
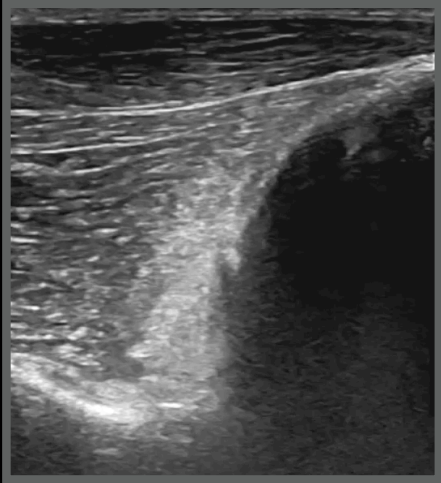
Cyn, FS, 10 years

6-8 transverse

Left shoulder

Scattering artifact

Right shoulder

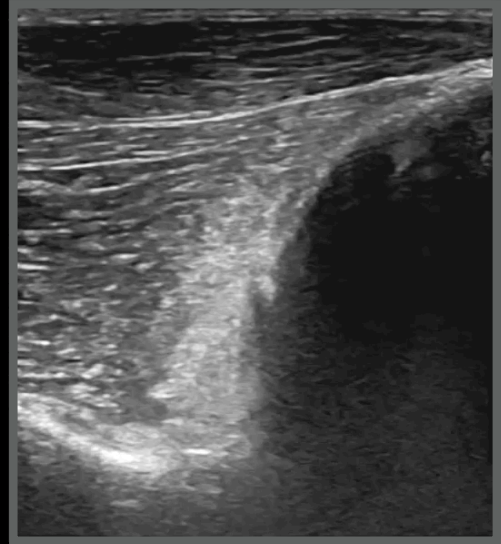




## Cin, Greyhound, FS, 10 years

### Ultrasonographic diagnoses:

- Focal area of scattering artefact left supraspinatus
- Possible chip fracture of the spine of the left scapula
- Suspected sub-acute muscle contusion



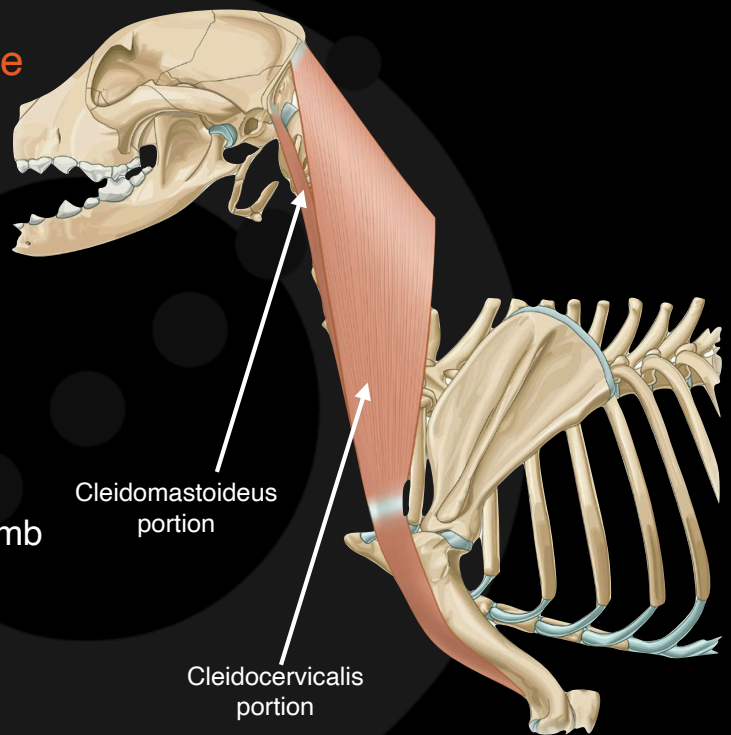
## Cin, Greyhound, FS, 10 years

- Local treatment
- Immediately better
- Recovered after one week



## The brachiocephalicus muscle

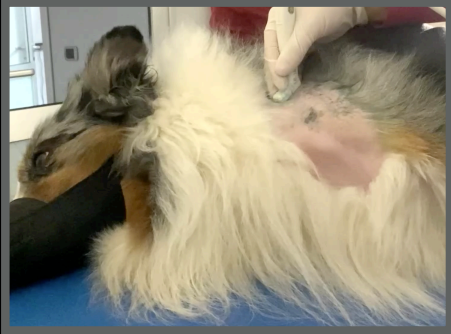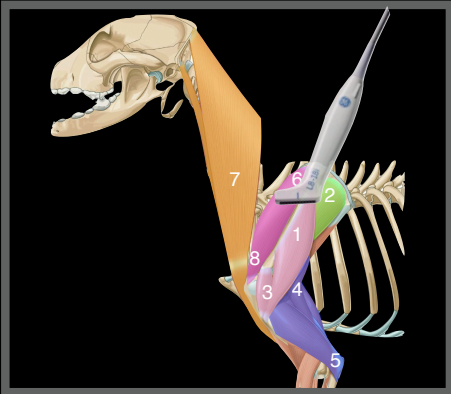
- Contains the clavicle
- Connect the head and the front limb



## Goldreig, Shetland, MI, 6 years

- After one training session, "seems painful"
- He tried to bite when the left side of his neck was touched
- Minimal improvement with NSAID
- Negative radiographic study



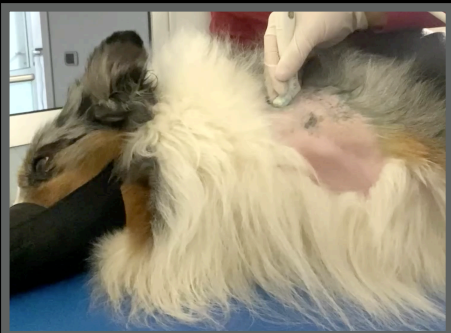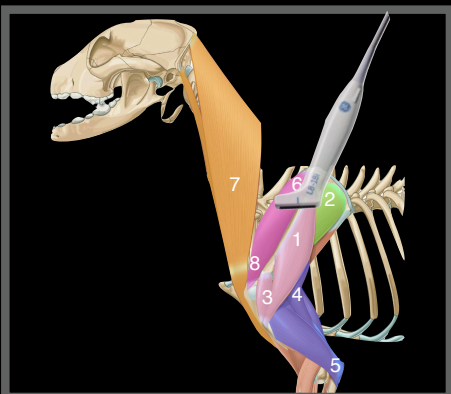
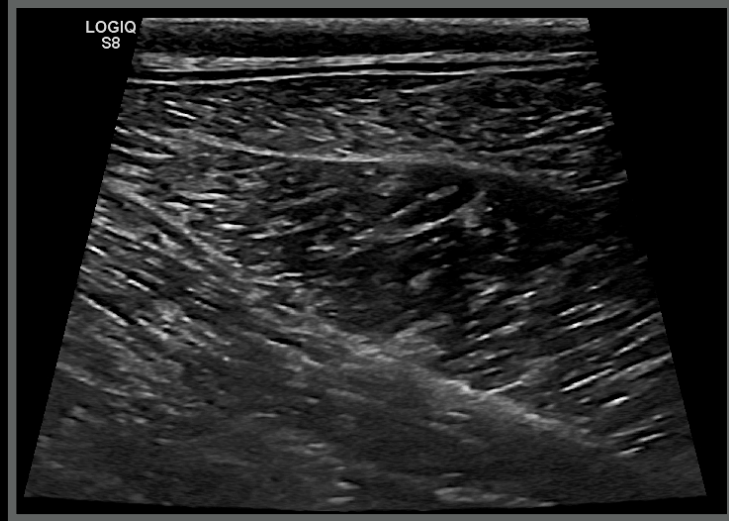


Goldreig, MI, 6 years



Right shoulder

6-7

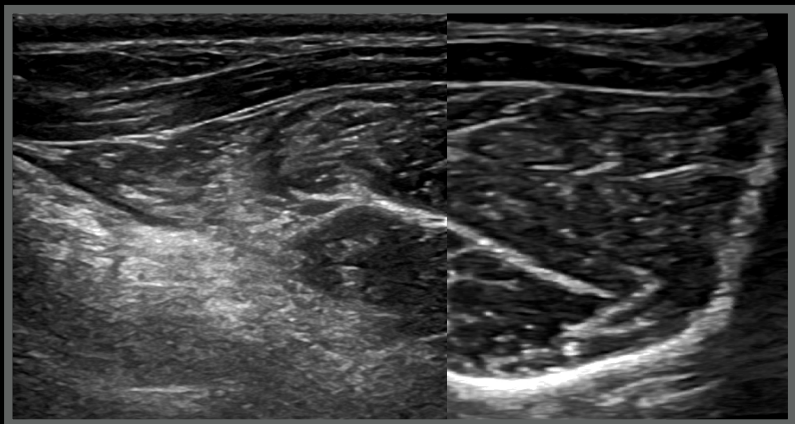


Goldreig, MI, 6 years



Left shoulder

6-7

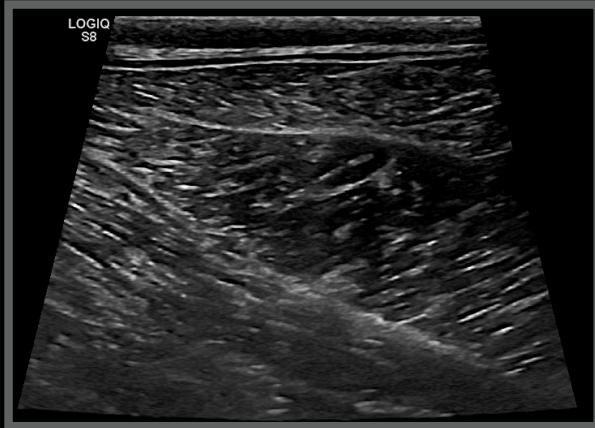


## Goldreig, MI, 6 years

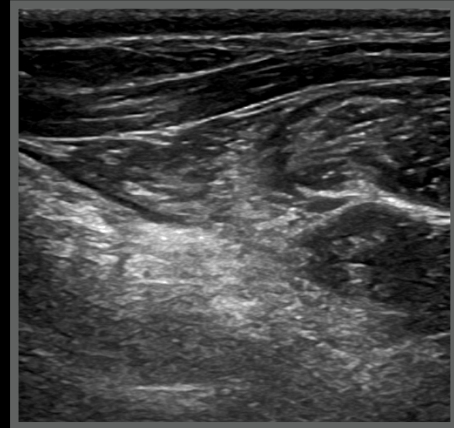


Brachiocephalic muscle

Right shoulder



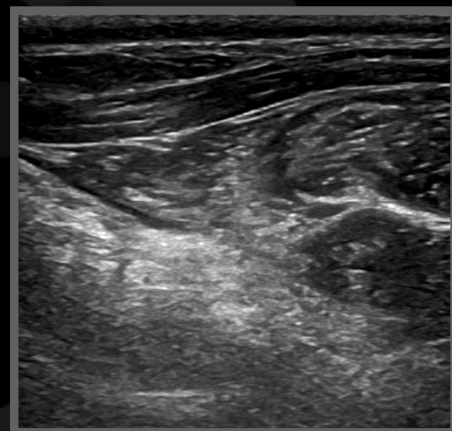
Left shoulder



## Goldreig, Shetland, MI, 6 years

Ultrasonographic diagnoses:

- Patchy hyperechoic areas of brachiocephalic muscle
- Pain on palpation at PE



## Goldreig, Shetland, MI, 6 years

Two months later

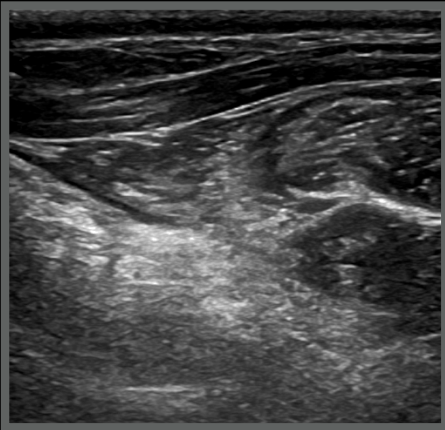
- Two months of physiotherapy and massage
- Seems fine but He is not back to sport



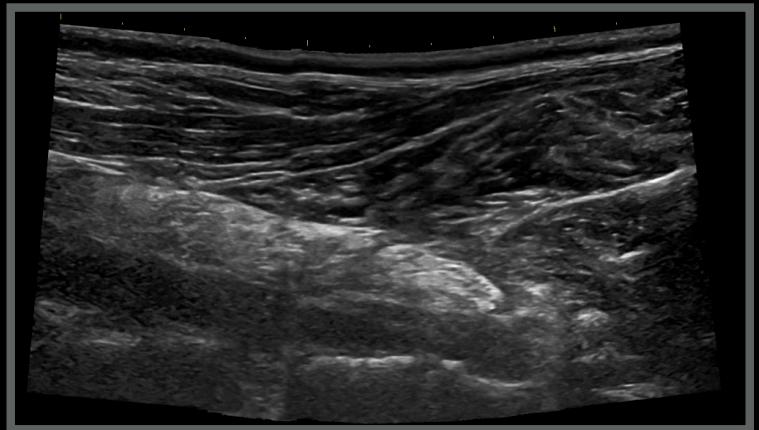
## Goldreig, MI, 6 years

Brachiocephalicus muscle

Left shoulder Time 0



Left shoulder Two months later



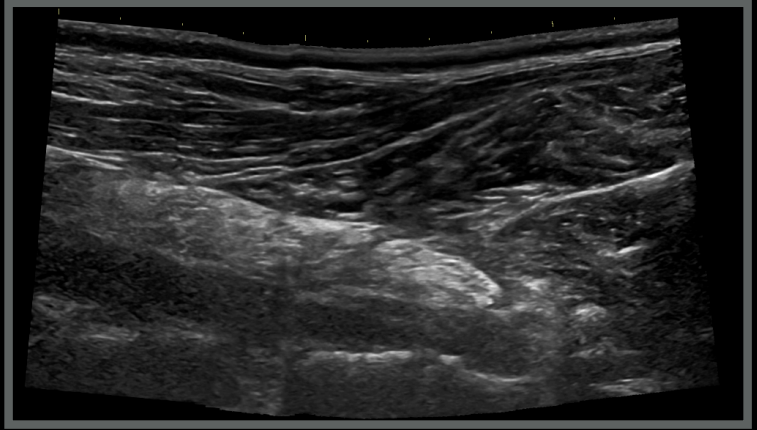
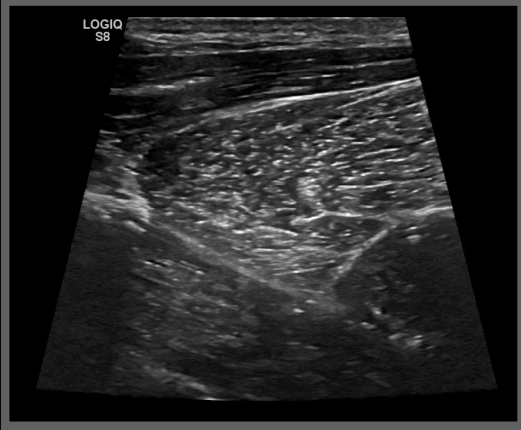
Goldreig, MI, 6 years



Brachiocephalicus muscle

Right shoulder Two months later

Left shoulder Two months later



Goldreig, MI, 6 years

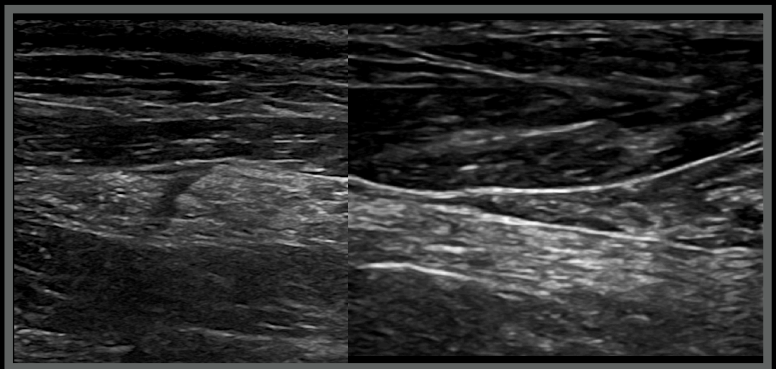
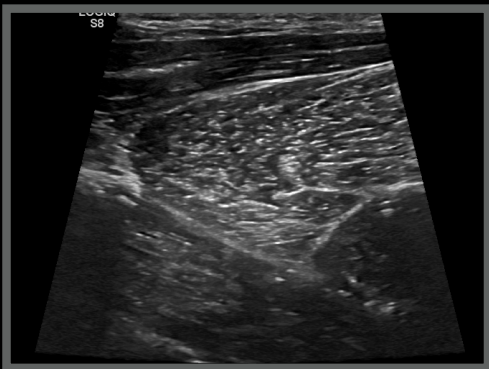


Brachiocephalicus muscle

Right shoulder

Six months later

Left shoulder

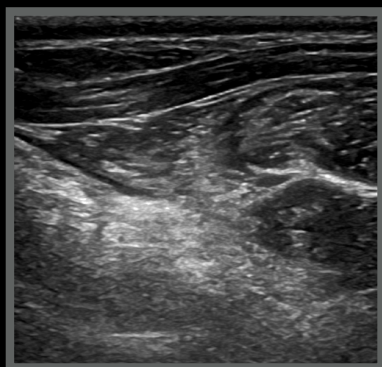


## Goldreig, MI, 6 years

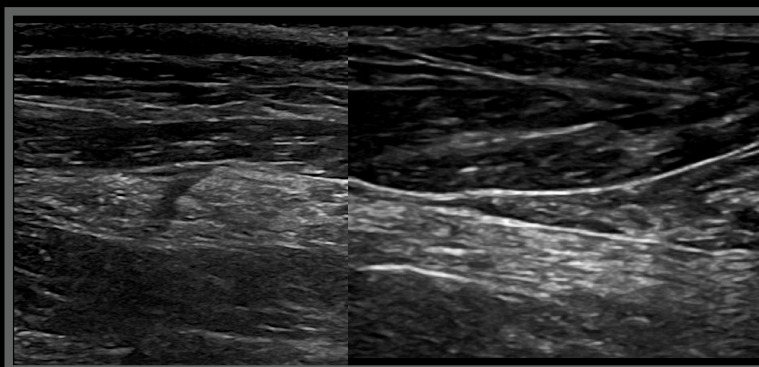


Brachiocephalicus muscle

Left shoulder Time 0



Left shoulder Six months later



## Goldreig, Shetland, MI, 6 years

- Chronic fibrosis/contracture?
- Chronic overuse soreness?



# Thank you



Diagnostic Mindset

[www.diagnosticmindset.com](http://www.diagnosticmindset.com)