

# Morpho-functional approach of shoulder and elbow ultrasound in 12 scan planes

## Supraspinatus Brachiocephalicus

Gigliola Spattini  
DVM, GP Cardio, CCRT, PhD, DECVDI



Thank to [www.imaio.com](http://www.imaio.com)

---

---

---

---

---

---

---

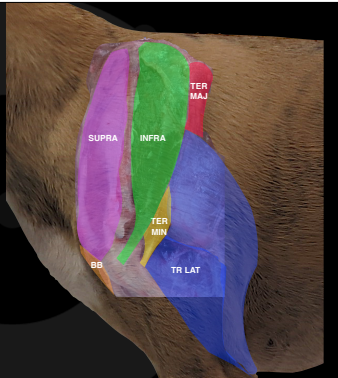
---

---

---

### Gross anatomy of the shoulder

- Deltoidaeus
- Infraspinatus
- Teres Major
- Triceps
- **Supraspinatus**
- BB
- Teres Minor



---

---

---

---

---

---

---

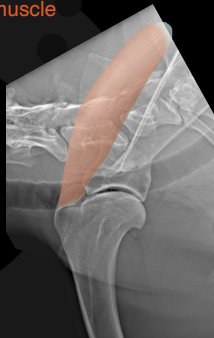---

---

---

### The supraspinatus muscle

- Carries the weight of the head
- Fibro-cartilagineous aponeurosis
- Low pain receptors density



---

---

---

---

---

---

---

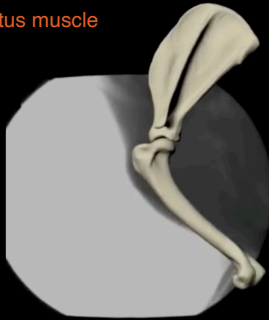
---

---

---

### The supraspinatus muscle

- Stop the humer from displacing cranially
- Carry the weight of the head



---

---

---

---

---

---

---

---

### Cin, Greyhound, FS, 10 years

- She ran against the door three days ago
- Since then, third-degree lameness left front limb
- Mild improvement on NSAID and pain killers



---

---

---

---

---

---

---

---

### Cin, Greyhound, FS, 10 years

- She cries if touched
- Neurologic problem?
- Not possible to localise the pain



---

---

---

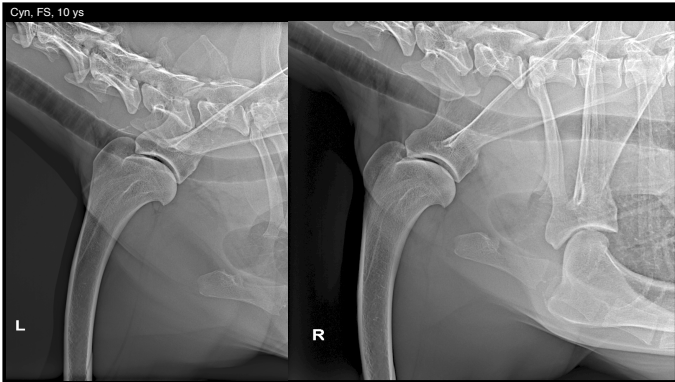---

---

---

---

---



---

---

---

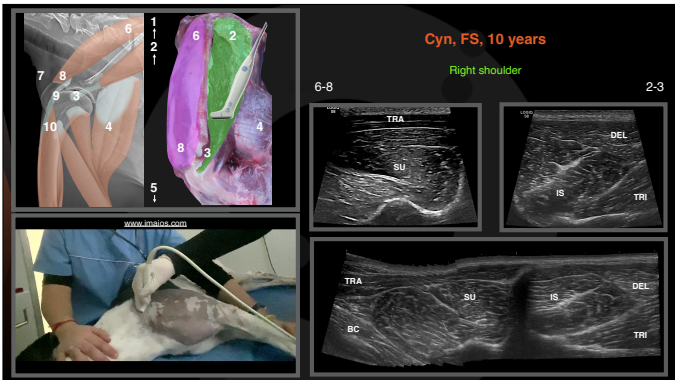
---

---

---

---

---



---

---

---

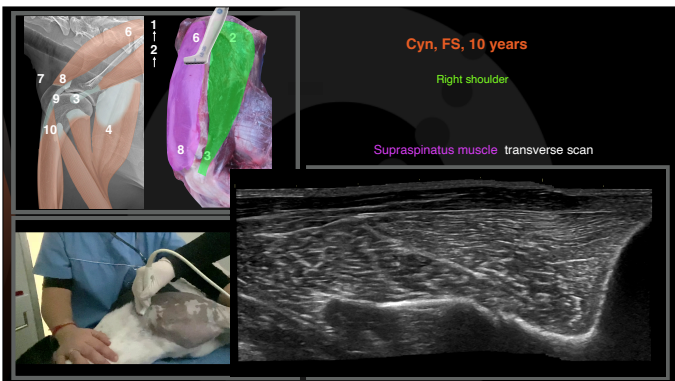
---

---

---

---

---



---

---

---

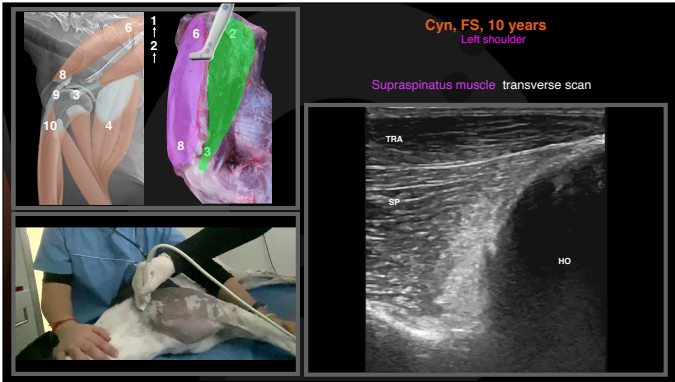
---

---

---

---

---




---

---

---

---

---

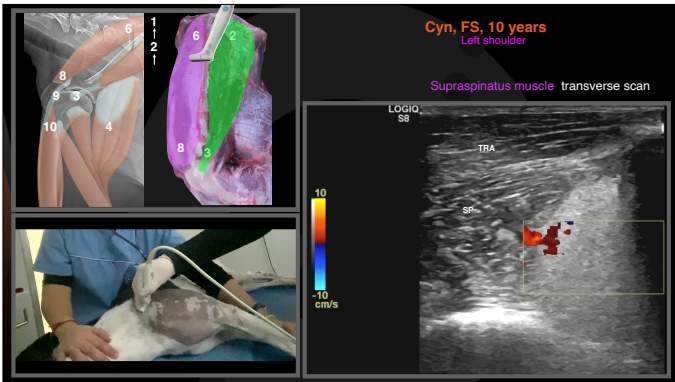
---

---

---

---

---




---

---

---

---

---

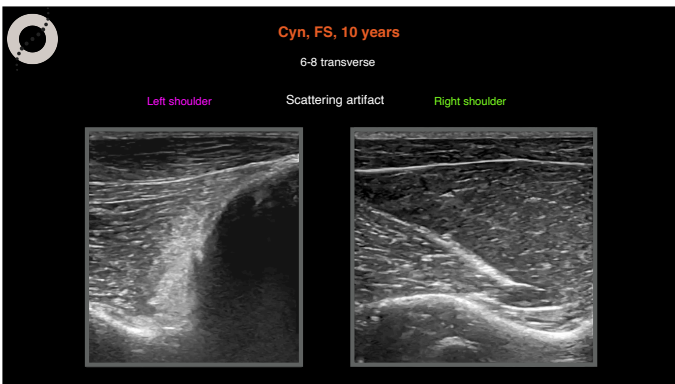
---

---

---

---

---




---

---

---

---

---

---

---

---

---

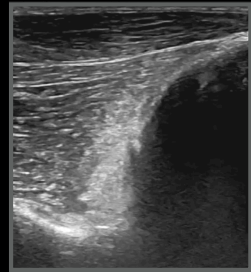
---



### Cin, Greyhound, FS, 10 years

#### Ultrasonographic diagnoses:

- Focal area of scattering artefact left supraspinatus
- Possible chip fracture of the spine of the left scapula
- Suspected sub-acute muscle contusion



---

---

---

---

---

---

---

---



### Cin, Greyhound, FS, 10 years

- Local treatment
- Immediately better
- Recovered after one week



---

---

---

---

---

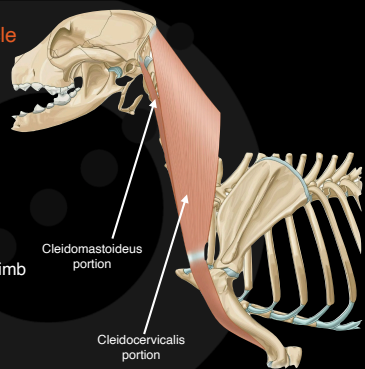
---

---

---

### The brachiocephalic muscle

- Contains the clavicle
- Connect the head and the front limb



---

---

---

---

---

---

---

---

### Goldreig, Shetland, MI, 6 years

- After one training session, "seems painful"
- He tried to bite when the left side of his neck was touched
- Minimal improvement with NSAID
- Negative radiographic study



---

---

---

---

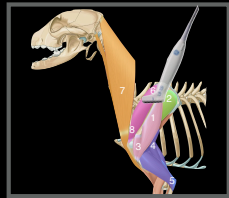
---

---

---

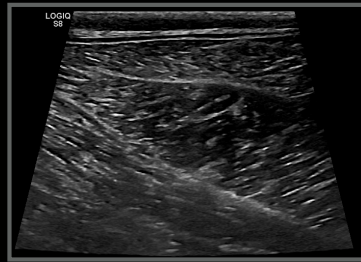
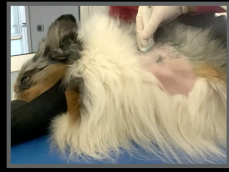---

### Goldreig, MI, 6 years



Right shoulder

6-7



---

---

---

---

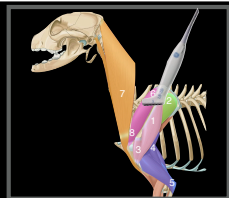
---

---

---

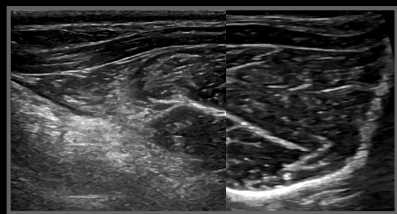
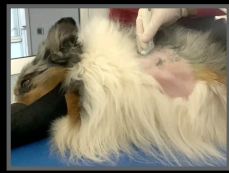---

### Goldreig, MI, 6 years



Left shoulder

6-7



---

---

---

---

---

---

---

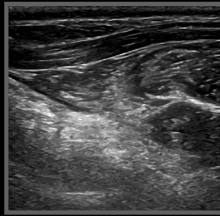
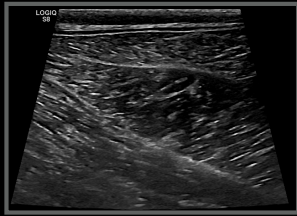
---

Goldreig, MI, 6 years

Brachiocephalic muscle

Right shoulder

Left shoulder



---

---

---

---

---

---

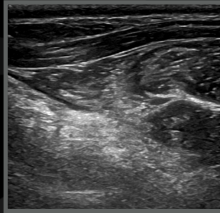
---

---

Goldreig, Shetland, MI, 6 years

Ultrasonographic diagnoses:

- Patchy hyperechoic areas of brachiocephalic muscle
- Pain on palpation at PE



---

---

---

---

---

---

---

---

Goldreig, Shetland, MI, 6 years

Two months later

- Two months of physiotherapy and massage
- Seems fine but He is not back to sport



---

---

---

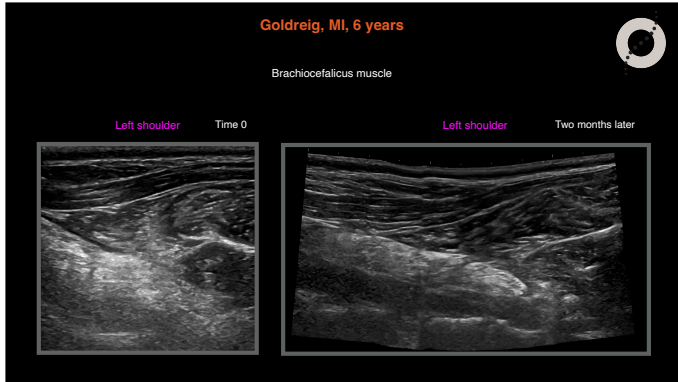
---

---

---

---

---



---

---

---

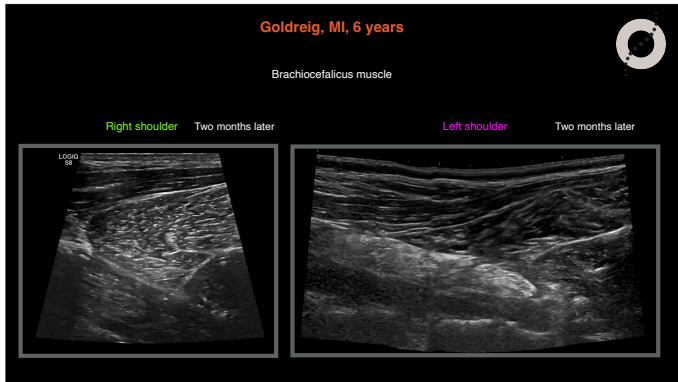
---

---

---

---

---



---

---

---

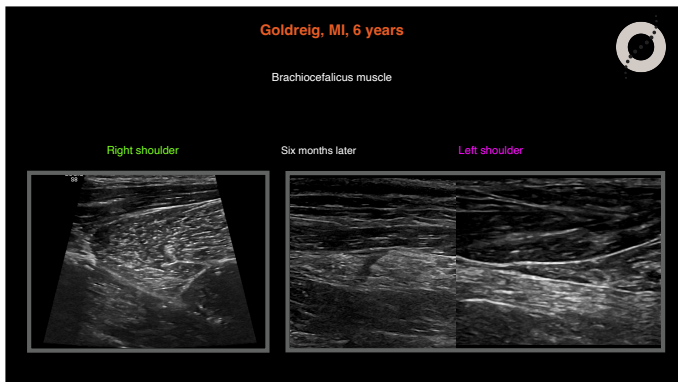
---

---

---

---

---



---

---

---

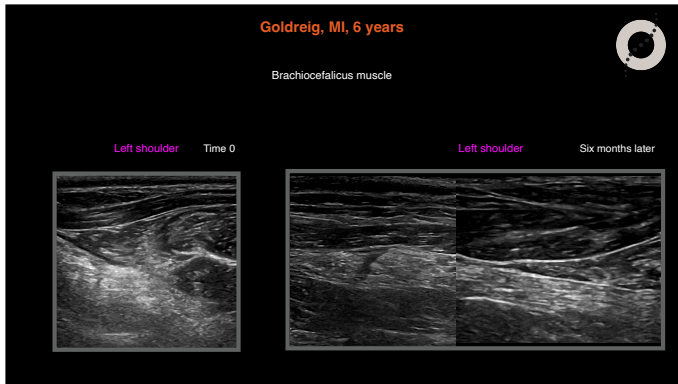
---

---

---

---

---



---

---

---

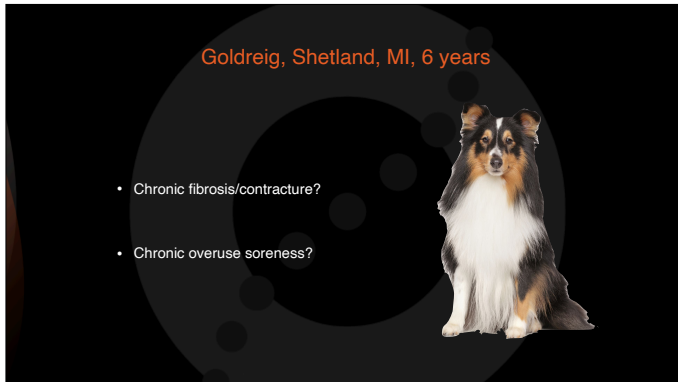---

---

---

---

---



---

---

---

---

---

---

---

---



---

---

---

---

---

---

---

---