

Morpho-functional approach of shoulder and elbow ultrasound in 12 scan planes

Supraspinatus- Biceps-Subscapularis

Giliola Spattini
DVM, GP Cardio, CCRT, PhD, DECVDI



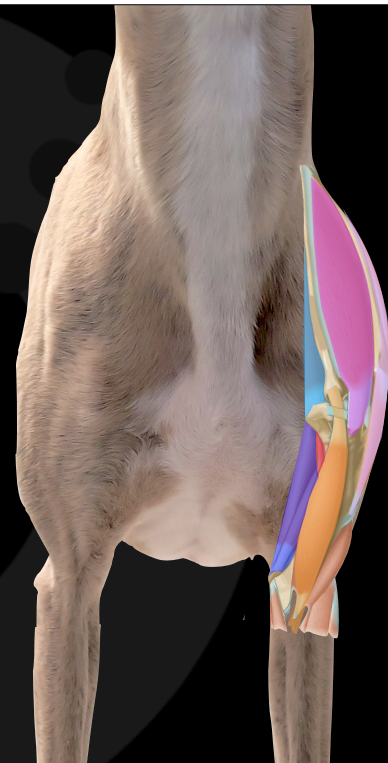Diagnostic Mindset



Thank to www.imaios.com

Gross anatomy of the shoulder

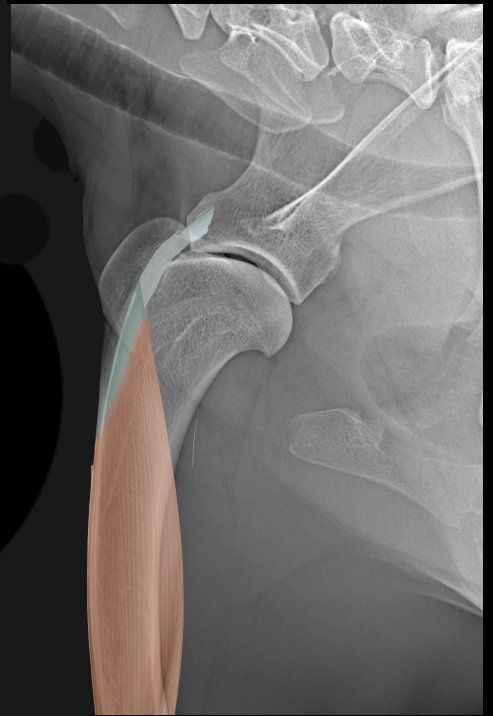
- Deltoideus
- **Infraspinatus**
- Teres Major
- Triceps
- Supraspinatus
- **Biceps Brachii**
- Subscapularis



www.imaios.com

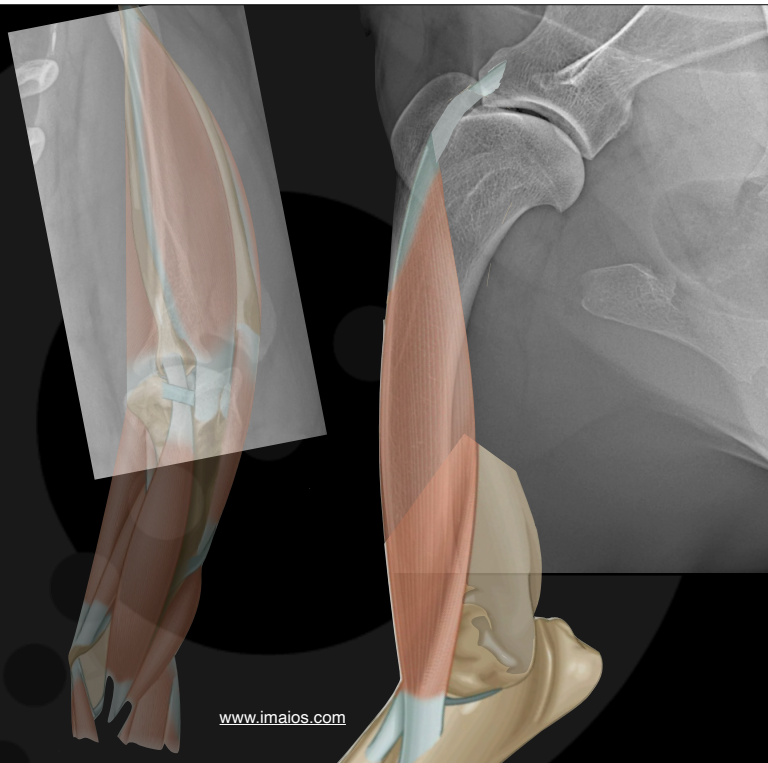
The biceps muscle

- A weak medial stabiliser of the shoulder
- Connect shoulder and elbow

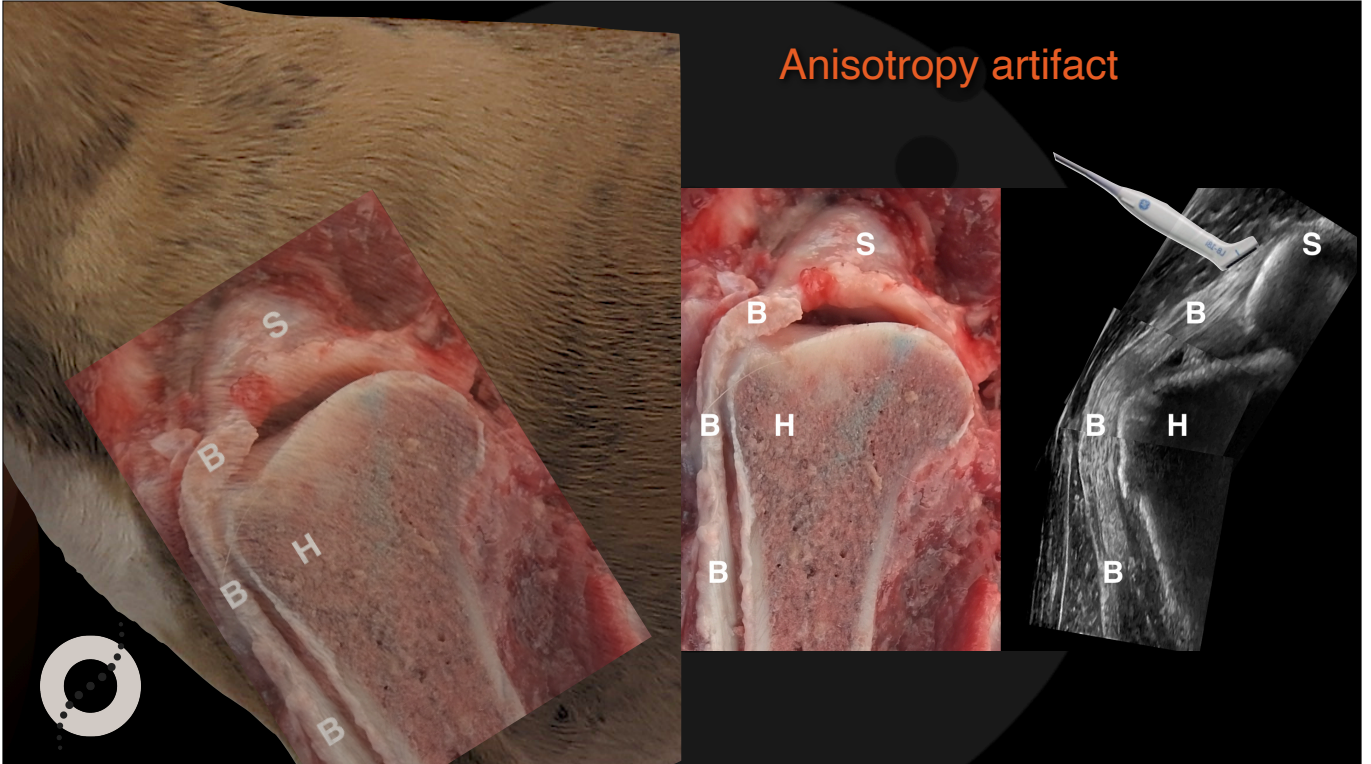


The biceps muscle

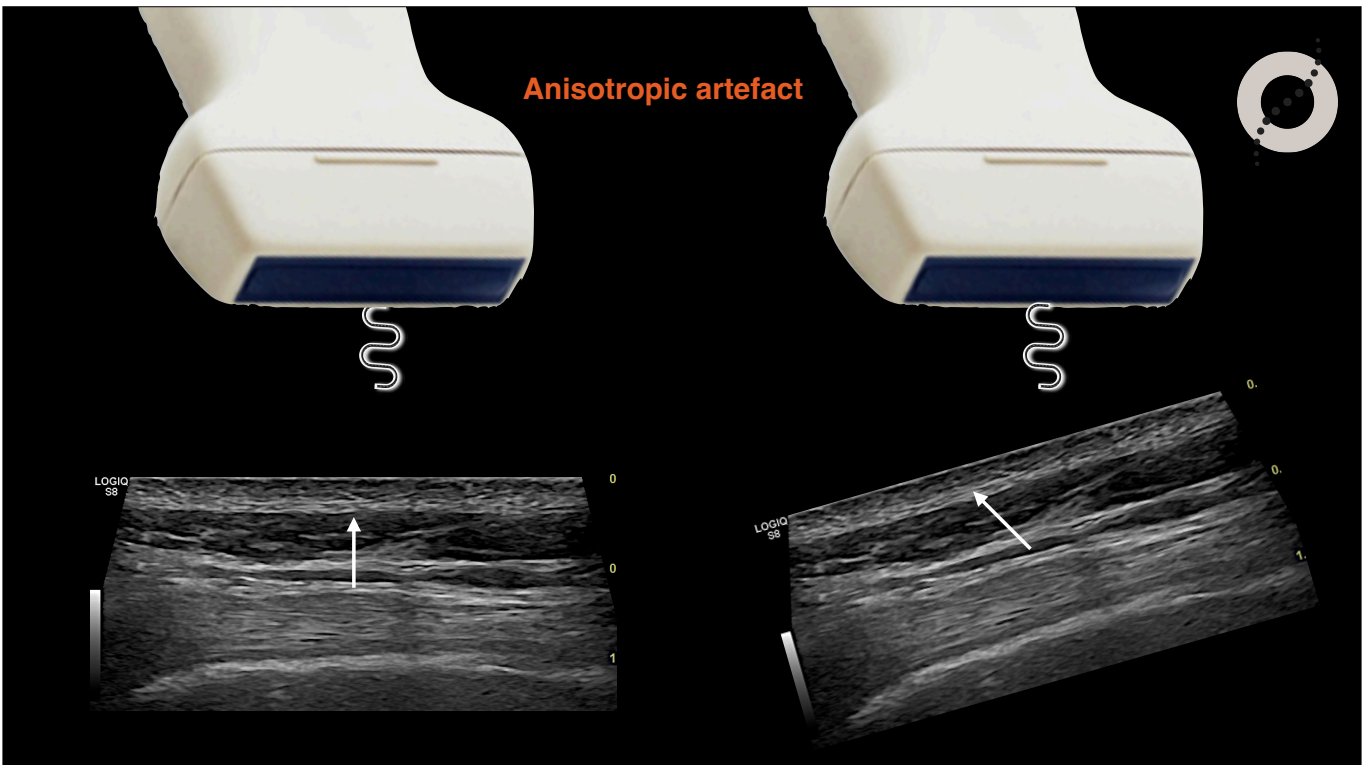
- Connect shoulder and elbow
- Flex the elbow and extend the shoulder



Anisotropy artifact



Anisotropic artefact



Ultrasound of the normal canine supraspinatus tendon: comparison with gross anatomy and histology

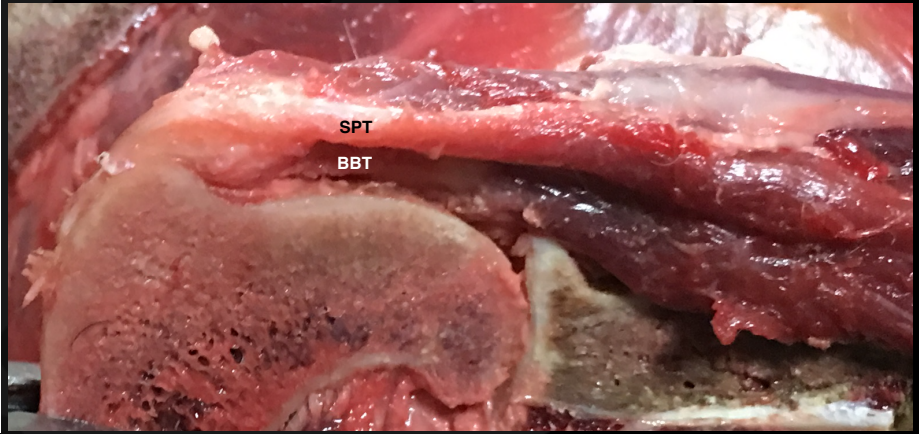
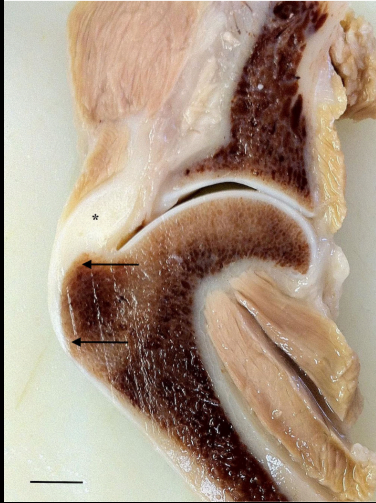Caroline Chloe Lassaigne ¹, Charlotte Boyer,² Lucile Sautier ², Olivier Taeymans³

Veterinary Record (2019)

doi:10.1136/vetrec-2019-105552

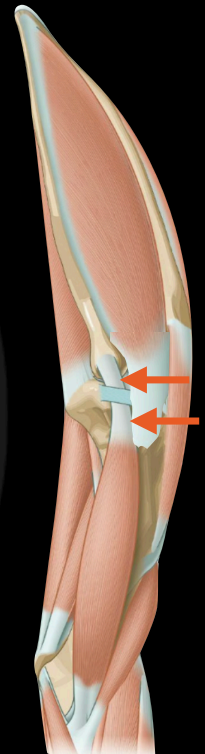
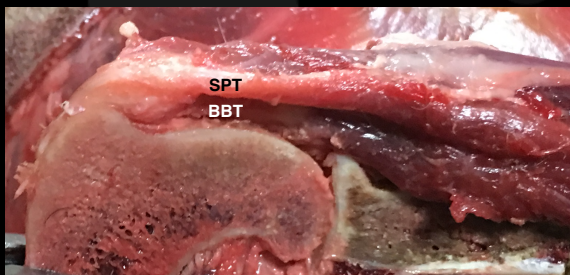
Supraspinatus tendon sustains 4,6 times the patient body weight during trot

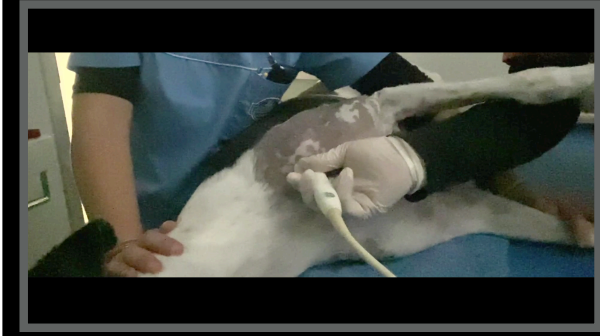
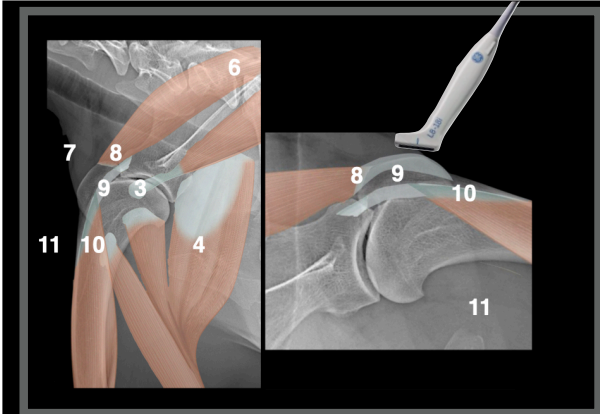
There are few nervous terminations



Chronic supraspinatus tendinopathy in sportive dogs

- Repetitive traumas results in hemorrhages that mineralise
- The patient is usually asymptomatic but the tendon diameter increases
- The end result is an impingement syndrome on the adjacent biceps tendon



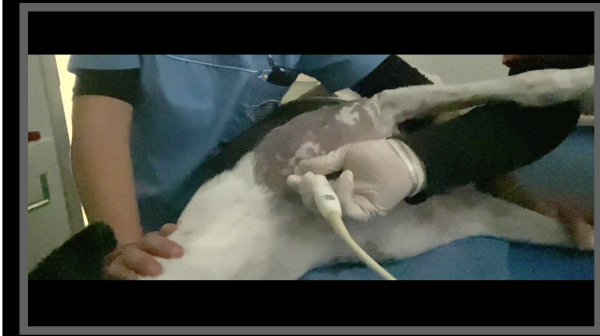
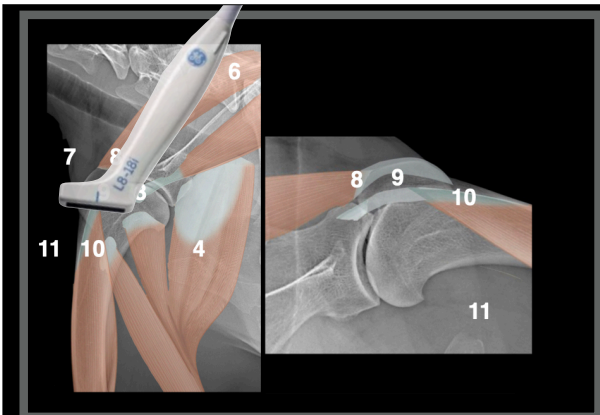
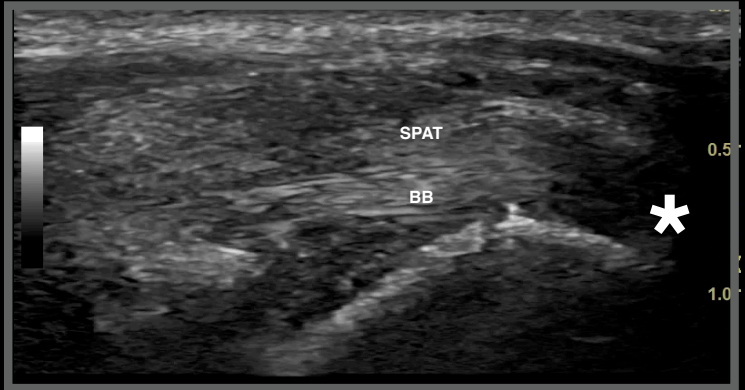

Normal anatomy scan plane 9
longitudinal



Supraspinatus tendon - BB longitudinal scan

9

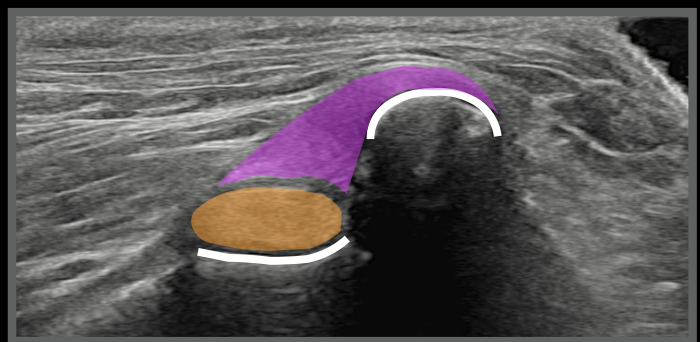


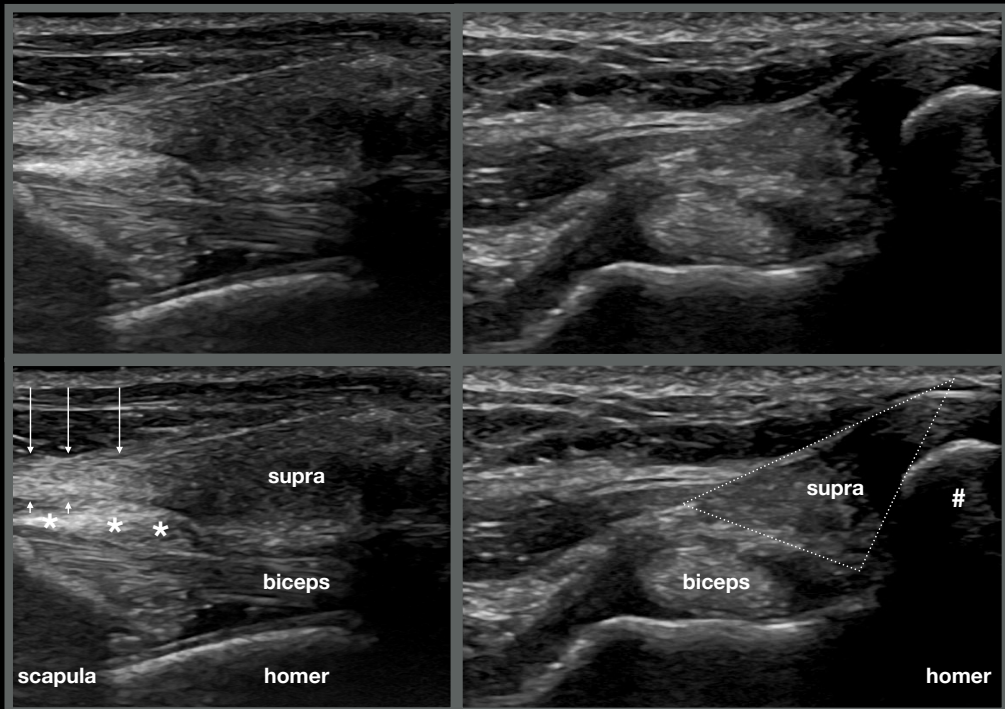
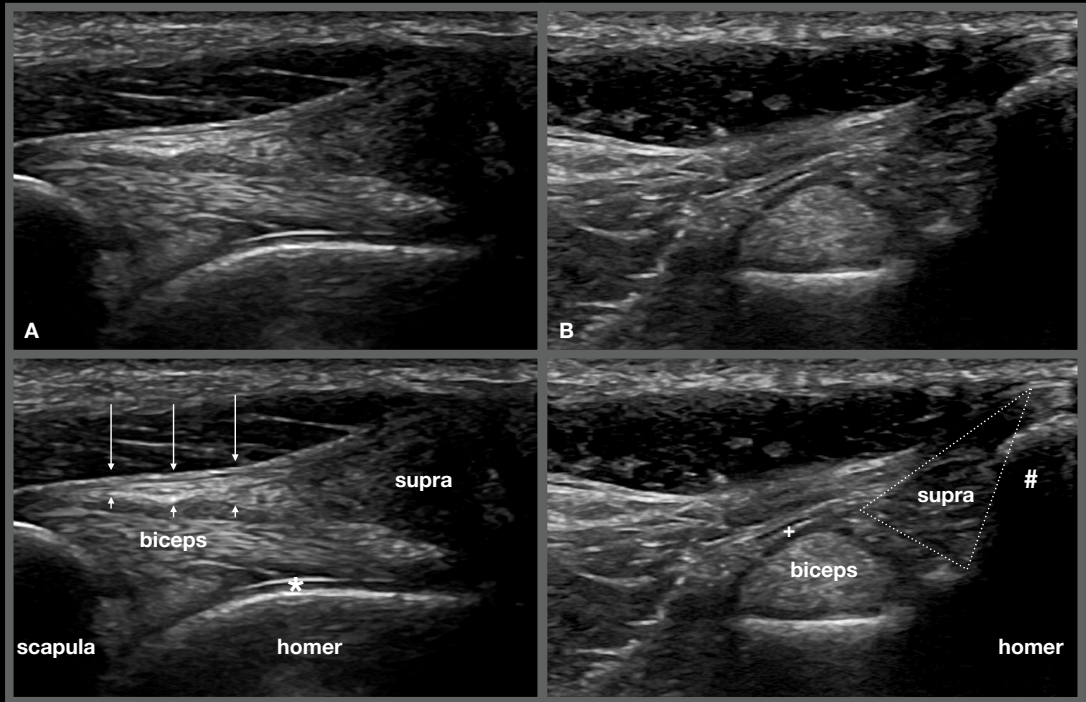
Normal anatomy scan plane 9
transverse

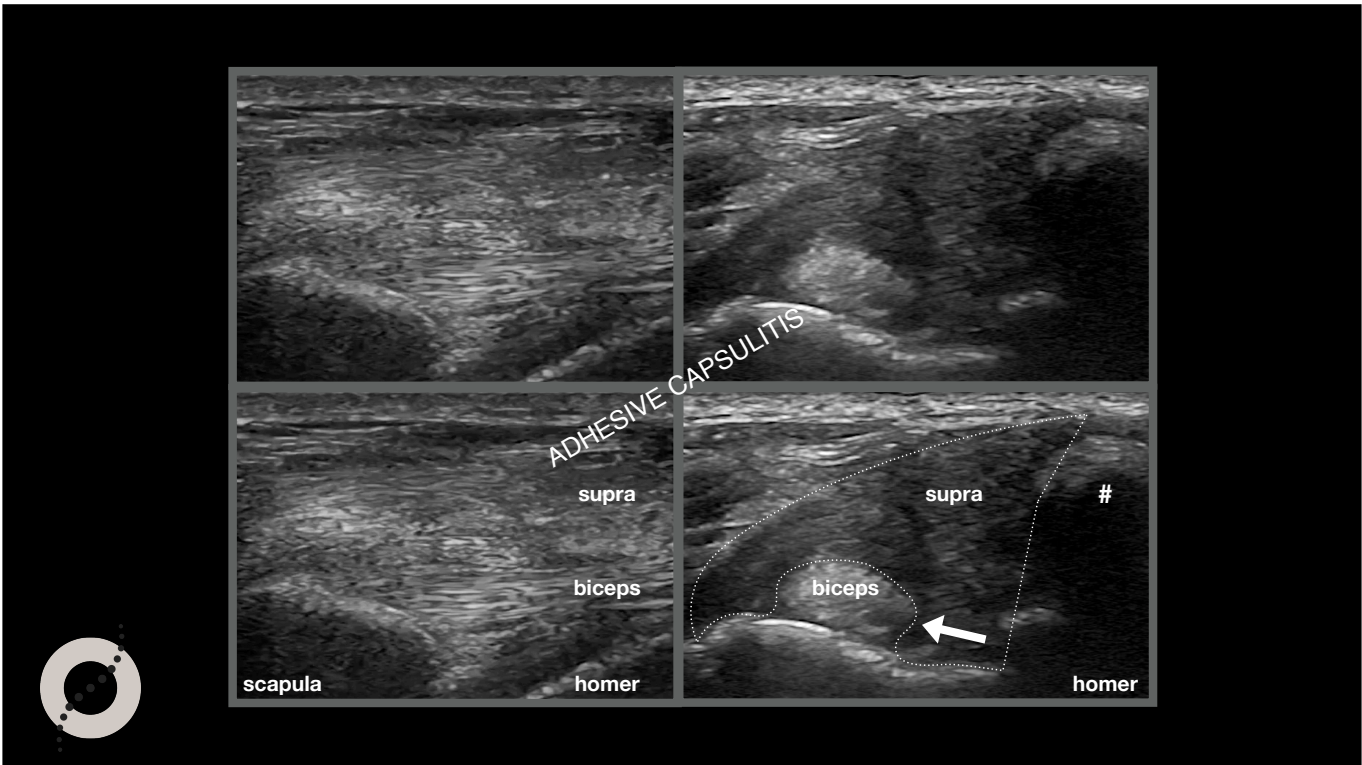
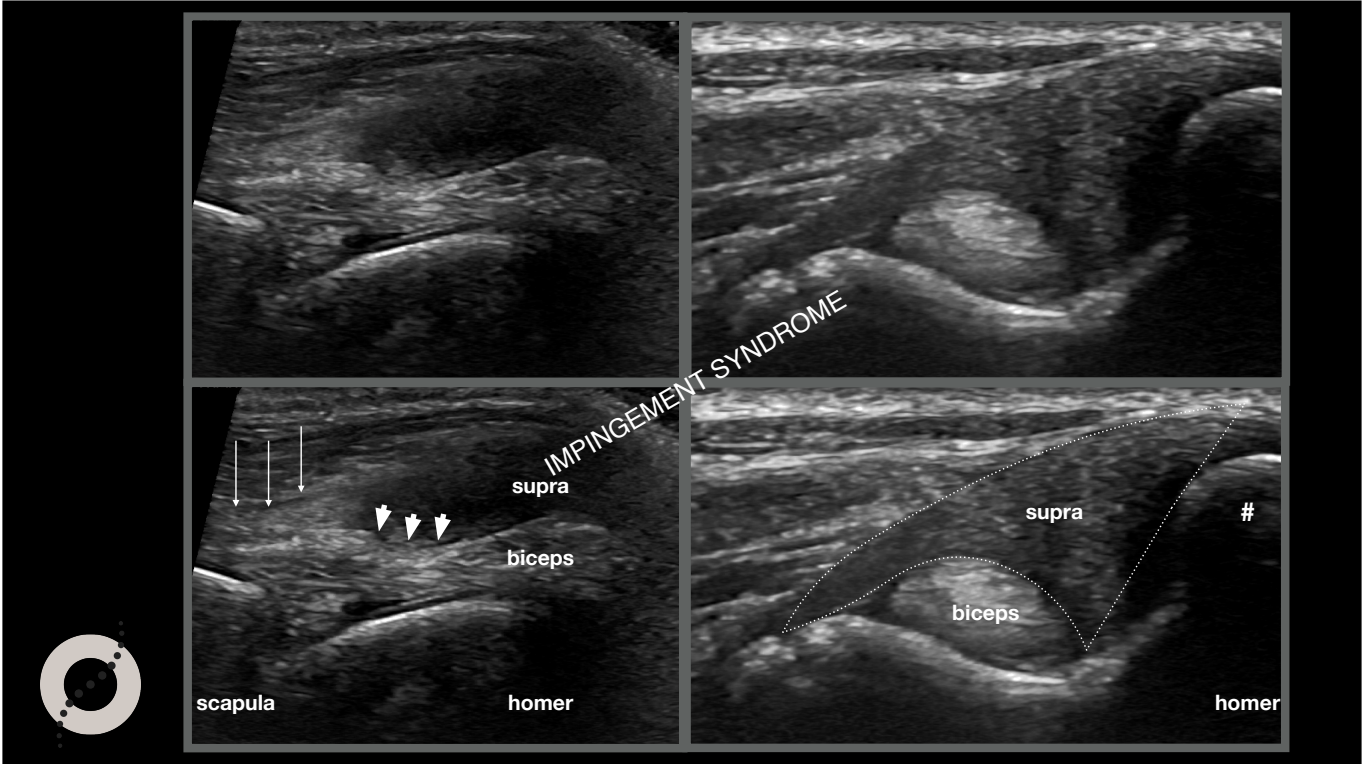


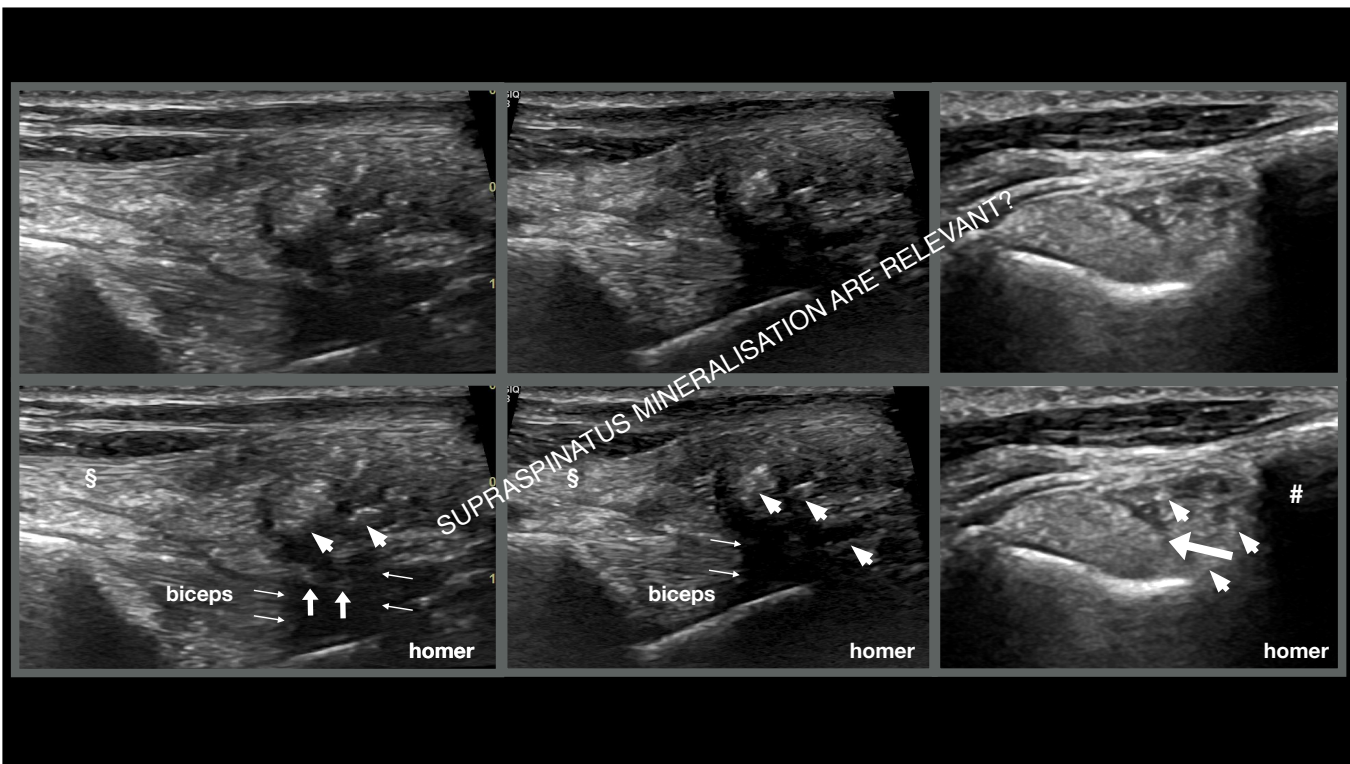
Supraspinatus tendon - BB transverse scan

9










Hill, German Shepherd, MI, 2 years

- Left front lameness from 2 weeks
- Last year right front lameness
- Doesn't respond to NSAID

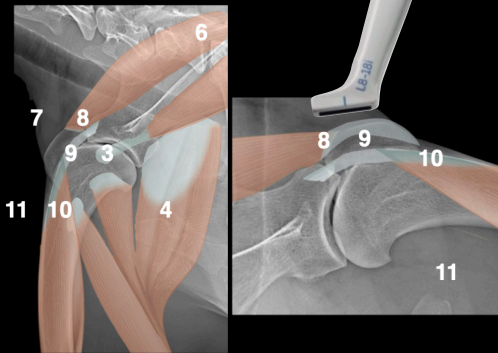


Hill, MI, 2 years



R

L



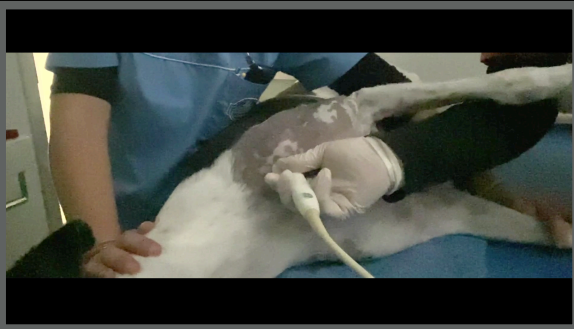
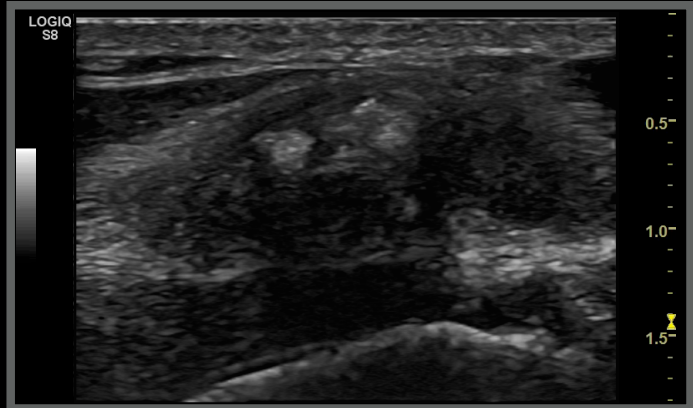
Hill, MI, 2 years

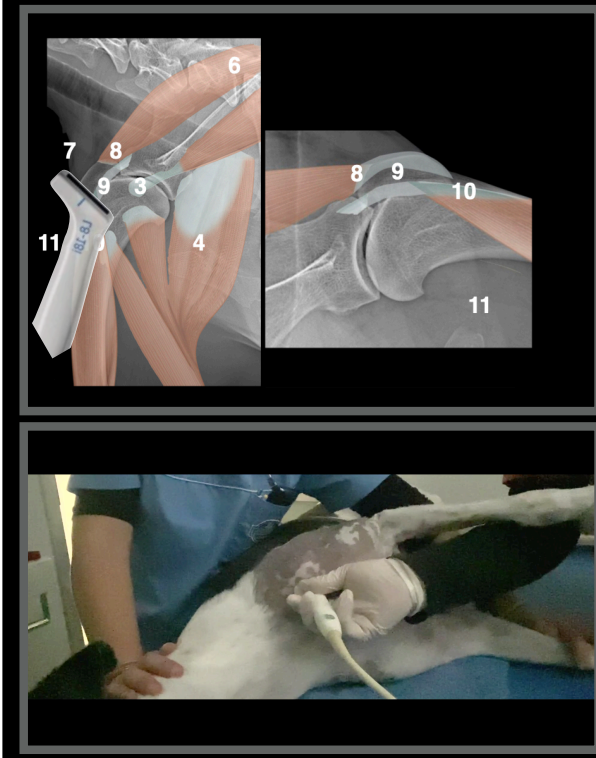


Right shoulder

Supraspinatus tendon - BB longitudinal scan

9



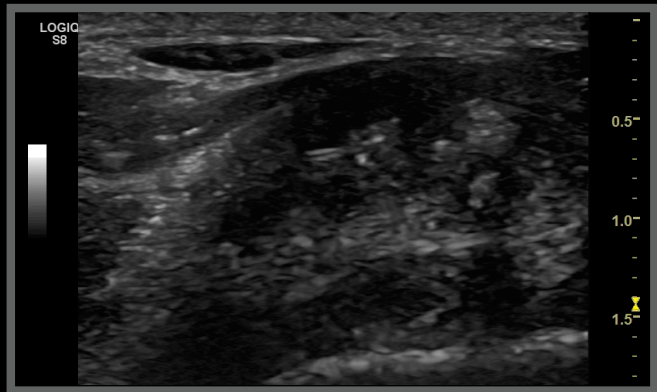


Hill, MI, 2 years

Right shoulder



Supraspinatus tendon - BB transverse scan 9



Mineralization of the supraspinatus tendon:

[Prevalence of mineralisation of the tendon of the supraspinatus muscle in non-lame dogs.](#)
Abbey R, Pettitt R.
J Small Anim Pract. 2021 Jun;62(6):450-454. doi: 10.1111/jsap.13298. Epub 2021 Jan 25.
PMID: 33492687
RESULTS: Supraspinatus mineralisation was detected in four out of 99 dogs (4%) with all four cases found in male dogs. ...CLINICAL SIGNIFICANCE: The prevalence of supraspinatus mineralisation was low in this population of non-lame dogs ...

[Mineralization of the supraspinatus tendon in dogs.](#)
Flo GL, Middleton D.
J Am Vet Med Assoc. 1990 Jul 1;197(1):95-7.
PMID: 2370229

Clinically relevant or not?

[Comparison between shoulder computed tomography and clinical findings in 89 dogs presented for thoracic limb lameness.](#)

Maddox TW, May C, Keeley BJ, McConnell JF.
Vet Radiol Ultrasound. 2013 Jul-Aug;54(4):358-64. doi: 10.1111/vru.12043. Epub 2013 Apr 18.
PMID: 23594097

[Surgical treatment of mineralized and nonmineralized supraspinatus tendinopathy in twenty-four dogs.](#)

Lafuente MP, Fransson BA, Lincoln JD, Martinez SA, Gavin PR, Lahmers KK, Gay JM.
Vet Surg. 2009 Apr;38(3):380-7. doi: 10.1111/j.1532-950X.2009.00512.x.
PMID: 19573103

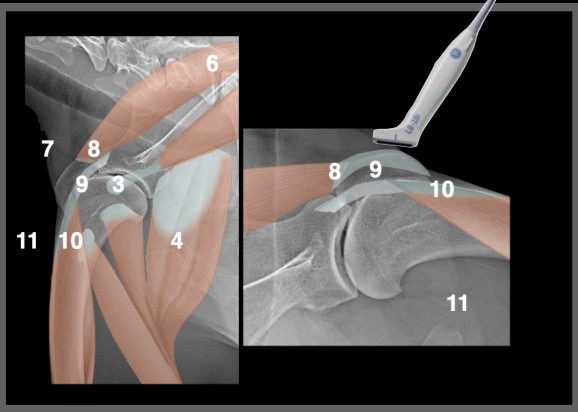
[Mineralization of the supraspinatus tendon in dogs: a long-term follow-up.](#)

Laitinen OM, Flo GL.
J Am Anim Hosp Assoc. 2000 May-Jun;36(3):262-7.
PMID: 10825100



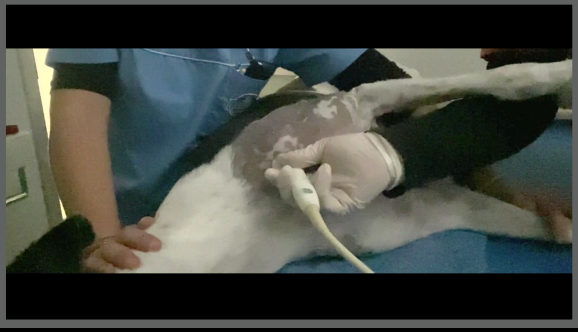
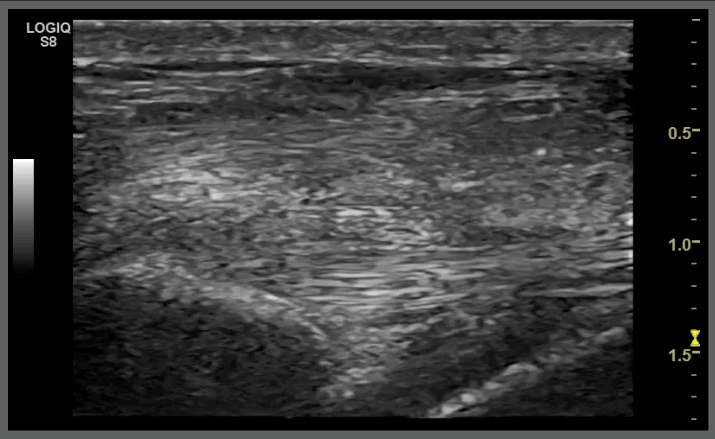
Hill, MI, 2 years

Left shoulder



Supraspinatus tendon - BB longitudinal scan

9



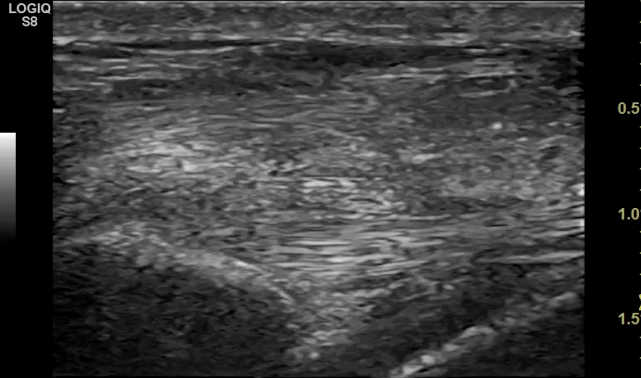
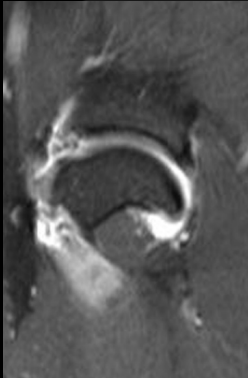Adhesive Capsulitis in Eight Dogs: Diagnosis and Management.

Carr BJ, Canapp SO, Canapp DA, Gamble LJ, Dycus DL.

Front Vet Sci. 2016 Jul 14;3:55. doi: 10.3389/fvets.2016.00055. eCollection 2016.

PMID: 27471728 **Free PMC Article**

Patient	Radiographs	Ultrasound	MRI	Arthroscopy	Cytology and histopathology
1	Normal	Supraspinatus disruption; biceps tendon sheath effusion	Marked joint effusion and synovitis; damage to the supraspinatus tendon and medial glenohumeral ligament	Biceps tendinopathy; impingement of the biceps tendon; fraying and disruption of the subscapularis and of the MGL; disruption of joint capsule; grade III/IV cartilage erosion along the caudal humeral head and glenoid; RF treatment was performed	Mild mononuclear inflammation (76% large mononuclear cells and 24% small mononuclear cells) Negative culture



Hill, German Shepherd, MI, 2 years

Ultrasonographic diagnoses:

- Right supraspinatus mineralisation and chronic tendinopathy
- Left sclerosing capsulitis with adhesions

What next?

Laser

Shock waves

Manual treatment



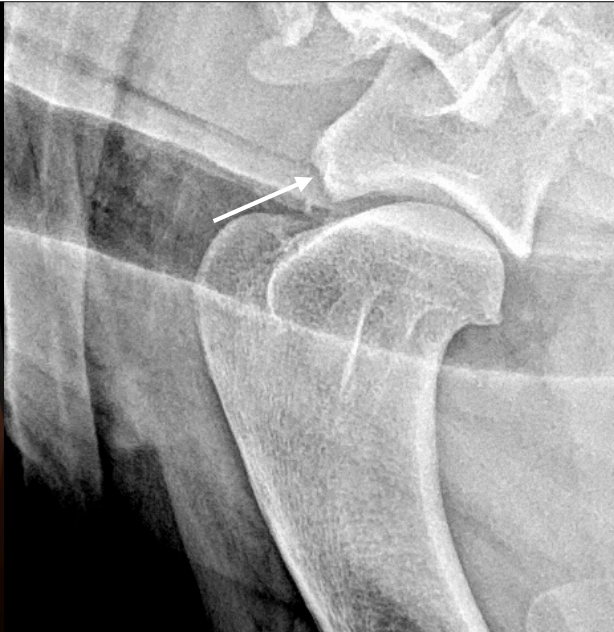Maky, Drahthaar, MI, 6 years

- Started to limp at the end of last hunter season
- Recovered
- After work, recurrent lameness when resting

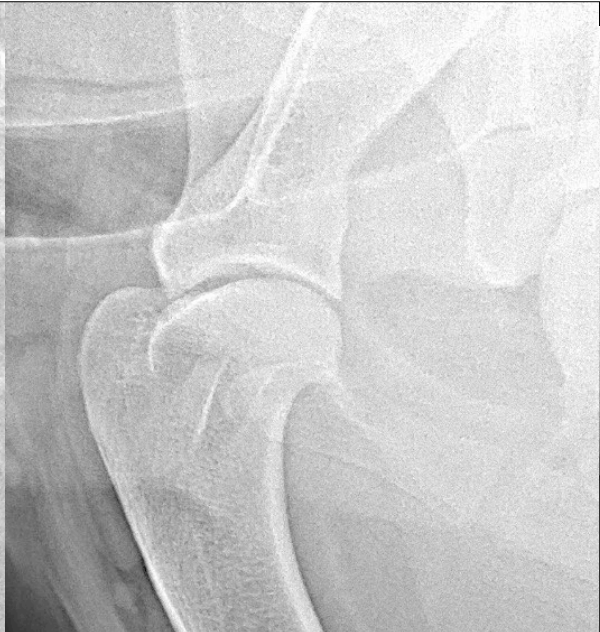

Maky, Drahthaar, MI, 6 years

- On physical examination pain on the extension of the right shoulder
- Increased right shoulder ROM

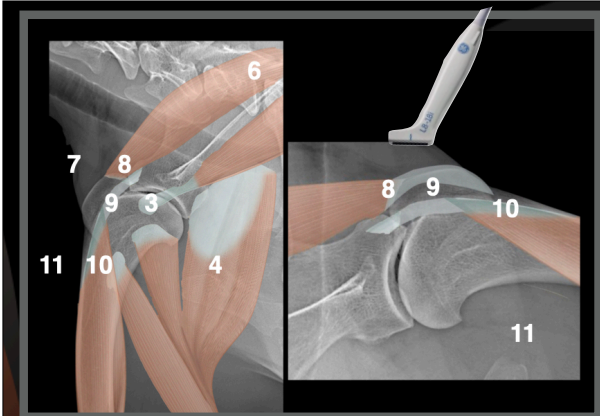


R



L



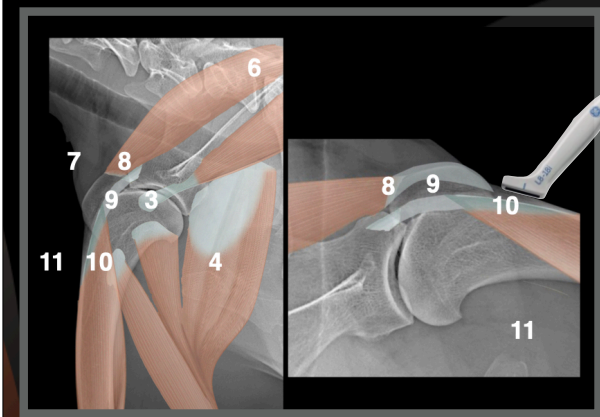
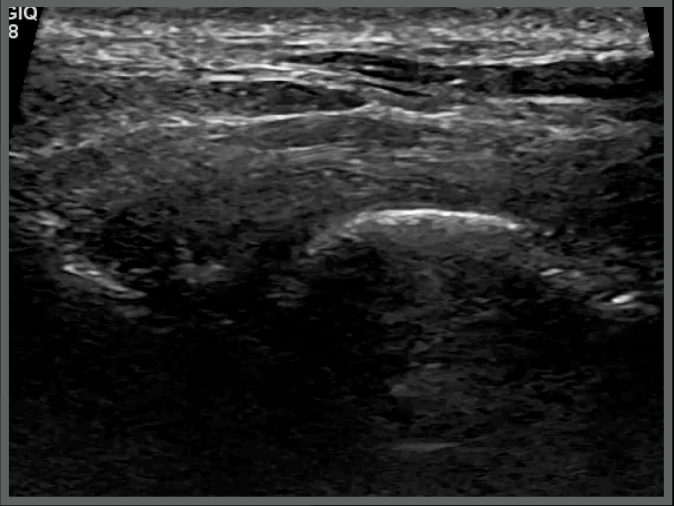
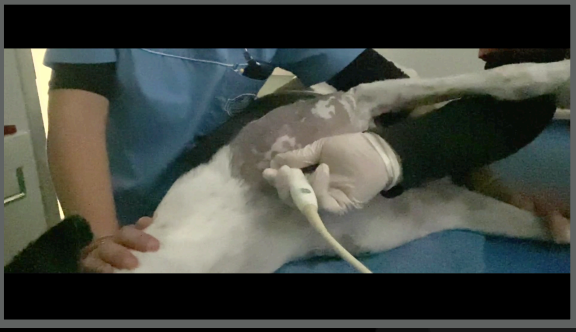


Maky, MI, 6 years

Right shoulder

BB longitudinal scan

9-10

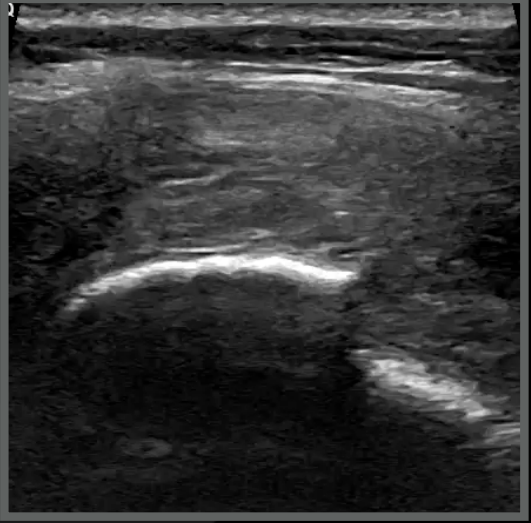
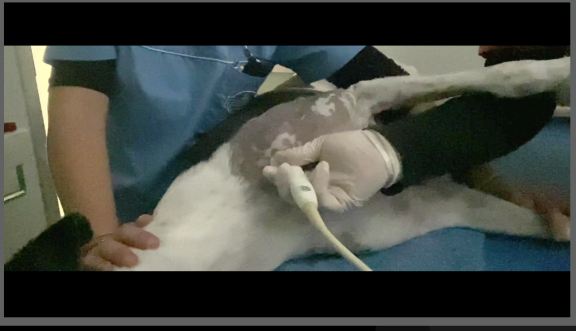


Maky, MI, 6 years

Right shoulder

BB longitudinal scan

10



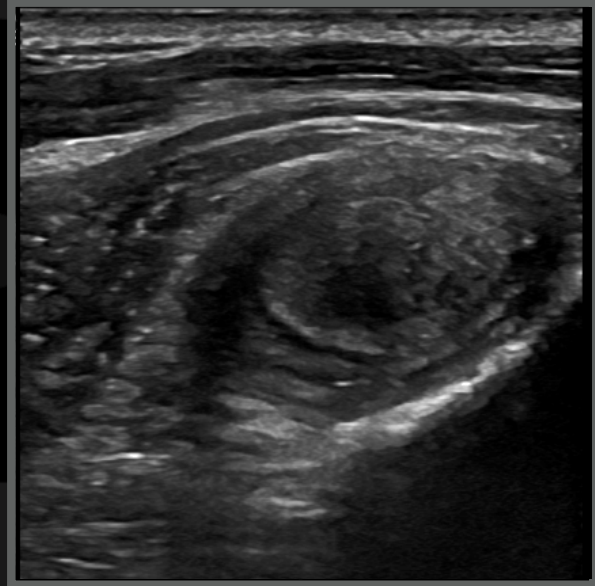
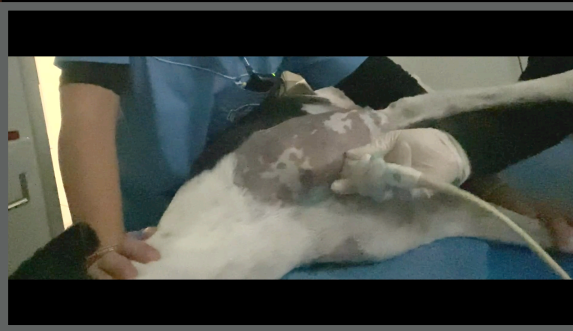
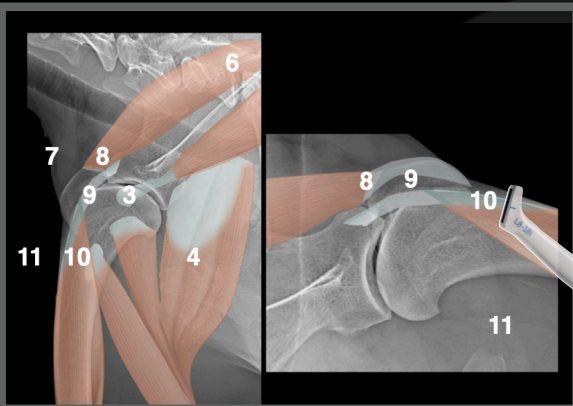
Maky, MI, 6 years

Right shoulder



BB trasverse scan

10



Maky, Drahthaar, MI, 6 years

Ultrasonographic diagnoses:

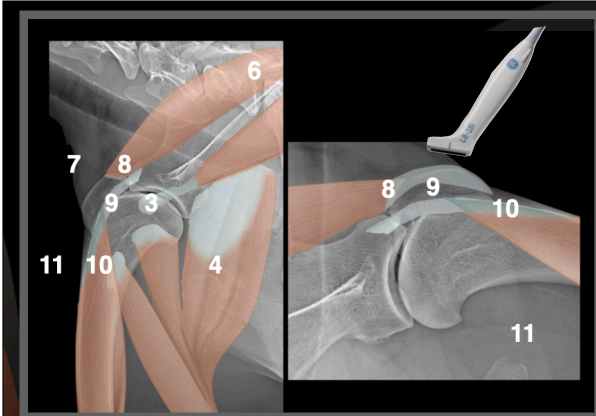
- Chronic and acute avulsion fracture of the right supraglenoid tubercle
- Partial right BB tendon avulsion
- Third degree tendinopathy right BB tendon

Conclusions

Consider right BB tendon resection

Consider consultation with a sport medicine specialist





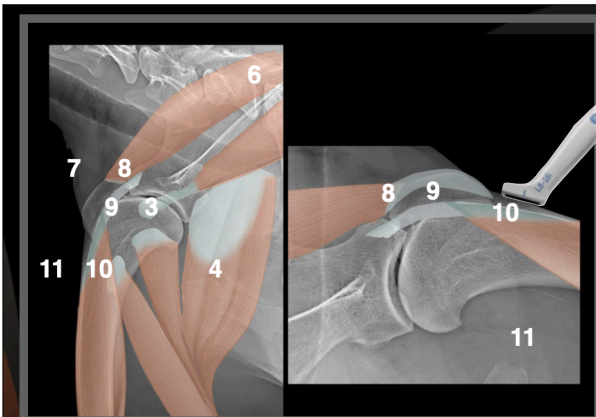
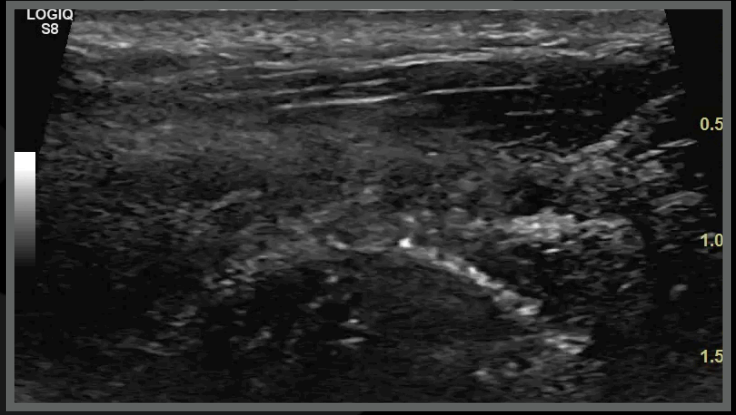
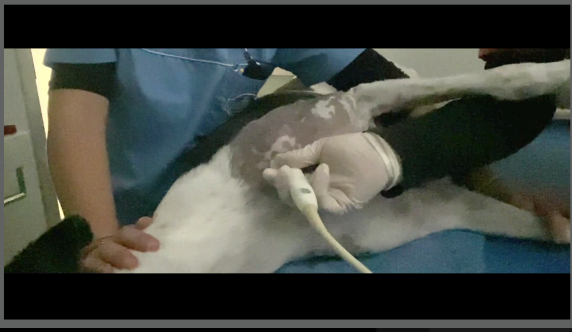
Maky, MI, 6 years

Right shoulder

Four months later

BB longitudinal scan

9



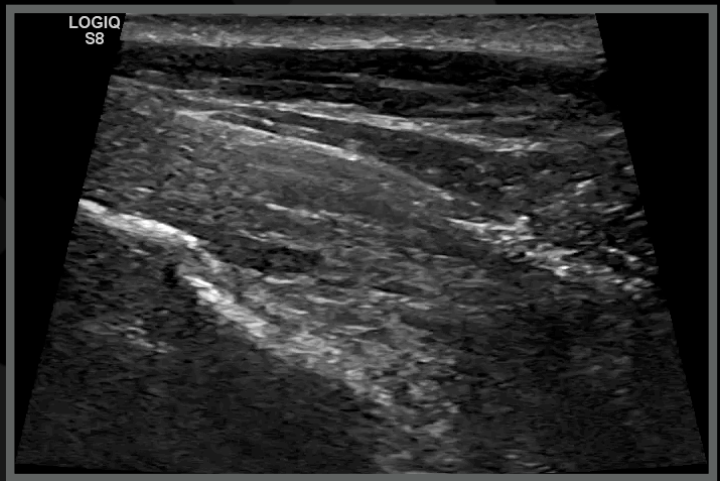
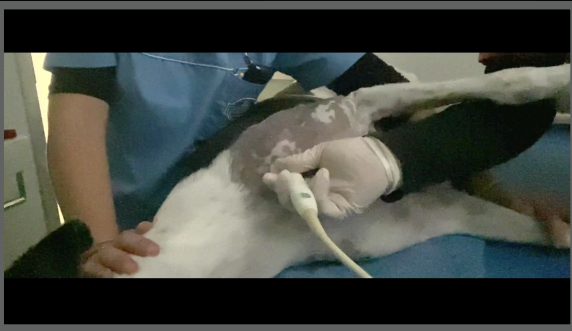
Maky, MI, 6 years

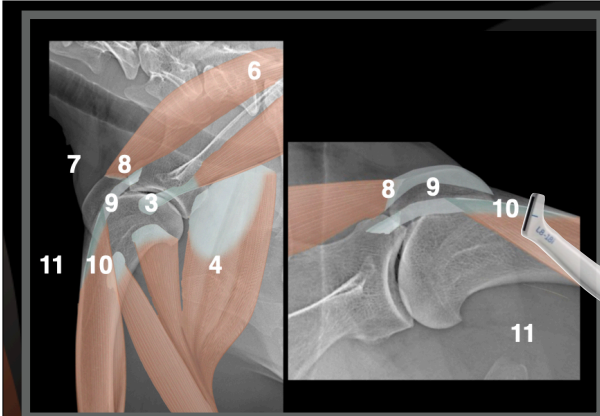
Right shoulder

Four months later

BB longitudinal scan

10





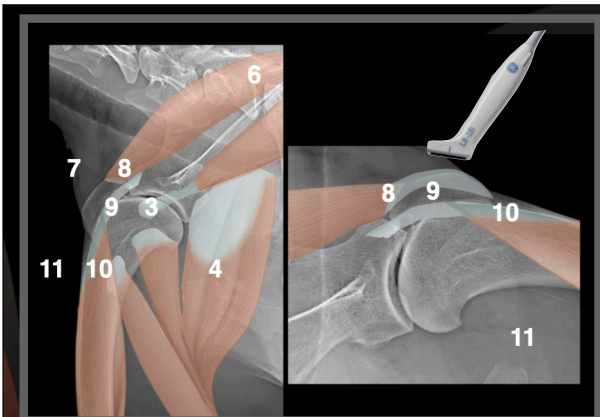
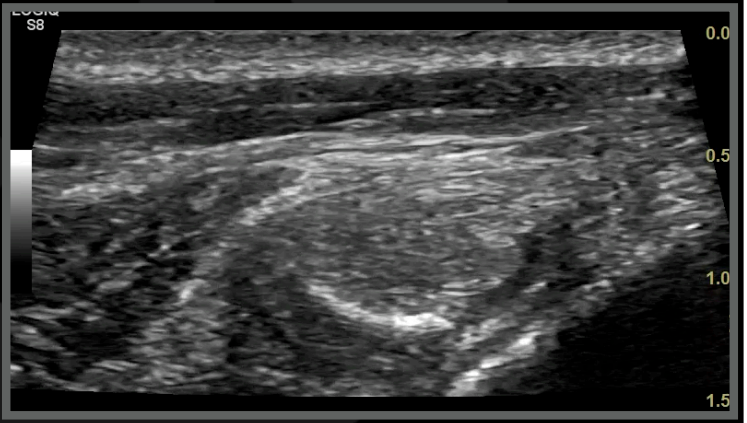
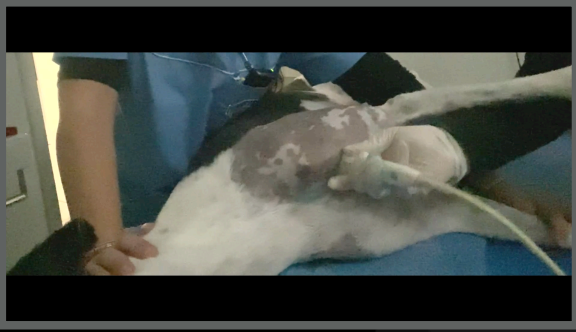
Maky, MI, 6 years

Right shoulder

Four months later

BB longitudinal scan

10



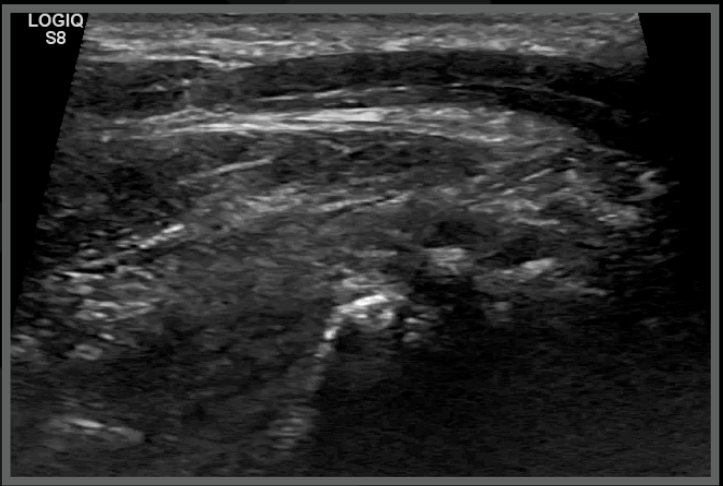
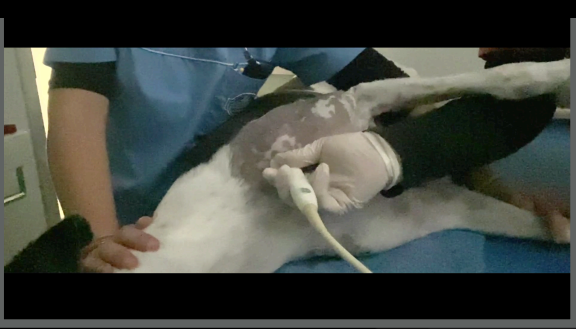
Maky, MI, 7 years

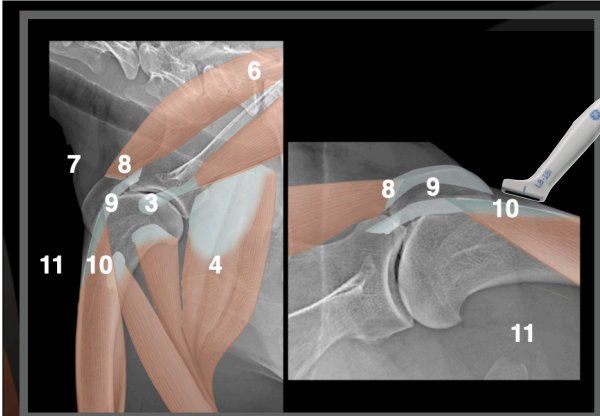
Right shoulder

One year later

BB longitudinal scan

9





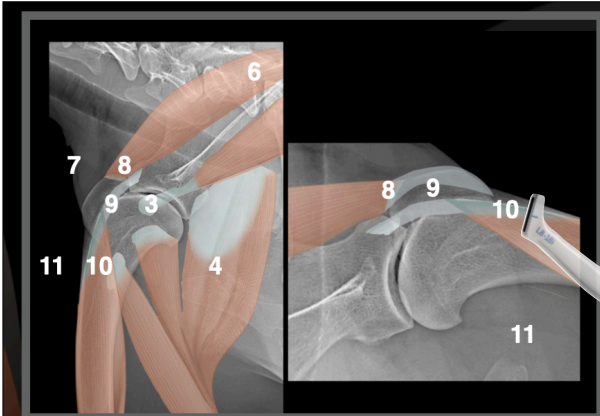
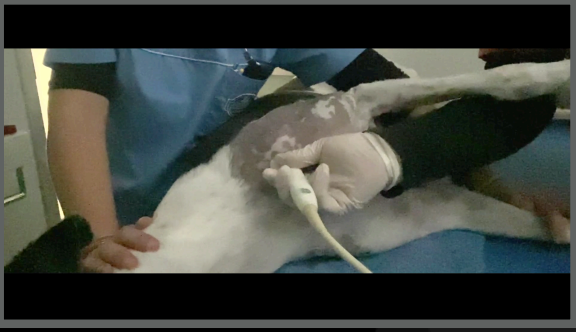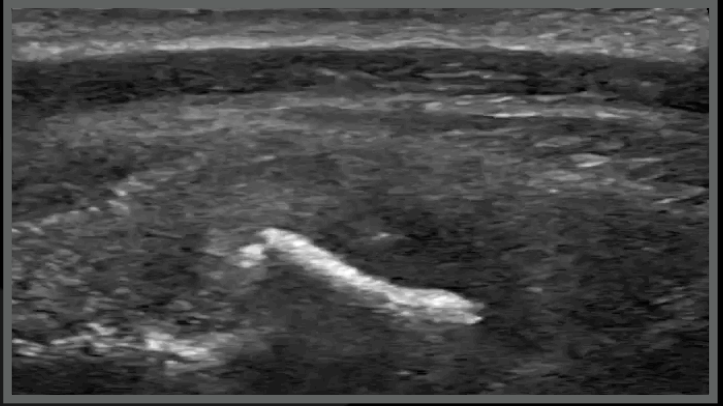
Maky, MI, 6 years

Right shoulder

One year later

BB longitudinal scan

9-10



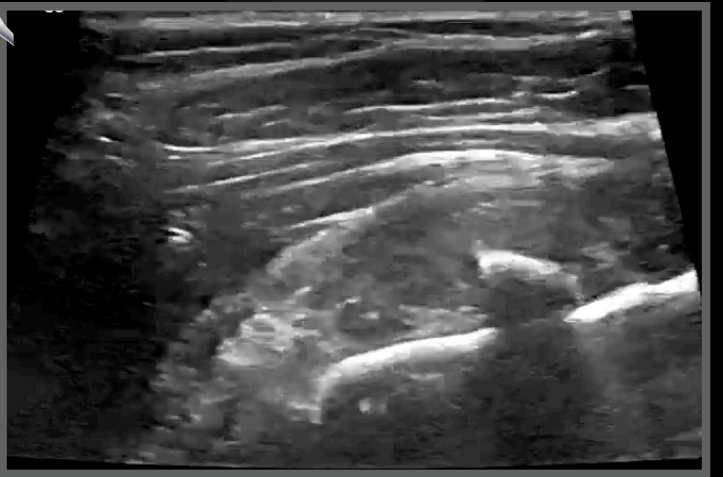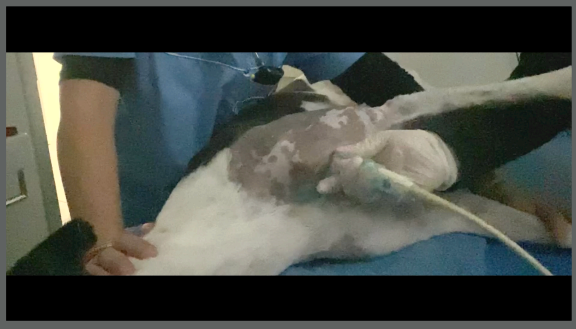
Maky, MI, 7 years

Right shoulder

One year later

BB trasverse scan

9-10



Maky, Drahthaar, MI, 6 years

Ultrasonographic diagnoses:

- Chronic third-degree tendinopathy BB tendon
- Tendinous mineralisation
- Moderate shoulder joint OA

Conclusions

He is doing fine

Follow up



Thank you



Diagnostic Mindset

www.diagnosticmindset.com