


Morpho-functional approach of shoulder and elbow ultrasound in 12 scan planes

Supraspinatus-Biceps-Subscapularis

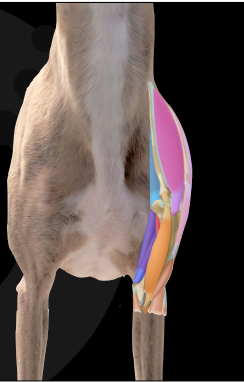Giliola Spattini
DVM, GP Cardio, CCRT, PhD, DECVI



Thank to www.inajos.com

Gross anatomy of the shoulder

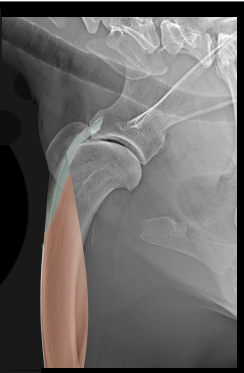
- Deltoides
- **Infraspinatus**
- Teres Major
- Triceps
- Supraspinatus
- **Biceps Brachii**
- Subscapularis



www.inajos.com

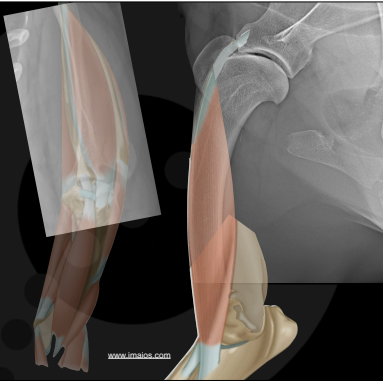
The biceps muscle

- A weak medial stabiliser of the shoulder
- Connect shoulder and elbow

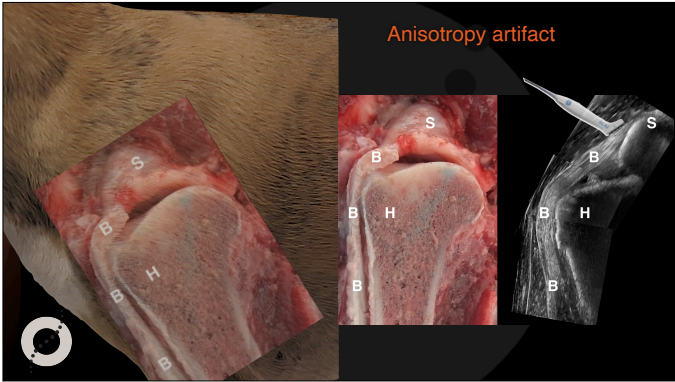


The biceps muscle

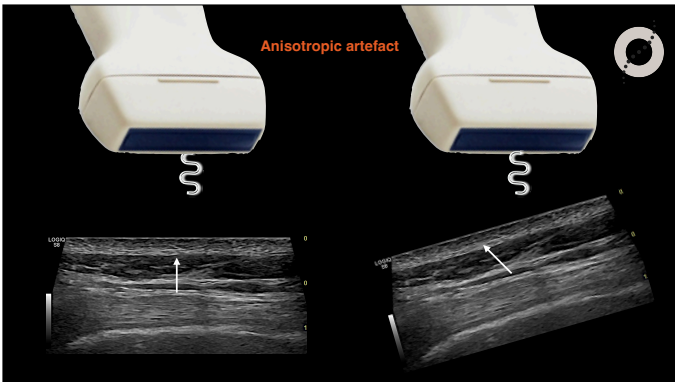
- Connect shoulder and elbow
- Flex the elbow and extend the shoulder



Anisotropy artifact



Anisotropic artefact



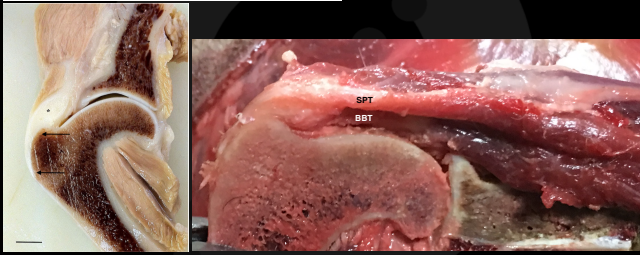
Ultrasound of the normal canine supraspinatus tendon: comparison with gross anatomy and histology

Caroline Oloé Lassaigne · Charlotte Boyer · Lucile Sautier · Olivier Tammans

Veterinary Record (2019) doi:10.1136/vetrec-2019-105552

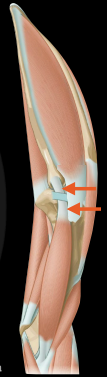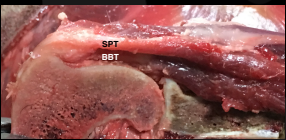Supraspinatus tendon sustains 4,6 times the patient body weight during trot

There are few nervous terminations



Chronic supraspinatus tendinopathy in sportive dogs

- Repetitive traumas results in hemorrhages that mineralise
- The patient is usually asymptomatic but the tendon diameter increases
- The end result is an impingement syndrome on the adjacent biceps tendon



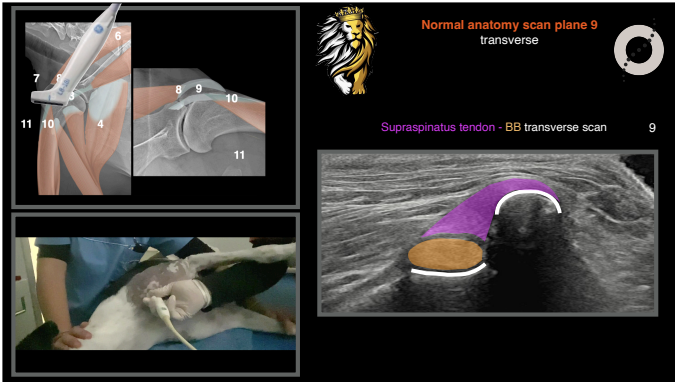
www.imaios.com

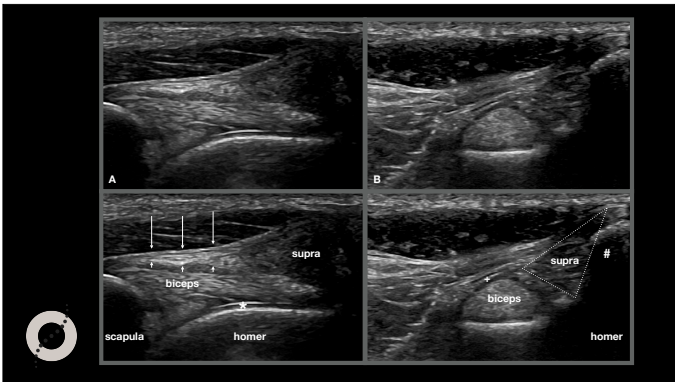
Normal anatomy scan plane 9 longitudinal

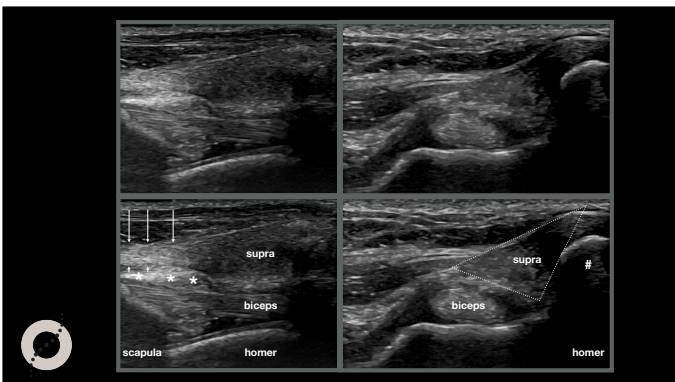
Supraspinatus tendon - BB longitudinal scan 9

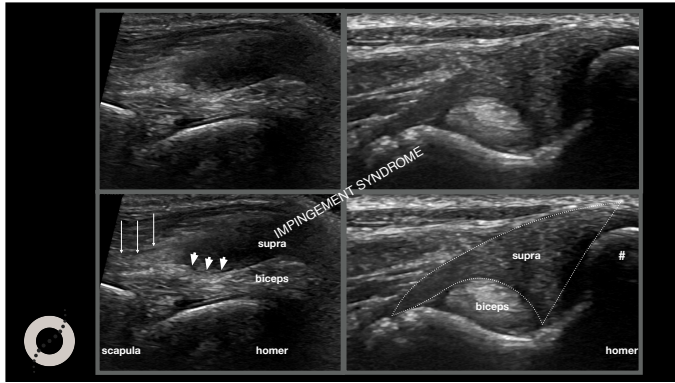
SPAT

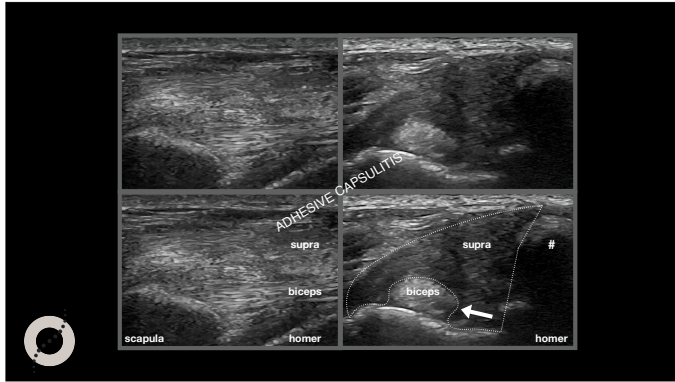
BB *

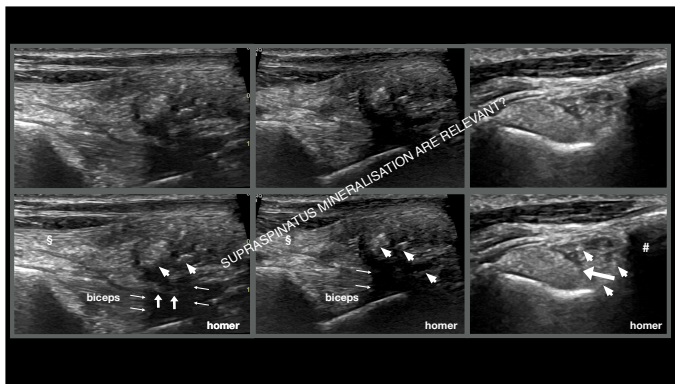








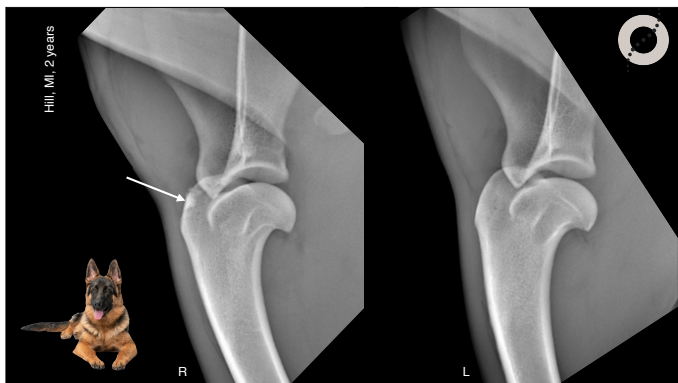


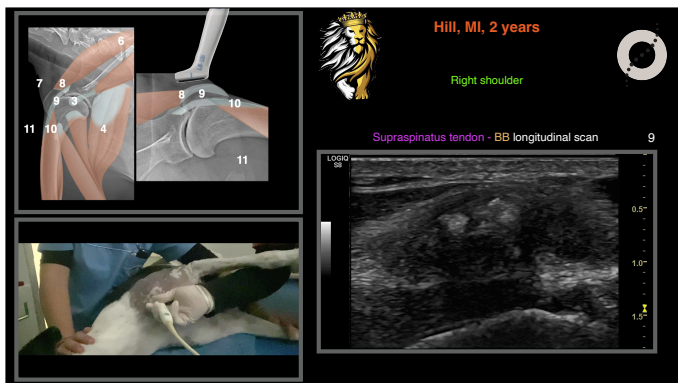


Hill, German Shepherd, MI, 2 years

- Left front lameness from 2 weeks
- Last year right front lameness
- Doesn't respond to NSAID







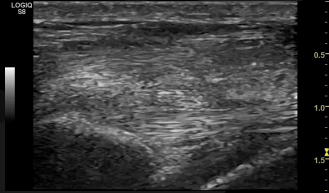
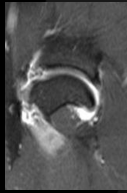
Adhesive Capsulitis in Eight Dogs: Diagnosis and Management.

Carr BJ, Canapp SO, Canapp DA, Gamble LJ, Dycus DL.

Front Vet Sci. 2016 Jul 14;3:55. doi: 10.3389/fvets.2016.00055. eCollection 2016.

PMID: 27471728 **Free PMC Article**

Patient	Histopathology	Ultrasonography	MR	Arthroscopy	Cytology and histopathology
1	Normal	Supraspinatus deviation; bilateral tendon sheath effusion	Minimal joint effusion and no obvious damage to the supraspinatus tendon and no major joint capsule changes	Stable tendinopathy; no management of the biceps tendon; tearing and disruption of the subscapularis and of the MCL; disruption of joint capsule grade III/IV cartilage erosion along the caudal humeral head and greater tuberosity (not seen in any other dog)	Microcrystalline effusion; 91% large mononuclear cells and 24% small mononuclear cells Negative culture



Hill, German Shepherd, MI, 2 years

Ultrasonographic diagnoses:

- Right supraspinatus mineralisation and chronic tendinopathy
- Left sclerosing capsulitis with adhesions

What next?

- Laser
- Shock waves
- Manual treatment



Maky, Drahthaar, MI, 6 years

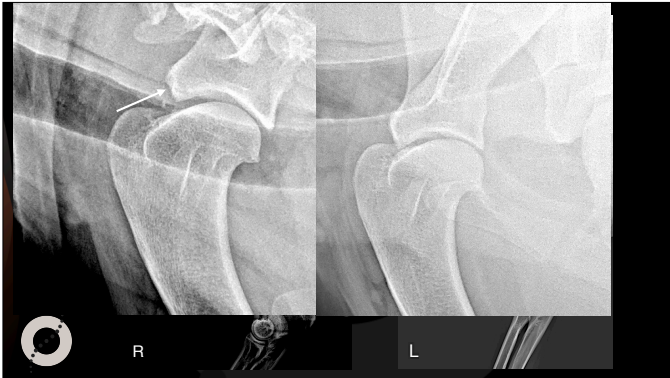- Started to limp at the end of last hunter season
- Recovered
- After work, recurrent lameness when resting

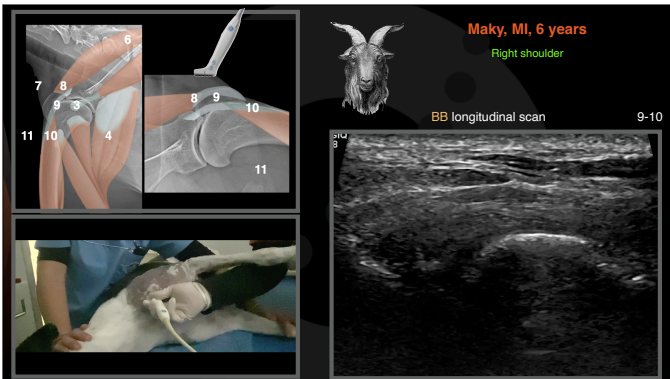


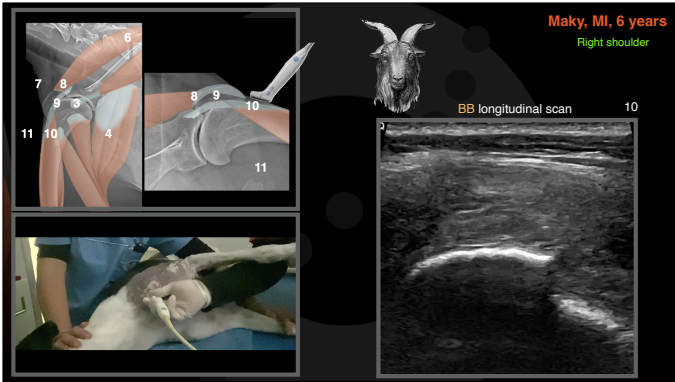
Maky, Drahthaar, MI, 6 years

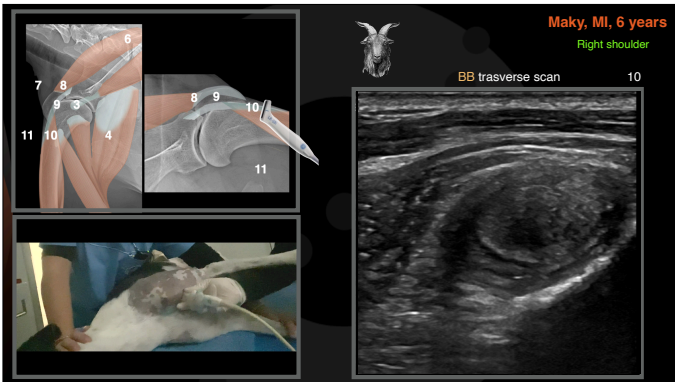
- On physical examination pain on the extension of the right shoulder
- Increased right shoulder ROM











Maky, Drahthaar, MI, 6 years

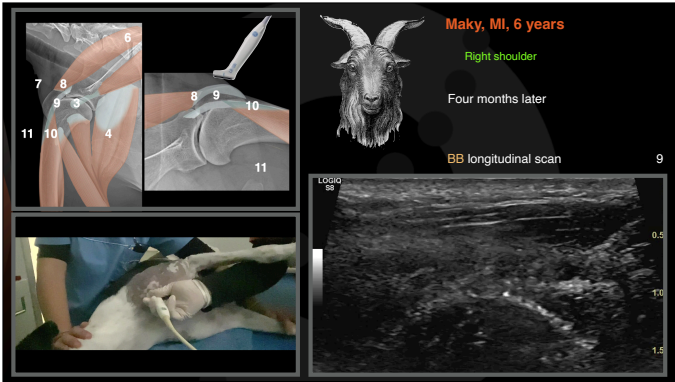
Ultrasonographic diagnoses:

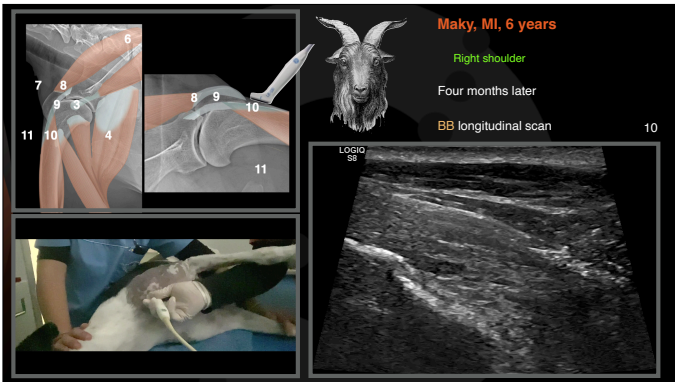
- Chronic and acute avulsion fracture of the right supraglenoid tubercle
- Partial right BB tendon avulsion
- Third degree tendinopathy right BB tendon

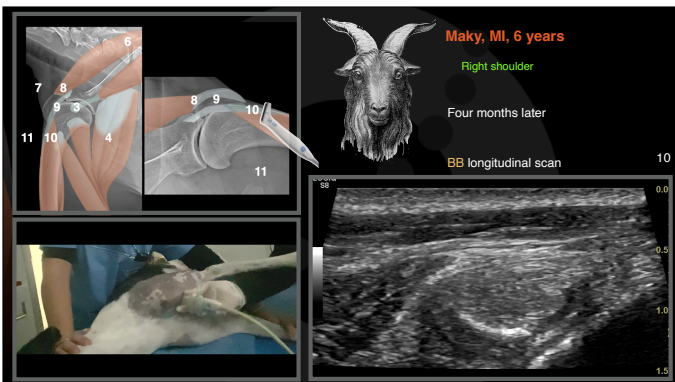
Conclusions

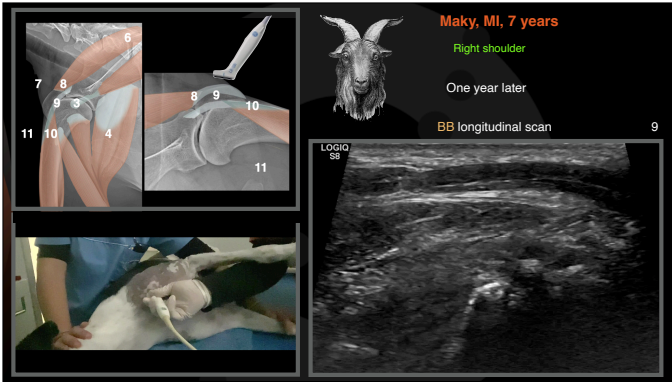
Consider right BB tendon resection

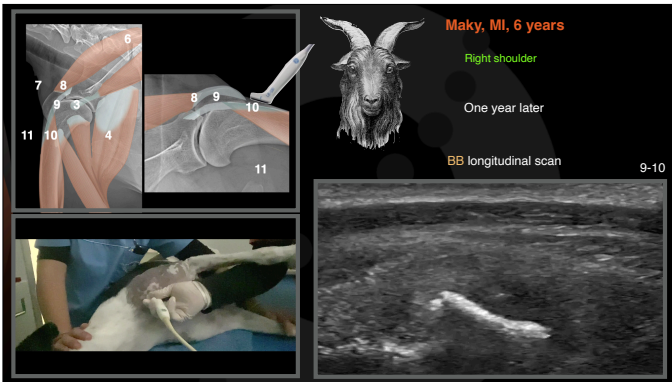
Consider consultation with a sport medicine specialist

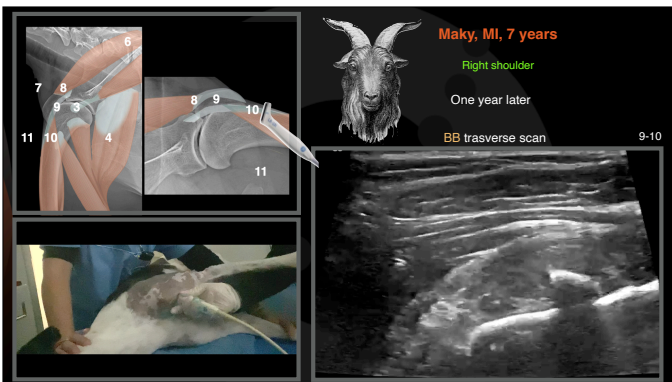












Maky, Drahthaar, MI, 6 years

Ultrasonographic diagnoses:

- Chronic third-degree tendinopathy BB tendon
- Tendinous mineralisation
- Moderate shoulder joint OA



Conclusions

He is doing fine

Follow up

Thank you



Diagnostic Mindset

www.diagnosticmindset.com
