


Canine Sports Medicine MSK Ultrasonography - The Forelimb

THE ULTRASOUND EXAMINATION OF THE HIP AND THIGH



Gabriele Barella

gabriele.barella@gmail.com

DVM, PhD, MSc

Milan - Italy

Espoo - Finland April 2024



LITERATURE

DEVELOPING A TECHNIQUE FOR ULTRASOUND-GUIDED INJECTION OF THE ADULT CANINE HIP

CHIARA BERGAMINO, ANNE-LAURE ETIENNE, VALERIA BUSONI

Vet Radiol Ultrasound, Vol. 56, No. 4, 2015, pp 456–461.

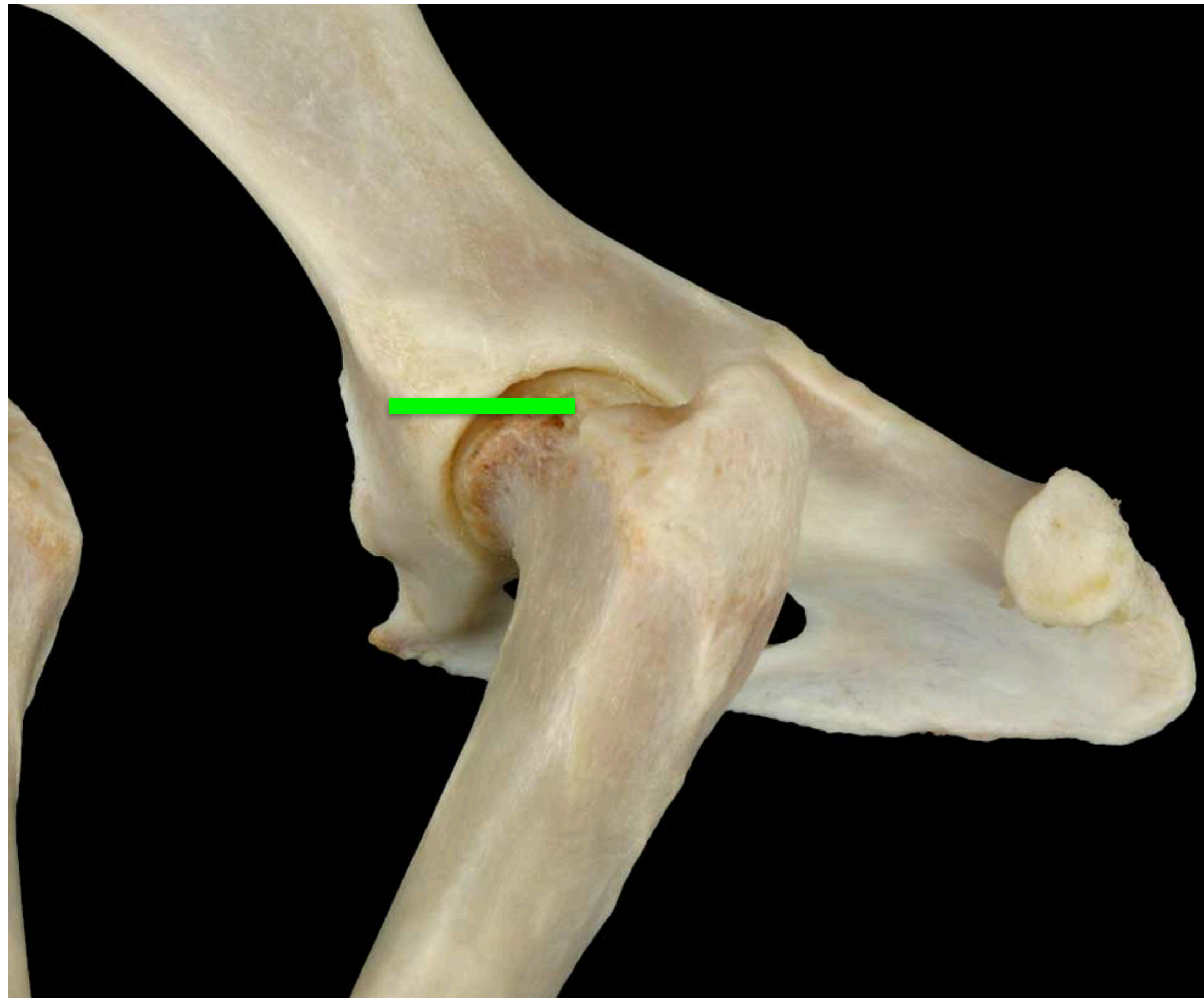
Static and dynamic ultrasonography for the early diagnosis of canine hip dysplasia

A. FISCHER, A. FLÖCK, B. TELLHELM,
K. FAILING, M. KRAMER AND C. THIEL

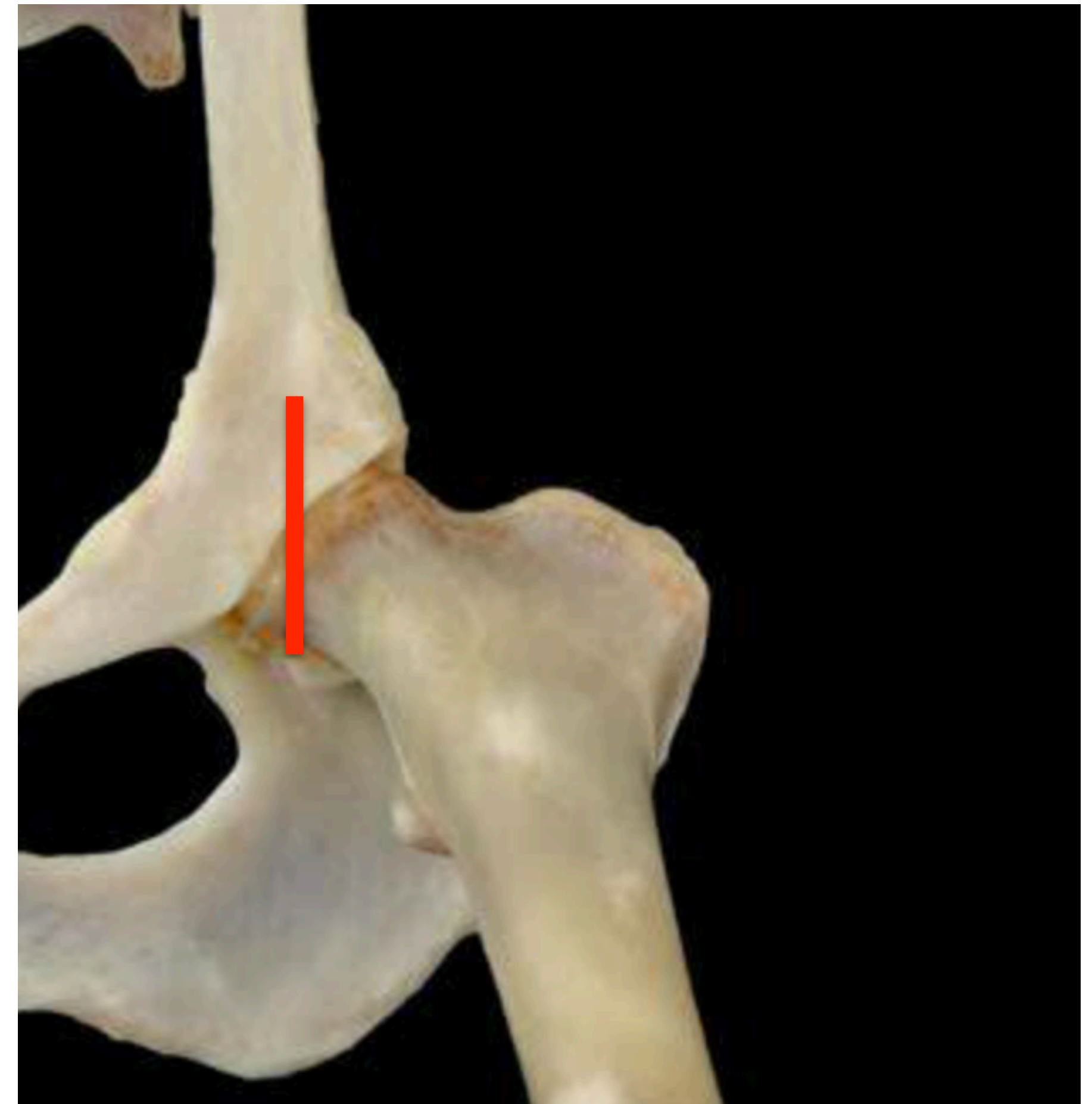Journal of Small Animal Practice (2010)
51, 582–588

CLINICAL SIGNIFICANCE: Results of our study suggest that static and dynamic ultrasonography of hip joints in puppies between 16 and 49 days of age is technically feasible but cannot be recommended for detecting puppies that will develop CHD between the ages of 12 and 24 months.

HIP JOINT

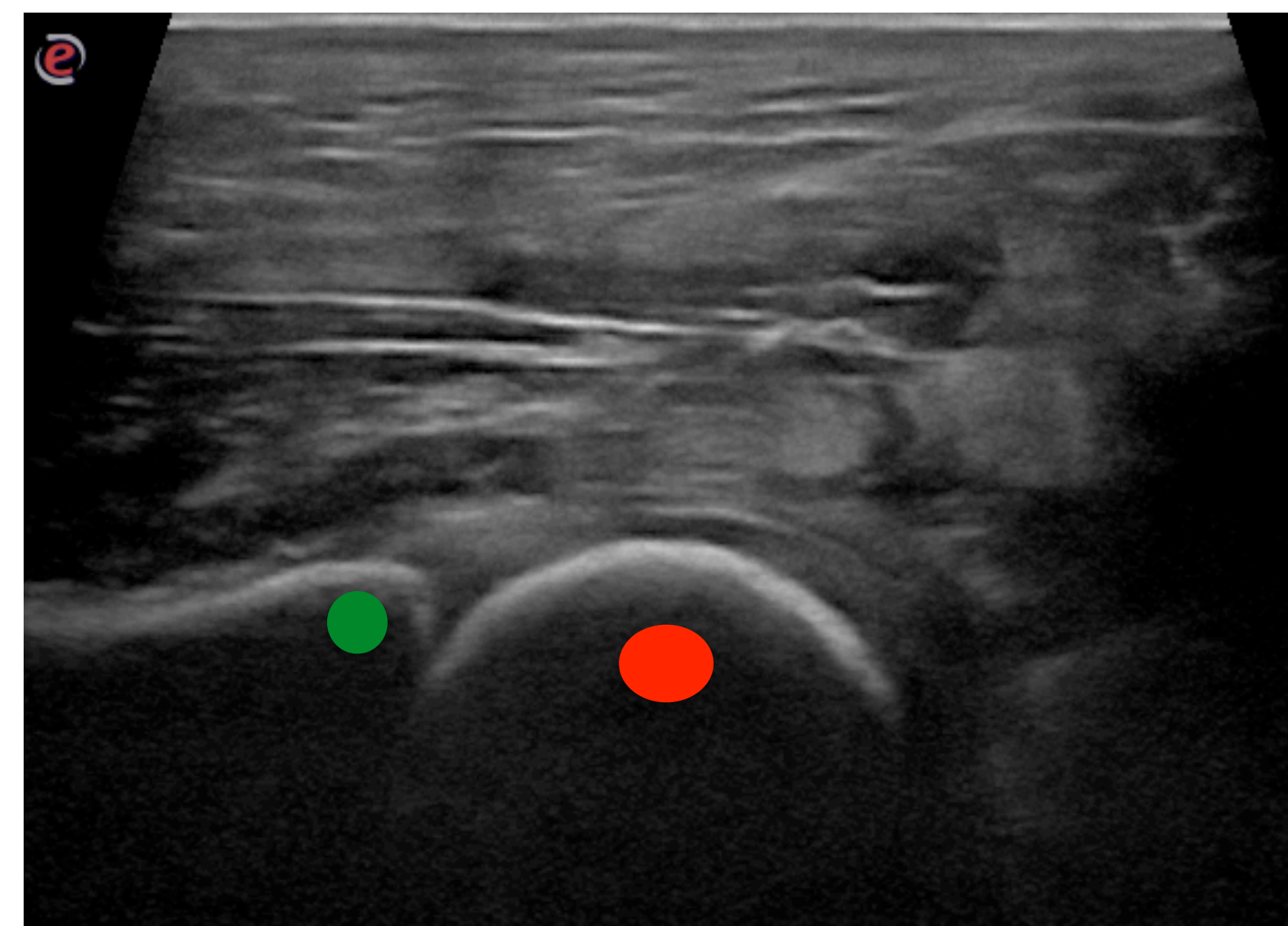
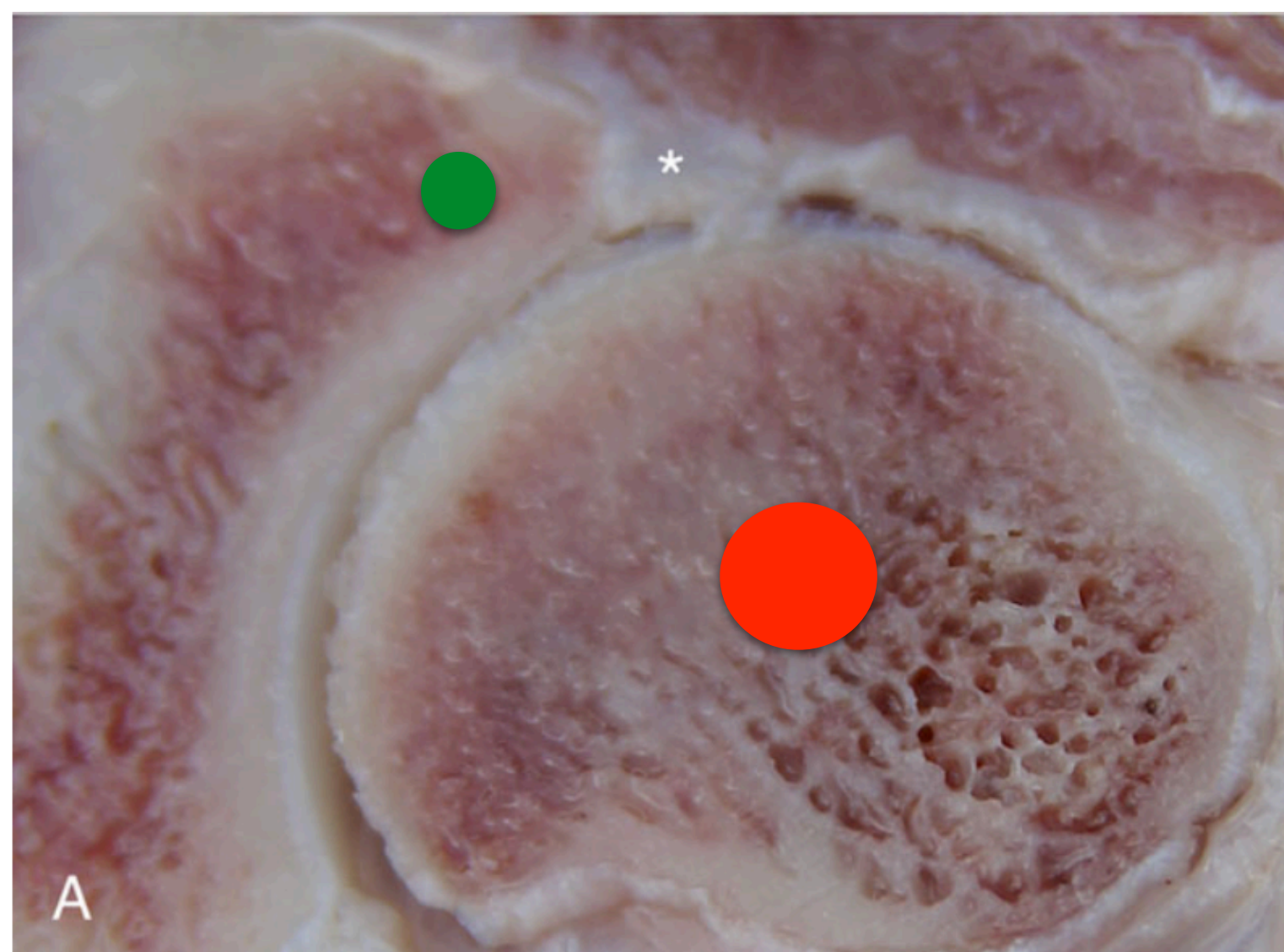
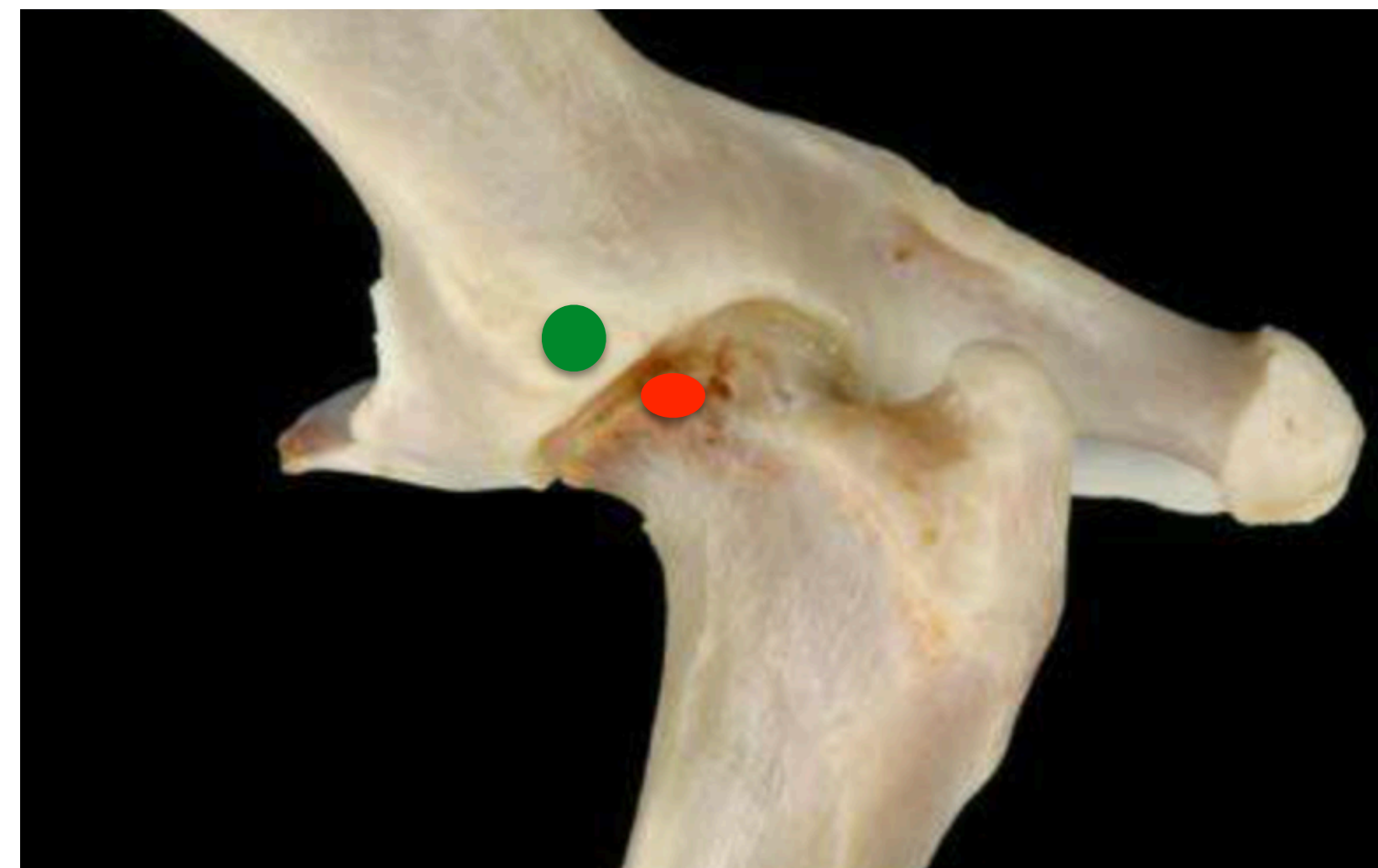
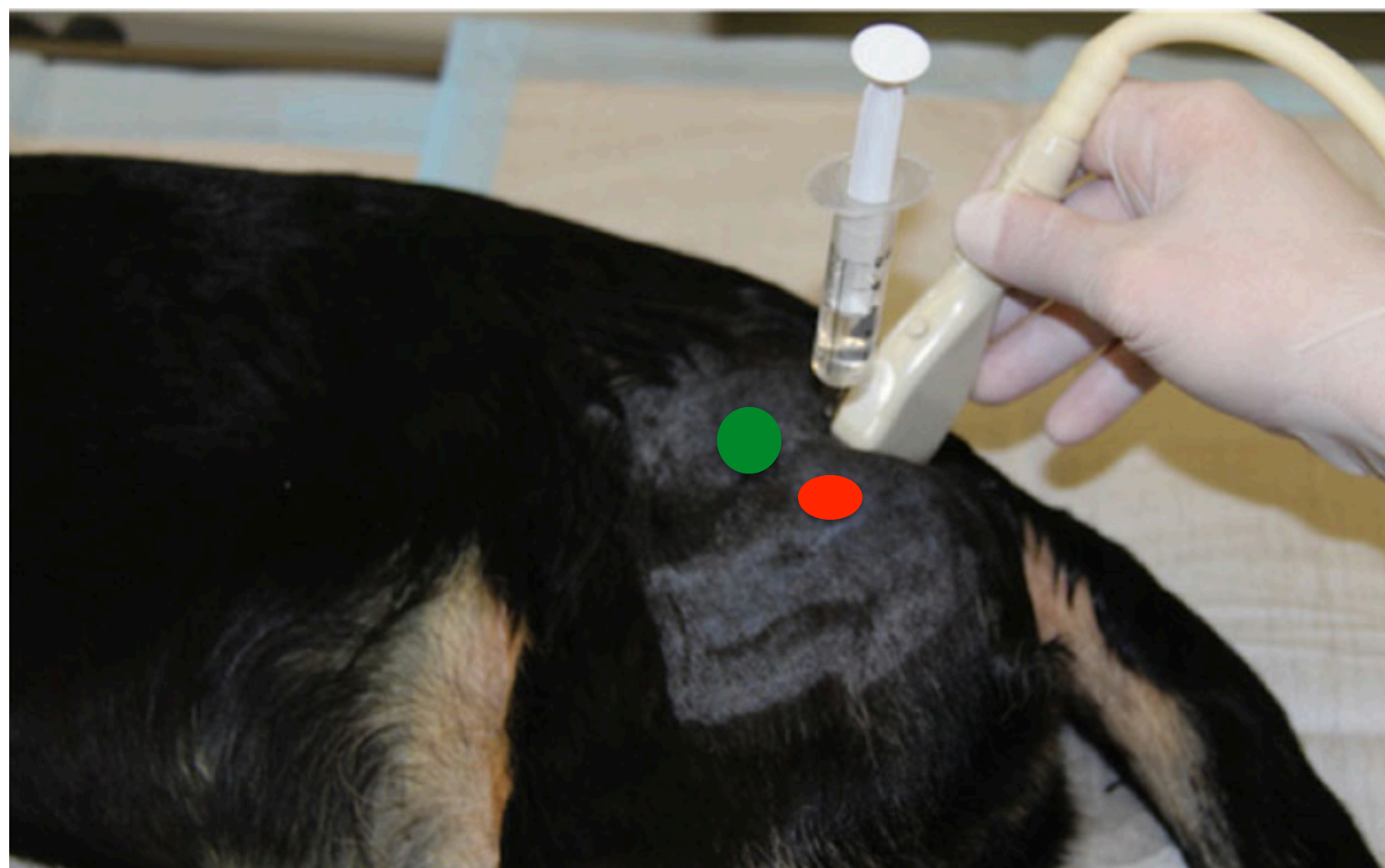

Lateral recumbency
Dorsal scan

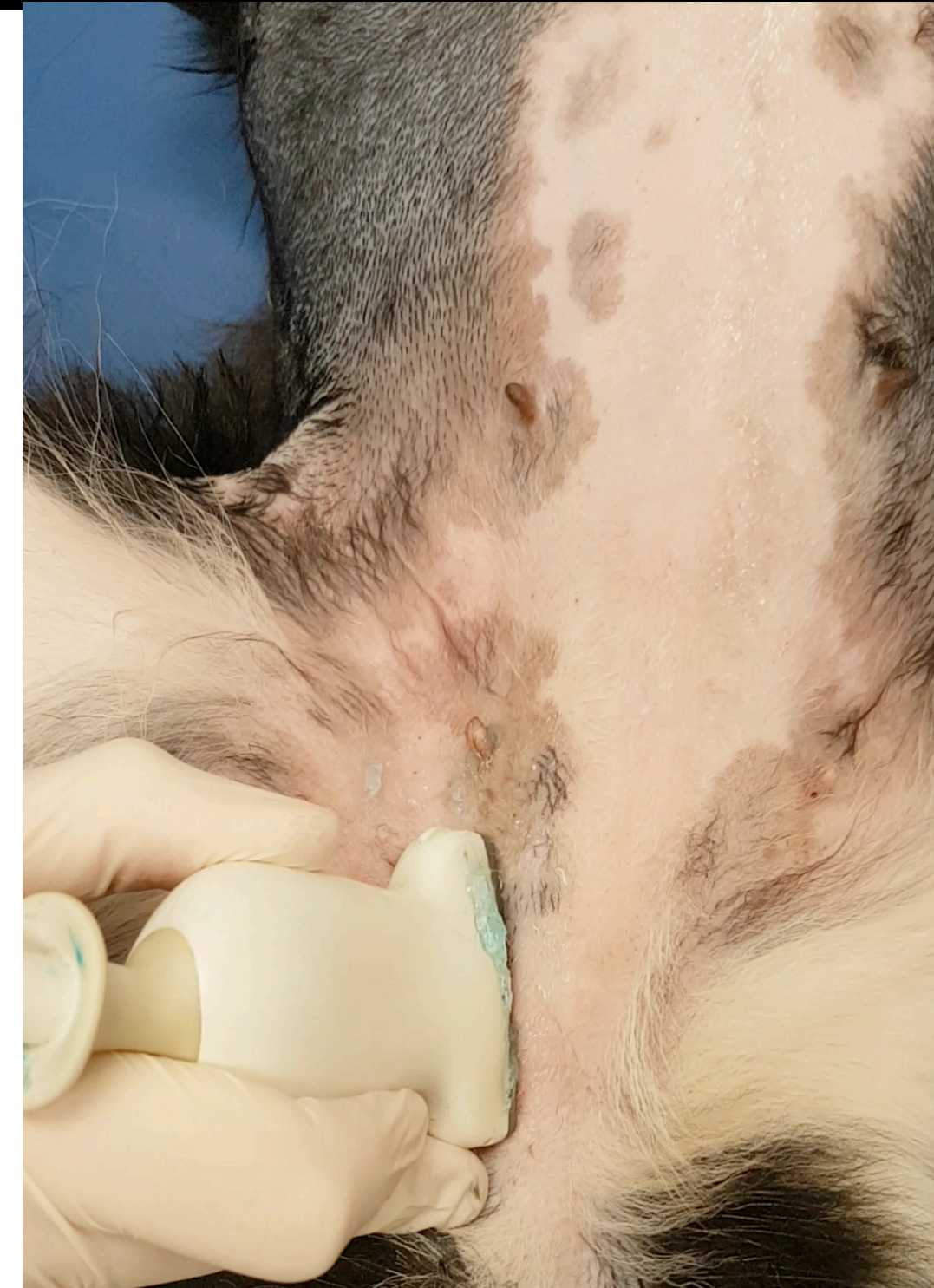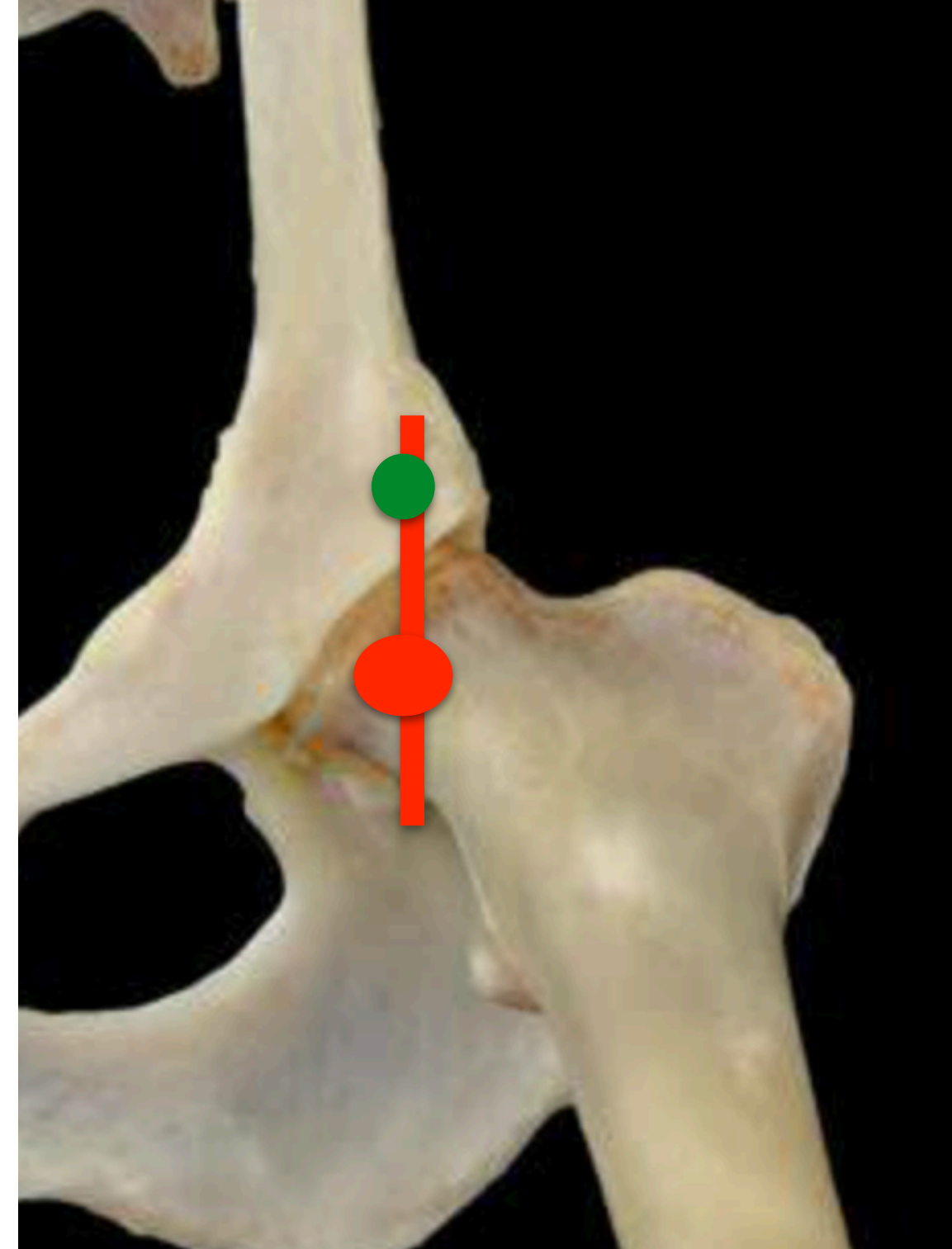
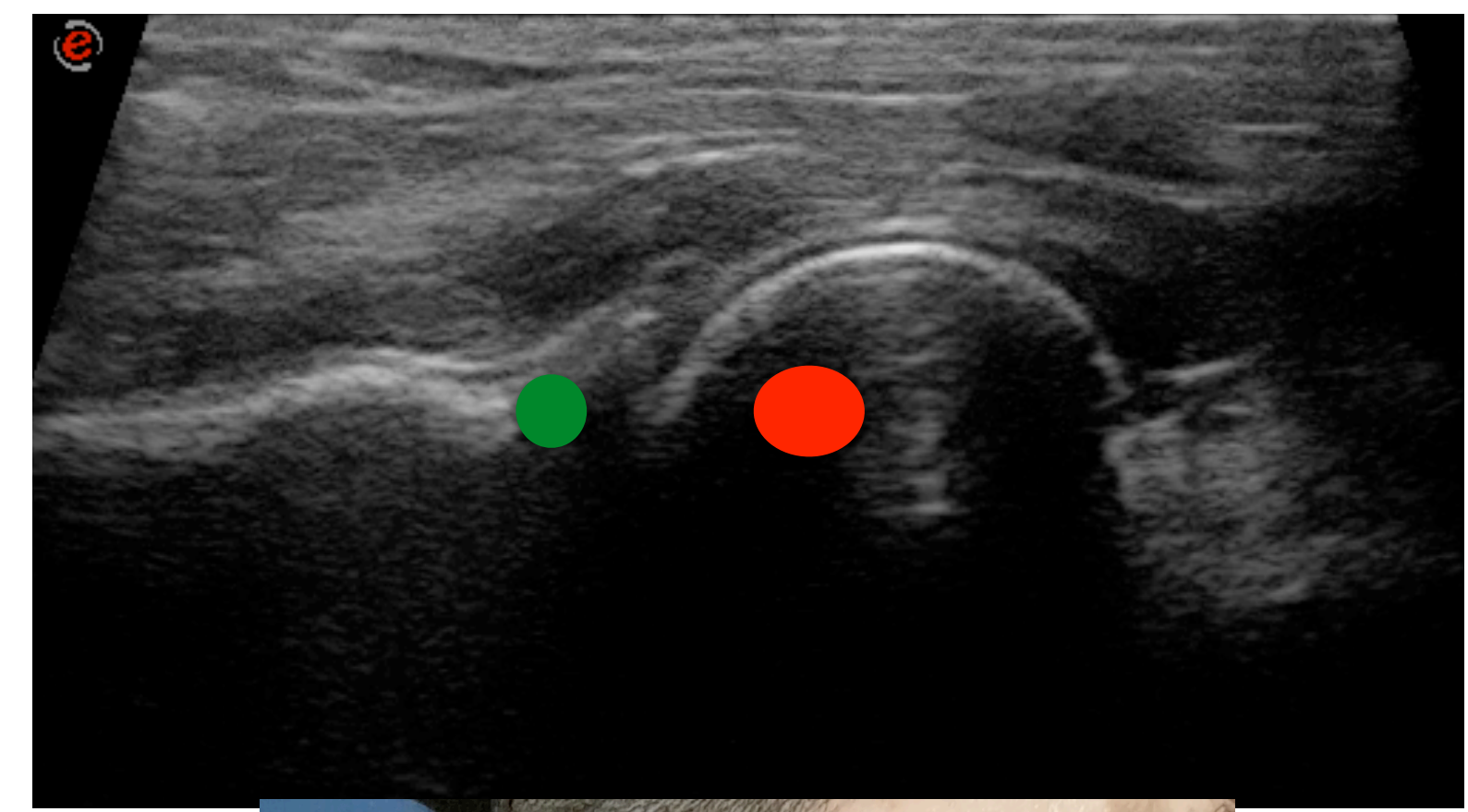
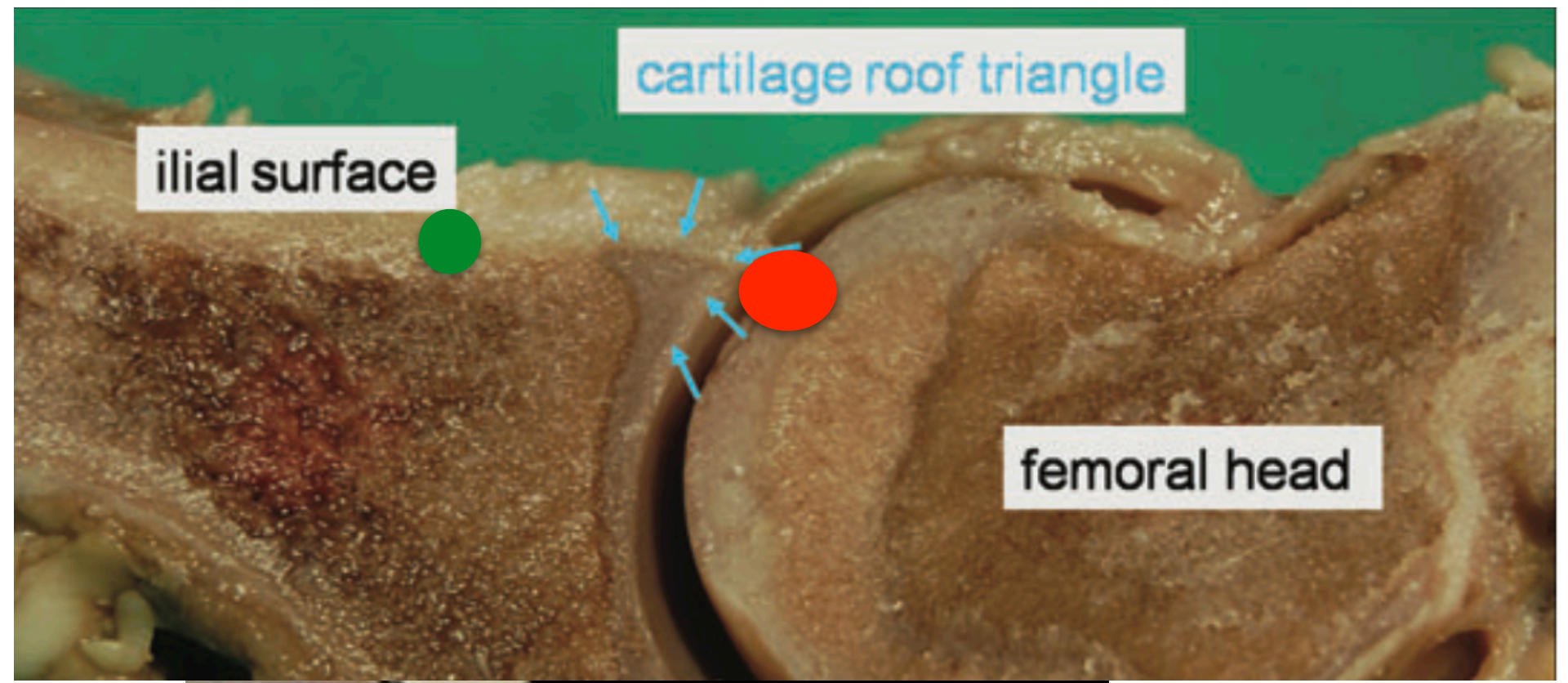


Dorsal recumbency
Ventral scan

US TECHNIQUE - DORSAL SCAN



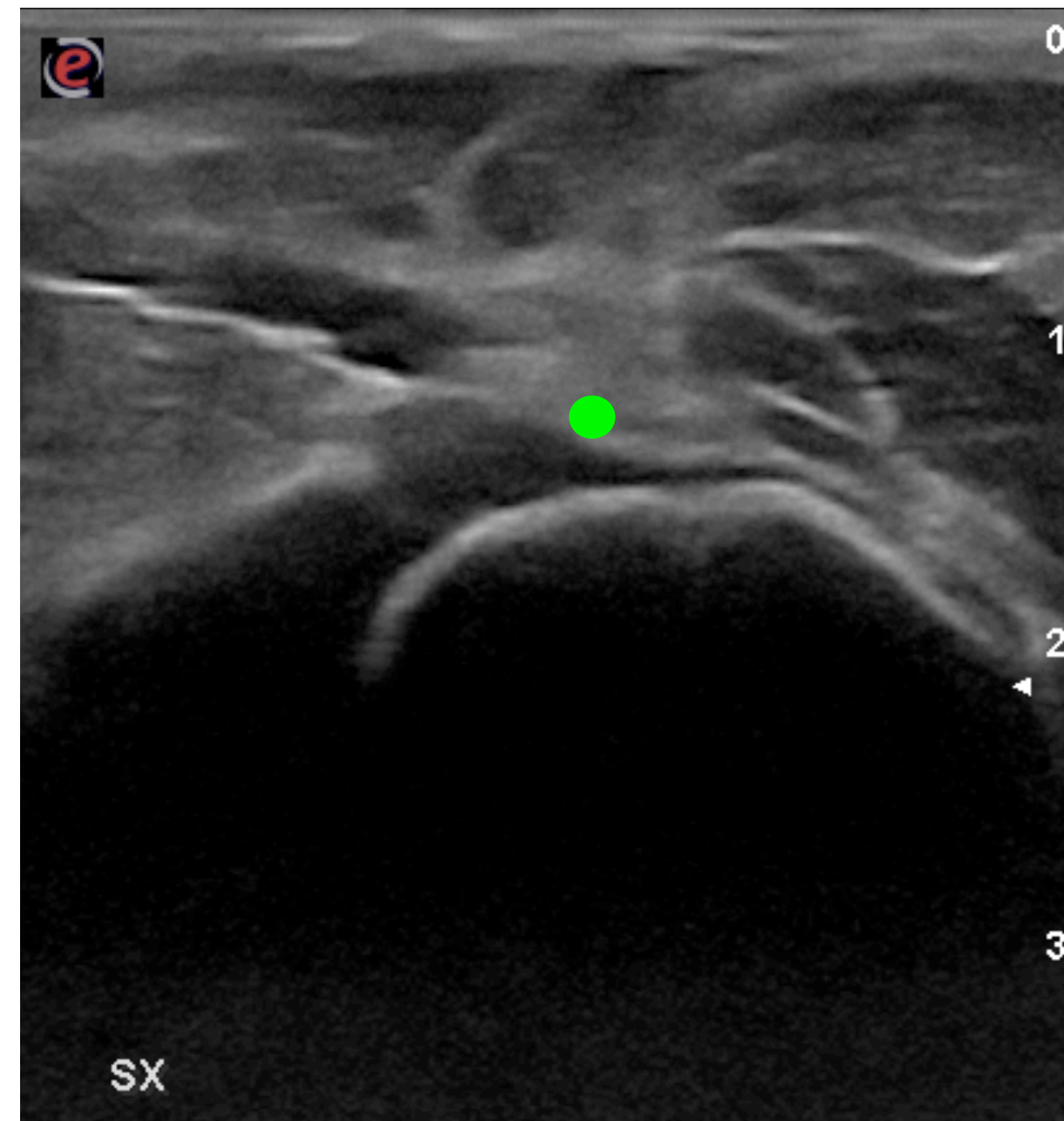
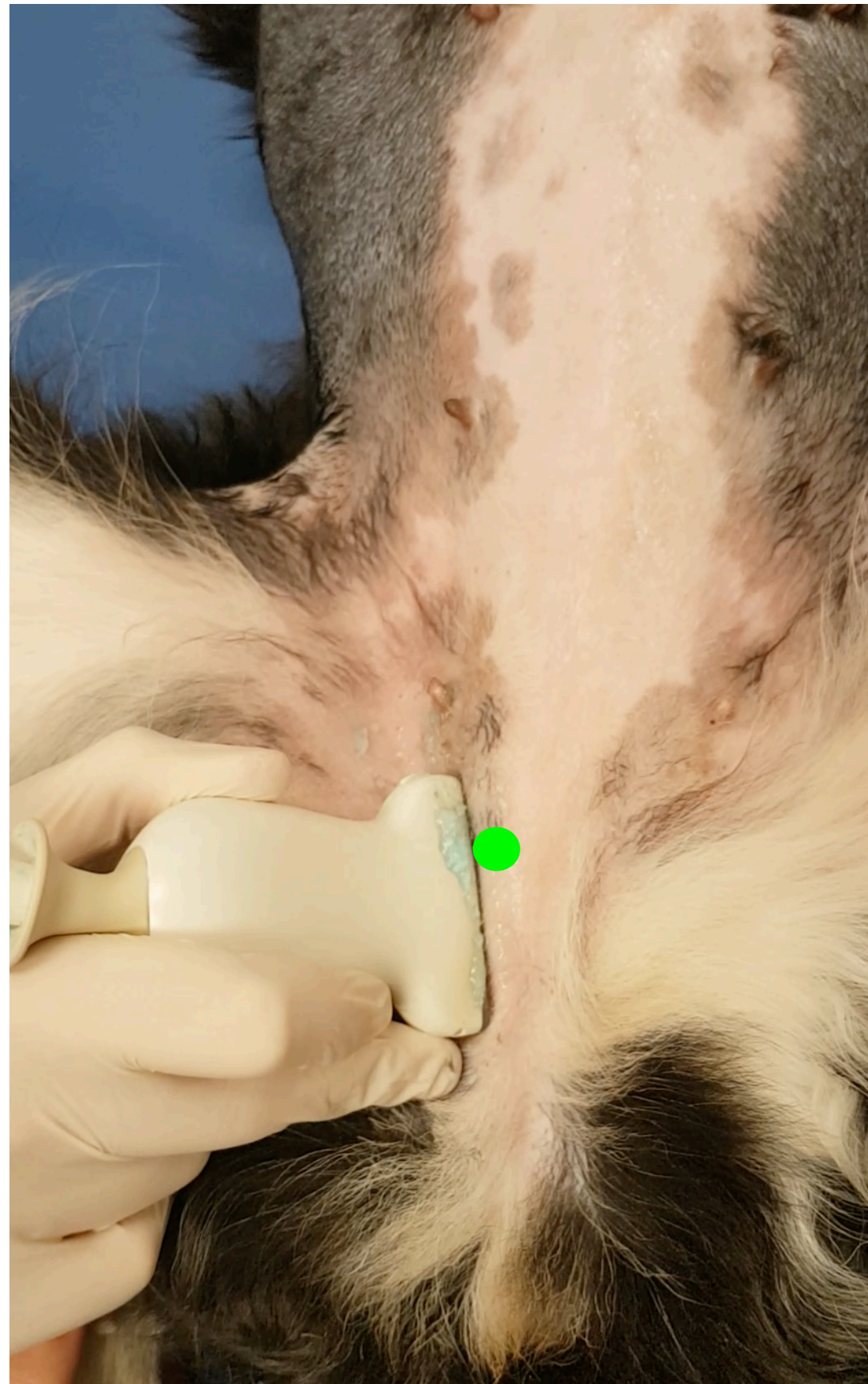
US TECHNIQUE - VENTRAL SCAN



SEPTIC ATHROSYNOVITIS

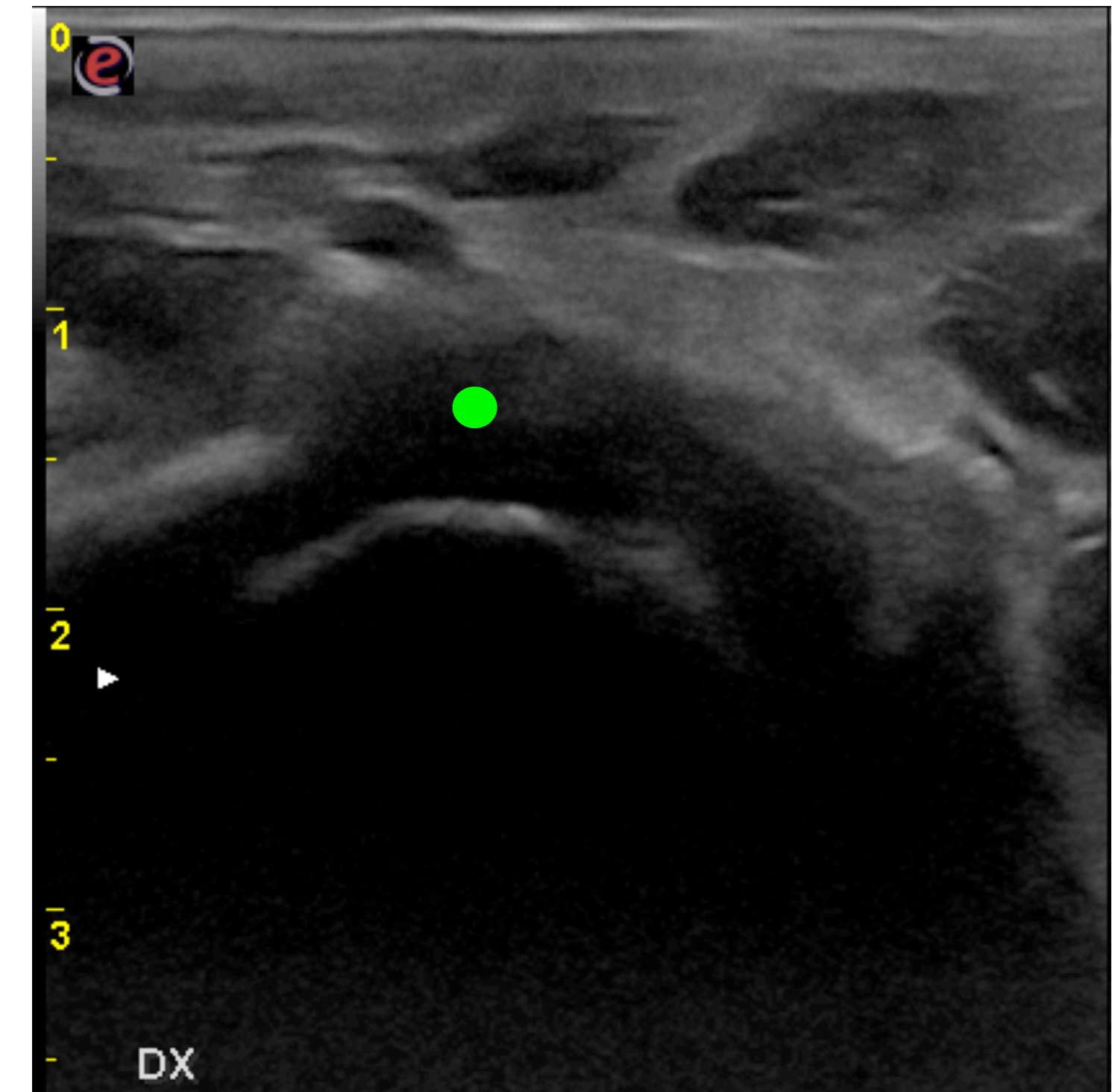
NORMAL ANATOMY

Longitudinal Plan
Ventral scan

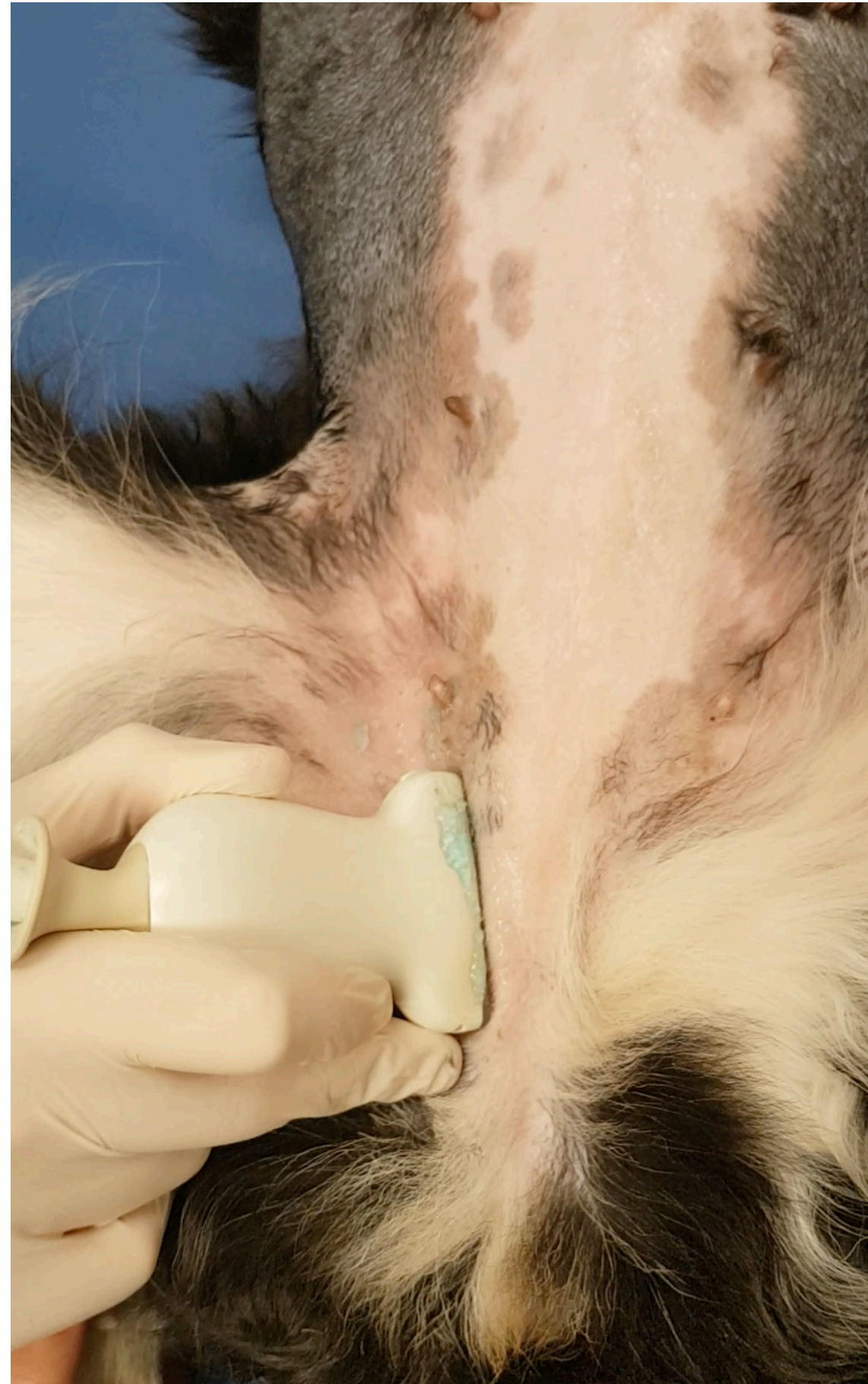


OSCAR

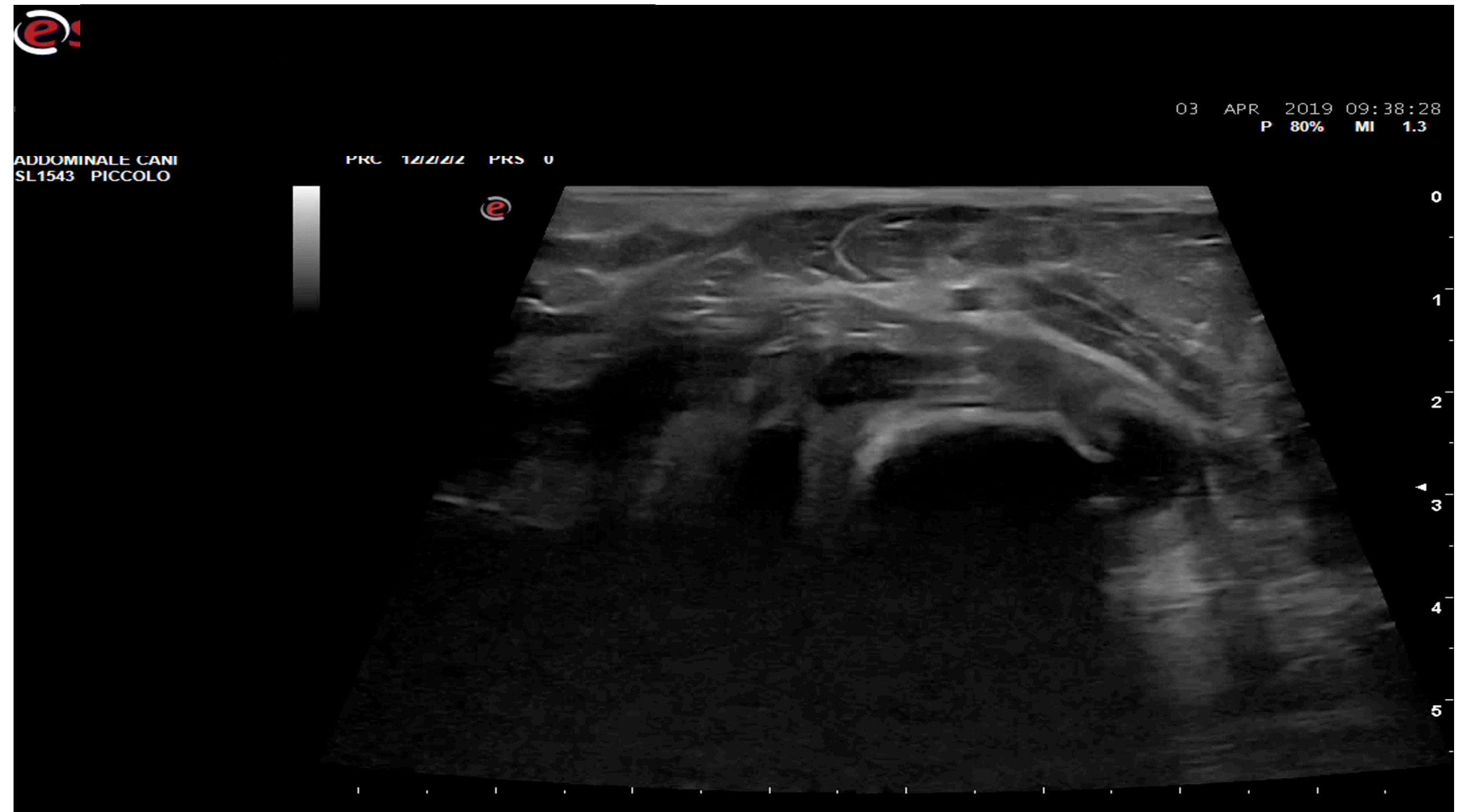
RHODESIAN R. 5MM M
Longitudinal Plan
Ventral scan



SEPTIC ATHROSYNOVITIS

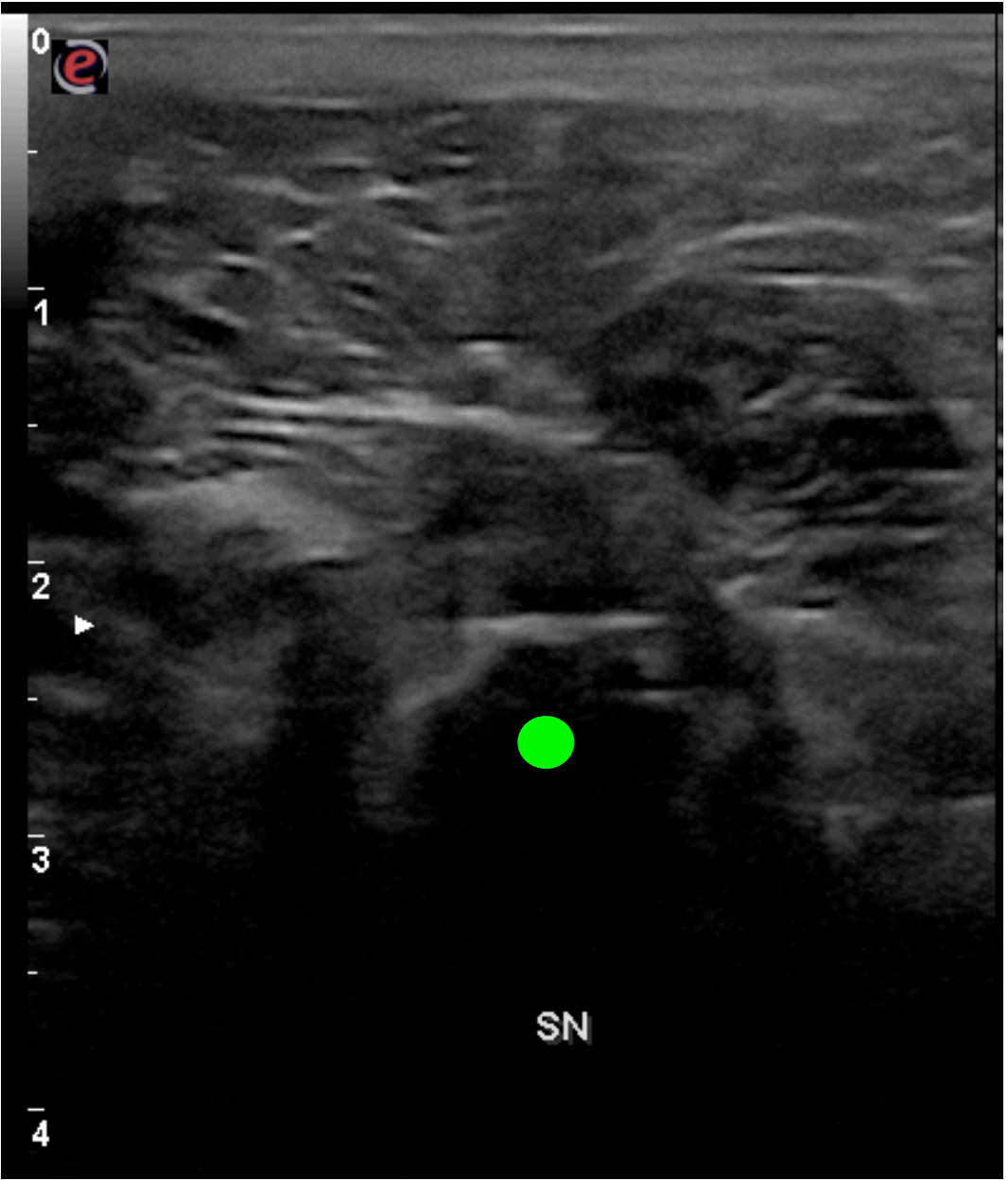
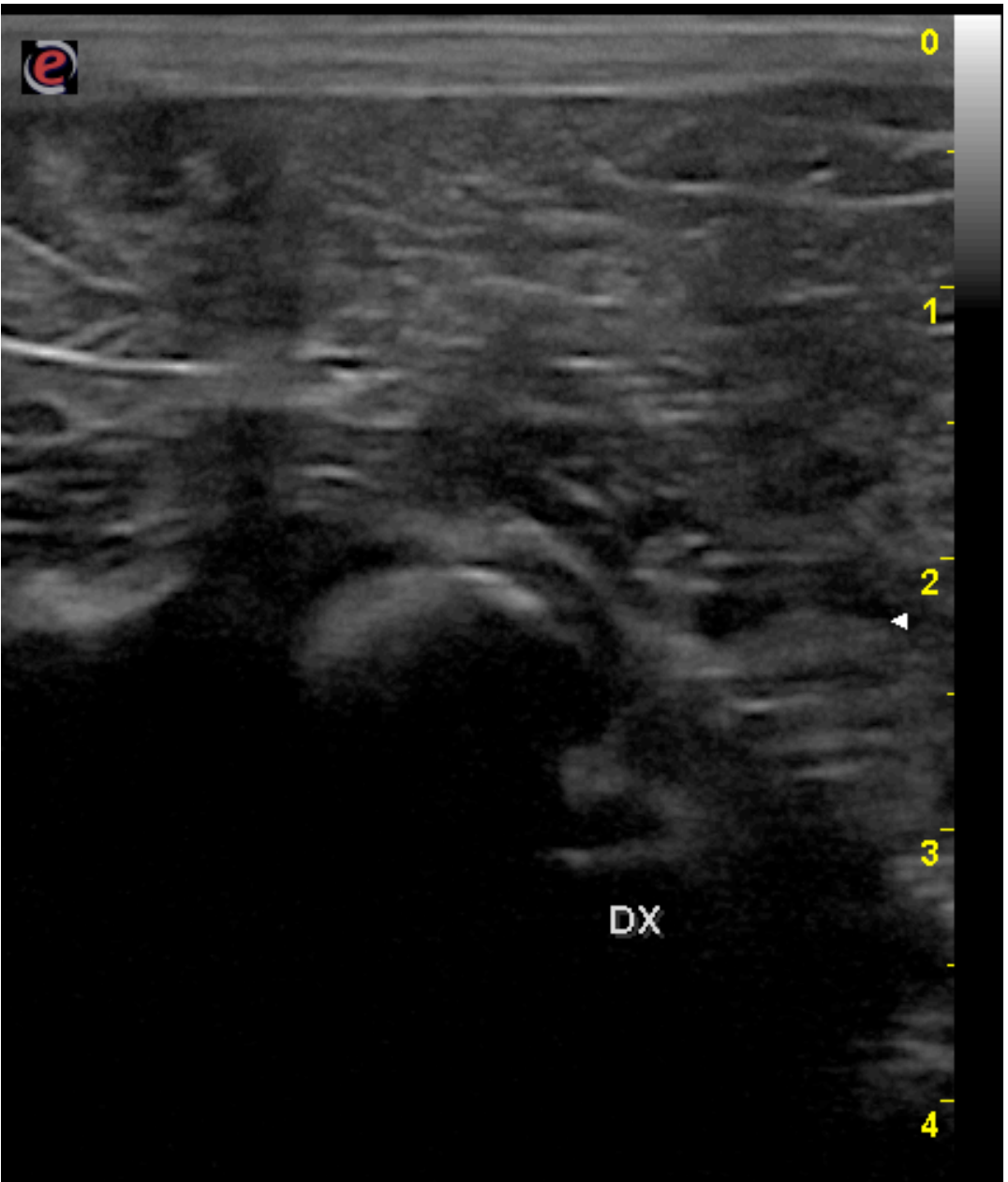
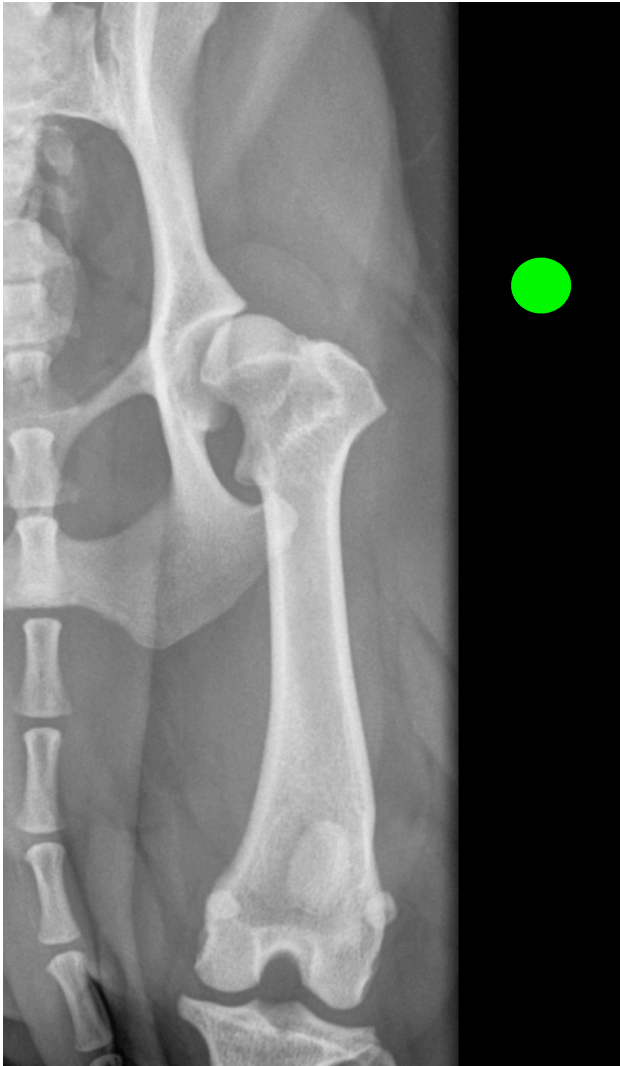
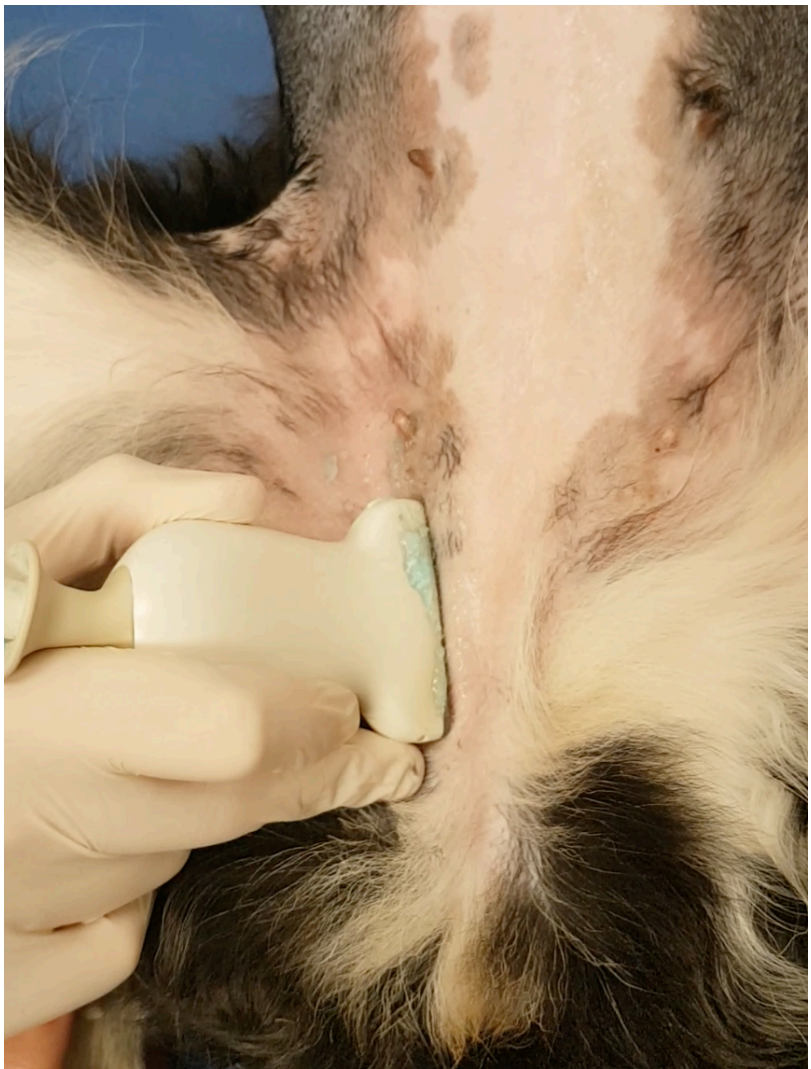


OSCAR
RHODESIAN R. 5MM M
Longitudinal Plan
Ventral scan



**Longitudinal Plan
Ventral scan**

HARIET
JRT; 5yo; FS



CLINICAL INDICATIONS FOR THE US EXAM OF THIGH MUSCLES

Diagnosis and treatment of hind limb muscle strain injuries in 22 dogs

C. Nielsen, G. E. Pluhar

Department of Veterinary Clinical Sciences, College of Veterinary Medicine, University of Minnesota, Minnesota, USA

12 Iliopsoas; 11 Pectineus; 3 Adductor; 1 Gracilis

Mostly Clinical Diagnosis

Vet Comp Orthop Traumatol 2005; 18: 247–53

Presence of muscle tumefaction


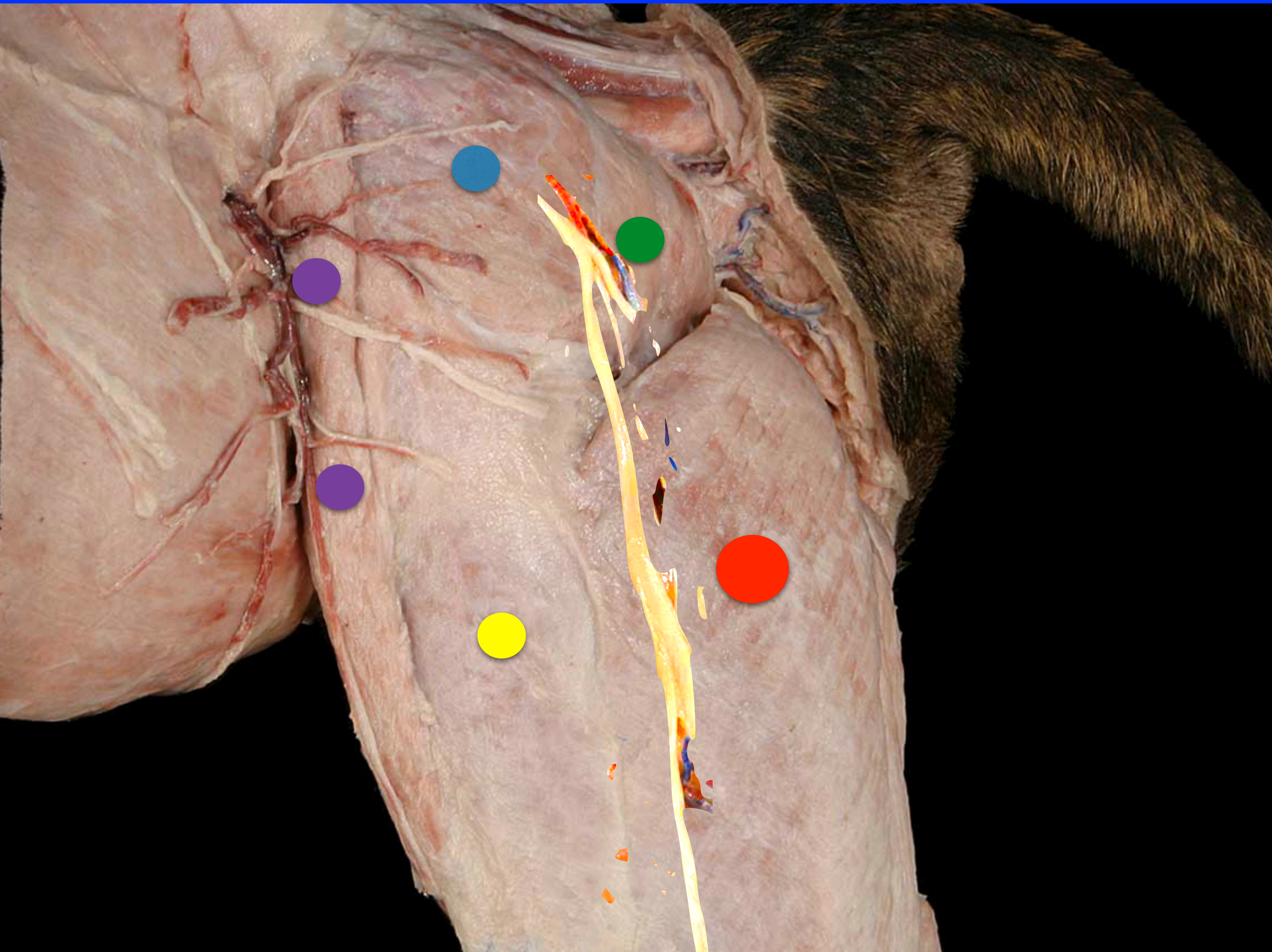
(Taut band within the affected muscle)

Pain at palpation

Typical gait/lameness


(The dog shows a typical internal rotation during extension of the stifle joint)

GLUTEAL REGION/LATERAL THIGH MUSCLES




M. Gluteus Medius

O: wing of ilium
I: greater trochanter



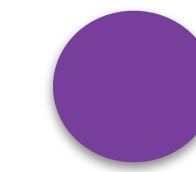
M. Gluteus Sup.

O: lateral sacrum, sacrotuberous ligament
I: trochanter tertius




M. Biceps Femoris

O: sacrotuberous ligament & ischiatic tuberosity
I: via fascia lata and fascia of the leg to patella, patellar ligament, tibial crest and body, tuber calcanei




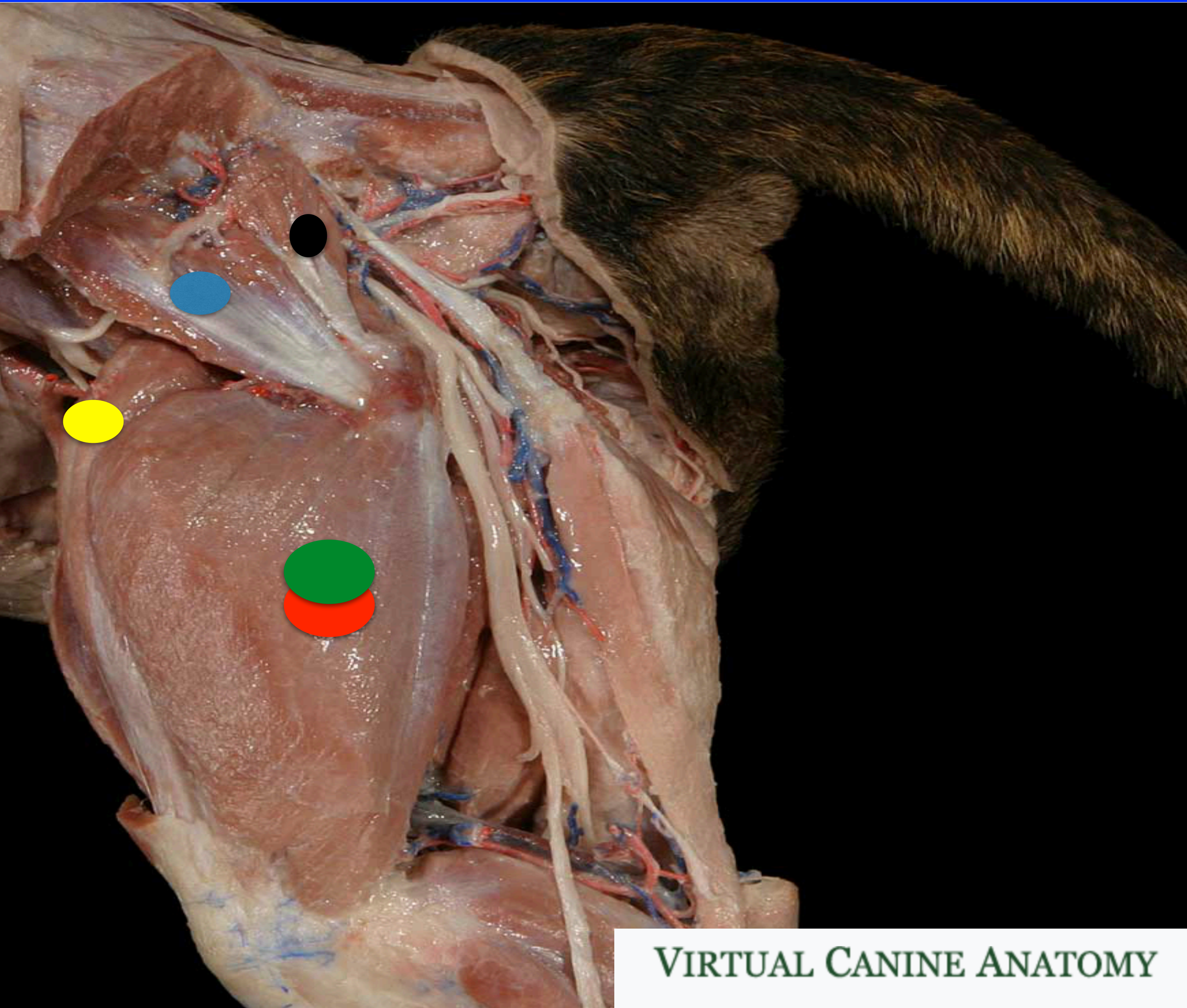
M. Sartorius

O: Cranial—crest of ilium and thoracolumbar fascia
Caudal—iliac spine and ventral border of ilium
I: Cranial—patella
Caudal—cranial border of tibia




Fascia Lata

GLUTEAL REGION/LATERAL THIGH MUSCLES




M. Gluteus Profundus

O: body of ilium
I: greater trochanter




M. Piriformis

O: S3
I: greater trochanter




M. Vastus Lateralis

O: craniolateral aspect of proximal femur
I: tibial tuberosity via patella and patellar ligament



M. Vastus Intermedius

O: craniolateral aspect of proximal femur
I: tibial tuberosity via patella and patellar ligament



M. Rectus Femoris

O: ilium cranial to the acetabulum
I: tibial tuberosity via patella and patellar ligament



OSCAR

**Rhodesian Ridgeback
5 Months**

**Tumefaction of
gluteal/lateral thigh muscles
(Right)**

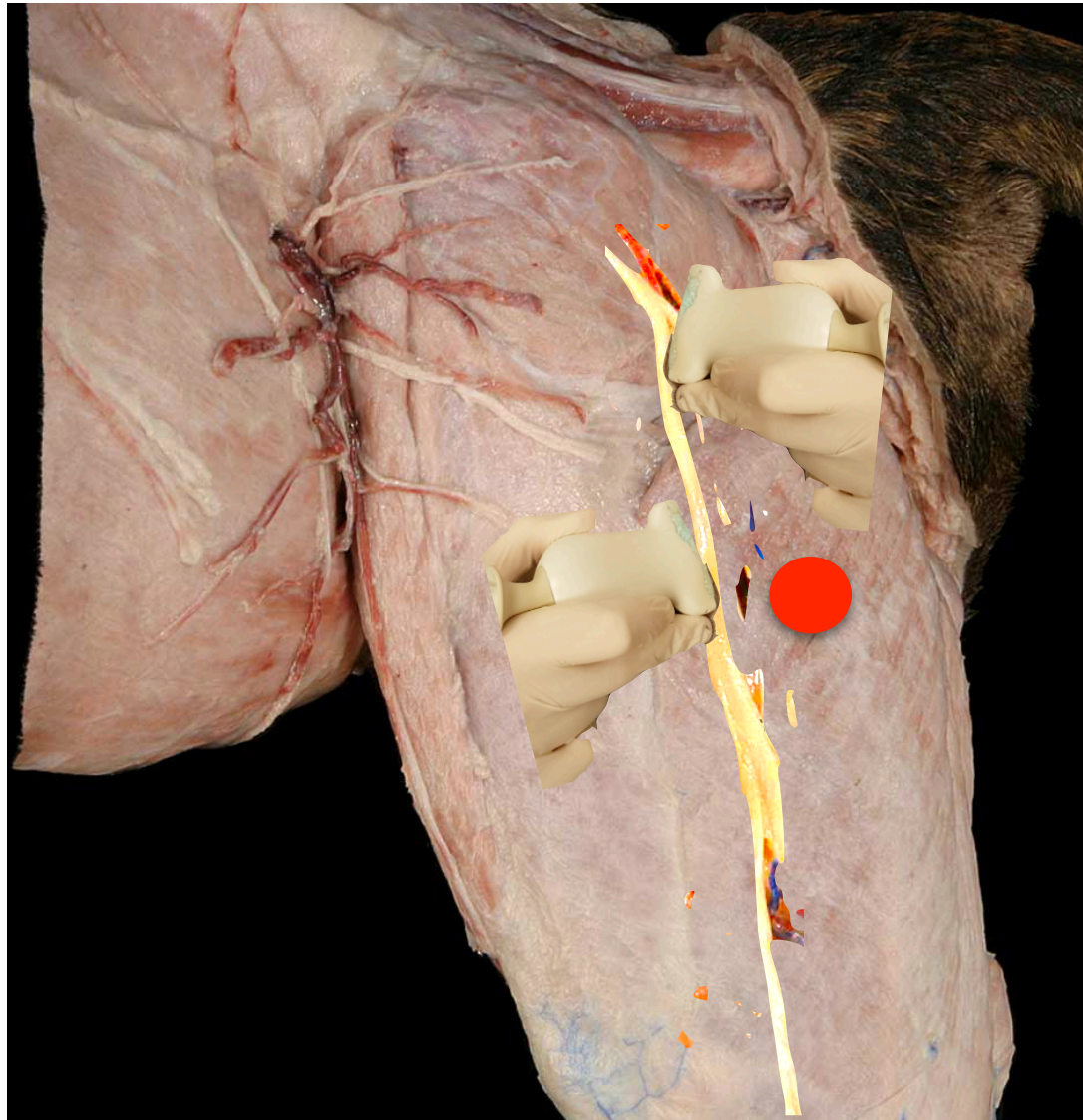
Severe Pain at palpation

Delayed postural reactions

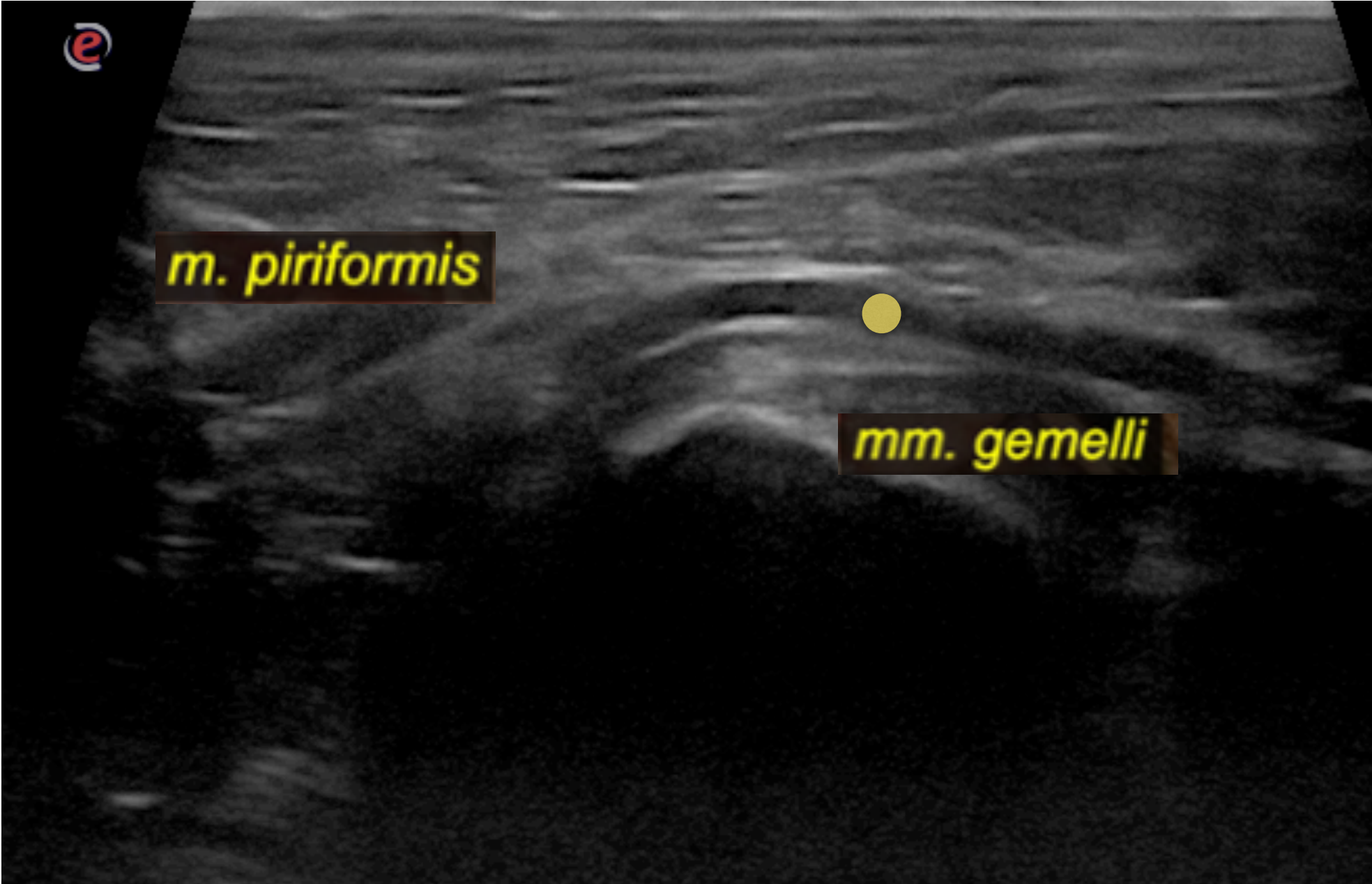
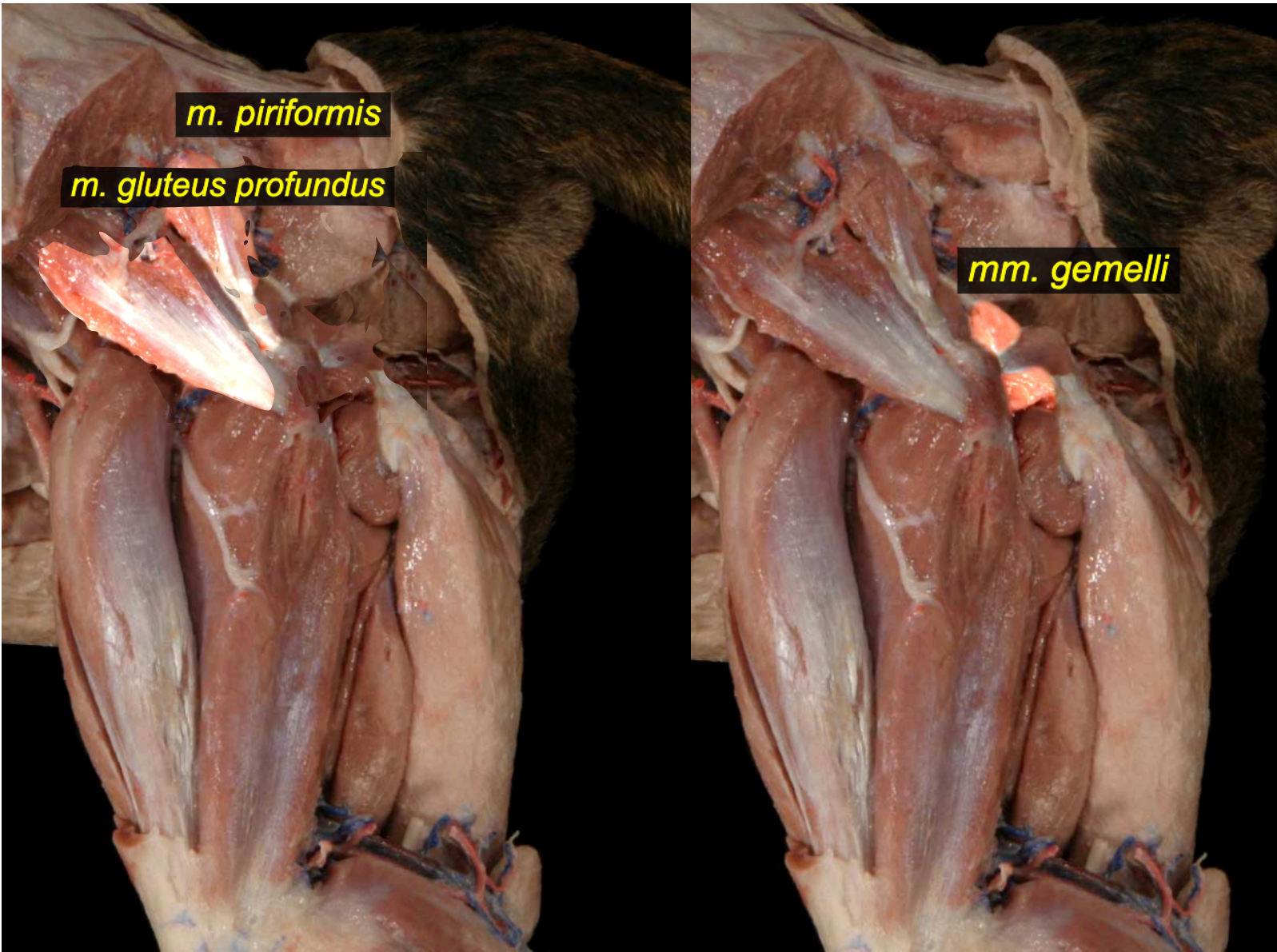
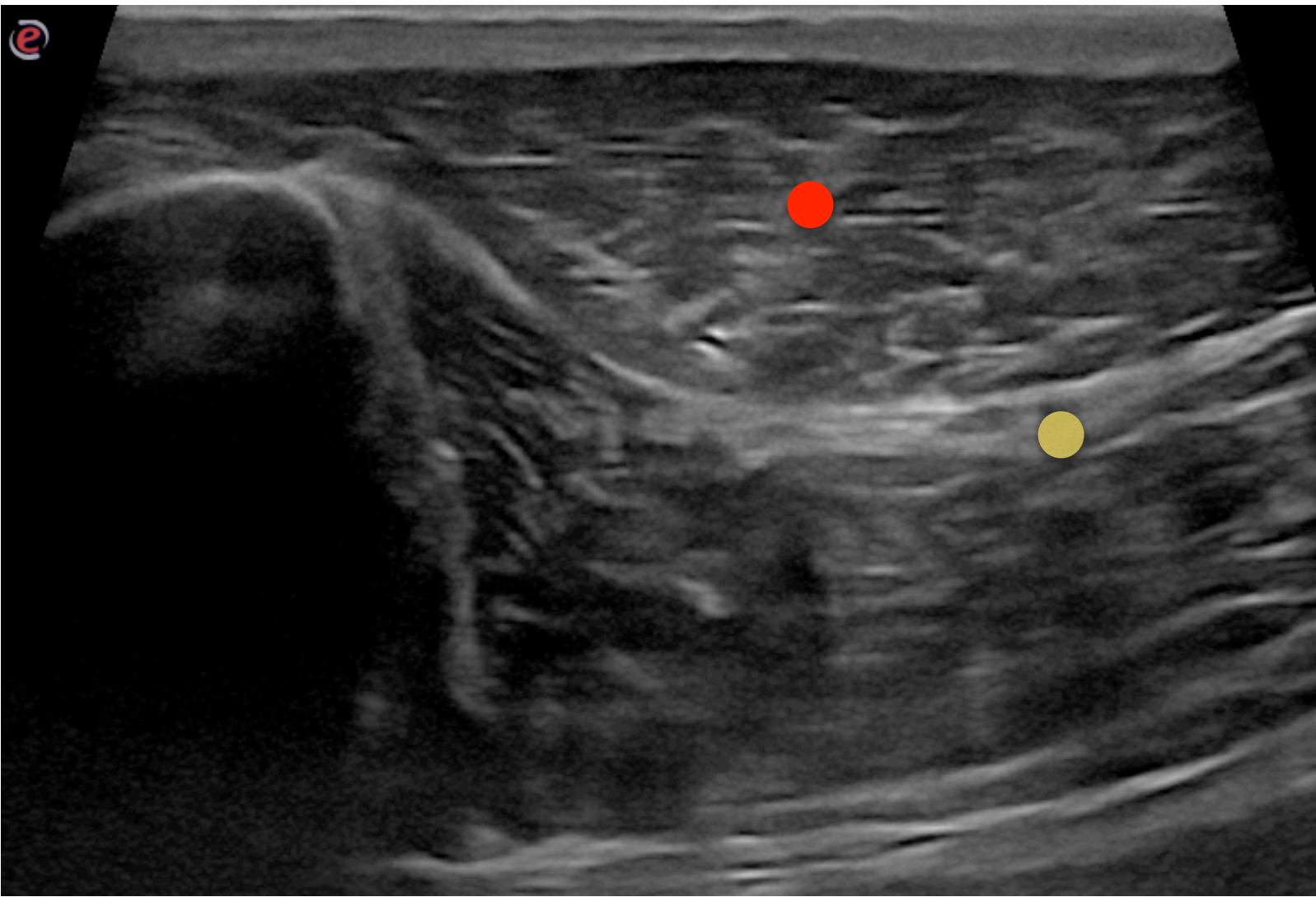
Reduced withdrawal reflex

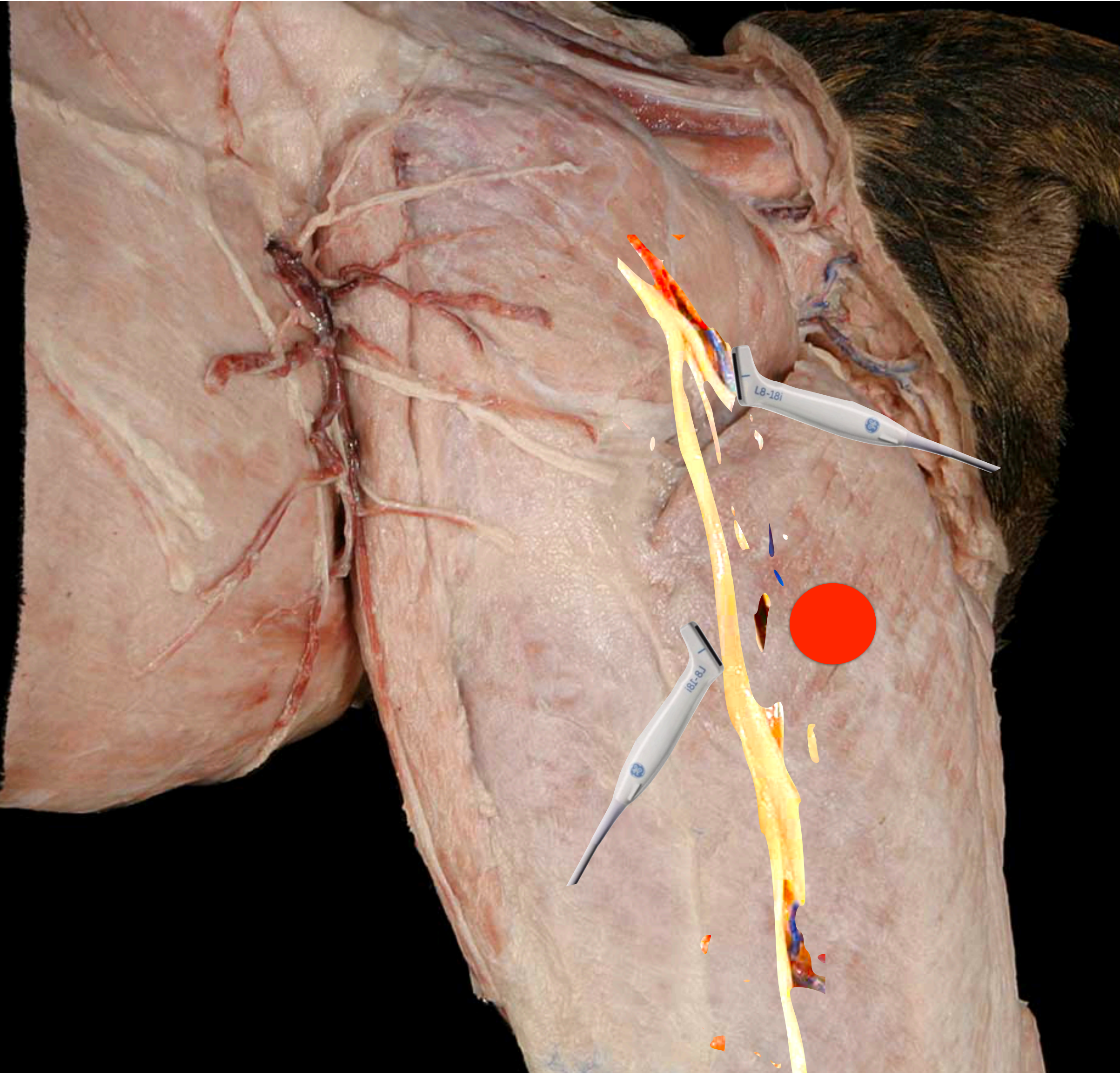
Occasional knuckling off the foot

M. Biceps Femoris and Sciatic nerve

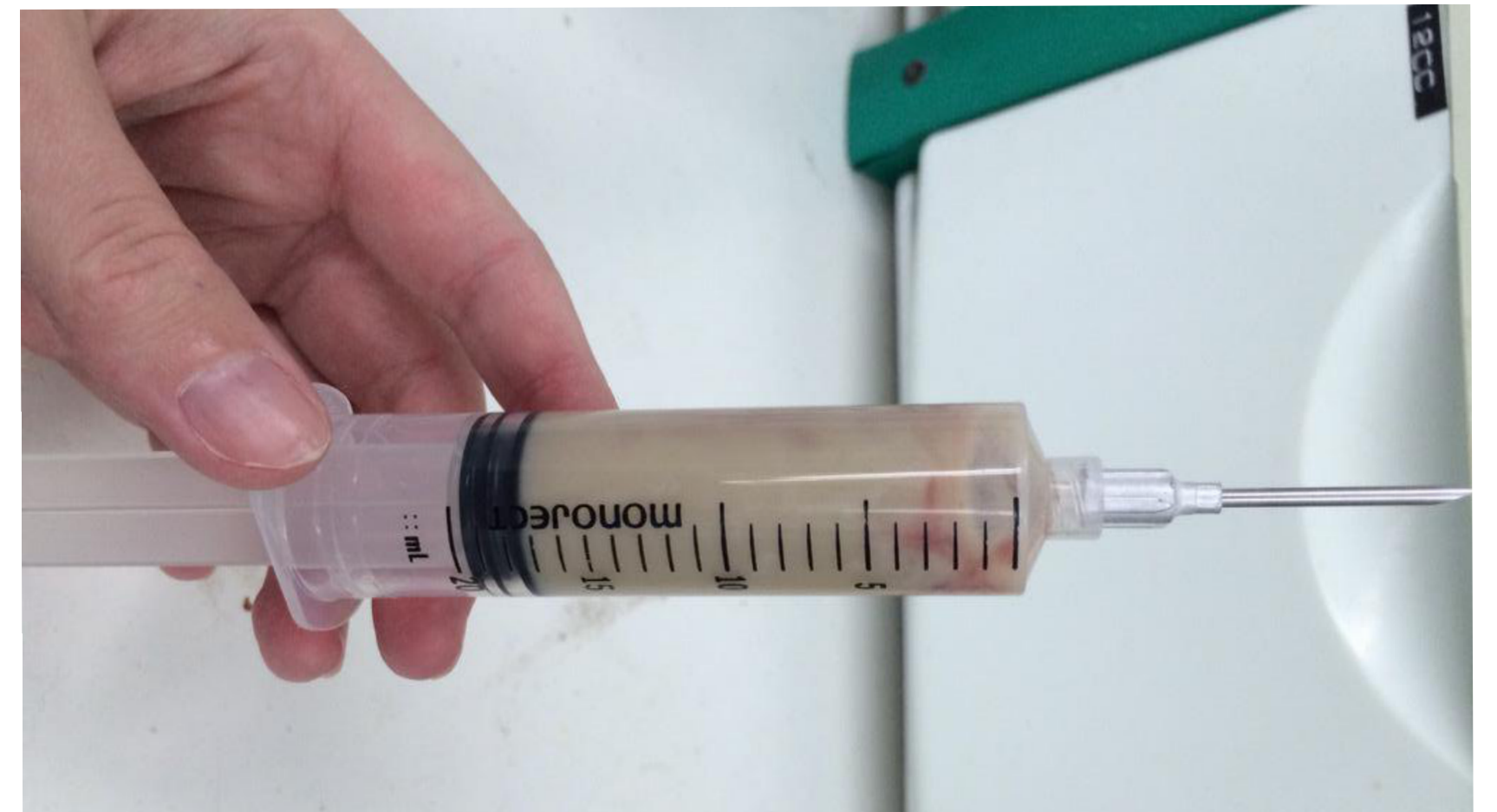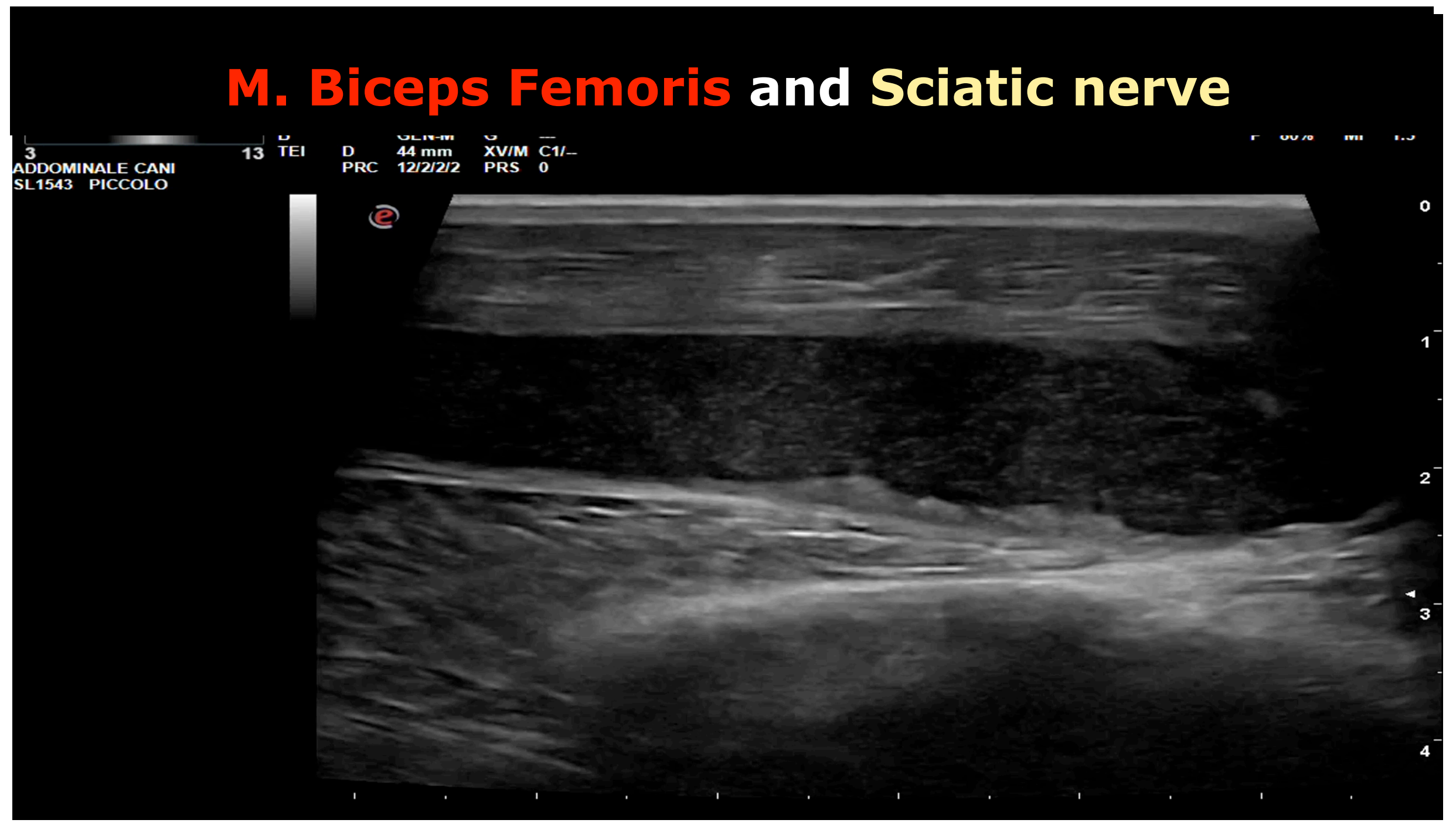


After drainage and antibiotic therapy

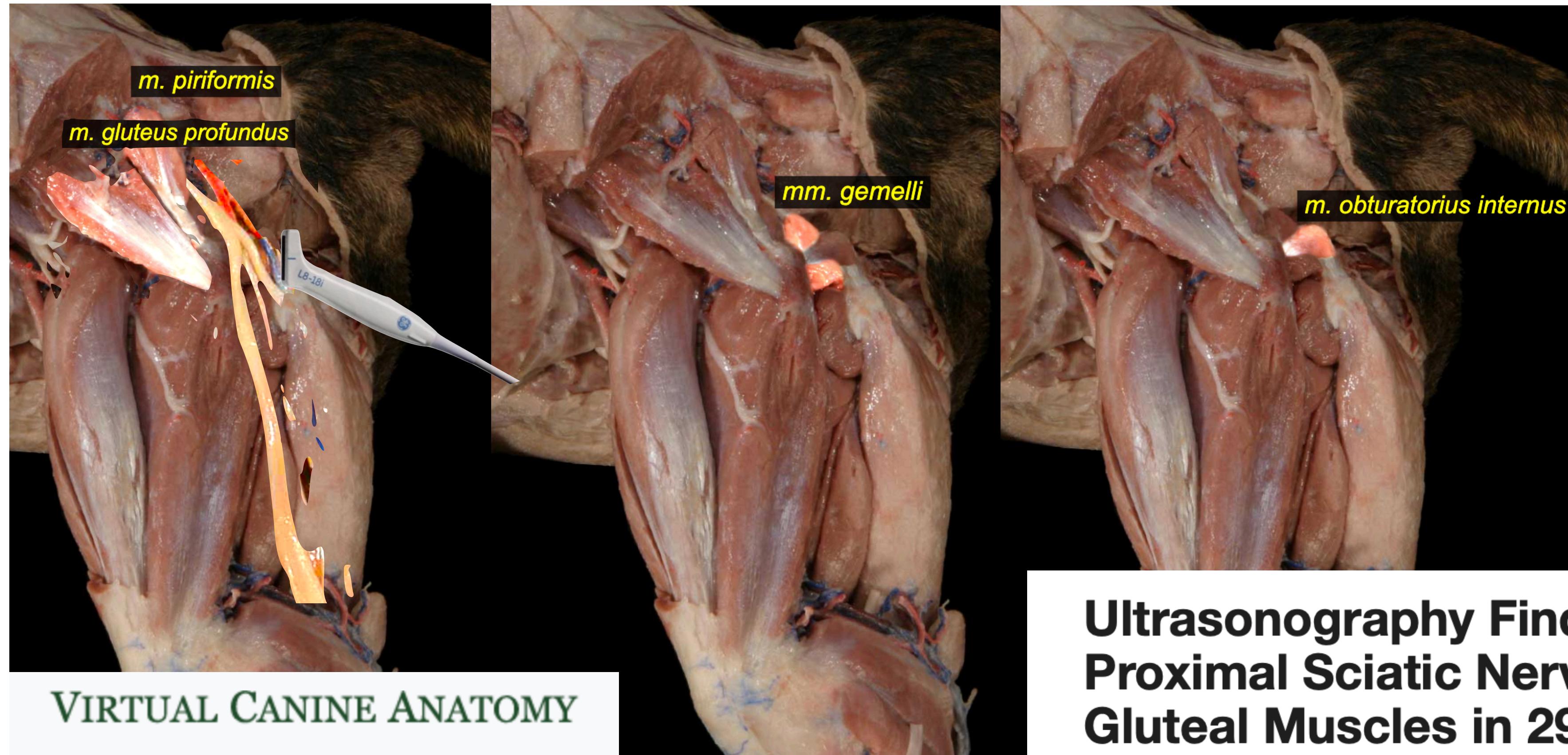




VIRTUAL CANINE ANATOMY



SCIATIC NERVE - GLUTEAL MUSCLE SYNDROME



Ultrasonography Findings in the Proximal Sciatic Nerve and Deep Gluteal Muscles in 29 Dogs With Suspected Sciatic Neuritis

Tiiu M. Toijala^{1*}, *Debra A. Canapp*² and *Sherman O. Canapp*²

¹ *Sporting Dogs Clinic Evidensia, Espoo, Finland,* ² *Veterinary Orthopedic and Sports Medicine Group, Annapolis Junction, MD, United States*

Haematomas, Abscessations, Hypertrophy

Sciatic Nerve compression

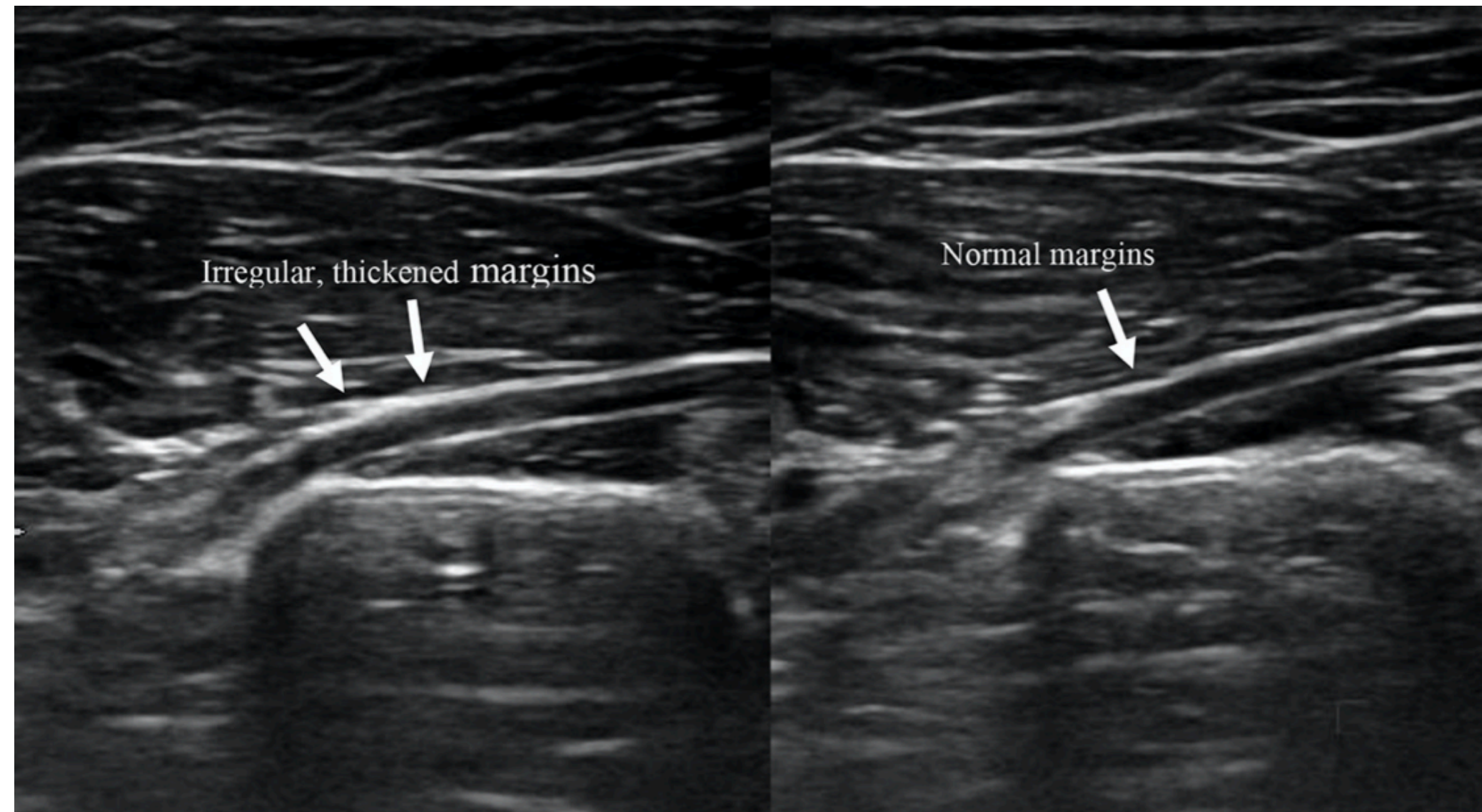
SCIATIC NERVE - GLUTEAL SYNDROME

Ultrasonography Findings in the Proximal Sciatic Nerve and Deep Gluteal Muscles in 29 Dogs With Suspected Sciatic Neuritis

Tiiu M. Toijala^{1*}, Debra A. Canapp² and Sherman O. Canapp²

¹ Sporting Dogs Clinic Evidensia, Espoo, Finland, ² Veterinary Orthopedic and Sports Medicine Group, Annapolis Junction, MD, United States

August 2021 | Volume 8 | Article 704904



Thickening of sciatic nerve

Thickening of perineurium

Hyperechogenicity of soft tissues

Fluid/Soft tissue oedema

Alterations of contiguous muscles

Synovial bursae (b. Internal obturator)

Surgical devices

Case Report

J Vet Intern Med 2012;26:1227–1231

Bilateral Sciatic Neuropathy in Dogs Caused by Spontaneous Muscular and Intraneural Hemorrhage

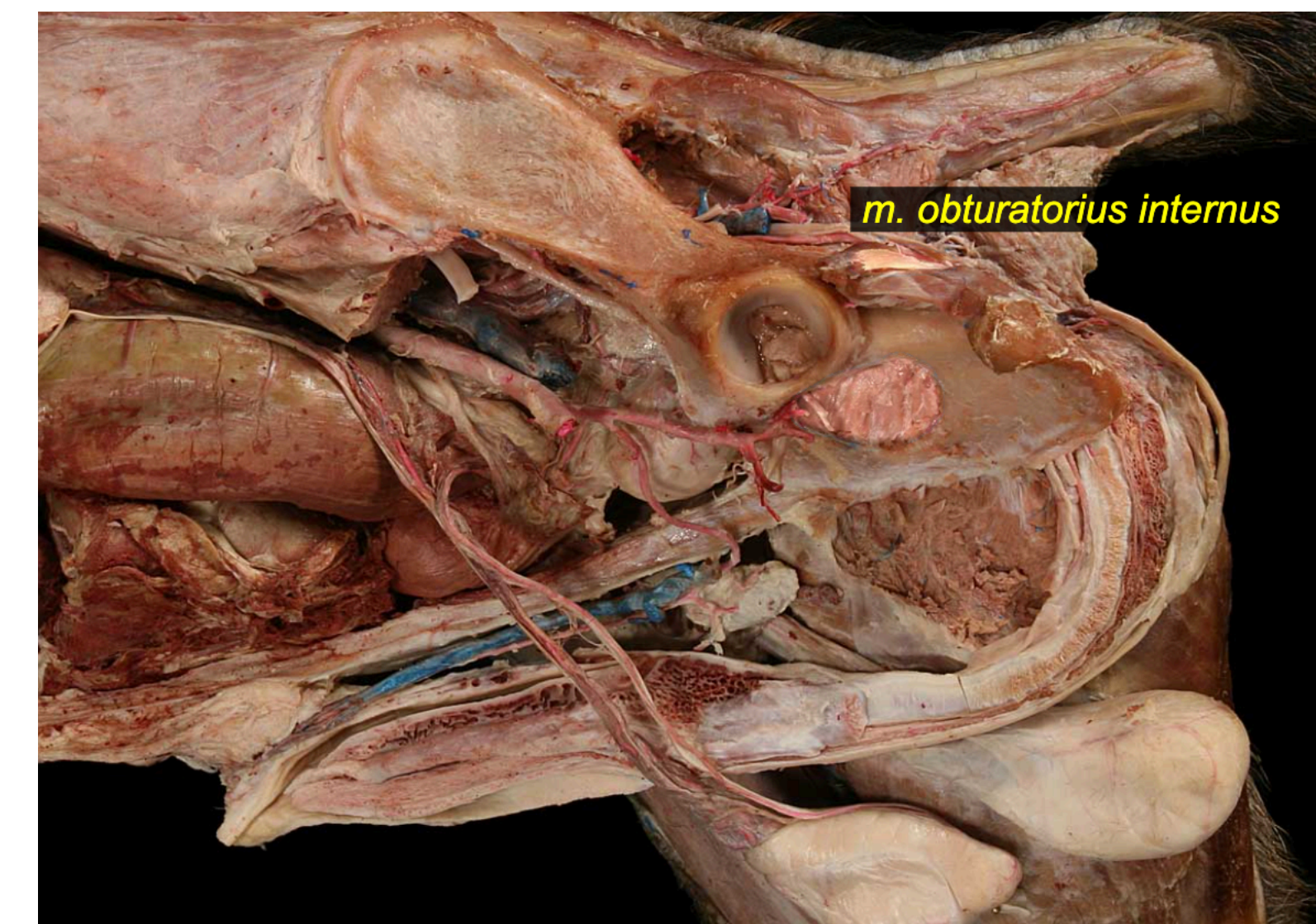
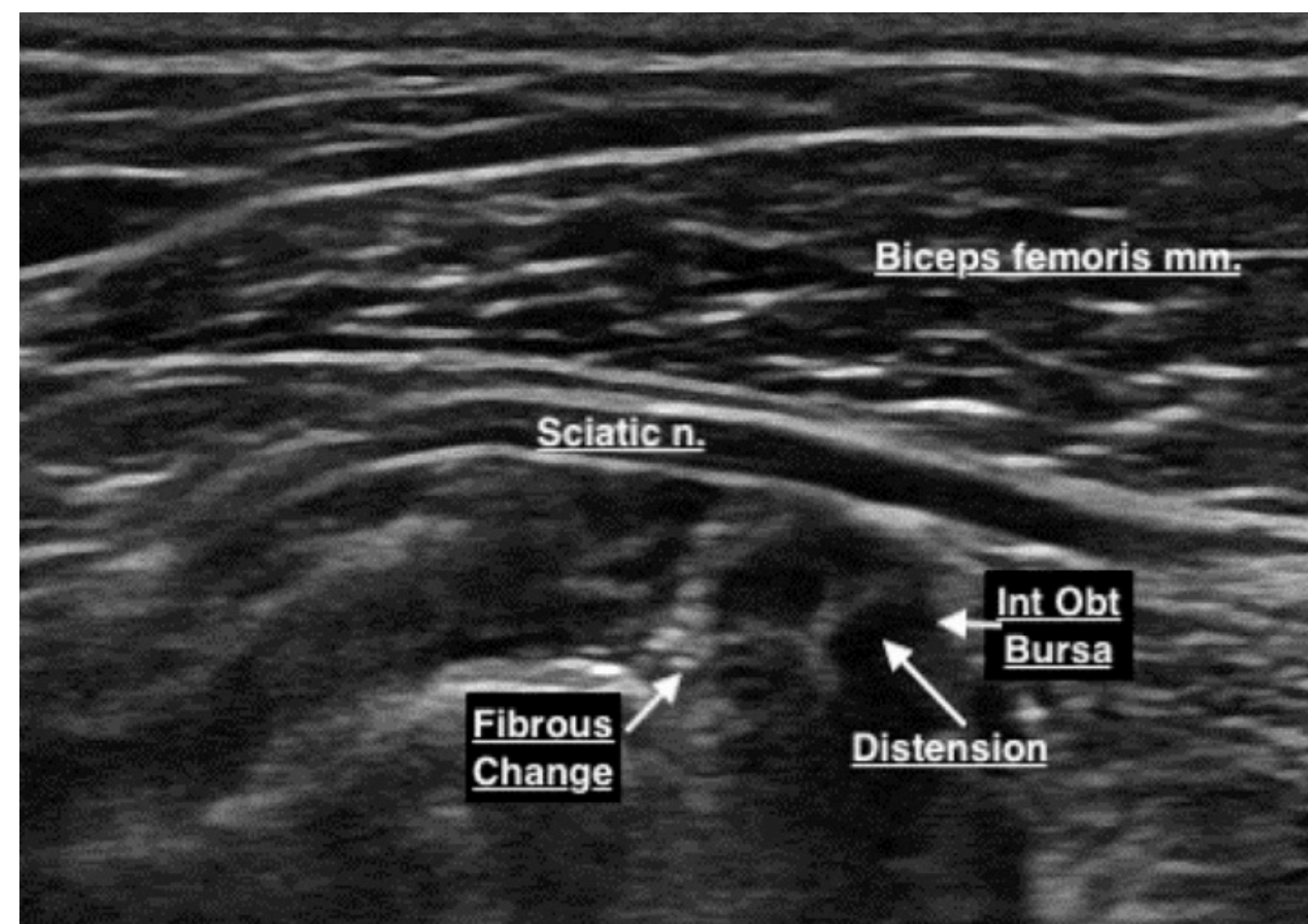
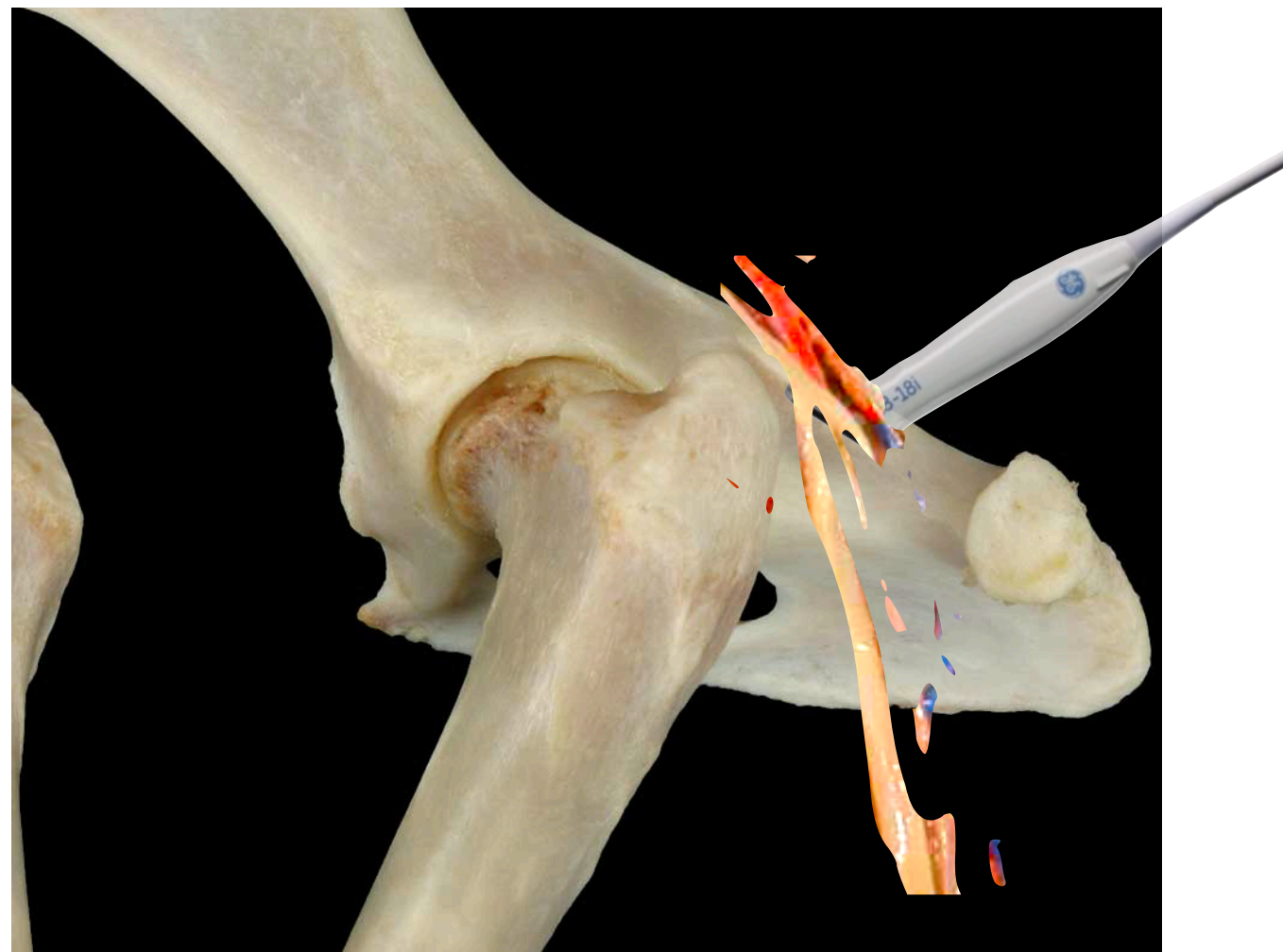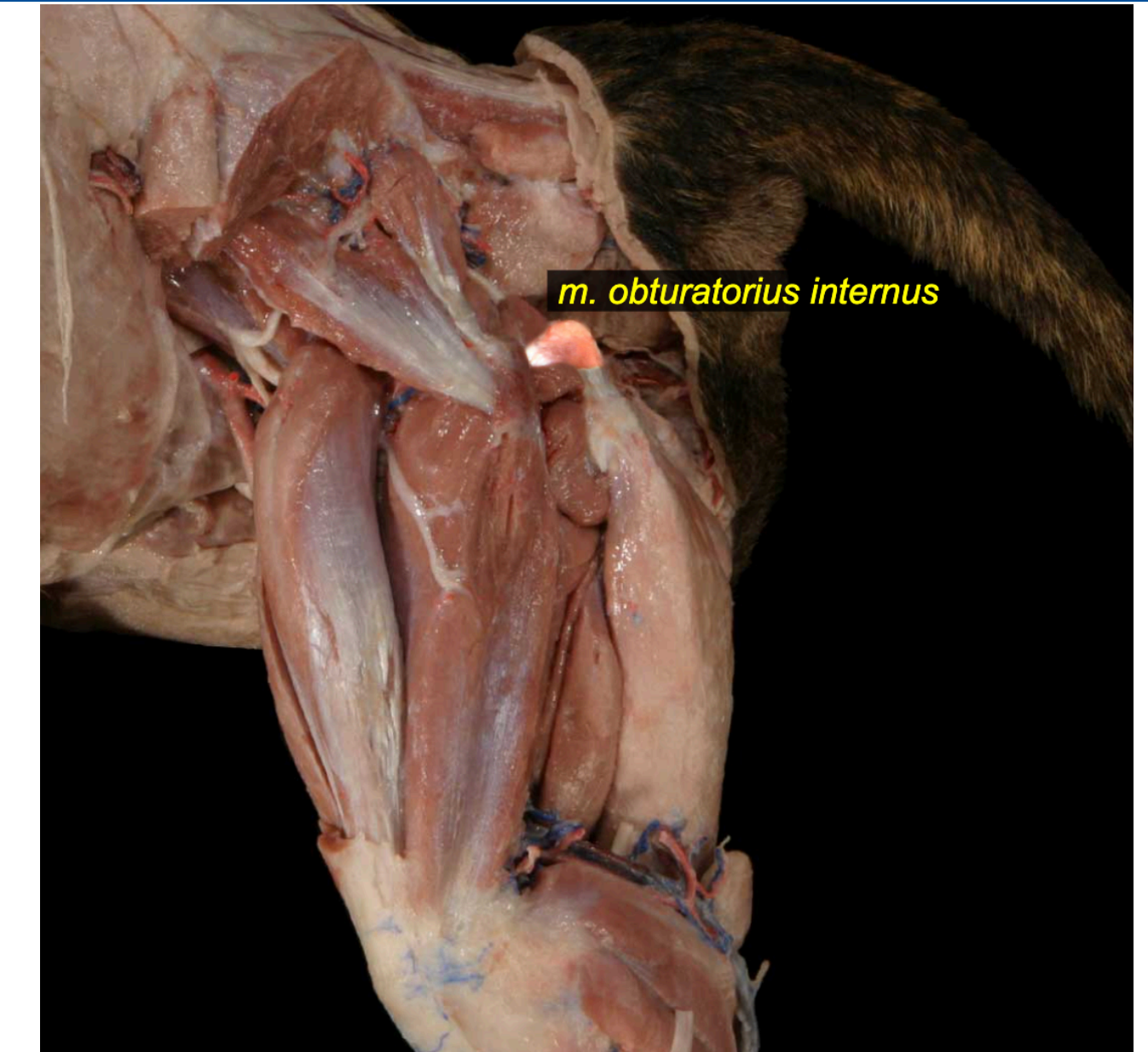
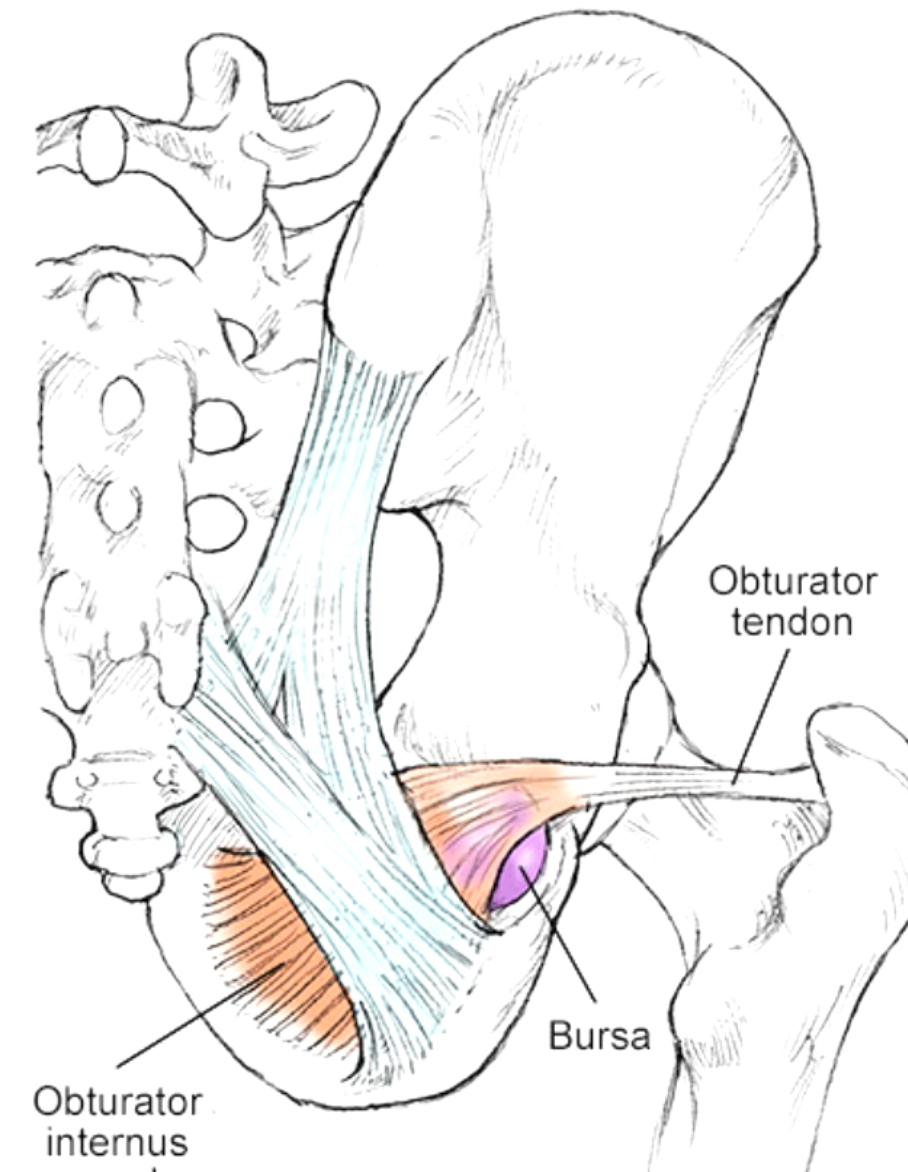
S. Ródenas, M. Pumarola, R.R. Gopegui, and S. Añor

INTERNAL OBTURATOR MUSCLE - GLUTEAL SYNDROME

M. Internal Obturator

O: pelvis side of the pubis and ischium

I: Trochanteric fossa



OBTURATOR INTERNUS MUSCLE - GLUTEAL SYNDROME

Sciatic Neuropathy in a Dog Secondary to a Bursitis

César Gomes¹ Angus Anderson² Jennifer Stewart³

¹ Queen's Veterinary School Hospital, University of Cambridge, Cambridge, United Kingdom of Great Britain and Northern Ireland

² Anderson Abercromby Veterinary Referrals, Ockley, Surrey, United Kingdom of Great Britain and Northern Ireland

³ Animal Health Trust, Lanwades Park, Kentford, Newmarket, Suffolk United Kingdom of Great Britain and Northern Ireland

Address for correspondence César Gomes, DVM MRCVS, Queens Veterinary School Hospital, University of Cambridge, Madingley Road, Cambridge, CB3 0ES, United Kingdom of Great Britain and Northern Ireland (e-mail: cg558@cam.ac.uk).

VCOT Open 2019;2:e1–e4.

Synovial Bursae

Fluidfilled connective tissue

Congenital (i.e. hypertrophic, possible Joint communication)

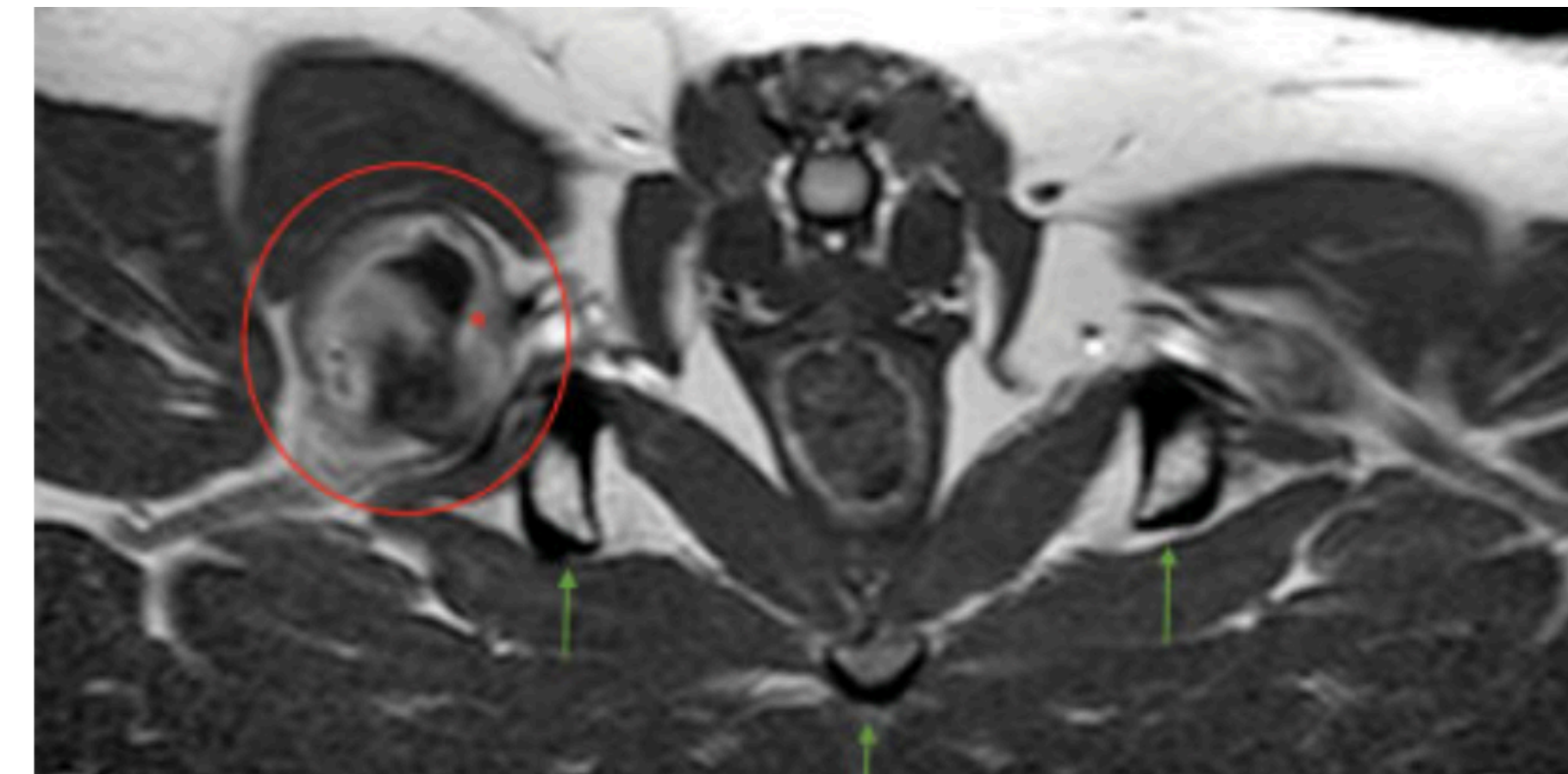
Acquired (local stress, trauma, inflammation, etc)

Hip region in canine patients

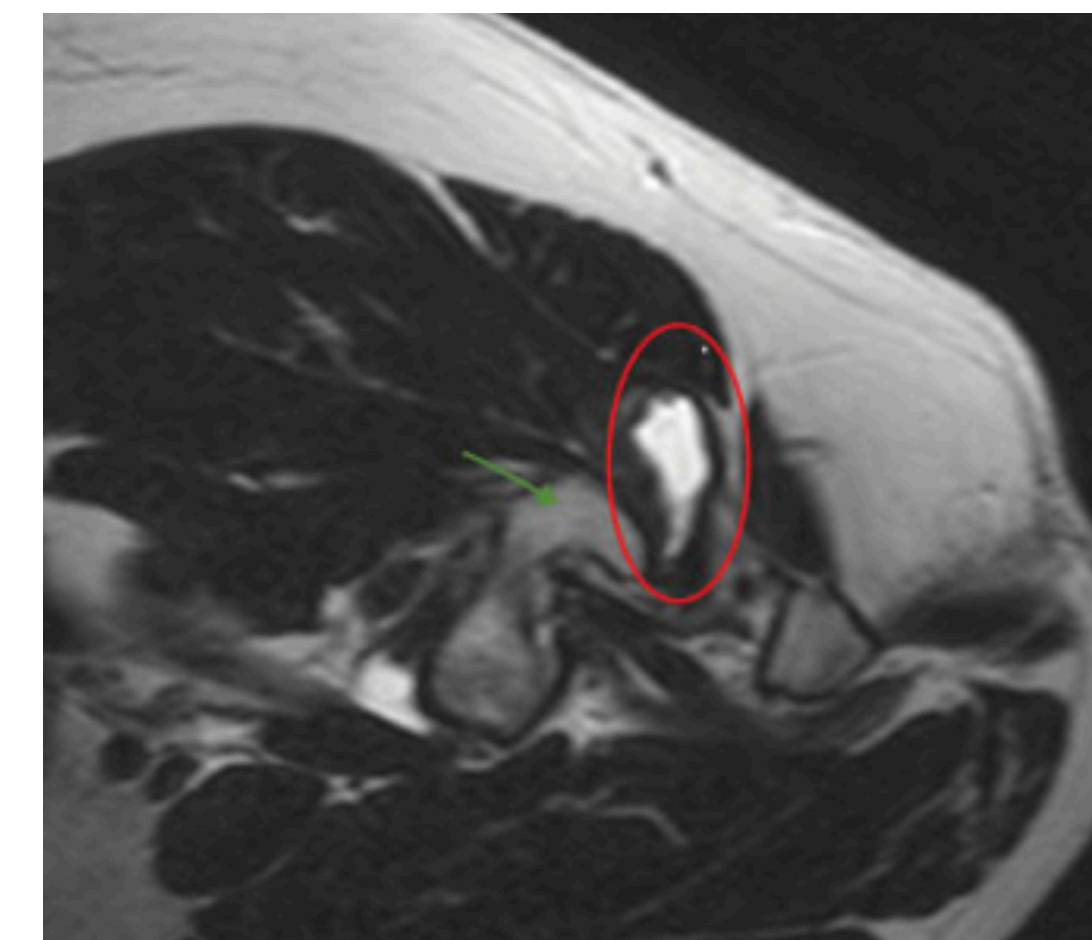
Distal bursa of the deep gluteal muscle (contiguous to the lesser ischial tuberosity)

Burasae of the mm. Internal Obturator and Gemelli (trochanteric fossa, between trochanter and joint capsule)

Trasv. Sec. Post Gad T1: Fluid, hypointense signal



Sagitt. Sec. T2: Fluid, hyperintense signal
Capsule: isointense to muscular tissue

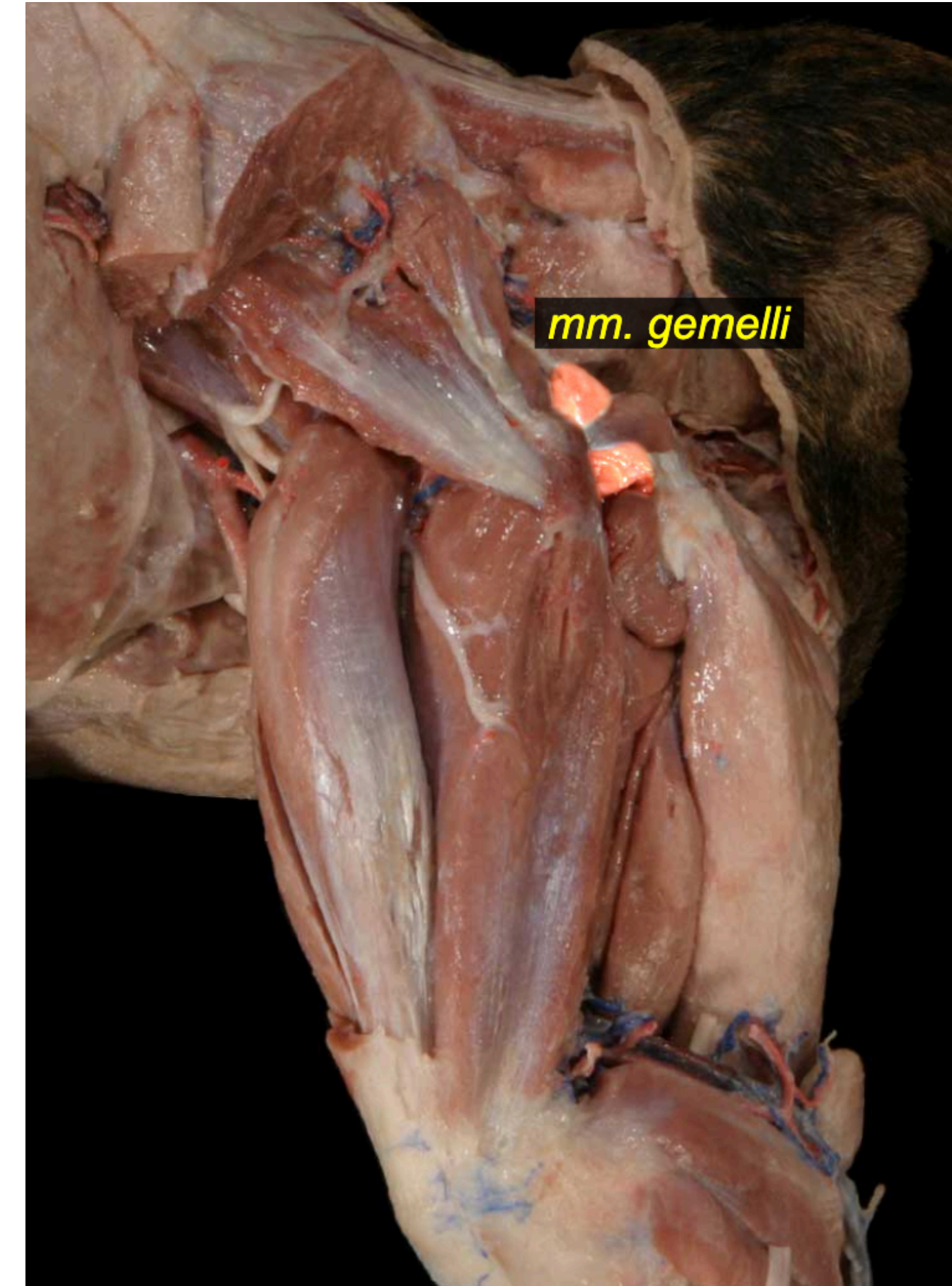
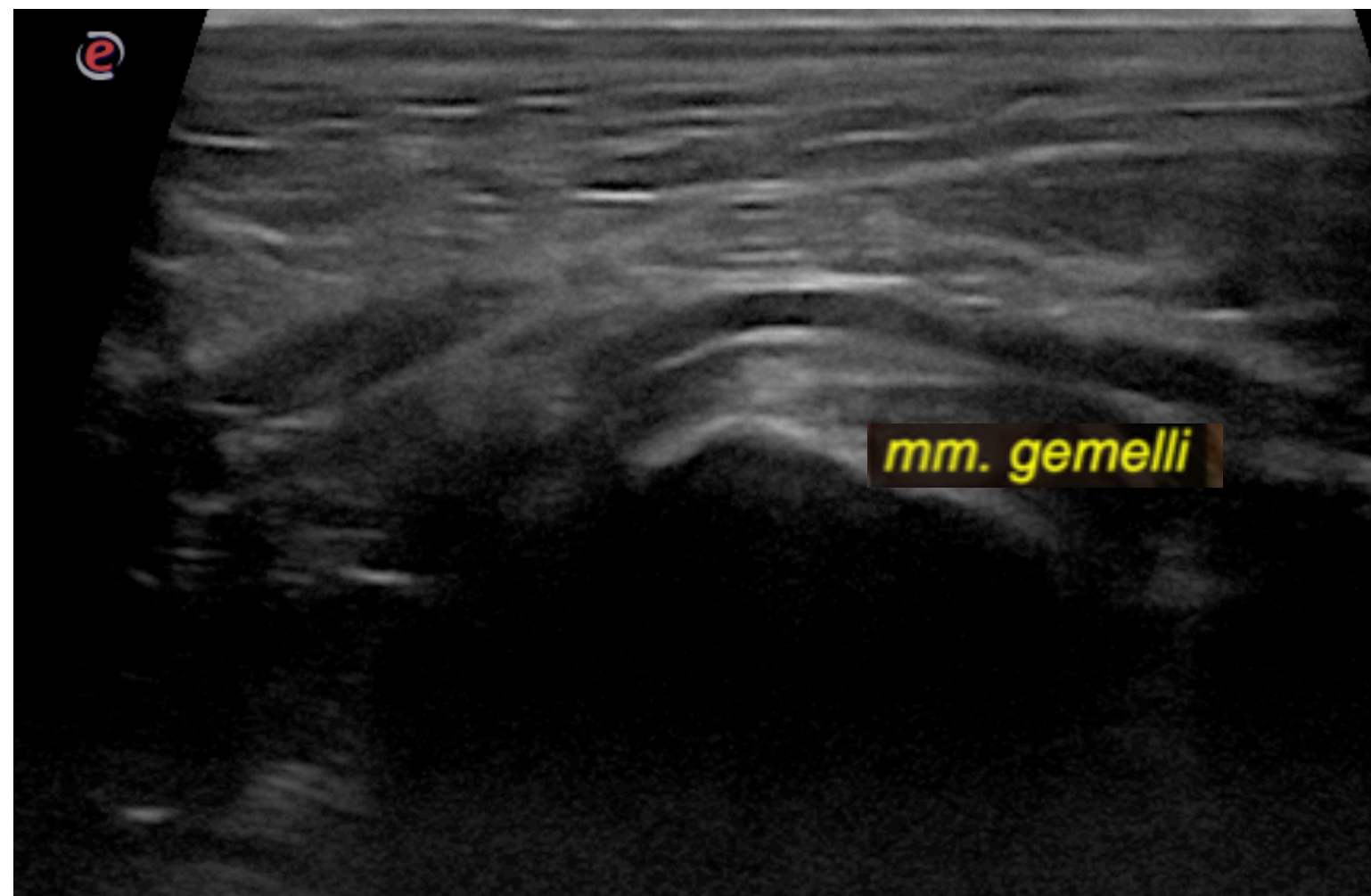
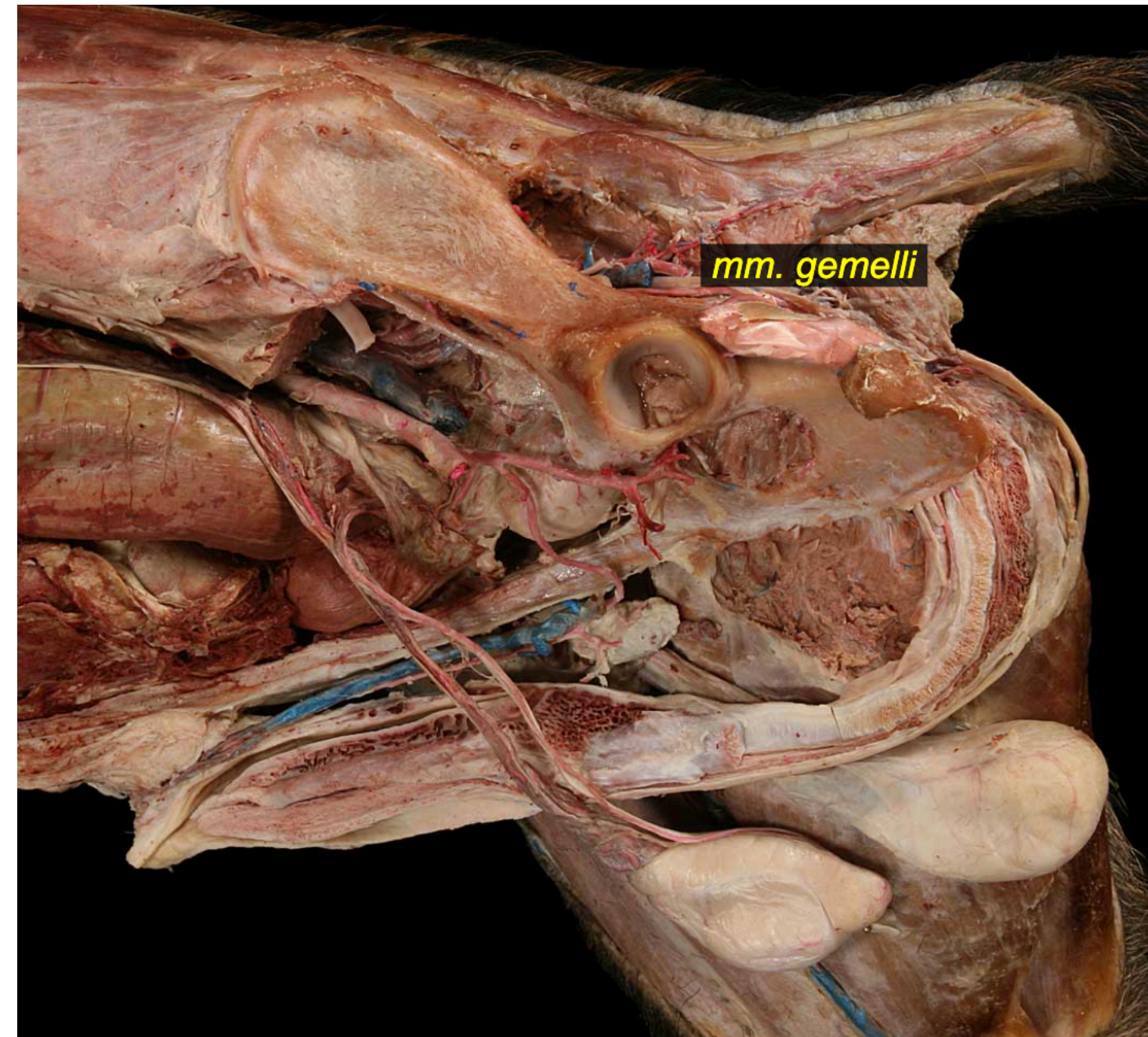
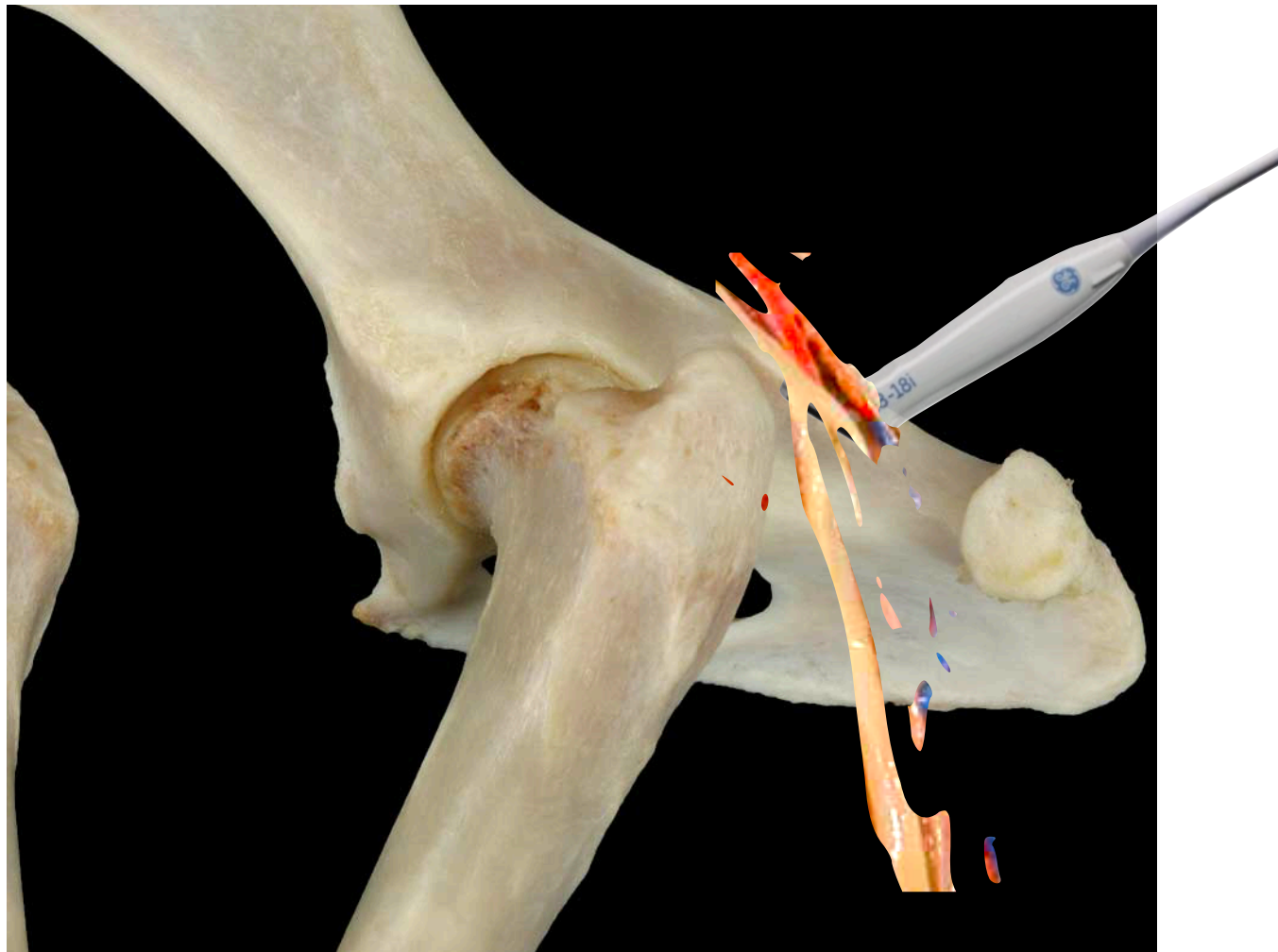


MM. GEMELLI - GLUTEAL SYNDROME

M. Gemelli

O: lateral ischium

I: Trochanteric fossa



PERLA - Mixed breed, NF, 2a

Ostectomy left femoral head (6 months before presentation)

Severe left hind limb hypomyotrophy

Lameness III

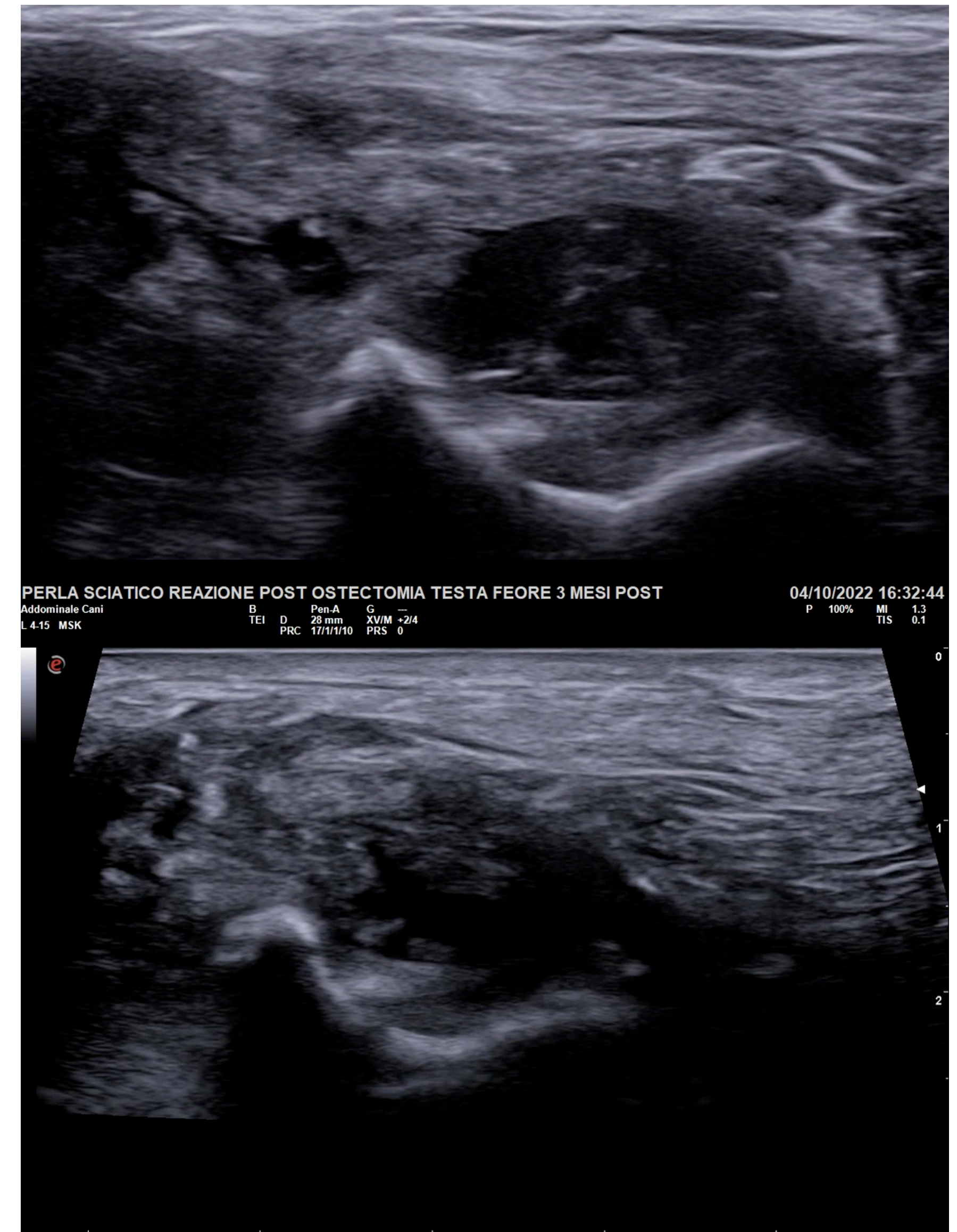
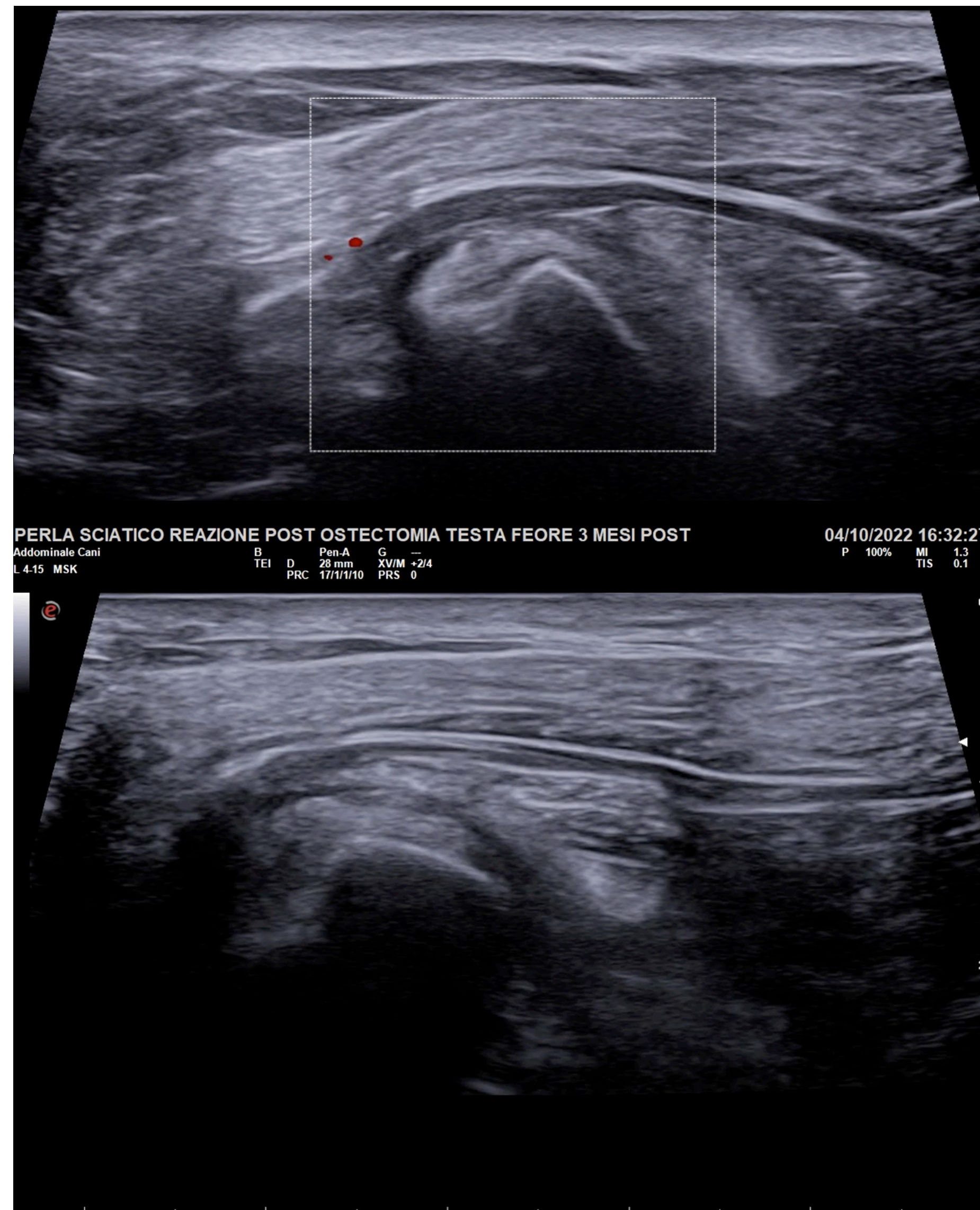
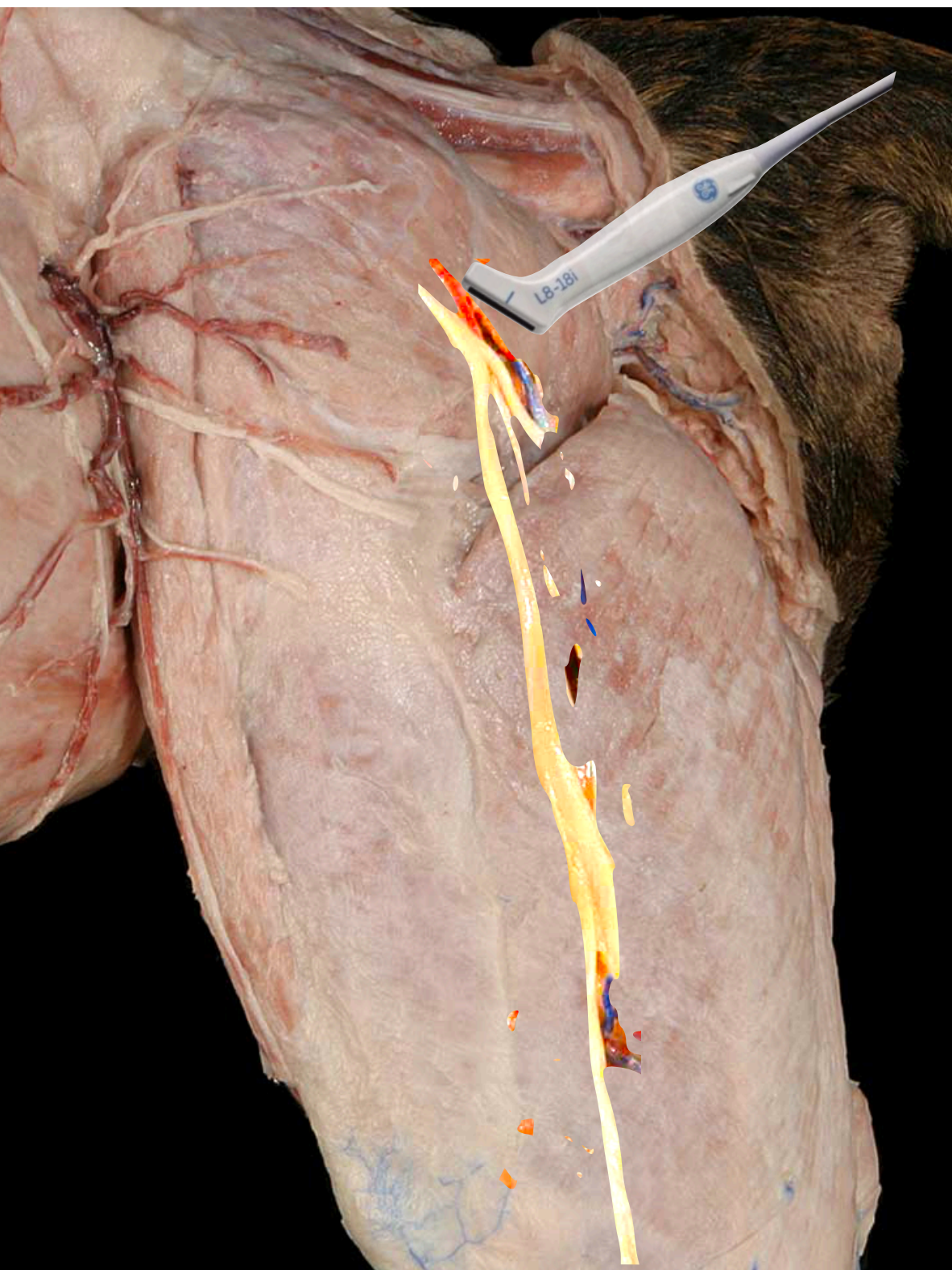
Absent/delayed proprioceptive response

Pain at trocanteri fossa palpation

Hyperextension of the hock (concurrent gastrocnemius contracture?)



NERVO SCIATICO - SINDROME GLUTEA



NEVE - ENGLISH SETTER, FS, 6a

Left transverse bicortical femoral fracture

sn (20 days before presentation)

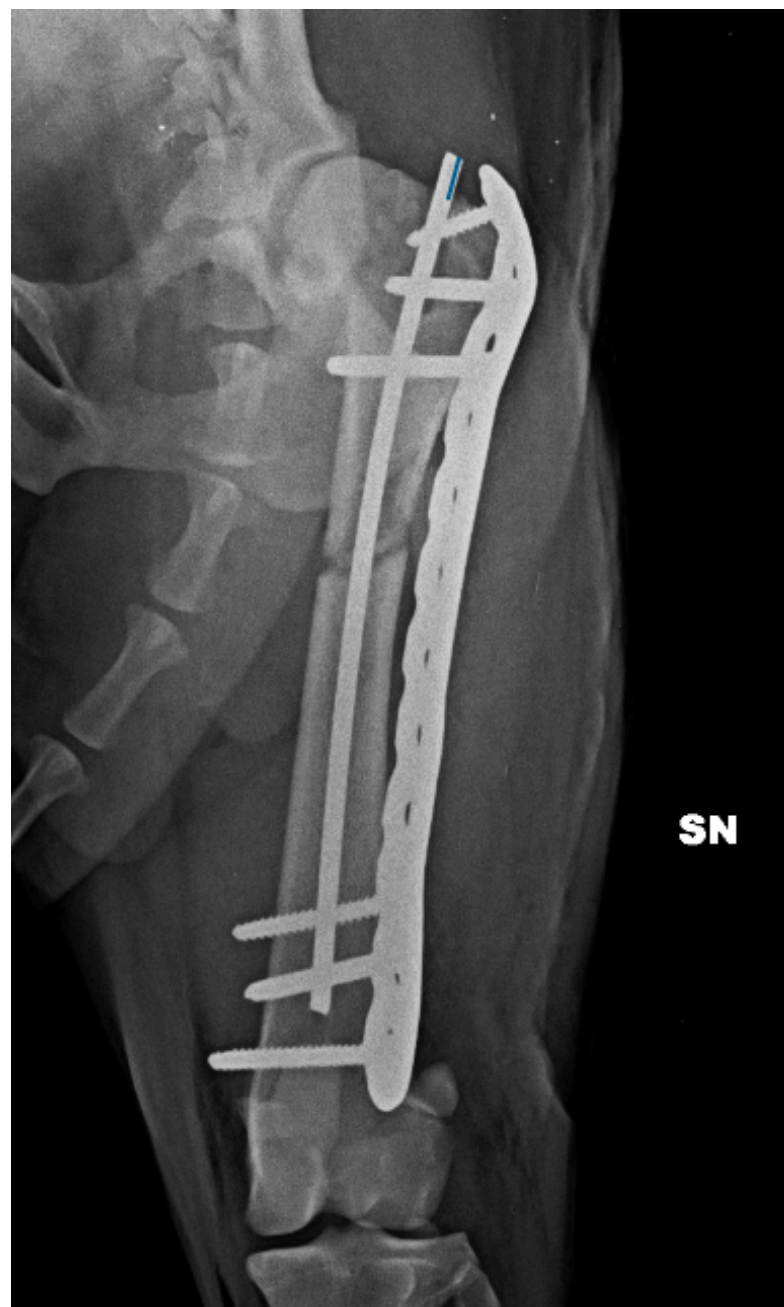Mild left hind limb hypomyotrophy

Lameness III-IV

Delayed proprioceptive response

Pain at trochanteric fossa palpation

Severe deficiency of retraction reflex



CLINICA VETERINARIA CMV ANICURA VARESE

CLINICA VETERINARIA CMV ANICURA VARESE

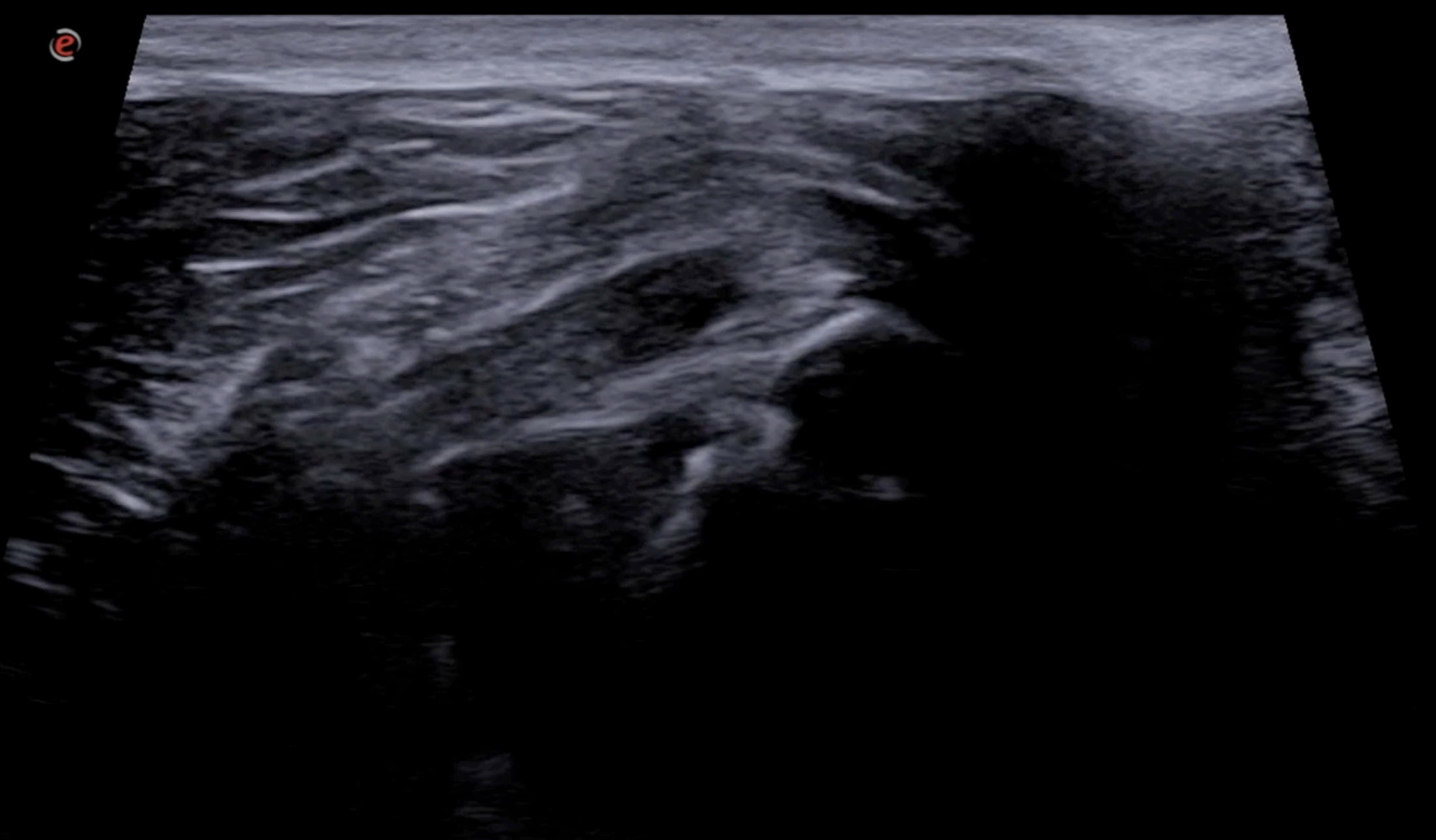
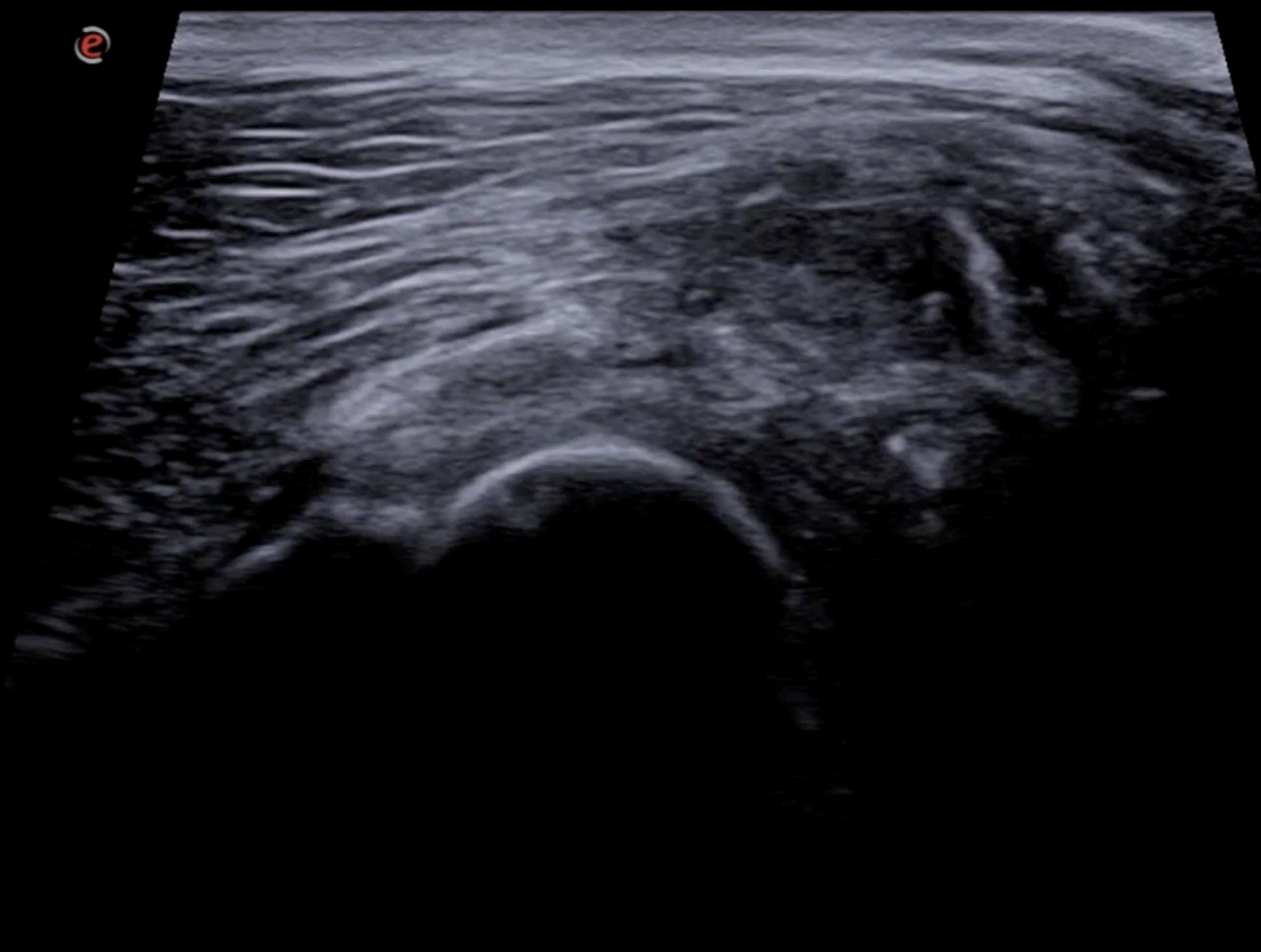
L 4-15 MSK

TEI D 46 mm XV/M +2/4
PRC 17/1/1/10 PRS 0

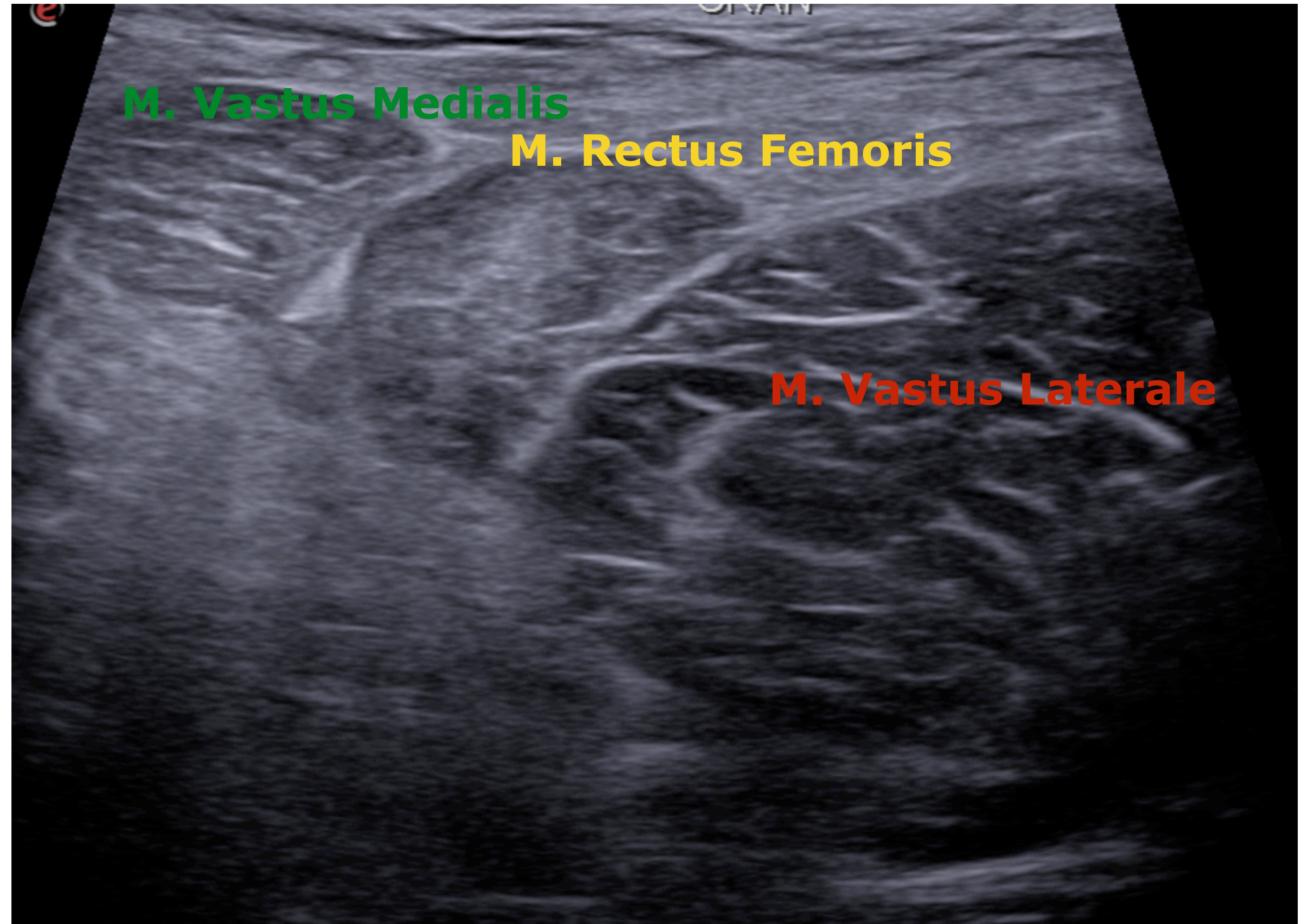
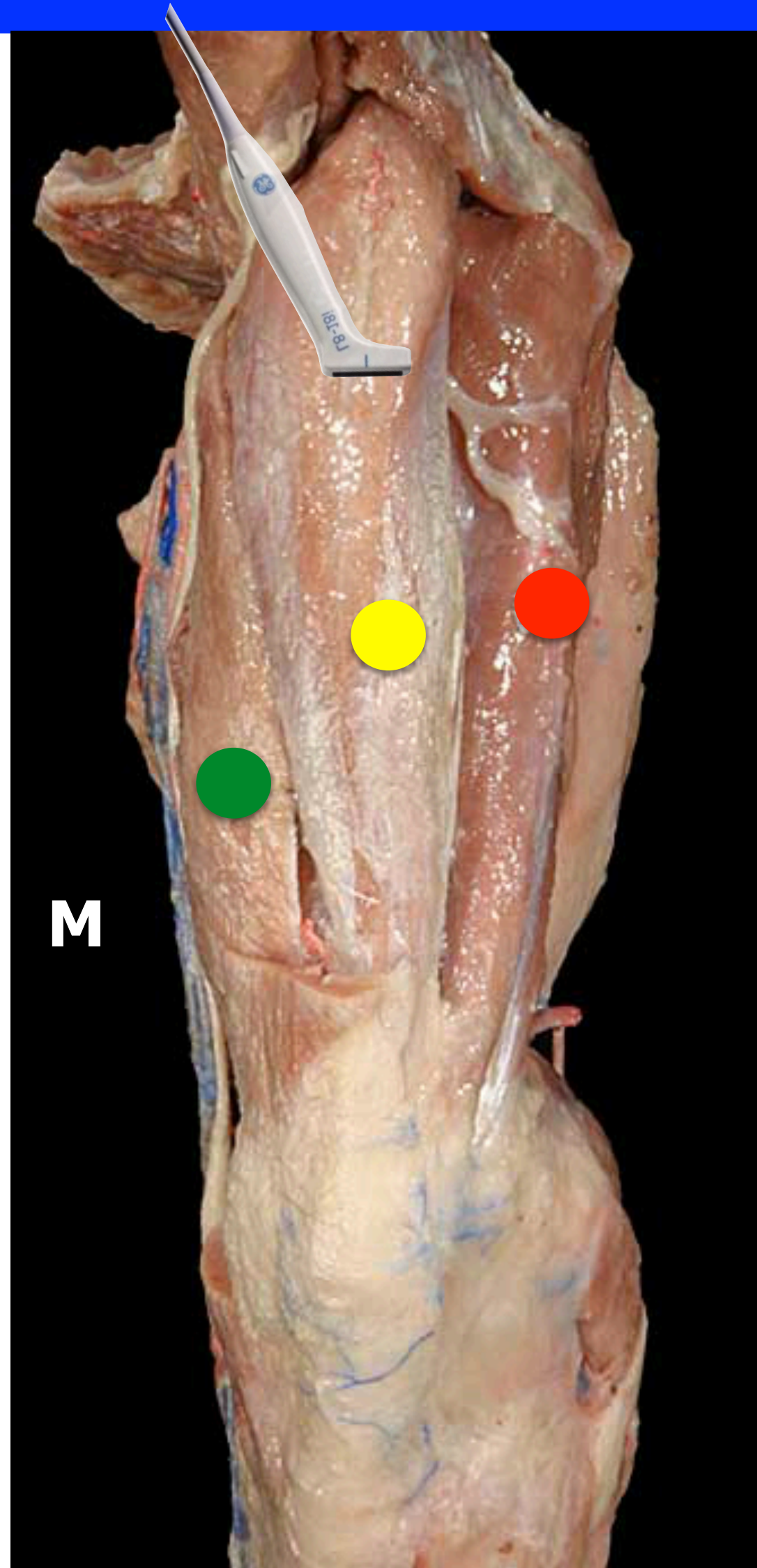
TIS 0.1
L 4-15 MSK

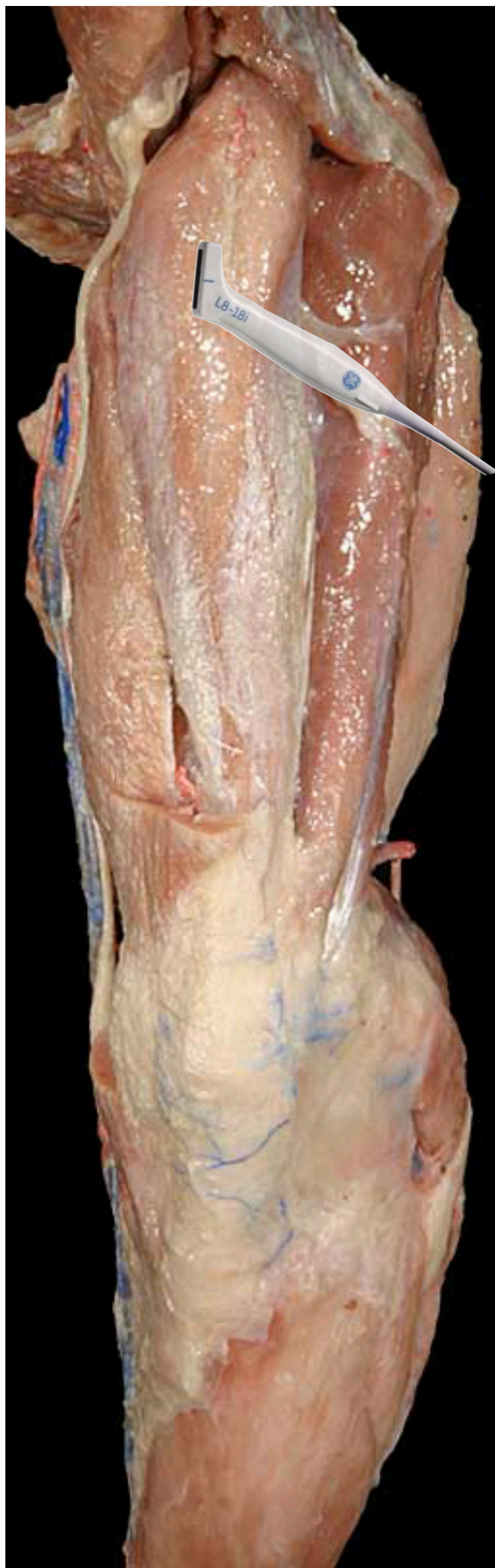TEI D 37 mm XV/M +2/4
PRC 17/1/1/10 PRS 0

TIS 0.1



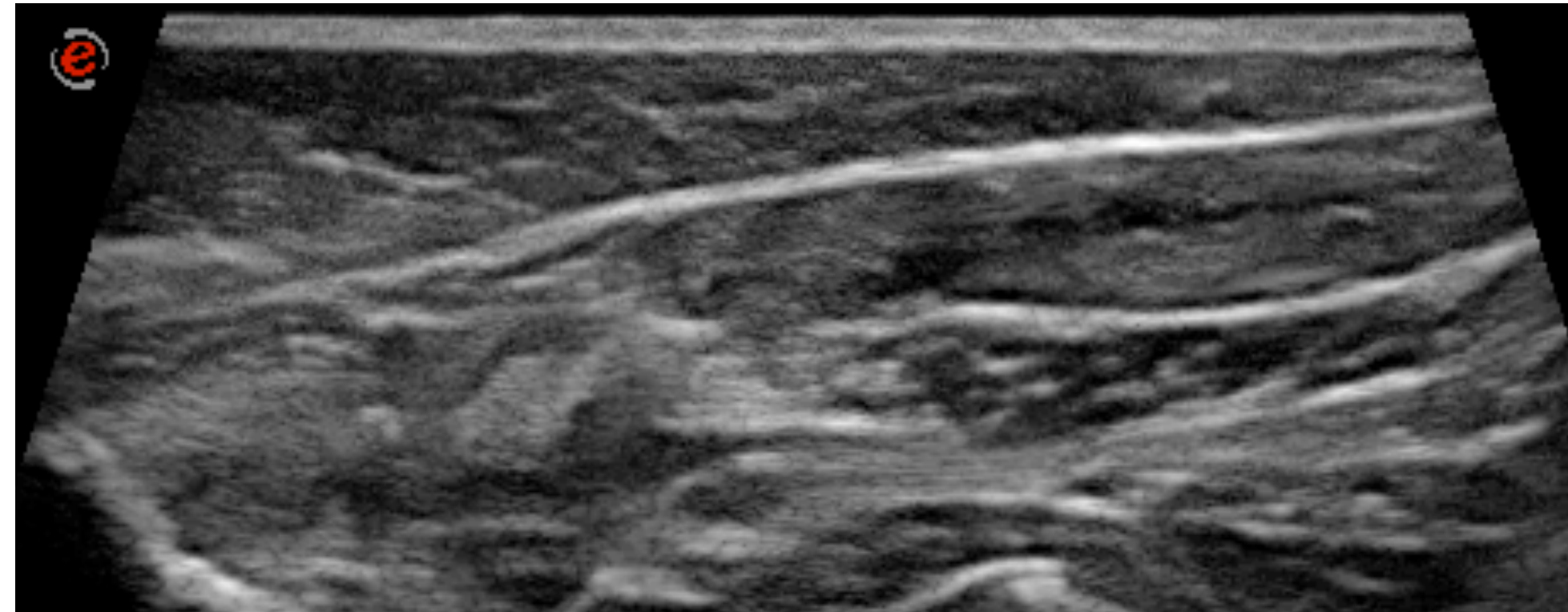
CRANIAL THIGH MUSCLES





RECTUS FEMORIS

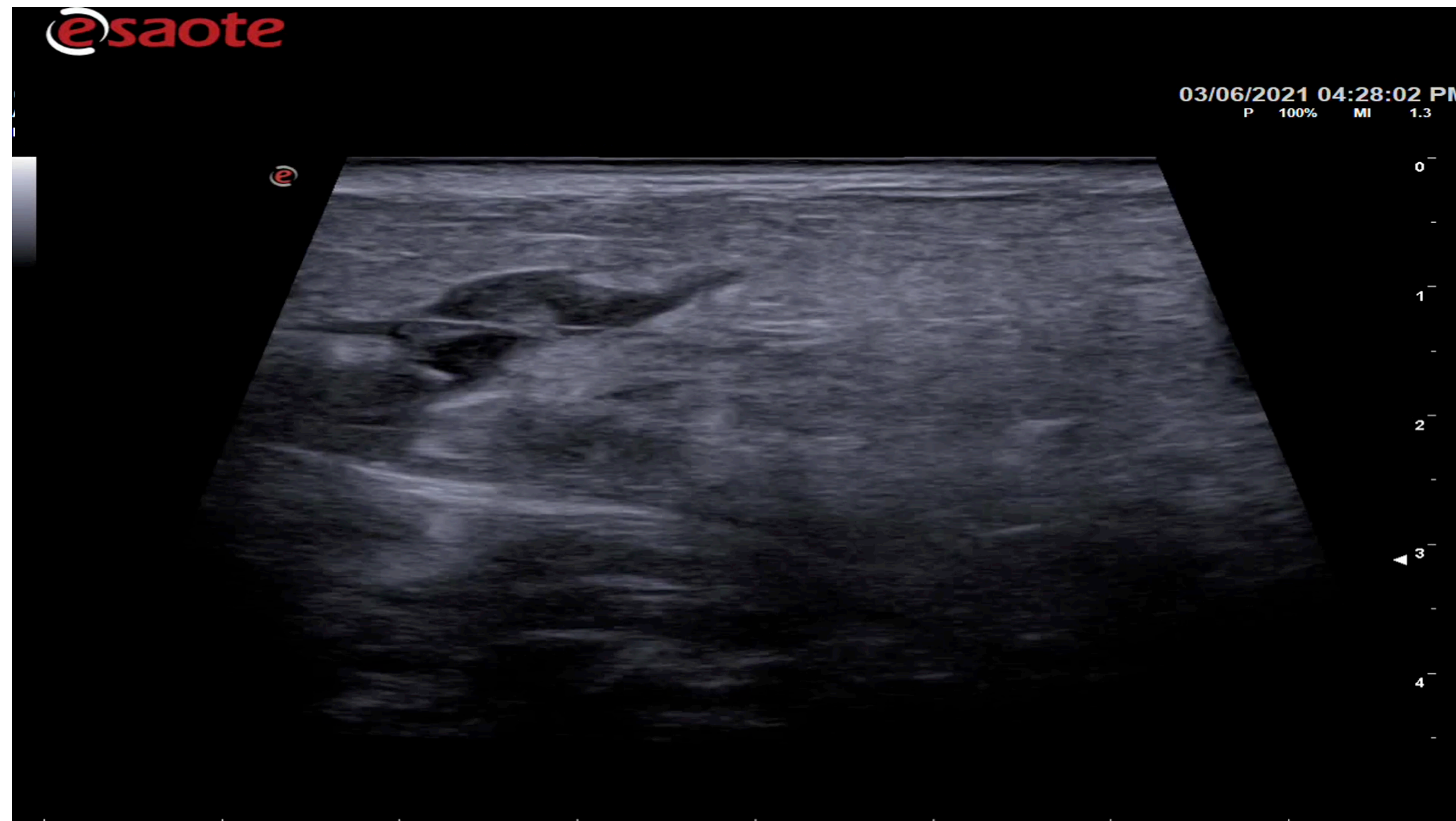
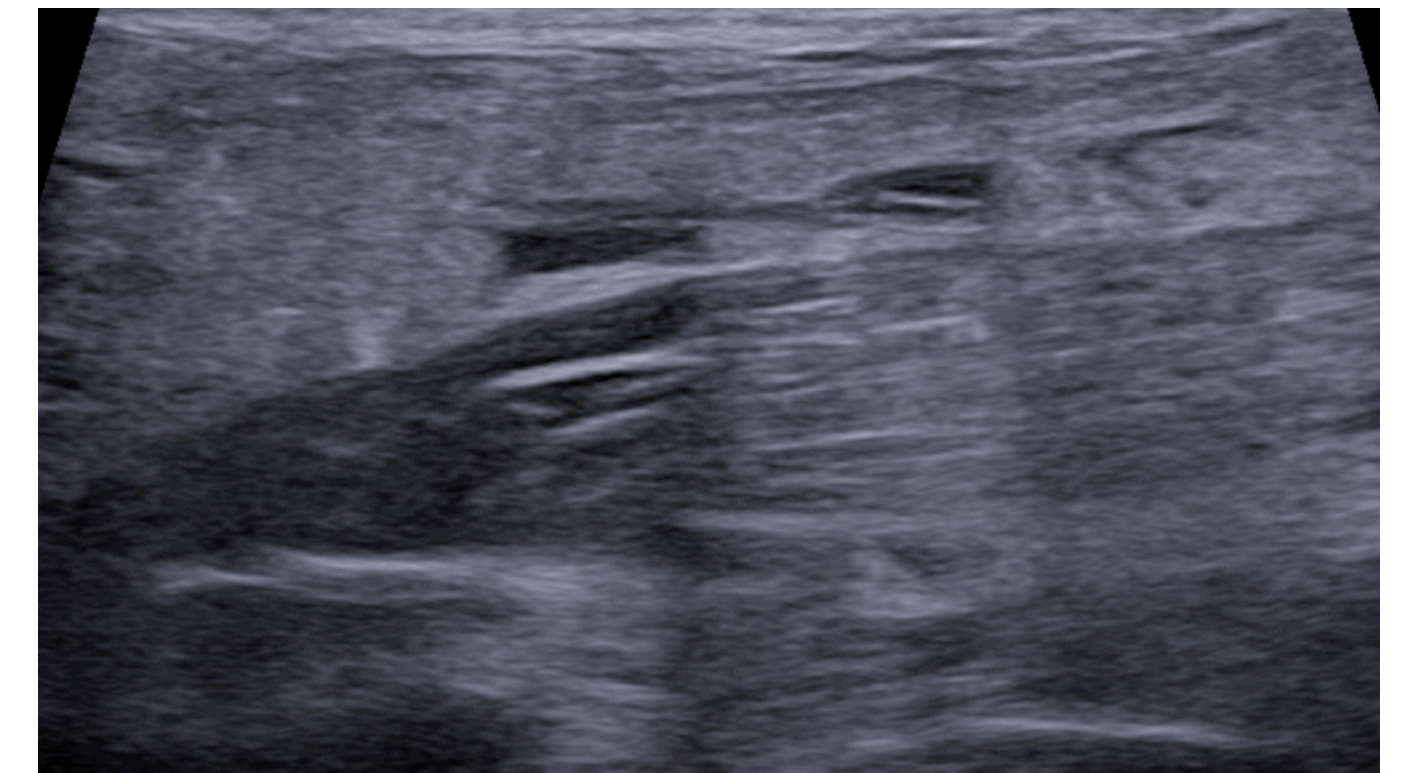
Normal anatomy
Longitudinal scan

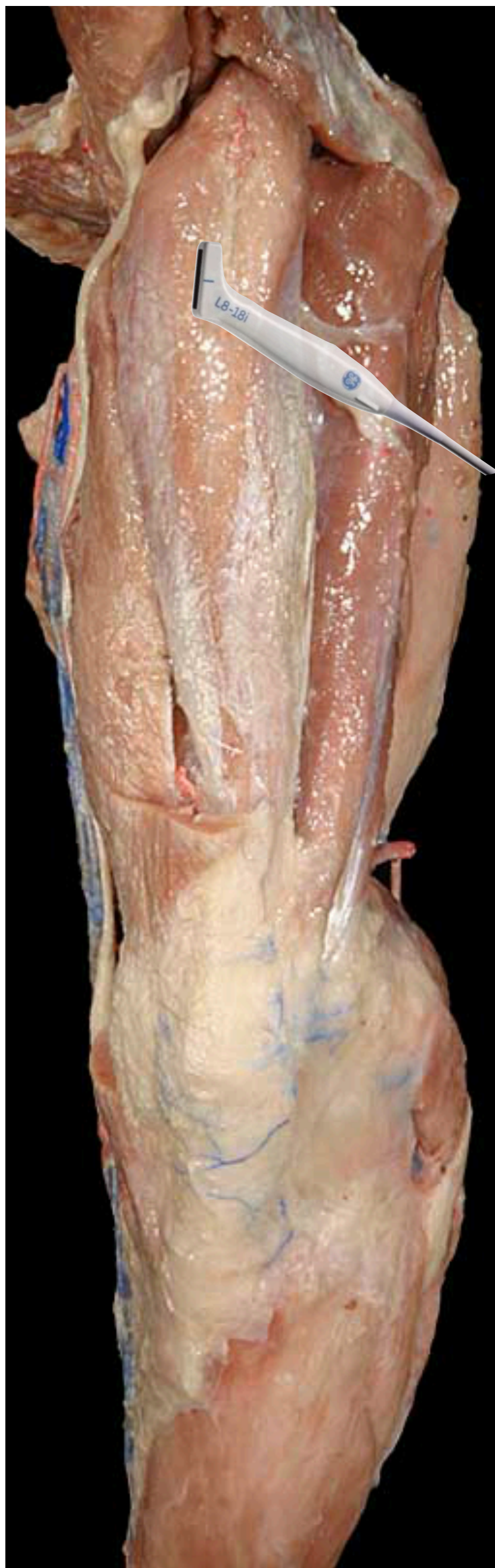

LESION AT ORIGIN

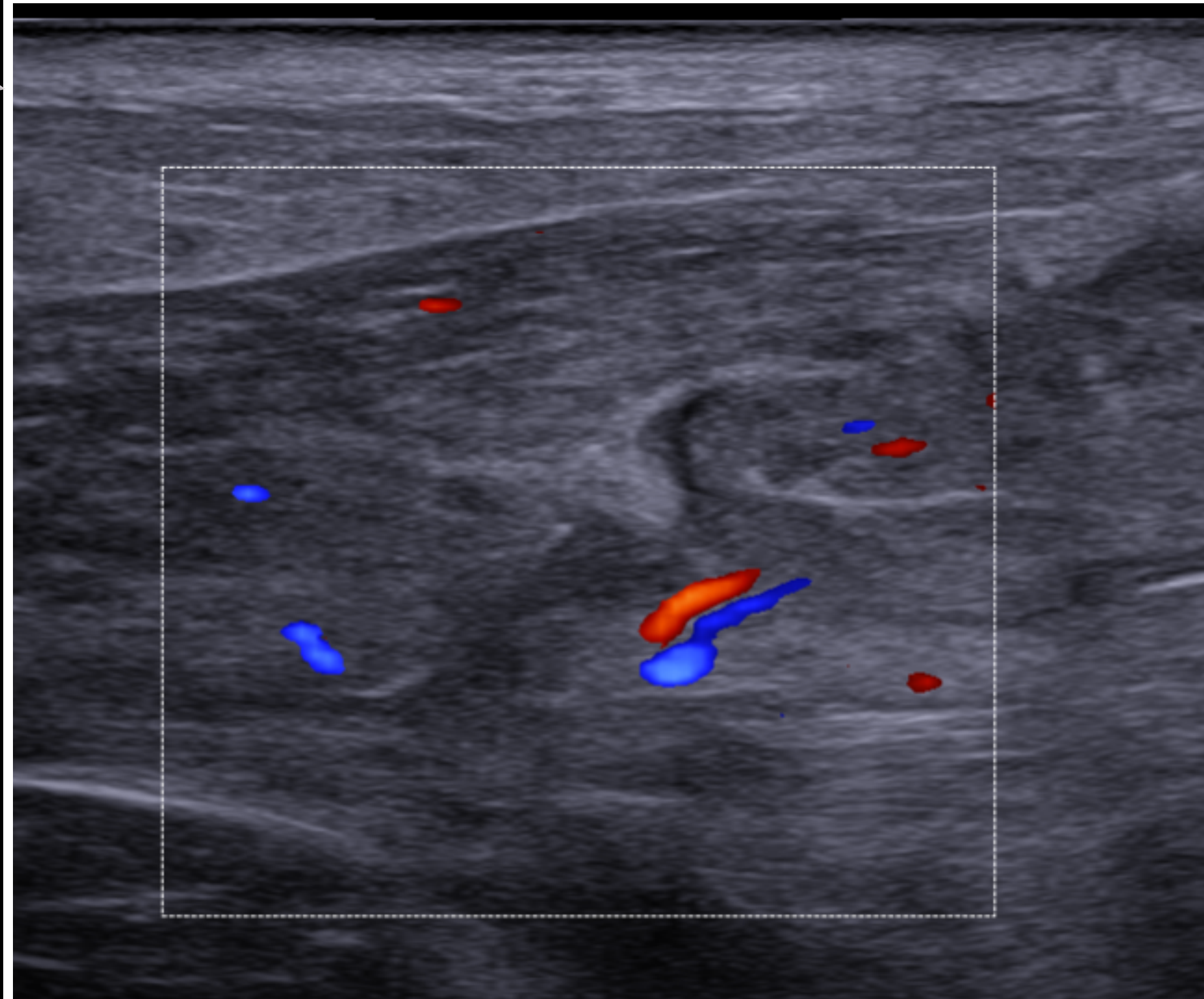
Border Collie

2 yo; M





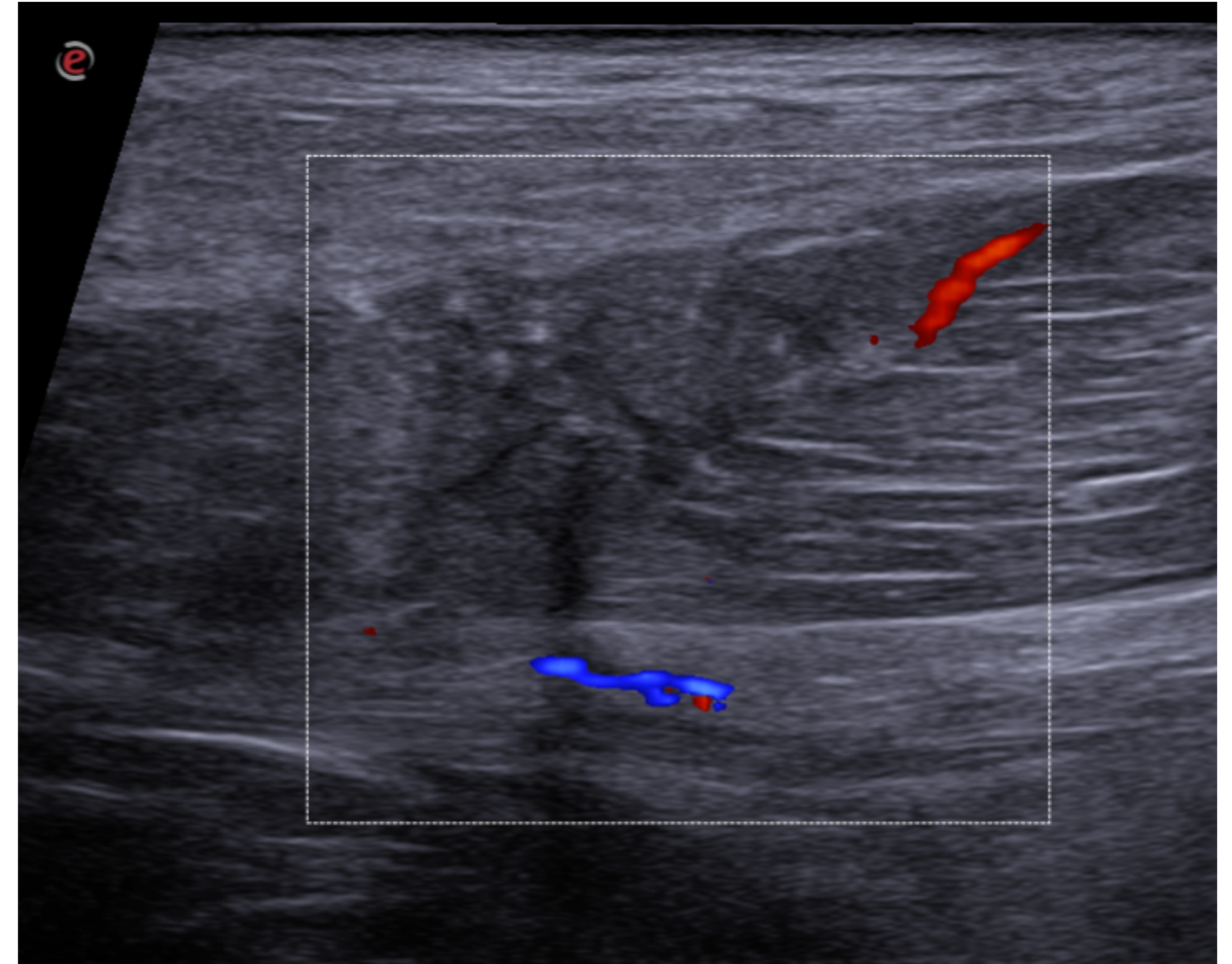
RECTUS FEMORIS

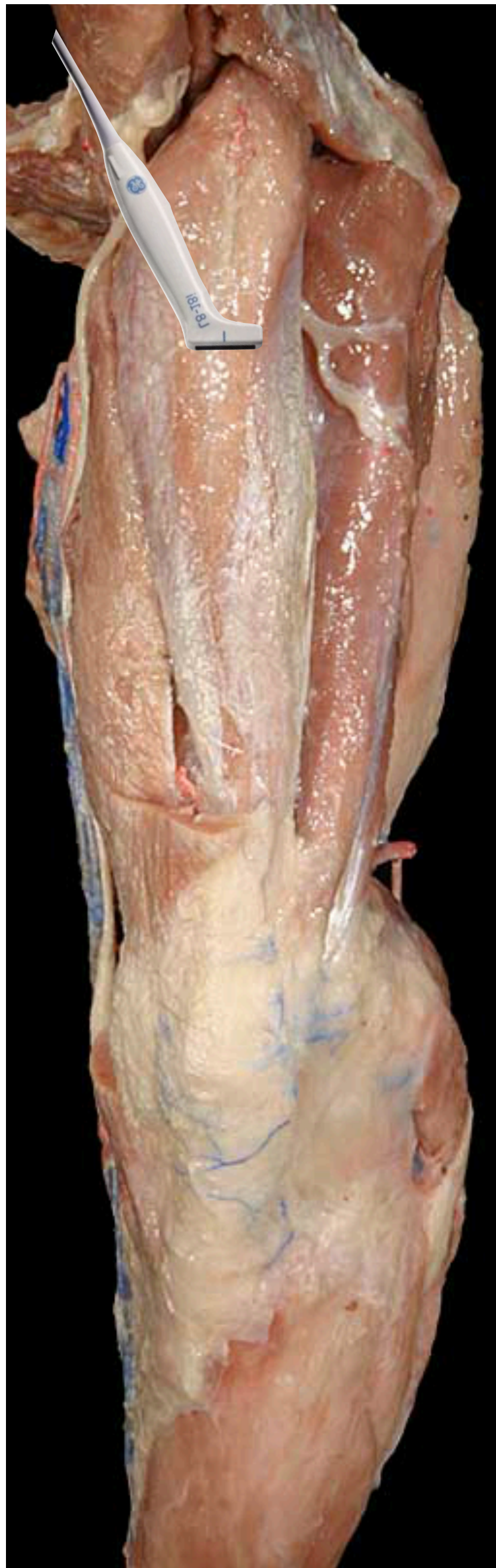

LESIONE ALL'ORIGINE

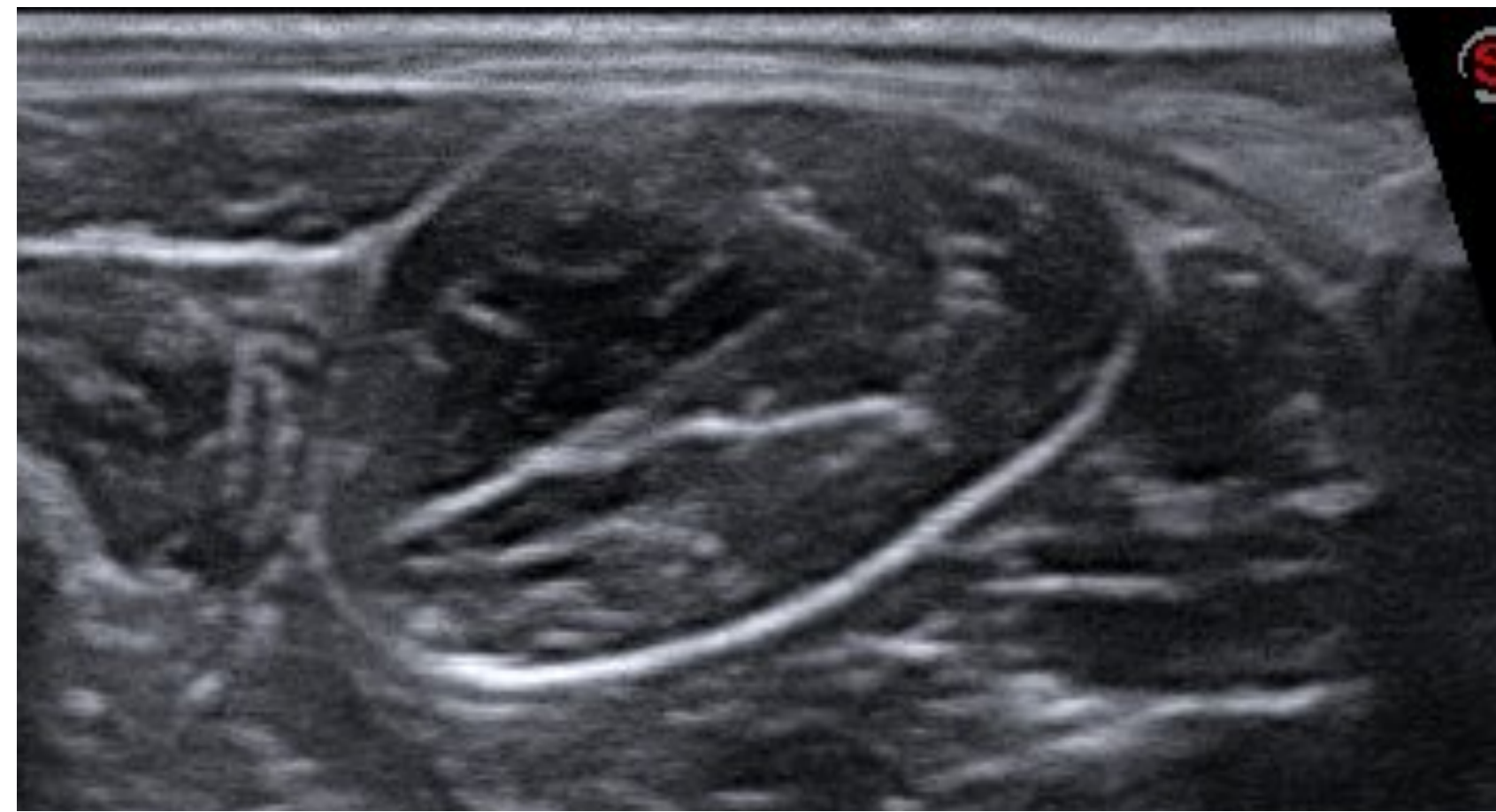Border Collie

2 aa; M

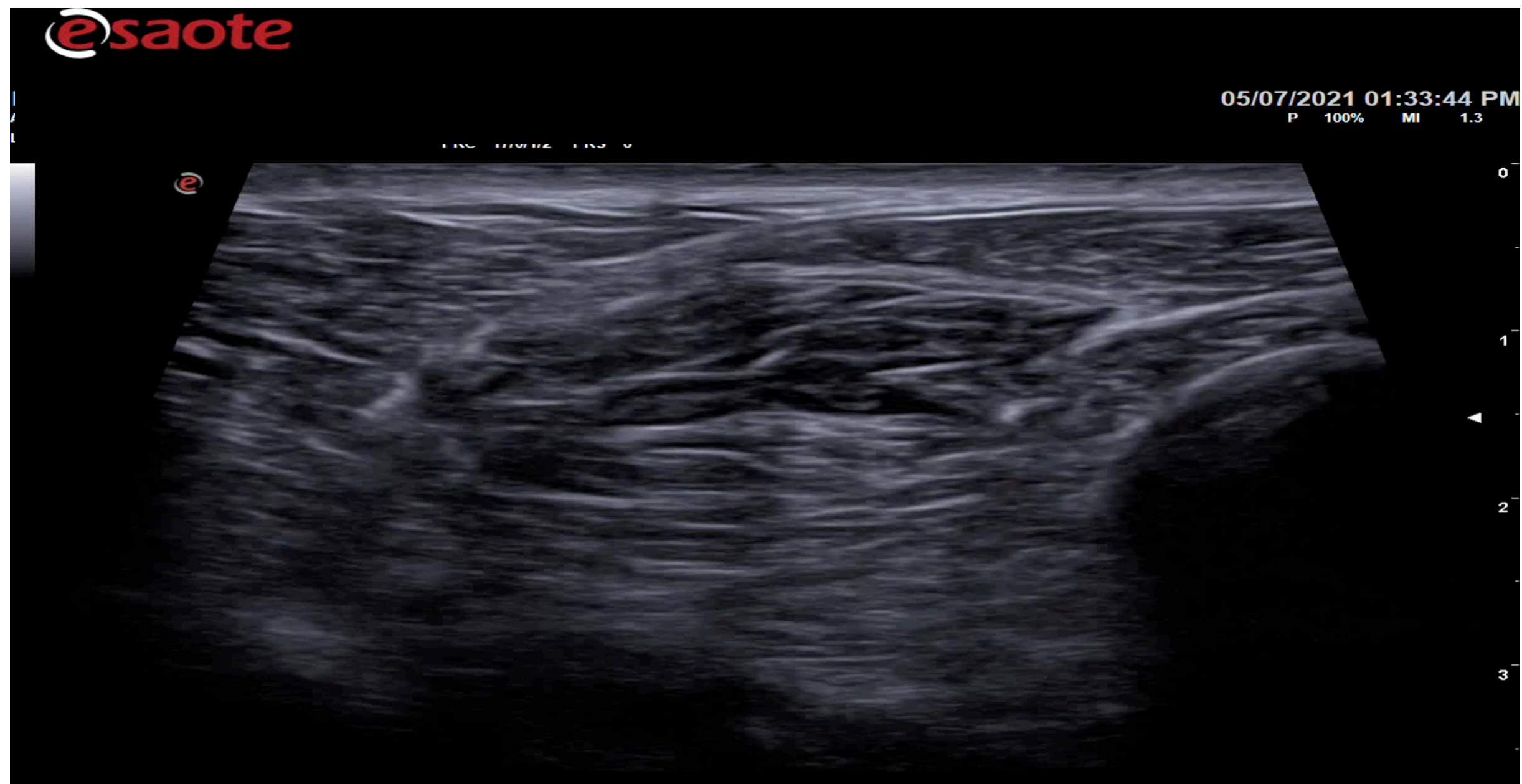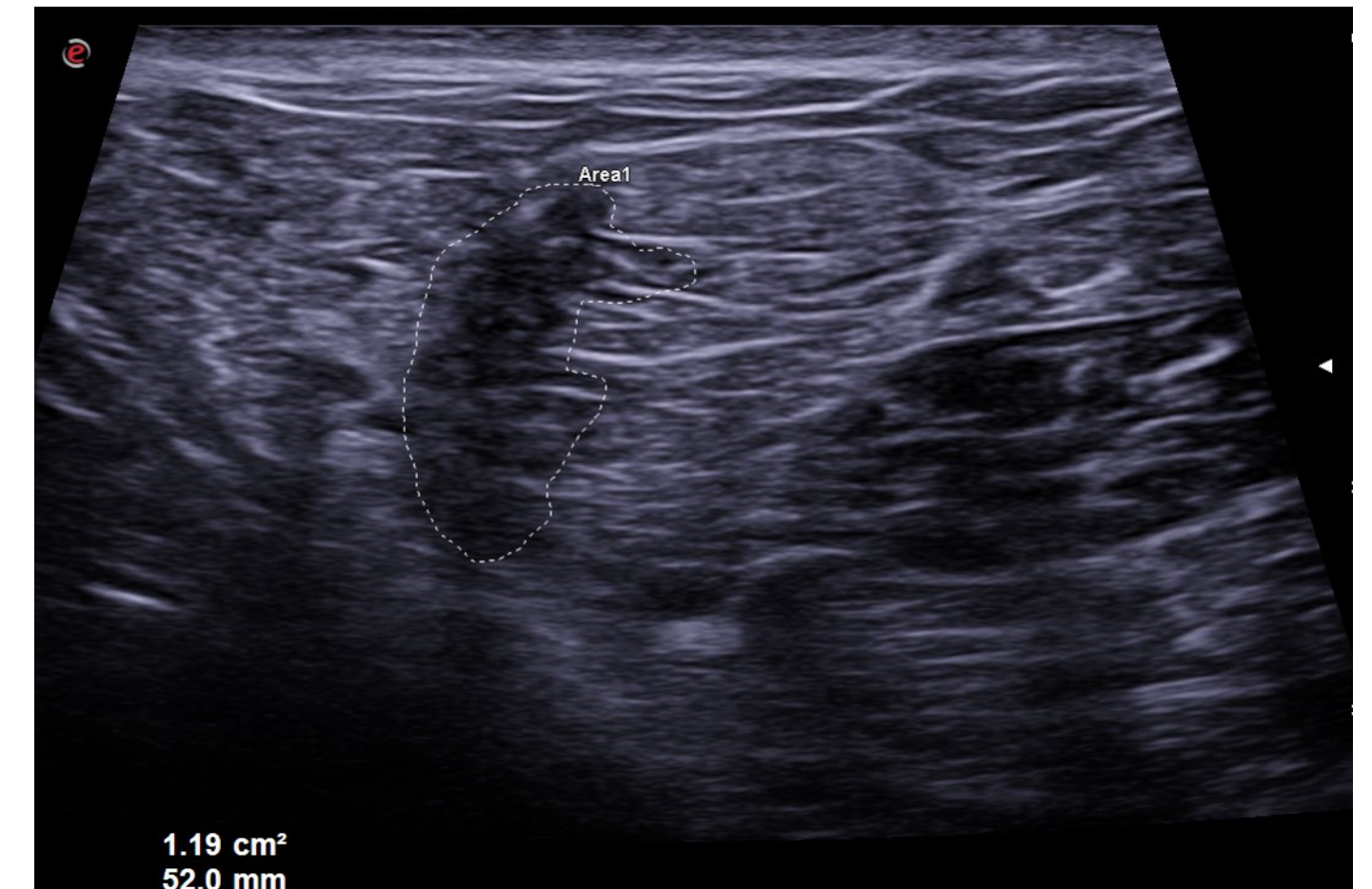




RECTUS FEMORIS
Transverse
Normal anatomy



**LESION AT
MUSCLE BELLY
Border Collie
2 yo; M**





CACOS

**MALINOIS
3 Years old**

**Schutzund/IPO
(Internationale Prüfungsordnung)**

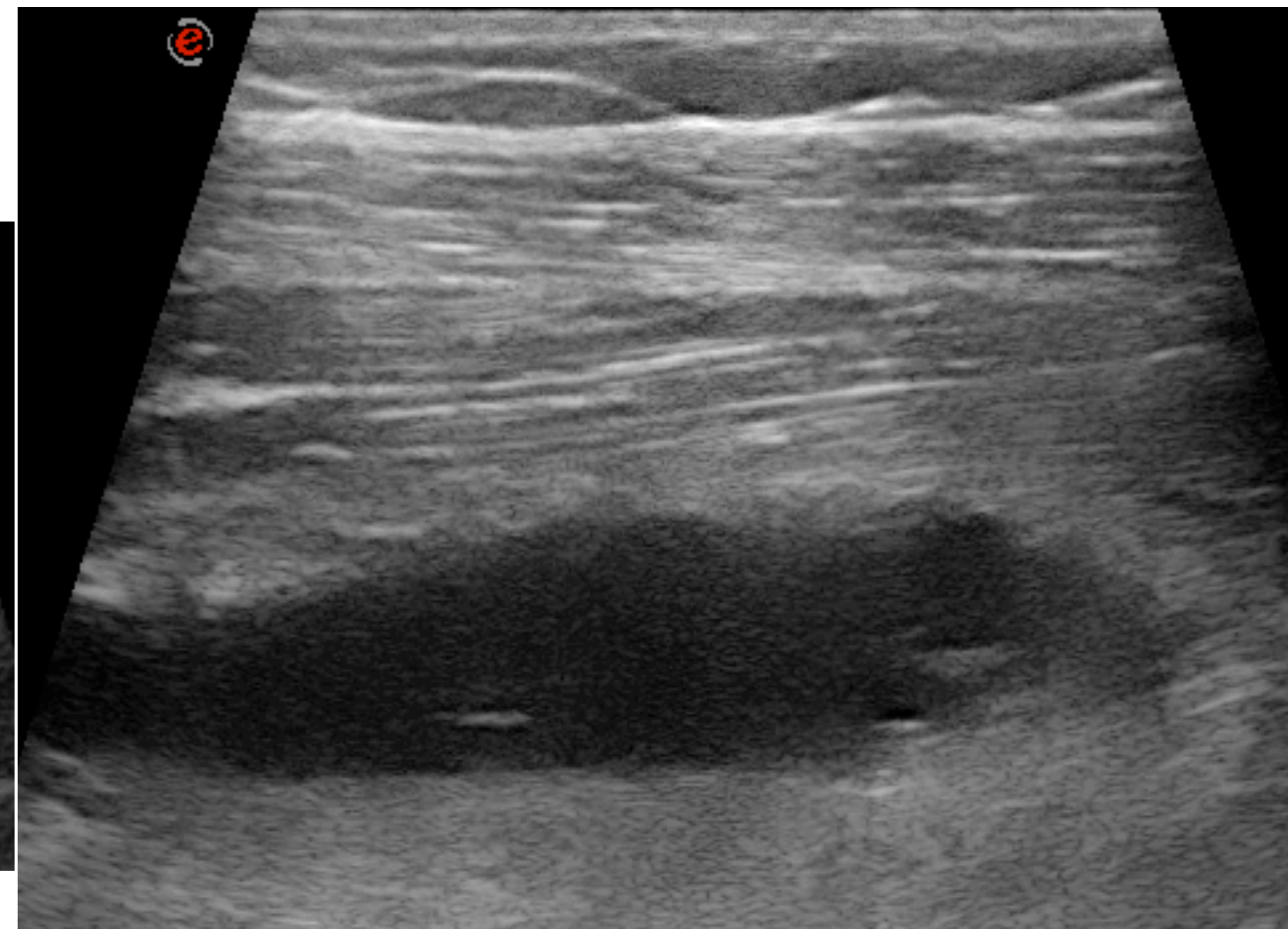
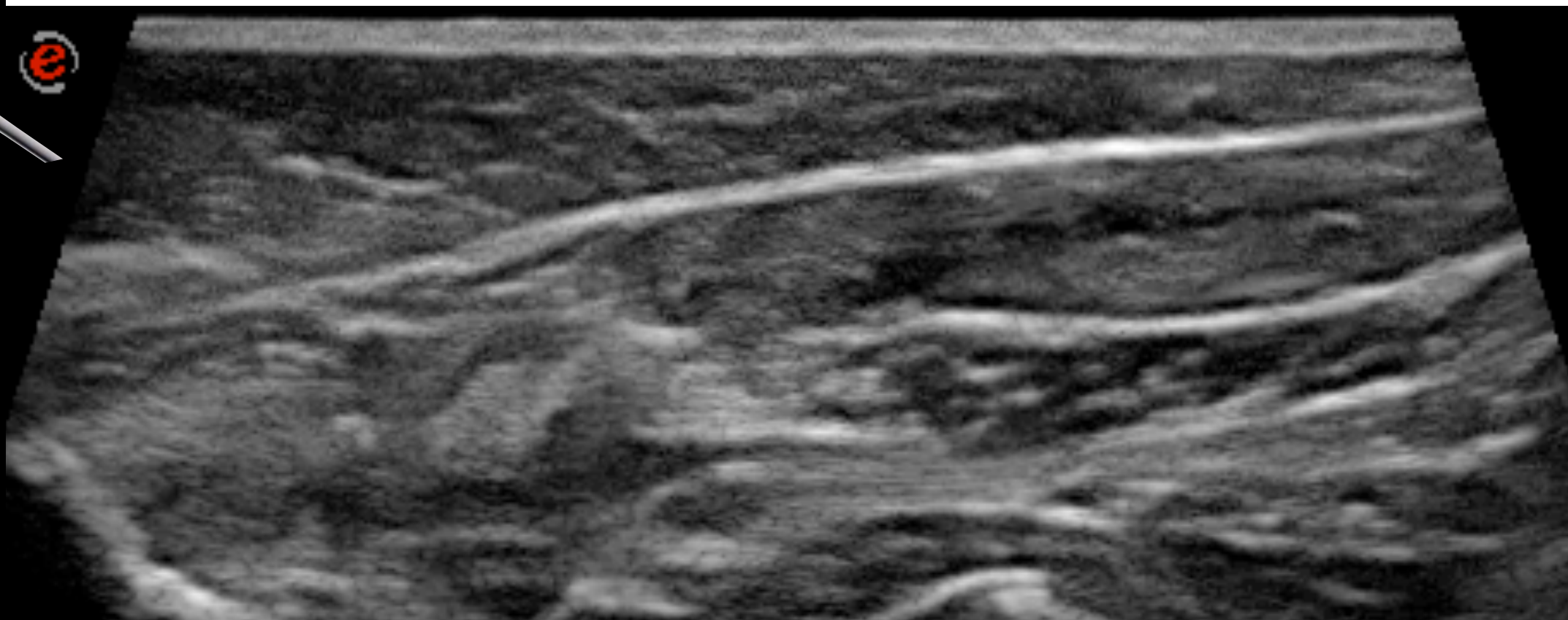
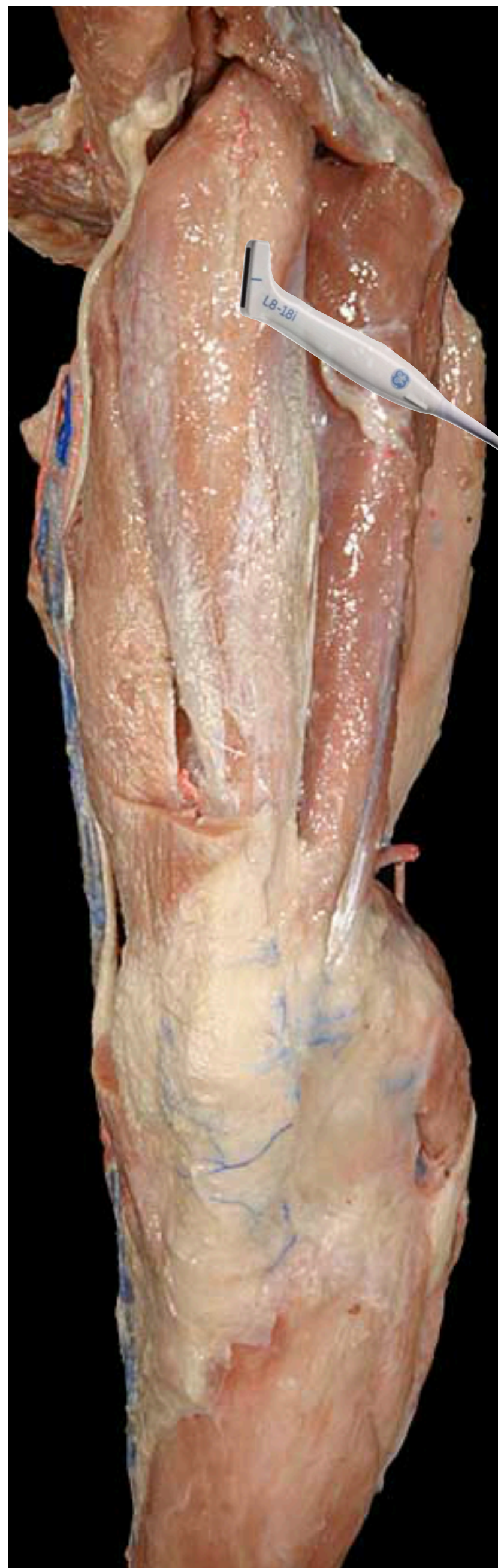

RECTUS FEMORIS

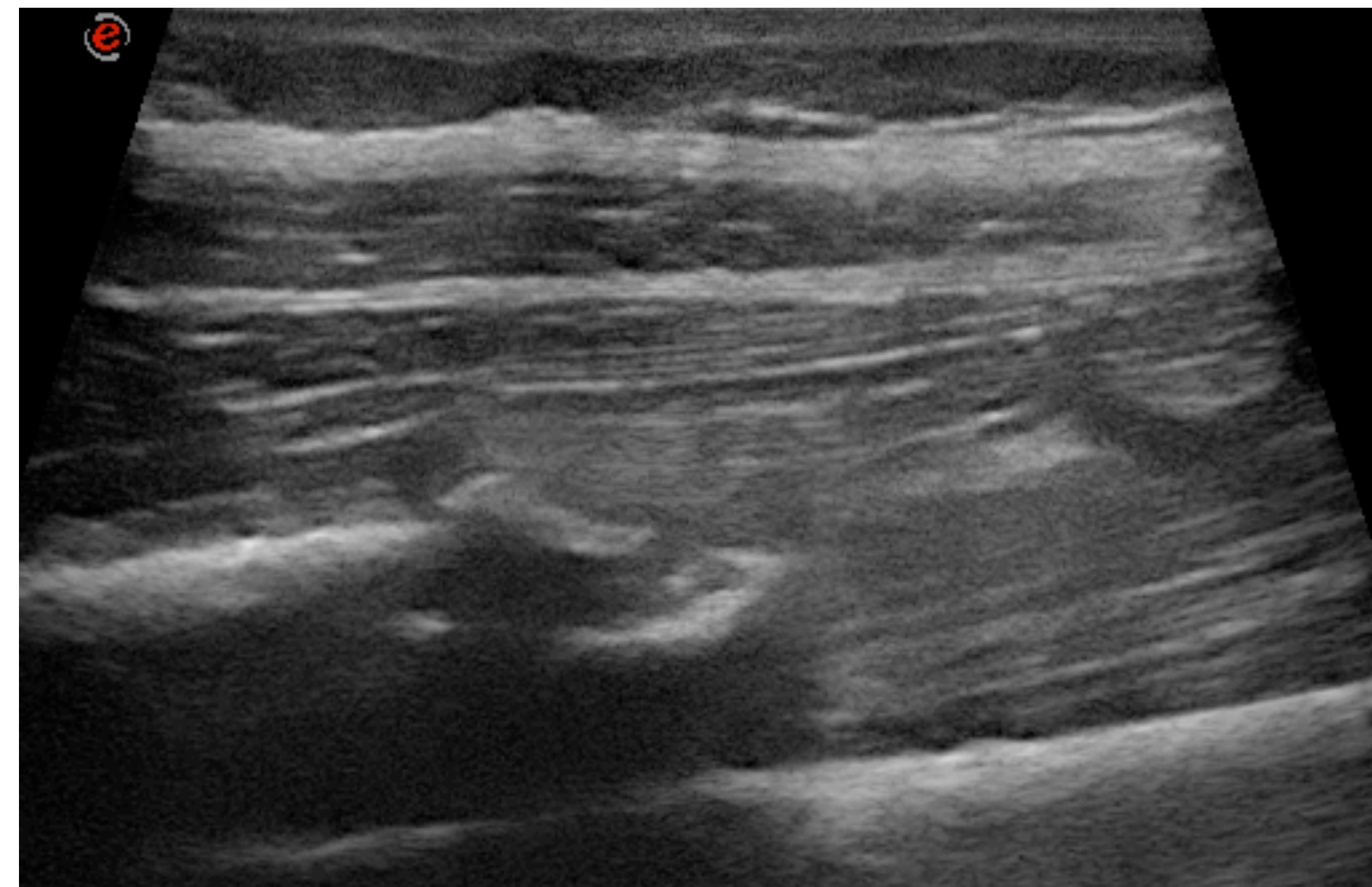
Longitudinal scan

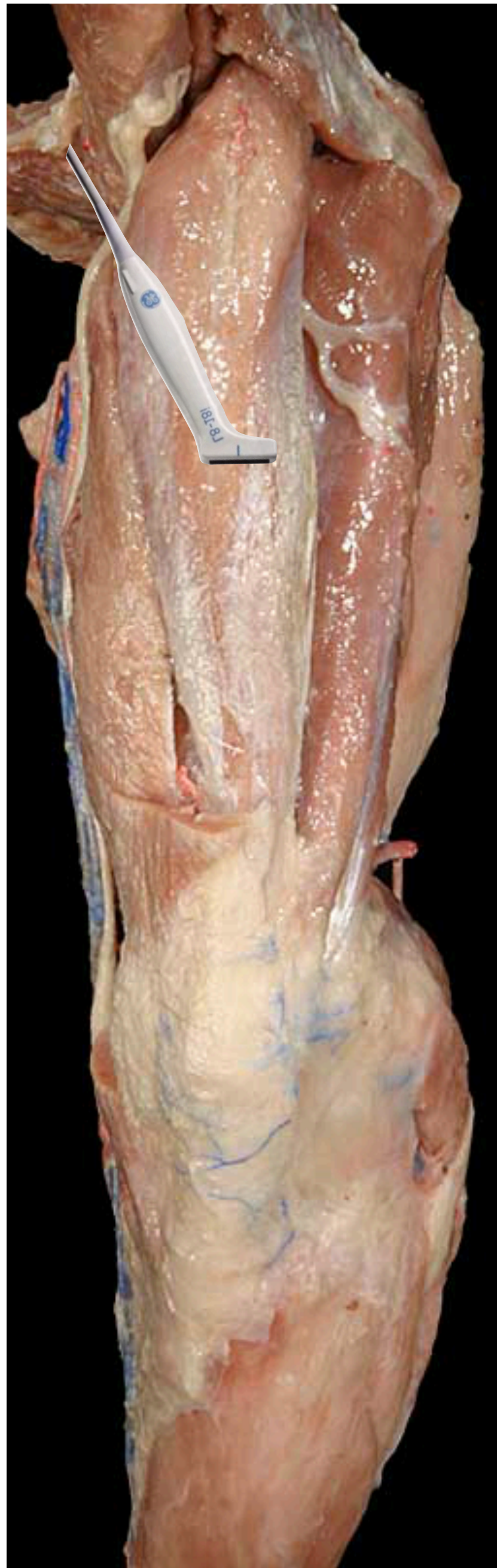Normal anatomy

LESION at MUSCLE BELLY

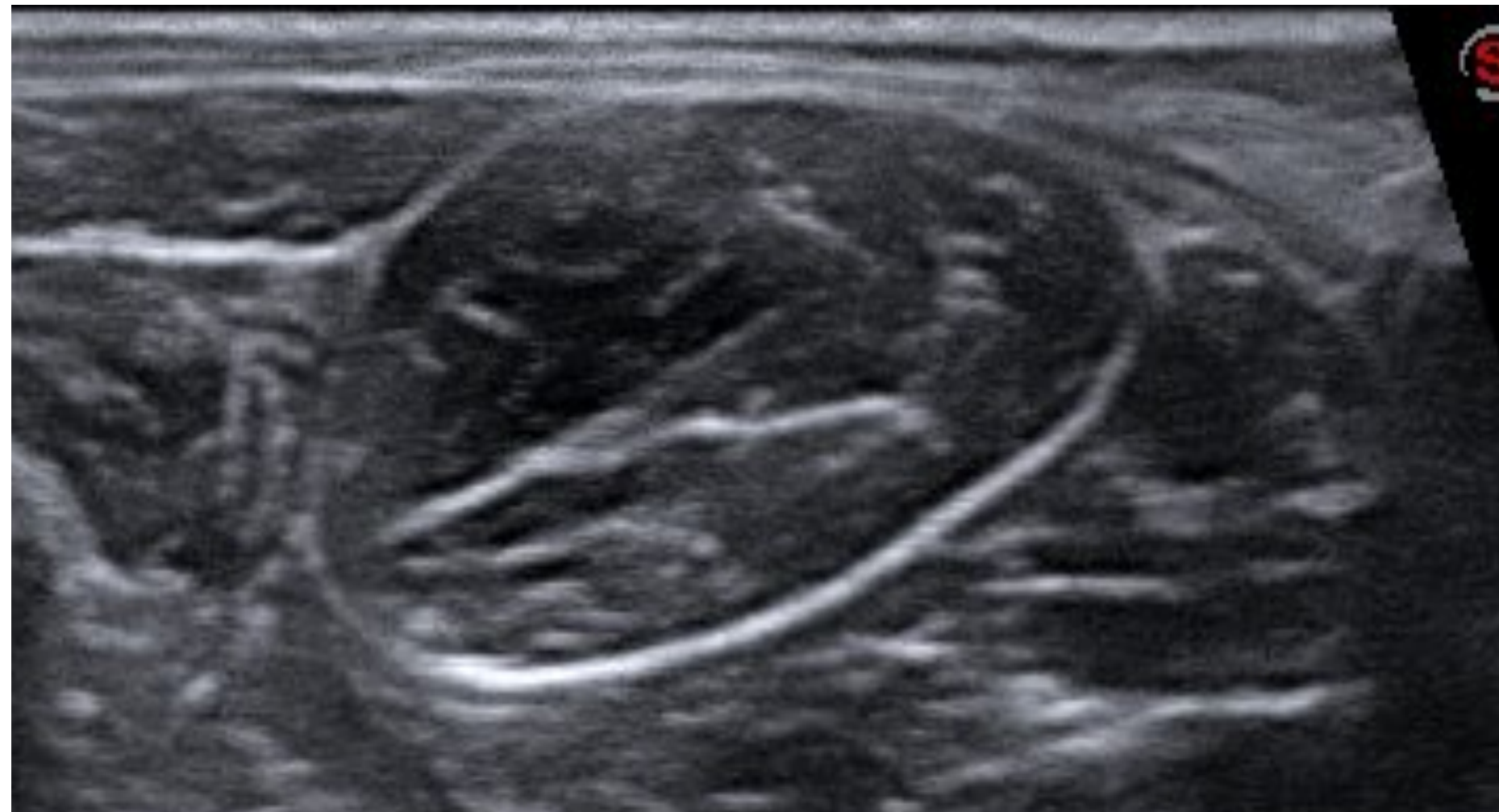

Follow-up 2 Months

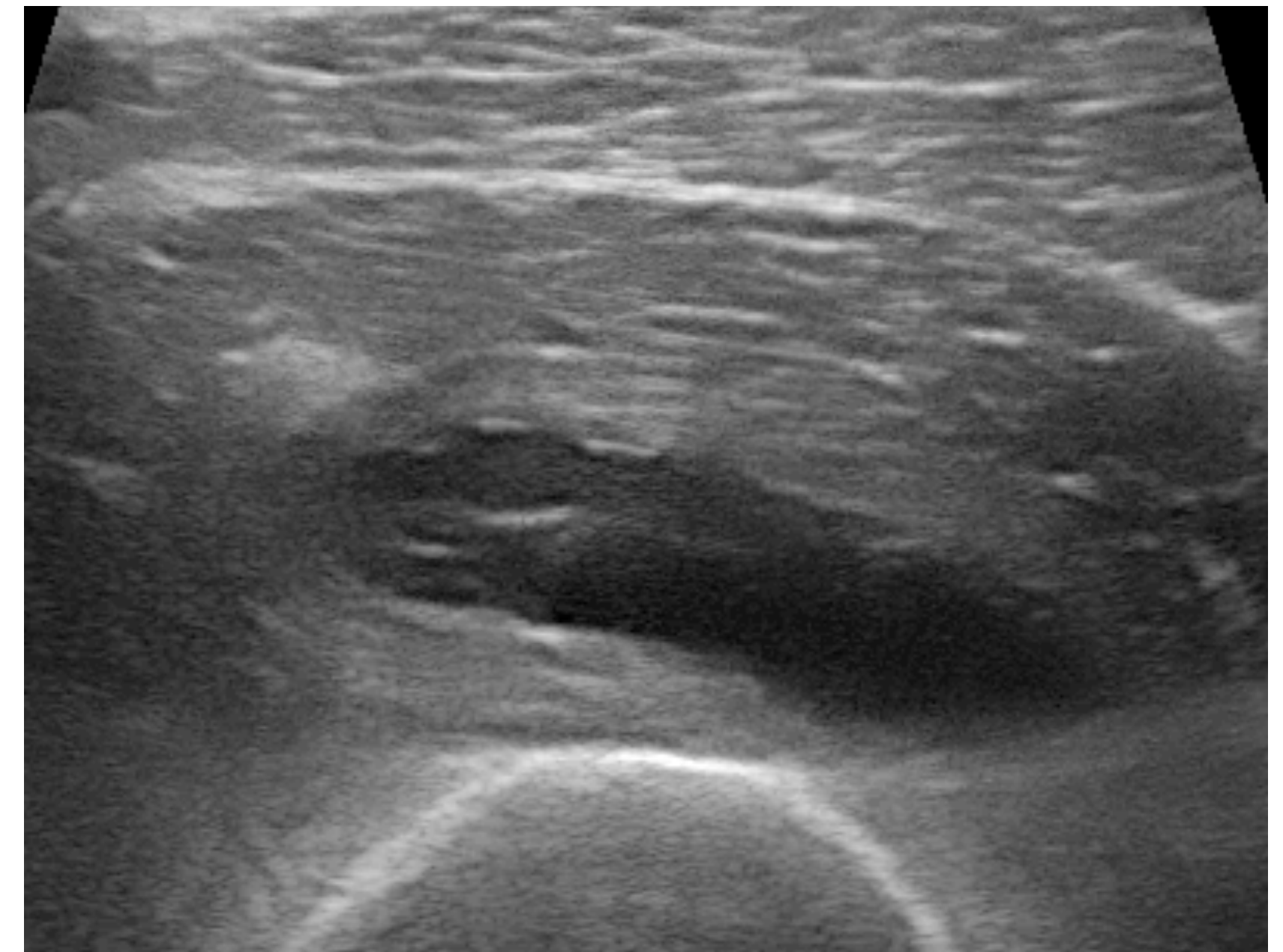




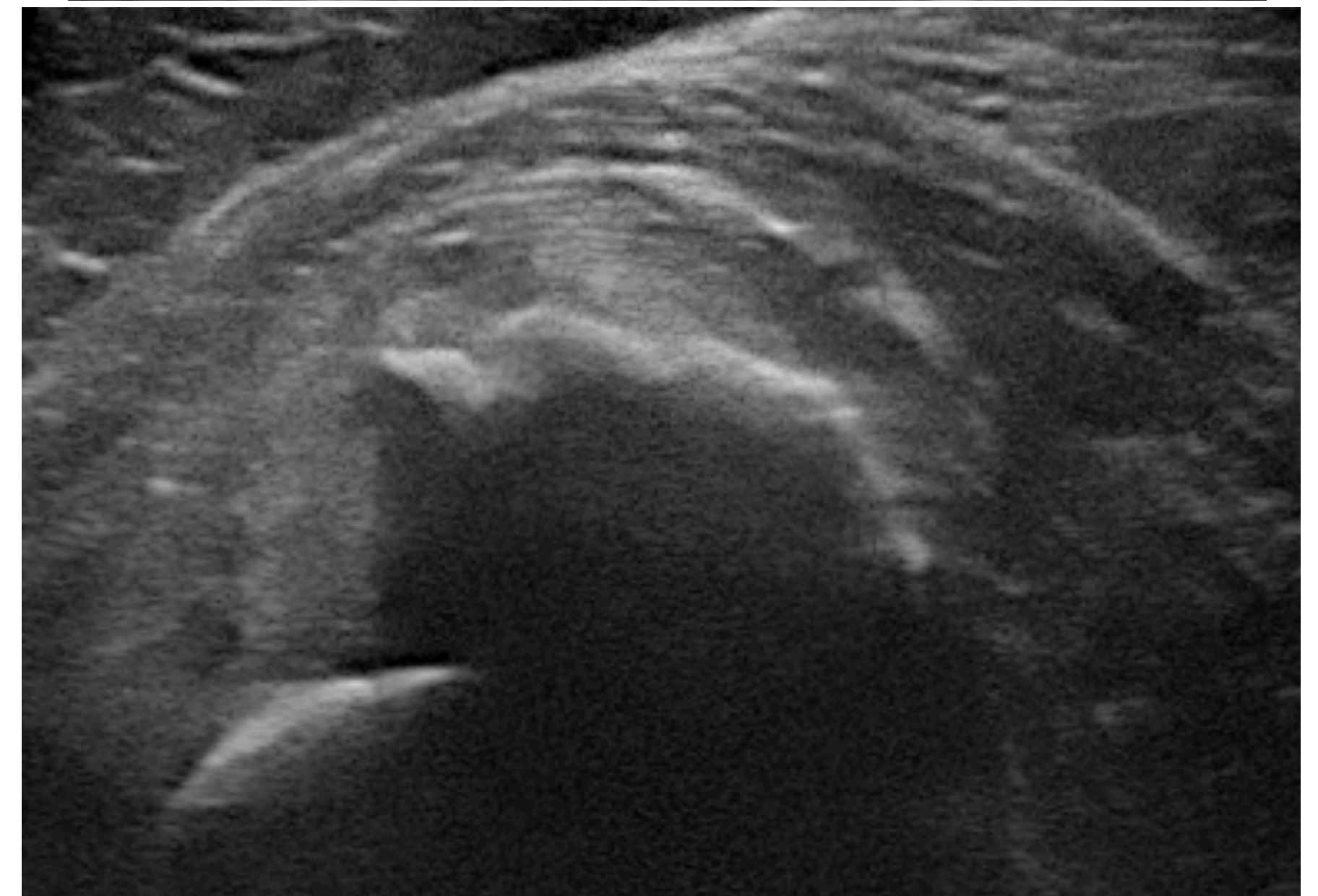
RECTUS FEMORIS
Transverse scan
Normal anatomy



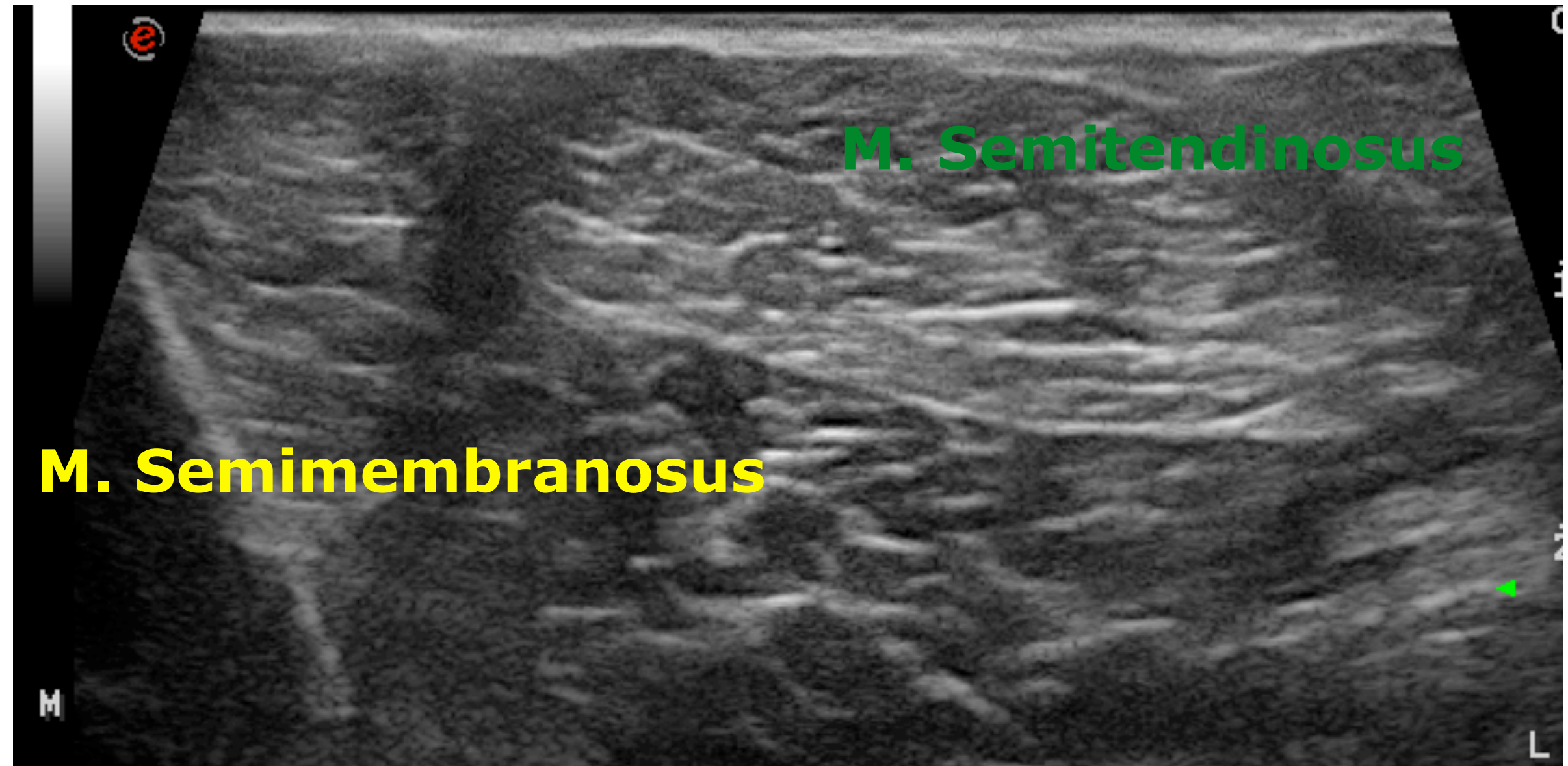
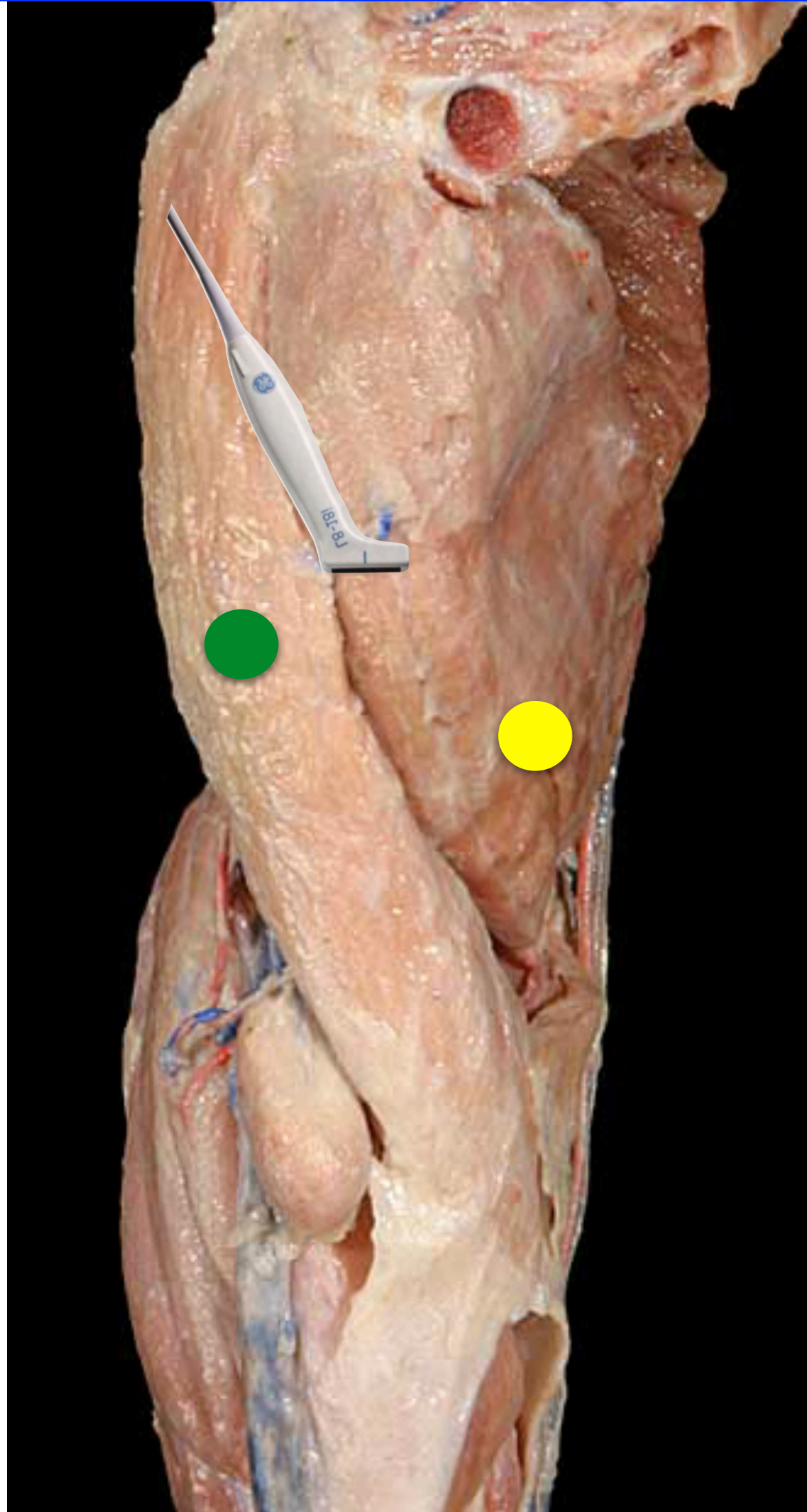
LESION at MUSCLE BELLY



Follow-up 2 Months




CAUDAL THIGH MUSCLES



M. Semimembranosus

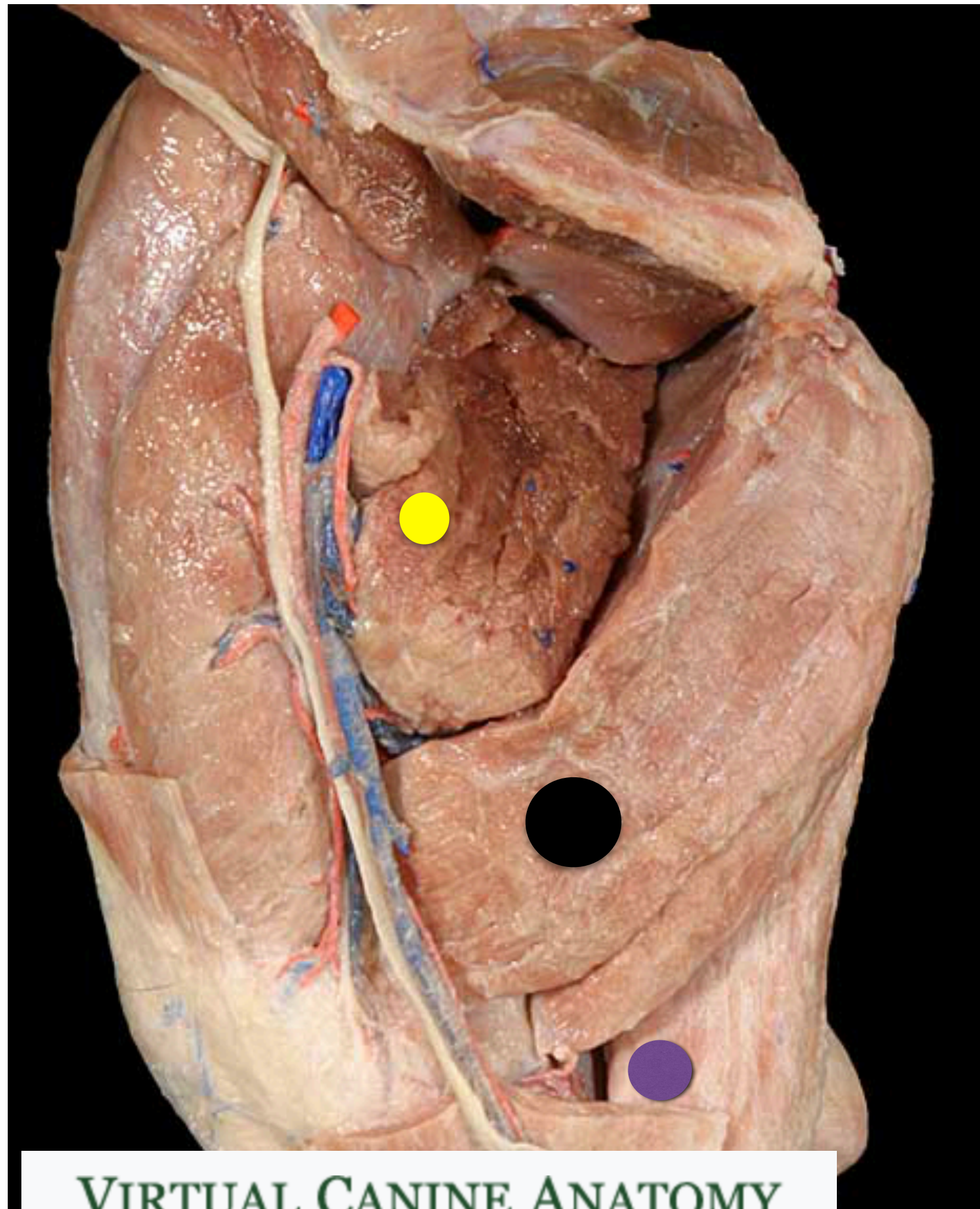
O: ischiatic tuberosity I: caudomedial aspect of distal femur and medial proximal tibia




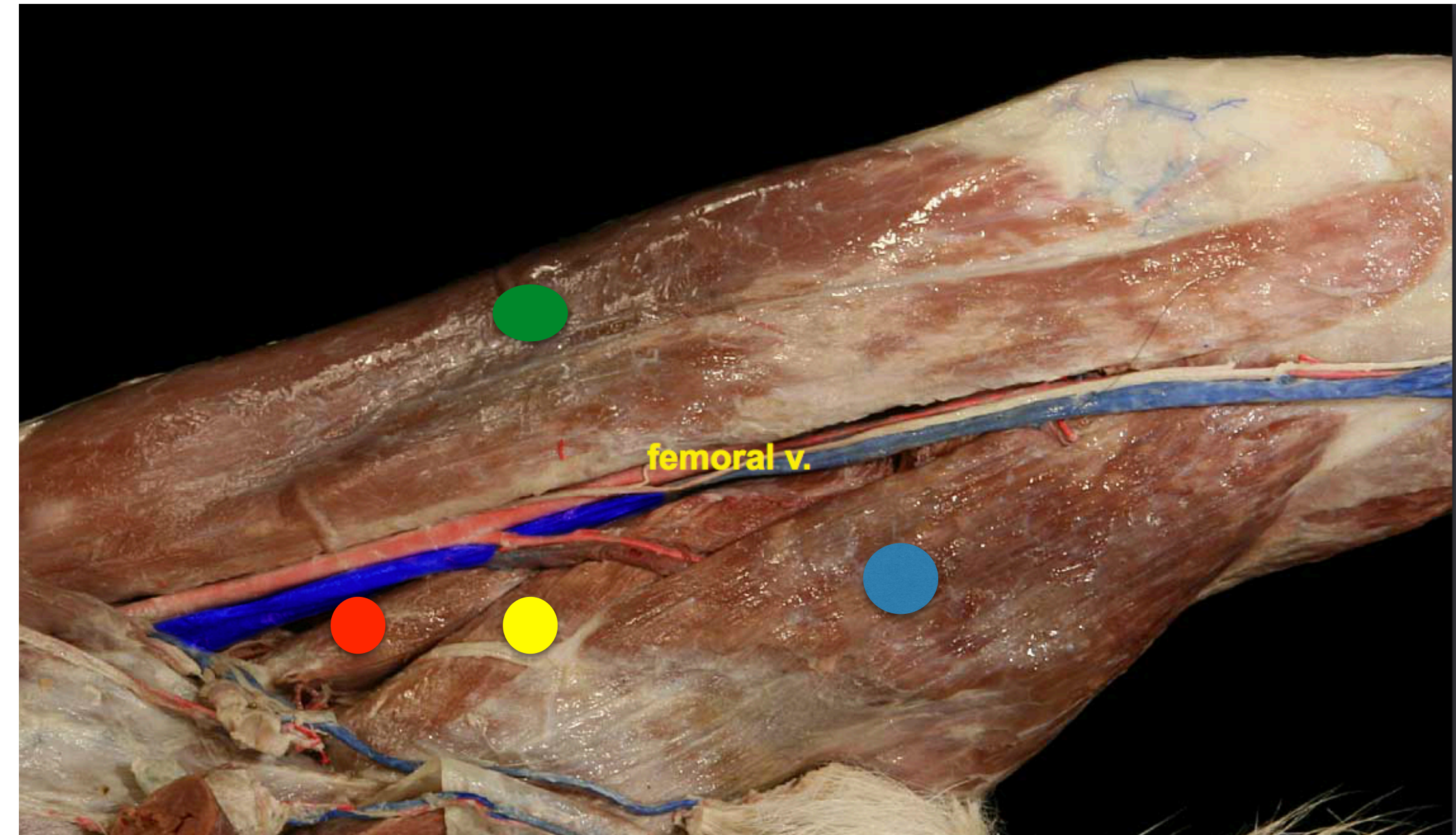
M. Semitendinosus

O: ischiatic tuberosity I: via fascia of the leg to medial body of tibia and tuber calcanei

MEDIAL THIGH MUSCLES




VIRTUAL CANINE ANATOMY




M. Sartorius

O: Cranial—crest of ilium and thoracolumbar fascia
 Caudal—iliac spine and ventral border of ilium
 I: Cranial—patella
 Caudal—cranial border of tibia




M. Pectineus

O: prepubic tendon and iliopubic eminence
 I: distal end of medial lip of caudal femur




M. Gracilis

O: pelvic symphysis
 I: cranial border of the tibia and tuber calcanei



M. Adductor

O: pelvic symphysis, ventral parts of pubis and ischium
 I: lateral lip of caudal femur



M. Semimembranosus O: ischiatic tuberosity I: caudomedial aspect of distal femur and medial proximal tibia



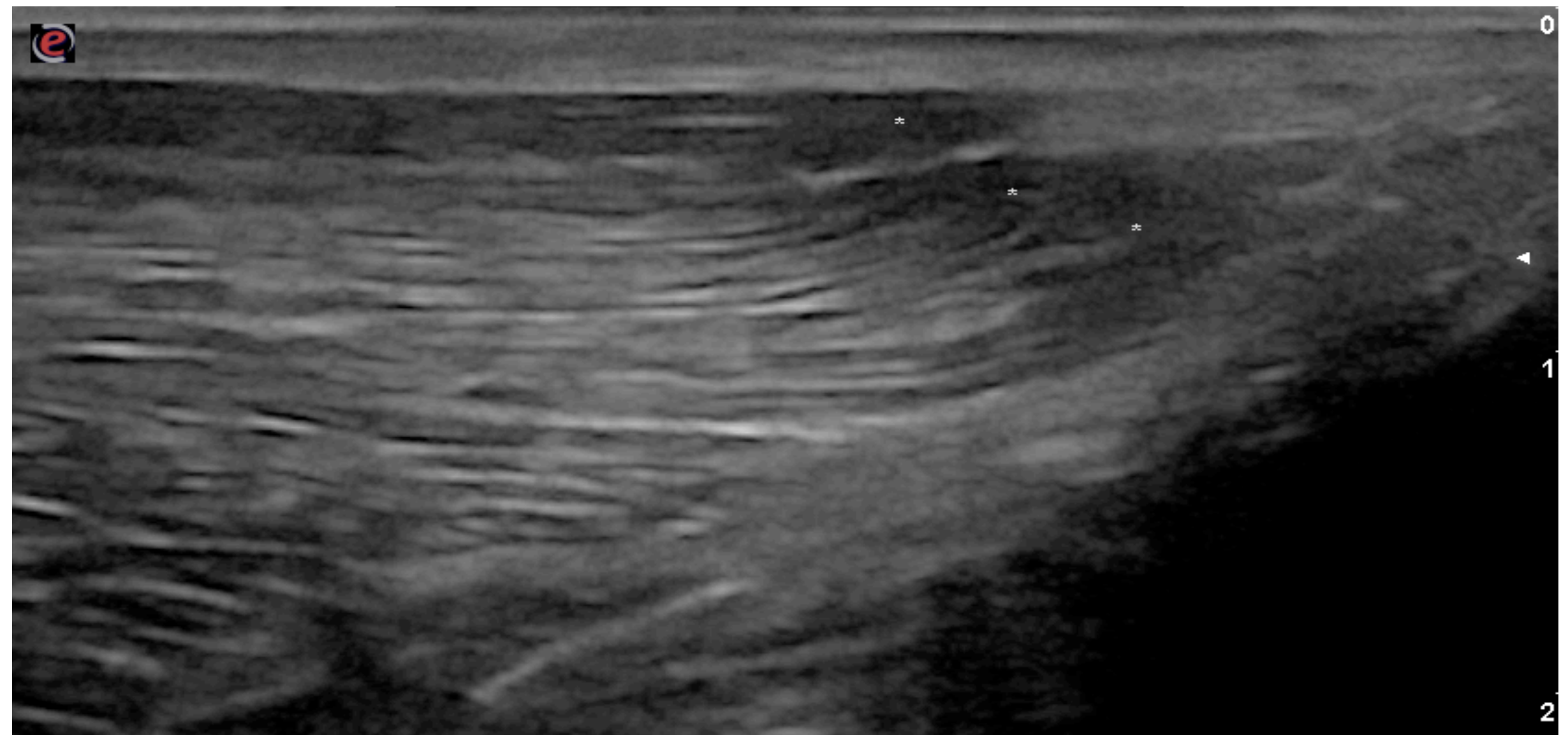
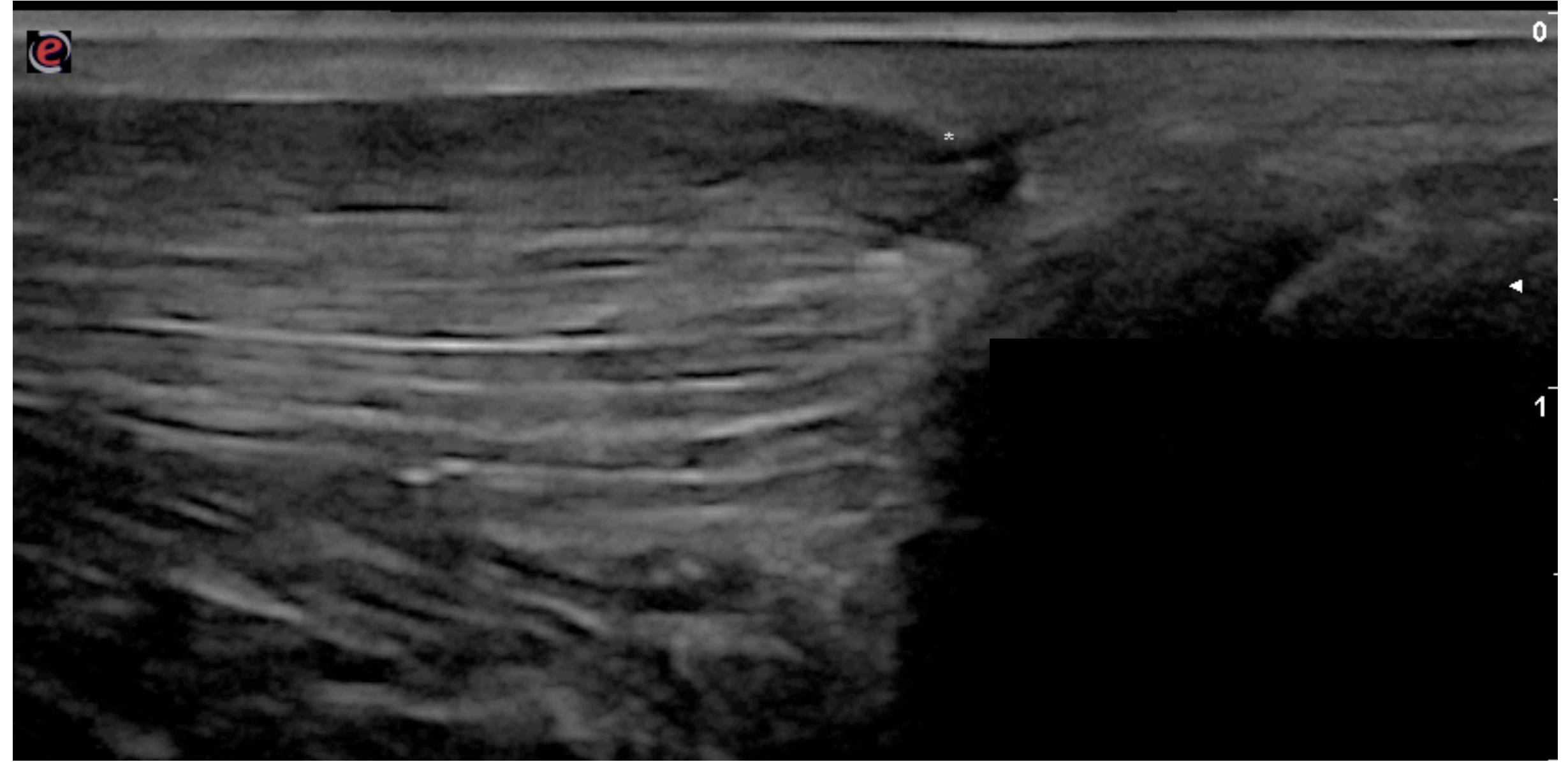
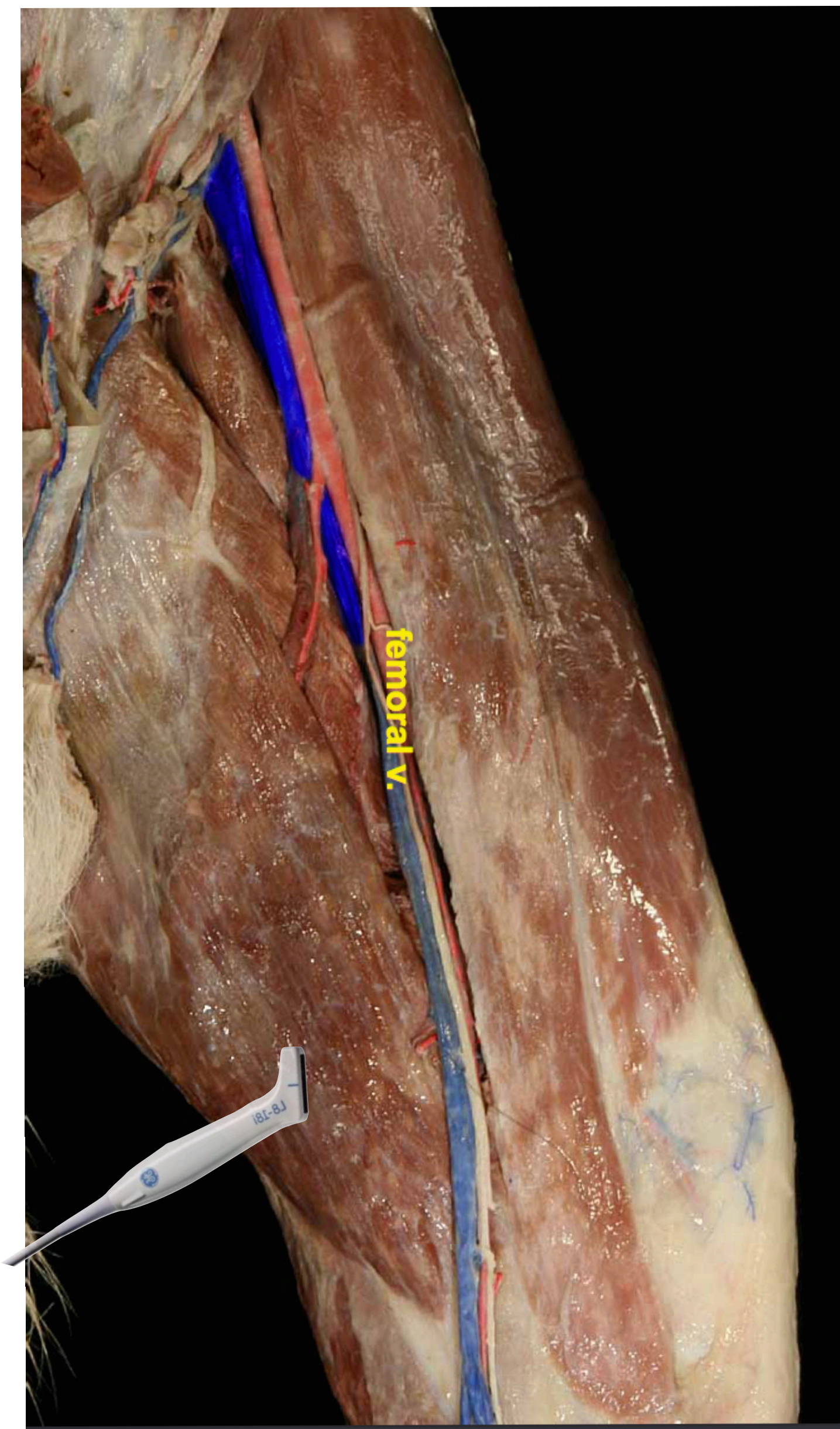
M. Semitendinosus O: ischiatic tuberosity I: via fascia of the leg to medial body of tibia and tuber calcanei

OLIVER

**Border Collie
5 Years old**

**Moderate pain at
distal third gracilis muscle**





VIRTUAL CANINE ANATOMY



ZEUS

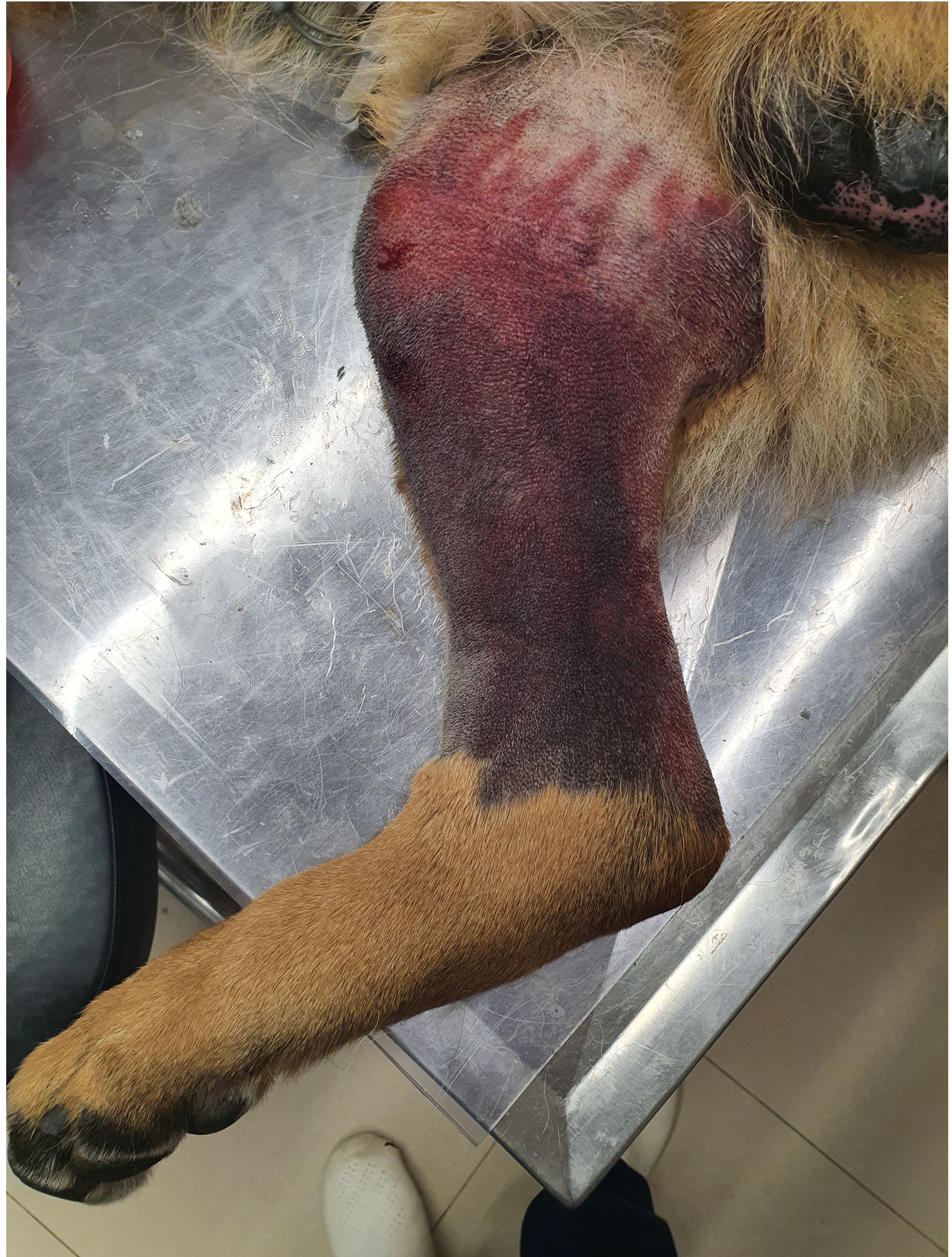German Shepherd

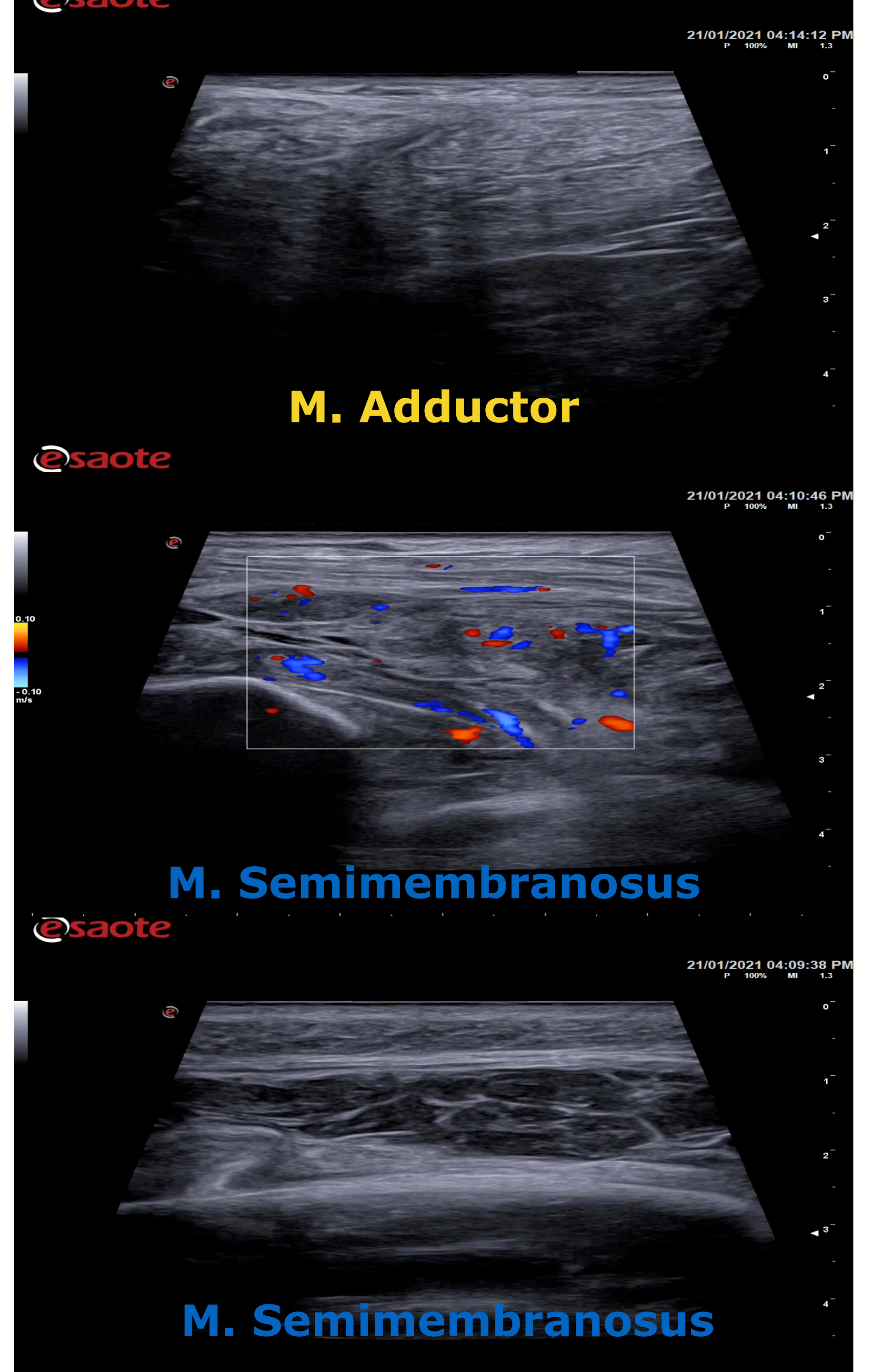
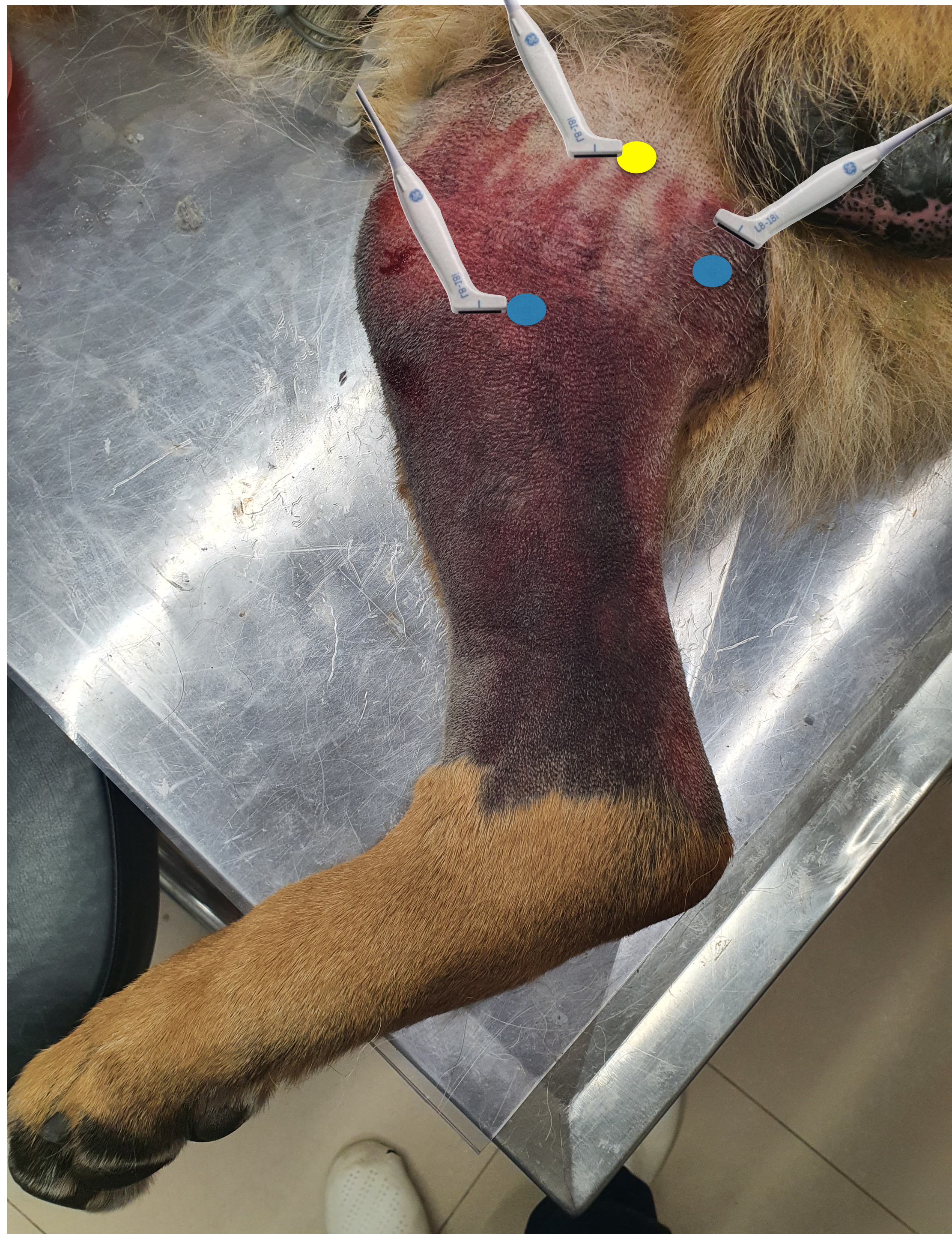M

6 Years old

Rapid-elastic internal rotation of the paw
External rotation of the calcaneus
Internal rotation during extension of the stifle







HYPERECHOIC MUSCLES LESIONS

Acquired muscle contractures in the dog and cat. A review of the literature and case report

J. Taylor, C. H. Tangner
Howell, New Jersey, USA

Vet Comp Orthop Traumatol 2007; 20: 79–85

CONTRACTURE FIBROSIS

Muscle size (normal or reduced)
Heterogeneous appearance
Hyperechoic areas within the muscle
Possible hypoechoic areas
Hyperechoic foci producing distal attenuation

ATROPHY

Reduced muscle size
Homogeneous appearance
Diffuse hyperechogenicity

Histopathology is the gold standard for diagnosis



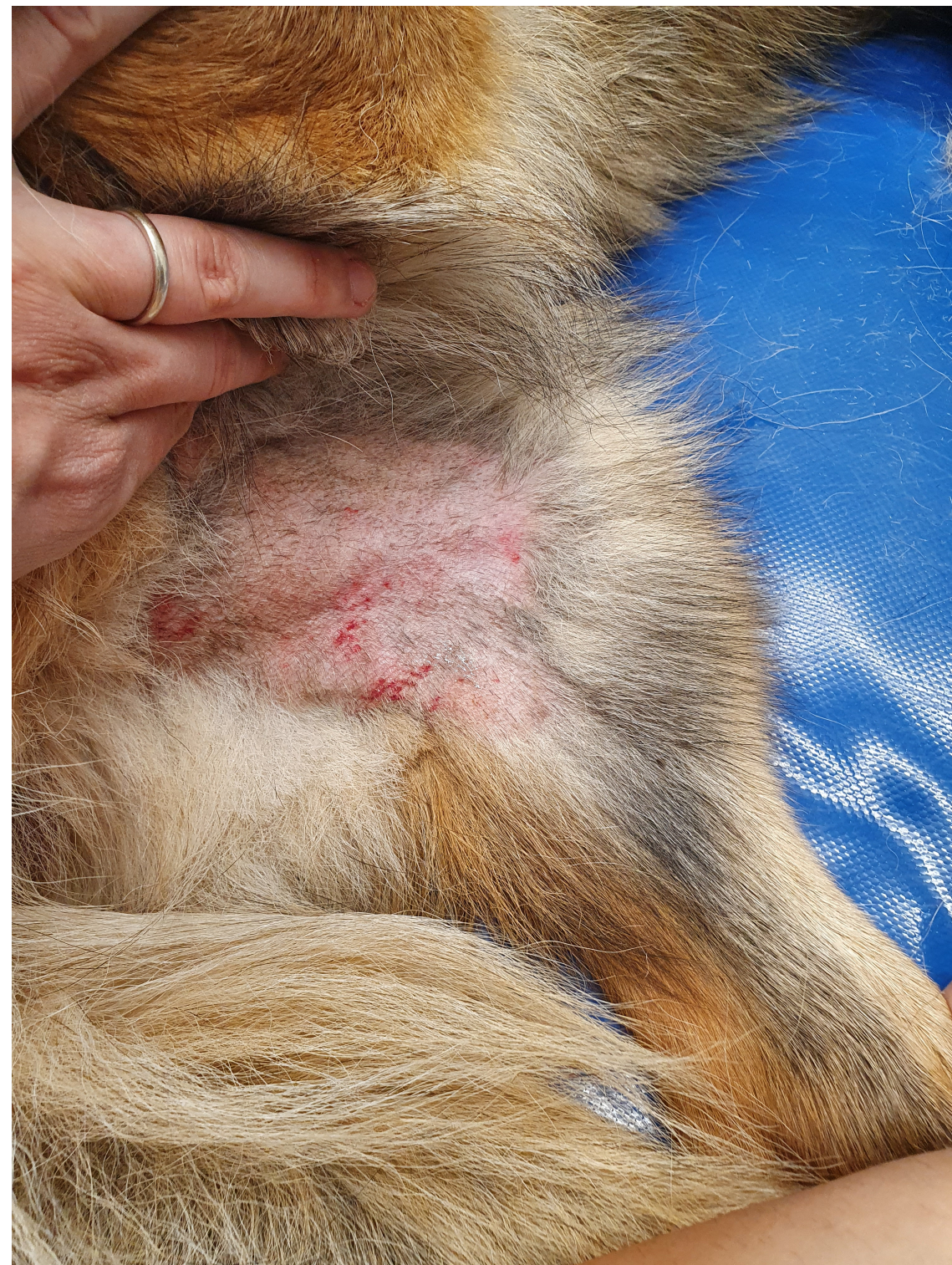
LOTH

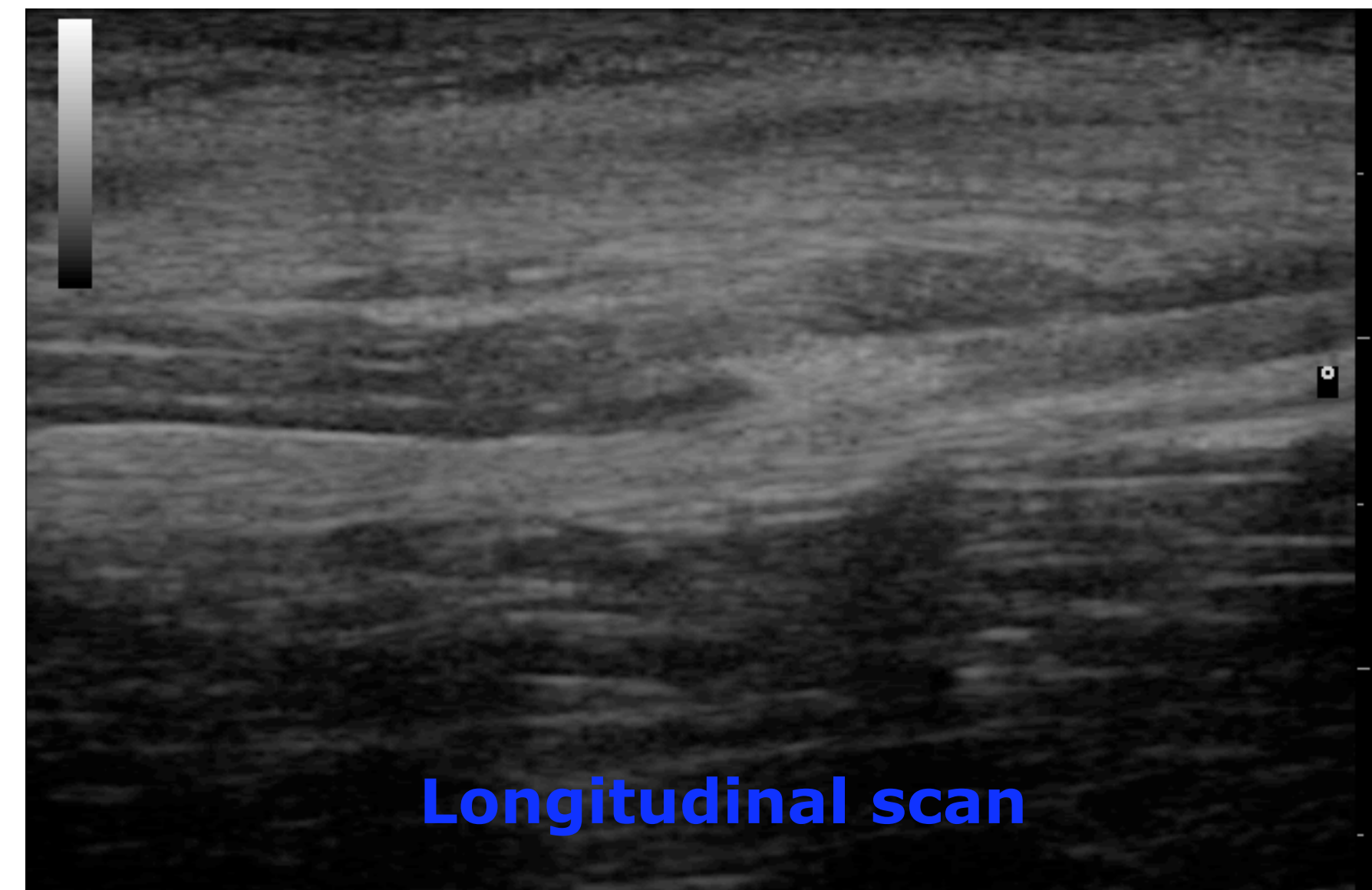
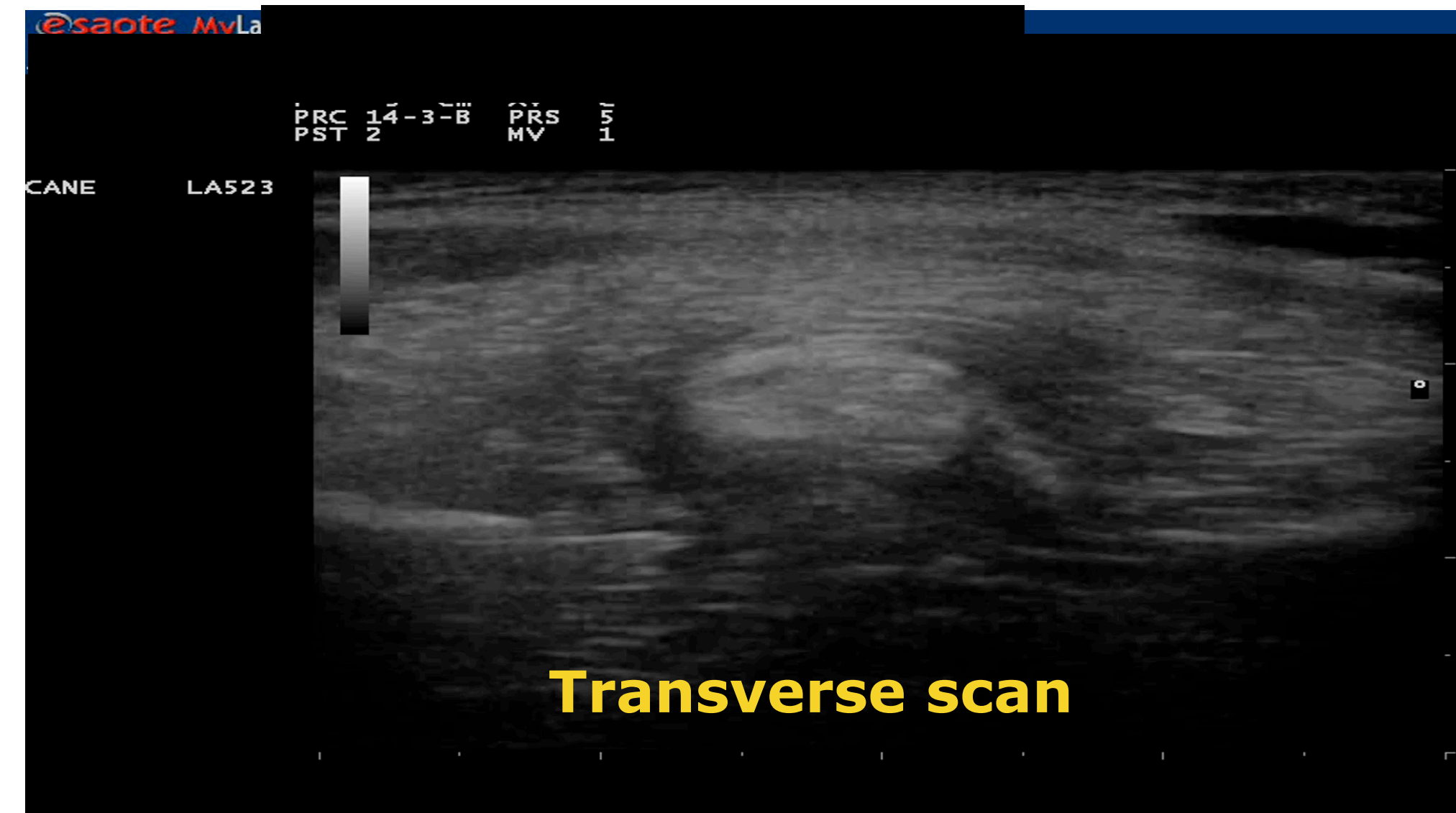
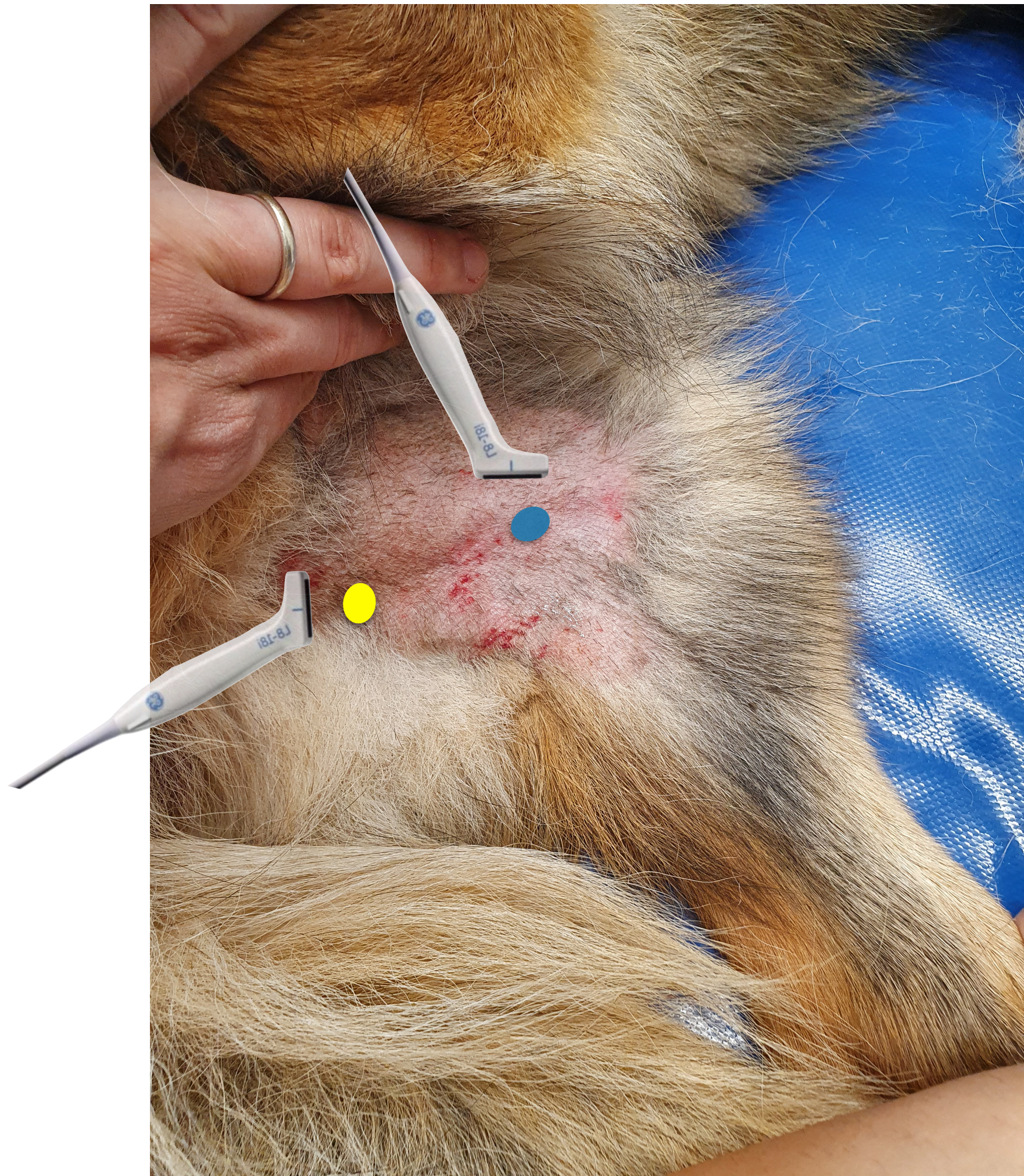
German Shepherd
8 Years old; NM

Stopped to run

Grade III Lameness Right Hindlimb

Full extension of the right hindlimb not possible
Internal rotation during extension of the knee





GRACILIS MUSCLE

Skeletal muscle characterized by chondroid metaplasia, fibrous tissue with mineralizations

TAKE HOME MESSAGE

Hip: joint distention, little information about hard tissues


Sciatic nerve syndrome/gluteal syndrome (+++)

Comprehensive evaluation of the thigh muscles

Monitoring of lesion progression/healing

Evaluation of post-surgical complications

Ultrasound-guided interventional procedures (arthrocentesis, joint injections, FNA, biopsies)



Ultrasound... Why? Not.

PILS
Lago Maggiore
2022



THANKS, ANY QUESTIONS?