High frequency examination of the Achille's tendon and the tarsus

Diagnostic Mindset

Giliola Spattini
DVM, PhD, DECVDI

Objectives

- Chronic Achilles tendon tendinopathy leading to rupture is common in hunting patients
- It is usually an easy clinical diagnosis
- How can the US change surgical planning?

Jack, Doberman, MN, 7 years

- Progressive left hind limb lame-abnormal gait for three months
- Bilaterally thickened Achille's tendon

Jack MN, 7 years

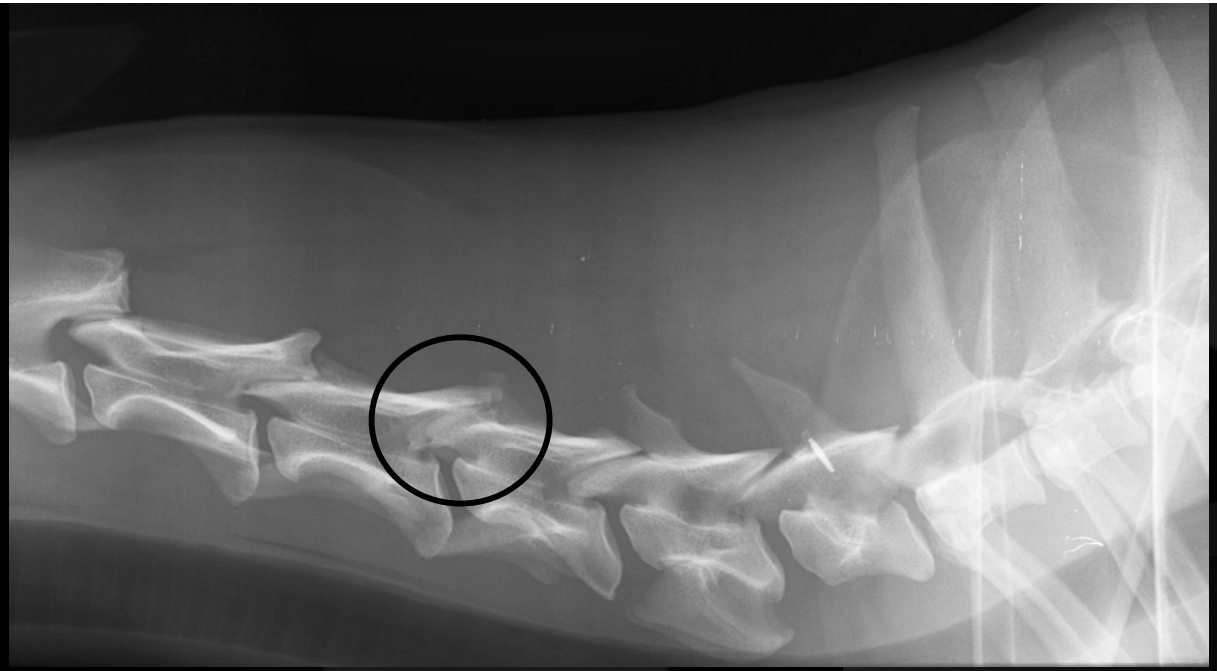

- Negative neurological examination
- Abnormal cervical radiographs

Jack MN, 7 years

Jack MN, 7 years

FSE T2 LONG

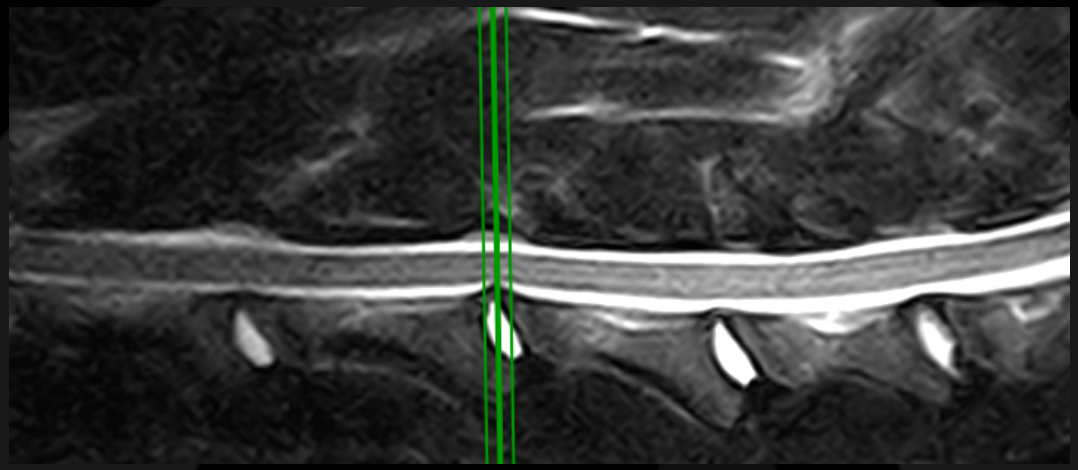

1-2-3

1 FSE T2 SAG

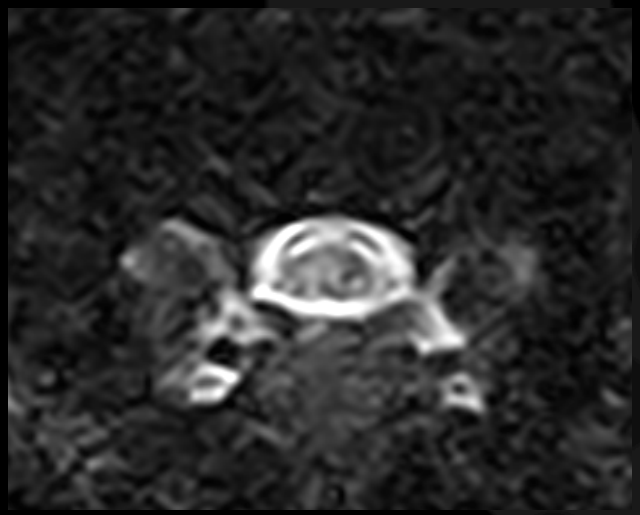

2 FSE T2 SAG

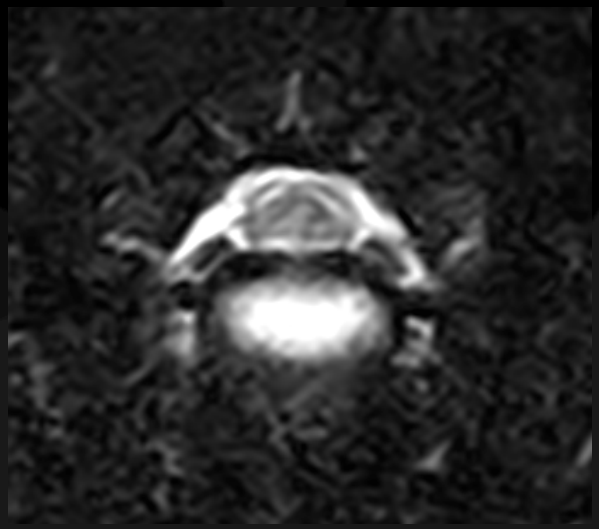

3 FSE T2 SAG

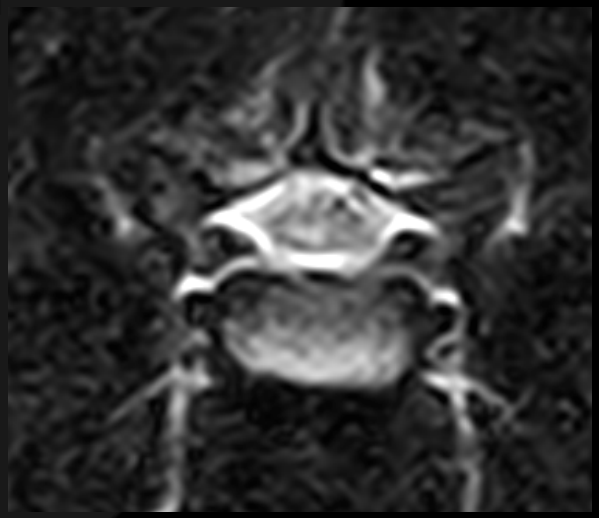

Jack MN, 7 years

FSE T1 LONG

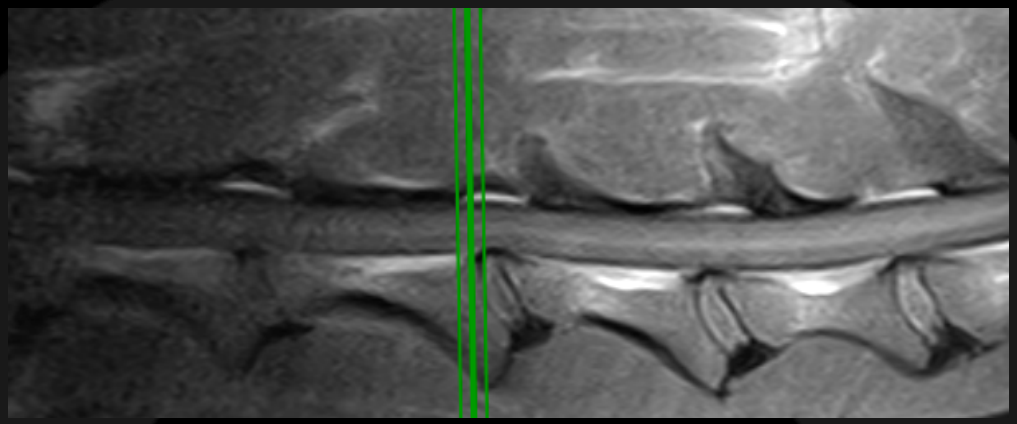

1-2-3

- Negative MRI

1 FSE T1 TRA

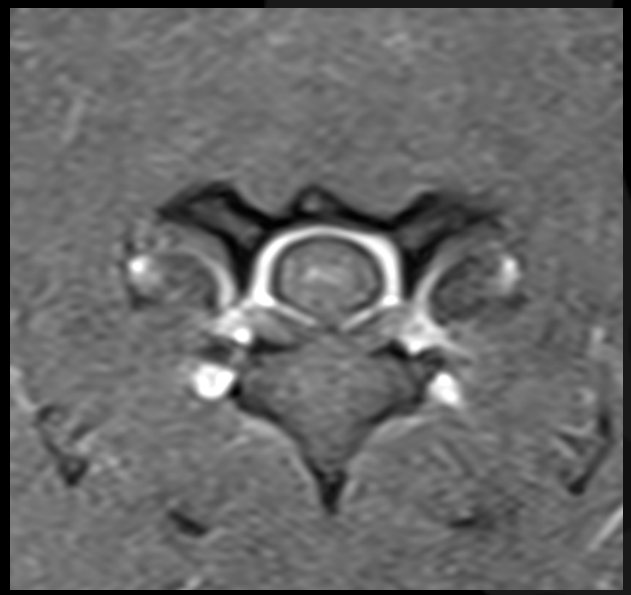

2 FSE T1 TRA

3 FSE T1 TRA

Jack MN, 7 years

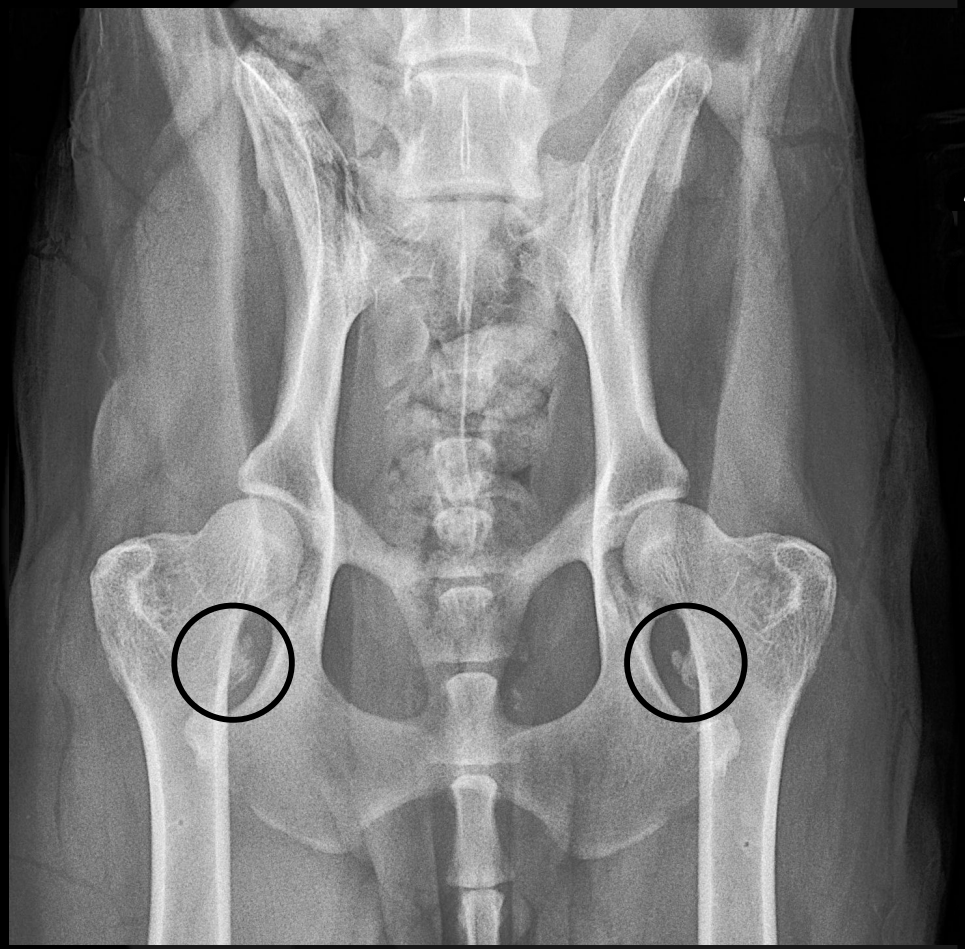

Jack MN, 7 years

Jack MN, 7 years

Jack MN, 7 years
R
R
L
L

Jack, Doberman, MN, 7 years

- Possible chronic, bilateral iliopsoas injury
- Chronic Achille's tendon injury

Ultrasonographic technique

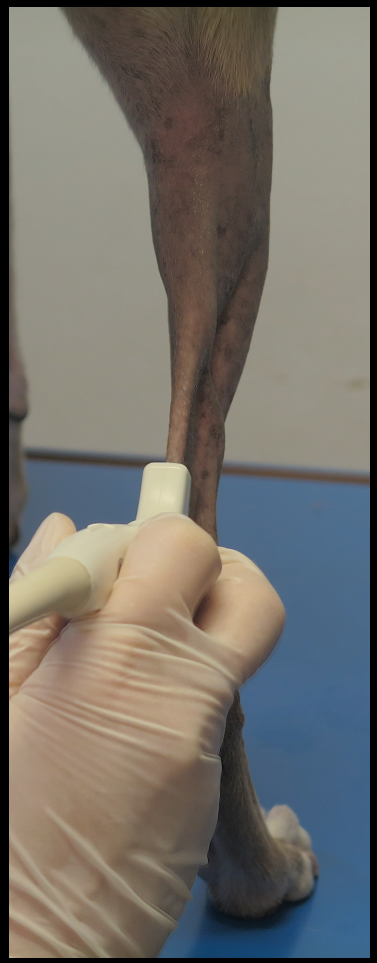

Jack, MN, 7 years

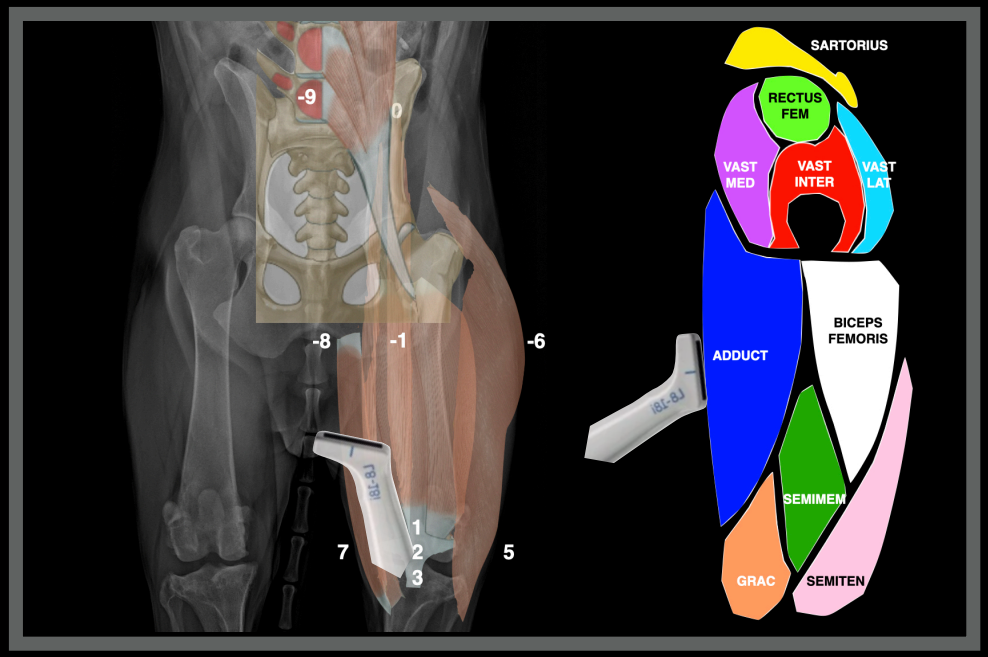

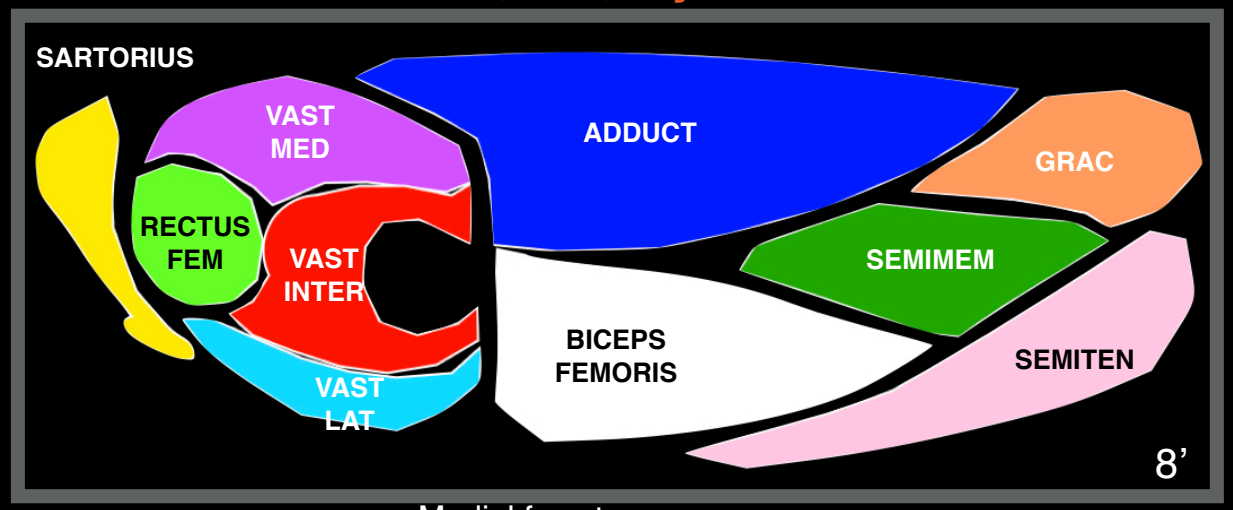

Medial face transverse scan

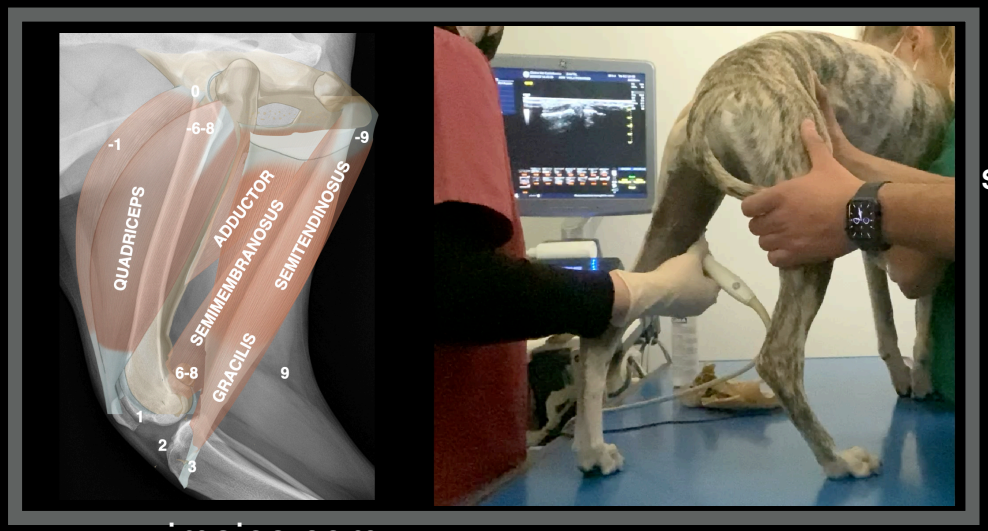

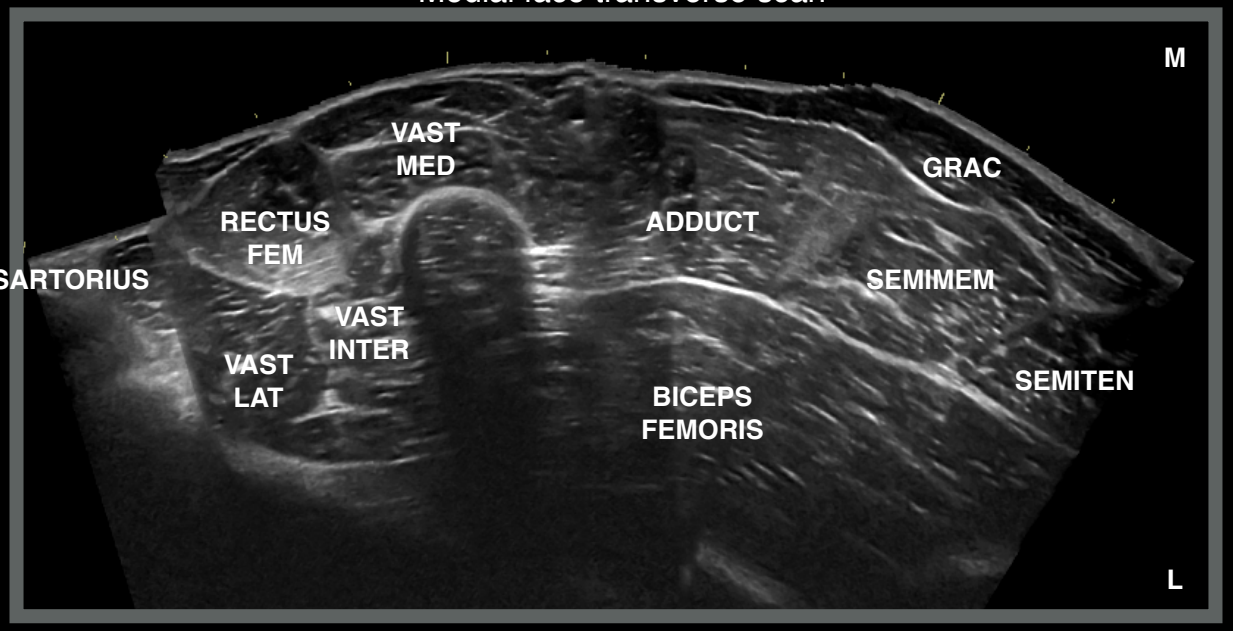

www.imaios.com

Jack, MN, 7 years

Left thigh

Medial face transverse scan -8

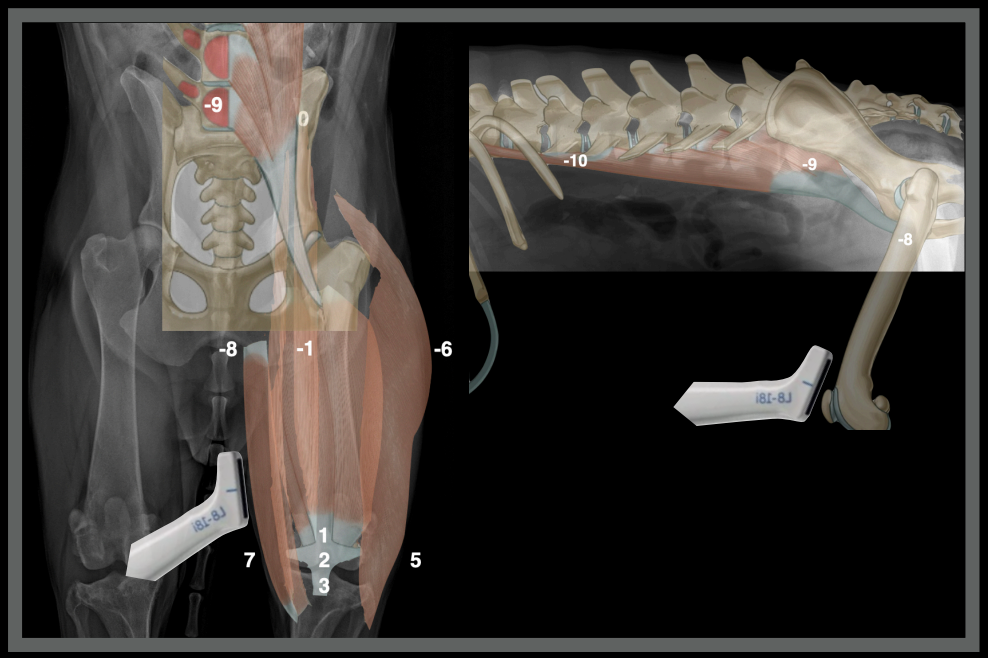

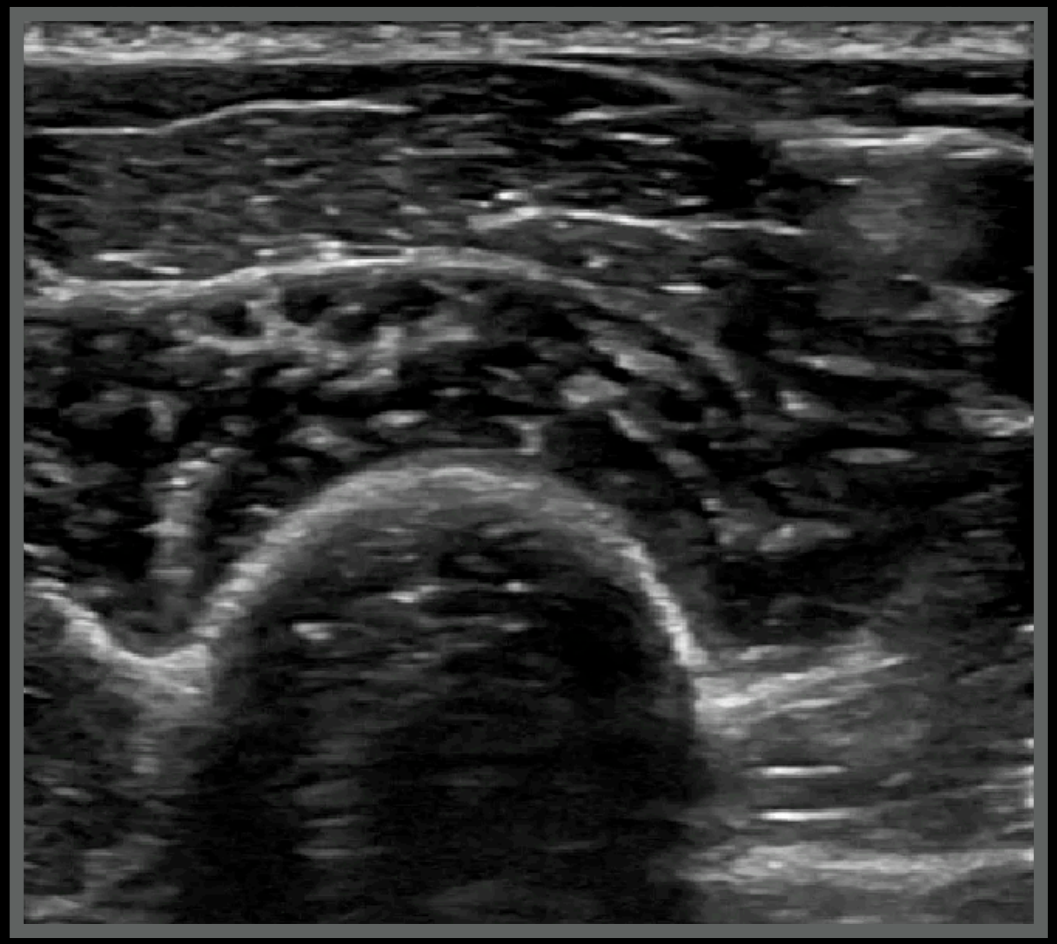

www.imaios.com

Jack, Mn, 7 years

Right thigh



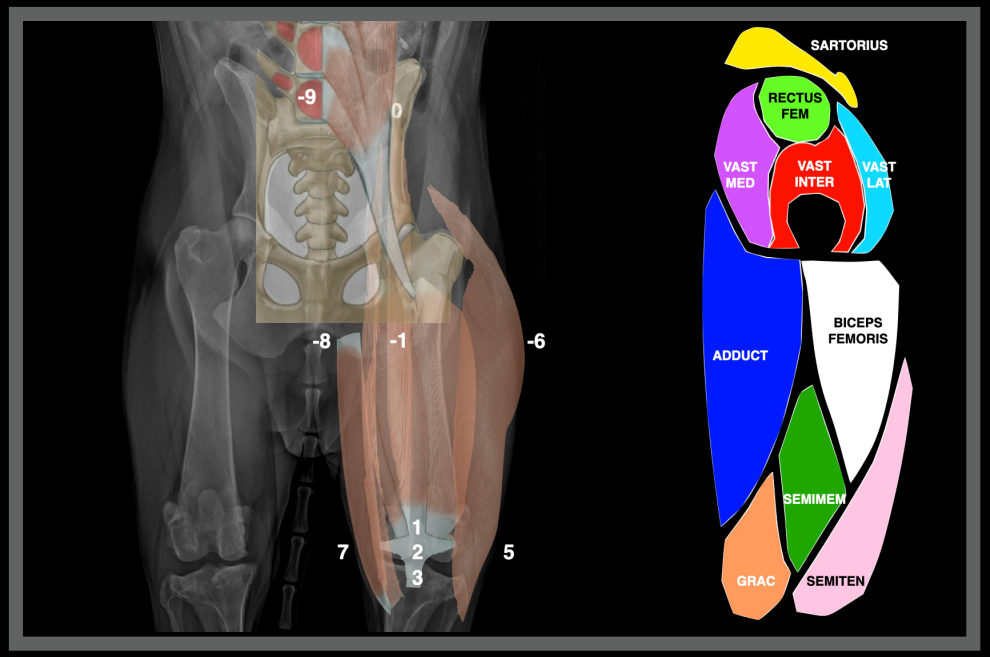

Caudal face longitudinal scan -9-9

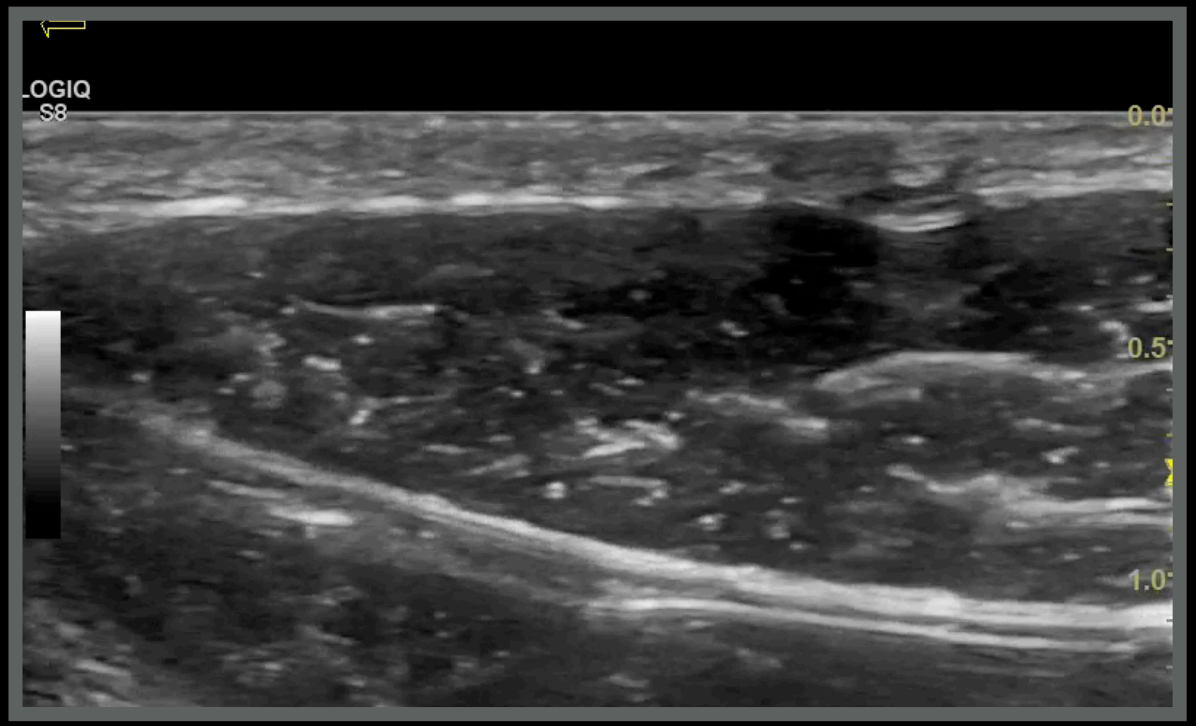

www.imaios.com

Jack, Mn, 7 years

Left thigh



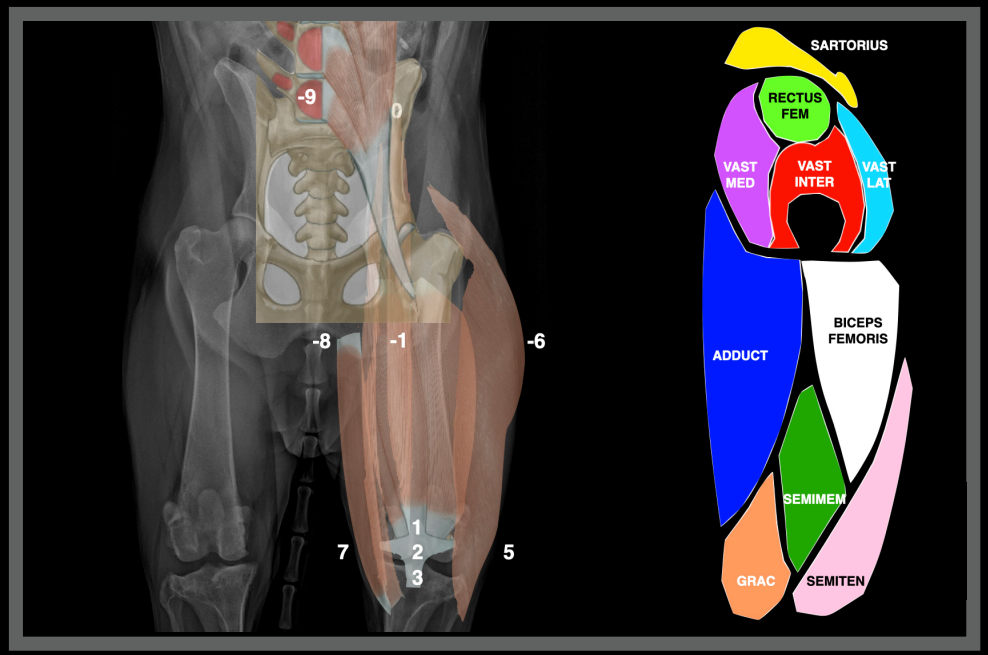

-9-9

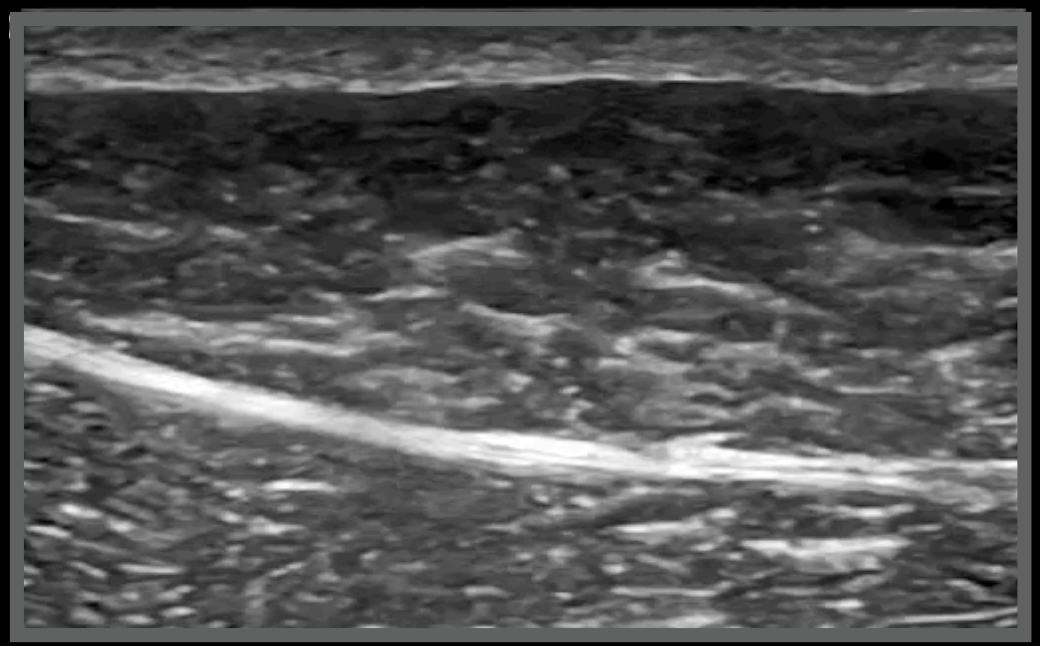

www.imaios.com

Jack, Doberman, MN, 7 years

Right gracilis

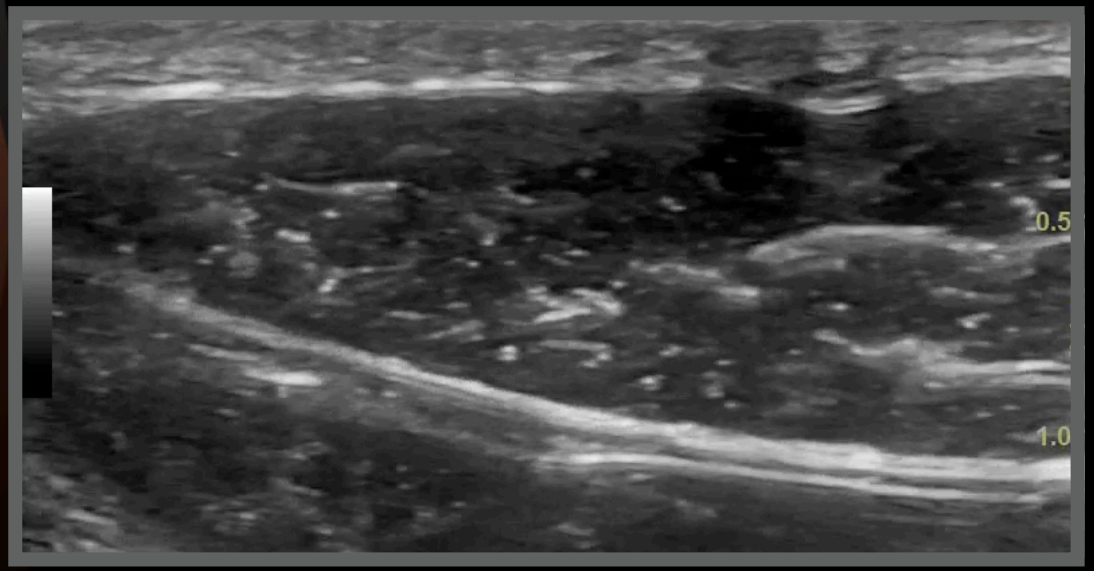

Left gracilis

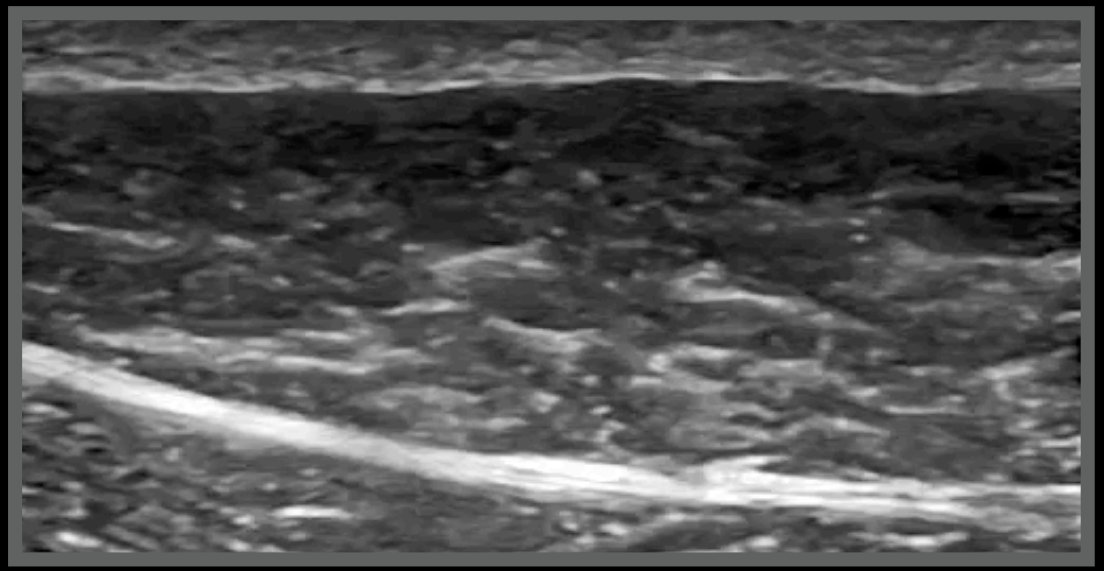

How to arrive at Conclusions:

- PE examination
- Blood works
- Xray and Ultrasonographic findings
- Literature

PubMed®

gracilis miopathy canine

Search

Advanced Create alert Create RSS User Guide

Save Email Send to Sorted by: Best match Display options

MY NCBI FILTERS

17 results

Page 1 of 2

RESULTS BY YEAR

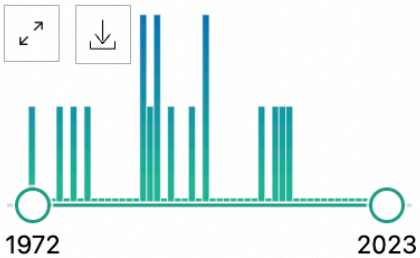

TEXT AVAILABILITY

- Abstract
- Free full text
- Full text

ARTICLE ATTRIBUTE

- Associated data

ARTICLE TYPE

Showing results for *gracilis myopathy canine*

Your search for *gracilis miopathy canine* retrieved no results

1 Cite Share

Gracilis or semitendinosus **myopathy** in 18 **dogs**.

Lewis DD, Shelton GD, Piras A, Dee JF, Robins GM, Herron AJ, Fries C, Ginn PE, Hulse DA, Simpson DL, Allen DA.

J Am Anim Hosp Assoc. 1997 Mar-Apr;33(2):177-88. doi: 10.5326/15473317-33-2-177.

PMID: 9111730

The clinical findings in 18 **dogs** with **gracilis** (n = 17) or semitendinosus (n = 1) **myopathy** are described. ...Medical management prior to or in lieu of surgery was attempted (n = 8) with no apparent response. Fifteen **dogs** had one or multiple surgical pr ...

2 Cite Share

Hypophosphatemia and rhabdomyolysis.

Knochel JP, Barcenas C, Cotton JR, Fuller TJ, Haller R, Carter NW.

J Clin Invest. 1978 Dec;62(6):1240-6. doi: 10.1172/JCI109244.

PMID: 748377 **Free PMC article.**

Muscle Na and Cl contents became higher (P <0.01). Sections of **gracilis muscle** showed frank rhabdomyolysis.6 of the 23 phosphorus- and calorie-deprived **dogs** were also given 140 kal/kg per day but in addition, each received 147 mmol of elemental phos ...

Normal ultrasound of the gracilis muscle

www.diagnosticmindset.com

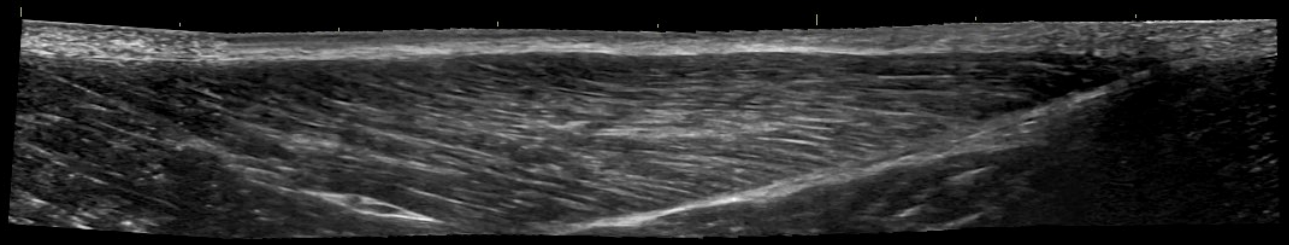

“Normal” walking

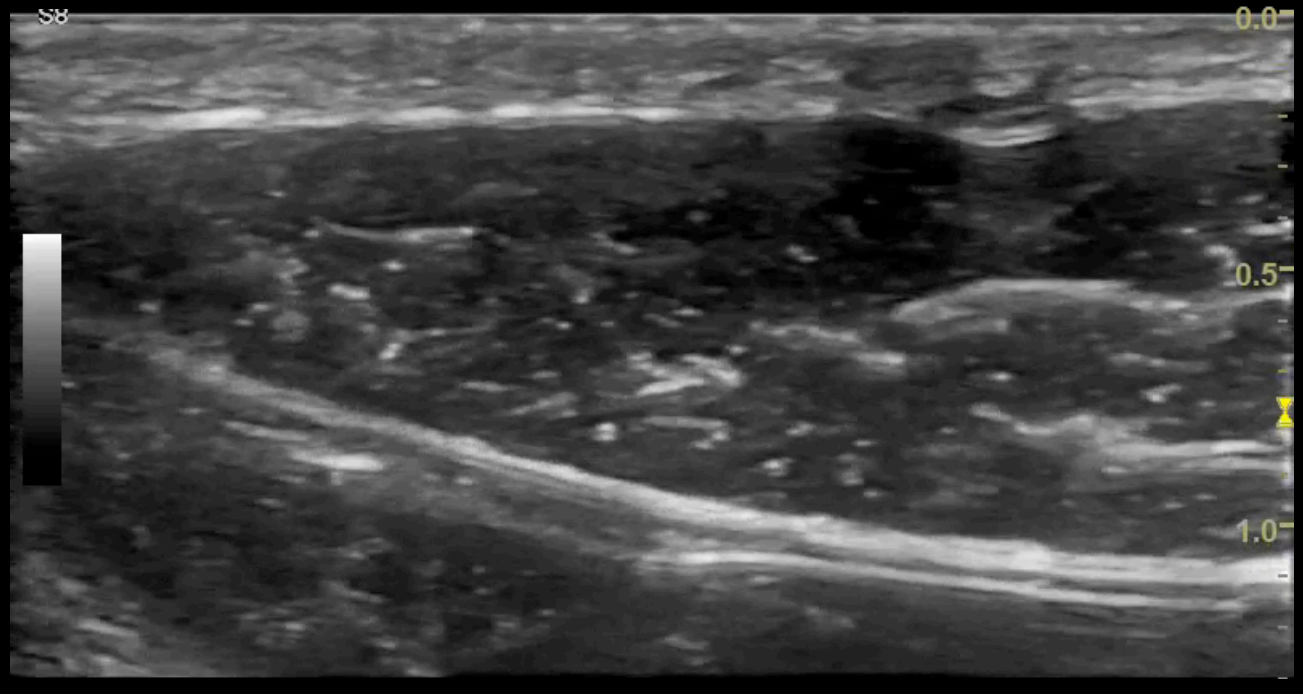

Early phase of gracilis myopathy

www.diagnosticmindset.com

Left hind limb affected

Hypoechoic area with decreased fibrillar pattern

Irregularly thickened fascia

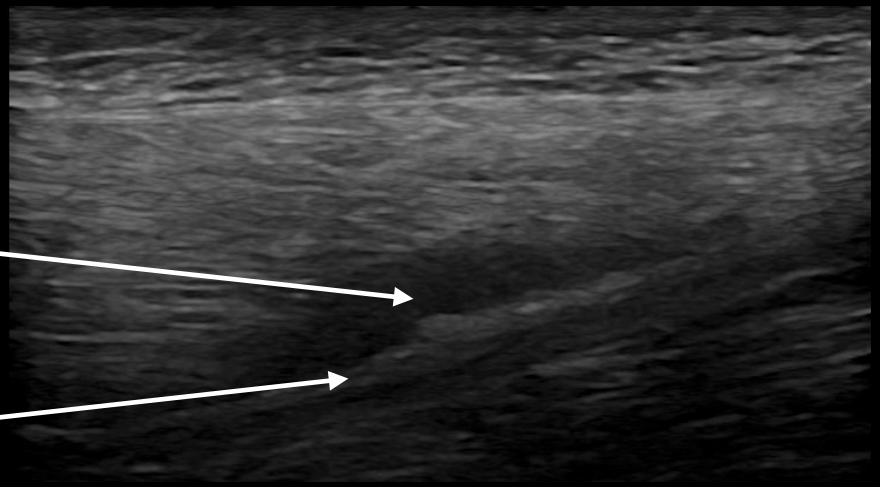

Often associated with mild muscle atrophy

Scattering artifact not present

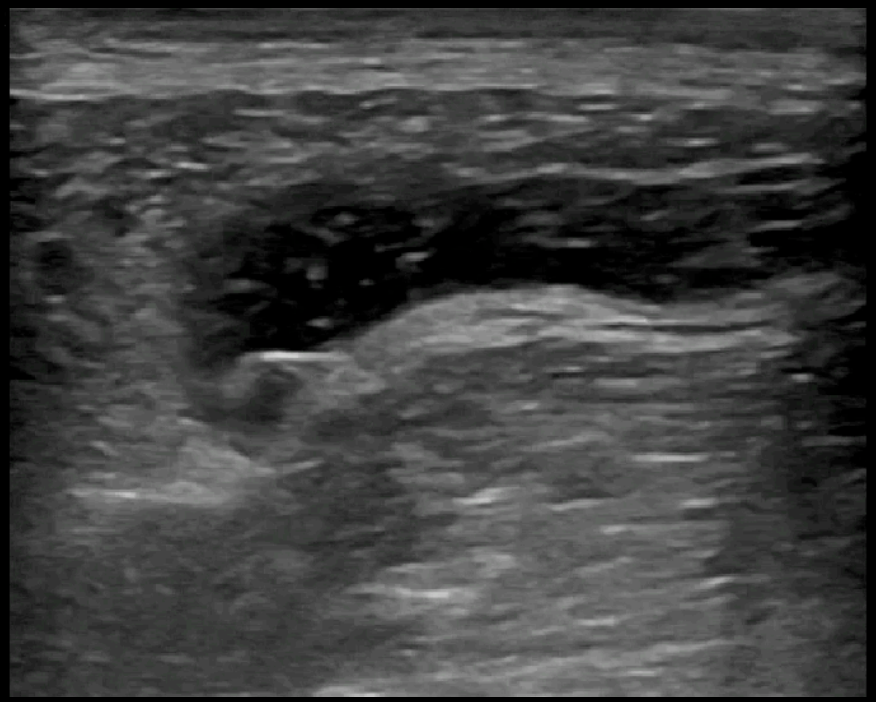

Middle phase of gracilis myopathy

www.diagnosticmindset.com

Scattering artifact

Nodular like lesion

Not homogeneous echostructure

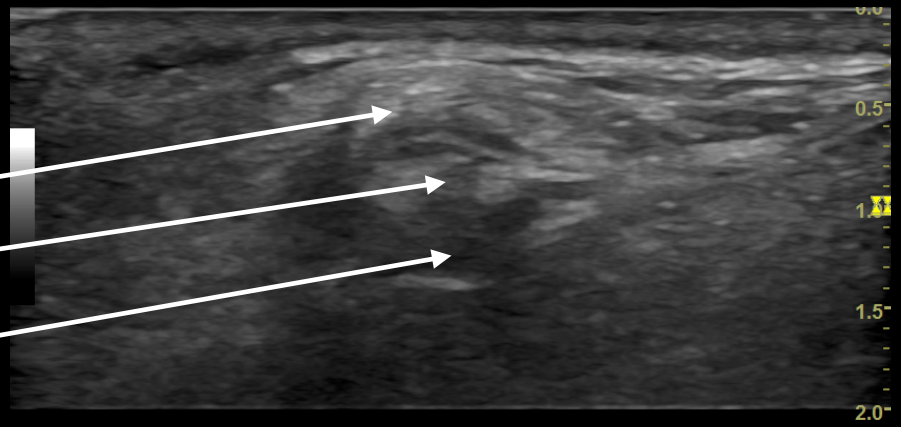

Left hind limb affected

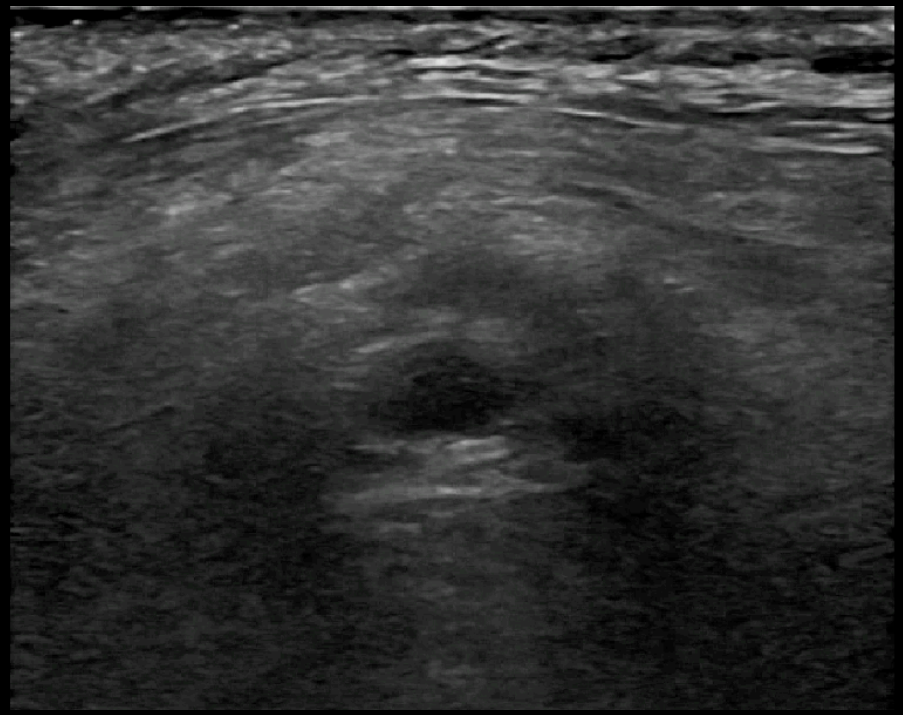

Late phase of gracilis myopathy

www.diagnosticmindset.com

Left hind limb affected

Well-defined echoic line-spots

No scattering artefacts

Well-defined margins

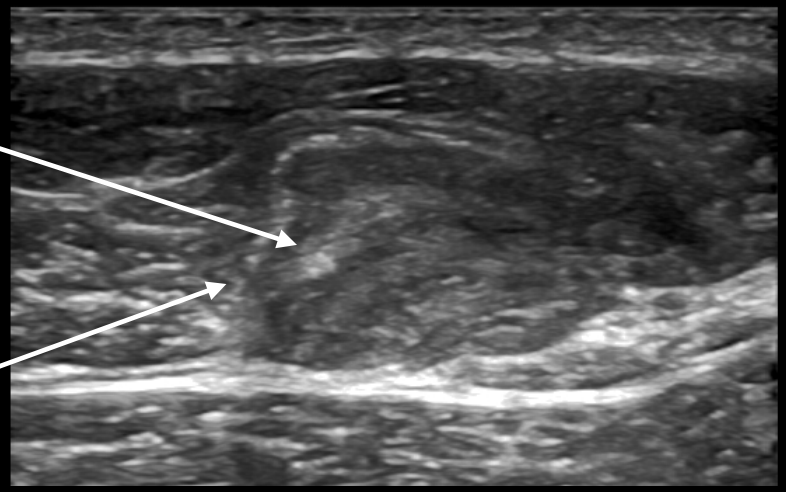

No signs of inflammation

Muscle fibrosis

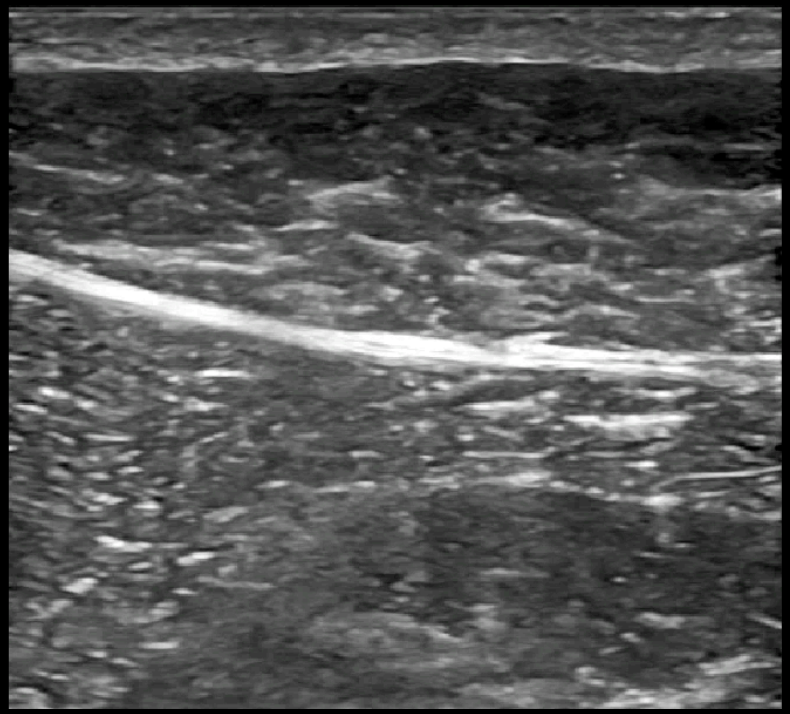

Jack, Doberman, MN, 7 years

Ultrasonographic diagnoses:

- Second degree left gracilis myopathy

Achille's tendon

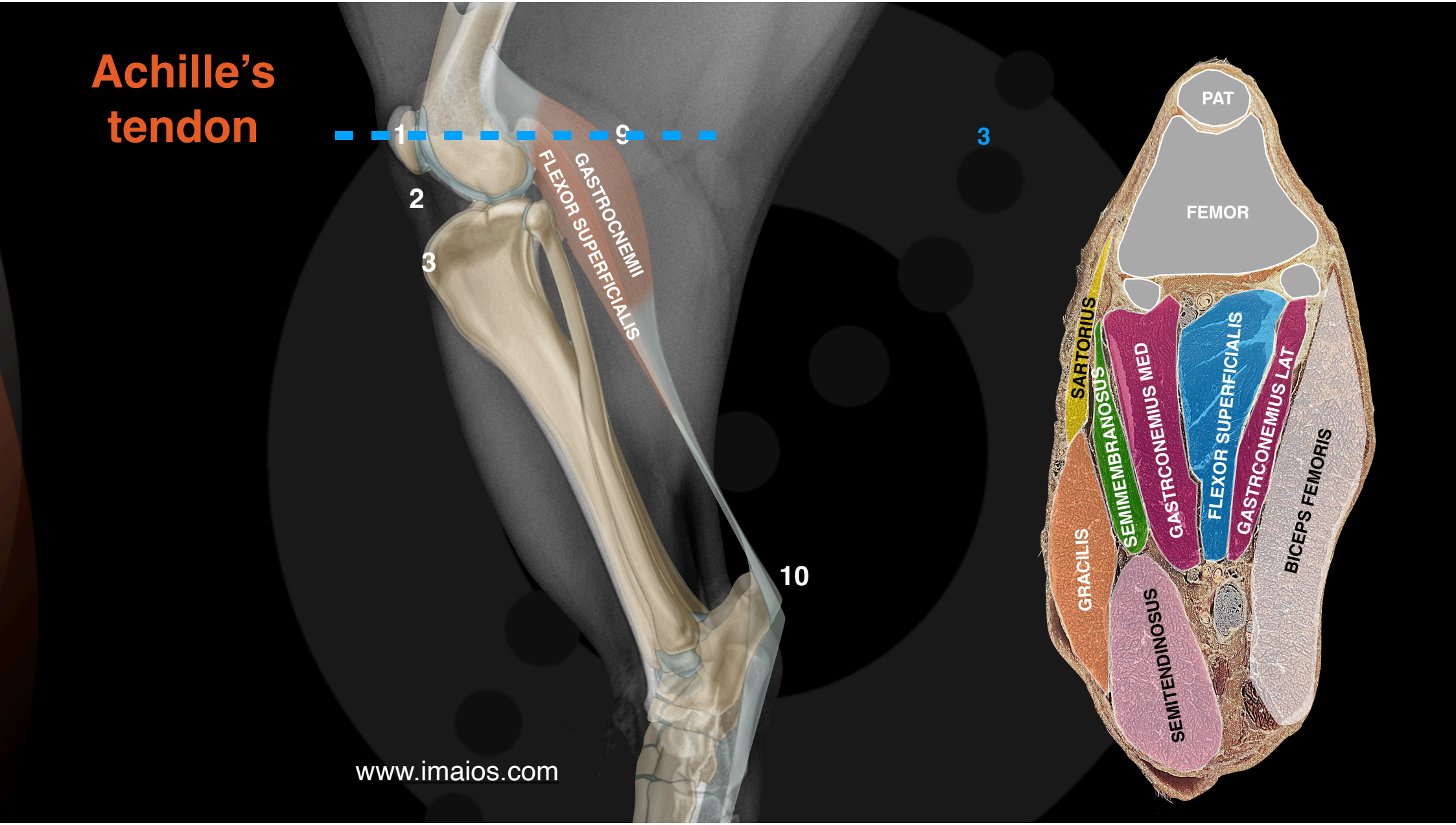

www.imaios.com

Anatomy

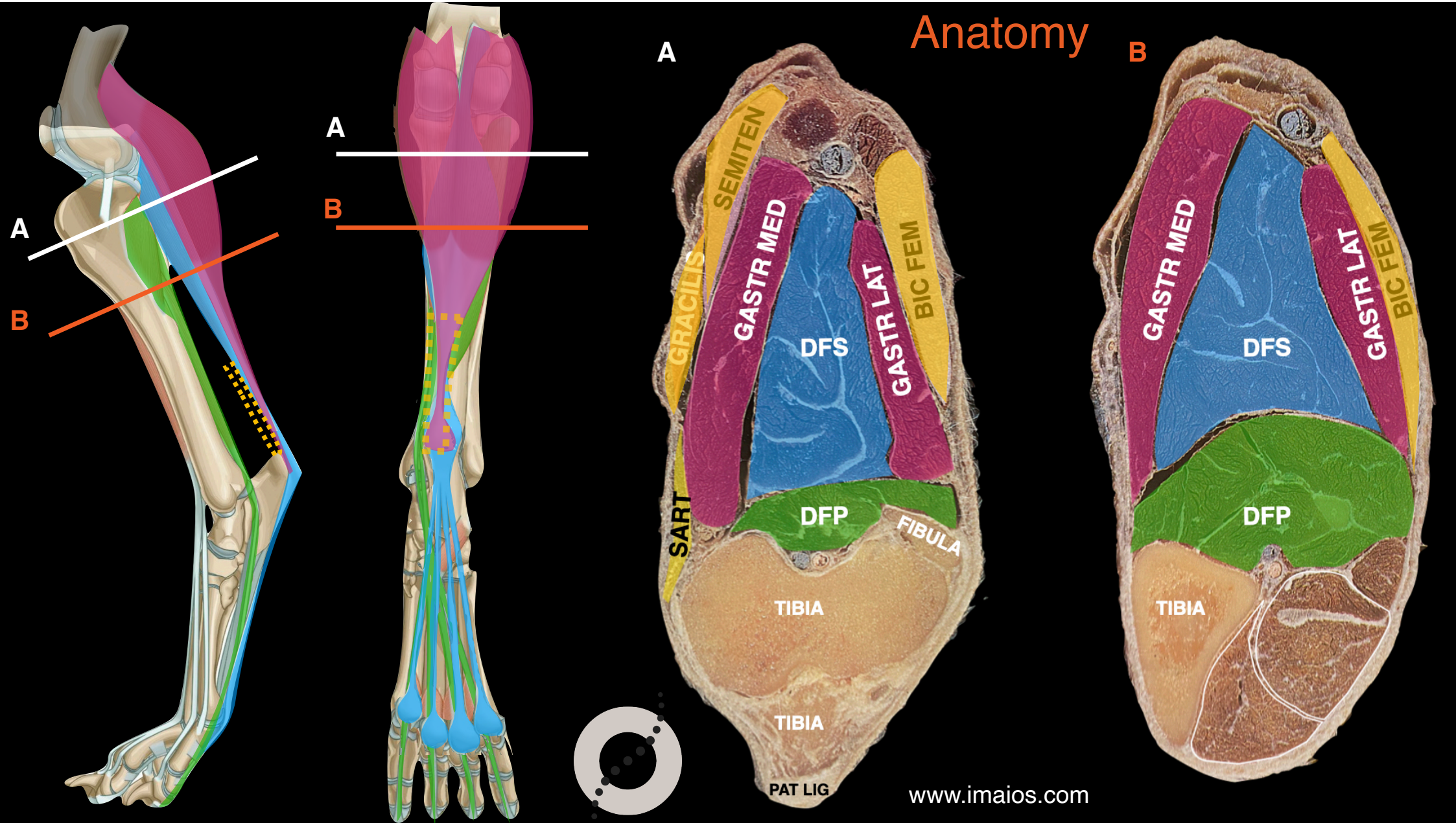

www.imaios.com

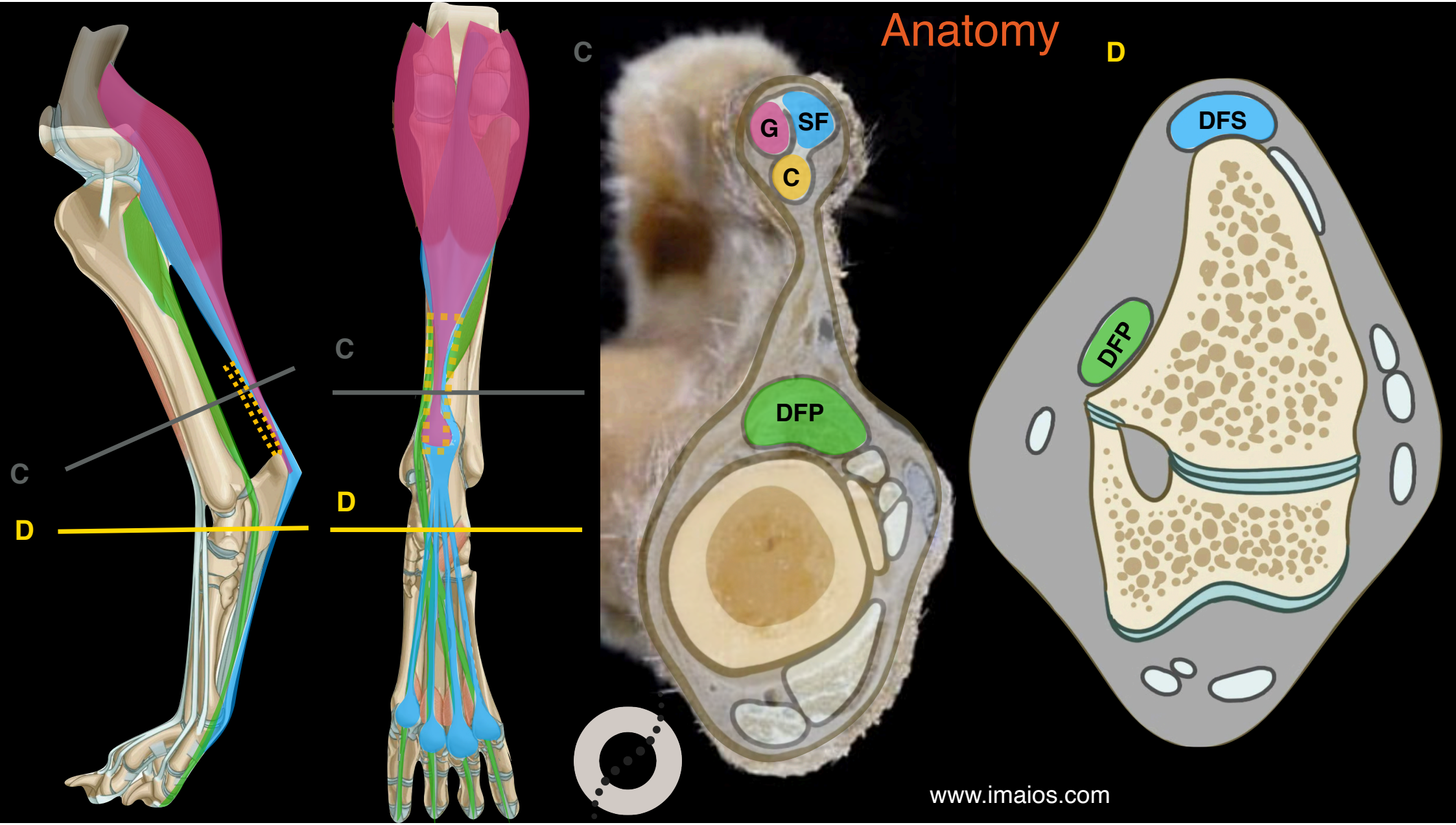
Anatomy
C
D
C
D
C
D
G
SF
C
DFP
DFS
DFP
www.imaios.com

Jack, MN, 7 years

Right stifle

Caudal face transverse scan 9

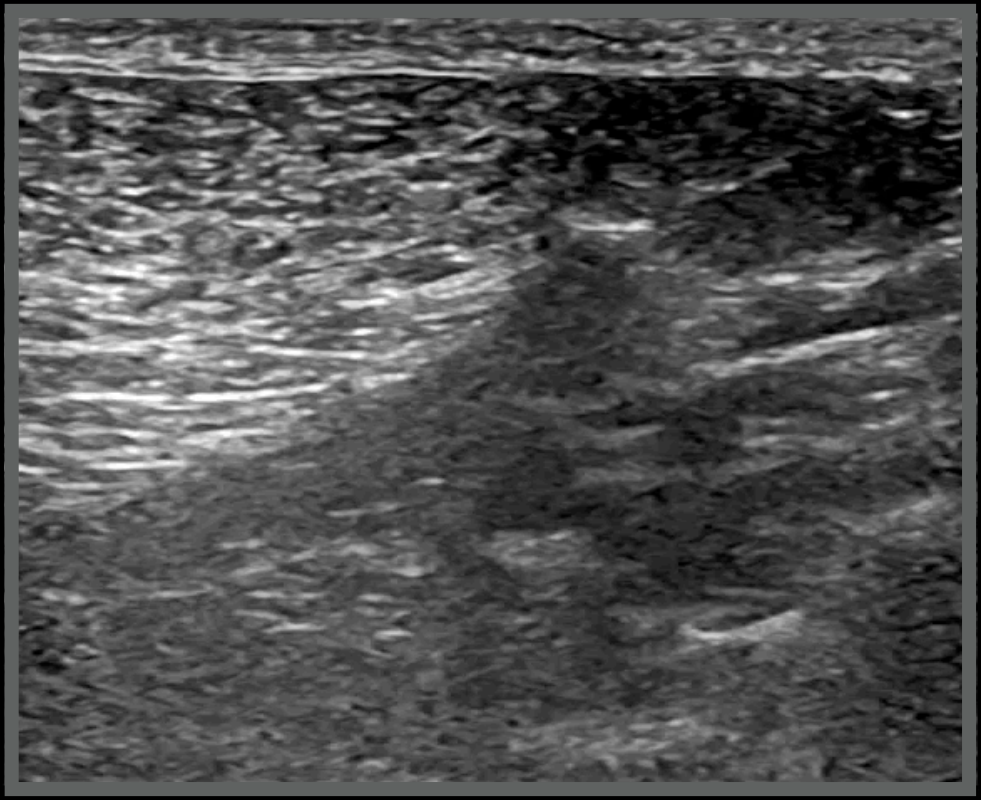

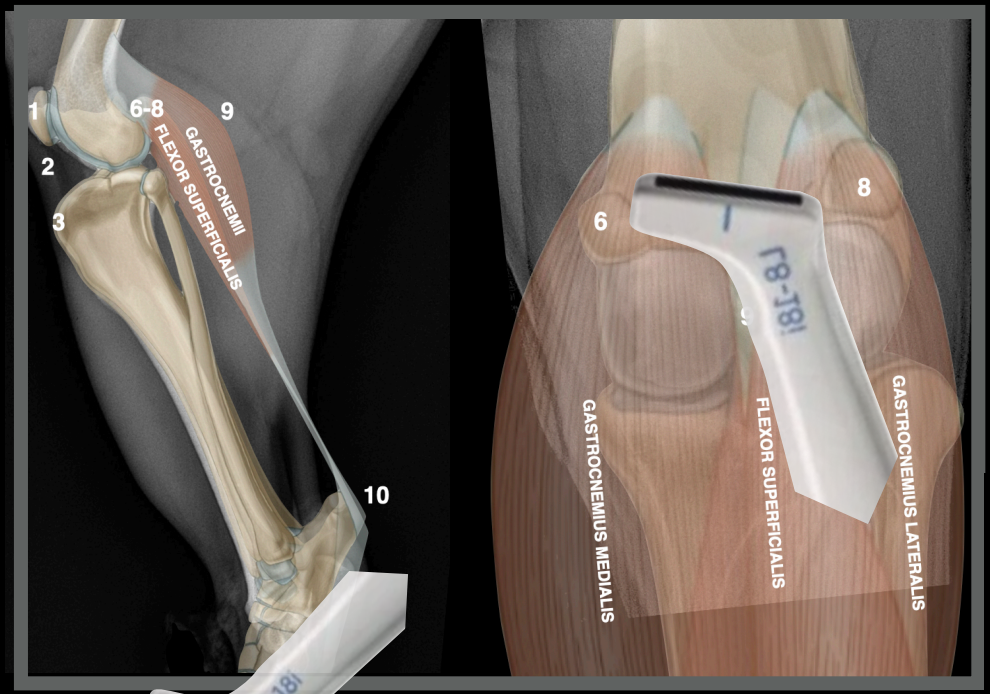

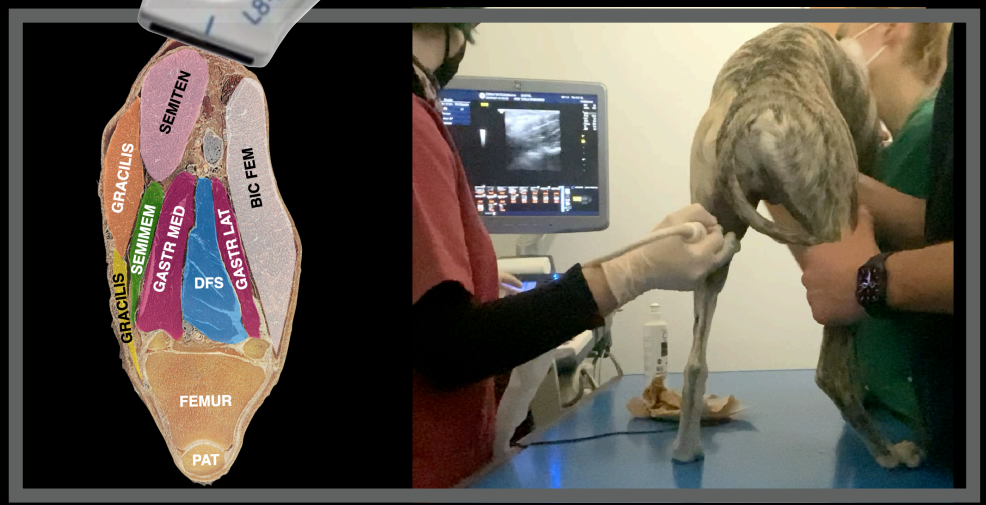

www.imaios.com

Jack, MN, 7 years

Right stifle

Caudal face transverse scan 9

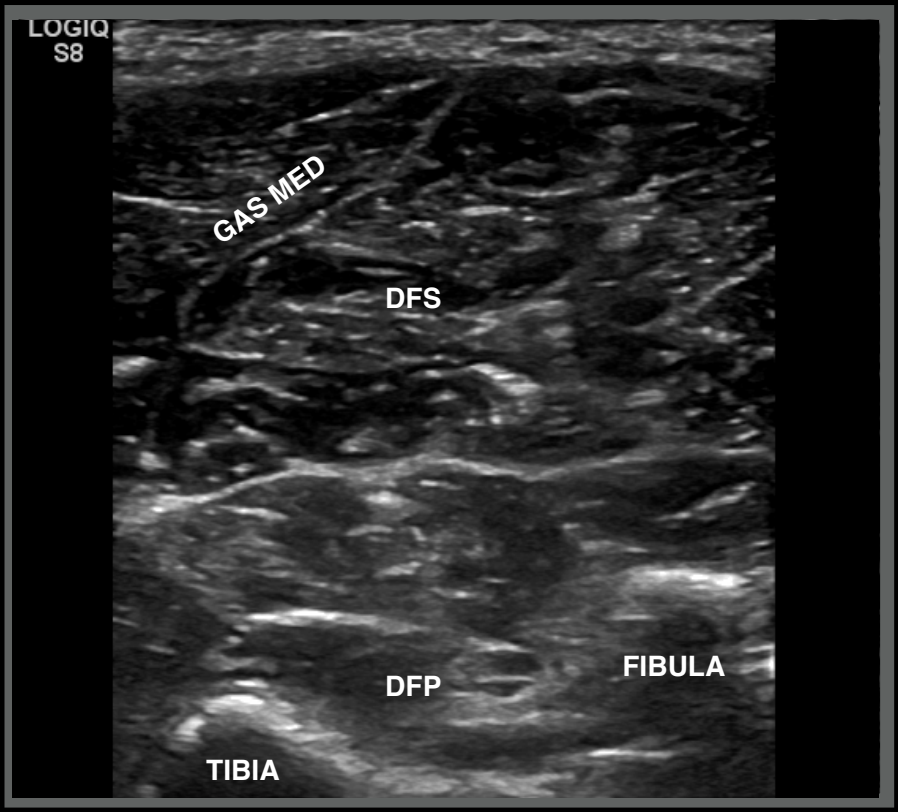

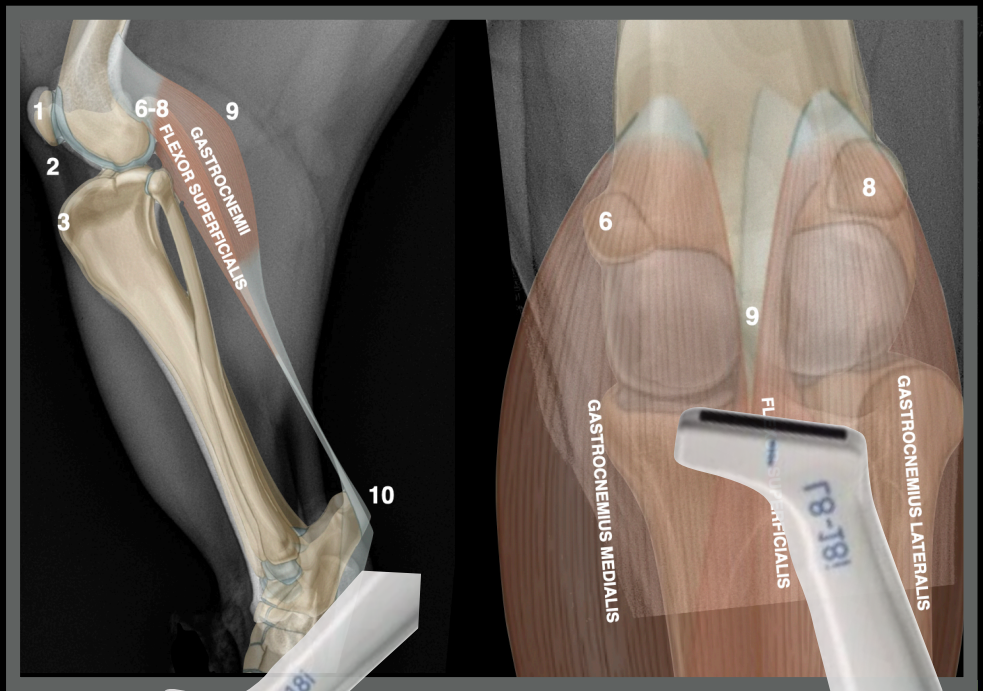

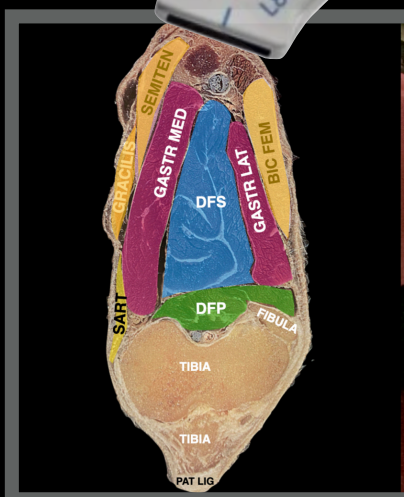

www.imaios.com

Jack, MN, 7 years

Right leg

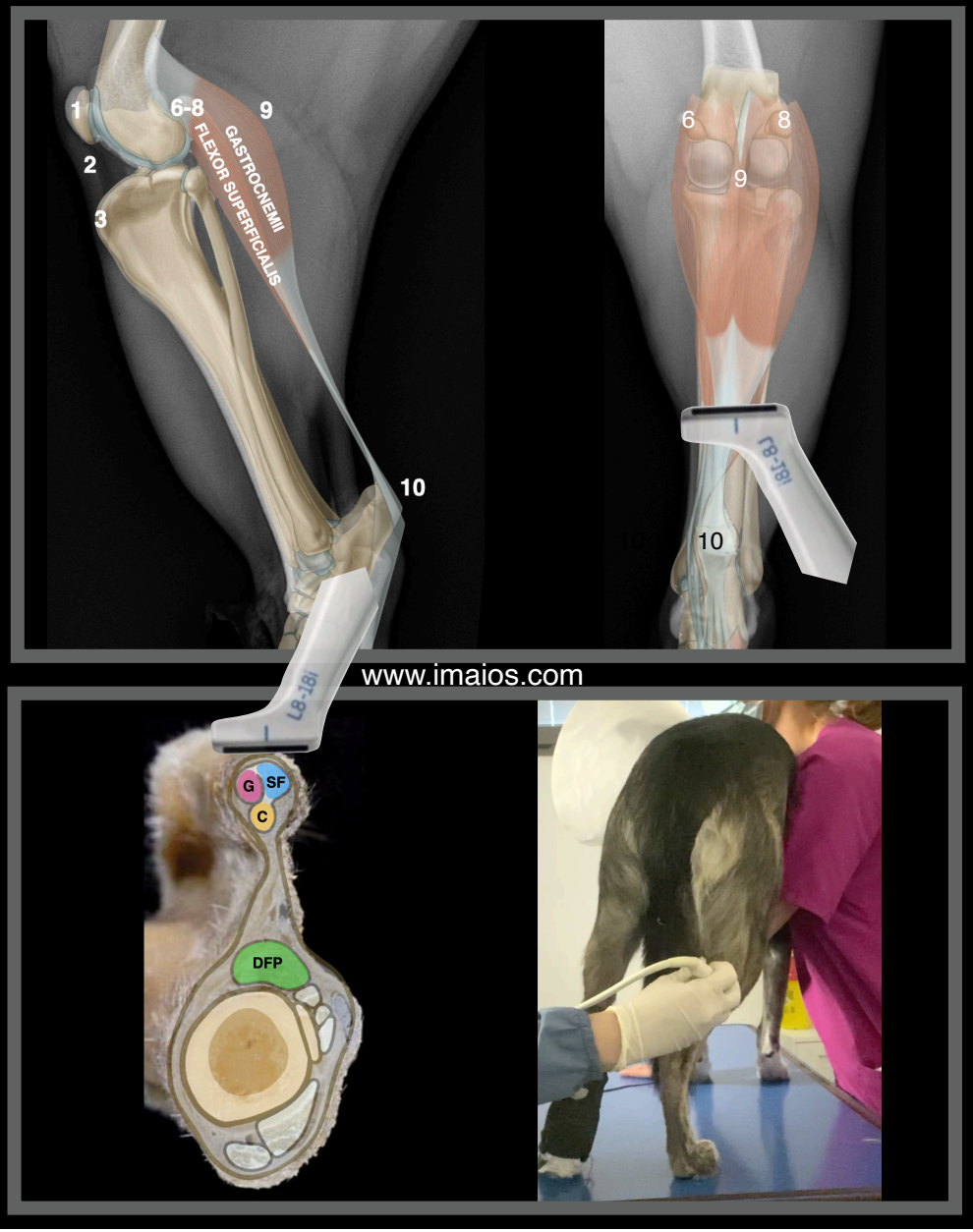

Caudal face transverse scan 9-10

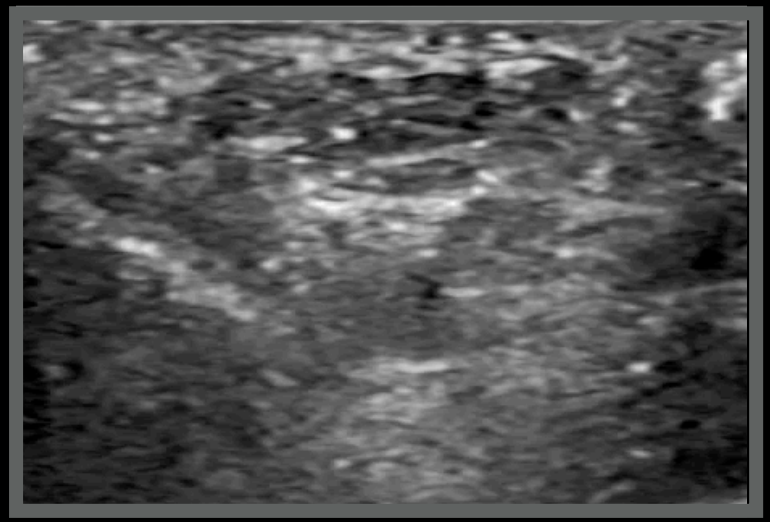

Jack, MN, 7 years

Left stifle



Caudal face transverse scan 9

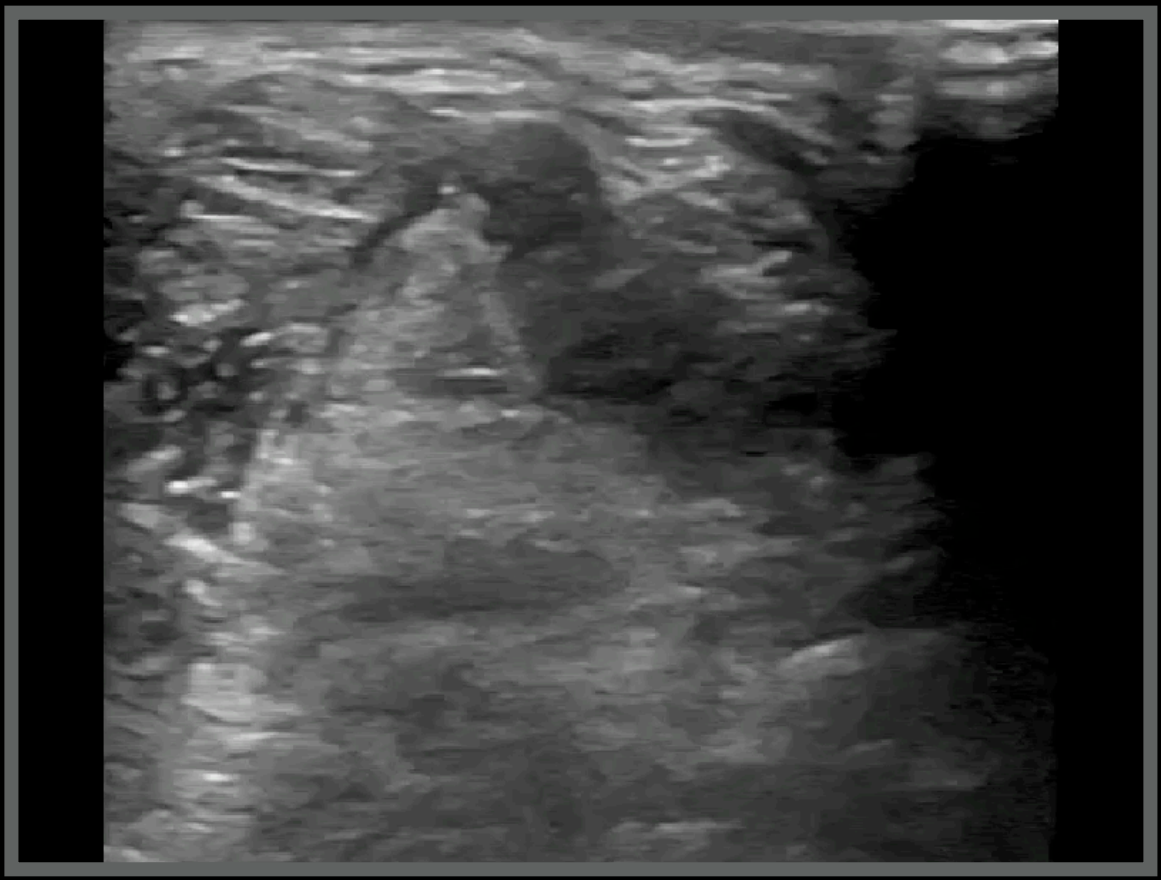

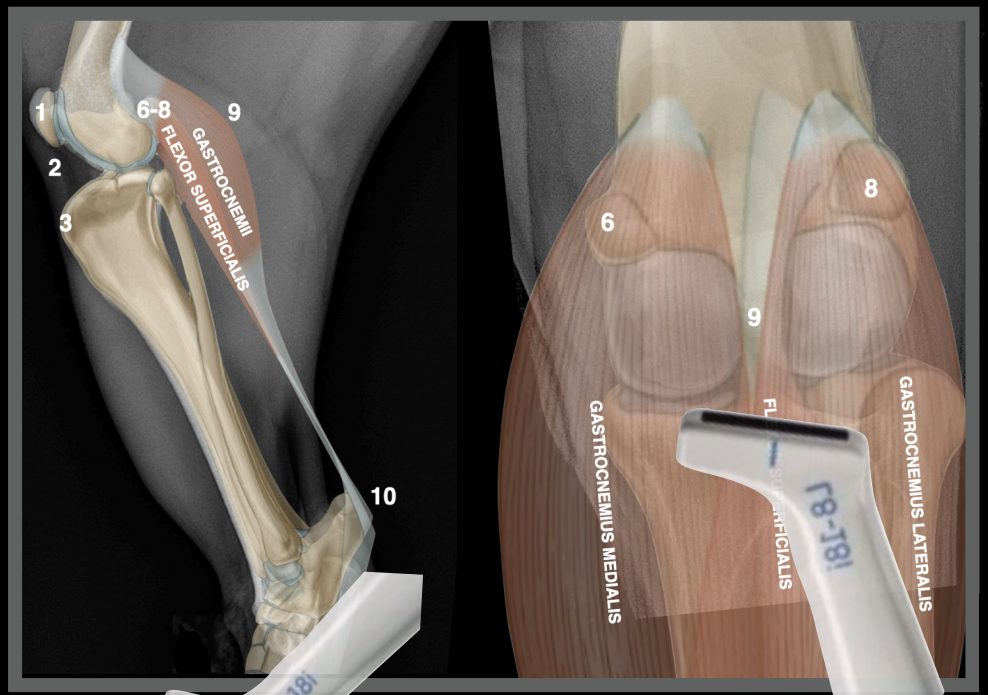

www.imaios.com

Jack, Doberman, MN, 7 years

Right

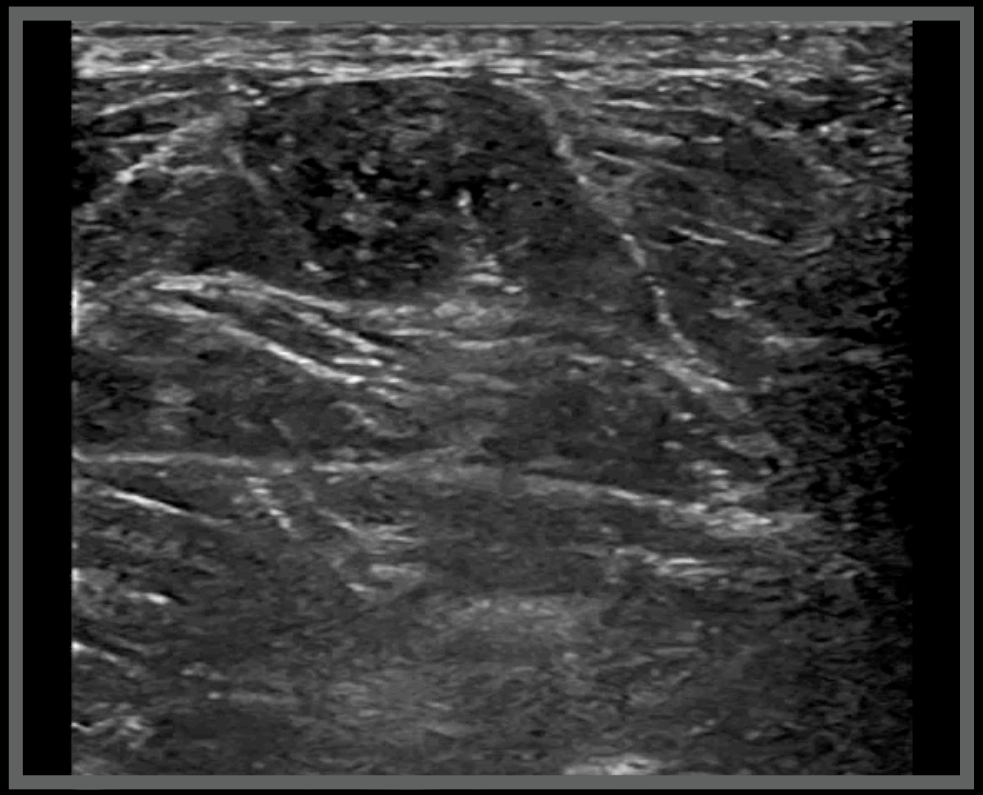

Left

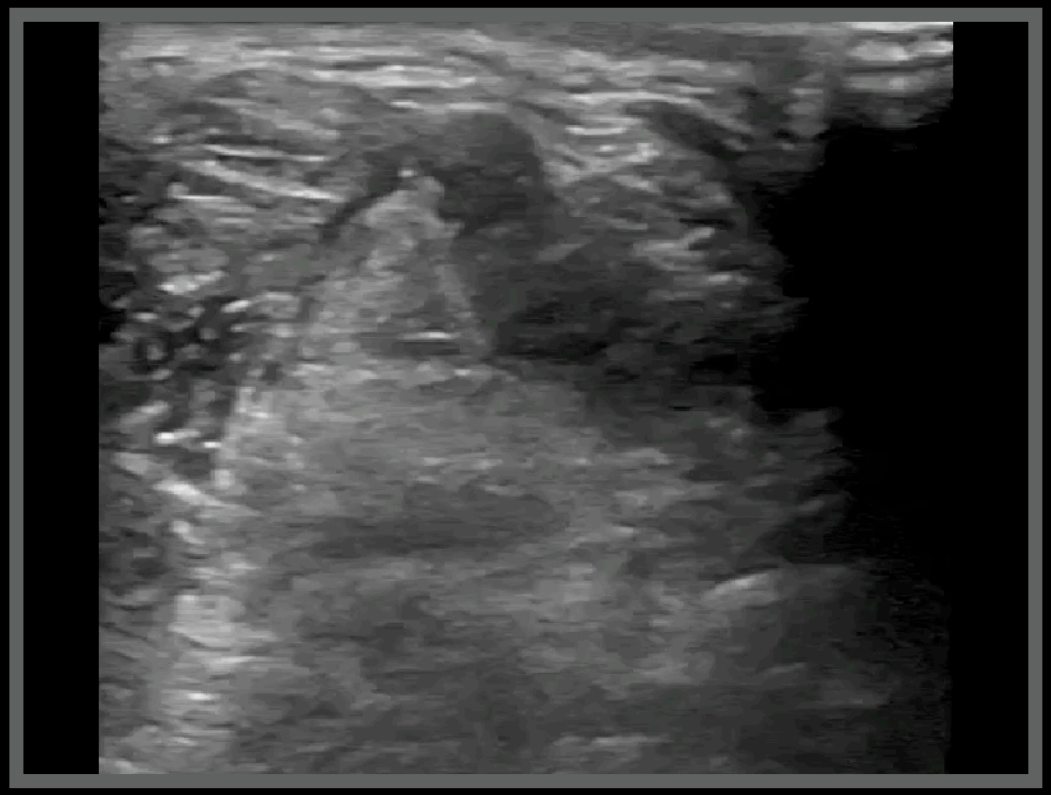

Jack, MN, 7 years

Right stifle

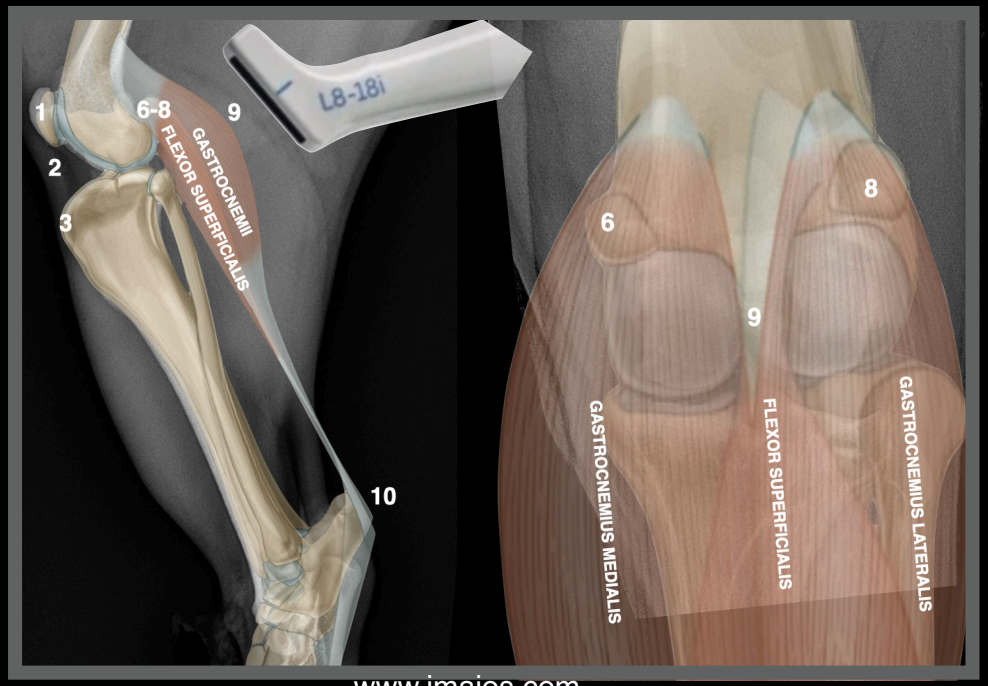

www.imaios.com

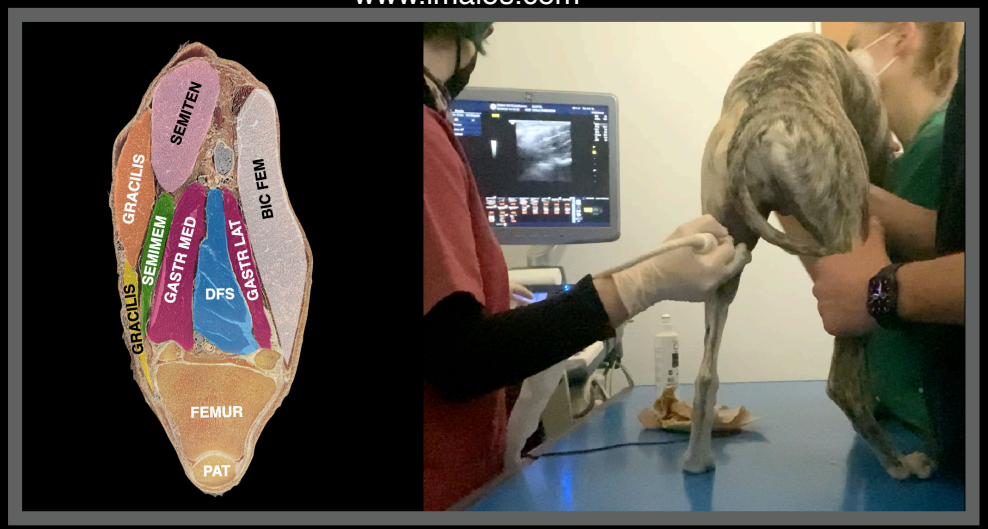

Caudal face longitudinal scan

9

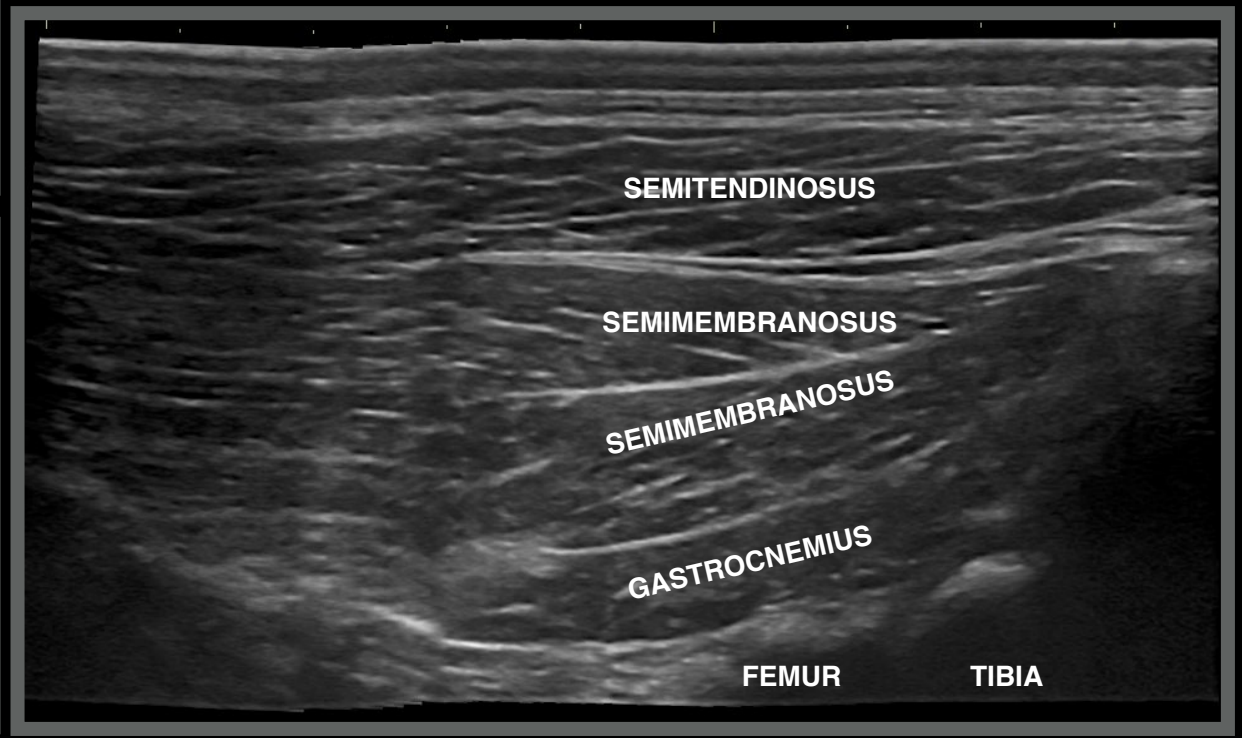

Jack, MN, 7 years

Right hock

Caudal face longitudinal scan 9-10

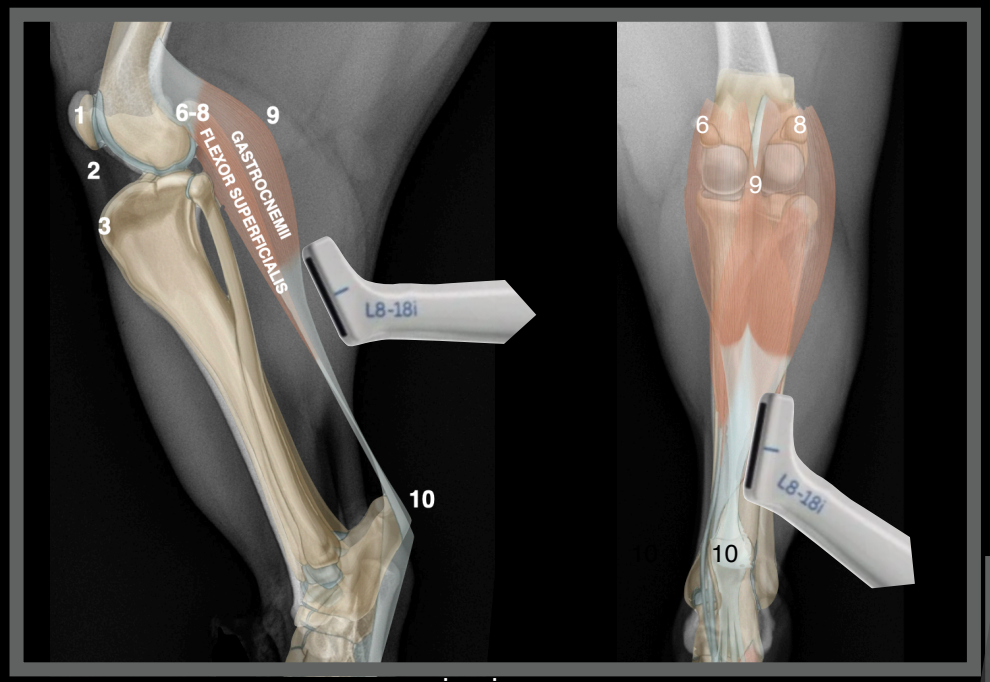

www.imaios.com

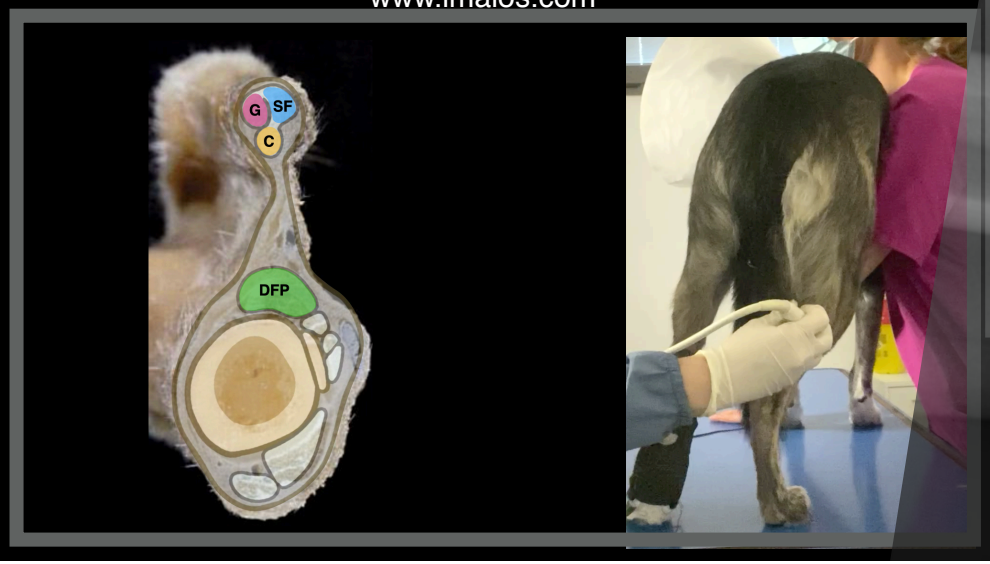

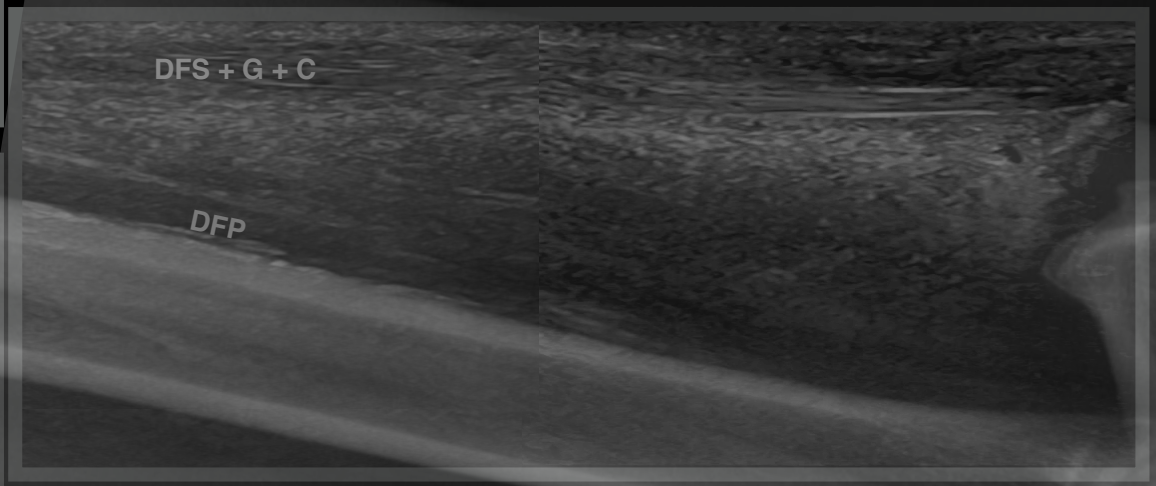

Jack, MN, 7 years

Left stifle

Caudal face longitudinal scan 9

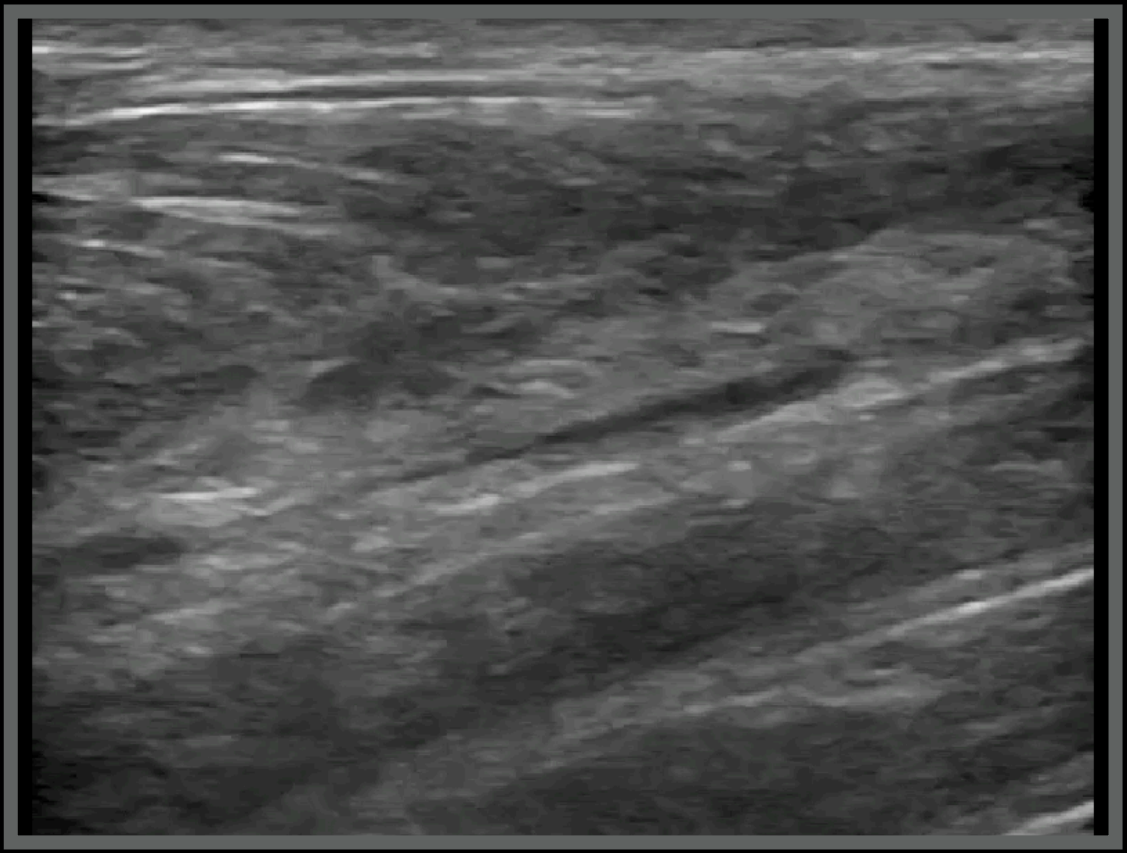

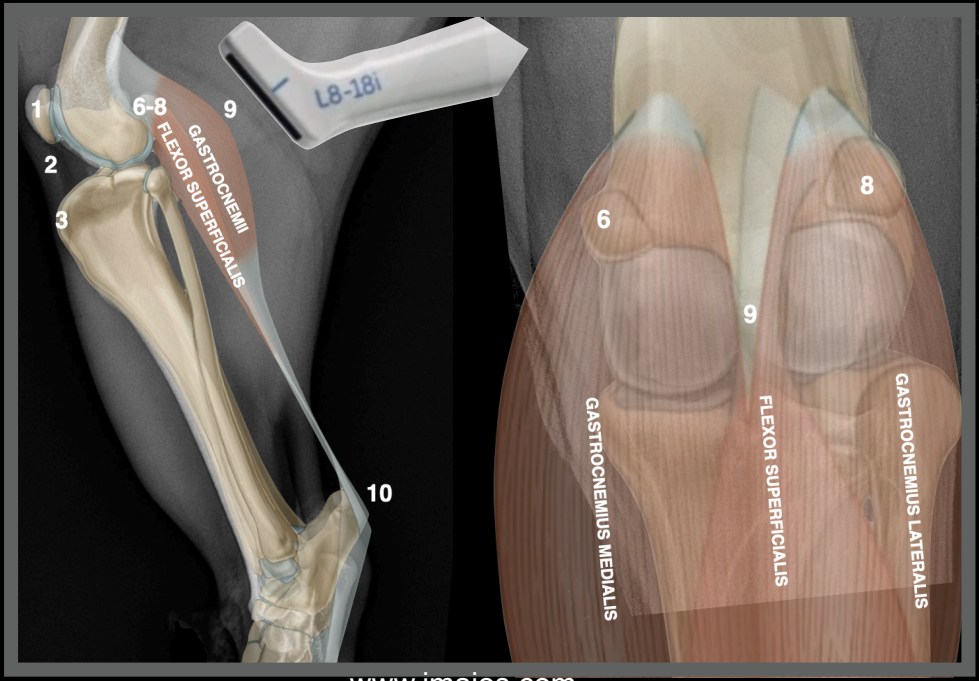

www.imaios.com

Jack, MN, 7 years

Left hock

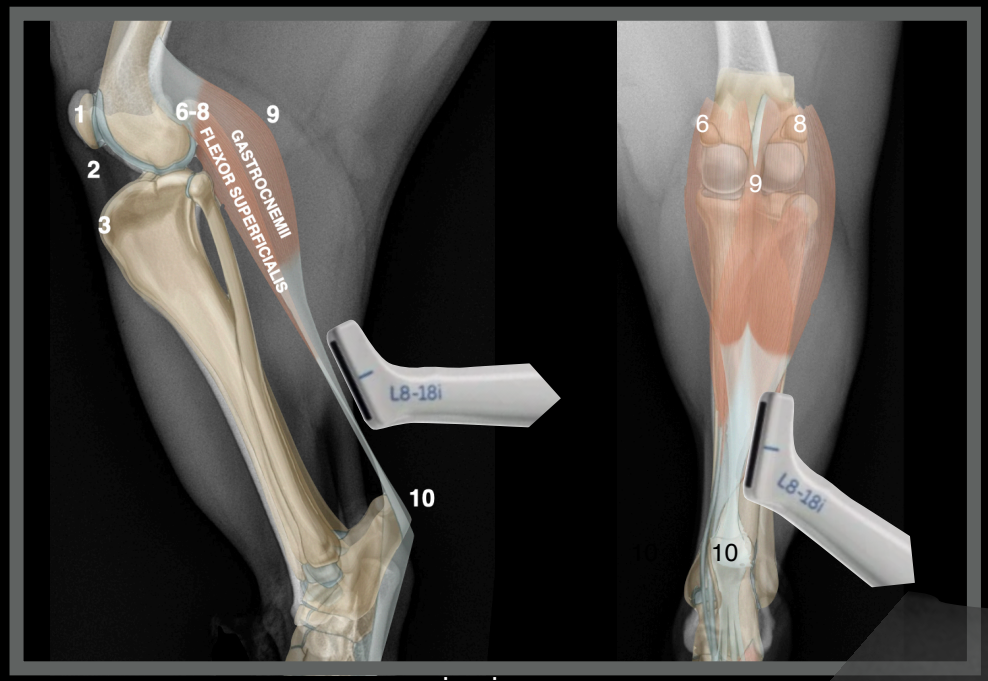

www.imaios.com

Caudal face longitudinal scan 10

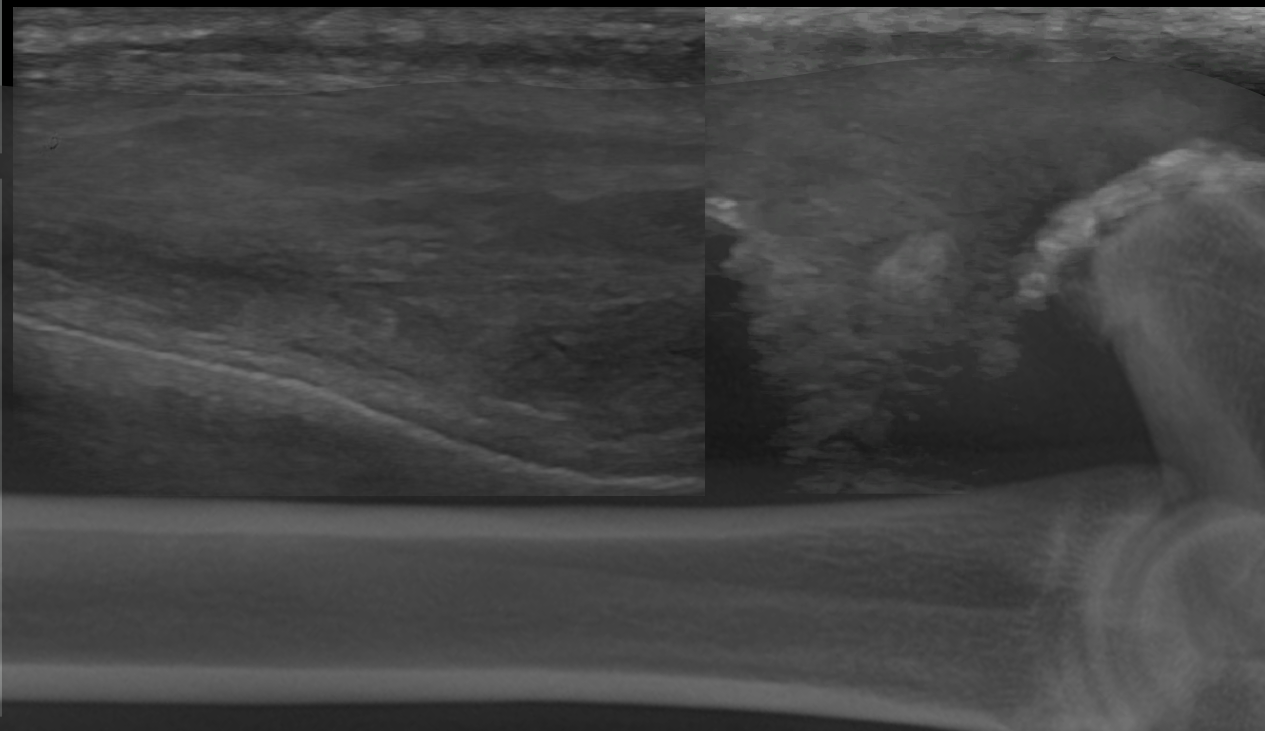

Jack, Doberman, MN, 7 years

Caudal face longitudinal scan 10

Right hock

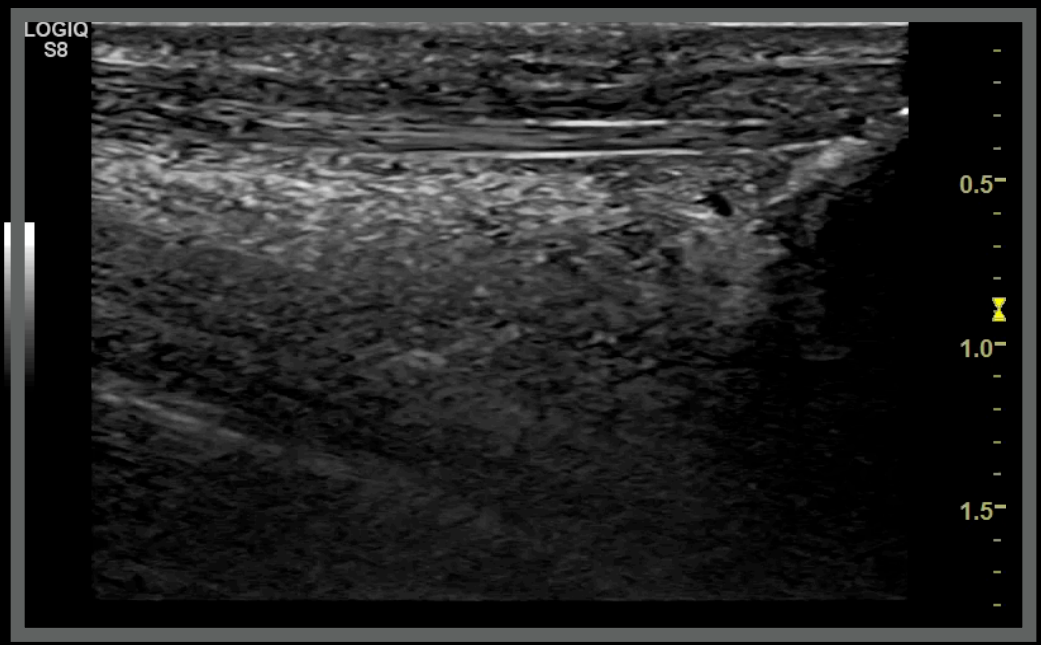

Left hock

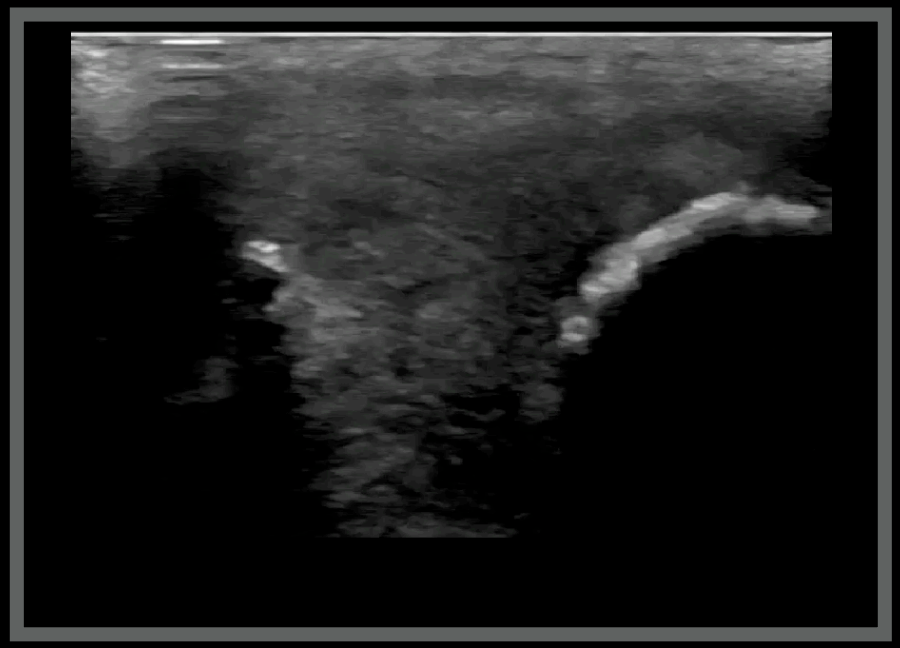

Jack, Doberman, MN, 7 years

Ultrasonographic diagnoses:

- Left-sided middle phase gracilis myopathy
- Severe third-degree chronic tendinopathy left Achille's tendon

What next?

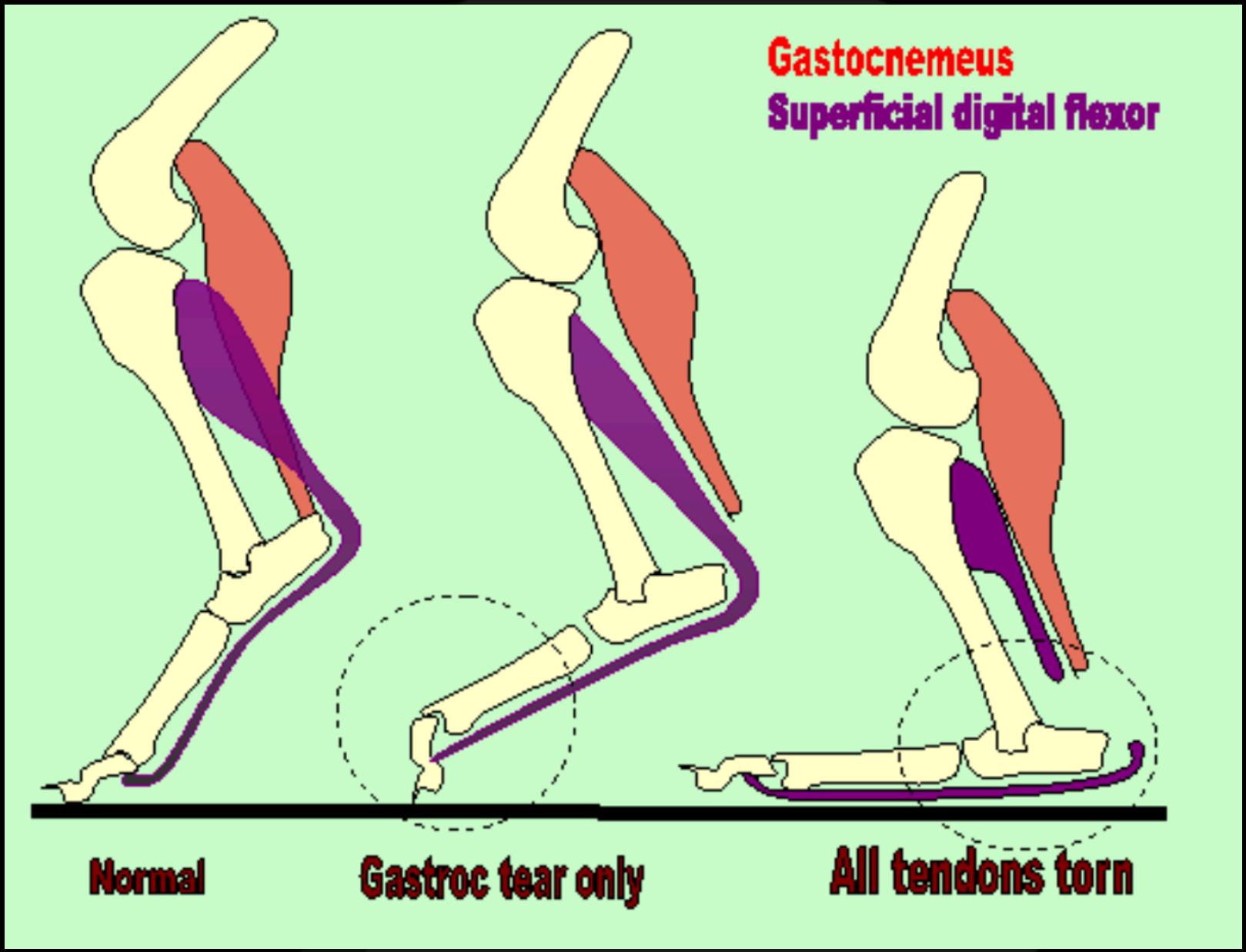
Gastocnemeus
Superficial digital flexor
Normal
Gastroc tear only
All tendons torn

Jack, Doberman, MN, 7 years

Follow up

- Physiotherapy:
  1. Stop the progression of gracilis myopathy
  2. Reestablish competence of left gastrocnemius muscle

Jack, Doberman, MN, 7 years

Three months later

- Much better for the last month
- Two treatment each week

Jack, Doberman, MN, 7 years

Caudal face longitudinal scan -9-9

Left gracilis

Time 0

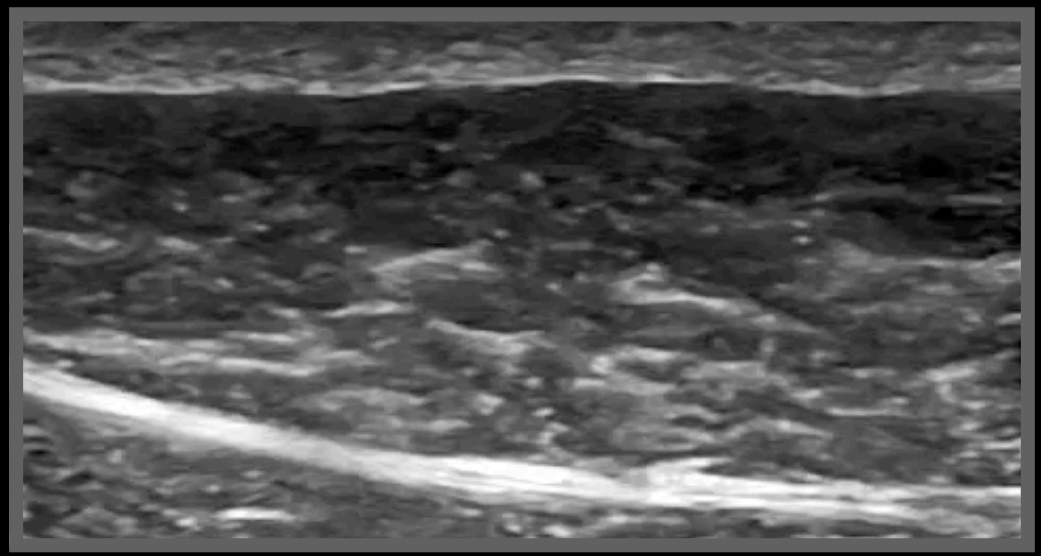

Left gracilis

Three months later

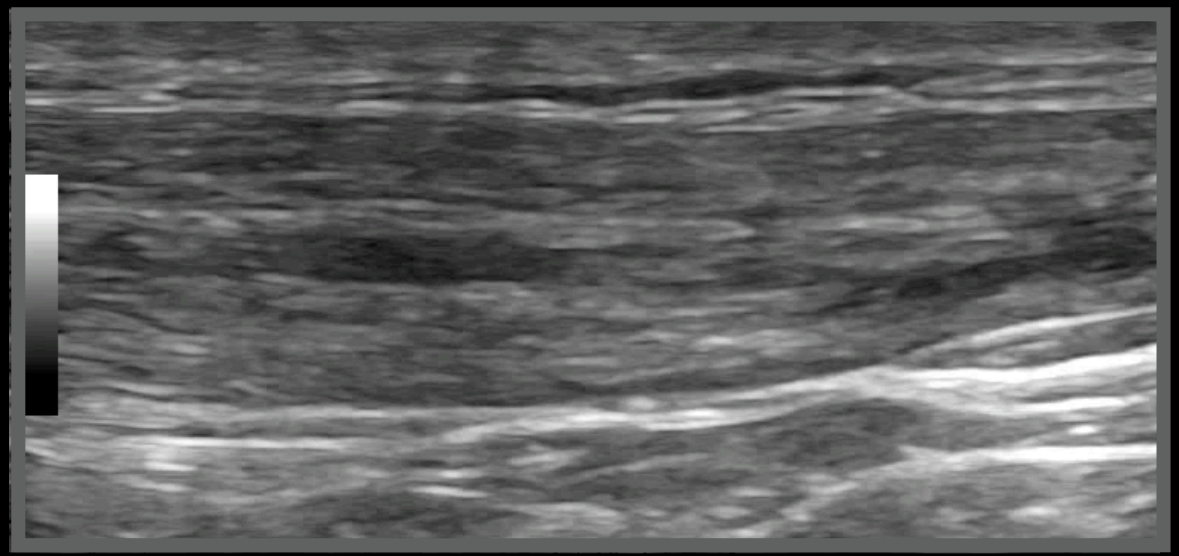

Jack, Doberman, MN, 7 years

Caudal face longitudinal scan 10

Left hock

Time 0

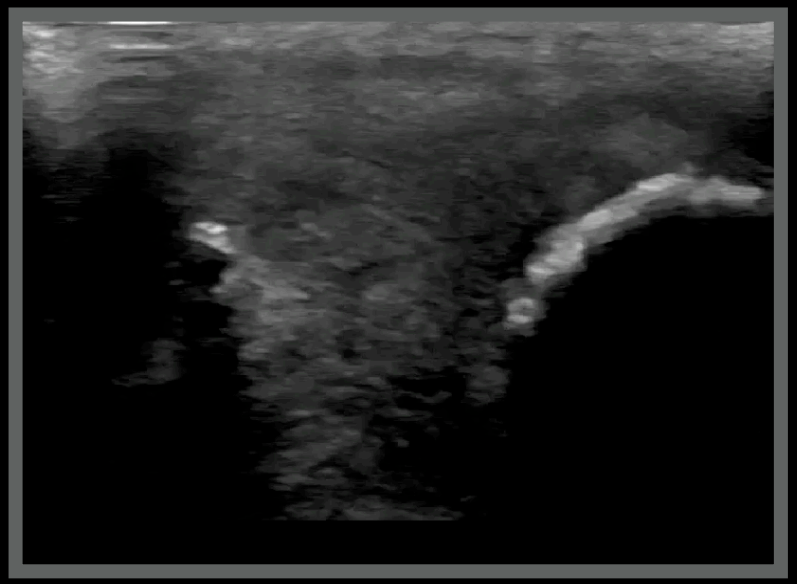

Left hock

Three months later

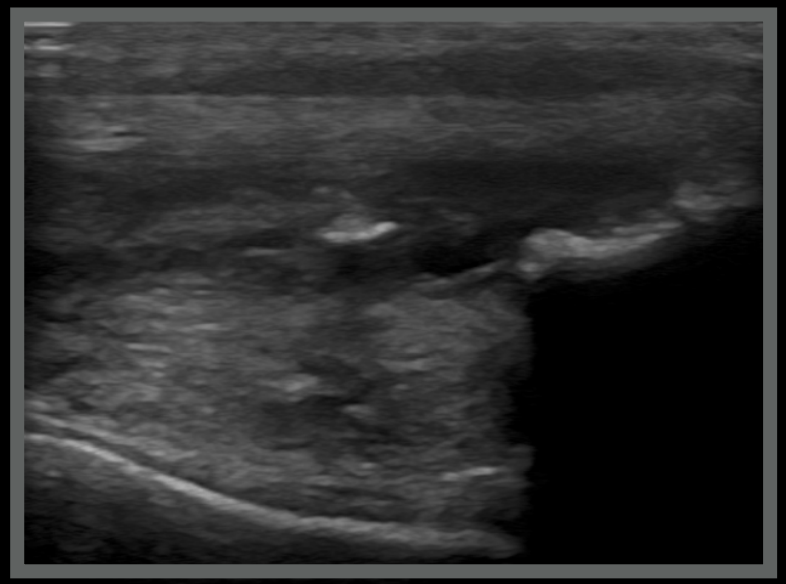

Conclusions

Lola, English Setter, FI, 4 years

- After hunting, She came back left hindlimb lame
- Plantigrade
- Planning surgical repair of Achille's tendon

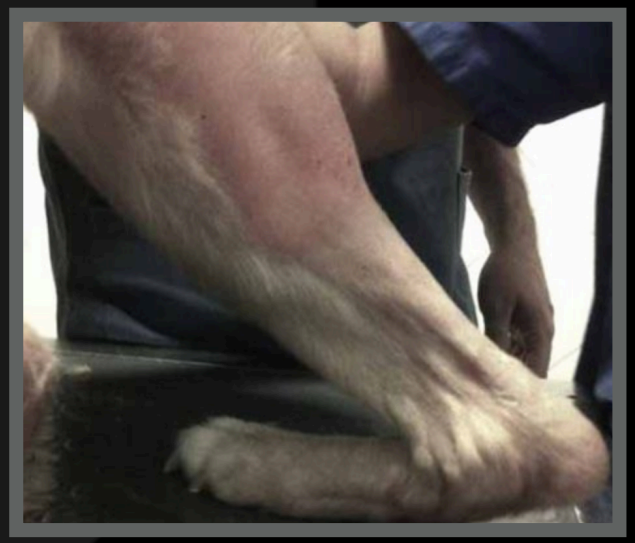

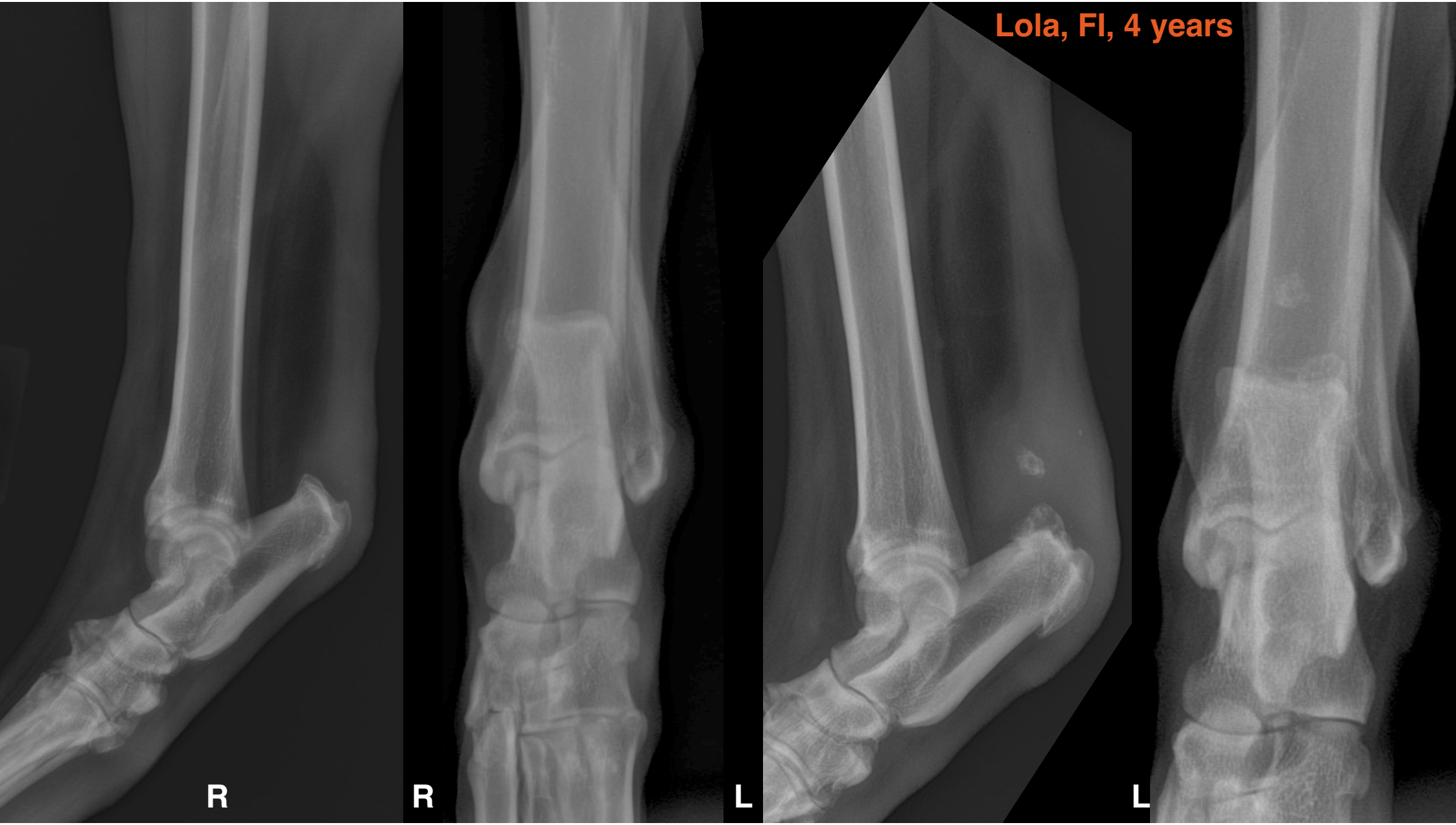
Lola, FI, 4 years
R
R
L
L

Ultrasonographic technique

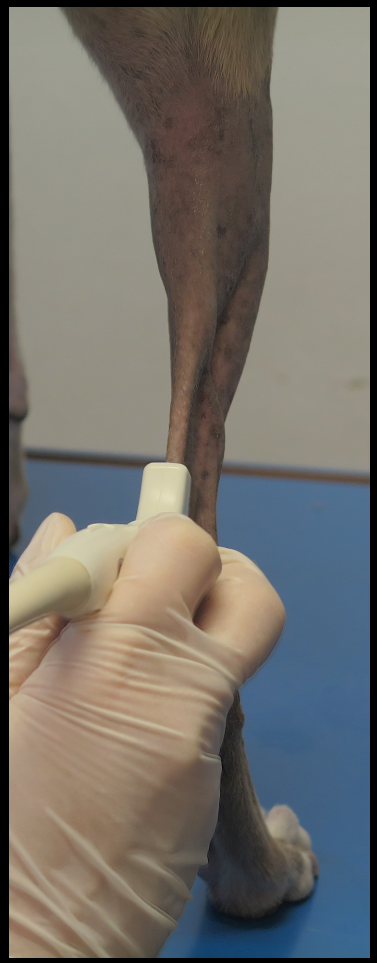

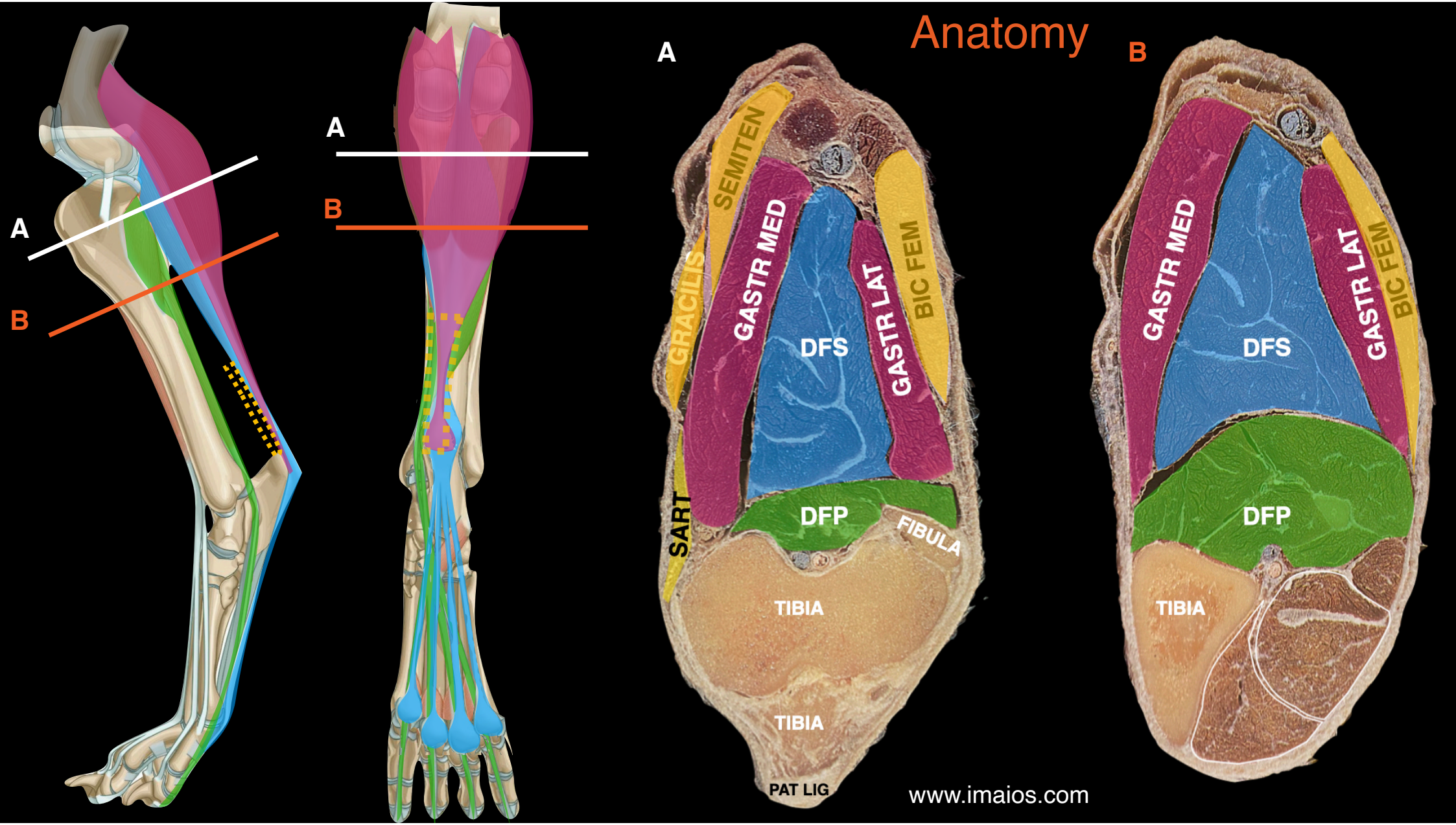
Anatomy
A
B
A
B
A
B
SEMITEN
GRACILIS
GASTR MED
DFS
GASTR LAT
BIC FEM
SART
DFP
FIBULA
TIBIA
TIBIA
PAT LIG
GASTR MED
DFS
GASTR LAT
BIC FEM
DFP
TIBIA
www.imaios.com

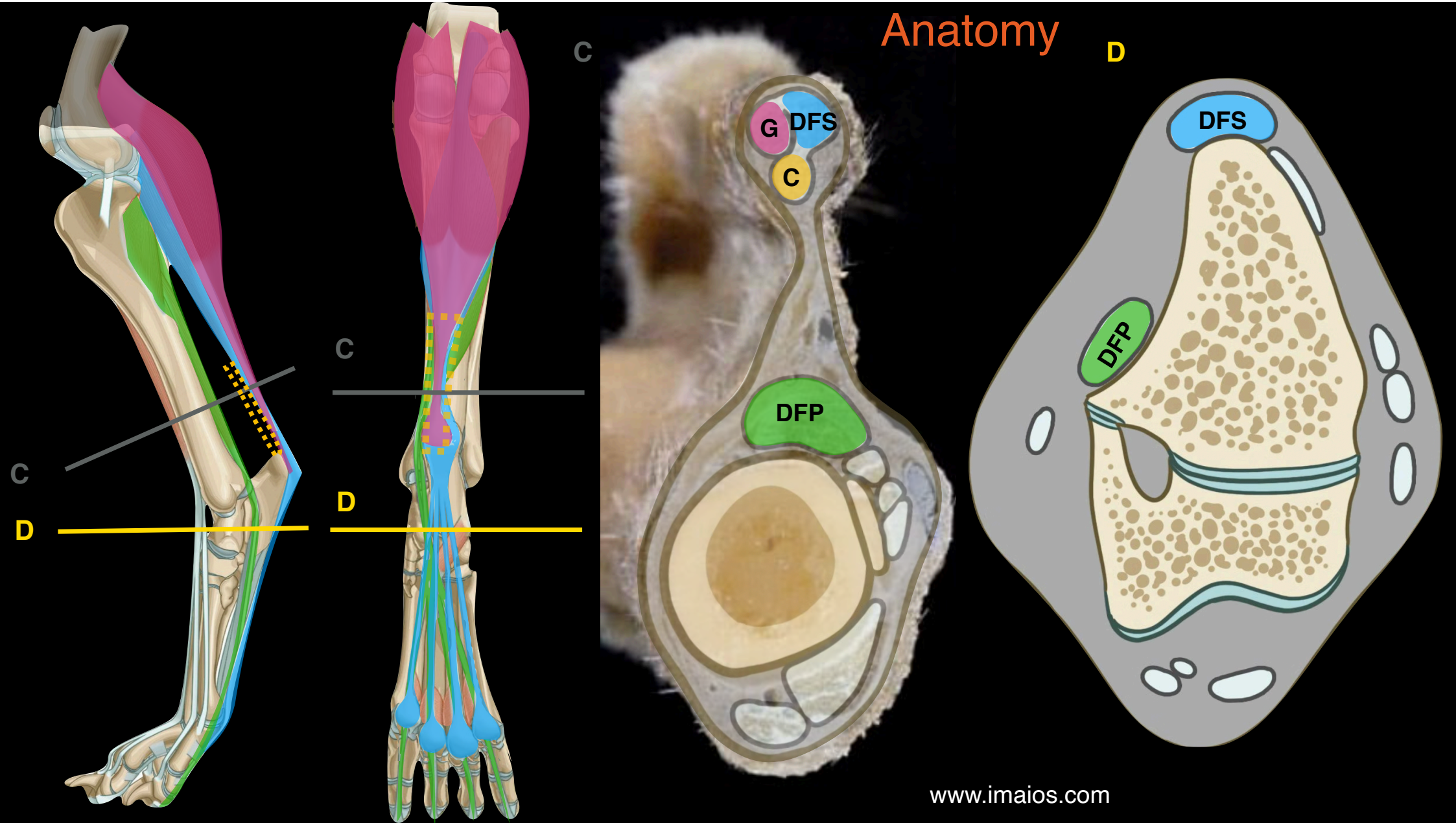
Anatomy
C
D
C
D
C
D
G
DFS
C
DFP
DFS
DFP
www.imaios.com

Lola, FI, 4 years

Right stifle

Caudal face transverse scan 9

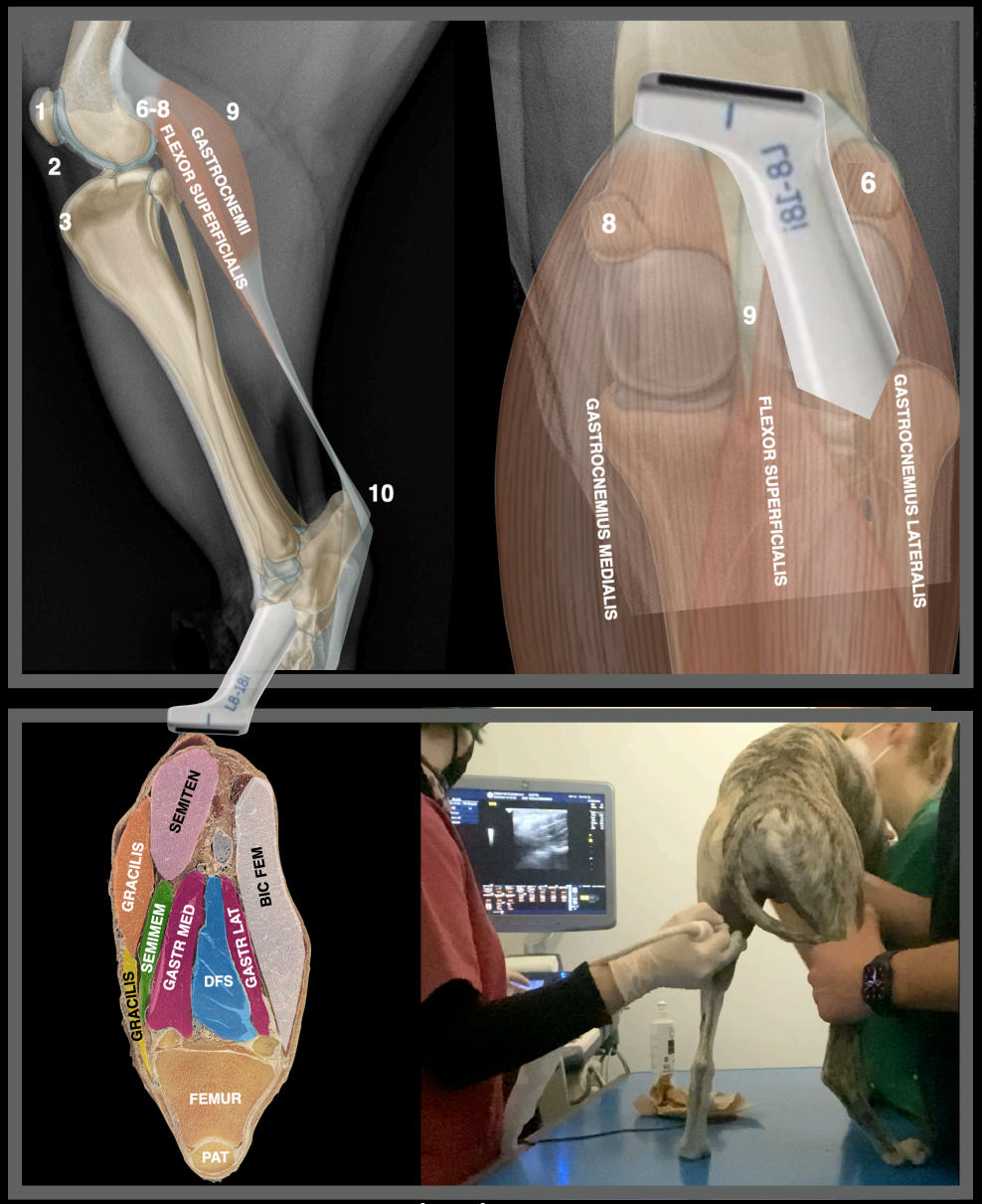

www.imaios.com

Lola, FI, 4 years

Right stifle

Caudal face transverse scan 9

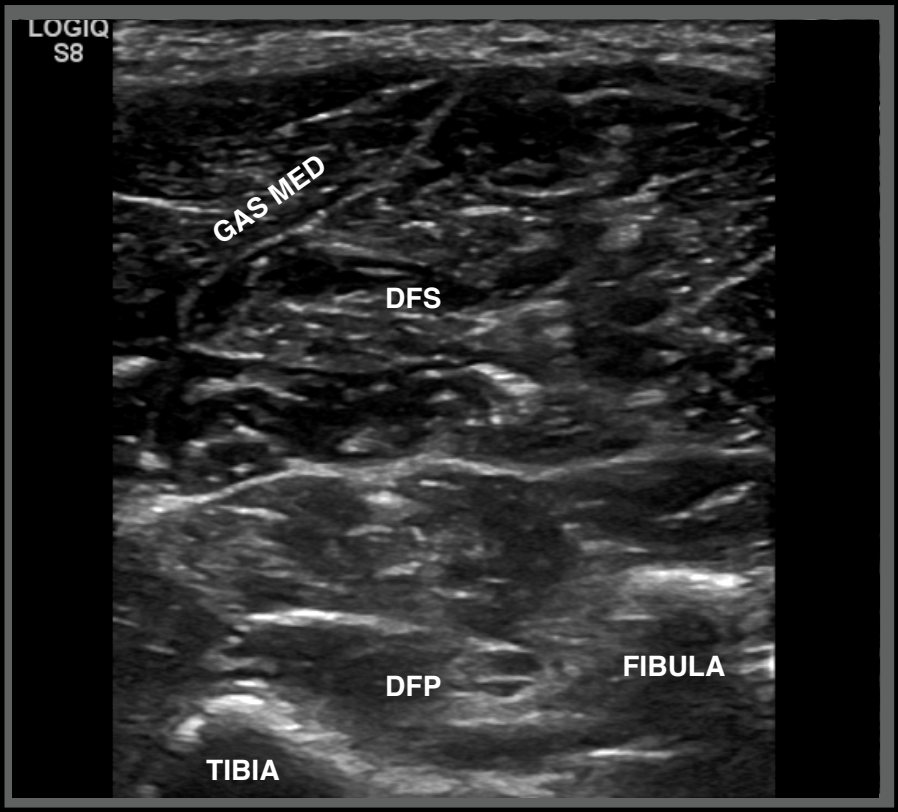

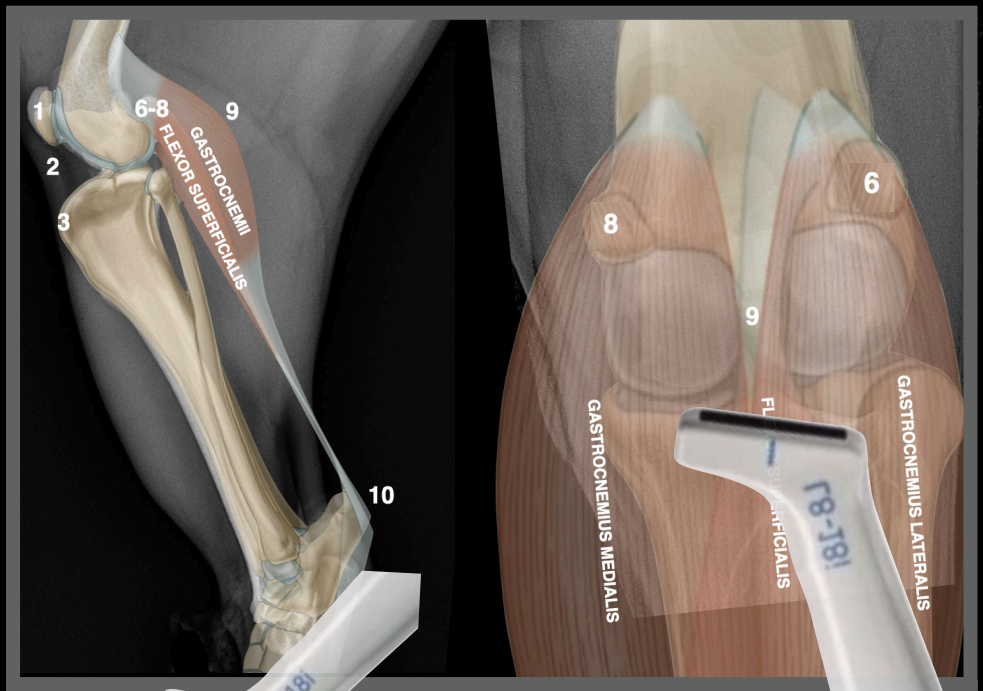

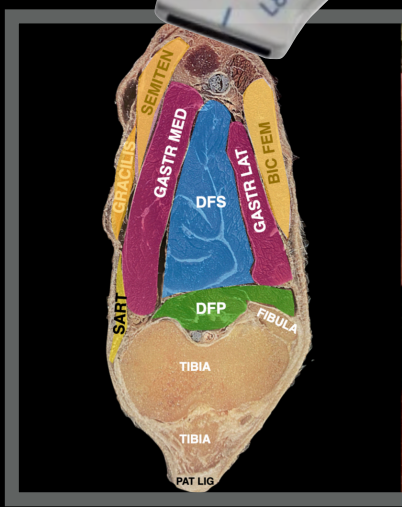

www.imaios.com

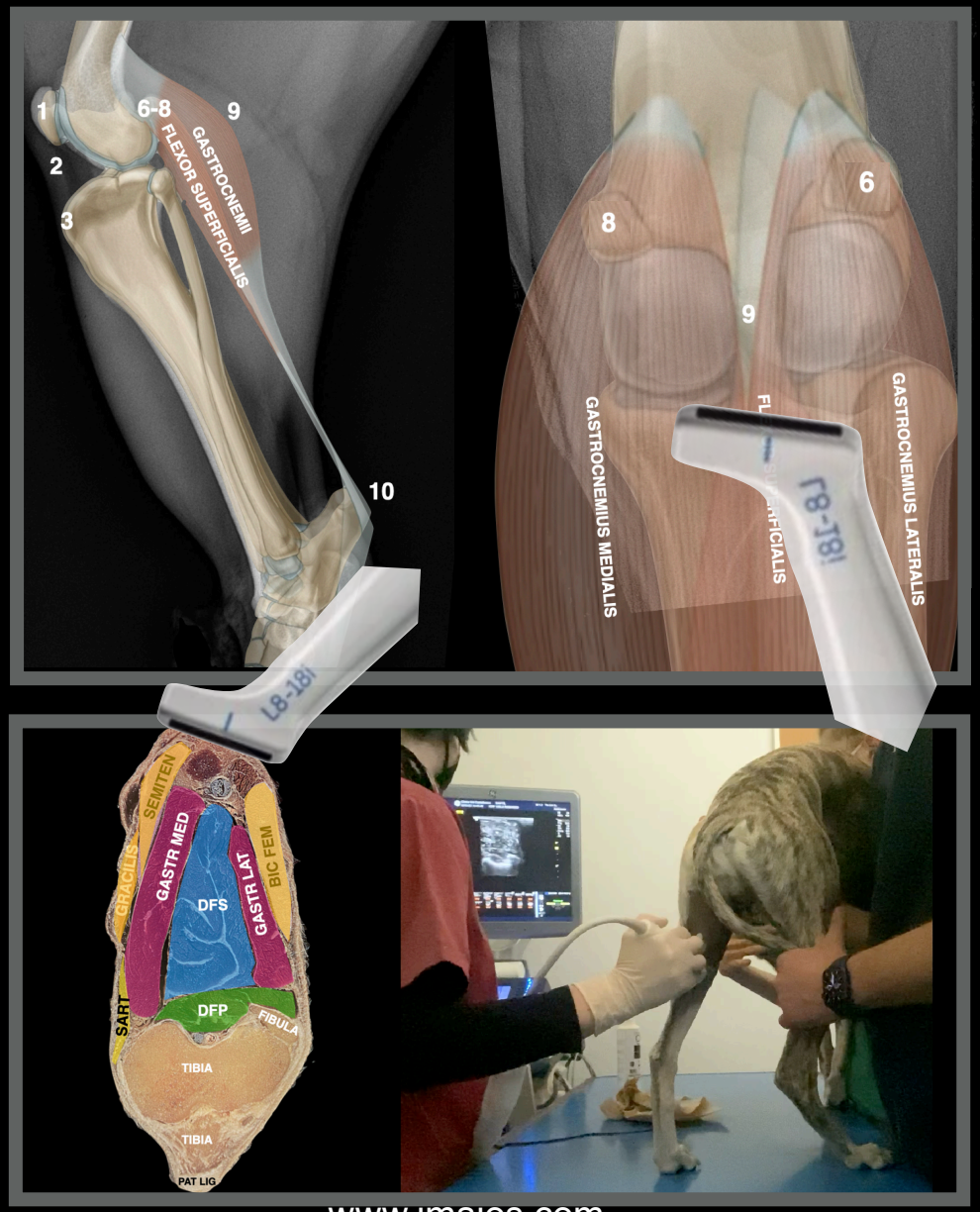

Lola, FI, 4 years

Left stifle

Caudal face transverse scan 9

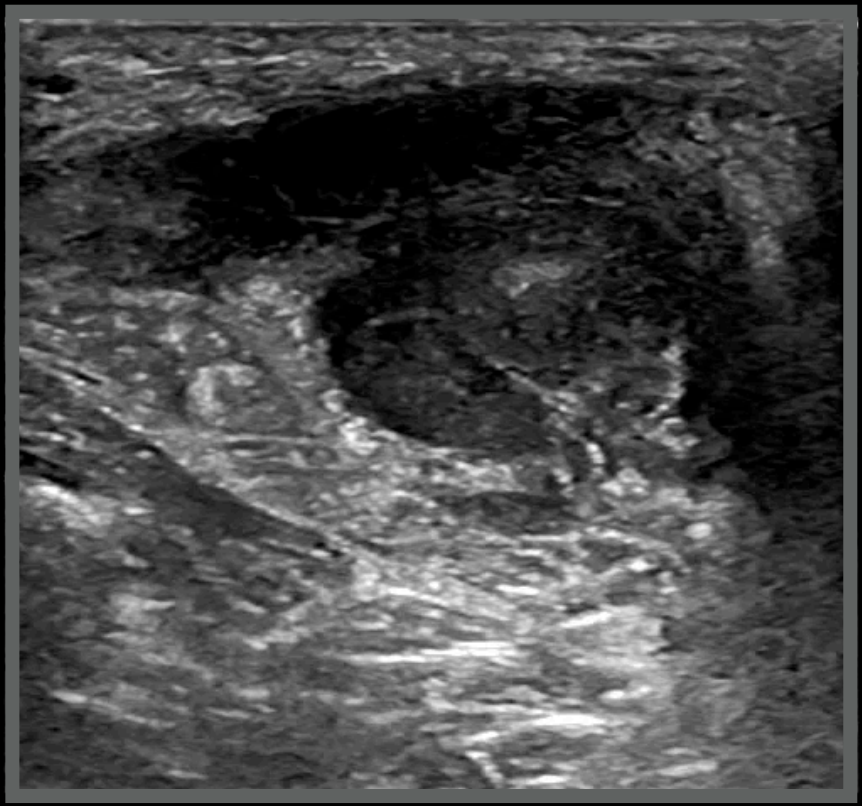

www.imaios.com

Lola, FI, 4 years

Right stifle

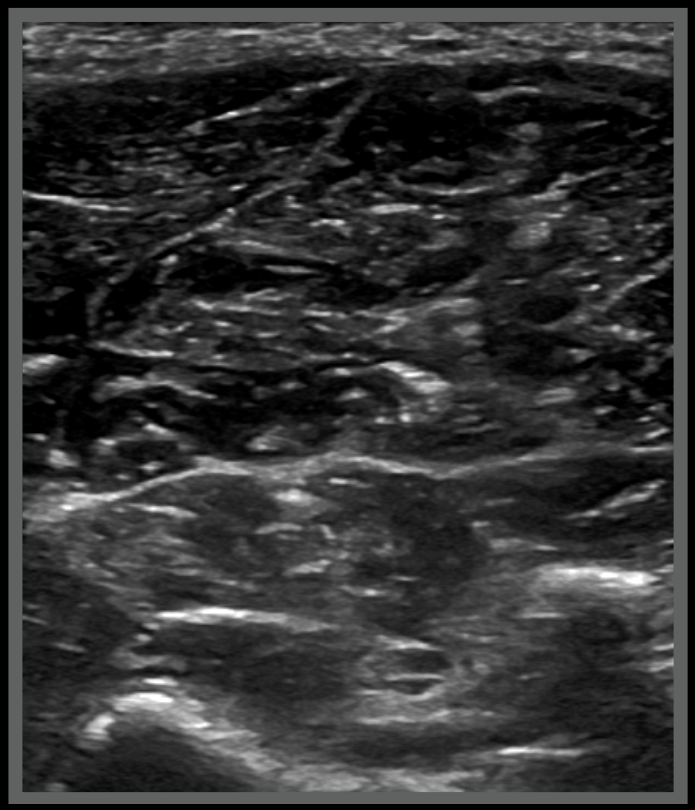

Left stifle

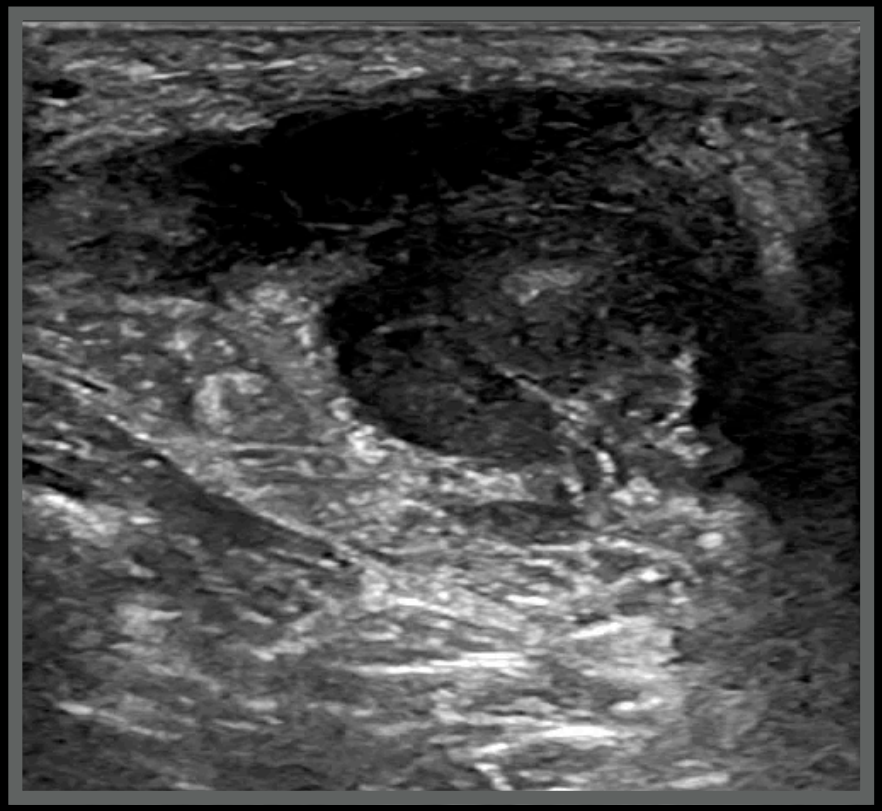

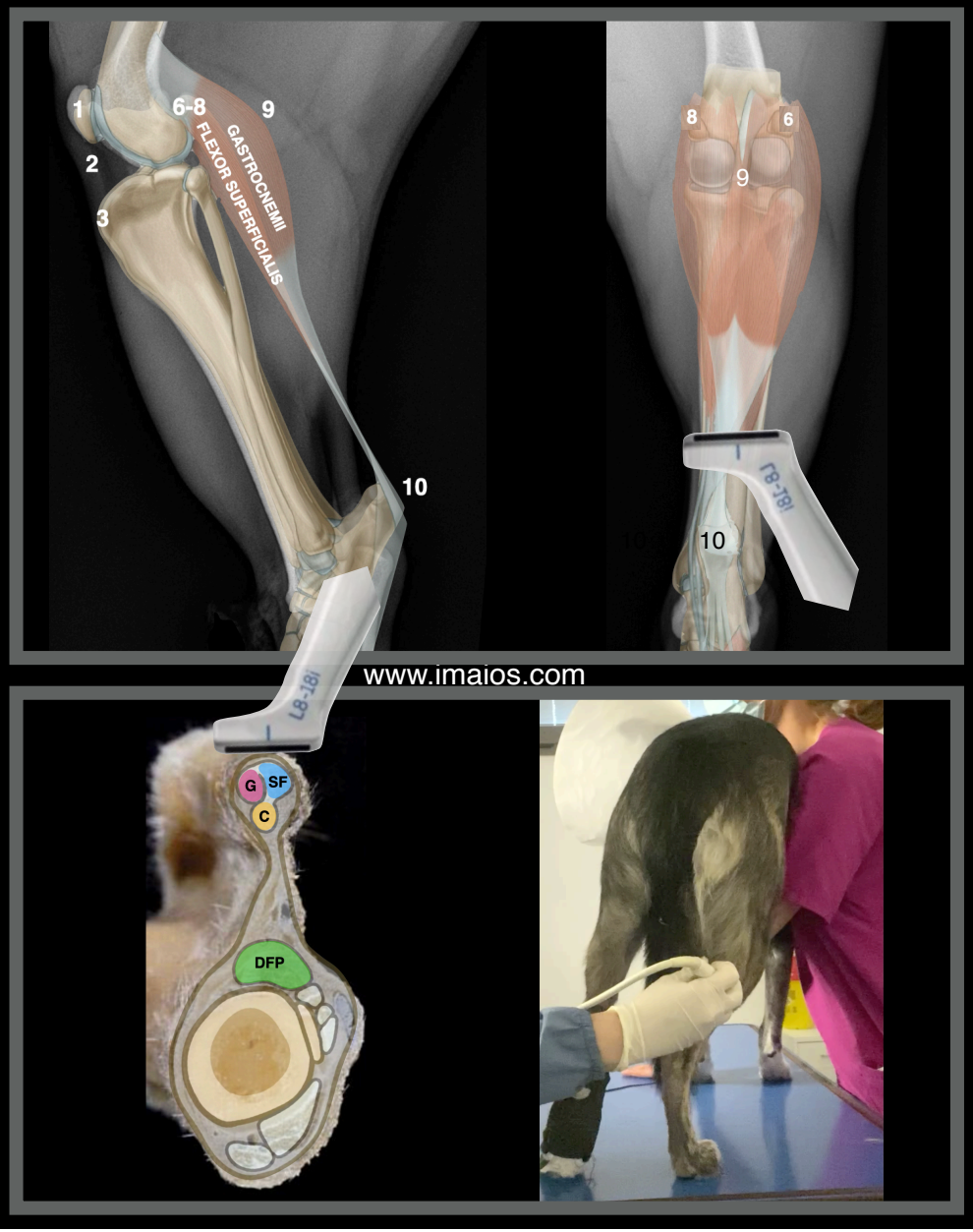

Lola, FI, 4 years

Right leg

Caudal face transverse scan 9

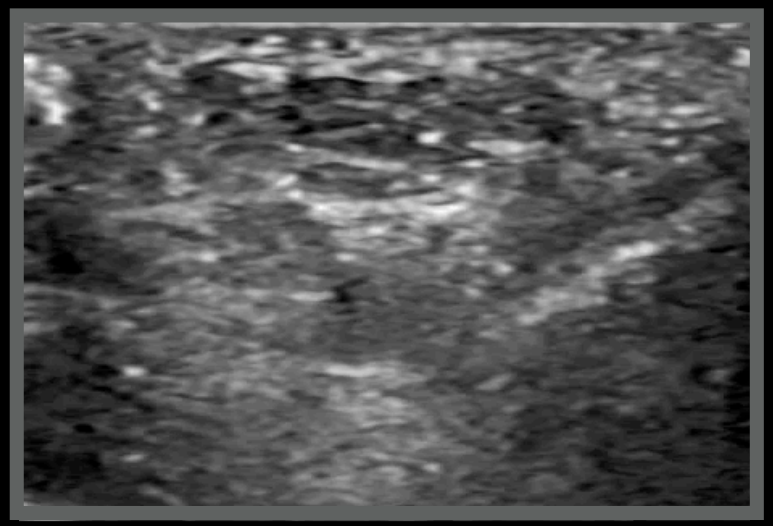

Lola, FI, 4 years

Left leg

Caudal face transverse scan 9

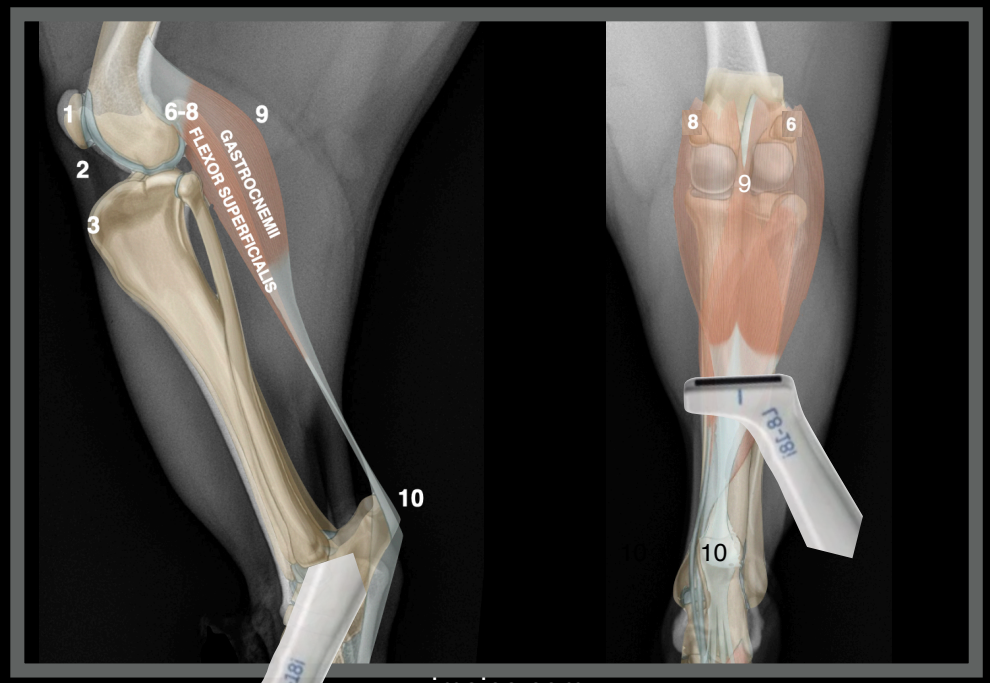

www.imaios.com

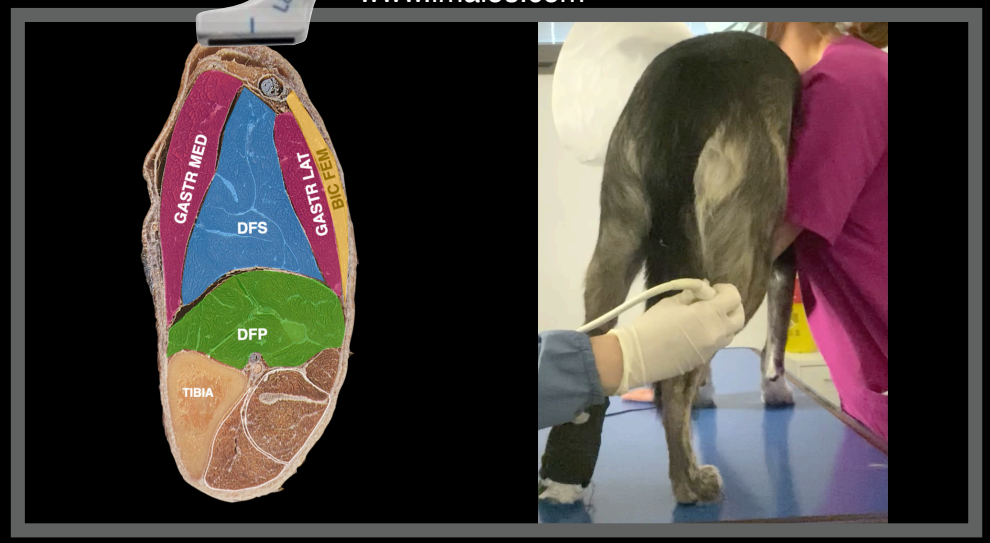

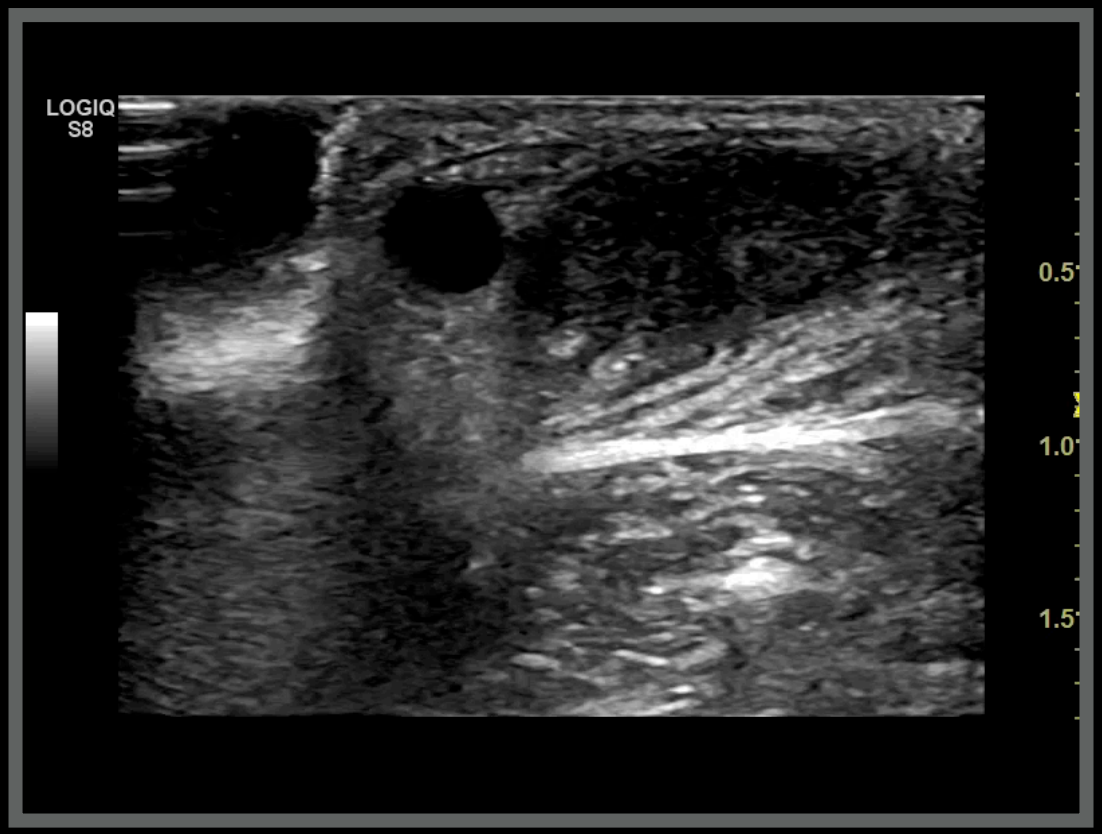

Lola, FI, 4 years

Left leg

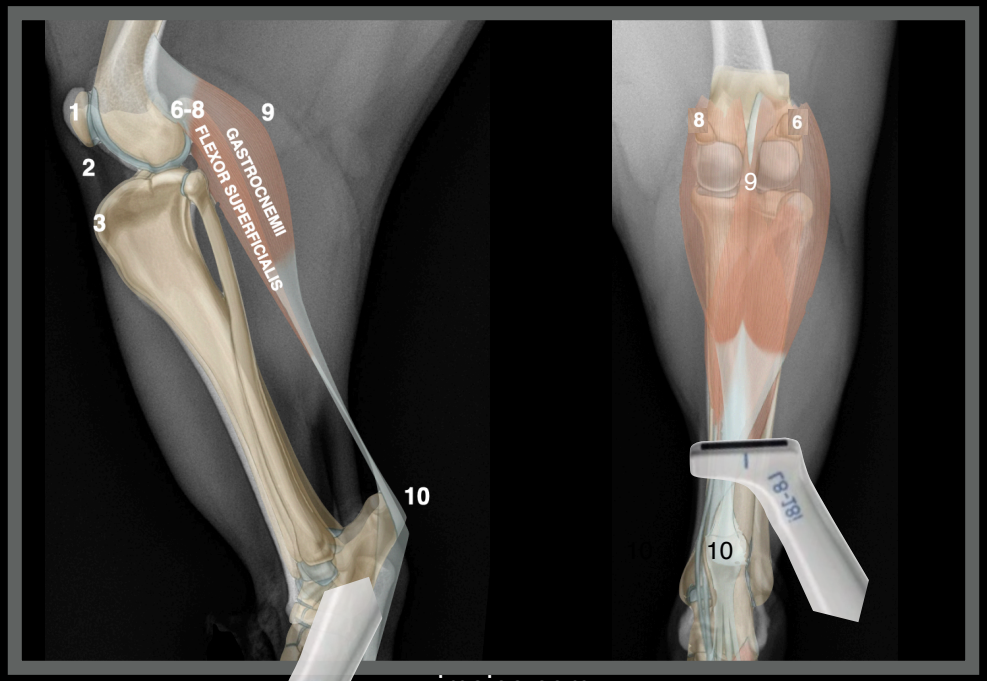

www.imaios.com

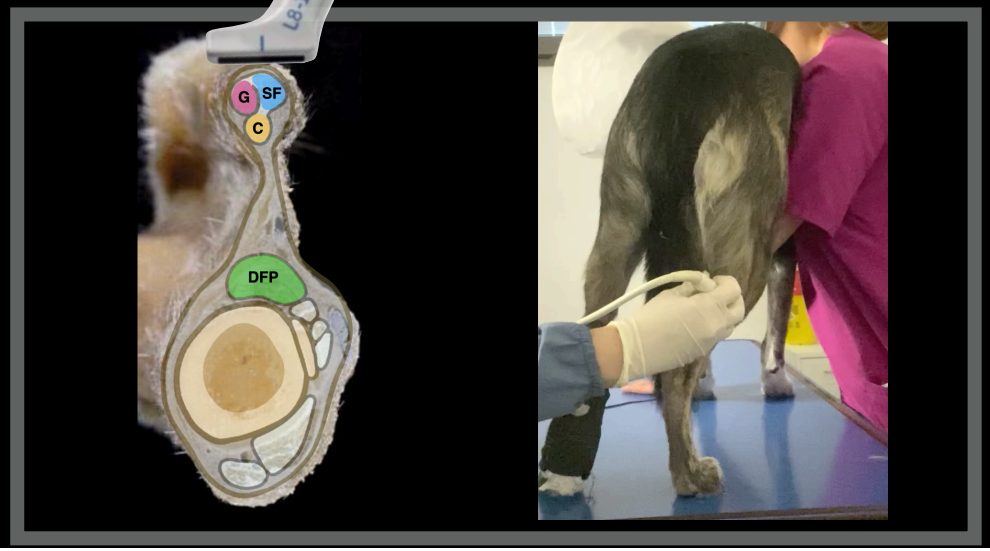

Caudal face transverse scan 9

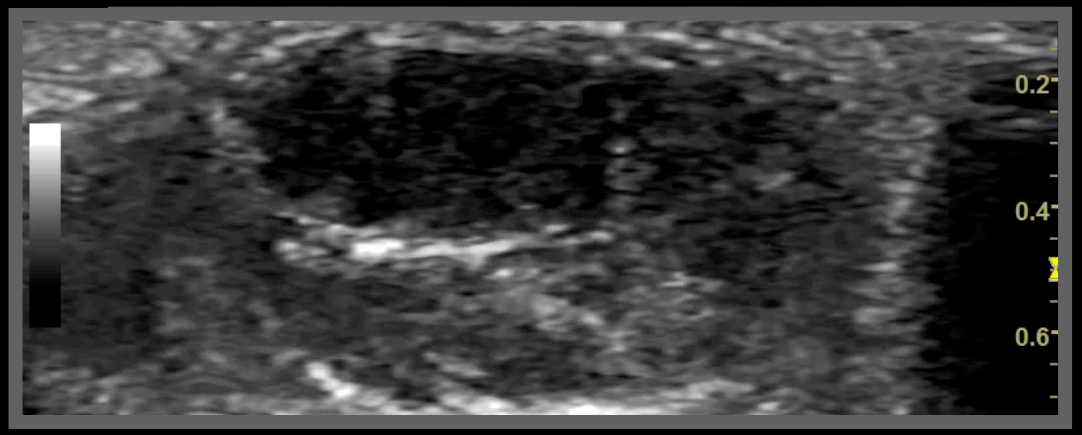

Lola, FI, 4 years

Right leg

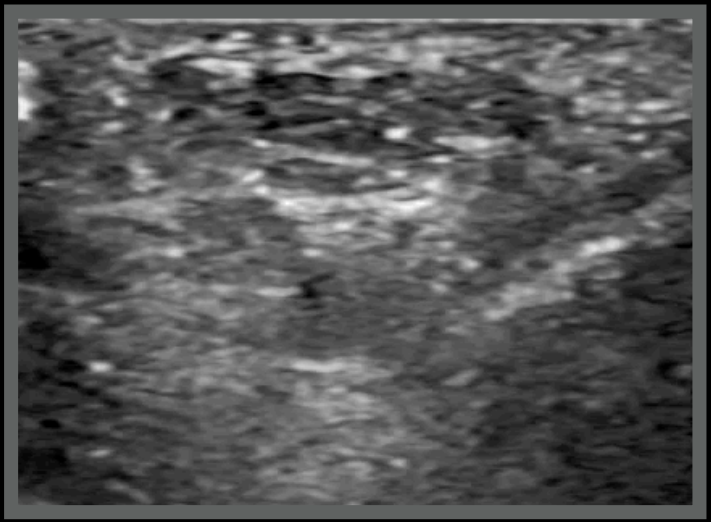

Left leg

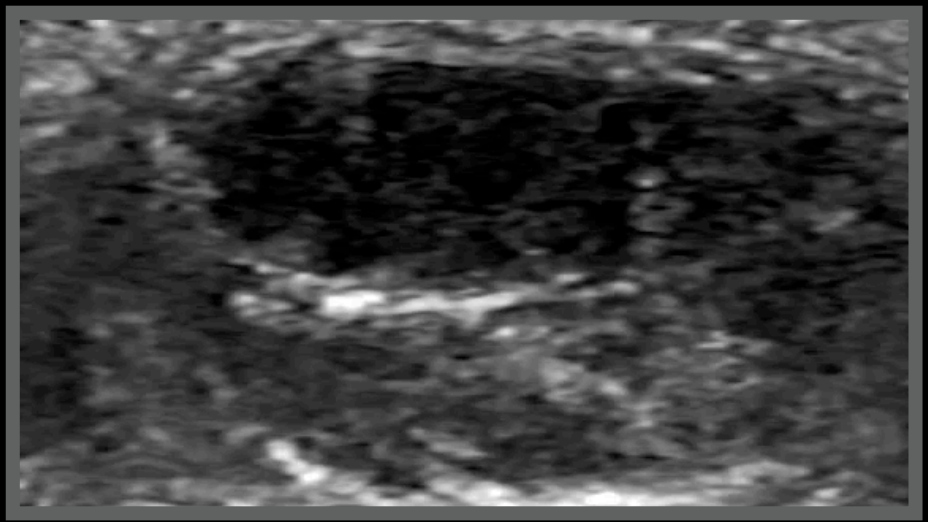

Lola, FI, 4 years

Right stifle

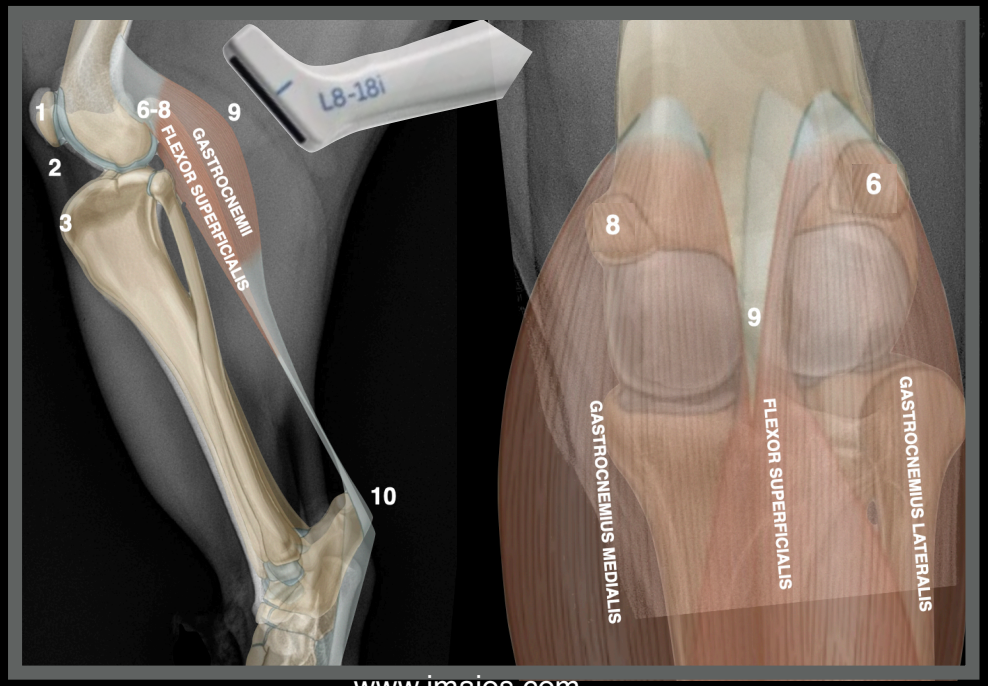

www.imaios.com

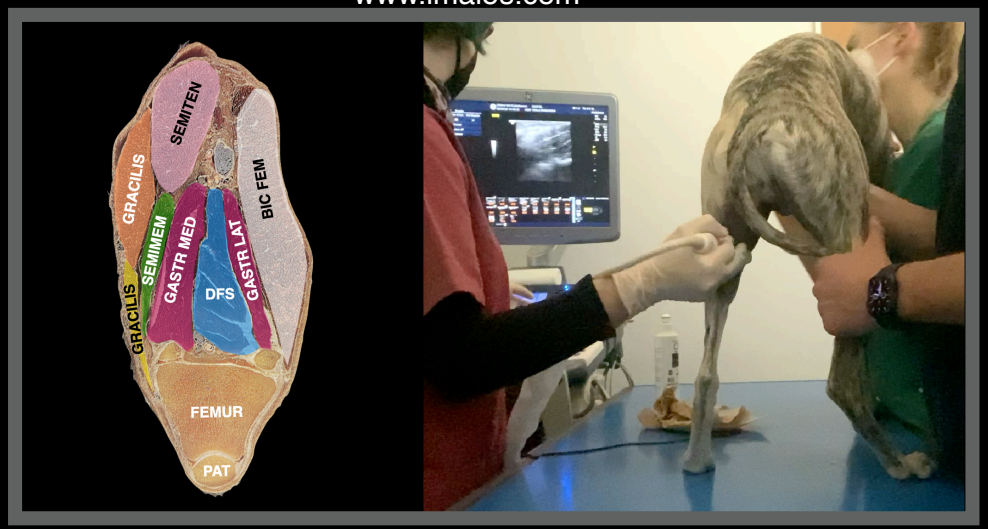

Caudal face longitudinal scan

9

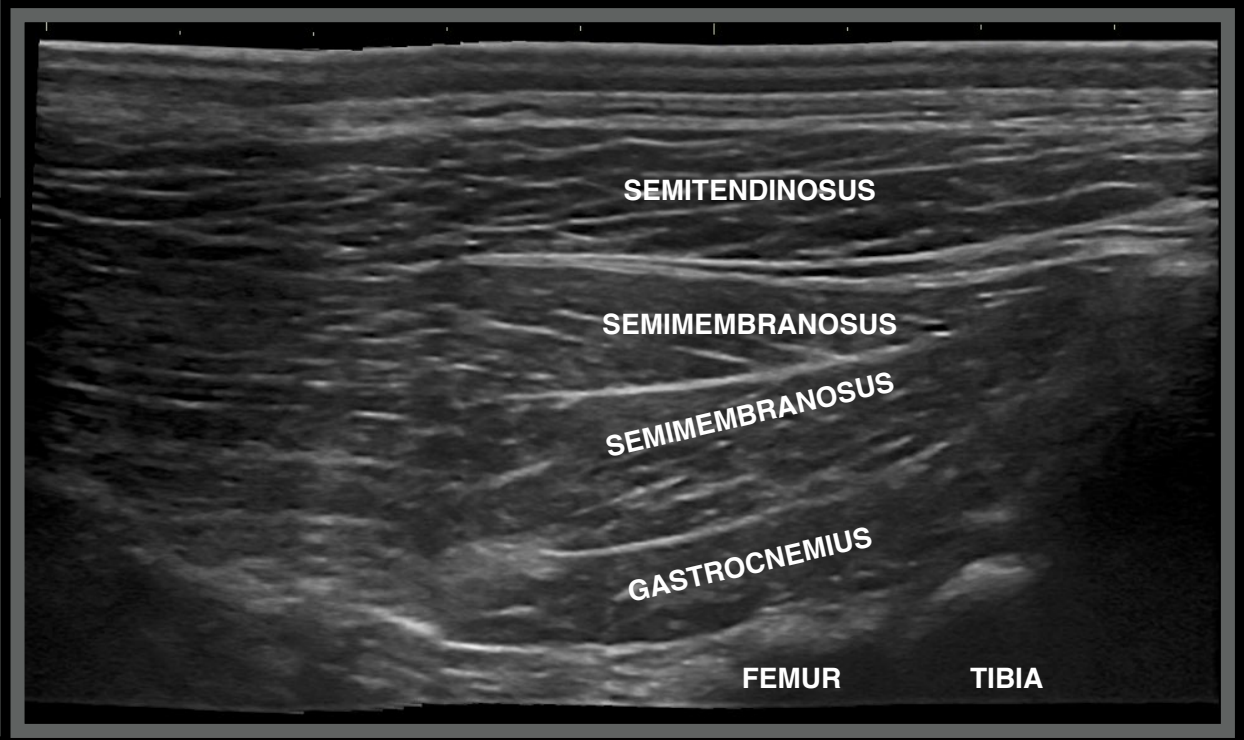

Lola, FI, 4 years

Right stifle

Caudal face longitudinal scan

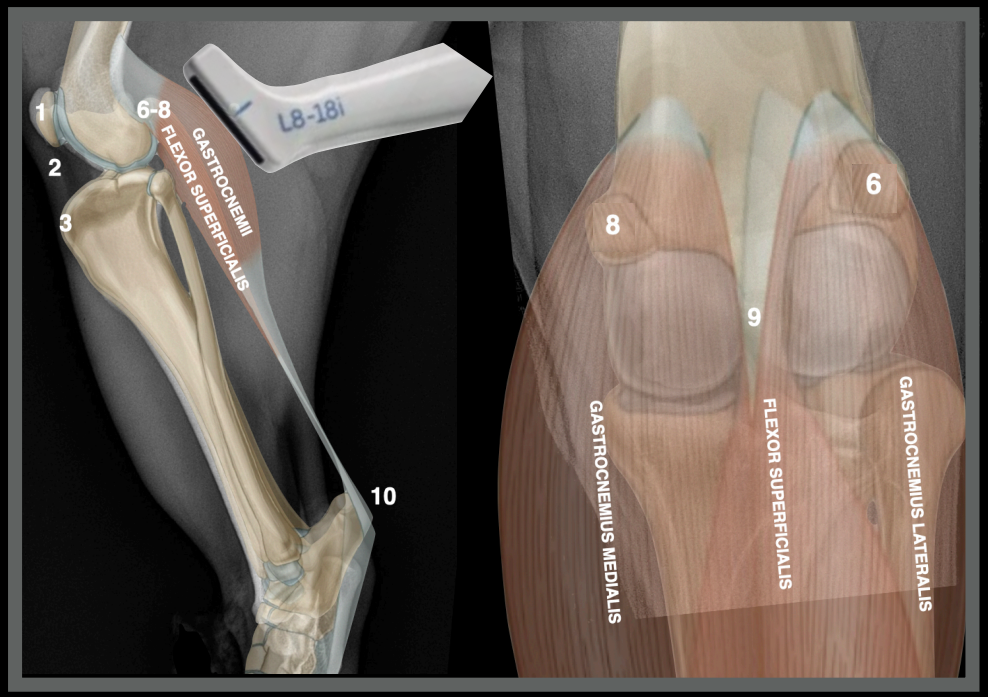

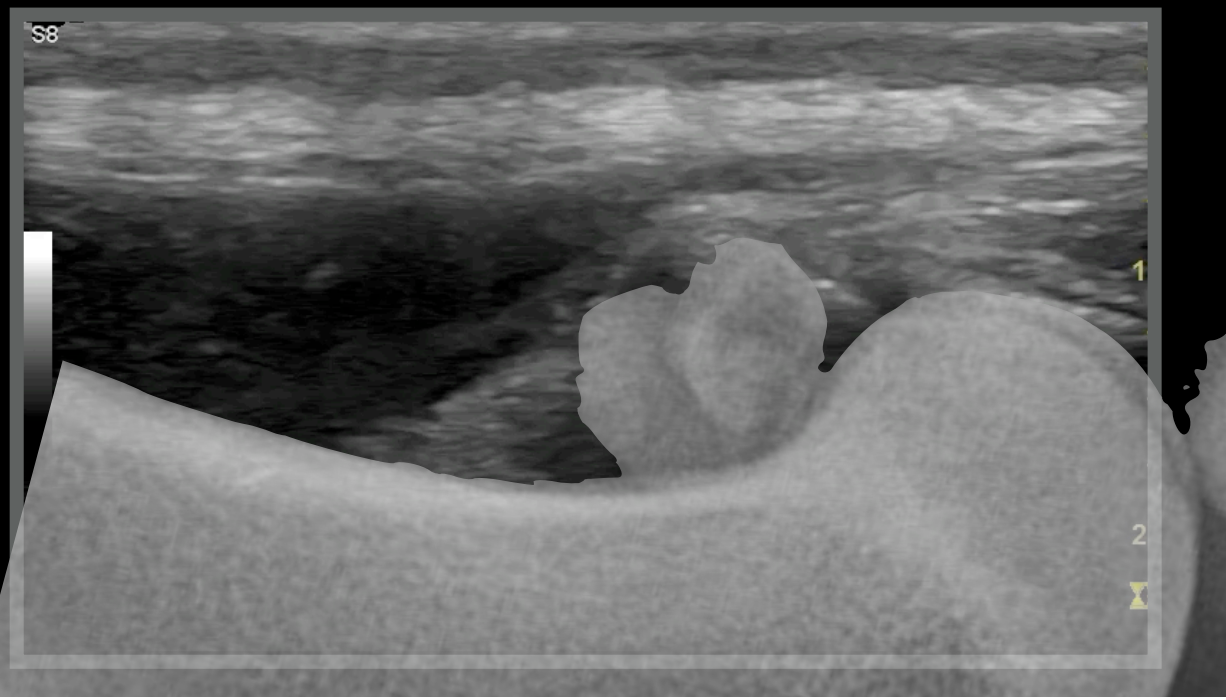

Lola, FI, 4 years

Right hock

Caudal face longitudinal scan 9-10

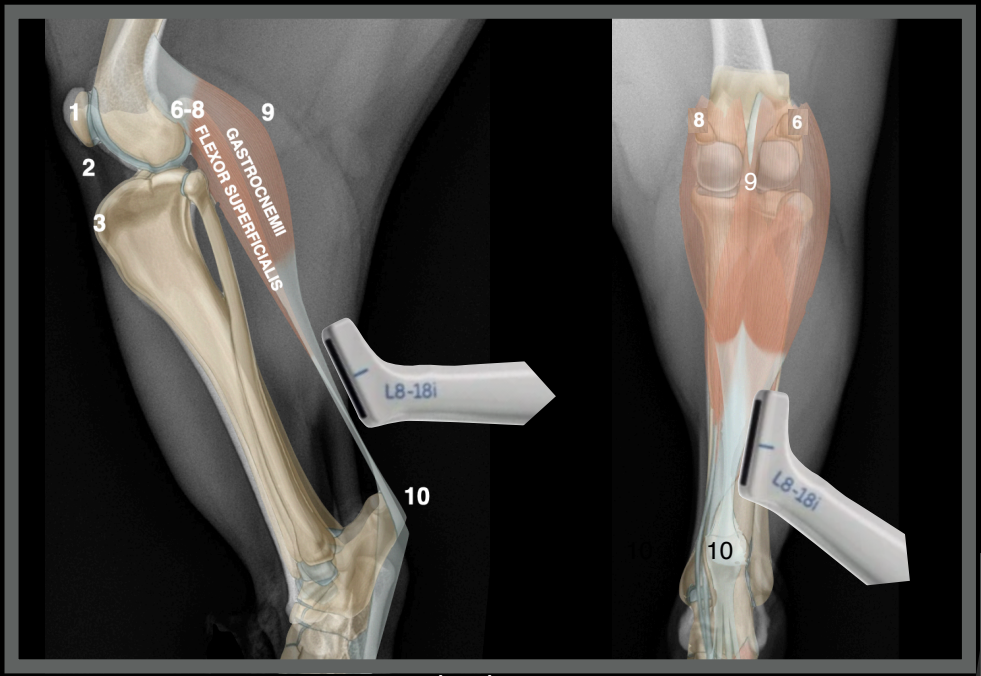

www.imaios.com

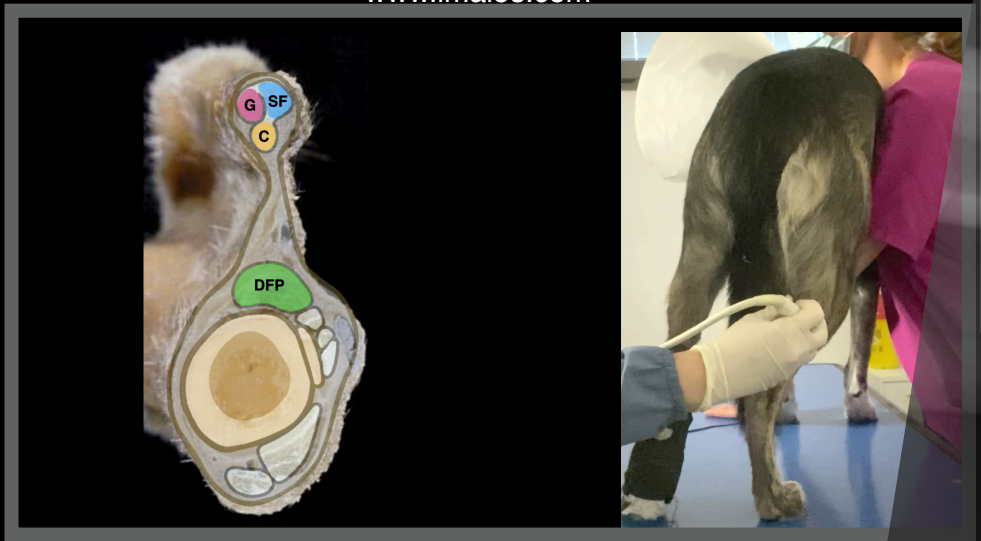



Lola, FI, 4 years

Left leg

Caudal face longitudinal scan 9

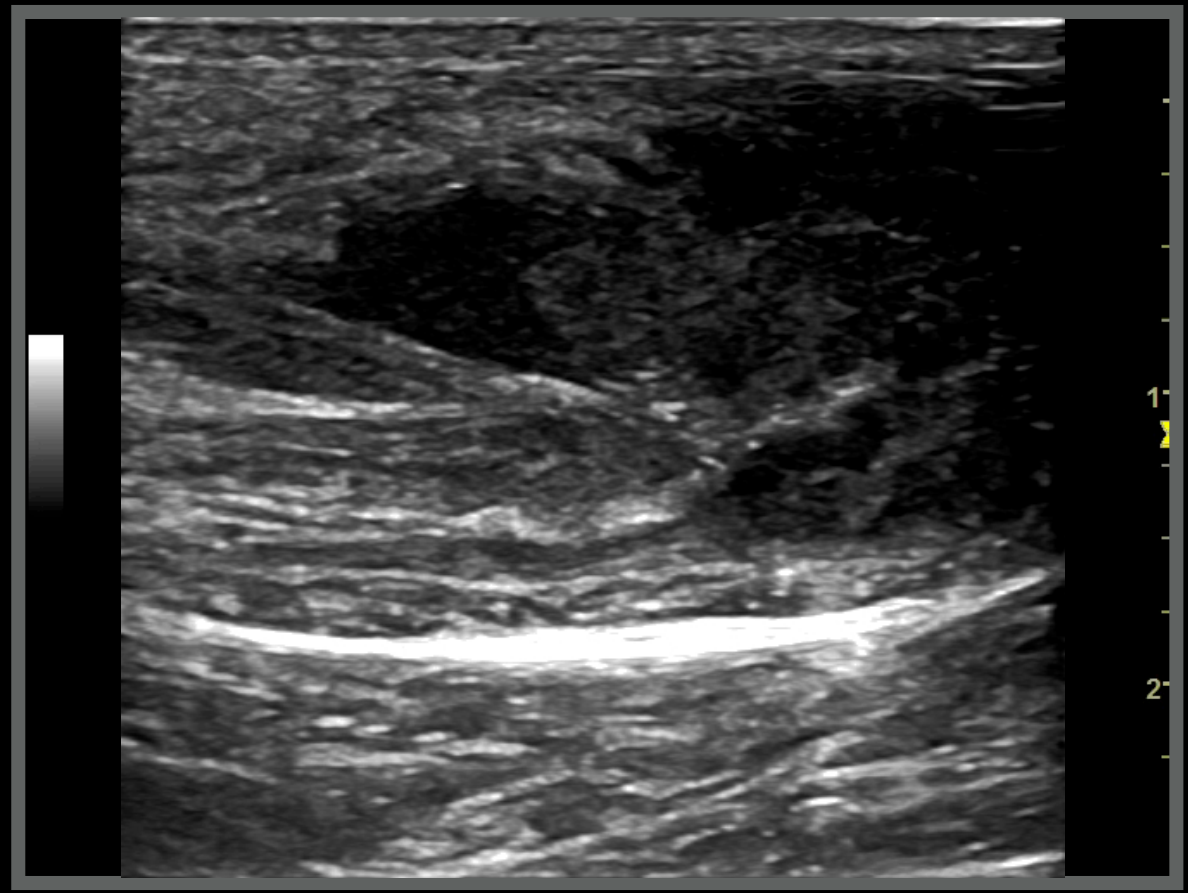

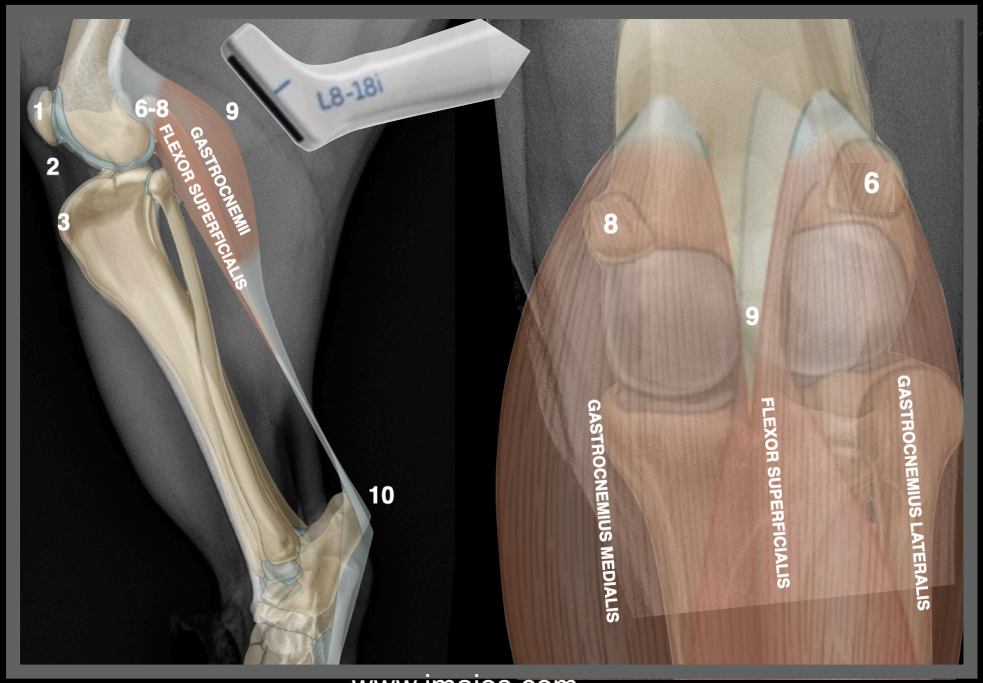

www.imaios.com

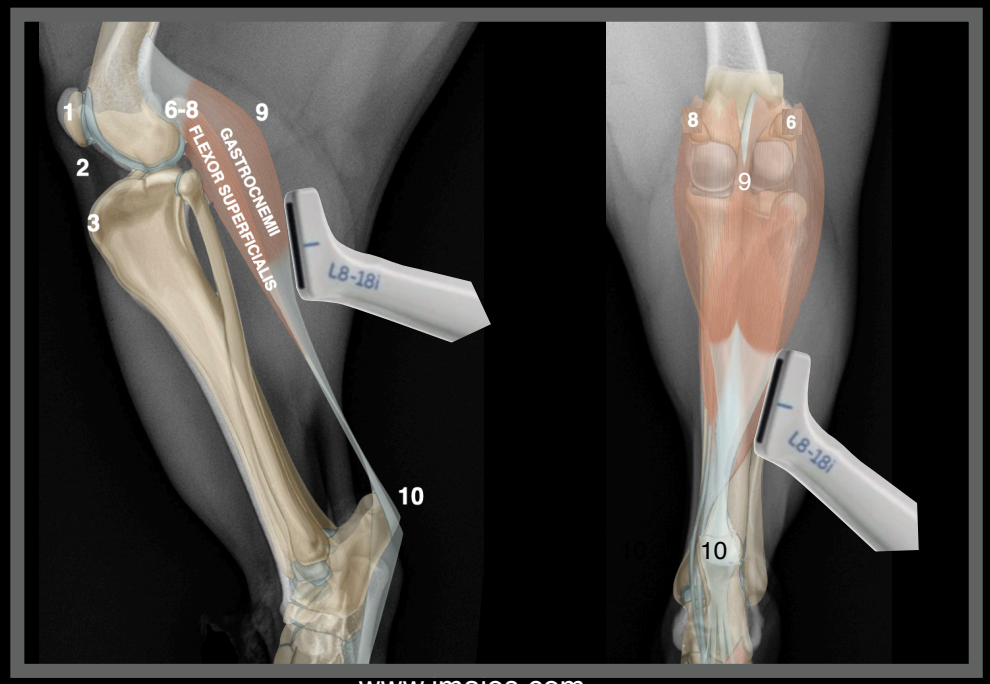

www.imaios.com

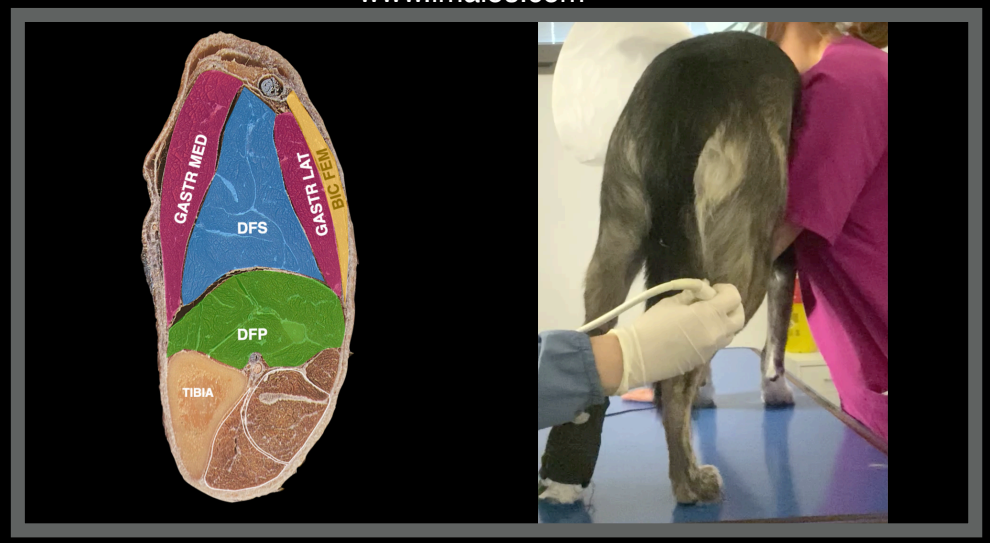

Lola, FI, 4 years

Left leg

Caudal face longitudinal scan 9

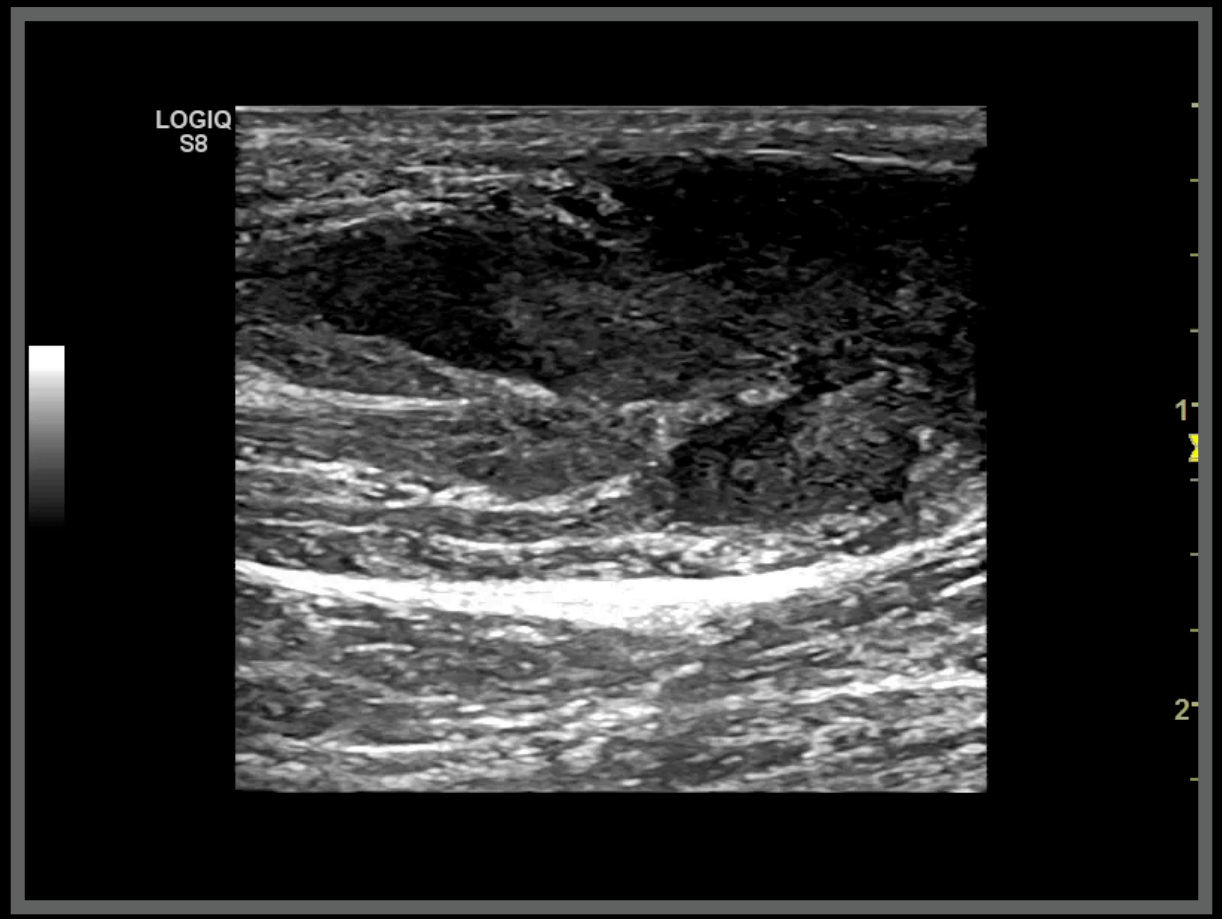

Lola, FI, 4 years

Left hock

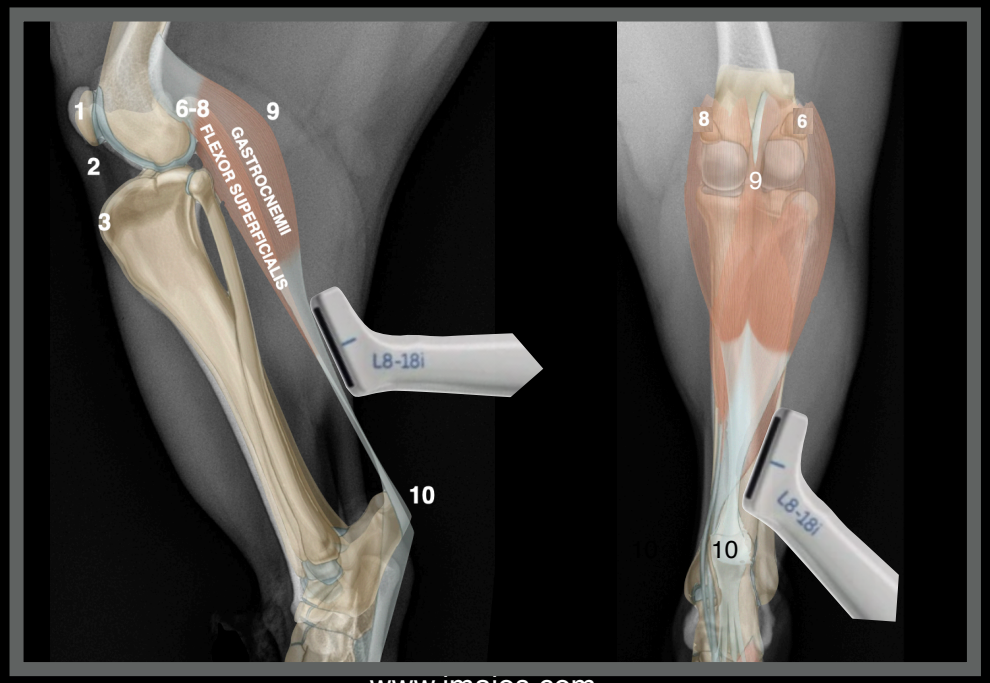

www.imaios.com

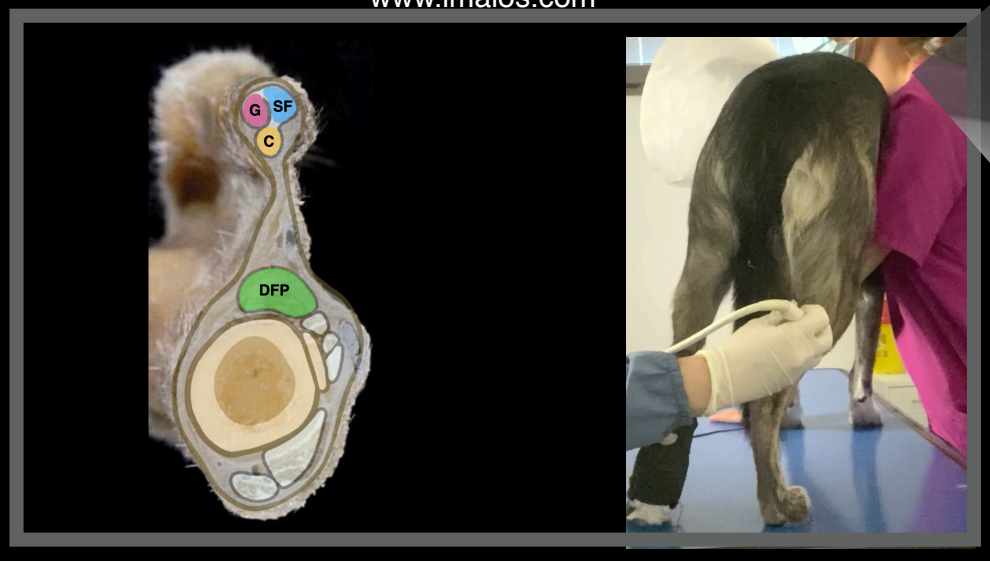

Caudal face longitudinal scan 9-10

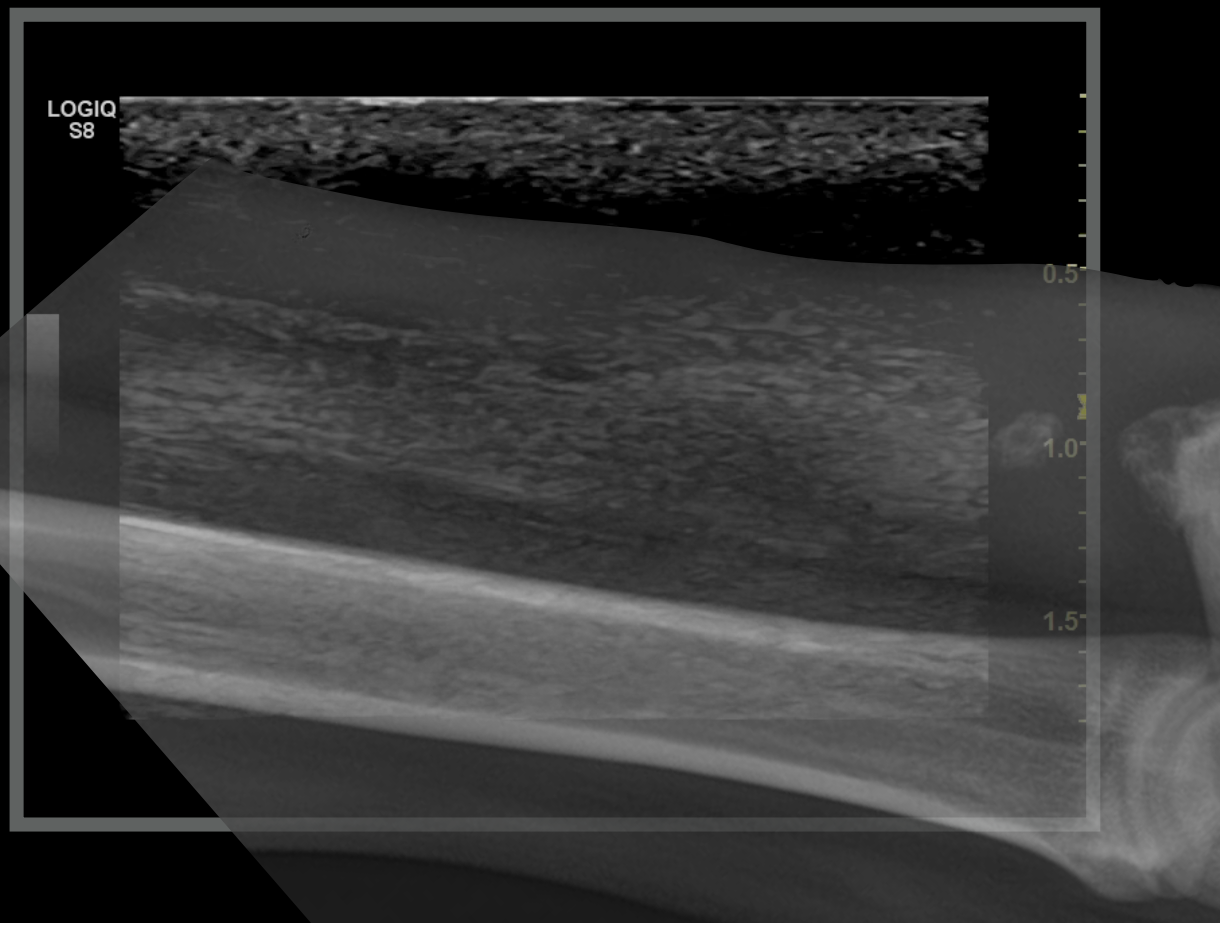

Lola, FI, 4 years

Left hock

Caudal face longitudinal scan 9-10

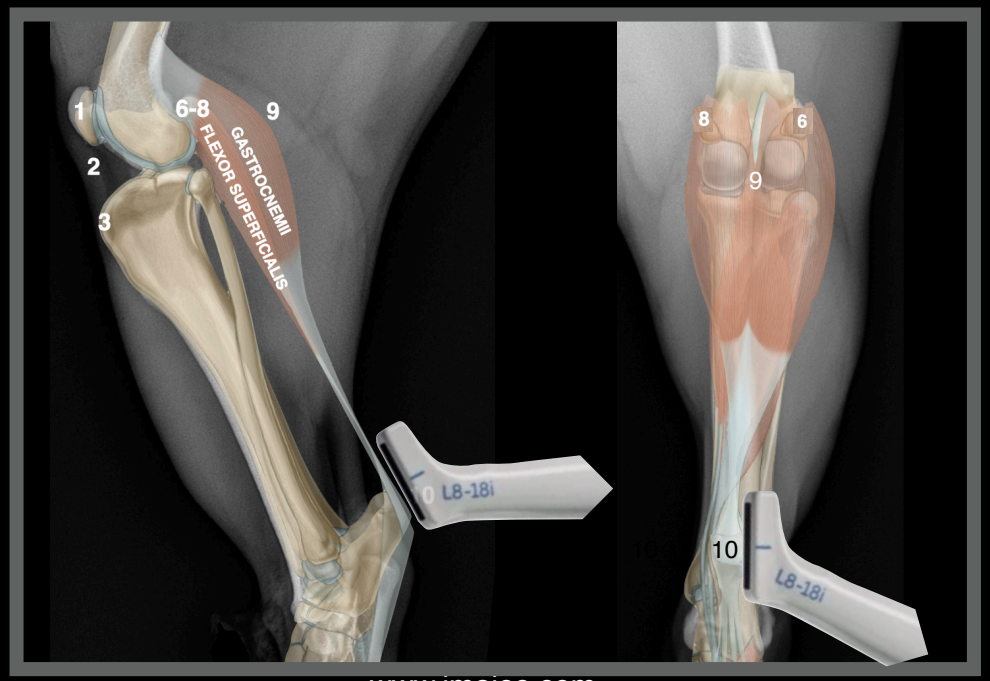

www.imaios.com

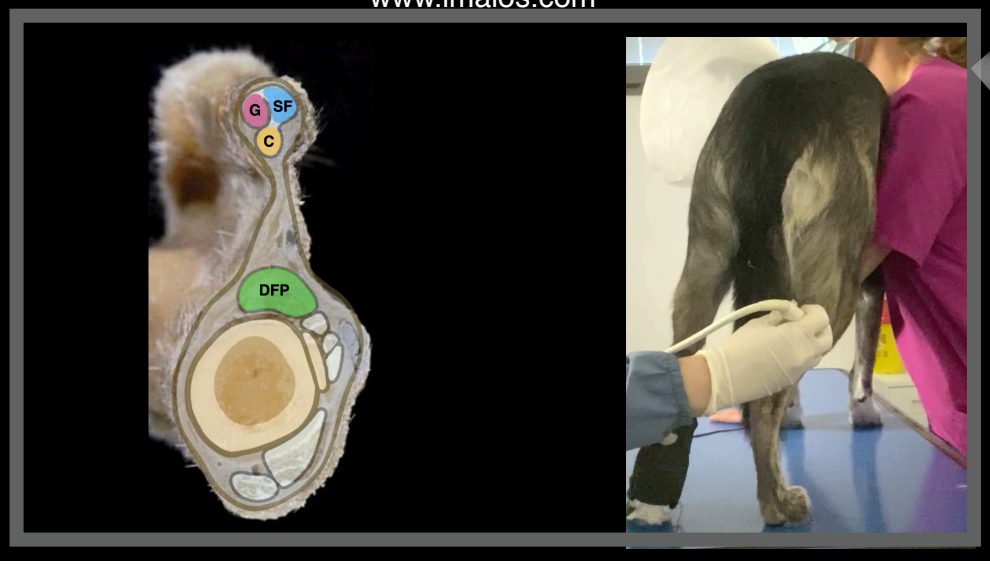

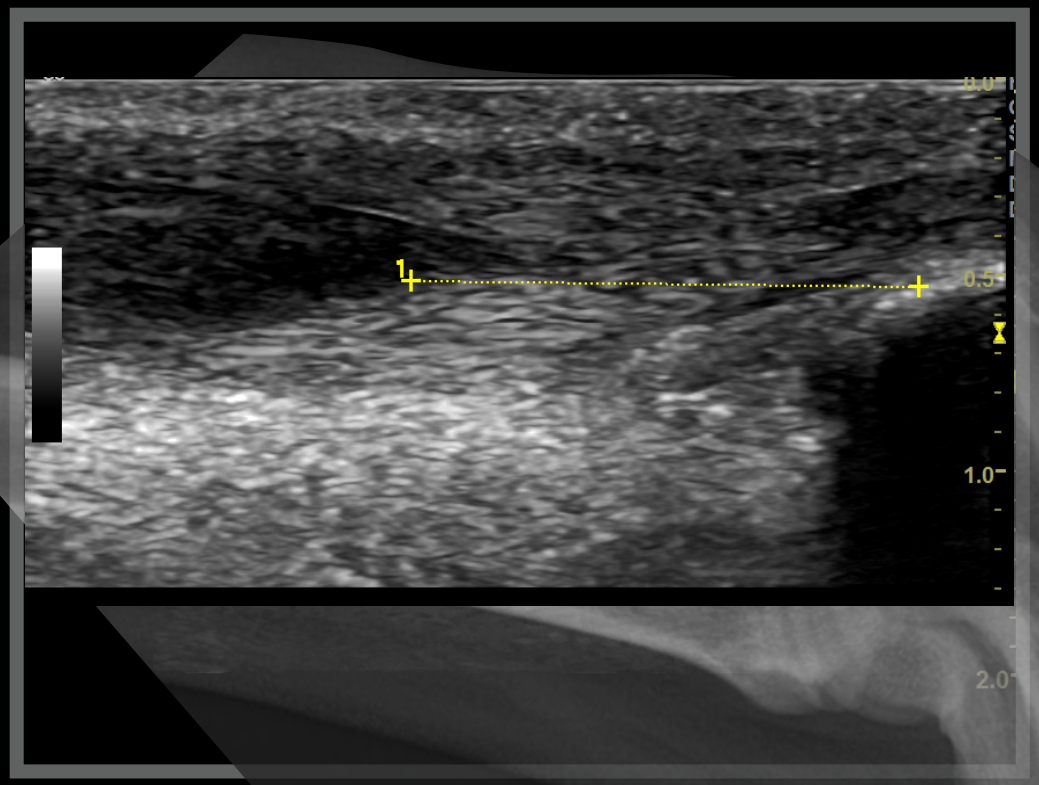

Lola, Fi, 4 years

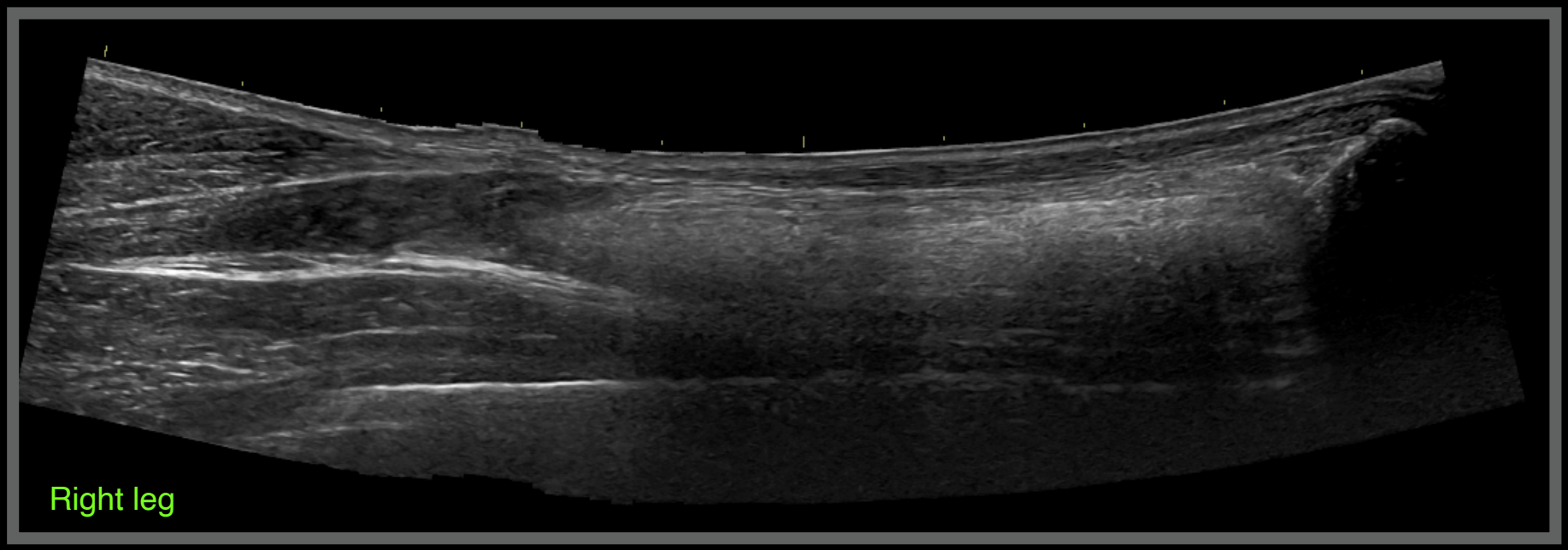

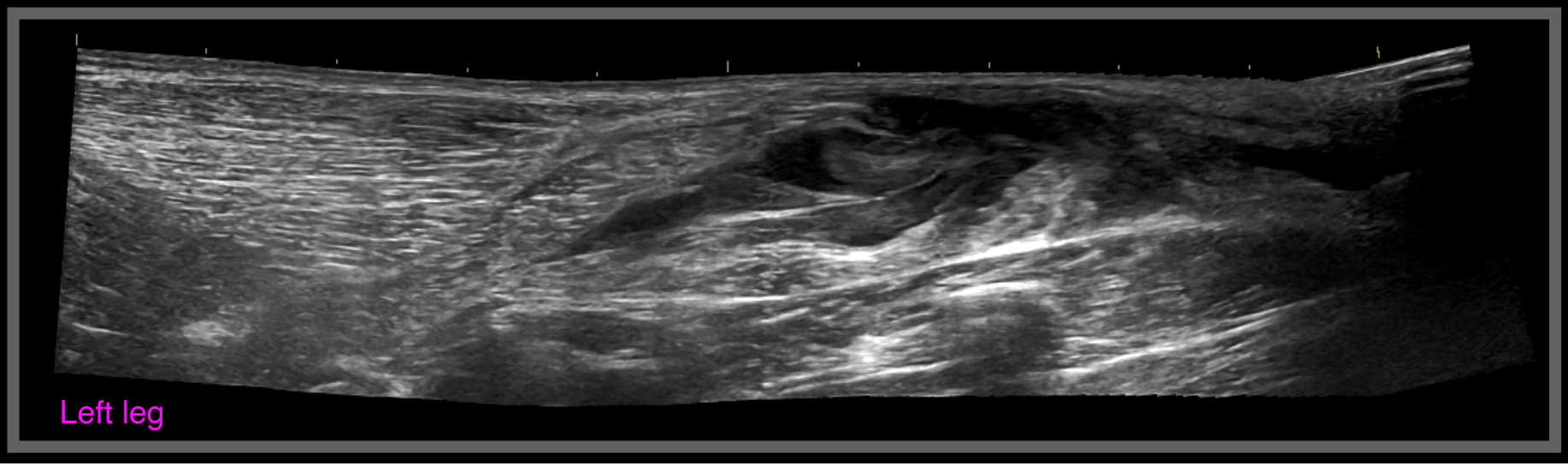

Lola, English Setter, FI, 4 years

Ultrasonographic diagnoses

- Left-sided rupture of the DFS muscle
- Focal rupture of the left Gastrocnemius muscle
- Extensive rupture of the left Gastrocnemius and Communis tendon
- Chronic left-sided Achille's tendonitis

Next steps:

- Removable cast and physiotherapy
- Surgery after three months
- Is back to hunting, light work

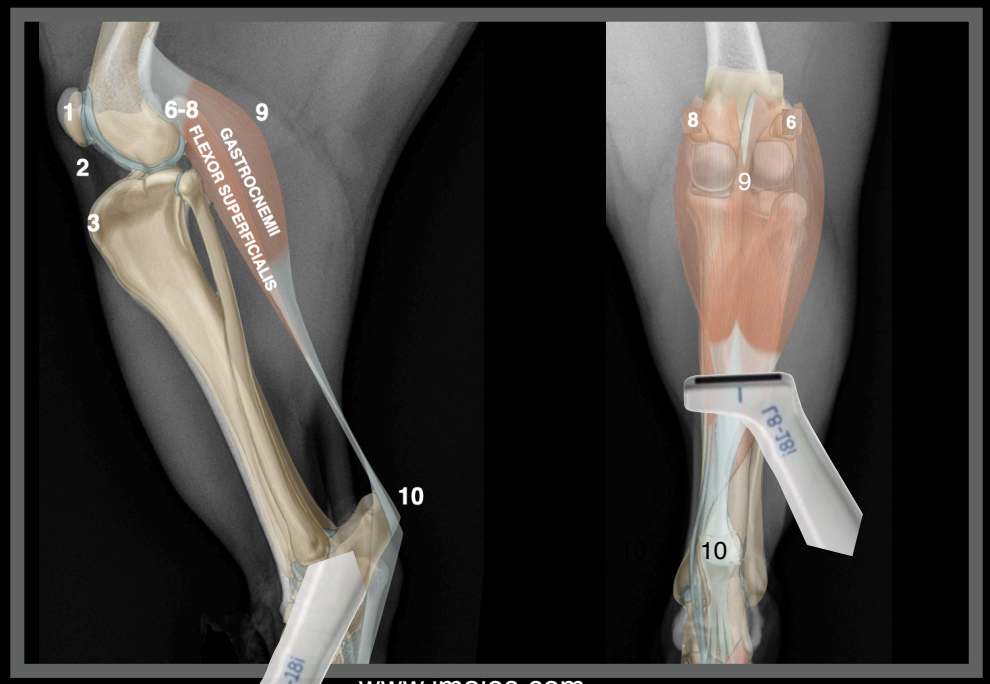

www.imaios.com

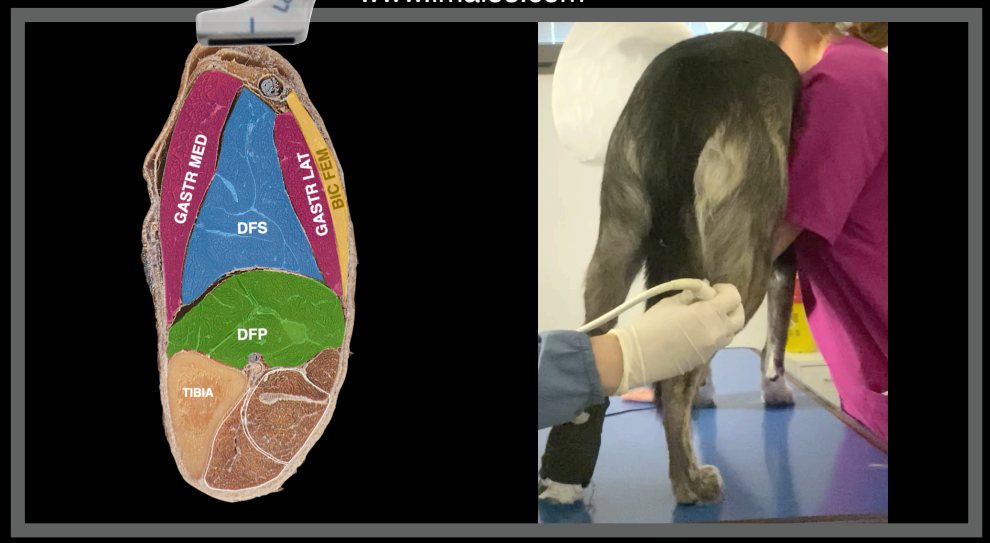

Lola, FI, 4 years

Left leg

Six months later

Caudal face transverse scan 9

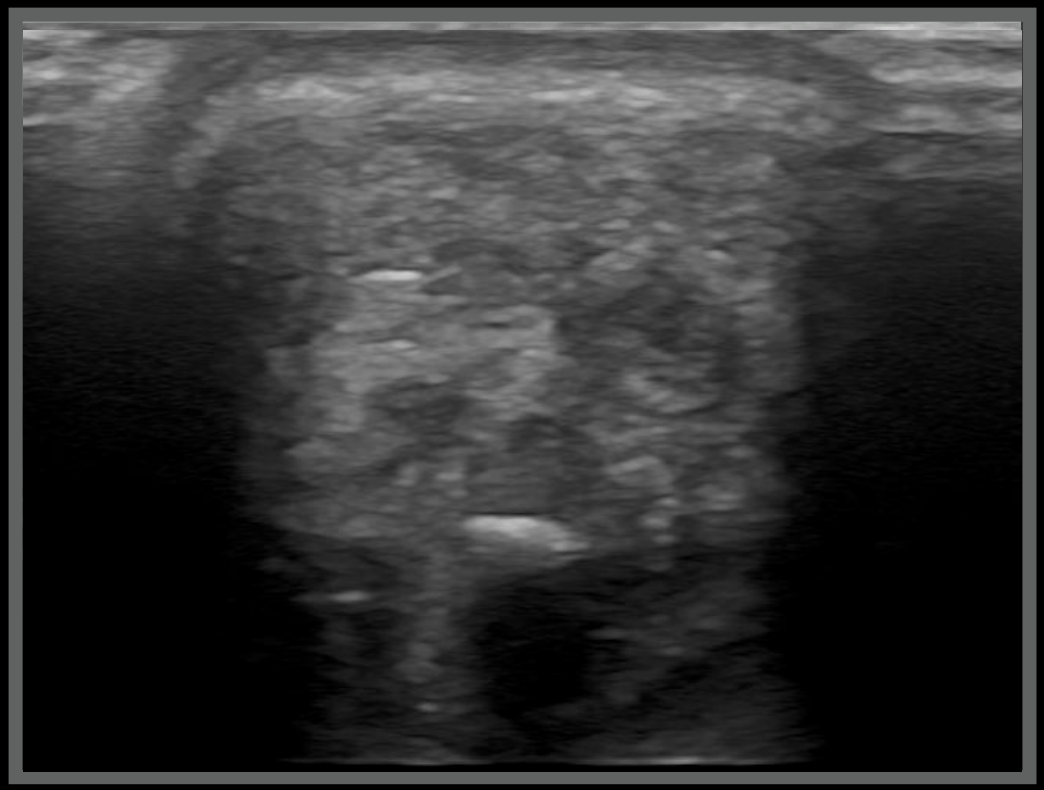

Lola, FI, 4 years

Left hock

Six months later

Caudal face longitudinal scan 10

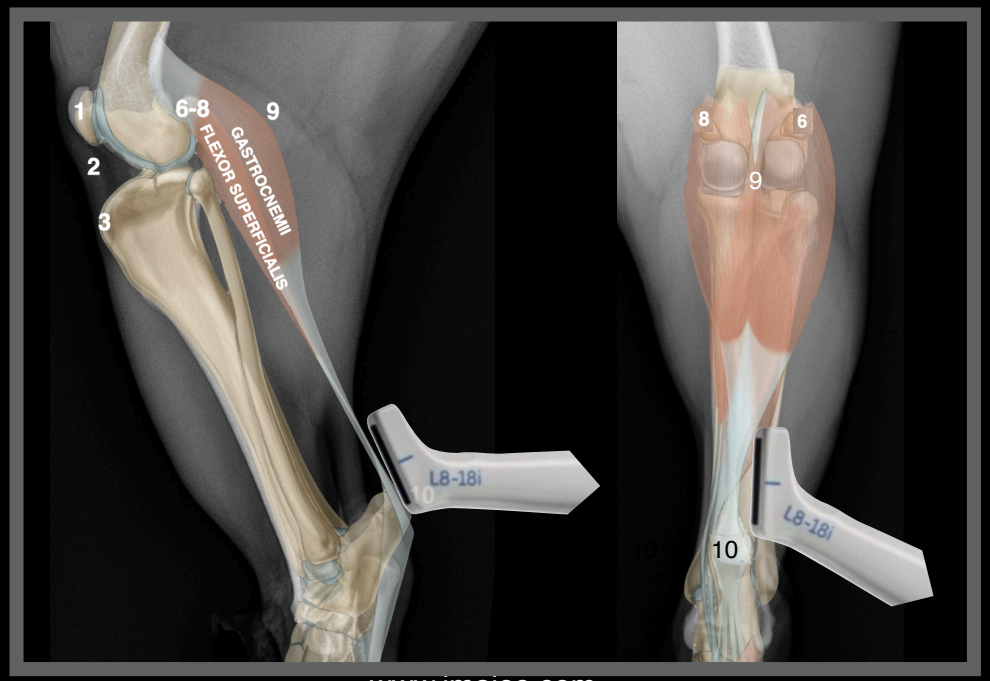

www.imaios.com

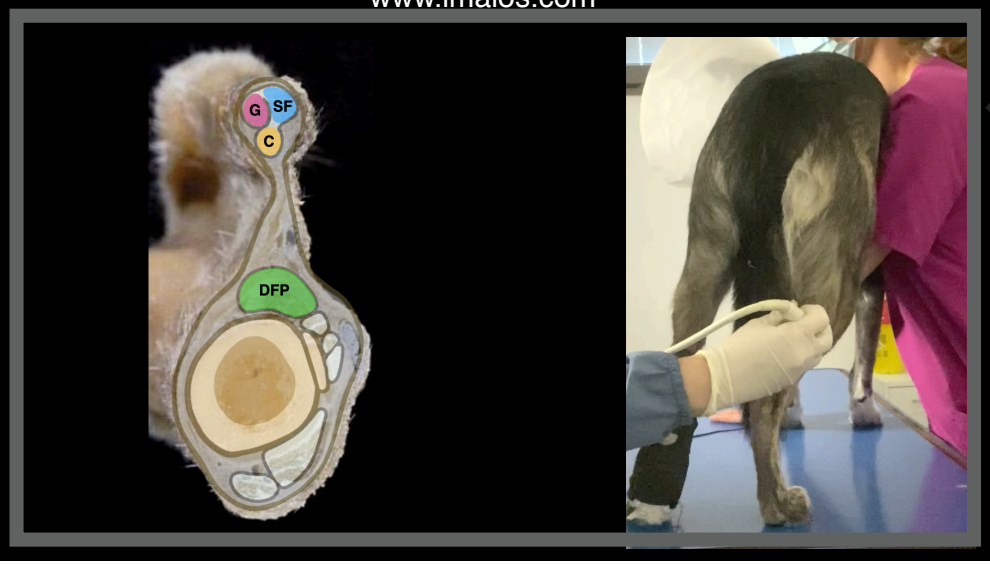

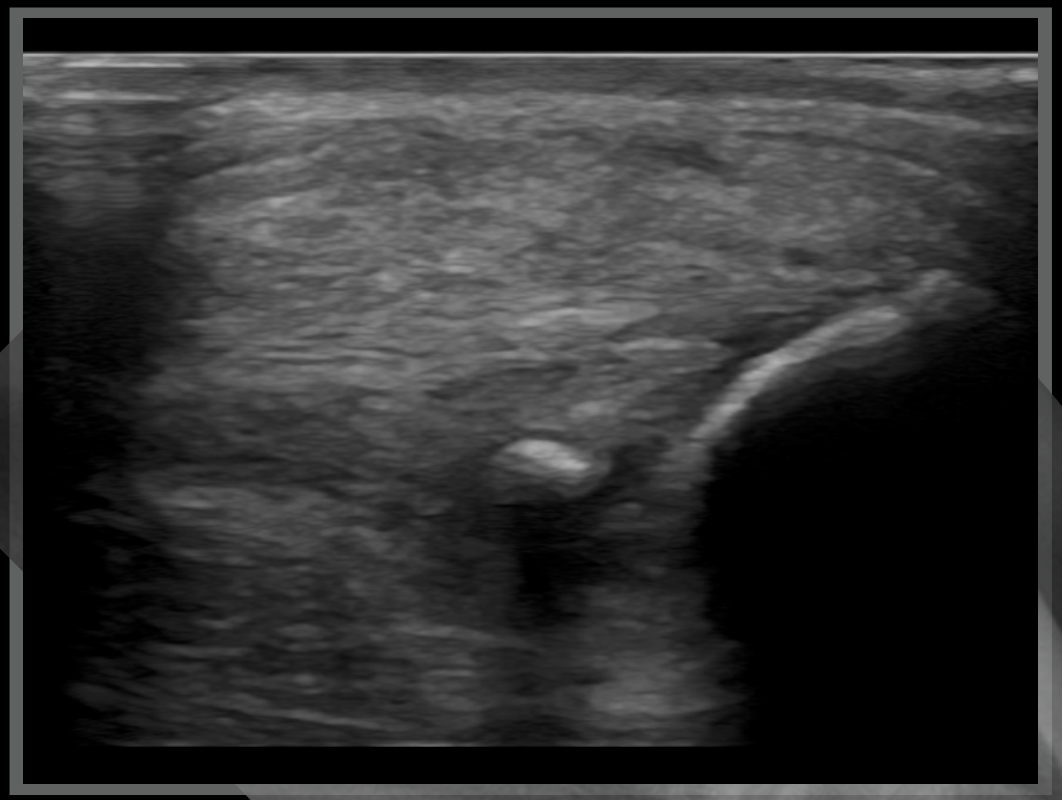

Lola, Fi, 4 years

Six months later

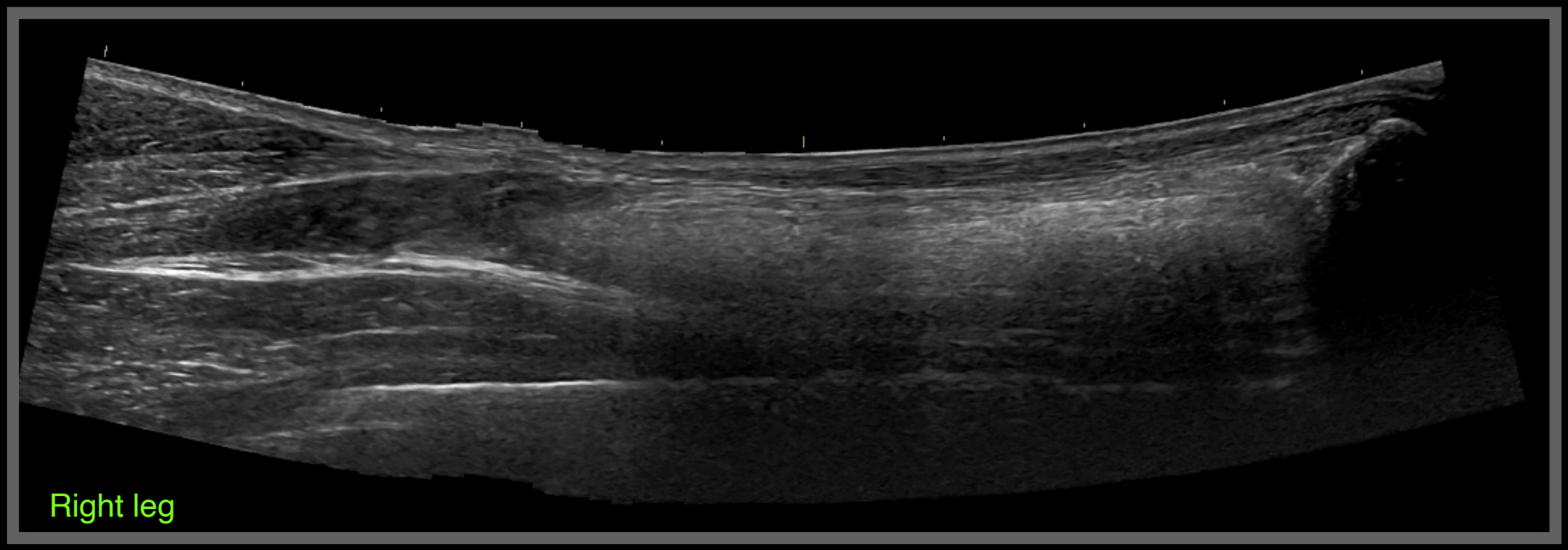

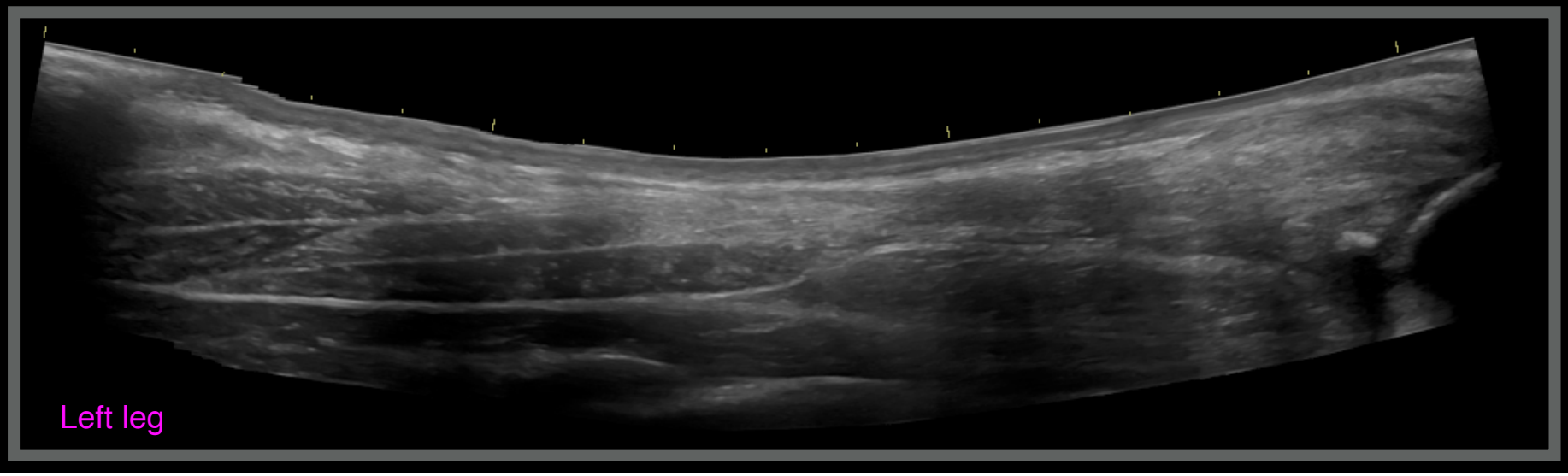

Key point ultrasound of the Achille's tendon

- Often chronic changes
- Healing usually doesn't involve going back to normal
- Underlying chronic predisposition
- Chronic management

Thank you

Diagnostic Mindset

www.diagnosticmindset.com