

Ultrasound of the most common front-digits diseases in sporting dogs

Giliola Spattini
DVM, GP Cardio, CCRT, PhD, DECVDI



Diagnostic Mindset



Thank to www.imaios.com

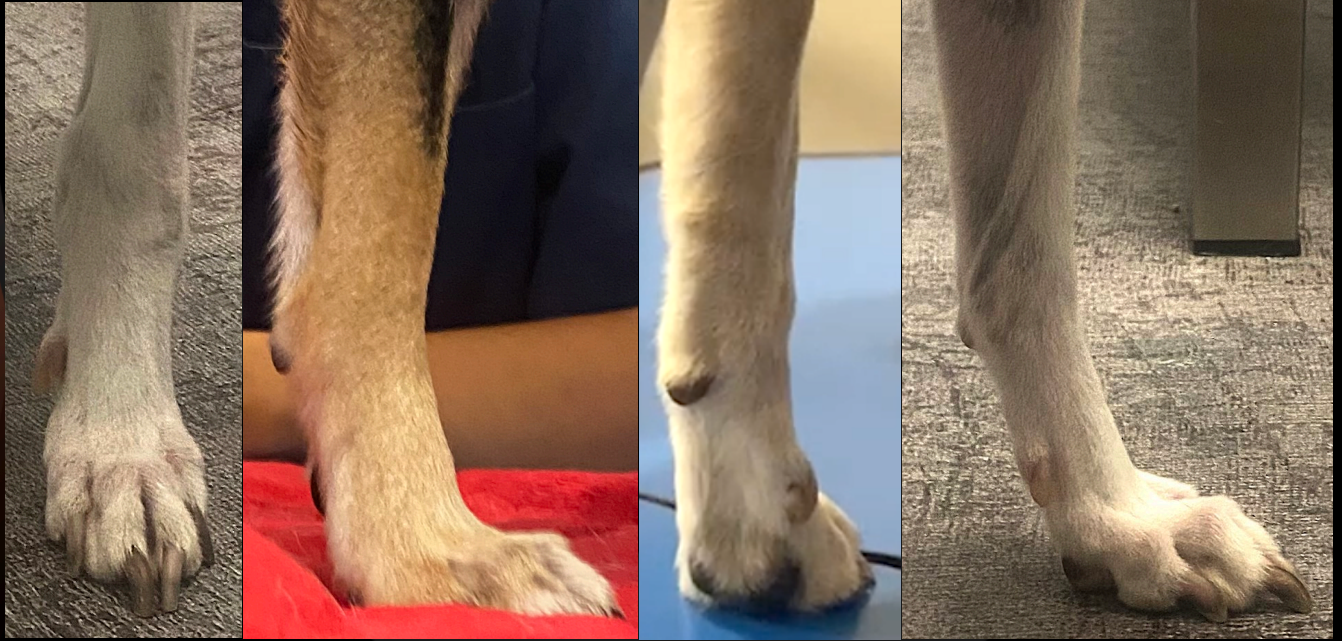Objectives

- High-resolution US improves the visualisation of distal MSK structures
- The information obtained can affect the planning for treatment



Thanks to Rico Vannini

Front limb

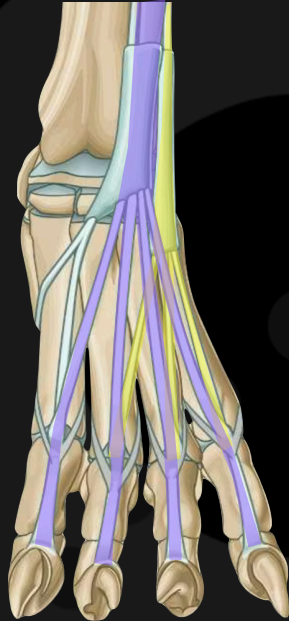


Digital anatomy

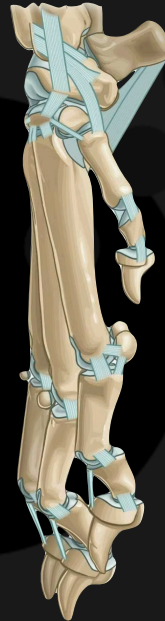D view



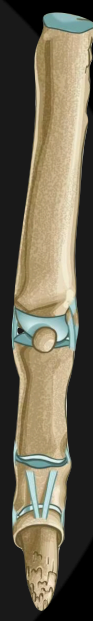Lateral digital extensor



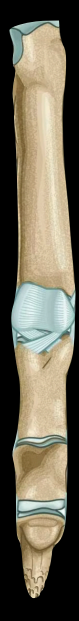ML view



D view



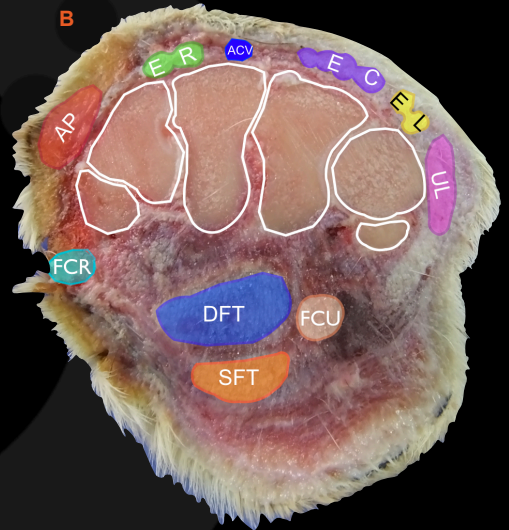
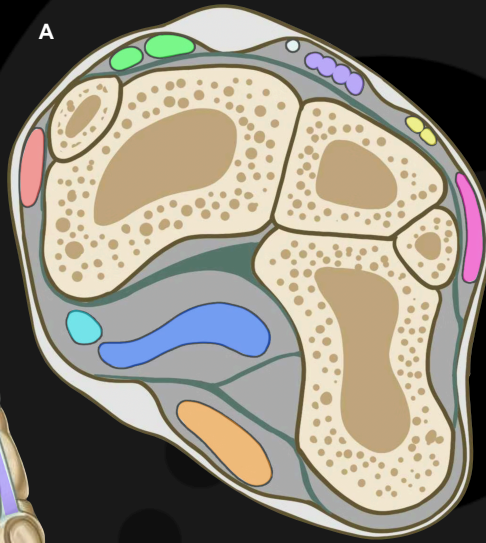
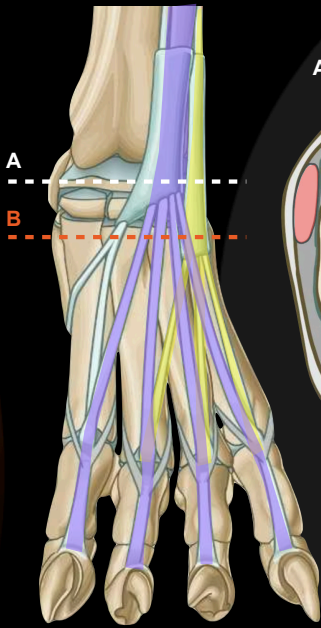
Pa view



Common digital extensor

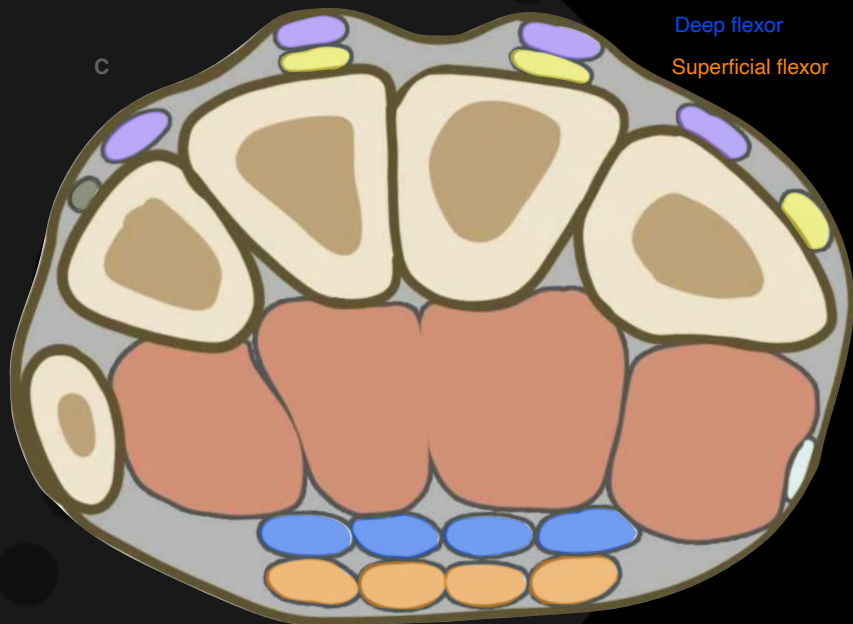
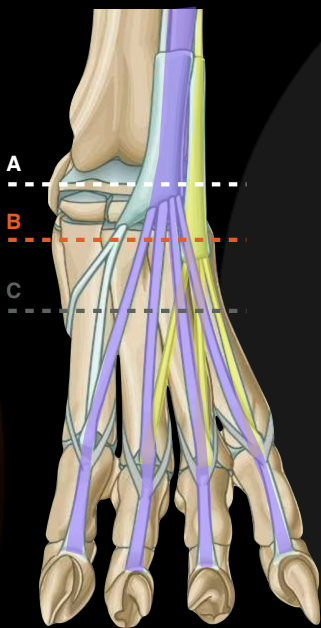
www.imaios.com

Dorsal face



www.imaios.com

Dorsal face



- Common digital extensor
- Lateral digital extensor
- Deep flexor
- Superficial flexor

www.imaios.com

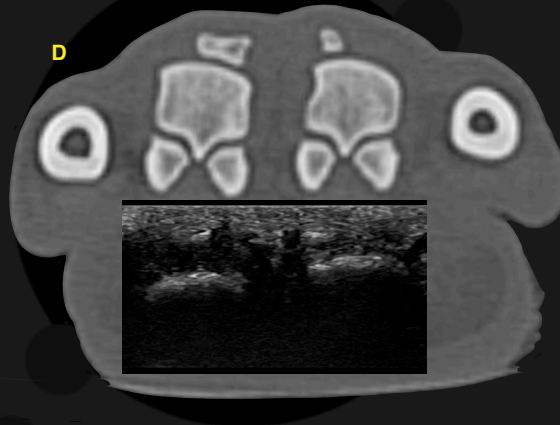
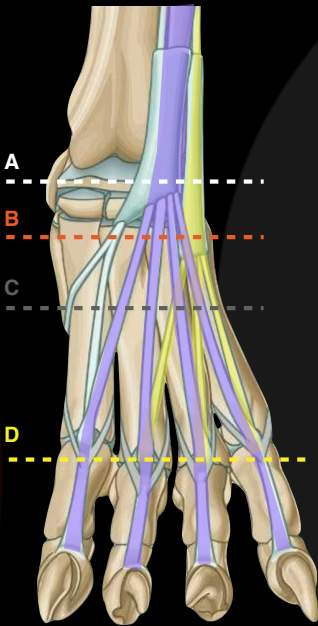
Dorsal face

Common digital extensor

Lateral digital extensor

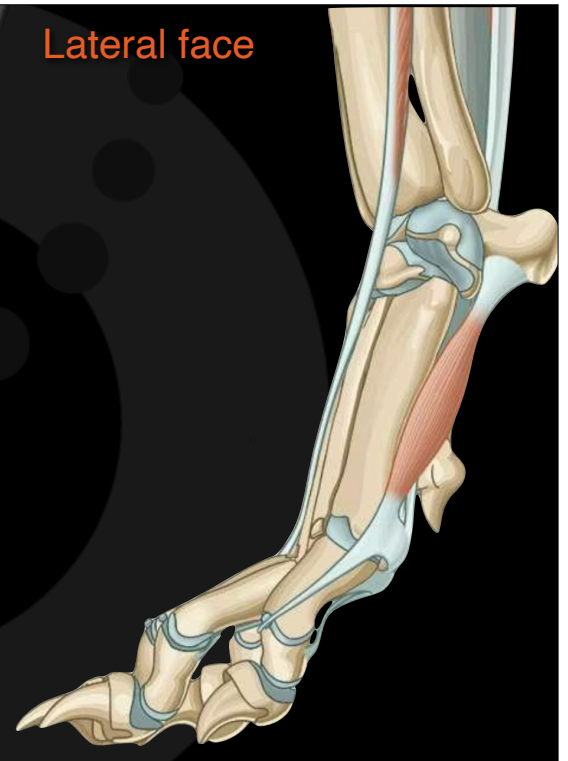
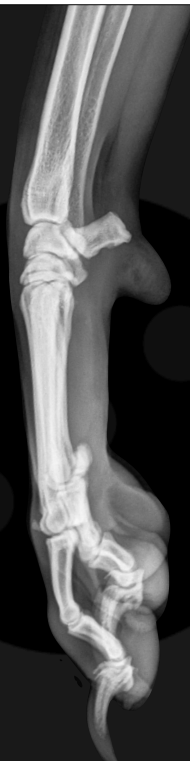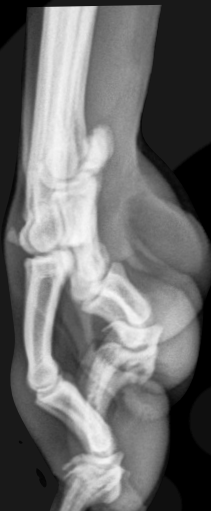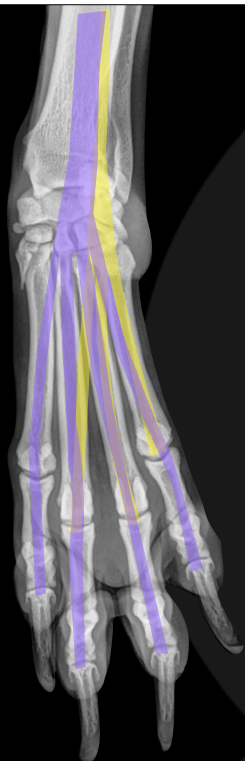Deep flexor

Superficial flexor



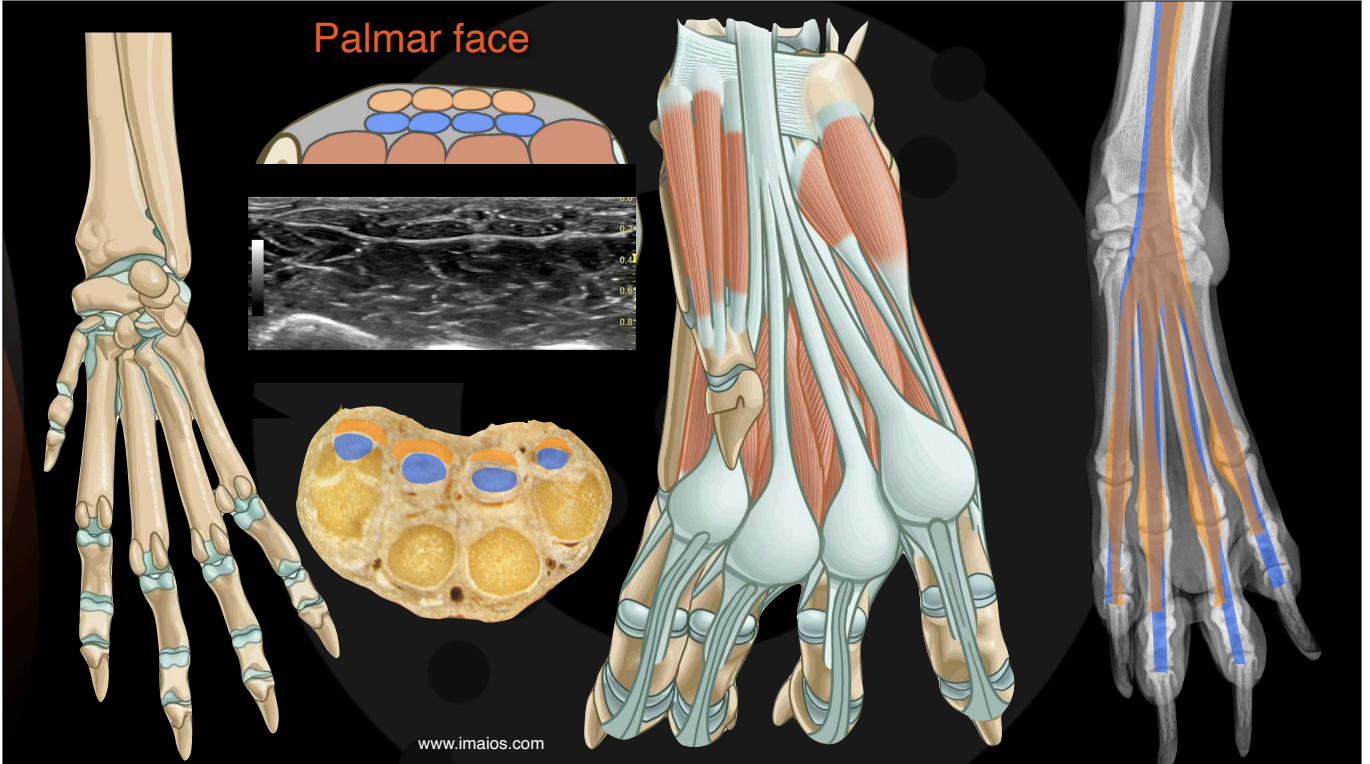
www.imaios.com

Lateral face

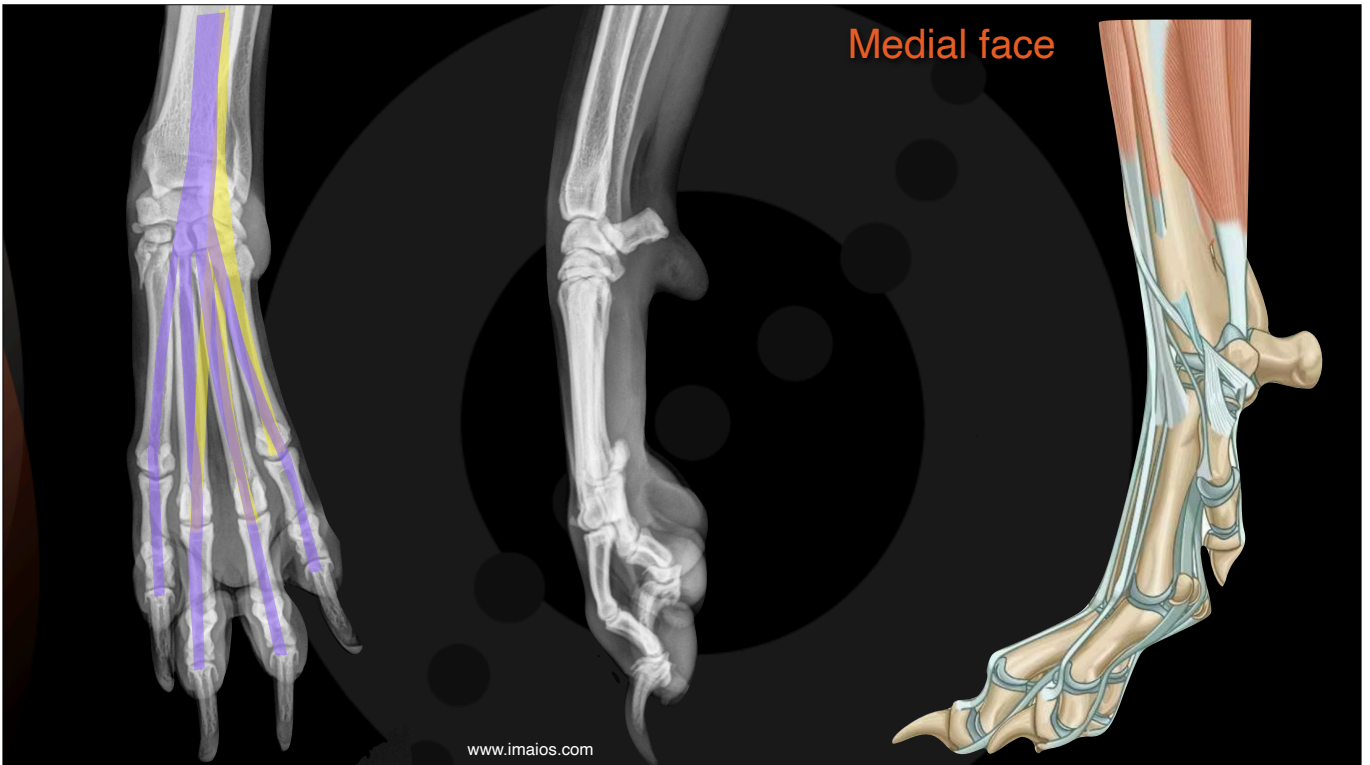


www.imaios.com

Palmar face



Medial face



What are you looking for with an ultrasound?

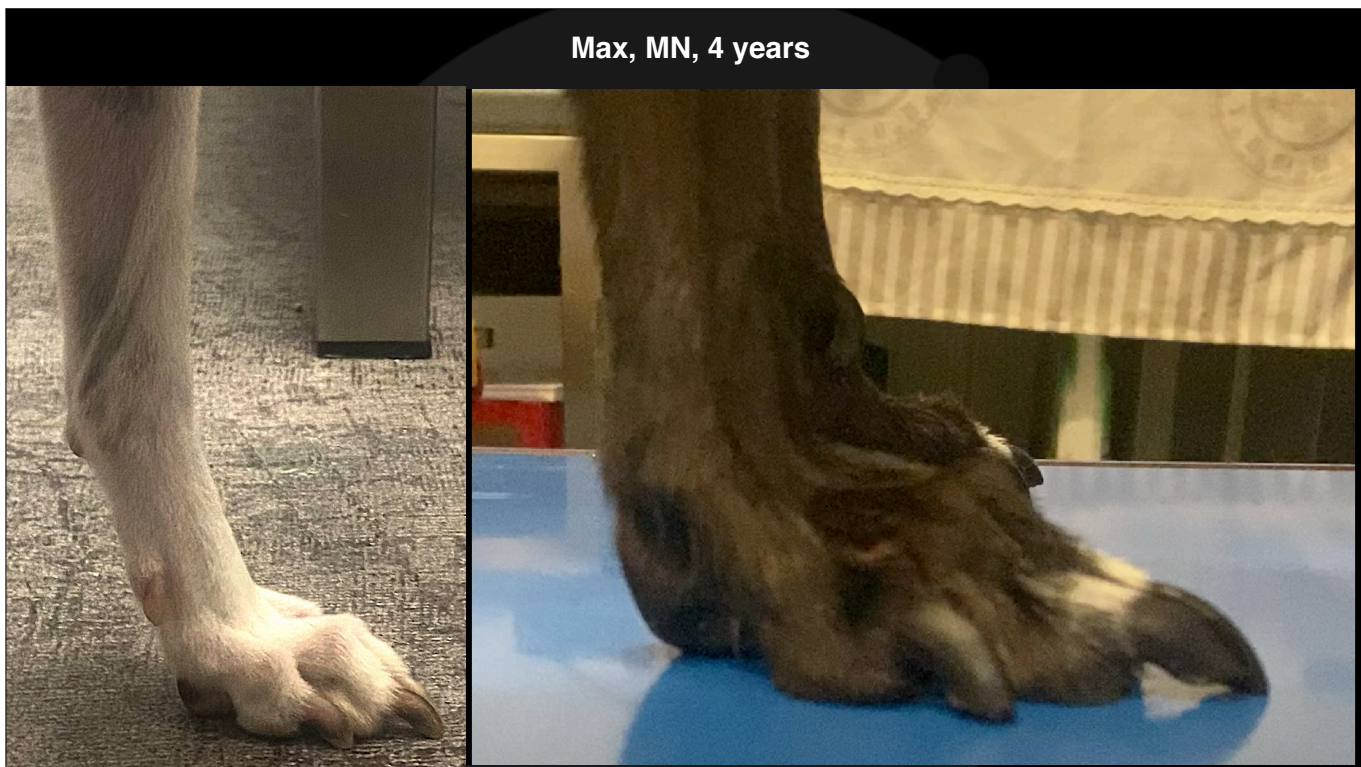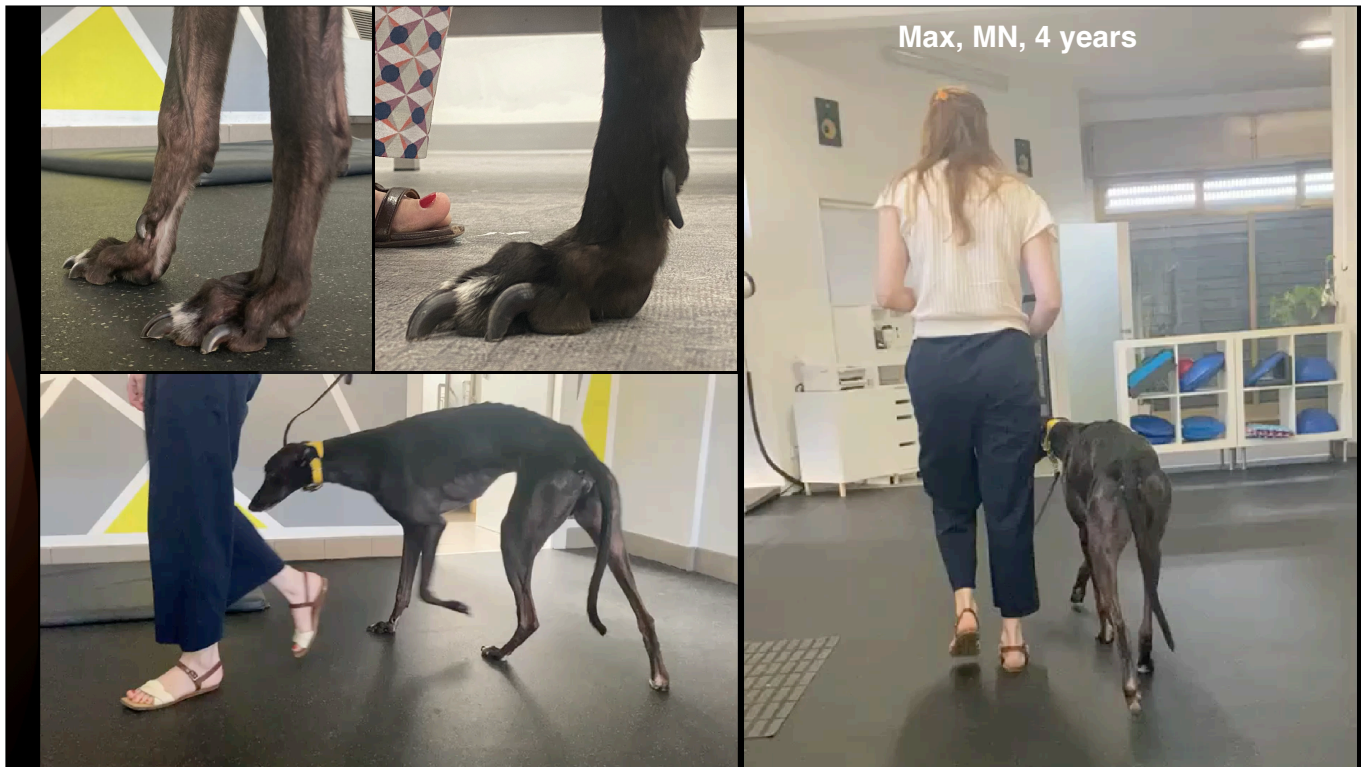- Start with a transverse scan at the dorsal sesamoid bones
- Extensors tendons
- Joint stability-DJD-inflammatory changes
- Distal phalangeal displacement
- Are the flexor tendons competent?

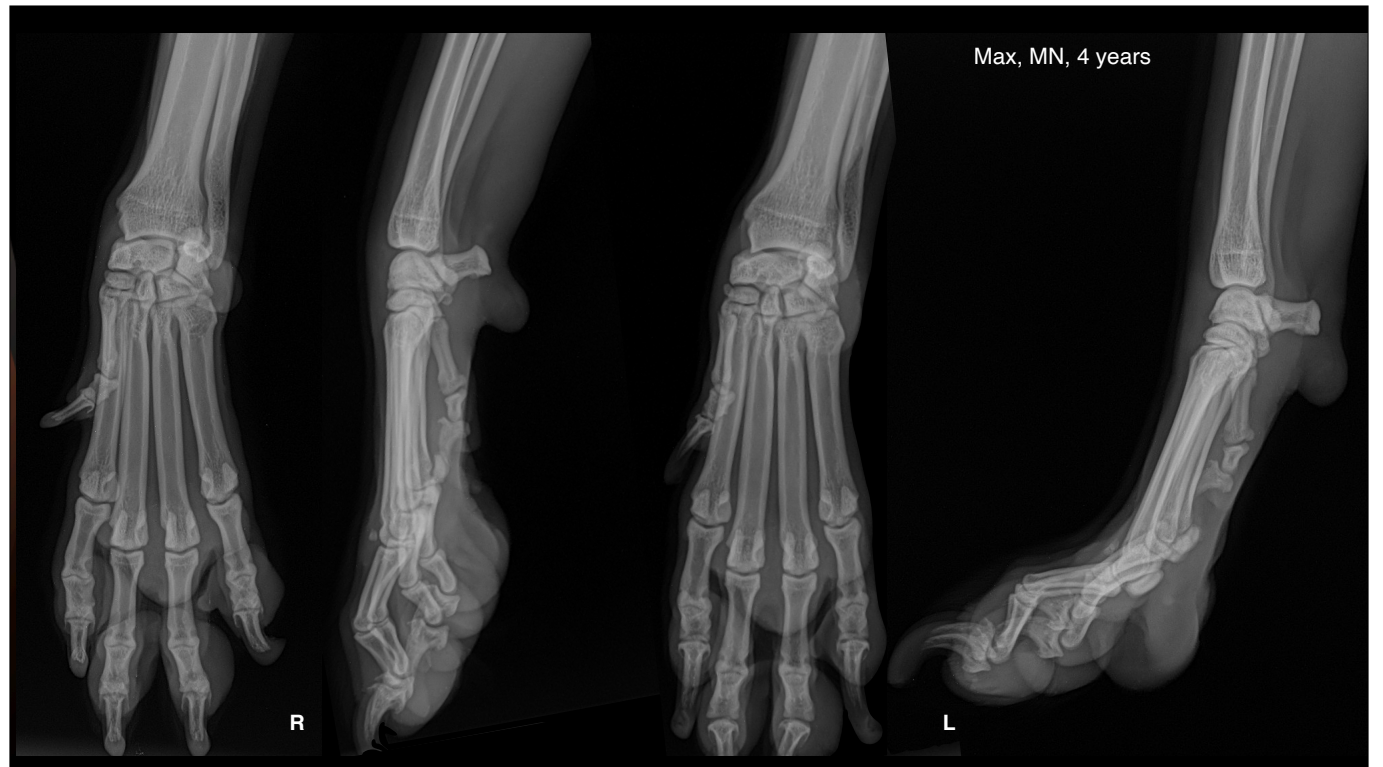

Max, Greyhound, MN, 4 years

- Ex racing
- Arrived at the new home three months ago
- After two months of lameness every time He runs
- He has recurrent digital dermatitis - inflamed digits







Ultrasonographic technique for the extremities

Prism ALCOOL

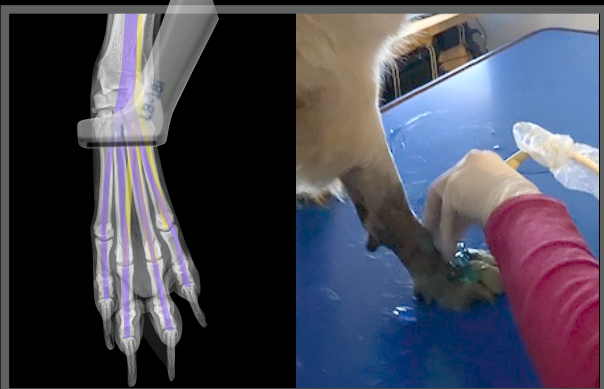
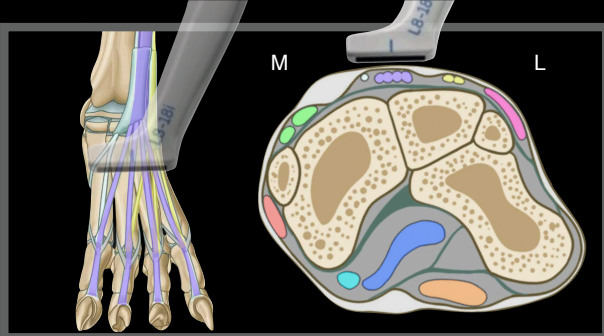
Prism ALCOOL

Prism ALCOOL

Prism ALCOOL

Max, Greyhound, MN, 4 years

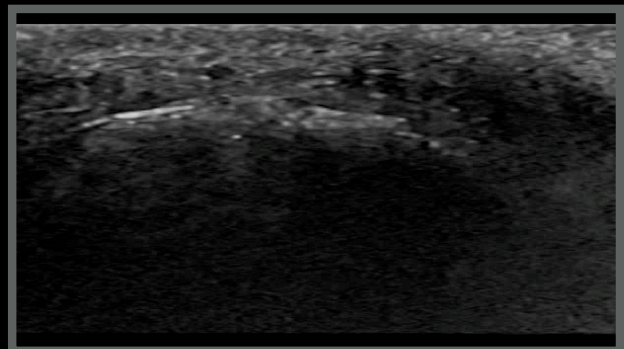
- Ex racing
- Arrived at the new home three months ago
- After two months of lameness every time He runs
- He has recurrent digital dermatitis - inflamed digits



Max, MN, 4 years

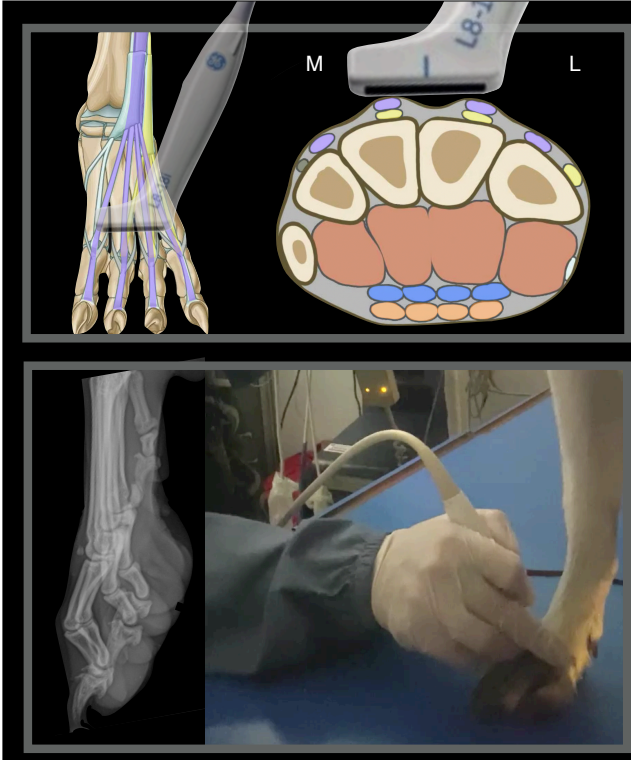
Right metacarpus

Transverse scan plan



www.imaios.com

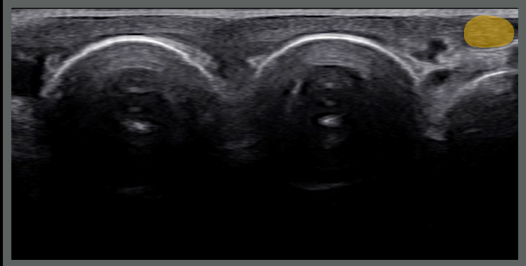




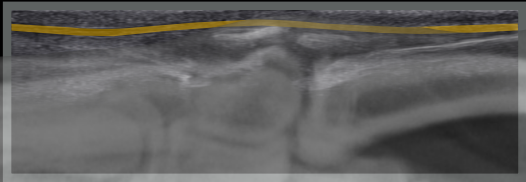
Normal anatomy of the metacarpal region

Left metacarpus

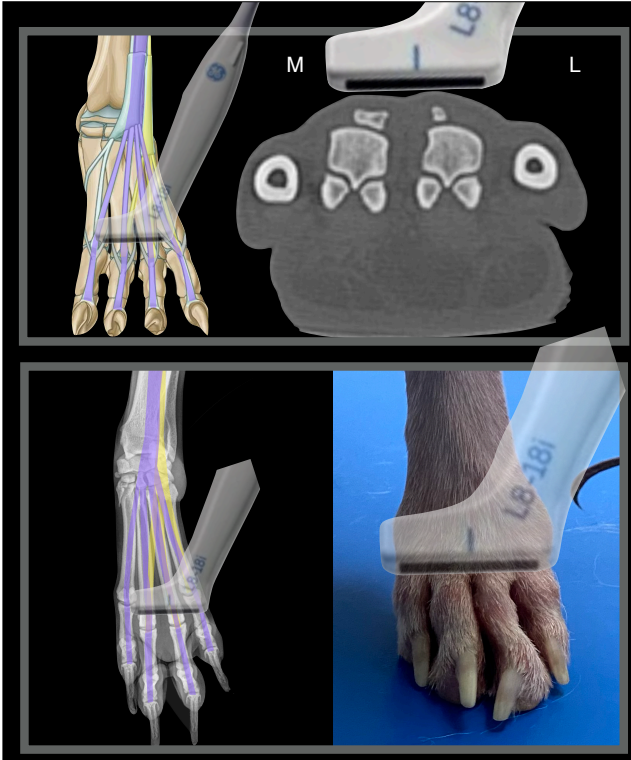
Transverse scan plan



Longitudinal scan plan



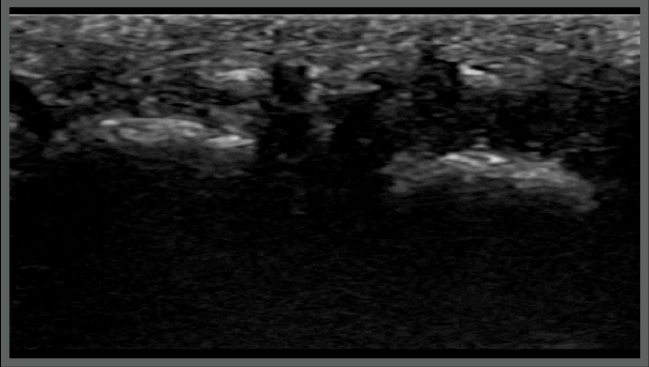
www.imaios.com



Normal anatomy of the MC-P1 third and fourth digits

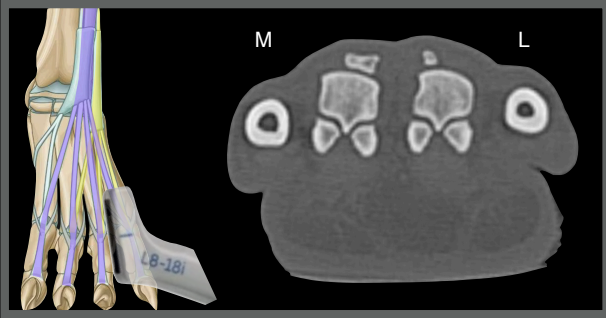
Left metacarpus

Transverse scan plan, dorsal face



www.imaios.com

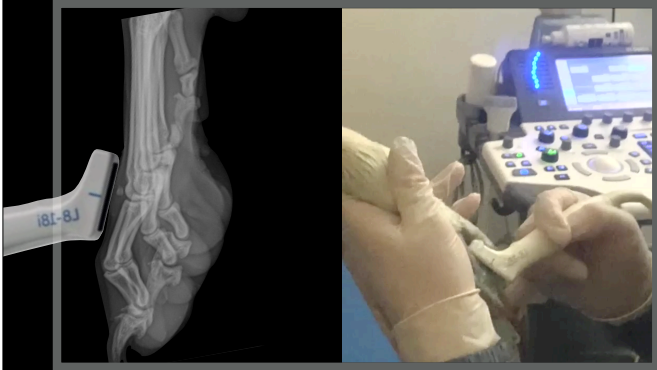
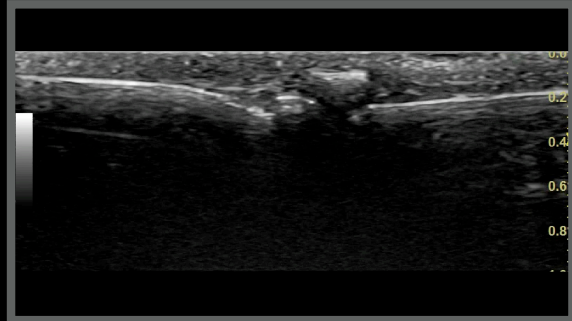




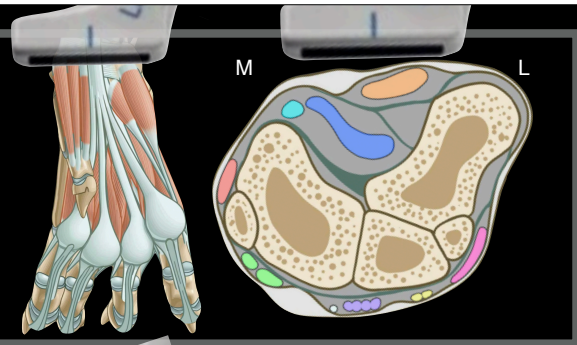
Normal anatomy of the MC-P1 third digit

Left metacarpus

Longitudinal scan plan



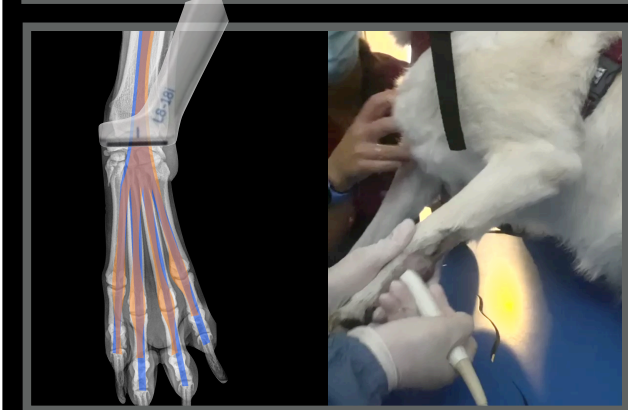
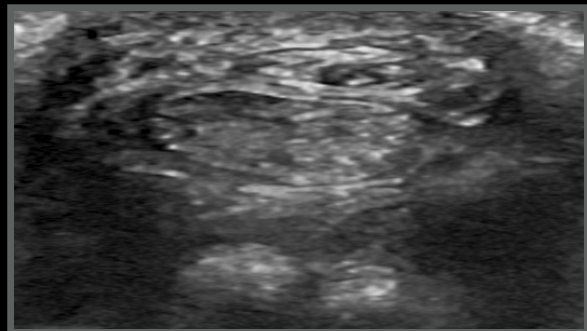
www.imaios.com



Normal anatomy metacarpal palmar face

Left metacarpus

Transverse scan plan

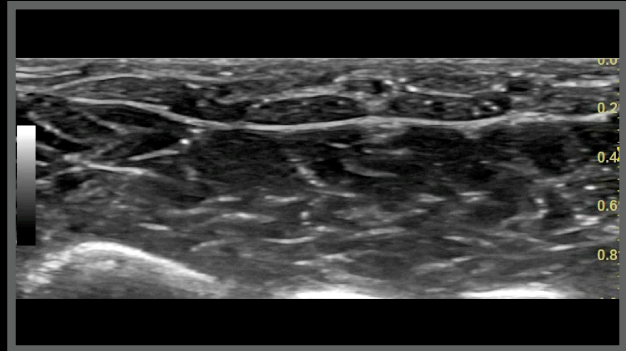


www.imaios.com

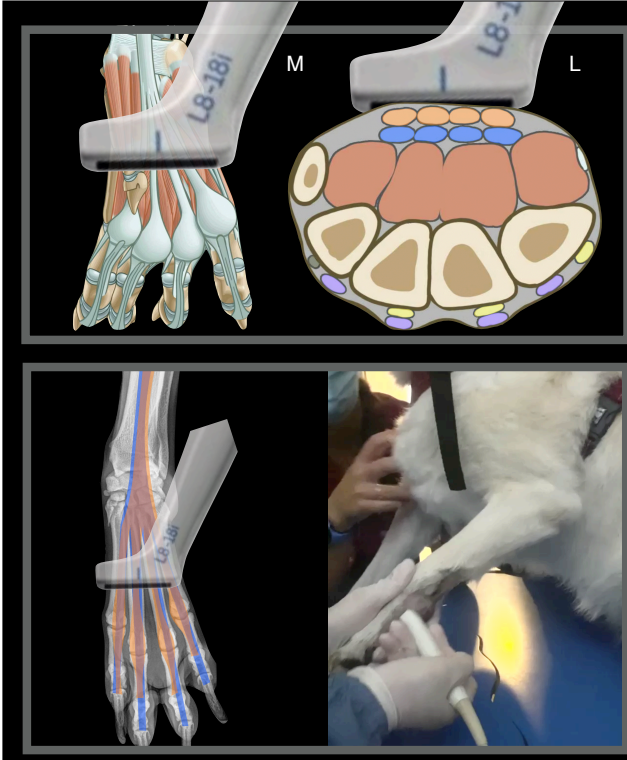
Normal anatomy metacarpal palmar face

Left metacarpus

Transverse scan plan



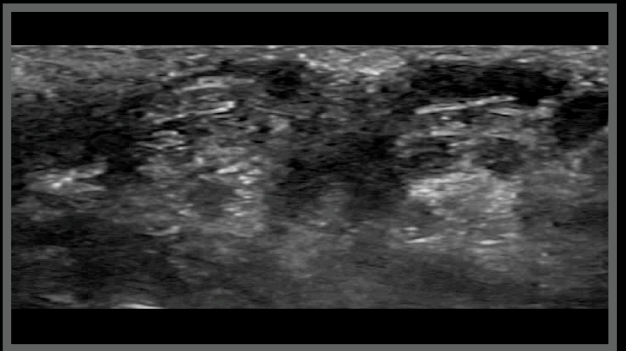
www.imaios.com



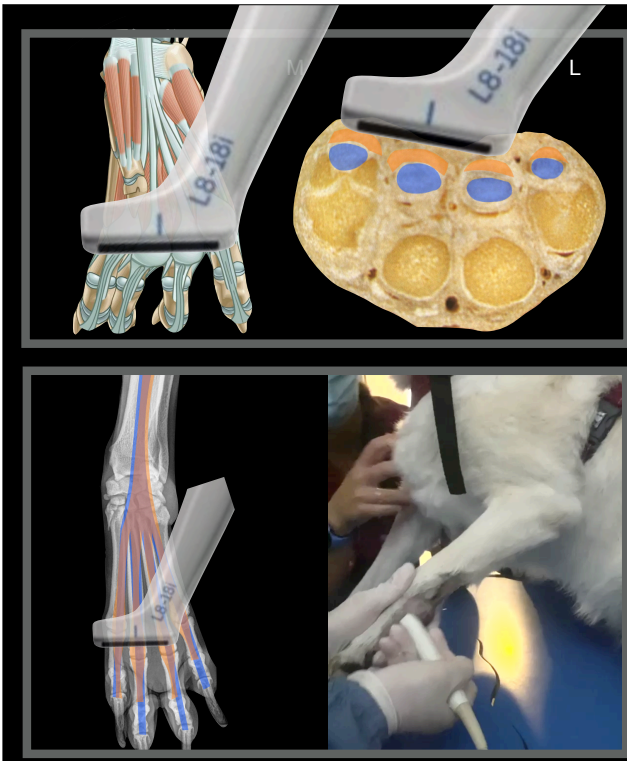
Normal anatomy metacarpal palmar face

Left metacarpus

Transverse scan plan



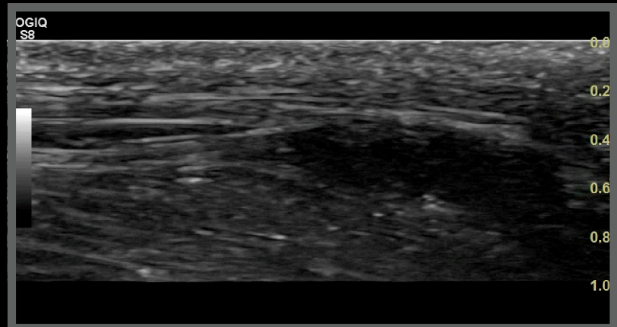
www.imaios.com



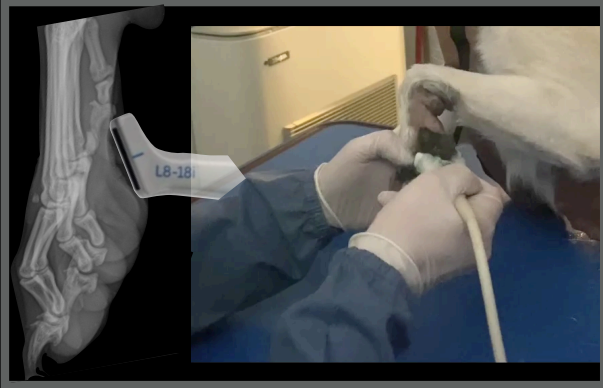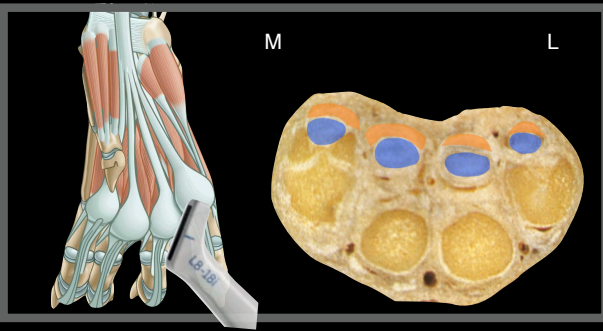
Normal anatomy metacarpal palmar face

Left metacarpus

Transverse scan plan



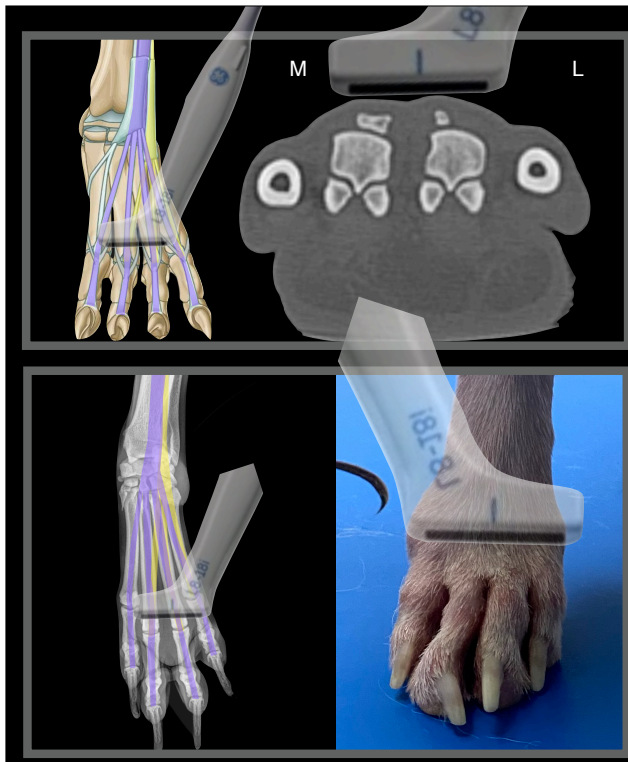
www.imaios.com



Max, Greyhound, MN, 4 years

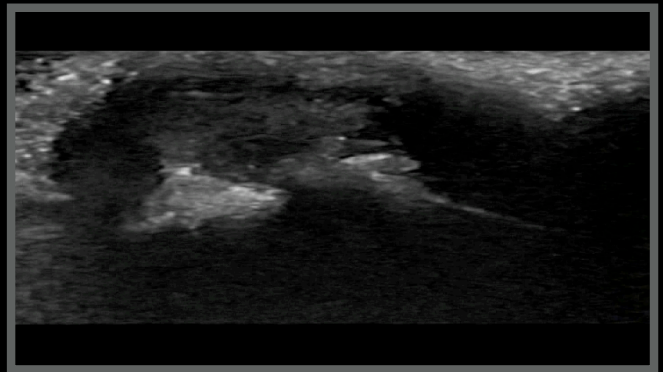
- Ex racing
- Arrived at the new home three months ago
- After two months of lameness every time He runs
- He has recurrent digital dermatitis - inflamed digits





Max, Mn, 4 years

Right metacarpus
Transverse scan plan, dorsal face



www.imaios.com

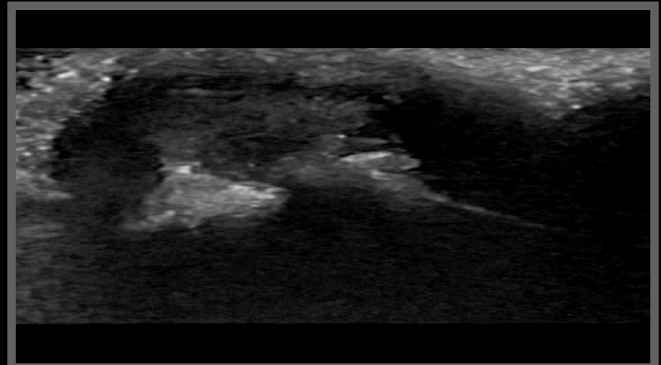
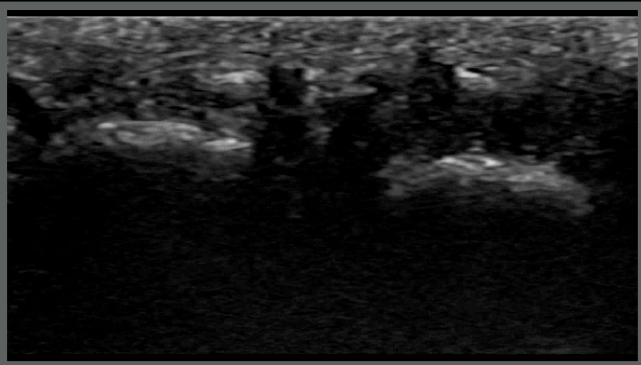


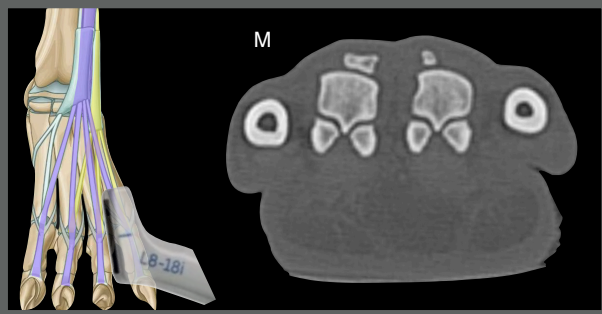
Max, Greyhound, MN, 4 years



Normal anatomy

Right MC-P1 third digit

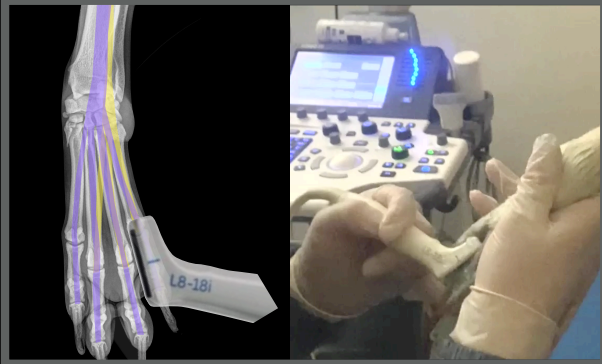
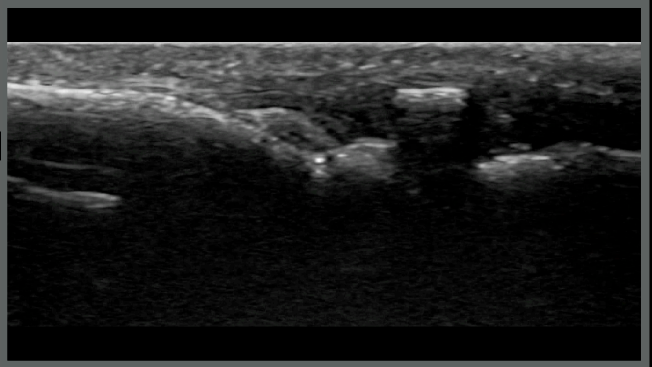




Max, Mn, 4 years

Right MC-P1 fourth digit

Longitudinal scan plan, dorsal face



www.imaios.com

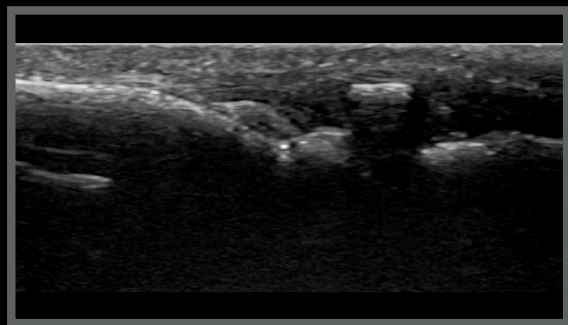
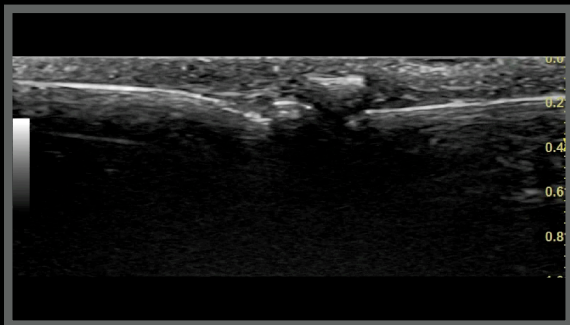


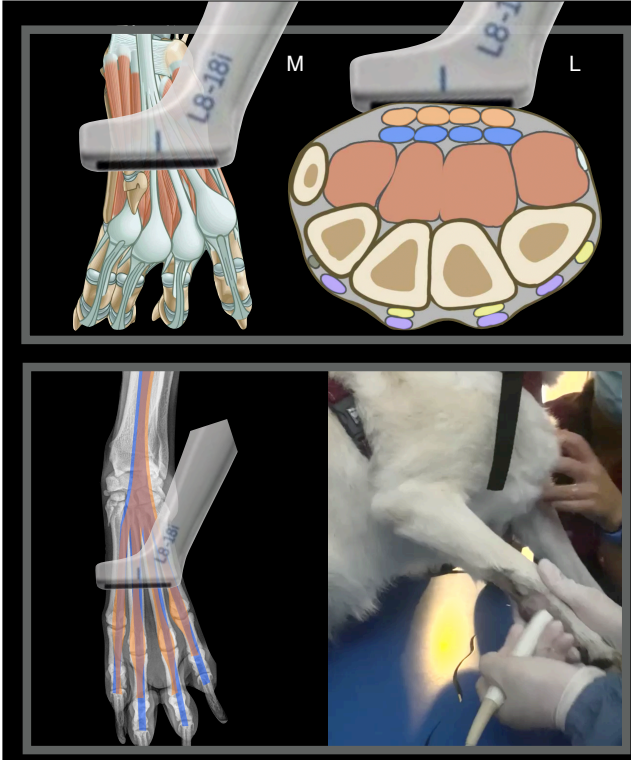
Max, Greyhound, MN, 4 years



Normal anatomy

Right metacarpus

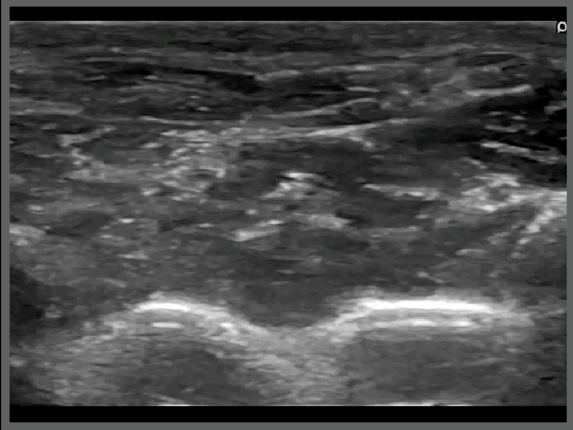




Max, Mn, 4 years

Right metacarpus

Transverse scan plan metacarpal bone plantar face



www.imaios.com



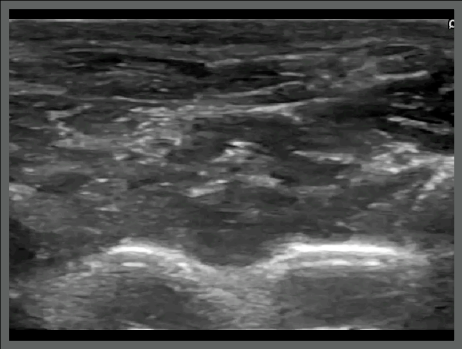
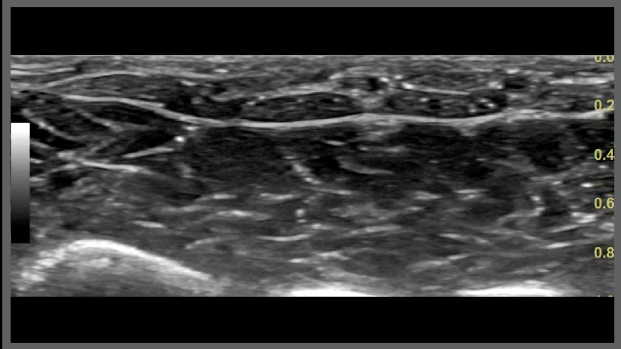
Max, Greyhound, MN, 4 years

MC-P1 third digit



Normal anatomy

Right metacarpus



Max, Greyhound, MN, 4 years

Ultrasonographic diagnoses (right third front digit):

- Severe effusion MC-P1 joint
- Severe tendon sheath effusion of the deep flexor tendon
- Core lesion of the distal portion of the deep flexor tendon



What next?

Max, Greyhound, MN, 4 years

- Custom made shoes
- Proprioceptive exercises to increase the flexor's tone
- Different activities to increase the general muscle tones



Thank you



Diagnostic Mindset

www.diagnosticmindset.com