Low performance after pregnancy

Can musculoskeletal ultrasound detect the cause of low performance after rest and pregnancy in this agility dog?

Diagnostic Mindset

Thanks to www.imaios.com

Giliola Spattini
DVM, PhD, DECVDI

Azulha, Shetland, FI, 4 years

- After pregnancy and rest, reluctant to jump
- Low sportive performance
- She escapes jumping
- Not interested in training

Azulha, Shetland, FI, 4 years

- Pain on right shoulder extension
- Unremarkable radiographs
- Unsuccessful physiotherapy (suspected supraspinatus and biceps tendinopathy)

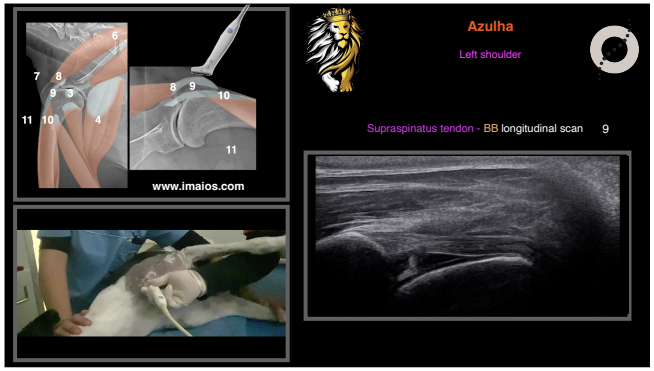
6
7 8
9 3
11 10 4
8 9 10
11
www.imaios.com
Azulha
Left shoulder
Supraspinatus tendon - BB longitudinal scan 9

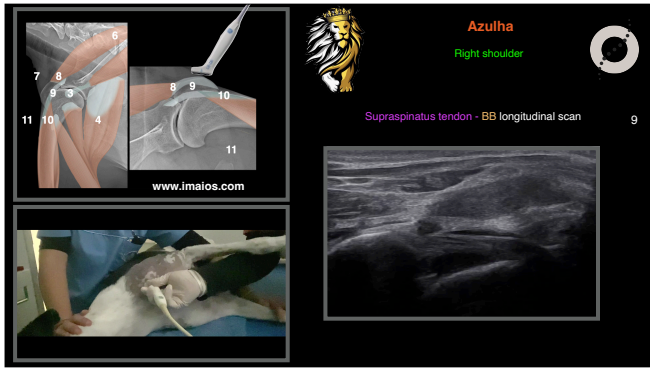
6
7 8
9 3
11 10 4
8 9 10
11
www.imaios.com
Azulha
Right shoulder
Supraspinatus tendon - BB longitudinal scan 9

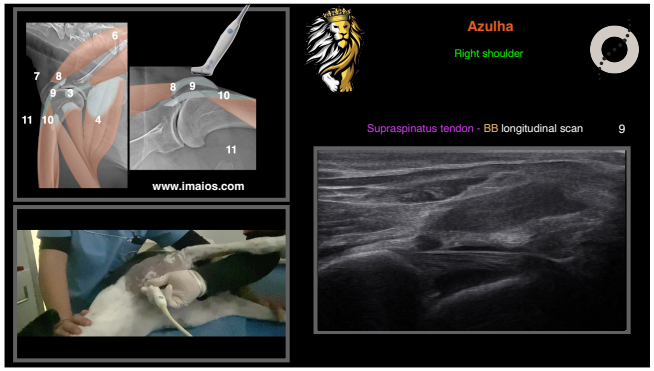
6
7 8
9 3
11 10 4
8 9 10
11
www.imaios.com
Azulha
Right shoulder
Supraspinatus tendon - BB longitudinal scan 9

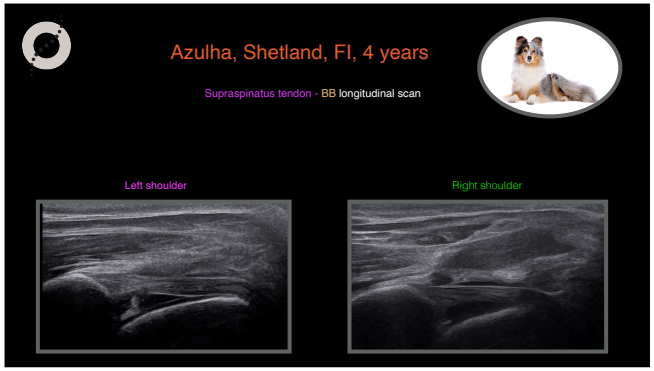
Azulha, Shetland, FI, 4 years
Supraspinatus tendon - BB longitudinal scan
Left shoulder
Right shoulder

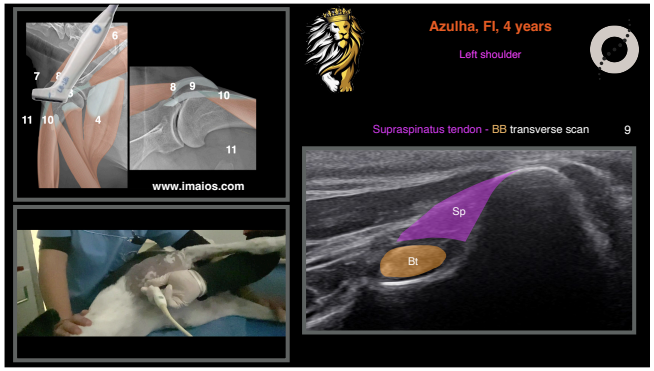
6
7
8
9
10
11
10
4
11
www.imaios.com
Azulha, FI, 4 years
Left shoulder
Supraspinatus tendon - BB transverse scan
9
Sp
Bt

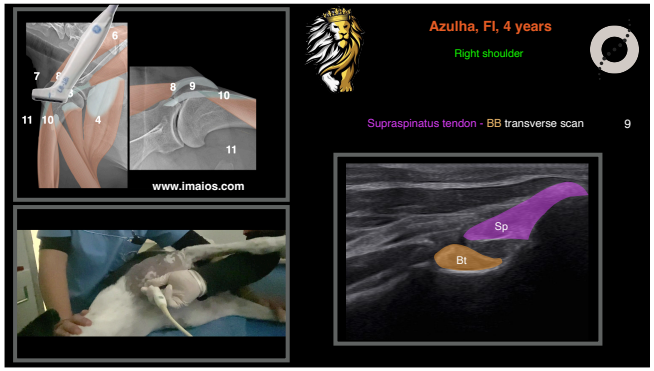
6
7
8
9
10
11
10
4
11
www.imaios.com
Azulha, FI, 4 years
Right shoulder
Supraspinatus tendon - BB transverse scan
9
Sp
Bt

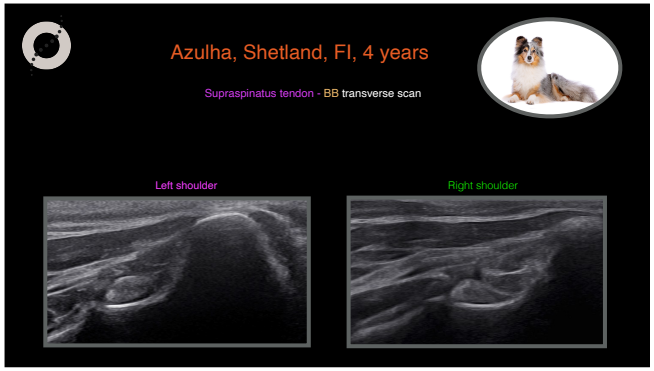
Azulha, Shetland, FI, 4 years
Supraspinatus tendon - BB transverse scan
Left shoulder
Right shoulder

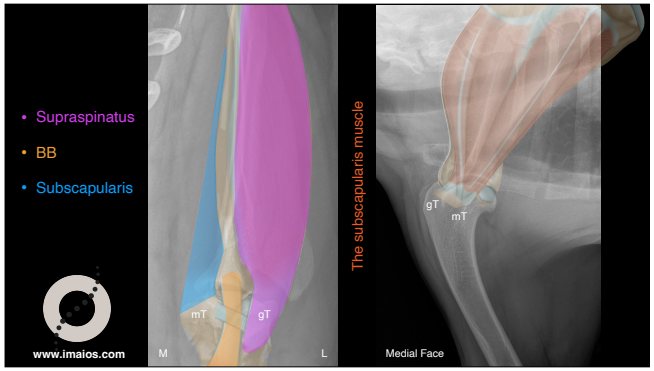
Supraspinatus
BB
Subscapularis
www.imaios.com
mT
gT
M
L
The subscapularis muscle
gT
mT
Medial Face

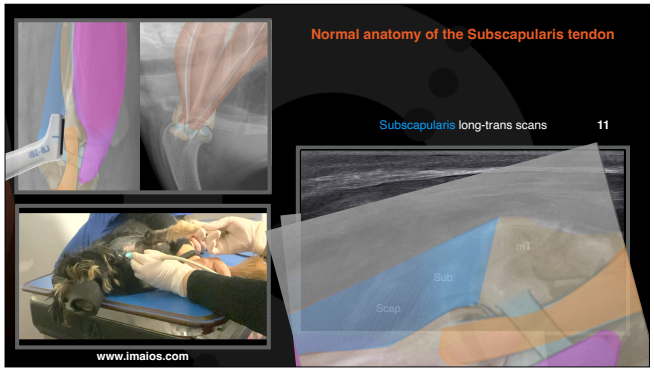
Normal anatomy of the Subscapularis tendon
Subscapularis long-trans scans
11
mT
Sub
Scap
www.imaios.com

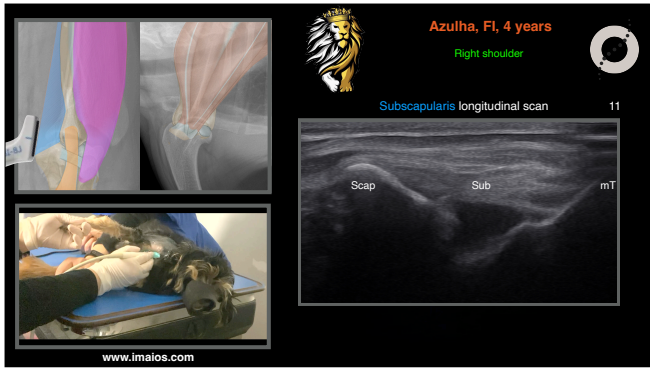
Azulha, FI, 4 years
Right shoulder
Subscapularis longitudinal scan
11
Scap
Sub
mT
www.imaios.com

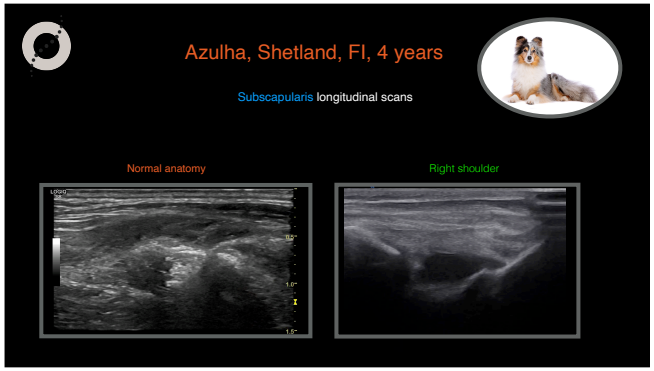
Azulha, Shetland, FI, 4 years
Subscapularis longitudinal scans
Normal anatomy
Right shoulder

Azulha, Shetland, FI, 4 years
Ultrasonographic diagnoses (right shoulder):
• Increased visualisation of the subscapularis tendon
• Subscapularis tendon elongation
• Right shoulder joint effusion
• Thickened joint capsule
Conclusions:
• Strong suspicion of strain of subscapularis tendon/muscle
• - - - Medial shoulder instability? - - -

Medial shoulder instability Syndrome

- Medial glenohumeral ligament
- Subscapularis tendon
- Lateral glenohumeral ligament

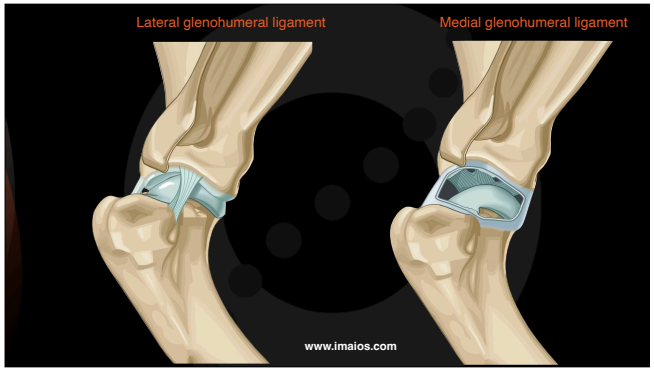

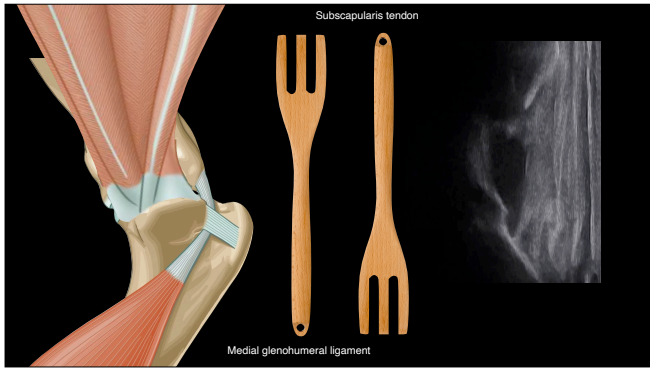

Azulha, Shetland, FI, 4 years

Six months later

- Much more active
- No lameness
- Still not at top performance
- Physiotherapy

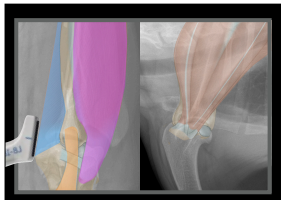

Azulha, FI, 4 years

Right shoulder

Subscapularis longitudinal scan 11

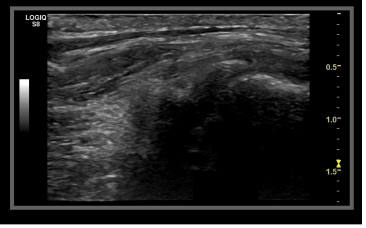

www.imaios.com

Azulha, Shetland, FI, 4 years

Subscapularis longitudinal scans

Normal anatomy

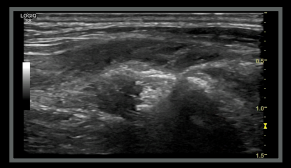

Right shoulder

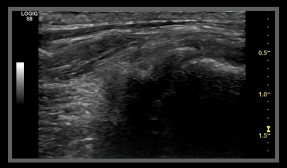

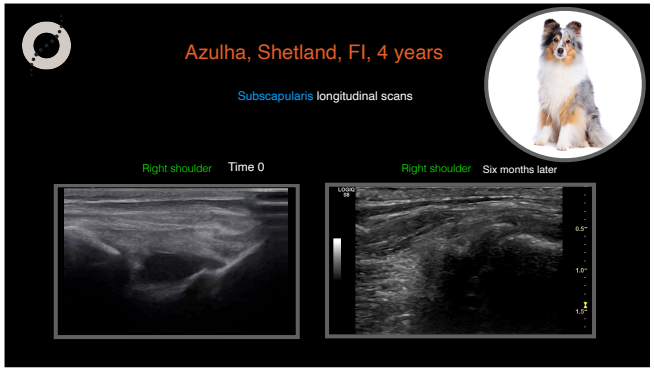
Azulha, Shetland, FI, 4 years
Subscapularis longitudinal scans
Right shoulder Time 0
Right shoulder Six months later

Thank you
Diagnostic Mindset
www.diagnosticmindset.com