

Low performance after pregnancy

CASES DISCUSSION

Giliola Spattini
DVM, GP Cardio, CCRT, PhD, DECVDI



Diagnostic Mindset



Thank to www.imaios.com

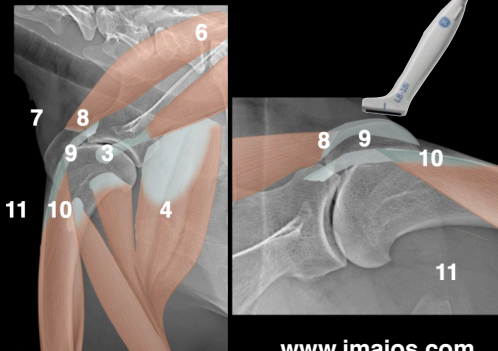
Azulha, Shetland, FI, 4 years

- After pregnancy and rest, reluctant to jump
- Low sportive performance
- She escapes jumping
- Not interested in training



Azulha, Shetland, FI, 4 years

- Pain on right shoulder extension
- Unremarkable radiographs
- Unsuccessful physiotherapy (suspected supraspinatus and biceps tendinopathy)

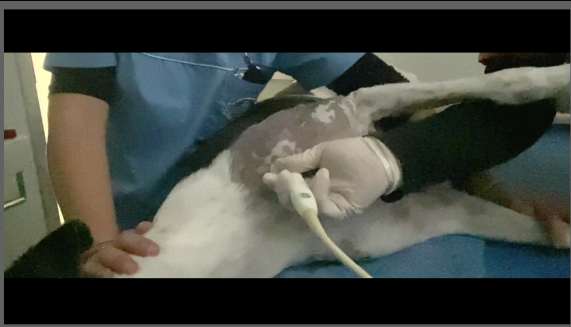
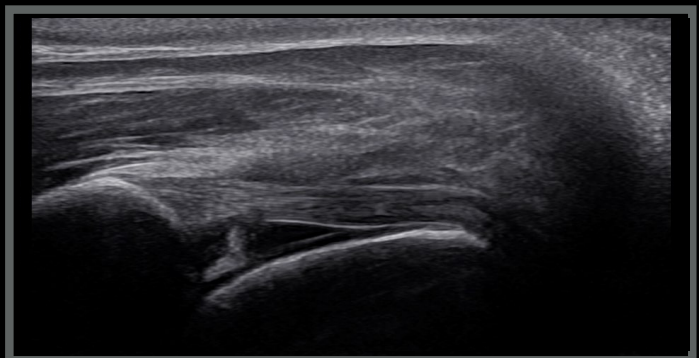


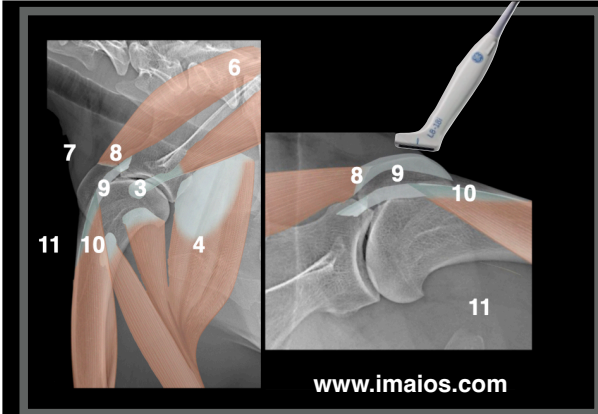
Azulha

Left shoulder



Supraspinatus tendon - BB longitudinal scan 9





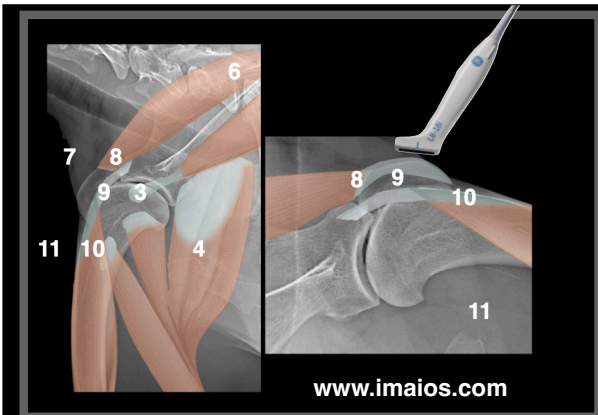
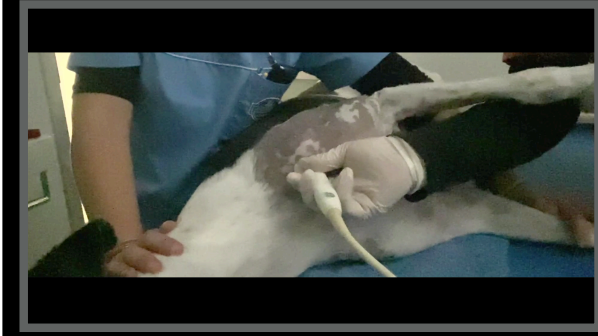
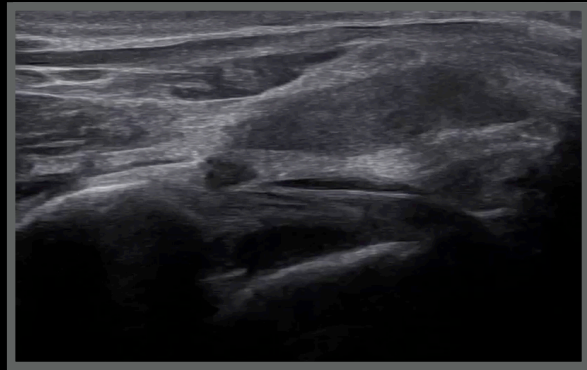
Azulha

Right shoulder



Supraspinatus tendon - BB longitudinal scan

9



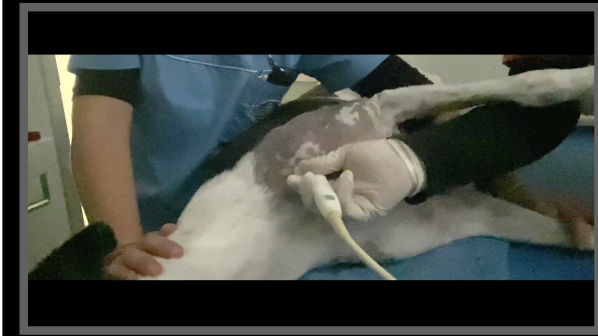
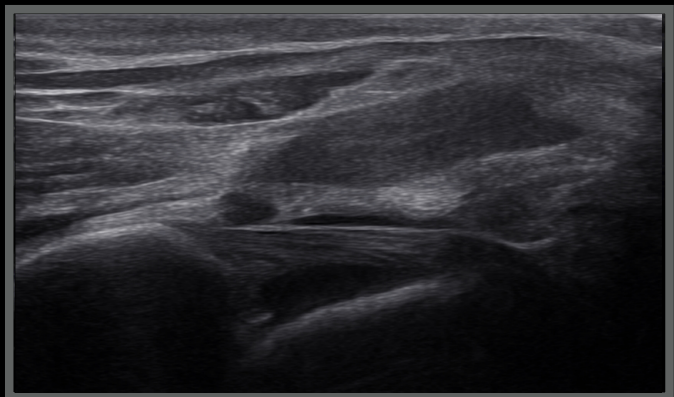
Azulha

Right shoulder



Supraspinatus tendon - BB longitudinal scan

9



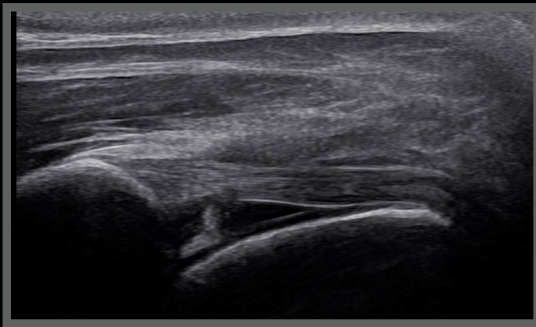


Azulha, Shetland, FI, 4 years

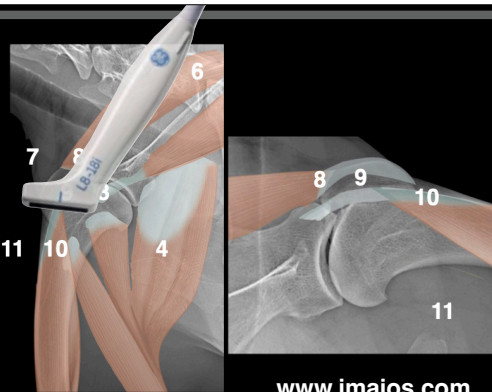
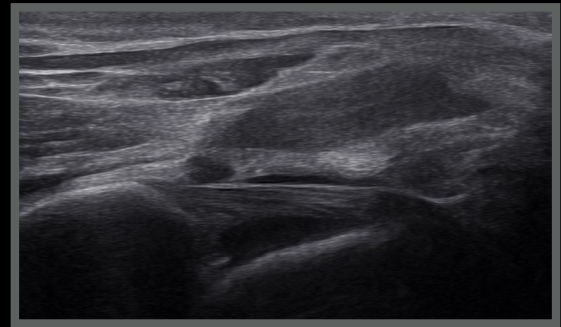


Supraspinatus tendon - BB longitudinal scan

Left shoulder



Right shoulder



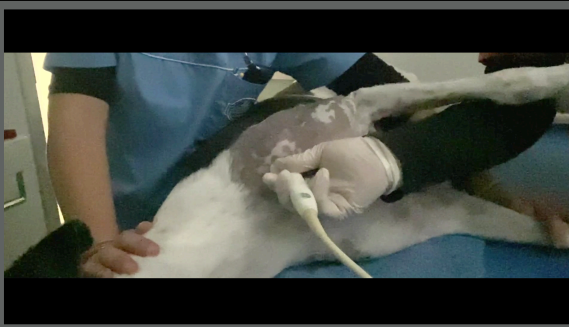
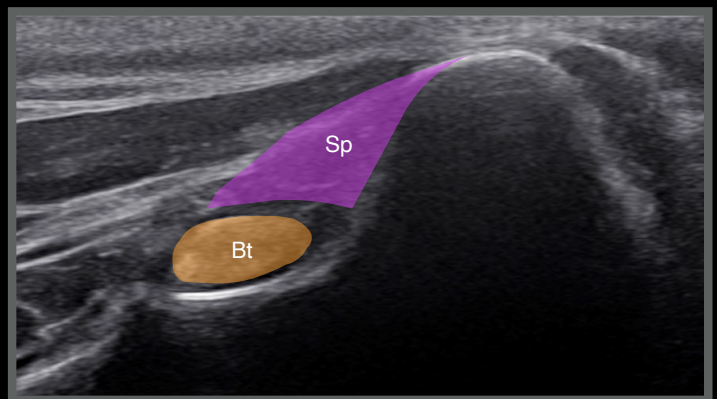
Azulha, FI, 4 years

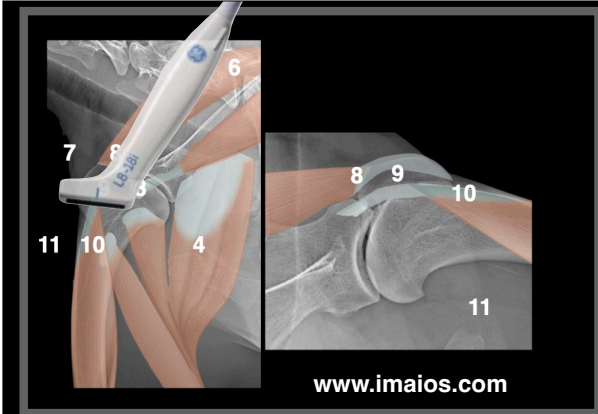
Left shoulder



Supraspinatus tendon - BB transverse scan

9





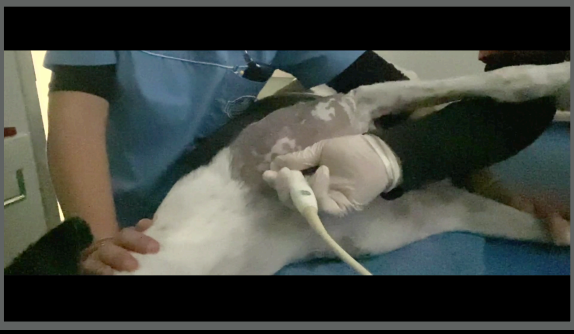
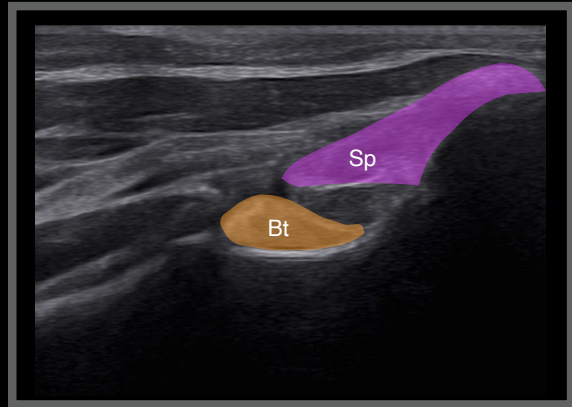
Azulha, FI, 4 years

Right shoulder



Supraspinatus tendon - BB transverse scan

9



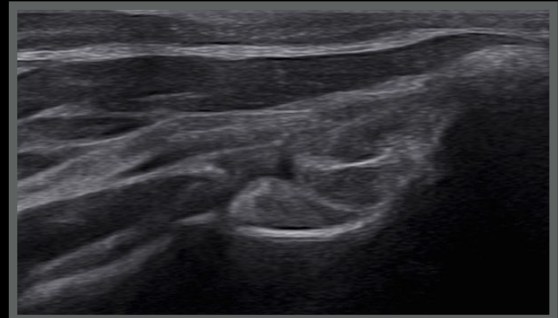
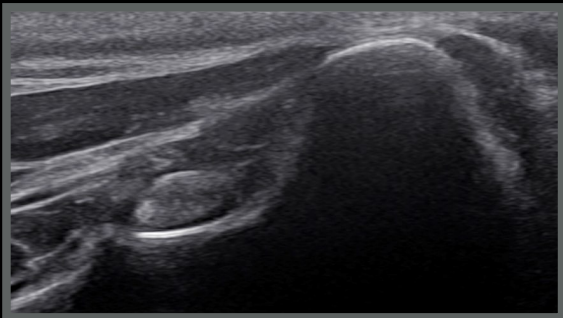
Azulha, Shetland, FI, 4 years

Supraspinatus tendon - BB transverse scan

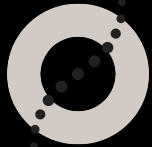


Left shoulder

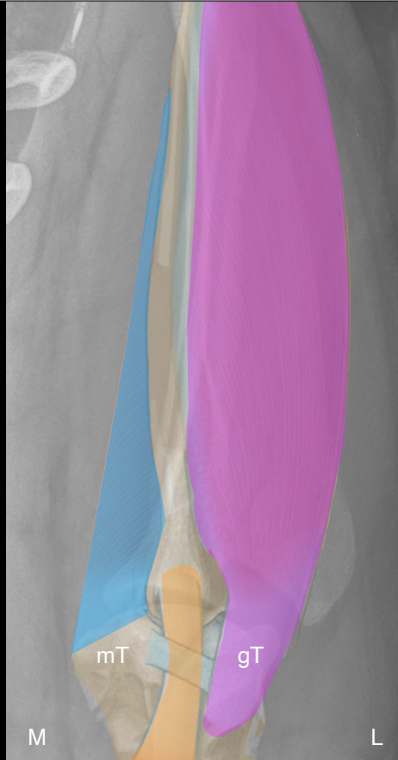Right shoulder



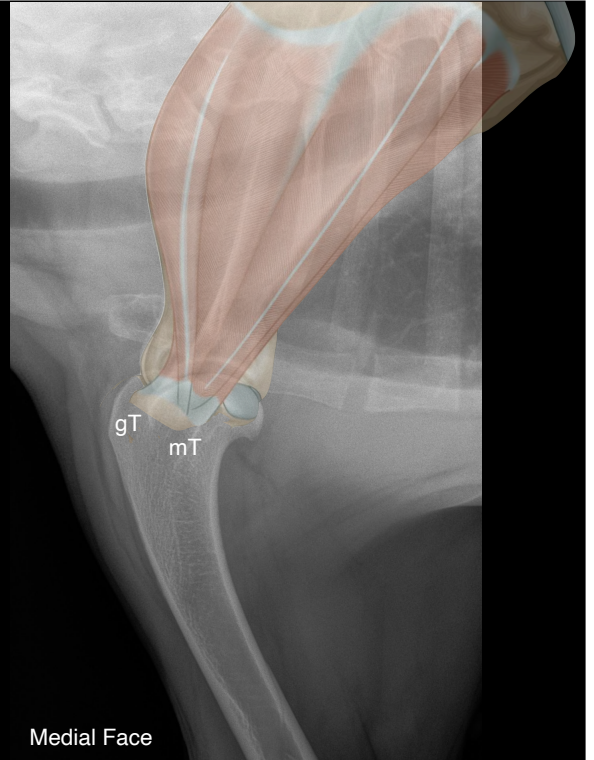
- Supraspinatus
- BB
- Subscapularis



www.imaios.com



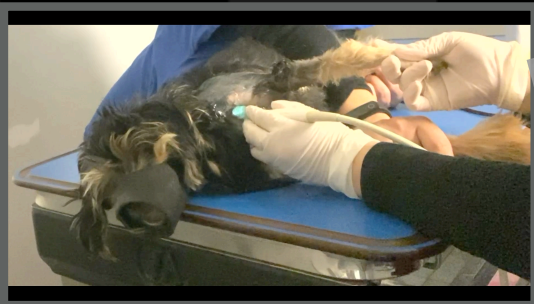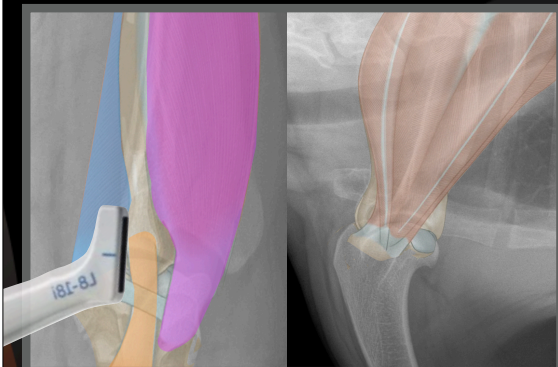
The subscapularis muscle



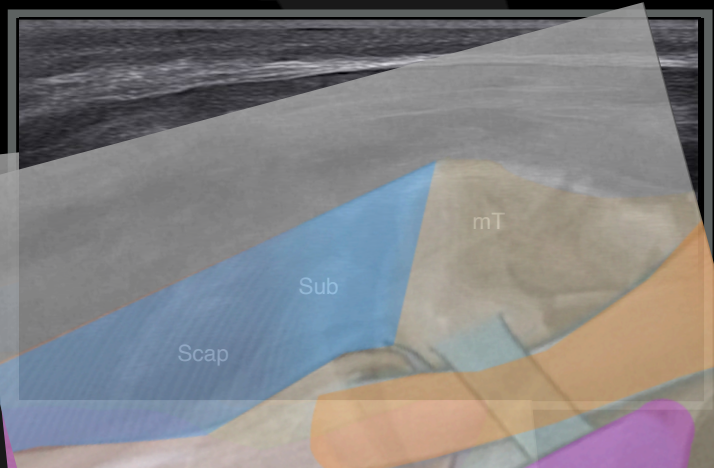
Normal anatomy of the Subscapularis tendon

Subscapularis long-trans scans

11



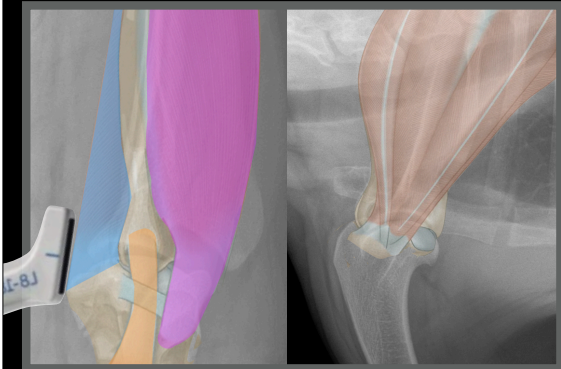
www.imaios.com





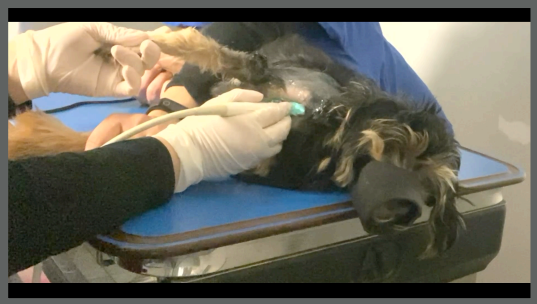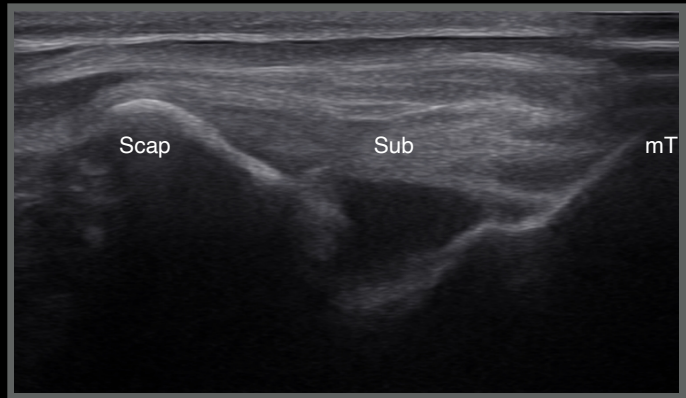
Azulha, FI, 4 years

Right shoulder



Subscapularis longitudinal scan

11



www.imaios.com



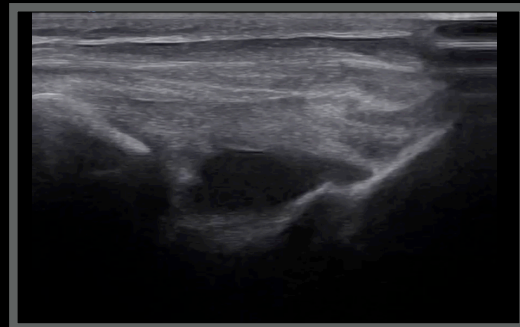
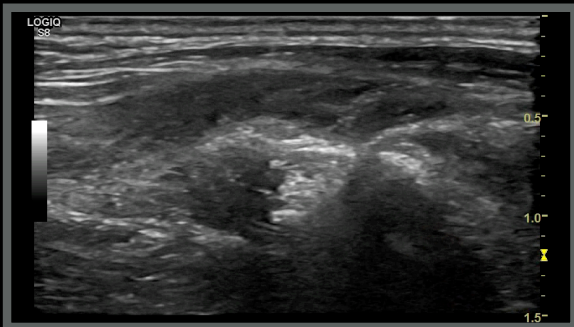
Azulha, Shetland, FI, 4 years



Subscapularis longitudinal scans

Normal anatomy

Right shoulder



Azulha, Shetland, FI, 4 years

Ultrasonographic diagnoses (right shoulder):

- Increased visualisation of the subscapularis tendon
- Subscapularis tendon elongation
- Right shoulder joint effusion
- Thickened joint capsule

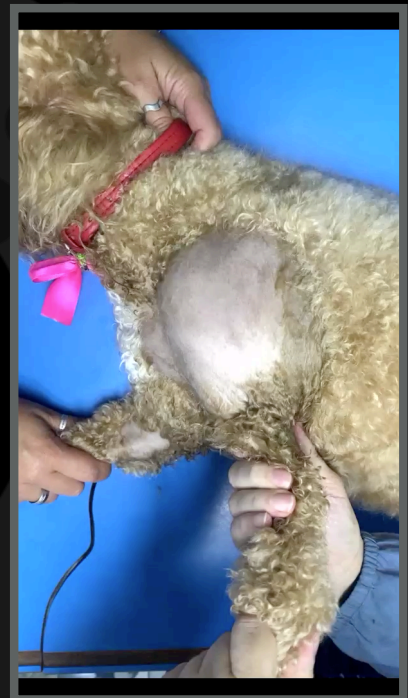Conclusions:

- Strong suspicion of strain of subscapularis tendon/muscle
- - - - Medial shoulder instability? - - -

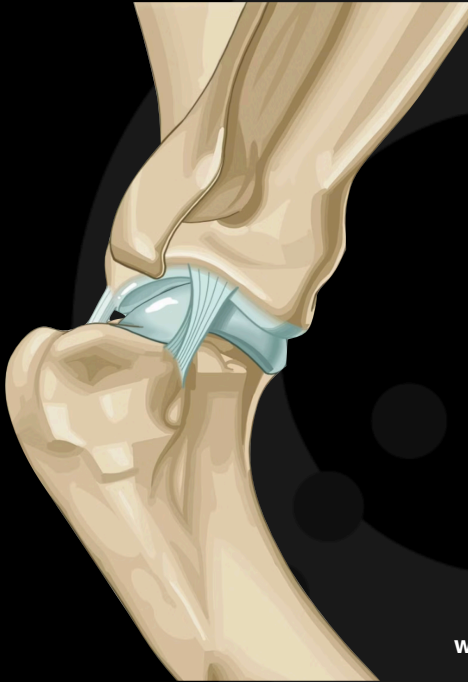


Medial shoulder instability Syndrome

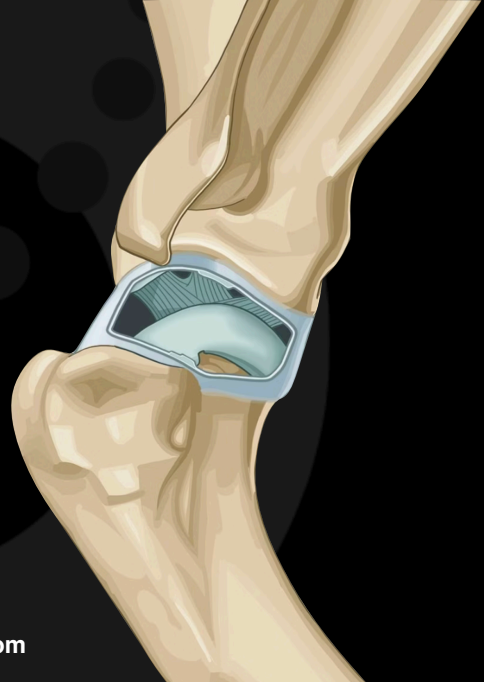- Medial glenohumeral ligament
- Subscapularis tendon
- Lateral glenohumeral ligament



Lateral glenohumeral ligament

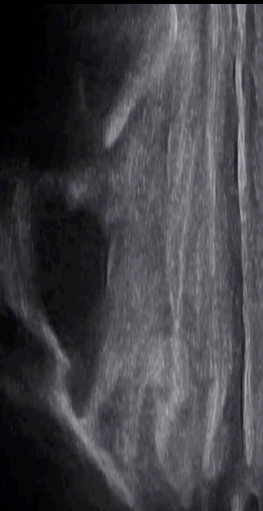
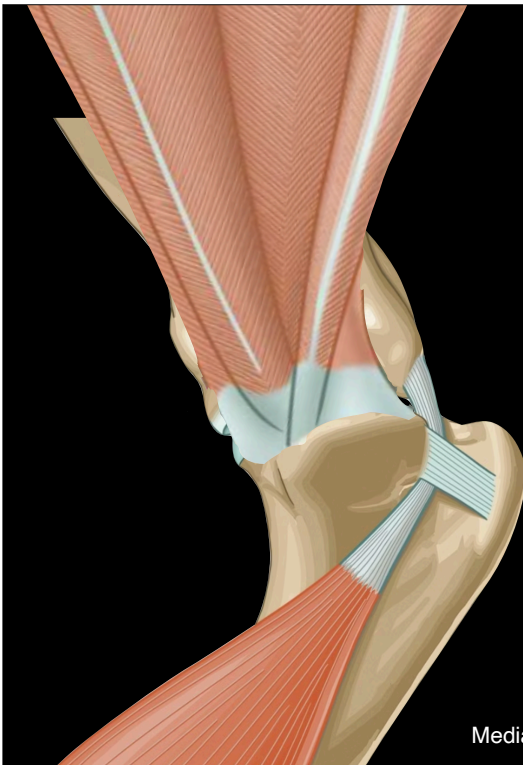


Medial glenohumeral ligament



www.imaios.com

Subscapularis tendon

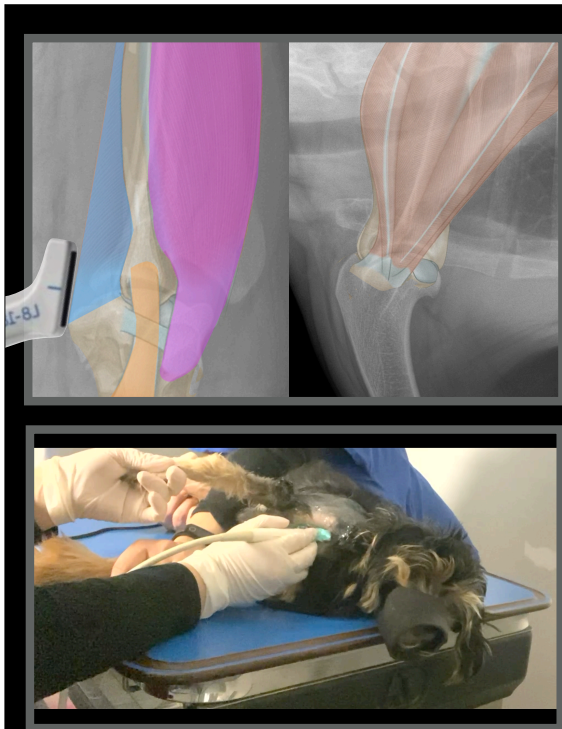


Medial glenohumeral ligament

Azulha, Shetland, FI, 4 years

Six months later

- Much more active
- No lameness
- Still not at top performance
- Physiotherapy

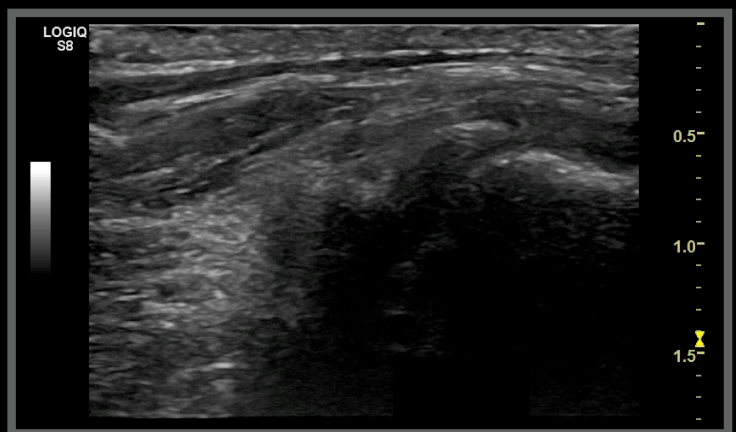


Azulha, FI, 4 years

Right shoulder

Subscapularis longitudinal scan

11



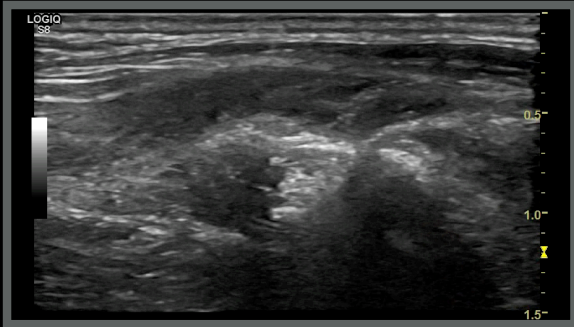


Azulha, Shetland, FI, 4 years

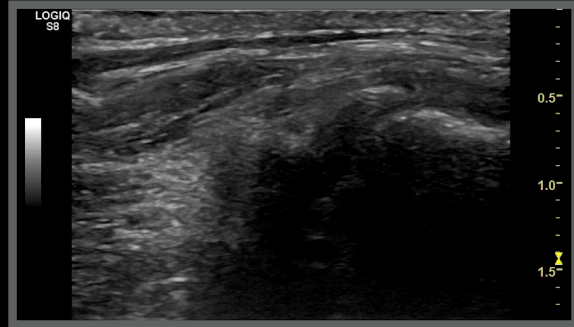
Subscapularis longitudinal scans



Normal anatomy



Right shoulder

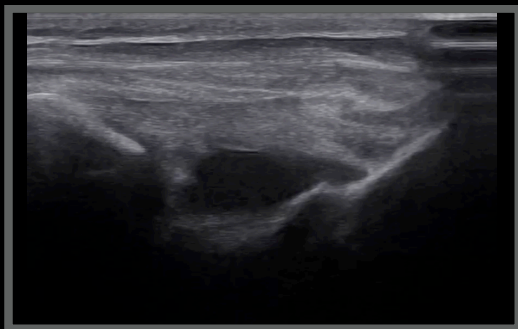


Azulha, Shetland, FI, 4 years

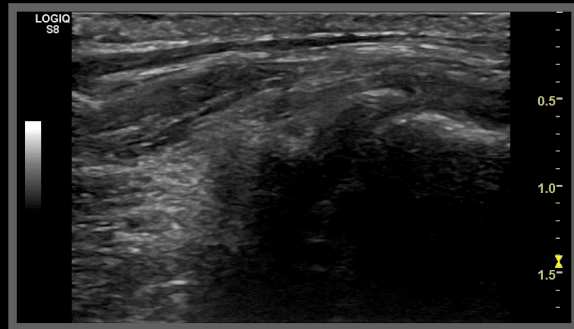
Subscapularis longitudinal scans



Right shoulder Time 0



Right shoulder Six months later



Thank you



Diagnostic Mindset

www.diagnosticmindset.com