Low performance after pregnancy

CASES DISCUSSION

Giliola Spattini
DVM, GP Cardio, CCRT, PhD, DECVDI

Diagnostic Mindset

Clinica Veterinaria CASTELLARANO

Thank to www.imaios.com

Azulha, Shetland, FI, 4 years

- After pregnancy and rest, reluctant to jump
- Low sportive performance
- She escapes jumping
- Not interested in training

Azulha, Shetland, FI, 4 years

- Pain on right shoulder extension
- Unremarkable radiographs
- Unsuccessful physiotherapy (suspected supraspinatus and biceps tendinopathy)

Azulha
Left shoulder
Supraspinatus tendon - BB longitudinal scan 9
www.imaios.com

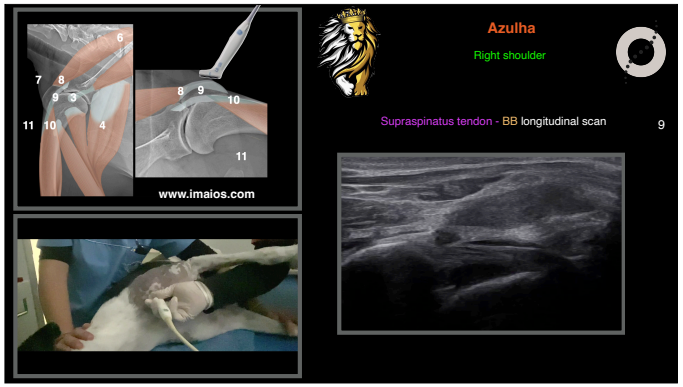
Azulha
Right shoulder
Supraspinatus tendon - BB longitudinal scan 9
www.imaios.com

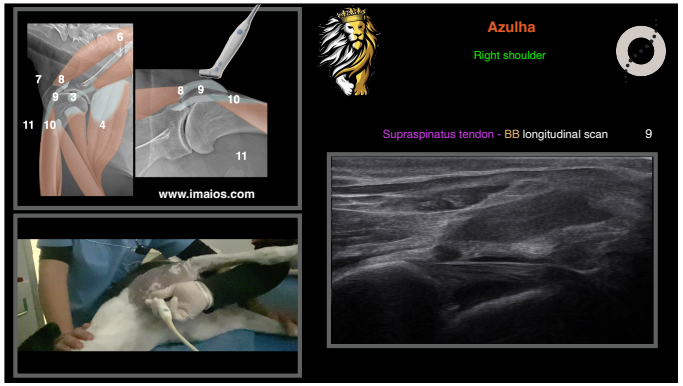
Azulha
Right shoulder
Supraspinatus tendon - BB longitudinal scan 9
www.imaios.com

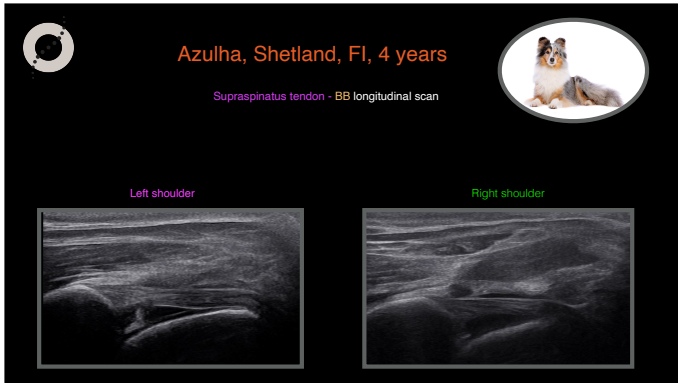
Azulha, Shetland, FI, 4 years
Supraspinatus tendon - BB longitudinal scan
Left shoulder
Right shoulder

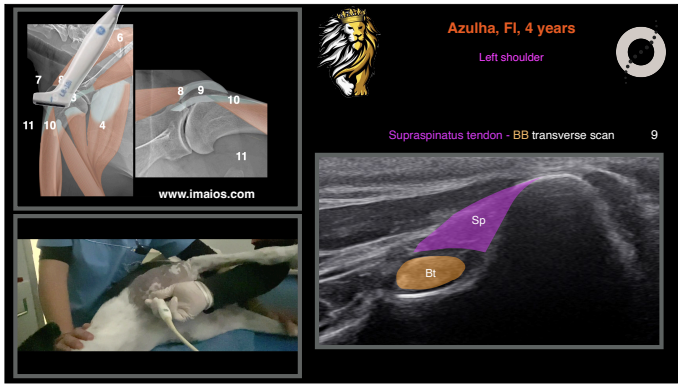
www.imaios.com
Azulha, FI, 4 years
Left shoulder
Supraspinatus tendon - BB transverse scan
9
Sp
Bt

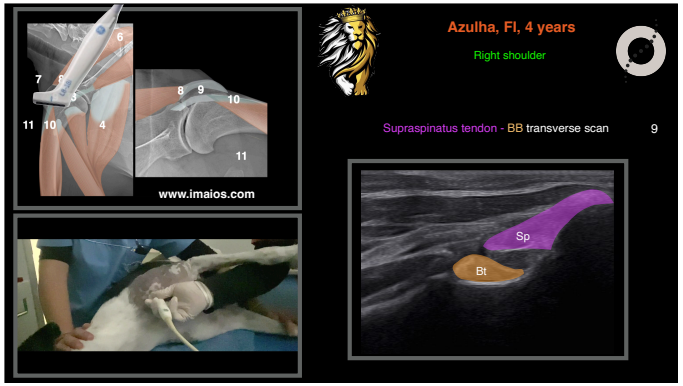
www.imaios.com
Azulha, FI, 4 years
Right shoulder
Supraspinatus tendon - BB transverse scan
9
Sp
Bt

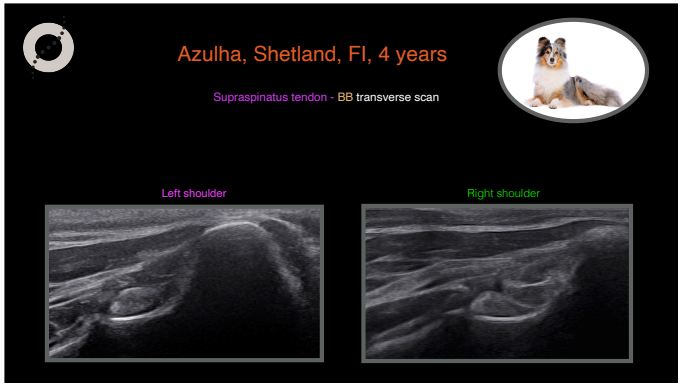
Azulha, Shetland, FI, 4 years
Supraspinatus tendon - BB transverse scan
Left shoulder
Right shoulder

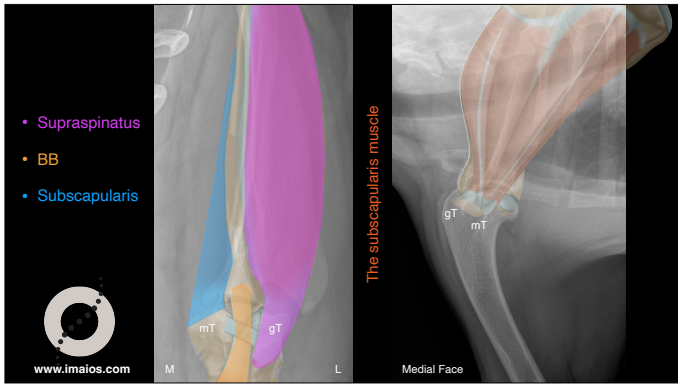
Supraspinatus
BB
Subscapularis
www.imaios.com
mT
gT
M
L
The subscapularis muscle
gT
mT
Medial Face

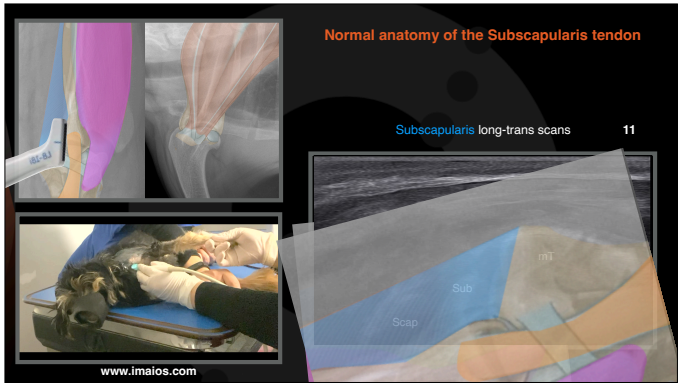
Normal anatomy of the Subscapularis tendon
Subscapularis long-trans scans
11
mT
Sub
Scap
www.imaios.com

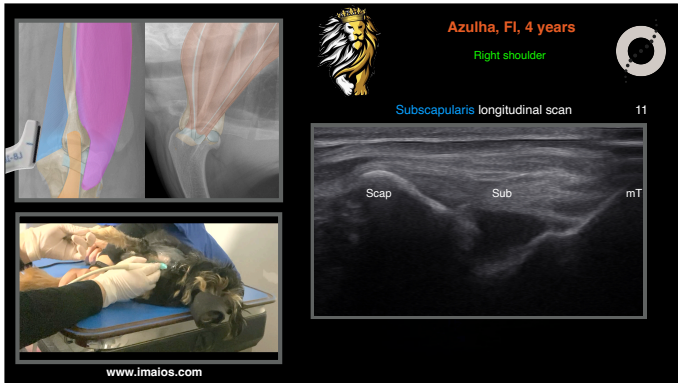
Azulha, FI, 4 years
Right shoulder
Subscapularis longitudinal scan
11
Scap
Sub
mT
www.imaios.com

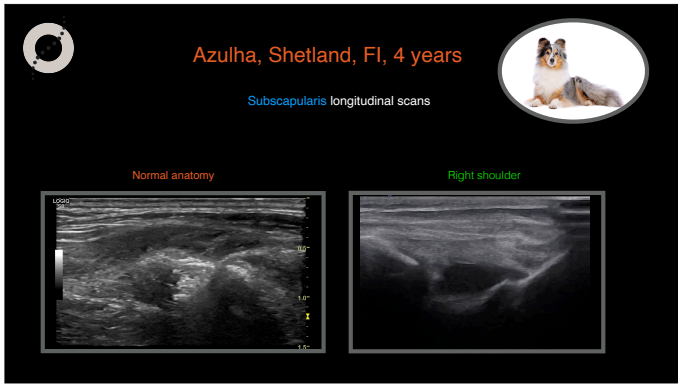
Azulha, Shetland, FI, 4 years
Subscapularis longitudinal scans
Normal anatomy
Right shoulder

Azulha, Shetland, FI, 4 years
Ultrasonographic diagnoses (right shoulder):
• Increased visualisation of the subscapularis tendon
• Subscapularis tendon elongation
• Right shoulder joint effusion
• Thickened joint capsule
Conclusions:
• Strong suspicion of strain of subscapularis tendon/muscle
• - - - Medial shoulder instability? - - -

Medial shoulder instability Syndrome

- Medial glenohumeral ligament
- Subscapularis tendon
- Lateral glenohumeral ligament

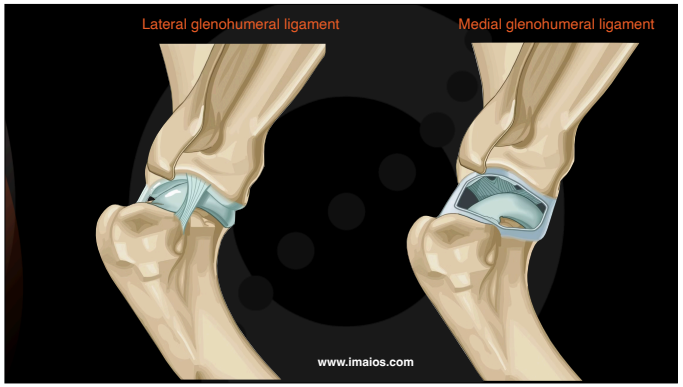

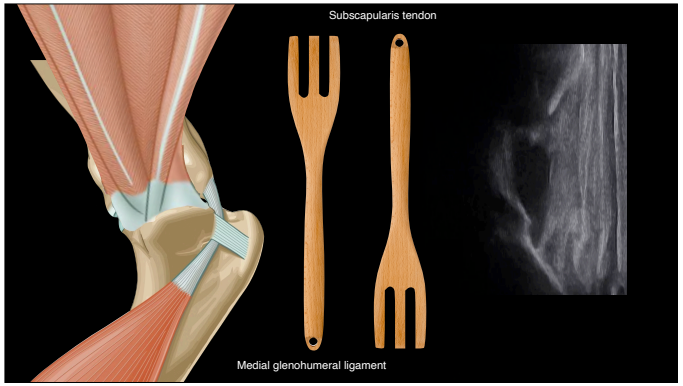

Azulha, Shetland, FI, 4 years

Six months later

- Much more active
- No lameness
- Still not at top performance
- Physiotherapy

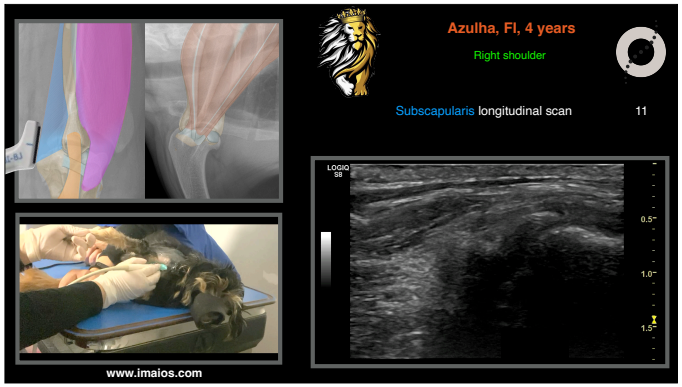

Azulha, Shetland, FI, 4 years

Subscapularis longitudinal scans

Normal anatomy

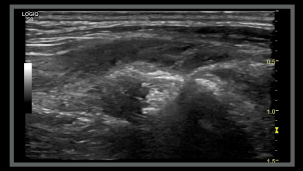

Right shoulder

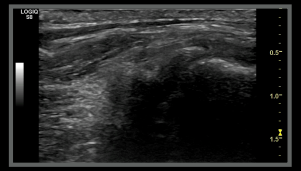

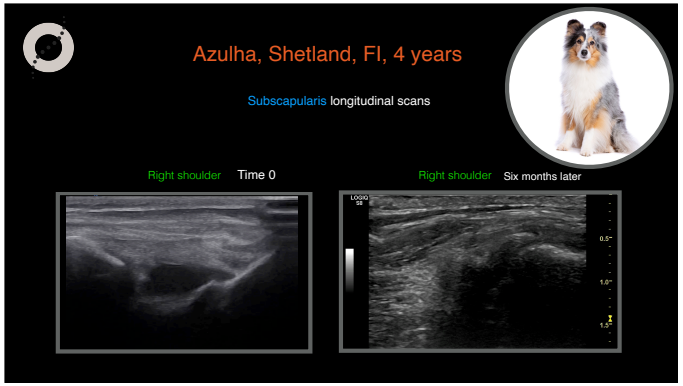
Azulha, Shetland, FI, 4 years
Subscapularis longitudinal scans
Right shoulder Time 0
Right shoulder Six months later

Thank you
Diagnostic Mindset
www.diagnosticmindset.com