

Most Common Sport Related Muscluo-Tendinous Lesions of the Hind Limb

Straight Patellar Tendon - Popliteal Tendon Avulsion - Long Digital Tendon Avulsion and Luxation - Meniscal Injuries

MSK Ultrasonography - The Hind Limb
Canine Sport Medicine Espoo - Finland 2024

Alessandro Piras
DVM - ISVS

Straight Patellar Tendon injuries

Straight Patellar Tendon injuries

Traumatic lesions of the patellar ligament (PL) are rare in dogs. The resulting injury can be a complete or partial laceration, depending on the quantity of torn collagen fibres. Information obtained from imaging evaluation is of great value to the clinical approach towards PL injuries, because subsequent treatment options are affected by the distinction between complete or partial tears.

Although ultrasound (US) and magnetic resonance imaging (MRI) have been described as useful diagnostic tools for the assessment of PL tears in human patients, specific comparative data regarding the evaluation of PL rupture in dogs using different imaging modalities is lacking in the veterinary literature.

Straight Patellar Tendon injuries

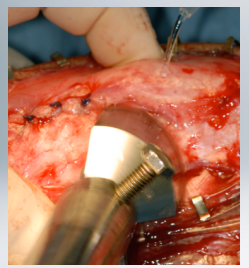

Pacchiana JAVMA 2003 - Priddy JAVMA 2003 - Stauffer JAAHA 2006 - Coletti CAN VET J 2014

The normal PL is described as a striated hyper-reflective structure hyperechoic to the patellar fat pad. Collagen bundles reflect sound waves to the transducer, giving an echogenic fibrillary pattern to the normal PL in both short and long axes.

The paratenon appears as a hyper-reflective solid line around the PL tissue (Soler et al., 2007; Chang and Miller, 2009; McNally, 2014).

A tear may be seen as a hypoechoic area interrupting ligament fibres and extending across the ligament as a full-thickness complete or partial tear (Hodgson et al., 2012).

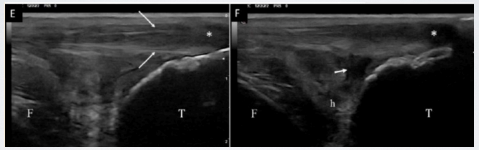

On US the PL shows enlargement of its distal part and heterogeneous echotexture with intraligamentous anechoic defect (asterisks). The paratenon (long arrows) appears unaffected. The infrapatellar fat pad (h) appears inhomogeneous, hypoechoic with a small inner fluid collection. T: Tibia; F: Femur.

Open Veterinary Journal, (2018), Vol. 8(3): 256-264

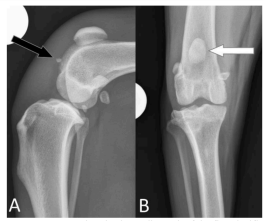

Fig. 1. (A): Lateral projection radiograph of the flexed stifle reveals severe soft tissue opacity in the cranial stifle region. A round, well-defined mineral opacity is found distal to the patella and cranial to the femoral condyles, consistent with an avulsion fracture of the distal pole of the patella (black arrow). **(B):** Craniocaudal projection of the extended stifle reveals the patella is proximally displaced suggestive of a patellar tendon rupture (white arrow).

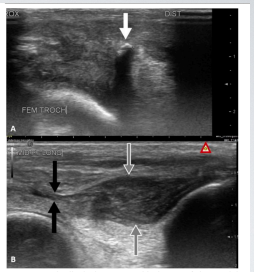

Fig. 2. Longitudinal ultrasonographic image of the cranial stifle in the region of the normal patellar tendon. **(A):** A hyperechoic structure distal to the femoral trochlear groove with distal acoustic shadowing is present (white arrow). **(B):** The patellar tendon has a focal area of fiber disruption and severe thickening (gray arrows). The patellar tendon abruptly tapers (black arrows) and cannot be traced proximally.

Straight Patellar Tendon injuries - Literature

Radiographic changes of the patellar ligament in dogs after tibial tuberosity advancement

Ladislav Stehlík , Pavel Proks , Petra Fedorová, Alois Nečas
ACTA VET. BRNO 2013, 82: 215–218

Patellar ligament rupture in the dog: repair methods and patient outcomes in 43 cases

Das S, Thorne R, Lorenz N.D, Clarke SP, Madden M, Langley-Hobbs SJ, Perry KL, Burton NJ, Moores AL, Mosley JRVet. Rec. 2014;175:370.

Comparative diagnostic imaging of a partial patellar ligament tear in a dog

Ricciardi M. - Open Vet - 2018; 8(2): 160–167.

Surgical repair of a proximal patellar tendon avulsion in a dog utilizing triple patellar bone tunnels and modified tendon repair technique

Johnson et Al - Open Veterinary Journal, (2018), Vol. 8(3): 256-264

Advantages of US images

Allows an in-depth-view of the PL structure at high spatial resolution and subsequent high detail of fibrillary pattern.

The identification of lesions and the evaluation of their extension are clearly assessed due to the high contrast resolution between the hypoechogenicity of the fibrillary gap and the echogenicity of the normal ligament tissue

Provides superior visualisation of the fibrillary PL architecture and further detail regarding the position, extension and paratenon involvement of the fibrillary gap (i.e. tendon fibre discontinuity)

US may offer slightly superior detail compared to MRI for the accurate imaging diagnosis of partial PL tears

Another key advantage of ultrasound compared to MRI is the ability to dynamically assess tendons and ligaments, allowing visualisation both from different angles and under stress (Hodgson et al., 2012).

Long Digital Extensor Tendon Avulsion - Anatomy

Origin: (LDE) originates from the extensor fossa on the lateral epicondyle of the femur and is protected by a capsular synovial bursa on the lateral aspect of the stifle; it runs through the extensor groove on the craniolateral aspect of the tibia. Distal to the sulcus, the tendineous structure gradually contains more muscle fibres. The muscle belly of the LDE muscle runs distally deep to the cranial tibial muscle on the craniolateral surface of the tibia.

Insertion: inserts at the distal phalanx of II-V digits

Function: Extension of the digits; flexion of the tarsus.

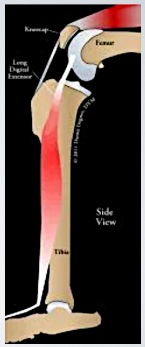

Long Digital Extensor Tendon Avulsion - Diagnosis

Incidence: injuries to the LDE in dogs are rarely the cause of pelvic limb lameness

Generally occur as avulsion injuries at the tendon origin in young, large breed dogs. Breeds most commonly affected include Great Danes, Golden retrievers and Labrador retrievers

Dogs develop this problem when they are typically under 1 year of age; however, two reports have cited Great Danes that were 14 and 16 months of age when clinical signs of the problem were first noted

Secondary mineralization of the LDE in response to this type of avulsion injury has been reported

Clinical Signs: unilateral pelvic limb lameness with joint effusion, stifle pain and soft tissues thickening on the lateral aspect of the femoral condyle

Diagnosis of the acute condition may be difficult which may be the reason chronic injuries are most commonly reported

Long Digital Extensor Tendon Avulsion - Imaging

Diagnosis
The diagnosis of a long digital extensor avulsion is supported by x-rays and physical examination findings
US, CT scan or MRI have been described

Surgical correction of avulsion of the long digital extensor in the dog
Olmstead - Veterinary Medicine/Small Animal Clinics 71, 608, 1976

Avulsion fracture of the origin of the extensor digitorum longus muscle in three dogs
Lammerding et Al - Journal of American Animal Hospital Association 12, 764, 1976

Radiographic, computed tomographic and magnetic resonance imaging evaluation of a chronic long digital extensor tendon avulsion in a dog
Fitch et Al - Veterinary Radiology and Ultrasound 38, 177-181, 1997

Unusual presentation of an avulsion of the long digital extensor tendon in a dog: radiographic, computed tomographic, arthroscopic, surgical and histological findings
Verhoeven et Al - Diergenesdundig Tijdschrift 76:438-42, 2007

Long Digital Extensor Tendon Avulsion - Luxation

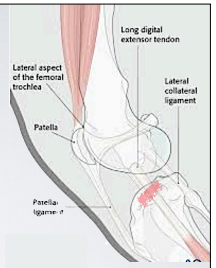

The tendon crosses the stifle joint and passes through the muscular groove on the craniolateral aspect of the tibia
A thin fibrous band bridges the LDE in its extensor sulcus

Displacement of the proximal tendon of the LDE muscle is an unusual problem in dogs
Two case reports can be found in the literature. First been described in a 2-year-old Bracco Italiono. Not anamnesis of trauma. Second describes displacement of the LDE tendon in a 1-year-old Whippet with a malunion fracture of the femoral shaft with a resultant medial bowing of the bone

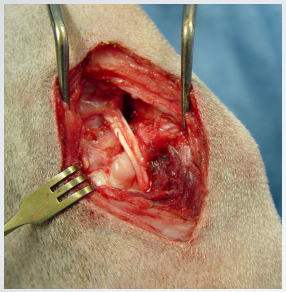

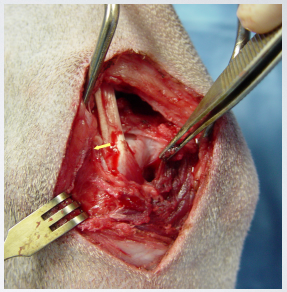

Nuove conoscenze sulla patologia del muscolo extensor digitorum longus nel cane
Addis F. - Folia Vet Lat 1971; 1: 630-52.

Unusual soft tissue orthopaedic problems in the dog
Bennett - BSAVA Proceedings 1979; 27-39

Long digital extensor and popliteal tendon avulsion associated with lateral patellar luxation in a dogs
Bardet - JAVMA 1983; 4: 465-6

Displacement off the proximal tendon of the long digital extensor muscle
De Rooster - VCOT 2004; 17: 253–5

Long term outcomes following plate stabilization to address spontaneous luxation of the long digital extensor tendon of origin in 2 dogs
Hasiuk, et al. Canadian Veterinary Journal, v. 58, p.1176-1180, 2017

Popliteal Muscle - Anatomy

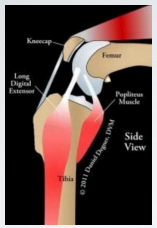

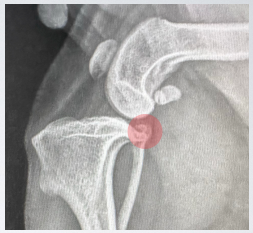

Origin: Plantar surface of the lateral condyle of the femur by a long tendon that contains a sesamoid bone

Insertion: Proximal third of the medial border of the tibia.

Popliteal Muscle - Function

The popliteal muscle assist in flexion of the stifle joint and to maintain internal rotation of the tibia with respect to the femur

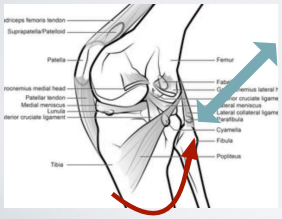



Popliteal Muscle Avulsion - Diagnosis

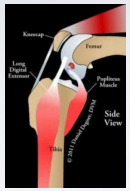

Rare cause of lameness

Avulsion occurs at the lateral femoral condyle
Pain on extension of the stifle and pain at palpation of caudal aspect of the stifle

Popliteal Muscle Avulsion - Imaging

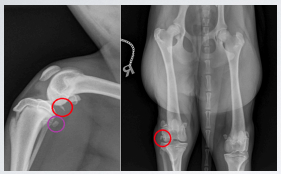

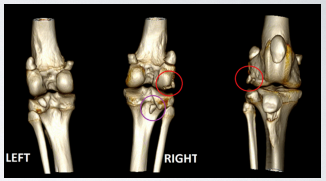

On radiographs: soft tissue swelling the popliteal sesamoid at the caudal aspect of the stifle joint will be displaced ditto-medially

Popliteal Muscle Avulsion - Case Example

Golden Retriever - Male - 2 Y of age

Complain of mild lameness of the right pelvic limb of 6 months' duration. The lameness was first noticed immediately after an episode of outdoor activity. Initially, the dog was non–weight bearing. The lameness had improved to partial weight bearing during the next 2 weeks, and the dog had been partially weight bearing on the limb during the next 6 months.

Physical and orthopedic examination revealed slight external rotation of the right pelvic limb when the dog was standing. Manipulation of the right stifle joint elicited mild crepitus through the normal range of motion and a slight pain response on deep palpation of the lateral femoral condyle.

Case Example - Imaging

Notice the avulsed fragment and the distal displacement of the sesamoid

Avulsion of the popliteus muscleman an Afghan hound
Eaton Wells- JSAP 1978

Long digital extensor and popliteal tendon avulsion associated with lateral patella *luxation in a dog*.
Bardet JF, Piermattei DL. - J Am Vet Med Assoc 1983;183:465–466.

Avulsion of the popliteus tendon in a Malinois Dog
Tanno - JSAP 1996

Isolated popliteus tendon avulsion: fully arthroscopic repair with suture anchor
Koukoulias et Al - JBJS Case Connector. 2020

Avulsion of the popliteus tendon in a Border Collie
Gonzales Montano - Vet Record 2021

Meniscal Injuries

Acknowledgments to B. Beale & A. Pozzi

Meniscal Anatomy

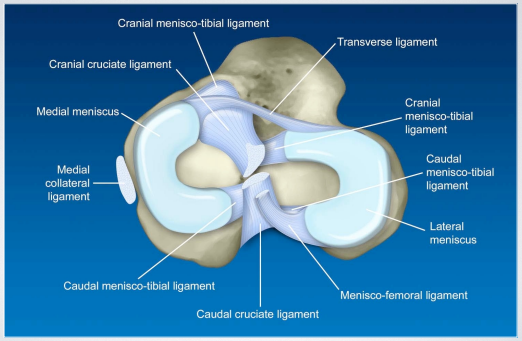

Meniscal Blood Supply

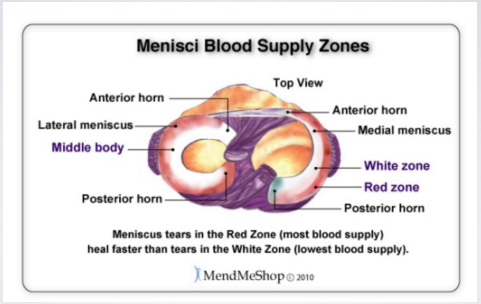

Meniscal Injuries

Commonly occurs secondary to complete or unstable partial CrCL rupture

- 50-80% of cases in dogs with CCL tear over 1 month

Uncommon with stable partial tears

Also occurs with small dogs and cats!

May be difficult to identify

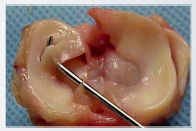

Meniscal Injuries - Mechanism

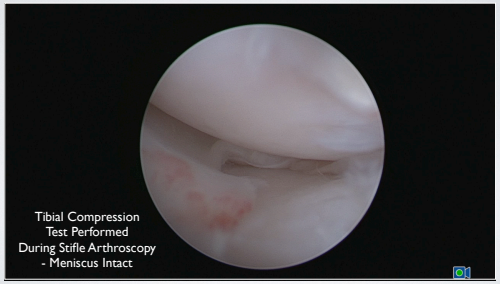

Late Onset Meniscal Injury

Meniscal tears following CCL repair

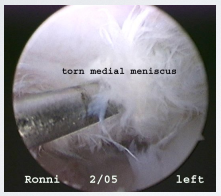

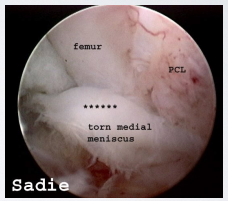

Incidence Based on 2nd look studies (TPLO, CBLO); 40%

Meniscal injury following initial cranial cruciate ligament stabilization surgery in 26 dogs (29 stifles)

J.B. Case Vet Comp Orthop Traumatol 2008; 21: 365–367

Increased lameness or acute onset of lameness after surgery for cranial crucial rupture is a consistent finding

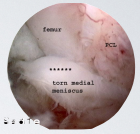

an audible or palpable click was present in 27.6% of cases

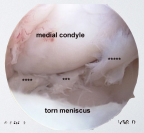

Meniscal Injuries - Examination

Meniscus is difficult to completely examine

- Tears often missed during exam
- Only 10-20% tears are displaced
- Probing increases sensitivity
  - 2X with arthrotomy
  - 3x with arthroscopy

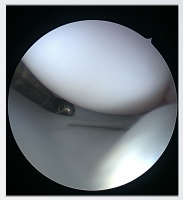

Pozzi et al. *Vet Surg* 2008

Meniscal Injuries - Tears Mechanism

Medial meniscus

- Fixed to tibia
- Caudal pole crushed

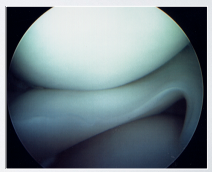

Lateral meniscus

- Caudal pole attached to femur
- Rarely tears

Meniscal Injuries - Tears Diagnosis

Bucket-handle tear most common

Lameness more severe than expected with CCL tear

Meniscal "click" < 50%

Lameness after previous CCL repair

Ultrasound

MRI

Arthrotomy or Arthroscopy

Meniscal Injuries - Benefits of Arthroscopy

Shown to improve detection of meniscal pathology

Minimally invasive treatment of meniscal pathology

Limitation

- Technically challenging
- Invasive

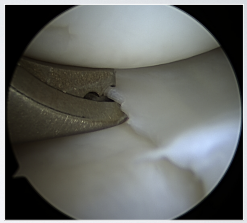

Arthroscopic Partial Meniscectomy

Meniscal Injuries - Tears Classification

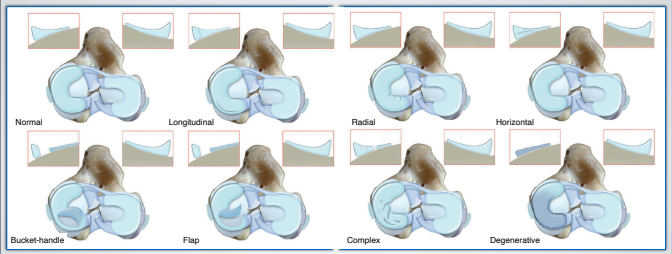

MENISCAL INJURIES - TEARS CLASSIFICATION

IMPORTANT TO CHOOSE THE APPROPRIATE TREATMENT

DIAGNOSIS MAY HAVE PROGNOSTIC VALUE

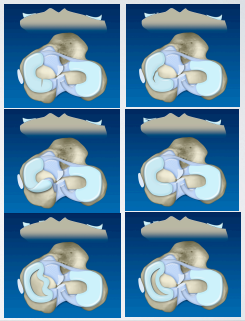

"Contact Mechanics of Simulated Meniscal Tears in Cadaveric Stifles"

Thieman, Pozzi et al. 2009

TO EVALUATE EFFECT OF TYPE OF TEAR ON MENISCAL FUNCTION

↓

INCREASED SEVERITY OF TEARS CORRESPONDS TO INCREASED LOSS OF FUNCTION



Radial Simple

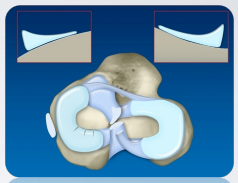

Complex

Multidirectional tears and crushing of the tissue

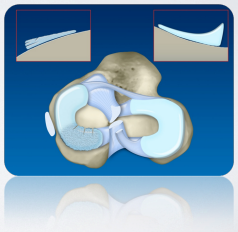

Vertical Longitudinal

NON DISPLACED
usually involving whole caudal pole

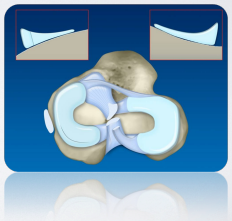

Bucket Handle

DISPLACED VERTICAL LONGITUDINAL
frequently crushed tissue

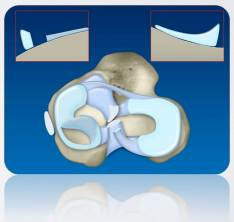

Flap

Transected bucket handle

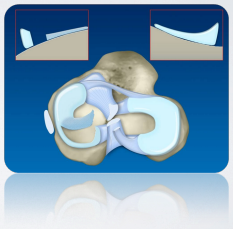

Degenerative



Frequently associated with complex and horizontal tears

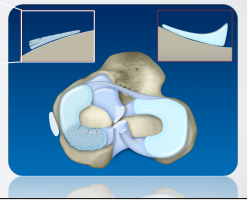

MENISCAL TEAR EVALUATION

TEAR CONFIGURATION	TYPE STABLE OR UNSTABLE LENGTH OF TEAR PRESENCE OF DEGENERATION
TEAR LOCATION	WHITE-WHITE ZONE WHITE-RED ZONE RED-RED ZONE
SALVAGEABLE OR NOT	REPAIRABLE ? PARTIAL MENISCECTOMY ? HEMIMENISCECTOMY

TEAR CONFIGURATION

PARTIAL THICKNESS IS IDEAL FOR REPAIR OR CONSERVATIVE

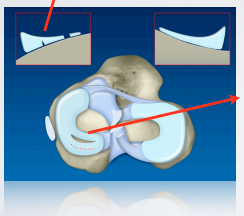

SHORTER VERTICAL TEAR MAY NOT NEED TO BE SUTURED

SALVAGEABLE OR NOT ?

THE MOST IMPORTANT QUESTION THAT SHOULD BE ASKED WHEN TREATING MENISCAL TISSUE

Is meniscal tissue firm at palpation?

There are signs of tissue degeneration?

There are complex tears?

Arthroscopic verification of ultrasonographic diagnosis of meniscal pathology in dogs

Mahn et Al - Vet Surg - 2005 Jul-Aug;34(4):318-23

Objective: To determine the clinical usefulness of ultrasonography for diagnosis of meniscal pathology in dogs.

Conclusions: Ultrasonography is highly specific and sensitive for diagnosing bucket handle tears of the medial meniscus in dogs.

Clinical relevance: Ultrasonographic evaluation of menisci in dogs is a noninvasive method for accurately and efficiently diagnosing pathology, determining the need for surgical intervention, and providing comprehensive information to clients.

Diagnostic value of ultrasonography to assess stifle lesions in dogs after cranial cruciate ligament rupture: 13 cases

Arnault et Al-VCOT- 2009;22(6):479-85

Objective: The objective of this study was to evaluate the accuracy of ultrasonographic diagnosis of lesions in the canine stifle associated with cranial cruciate ligament rupture.

Clinical relevance: High frequency ultrasonography is a non-invasive method for accurately and efficiently detecting superficial ligaments, tendons and meniscal lesions associated with cranial cruciate ligament rupture in the stifle of non-sedated dogs.

"A Dog never bit me, never a Cat scratched me...
Just humans.."

Marilyn Monroe



Most Common Sport Related Muscluo-Tendinous Lesions of the Hind Limb

Ileopsoas Injuries - Myopathy of Gracilis/semitendinous Gracilis injury - Tensor Fascia Lata Injury

MSK Ultrasonography - The Hind Limb
Canine Sport Medicine Espoo - Finland 2024

Alessandro Piras
DVM - ISVS

The Ileopsoas - A common Overload Injury

Recently reported as a common injury in dogs

Acute, stretching-induced muscle injuries are estimated to account for over 30% of injuries seen in a typical human sports medicine practice and have been reported to be the most common injury seen in human general practices

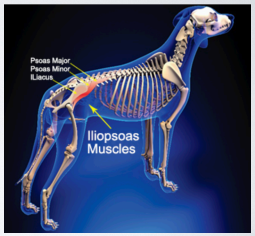

Box 1. Anatomy of the Sublumbar Musculature

- The **psoas minor muscle** is the most ventral muscle arising from the ventral surfaces of the last thoracic and first four or five lumbar vertebrae and inserts on the ilium adjacent to the iliopubic eminence[2] (**FIGURE 1** and **FIGURE 2**).
- The **psoas major muscle** arises laterally from psoas minor muscle and ventral to the quadratus lumborum muscle from the last two thoracic vertebrae and ribs and most of the lumbar vertebrae and inserts, in common with the iliacus muscle as the iliopsoas, on the lesser trochanter of the femur.[4]
- The **iliacus muscle** arises from the ilium and fuses with the psoas major muscle to insert on the lesser trochanter of the femur.
- The **iliopsoas muscle** is innervated by the femoral nerve which is formed by the nerve roots L4, L5 and L6.[4]
- The **quadratus lumborum** muscle arises dorsal to the psoas muscles from the ventral surfaces of the 10th to 13th thoracic vertebrae to insert on the first three lumbar vertebrae as well as the ventral aspect of the sacrum and ilium.[4]

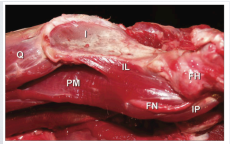

Figure 2. Lateroventral aspect of the pelvic region of a dog (cranial is to the left). *FH* = femoral head, *FN* = femoral nerve, *I* = ilium, *IL* = iliacus muscle, *IP* = iliopsoas muscle, *PM* = psoas major muscle, *Q* = quadratus lumborum muscle.

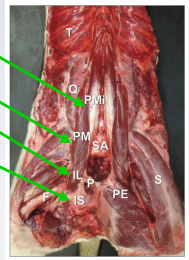

Figure 1. Ventral aspect of the sublumbar and hindlimb musculature (cranial is to the top). *F* = femur, *IL* = iliacus muscle, *IS* = ischium, *T* = thoracic cavity, *PE* = pectineus muscle, *PM* = psoas major muscle, *PMi* = psoas minor muscle, *P* = pubis, *Q* = quadratus lumborum muscle, *S* = sartorius muscle, *SA* = sacrum.

Anatomy

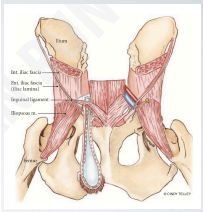

Ileopsoas - Functions

Flexion of the hip joint
Adduction and external rotation of the femur

Core stabilisation:
Flexion and stabilisation of the lumbar spine when the hindlimb is fixed
Caudal traction o the trunk when the hindlimb is in extension

The Ileopsoas - Clinical Signs

Most commonly reported lameness with sudden onset, usually following strenuous exercise or sudden fall. In some case lameness can be chronic with muscle loss

Lameness after activity or after rest
Difficulty rising after lying down
Stiffness and reluctancy to move
Pain when stretching or extending the limb
Decreased ROM and resistance to manipulation of the limb
Muscle atrophy

The Ileopsoas - Causes of Injury



Iliopsoas strain occurs as the result of overloading acting on this muscle during intense athletic activities

Most common location at the muscle-tendinous junction

A passive extension during an active contraction or an eccentric contraction, in which the muscle is activated during stretch, are important factor in the development of these acute strain injuries.

Traumatic incidents that result in active eccentric muscle contraction, such as slipping into a splay-legged position, jumping out of a vehicle, aggressive agility training, or roughhousing with other dogs are often suspected in precipitating acute lameness.

The Ileopsoas - Relevant Literature

Traumatic injury of the ileopsoas muscle in 25 dogs
Breur , ACVS Symp. 1995

Traumatic injury of the ileopsoas muscle in 3 dogs.
Breur , JAVMA. 1997

CT features of a suspect injury of the ileopsoas and pelvic muscolature of a dog
Rossmeisl - Vet Rad 2004

Ileopsoas Injury in Dogs
Q. Cabon - Compendium: Continuing Ed for Vet - 2013

Evaluation of Iliopsoas Strain with Findings from Diagnostic Musculoskeletal Ultrasound in Agility Performance Canines -73 cases
R.E. Cullen - 2017 -Vet Evidence Online

CASE EXAMPLE

Golden retriever - Male 3 years of age

Acute onset of lameness

No Trauma!

Difficulty in standing up

Reluctant to climb stairs or jump

External Rotation of the hip when sitting

Pain during hip extension and internal rotation of the limb

CASE EXAMPLE

Airdale - Male 5 years of age

Acute lameness

Difficulty in standing up

Sitting with extended and externally rotated limb

CASE EXAMPLE

Rottweiler - Female - 2 years of age

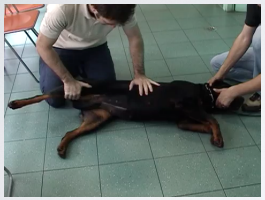

Pain hip extension Pain at palpation

RADIOGRAPHIC FINDINGS

Generally inconsistent

Rarely calcification in the insertion

TREATMENT

Complete rest for 7 to 15 days

NSAID

Gradual reintroduction to controlled activity

Physiotherapy modalities

Return to activity in 2 to 3 months

Tendency to reoccur

Surgery?

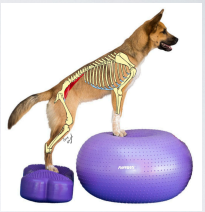

MYOPATHY OF GRACILIS/SEMITENDINOUS M.

Anatomy

Origin: pelvic symphysis

Insertion: cranial border of the tibia and with Semitendinous on tuber calcanei

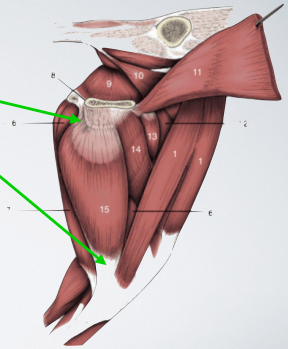

Gracilis - Functions

Actions: abduction of the limb, stifle flexion, hip and hock extension

Innervation: Obturatory nerve



Fibrotic myopathy of the gracilis, semimembranosus, and/or semitendinosus muscles - Clinical Signs

Patognomonic Lameness:

Gait pattern with a shortened stride, rapid elastic medial rotation of the paw, external rotation of the hock, and internal rotation of the stifle during mid- to late-swing phase of the stride.

The lameness might be more noticeable at a trot.

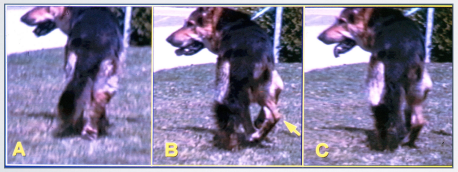

"Jerky Gate"

Fibrotic myopathy of the gracilis, semimembranosus, and/or semitendinosus muscles - Clinical Examination Findings

On physical examination, a taut band can be palpated, depending on which muscle is affected. Pain may or may not be noticed on muscle palpation.

Joint range of motion is expected to be decreased during hip abduction, stifle extension, and tarsal extension

Fibrotic myopathy of the gracilis, semimembranosus, and/or semitendinosus muscles - Epidemiology

Onset of symptoms: from 8 months to 9 years of age

Average: 5 years of age

Bilateral: 20%; 22%; 39%.

Gracilis vs Semitendinous: 17/1; 9/0; 25/6.

German Shep. affected breed 66/90%

Other reported breeds: Belgian Shep.- S. Bernard - Doberman- English Setter - German Pointer - Boxer.

Fibrotic myopathy of the gracilis, semimembranosus, and/or semitendinosus muscles - Aetiology

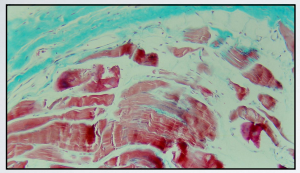

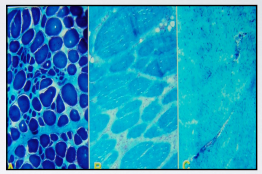

Unknown
Hypothesis: Trauma, micro-trauma, hyperactivity
Immuno-mediate myopaty
Vascular: arterial occlusion (Congenital Torcicollis H.)

CASE EXAMPLE

GERMAN SHEPHERD -FEMALE -4Y.

Subtle onset of lameness
No history of trauma
Intollerant to activity
Abnormal gate

Cording of the Gracilis from origin to insertion
Muscle waste
No pain

Diagnistics

X-Ray - not relevant
Ultrasound- diagnostic

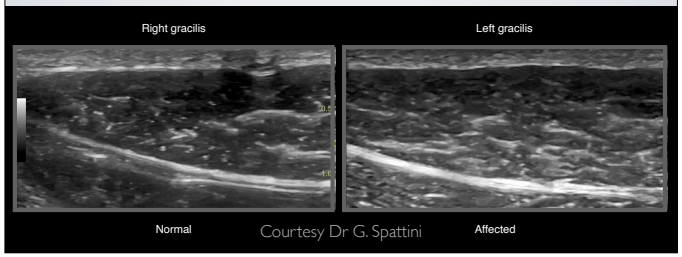

Fibrotic myopathy of the gracilis, semimembranosus, and/or semitendinosus muscles - Treatment

Tenotomy
Tenectomy

Miotomy
Total Miectomy

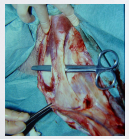

Fibrotic myopathy of the gracilis, semimembranosus, and/or semitendinosus muscles - Prognosis

Immediate resolution of the lameness
Gradual reappearance of the synthoms, 6 weeks to 5 months
(Average 2.5 Months)

Fibrosis of the caudo lateral margin

Semitendinosus myopathy and treatment with adipose-derived stem cells in working German shepherd police dogs
Melissa A. Gibson, S. Gary Brown, Nancy O. Brown
CVJ / VOL 58 / MARCH 2017

This study demonstrated that semitendinosus myopathy treated with adipose-derived MSCs can improve, or help prevent progression, of the career-ending fibrosis and muscle contracture that occurs with this pathology. Initial diagnosis of semitendinosus myopathy is easily confirmed by ultrasound examination, and falciform adipose tissue can be collected under a short anesthetic procedure at the time of initial ultrasound examination. All 9 affected dogs returned to active police duty with no restrictions and continued on active duty until their retirement or demise from unrelated diseases

DIFFERENTIAL DIAGNOSIS

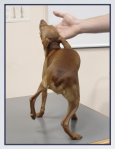

Traumatic contracture in small breeds

Courtesy of Dr M. Petazzoni

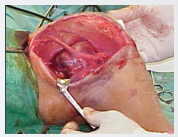

Muscle neoplasia

SELECTED MUSCULO-TENDINOUS INJURIES



MECHANISM OF MUSCLE INJURY

Strain : longitudinal stretching and tearing of muscle fibers, partial or total muscle rupture caused by over-stretching

Fascial damage +\-

Haematoma formation +\-



Strain

Passive elongation during a powerful active contraction

Eccentric contraction

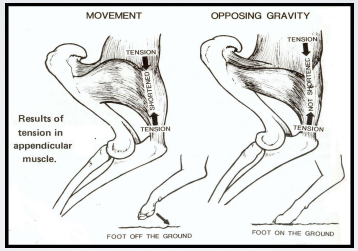

Breed/Sport Oriented Approach - BSOA

Signalment - Breed - Age - Gender - Weight - Activity

Breed/Sport Oriented Approach - BSOA

Racing Greyhound 15 months lame fore left after training - wide in the bends - pain right metatarsal III

Racing Greyhound 2 years of age, mildly lame after training - poor performances - stagger in bends - pain right hock

Border Collie Agility, 4 years, lame on hard surfaces, slowing down in times, lack of coordination in turns, prudent on the A frame, jumpy when turning, reacts to manipulation of his left paw during metatarso-phalangeal joints

Australian SD Agility, 14 months, mildly lame after rest after training, jumping push phase too close to obstacles, clips the obstacles, loses balance in tight turns on right direction, heard a cry during training in a few occasions, poor balance in A frame and wall, struggles to seat and get up with hindlimbs. Pain during extension hip and in adduction of the right limb

Malinois IPO, 3 years suddenly right hind limb lame for 36 hours after attack to sleeve, seemed ok after 48 hours but is not so motivated anymore, right hind limb adducted and mild circumduction during walk and sometimes a "cramp like" position

Breed/Sport Oriented Approach - BSOA

Malinois IPO, 3 years, right hind limb lame for 36 hours after Protection Training, seemed ok after 48 hours but lost motivation to attacks, right hind limb adducted and mild circumduction during walk, sometimes a "cramp like" position

"During the attack when he was in "lock" on the sleeve the helper swung her clockwise and is then that she cried"



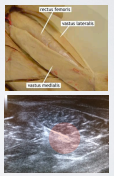

Mid-substance Tear of the Rectus Femoris

GRACILIS M.

Origin: pelvic simphysis

Insertion: cranial border of the tibia and with semitendinous on tuber calcanei

Actions: adduction of the limb, stifle flexion, hip and hock extension

Innervation: obturatory nerve

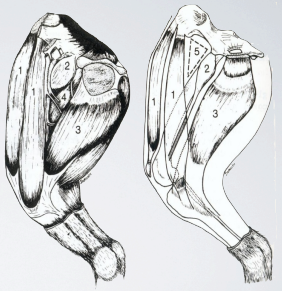

SUPERFICIAL DISSECTION

SCHEMATIC, DEEP MUSCLES REMOVED

Medial femoral muscles, medial view.

GRACILIS M. - INJURY MECHANISM

Passive elongation during active contraction

Abduction and flexion counteracted by violent adduction and extension

SUPERFICIAL DISSECTION

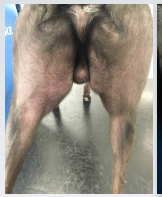

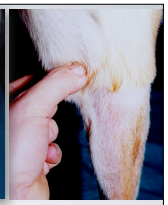

Origin

Mid-belly

Musculo-tendinous junction

TENSOR FASCIA LATAE (TFL)

Origin: Tuber Coxae and adjacent part of the Ileum, the aponeurosis of the middle Gluteal Muscle

Insertion: The lateral femoral fascia

Action: To tense the fascia latae, flex the hip and extend the stifle

Innervation: Cranial Gluteal Nerve

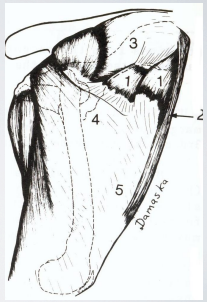

TFL - INJURY MECHANISM

Overstretch - passive elongation during contraction

Full weightbearing on one limb during rapid deceleration

TENSOR FASCIA LATAE (TFL)

Distal musculo-tendinous junction

Longitudinal fascial tear

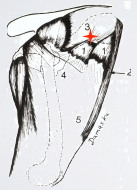

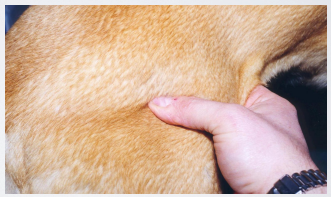

Grade III: Surgical repair

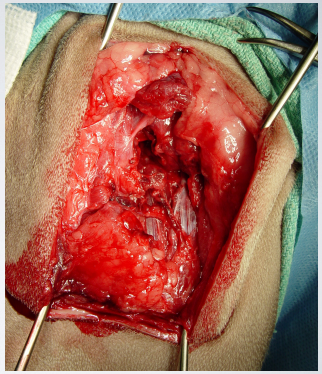

Other muscles commonly involved

Rectus Abdominis: Insertion

Gluteal muscles

Pectineus

Sartorius Muscle

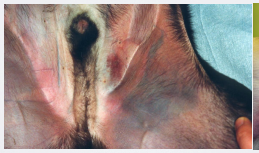



Most Common Sport Related Muscluo-Tendinous Lesions of the Hind Limb

Gastrocnemius Injuries - Superficial Digital Tendon Luxation

MSK Ultrasonography - The Hind Limb
Canine Sport Medicine Espoo - Finland 2024

Alessandro Piras
DVM - ISVS

ACHILLES' TENDON OR "CHORDA MAGNA"

Common tendon of gastrocnemious

Tendon of the superficial digital flexor m.

Common tendons of gracilis, semitendinous, biceps fem.

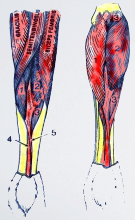

1) Gastrocnemious
2) Superficial Digital Flexor Tendon
3) Biceps fem.
4) Semitendinous
5) Gracilis
6) Common calcaneal tendon

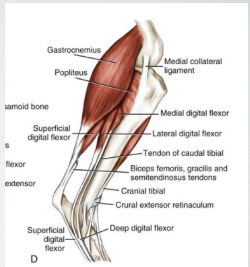

ACHILLES' TENDON OR "CHORDA MAGNA"

Frequent cause of acute lameness
All breeds
Frequent cause of chronic lameness
Working dogs: hunting, field trial, agility, racing

COMMON SITE OF INJURIES

origin: caudolateral femur
mid muscle
musculotendinous junction
mid tendon
calcaneal insertion

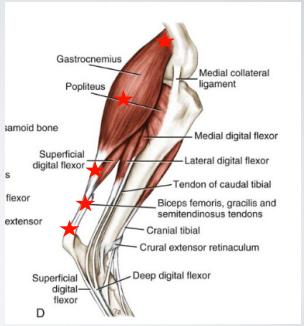

ACHILLES' TENDON OR "CHORDA MAGNA"

ETHIOPATOGENESIS

Acute traumatic: Bite, cut wound, falling from height

Chronic: Degenerative by chronic strain, often bilateral

The classification of the Achilles' tendon lesions: Meutstege; VCOT, 6:53-5, 1993

Type 1- 2 - 3

COMPLETE RUPTURE: TYPE 1

Complete rupture of all components

Extended stifle, flexed hock, plantigrade stance

Palpable gap

No phalangeal hyperflexion

PARTIAL RUPTURE: TYPE 2 A

Musculotendinous junction

Intact SDFT

Extended stifle, flexed hock
Palpable lesion
Variable degrees of phalangeal hyperflexion



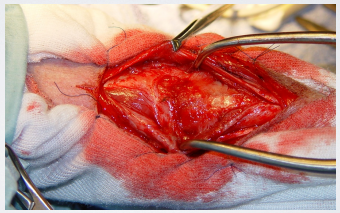

PARTIAL RUPTURE: TYPE 2 B

Intact paratenon

Intact SDFT

Extended stifle, flexed hock
Palpable lesion
Variable degrees of phalangeal hyperflexion

AVULSION: TYPE 2 C

Disinsertion from tuber calcanei

Intact SDFT

Extended stifle, flexed hock
Palpable lesion
Severe phalangeal hyperflexion

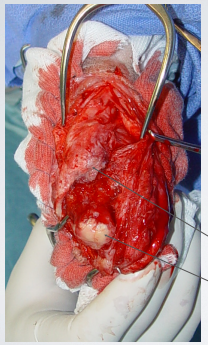

Avulsed tendon

Tuber calcanei

PARTIAL RUPTURE: TYPE 3

Tendinopathy: distal part of gastrocnemious

Normal stance
Palpable lesion
Lame after exercise

Treatment options

Conservative

- Physical therapy ?
- Custom orthosis +/- regenerative medicine ?

Surgical – which procedure?

- MT junction suture + calcaneo-ischial sling ?
- "Internal splint" ?
- Shorten distal tendon ?
- Pantarsal arthrodesis ?
- Provisional Arthrodesis (A. Boero - L.Vezzoni)

Treatment options



Do on't do anything:

Conservative treatment and full forced rest + confinement for at least 8 weeks

"Treatment suggested by Dirsko J.F. von Pfeil based on his experience on Iditarod sledge dogs"

Gastrocnemius: Musculotendinous Junction Tear

© Dirsko von Pfeil

	Signalment	Body weight	Function
1	5yo FS Alaskan Husky	17.0kg	Sledding - competitive
2	5yo MN Alaskan Husky	19.2kg	Sledding - competitive
3	2yo M Alaskan Husky	22.4kg	Sledding - competitive
4	6yo F Alaskan Husky	17.0kg	Sledding - competitive
5	7yo MN Irish Setter	31.1kg	Bird hunting
6	9yo FS Golden Retriever	32.0kg	Companion animal
7	7yo FS Brittany Spaniel	14.4kg	Companion animal
8	9yo MN Labrador	32.0kg	Companion animal
9	8yo M Alaskan Husky	25.0kg	Sledding - competitive
10	3yo M Alaskan Husky	21.3kg	Sledding - touring

Dog	Complete confinement	Partial confinement	Length of time before return to normal occupation	External coaptation
1	6 months	2 months	8 months	None
2	3 months	2 months	6 months	None
3	8 months	None	8 months	None
4	2 months	4 months	6 months	None
5	1 month	8 months	9 months	None
6	2 weeks	4 weeks	6 weeks	Cranial fibreglass cast for 2 weeks; padded bandage for a further 4 weeks
7	5 weeks	2 weeks	7 weeks	Fibreglass cast for 5 weeks; padded bandage for a further 2 weeks
8	4 weeks	2 weeks	6 weeks	Full cast for 10 days; partial cranial cast for 3 weeks
9	8 months	None	8 months	None
10	5 months	None	5 months	Custom orthotic initially full-time, progressing to as needed for activity

Manuscript in progress: Boyd N., von Pfeil D.

Small Animal Surgery Locum

Other treatment Options

© Dirsko von Pfeil

Stem Cells

Orthosis

Closed or open toe?

Strap position?

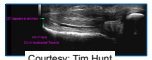

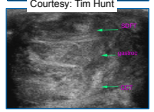

Courtesy: Tim Hunt

Courtesy: Tim Hunt

Courtesy: Chris Freye

Veterinary Surgery 42 (2013) 355–360

Gastrocnemius Tendon Strain in a Dog Treated With Autologous Mesenchymal Stem Cells and a Custom Orthosis

J. Brad Case, DVM, MS, DACVS, Ross Palmer, DVM, MS, Diplomate ACVS, Alex Valdes-Martinez, DVM, Diplomate ACVR, Erick L. Egger, DVM, Diplomate ACVS, and Kevin K. Haussler, DVM, DC, PhD, Diplomate ACVSMR

Figure 2 Custom, progressive, dynamic, orthosis Gradual extension of talocrural joint. At 140 days paw segment removed.

Small Animal Surgery Locum

SDFT LUXATION - EPIDEMIOLOGY

Uncommon orthopaedic condition

Mostly reported in: Collie and Sheltie Sheepdogs, Eastern Siberian Laika, Jamthund Jamtlannin Spitz, Siberian Husky, Border Collie, Greyhound

Rainio, Hughannan - 1993
Houseree, Prata; - 1993

No Gender Predisposition

Transmitted as an autosomal recessive condition

Salanti - 2002

SDFT LUXATION - ANATOMY

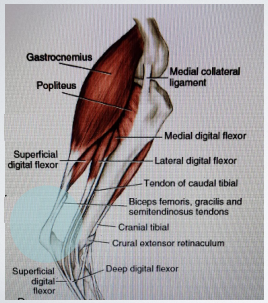

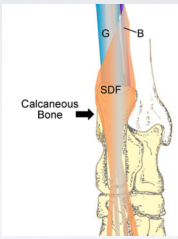

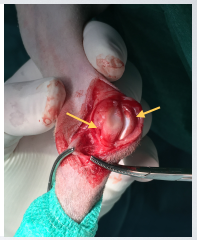

SDFT LUXATION - AETIOLOGY

Unknown

Predisposing factors:

Repetitive micro-trauma - Excessive early physical activity
Frequently reported in agility and sporting dogs

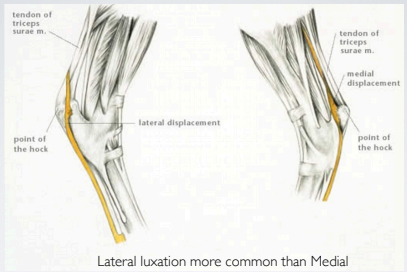

Lateral luxation more common than Medial

Lateral insertion of the tendon being stronger and more pronounced than the medial insertion predisposes to its lateral displacement

SDFT LUXATION - AETIOLOGY

Forces acting during vigorous activity that displace the tendon at its crossing point over the tuber calcanei.

Change of the angulation between the calcaneus, insertion and origin points of the muscle in flexed hind limb

+ - associated with incompetence of the SDFT reticular mechanism

SDFT LUXATION - AETIOLOGY

Calcaneal Dysplasia

A - Calcaneus is narrow and with a shallow grove

B - Calcaneus is broad and with a competent grove

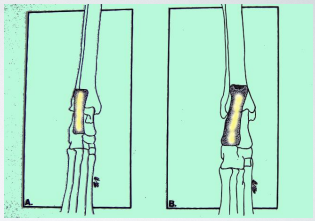

Reinke JD, MughannamAJ. (1993) Lateral luxation of the superficial digital flexor tendon in 12 dogs

ournal of the American Animal Hospital Association; 29: 303–309.

SDFT LUXATION - HISTORY

Usually no history of trauma

Acute lameness after intense exercise with no weight bearing for few hours

Intermittent lameness after exercise frequently reported

Mild constant lameness during walking frequently reported as "strange gate"

SDFT LUXATION - CLINICAL EXAMINATION

Variable degrees of swelling affecting the tuber calcanei region

Palpable effusion - Medial or Lateral luxation

Early presentation: SDF luxates easily - generally reduced but unstable in extension - Luxated in flexion

Chronic presentation: SDF is stable in luxated position and doesn't reduces

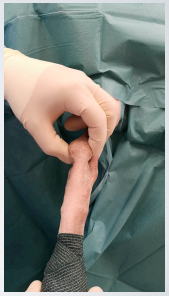

SDFT LUXATION - CLINICAL EXAMINATION

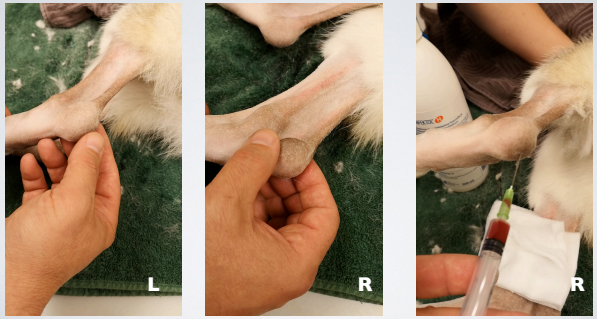

SDFT LUXATION - DIAGNOSTIC IMAGING

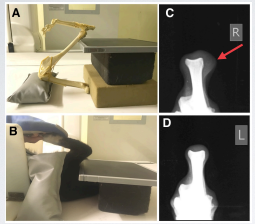

Sky-line view of the tarsus.
Image C shows the calcaneal groove and soft tissue opacity on the lateral side of the calcaneus, indicative of lateral luxation of SDFT in the right tarsus (arrow). In the left tarsus (D) the SDFT appears correctly located into the calcaneal groove

ML view showing increased soft tissue opacity at the level of calcaneal tuberosity (arrow)
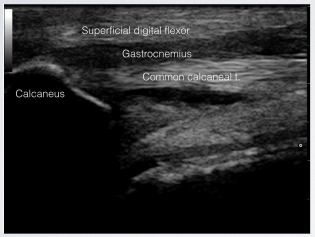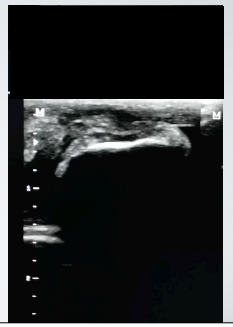
SDFT LUXATION - DIAGNOSTIC IMAGING