

Torsione, dilatazione,
congestione o
occlusione gastrica?
Che ruolo rimane alla
ecografia?



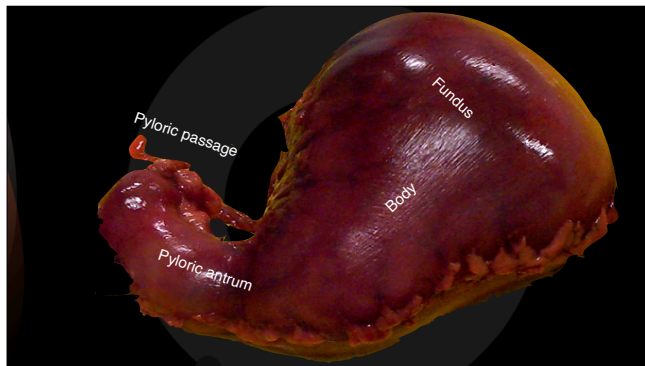
Diagnostic Mindset

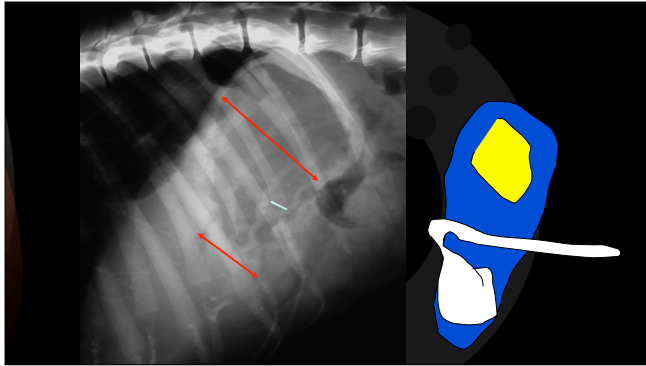
Thanks to Clinica Veterinaria Castellarano

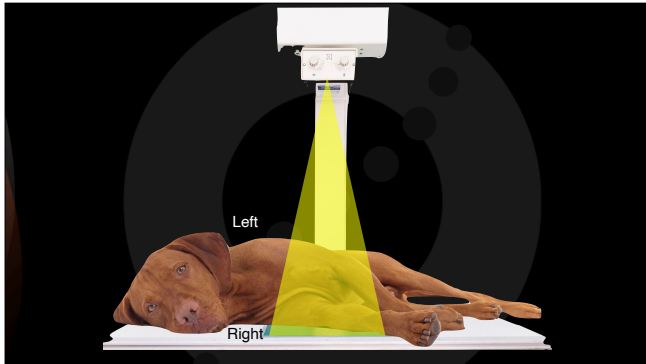
Giliola Spattini
DVM, PhD, DECVI

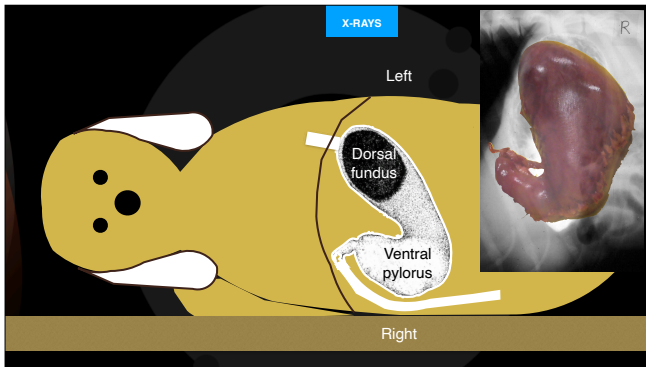
Objectives

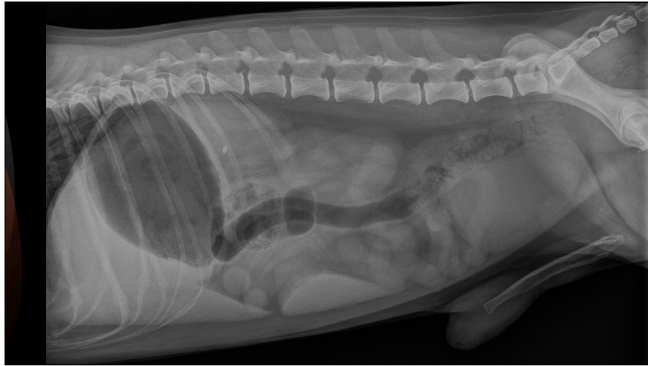
- Gastric dilatation, torsion, congestion or chronic sub-occlusion can be a diagnostic challenge
- This lecture wants to provide key points for a quick and correct diagnosis

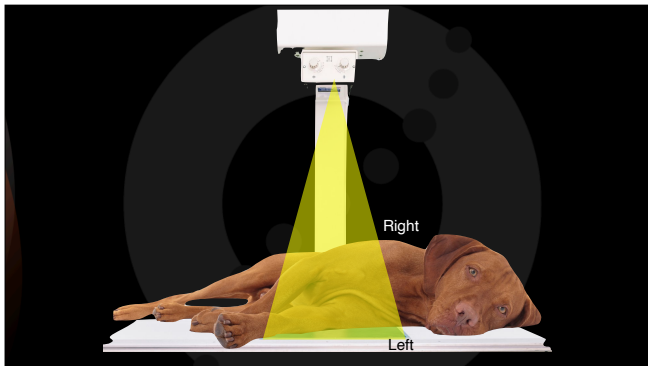


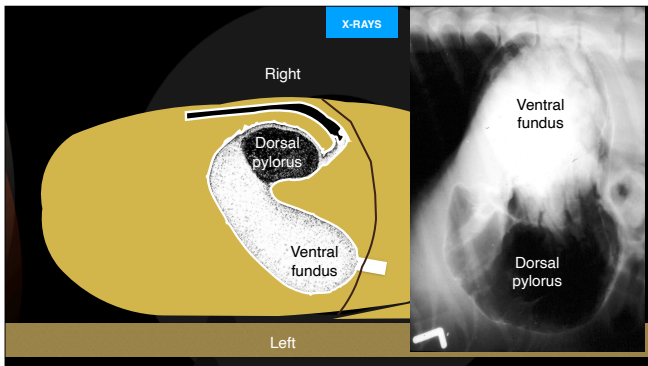


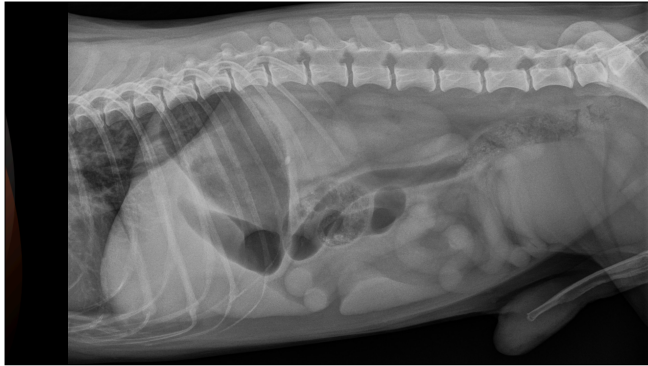

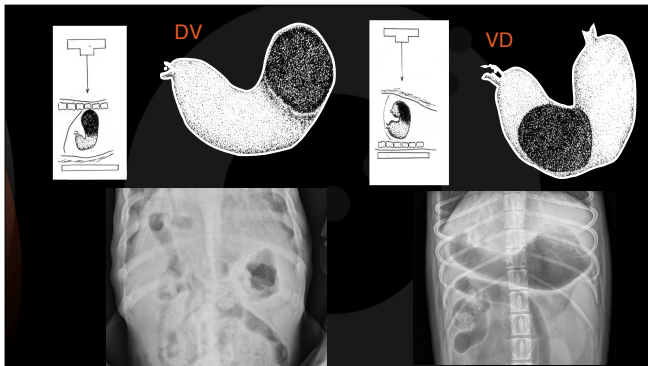


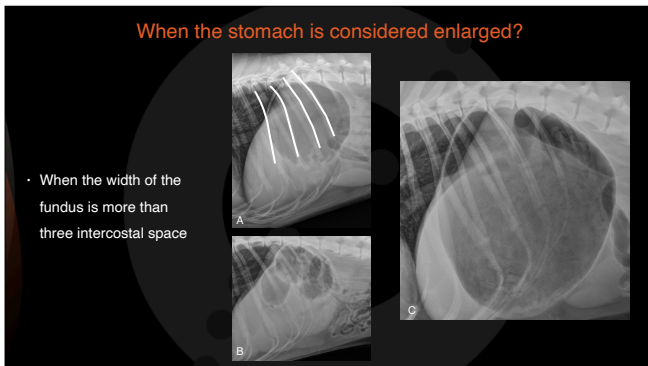






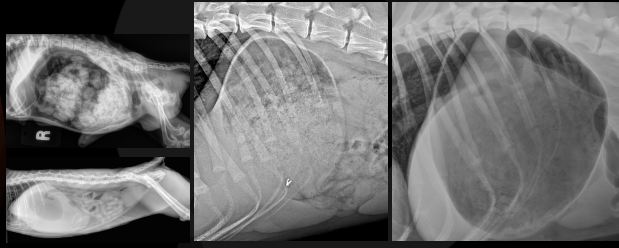






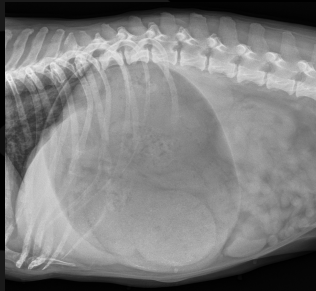
Does the gastric content matters?

- Gas
 - Dilatation or Volvulus
- Fluid
 - Sub-occlusion or severe gastritis
- Granular material
 - Gastric congestion



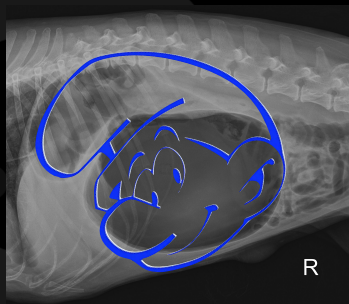
How to check for a gastric volvulus

- The fundus is dorsal and to the left?
- The pylorus is ventral and to the right?



How to check for a gastric volvulus

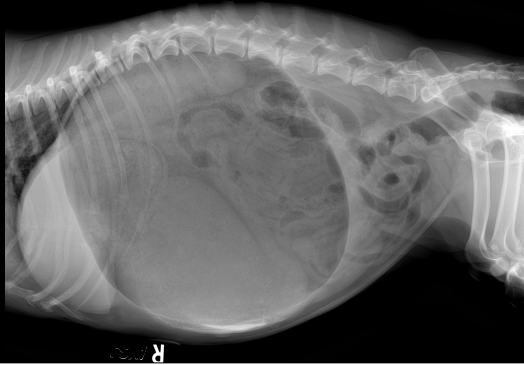- Is the fundus dorsal and to the left?
- Is the pylorus ventral and to the right?
- Can you see a smurf face?



Learning check!

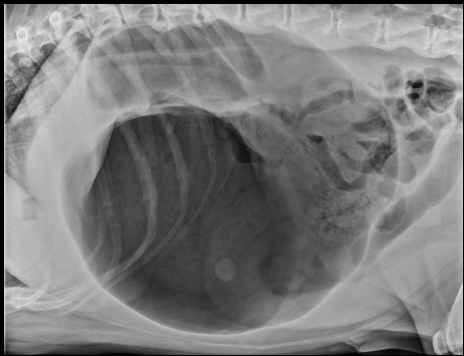CASE 1

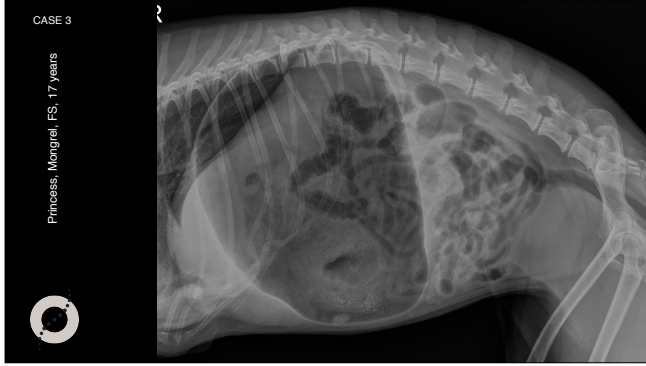
Lilly, Dachshund, FS, 15 years

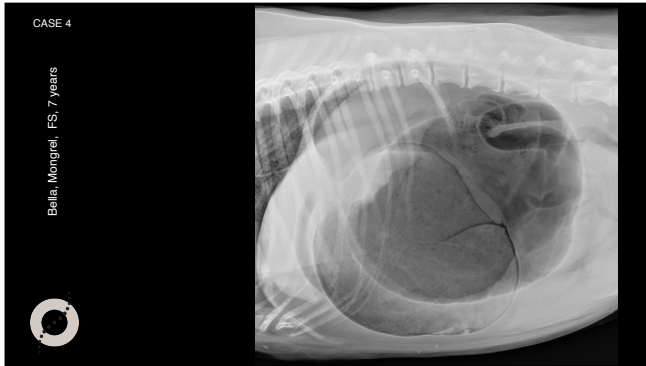


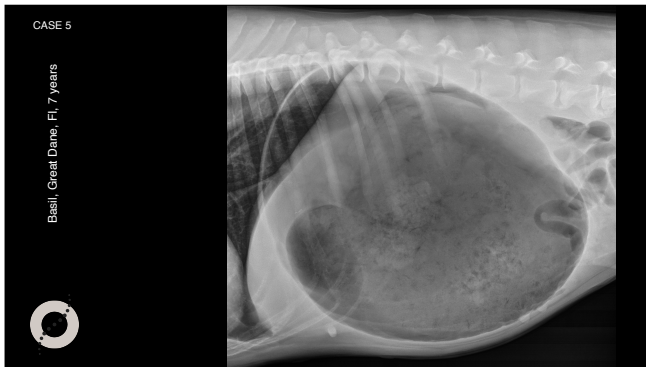
CASE 2

Tank, American SH, MN, 10 years







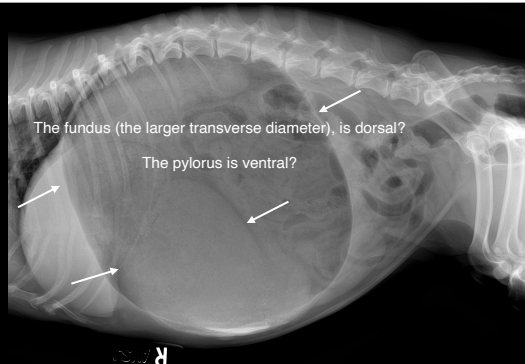


Your evaluation

- Which patient has a gastric volvulus, and which has a gastric dilatation?
- Where is the fundus, and where is the pylorus?

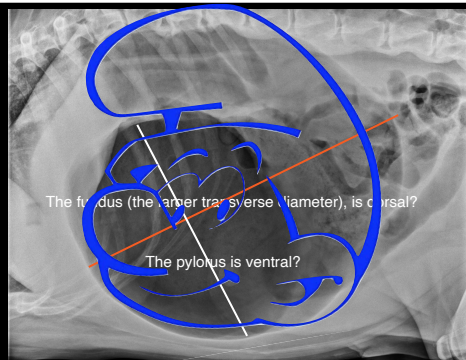
CASE 1

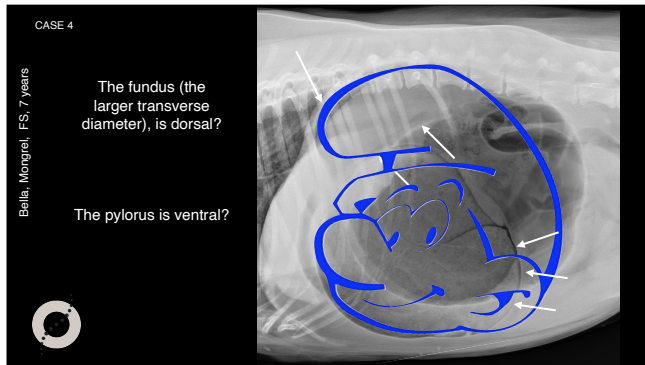
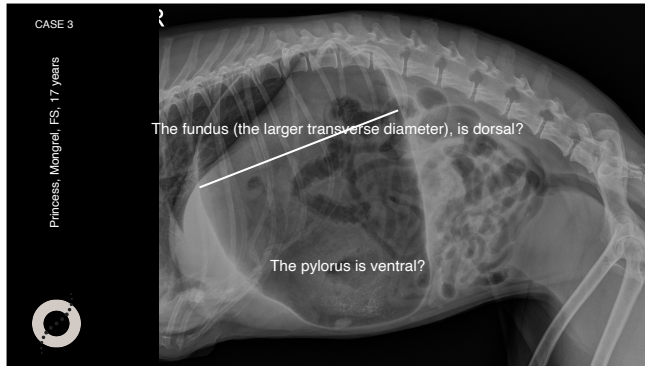
Lilly, Dachshund, FS, 15 years



CASE 2

Tank, American SH, MN, 10 years





Emerg Radiol
DOI 10.1007/s10140-016-1401-6

REVIEW ARTICLE

Vacuum phenomenon

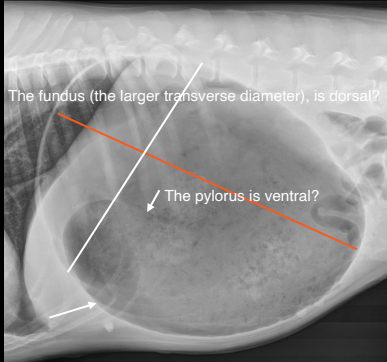
Yoshiaki Yanagawa¹ · Hiromichi Ohnaka¹ · Kei Jitsui¹ · Toshiko Yoshizawa¹ · Ikuto Takeuchi¹ · Kazuhiko Omori¹ · Yasumasa Odo¹ · Kouhei Ishikawa¹

the mechanism responsible for the formation of the VP [1]. If an enclosed tissue space is allowed to expand as a rebound phenomenon after an external impact, the volume within the enclosed space will increase. In the setting of expanding volume, the pressure within the space will decrease. The solubility of the gas in the enclosed space will decrease as the pressure of the space decreases. Decreased solubility allows a gas to leave a solution. The combination of lower nitrogen solubility and the minimal metabolism of nitrogen by the body mainly accounts for the formation of the VP. Basically, the mechanism underlying the formation of the VP is the same as cavitation induced by rotation of a ship's propeller in water, which depends on two laws of physics: Henry's Law and Boyle's Law.

Received: 17 March 2016 / Accepted: 26 April 2016
© American Society of Emergency Radiology 2016

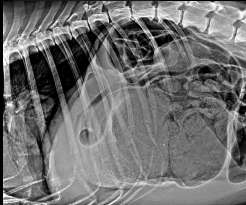
CASE 5

Basil, Great Dane, FI, 7 years



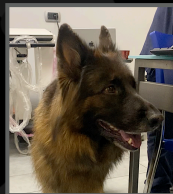Key points

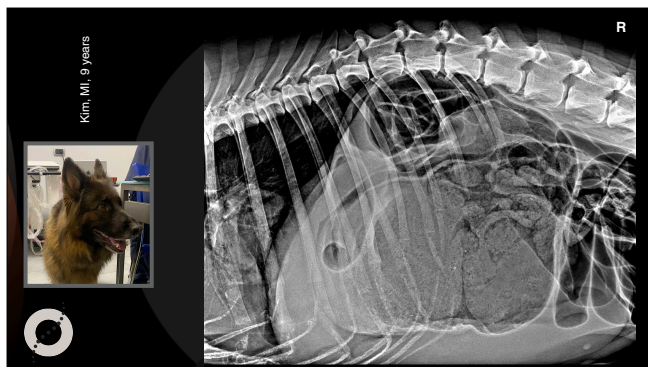
- Check the pylorus
- Check the fundus
- Smurfs face
- Check every radiographic details

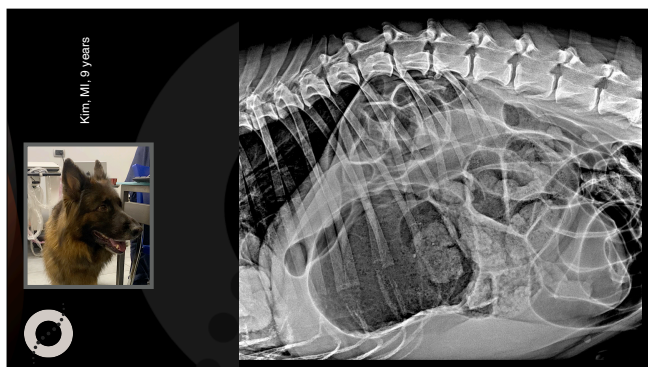


Kim, German Shepherd, MI, 9 years

- He ate more than usual
- Soon after, He started to attempt to vomit
- He seems painful
- Overdistended stomach




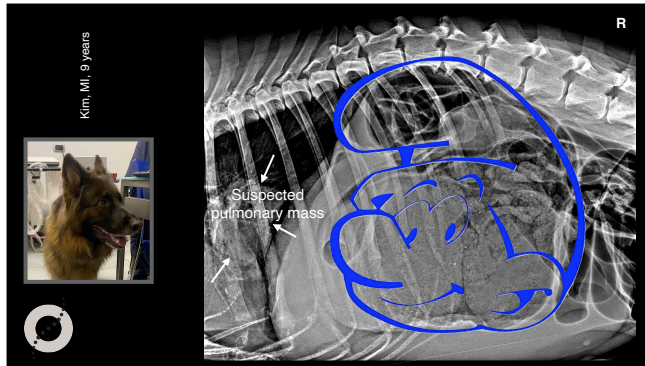


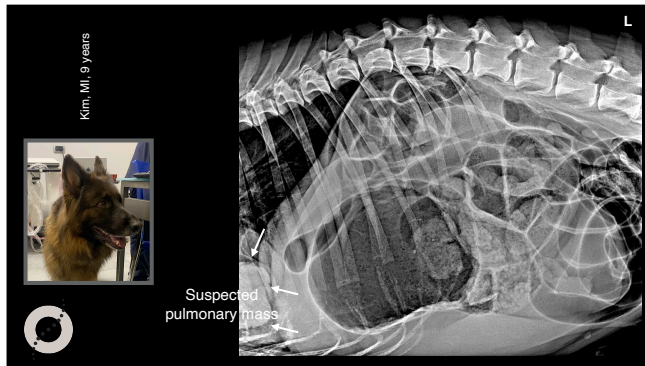


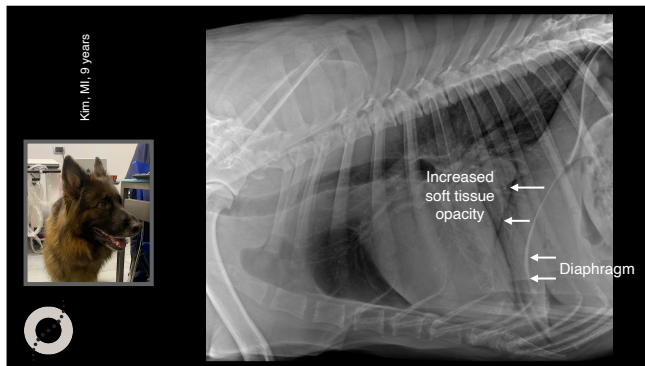
Your evaluation

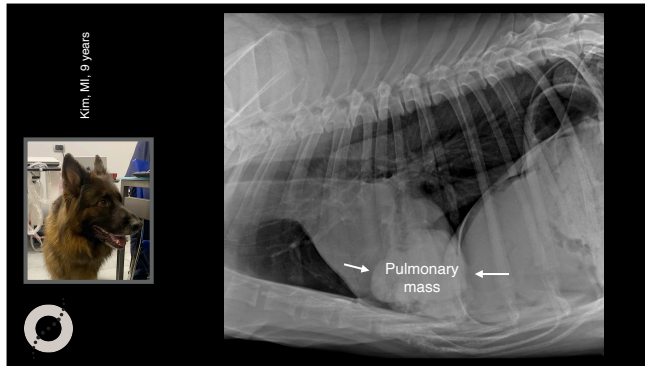
- Is there lumbar spondylosis?
- Is there gastric dilatation?
- Is there gastric volvulus?

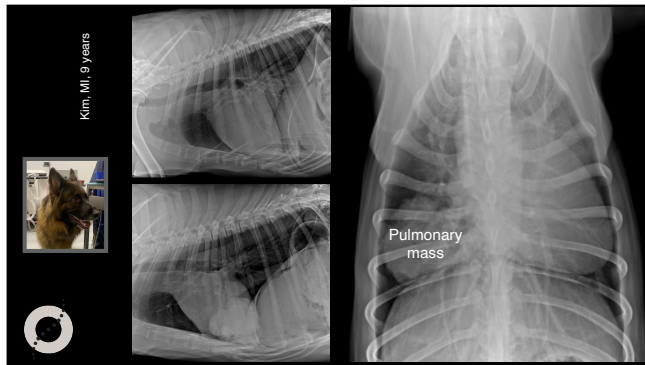


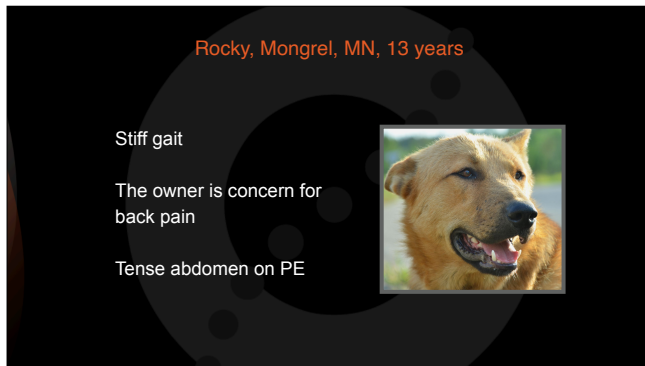

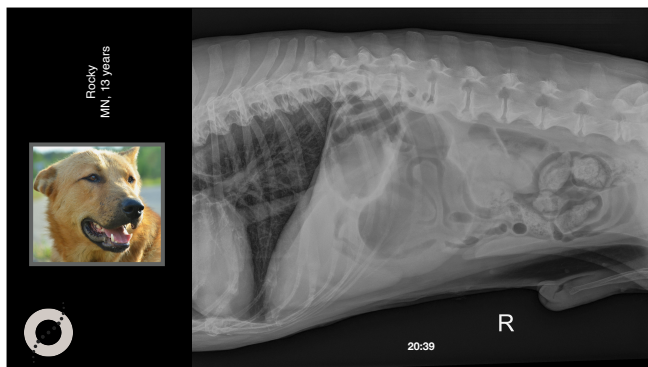


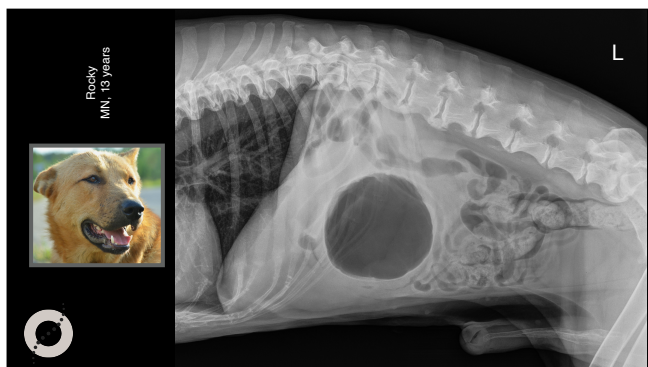



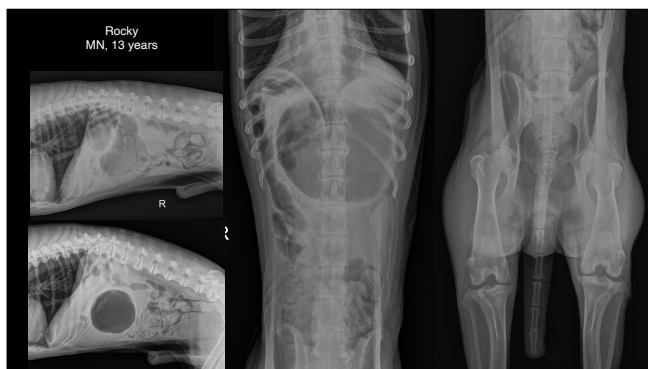










Your evaluation

- Is there gastric torsion?
- Is there gastric dilatation?
- Is there hip dysplasia?



Rocky, Mongrel, MN, 13 years

Radiographic diagnoses:

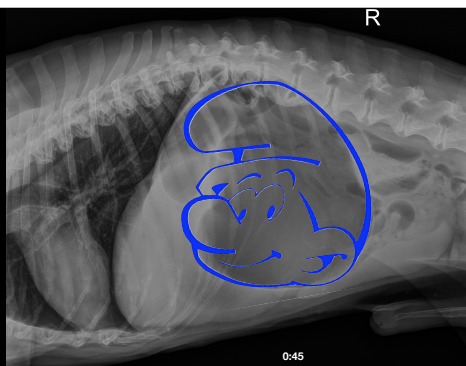
- Multiple sites of chronic thoracolumbar spondylosis
- Ventral displacement of the fundus
- Dorsal displacement of the pylorus

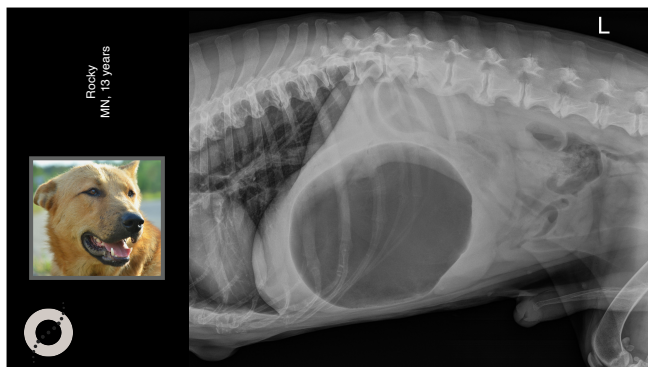


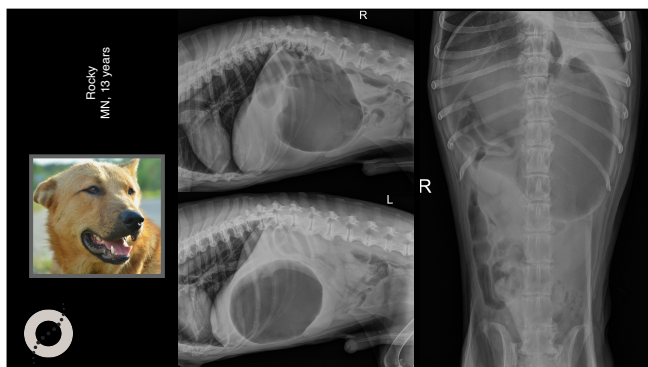
Rocky
MN, 13 years

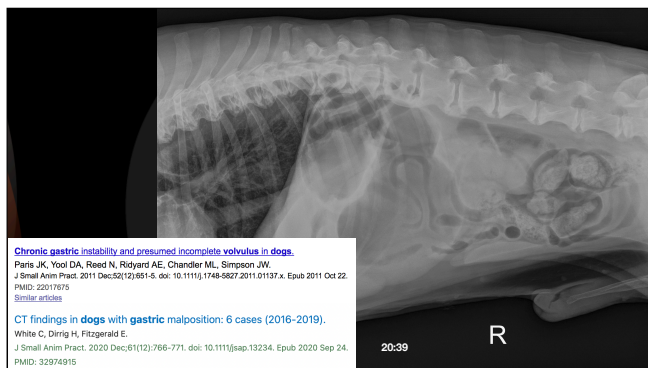Sialorrhea

Distended abdomen









Principessa, English Bulldog, FI, 12 years

- Severe vomiting for the last two months

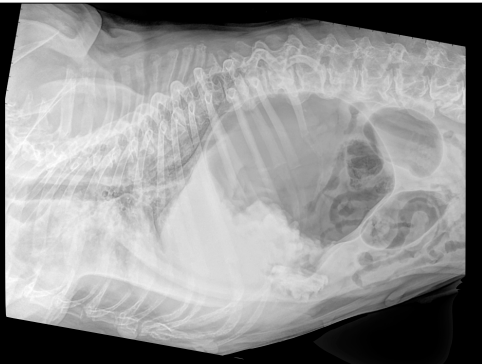Severe weight loss

Suspected gastric mass on first ultrasonographic consultation

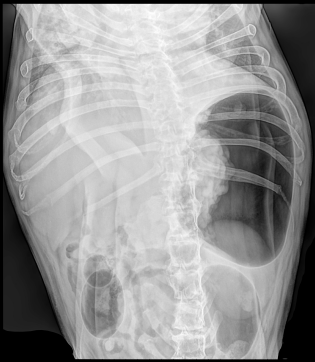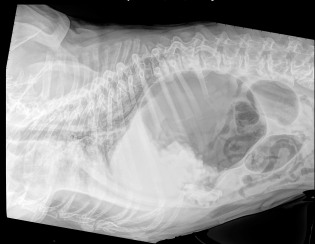Second ultrasonographer didn't find the suspected mass



Principessa, FI, 12 years



Principessa, FI, 12 years

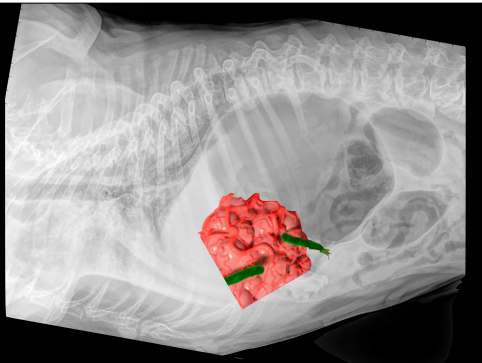


Your evaluation

- Is there pneumonia?
- Is there a gastric FB?
- Is there a gastric mass?

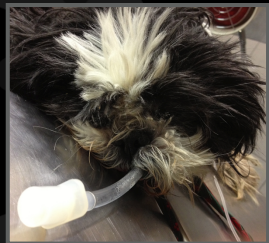

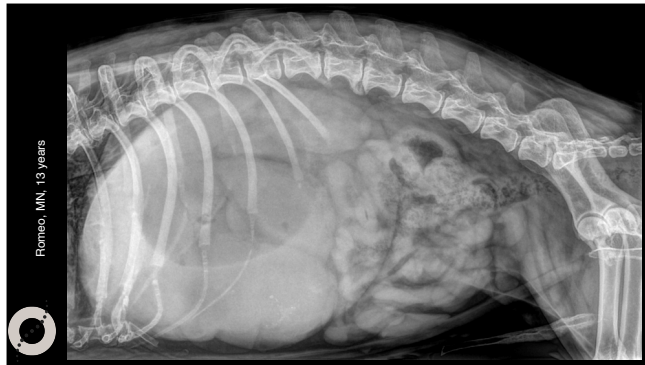
Principessa, FI, 12 years

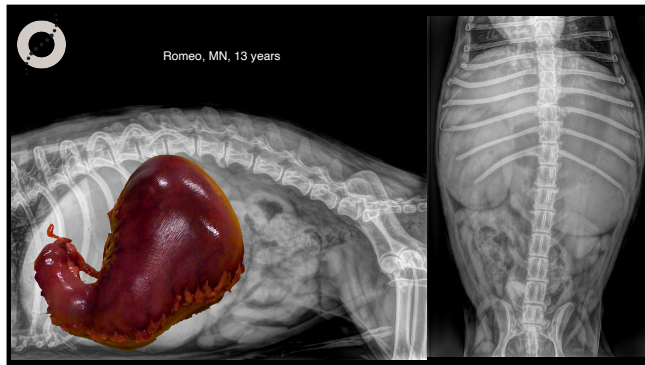


Romeo, Shitzu, MN, 13 years

- Chronically vomiting twice weekly
- Now worsening
- Still eating







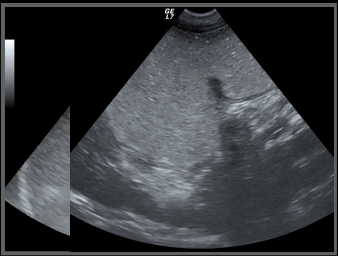
Your evaluation

- Is there gastric dilatation?
- Is there a gastric torsion?
- Is there a gastric FB?



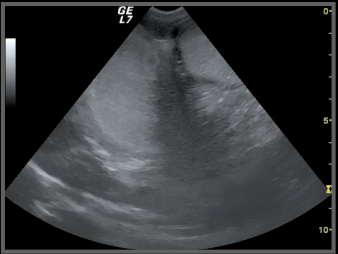
Romeo, MN, 13 years

Probe position in a different patient



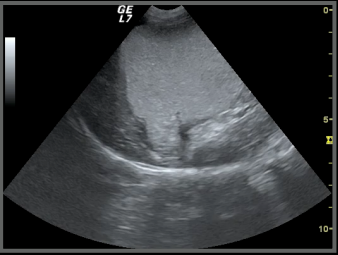
Romeo, MN, 13 years

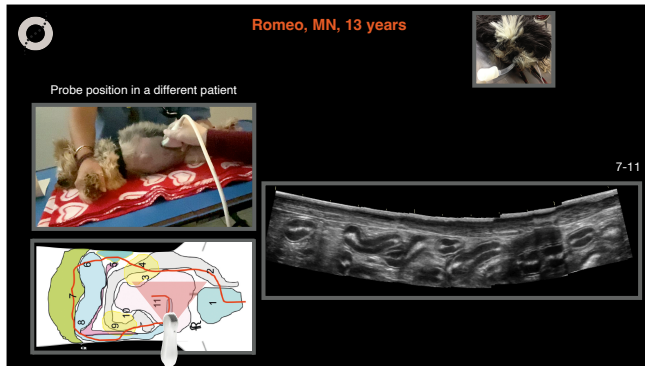
Probe position in a different patient

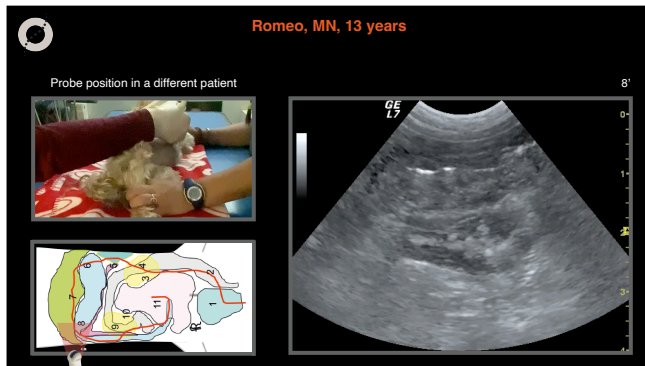


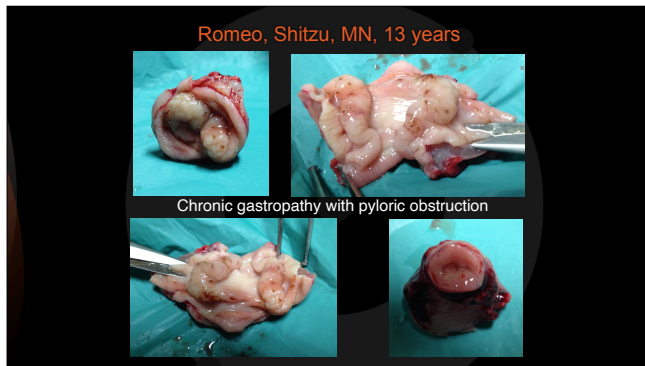Romeo, MN, 13 years

Probe position in a different patient



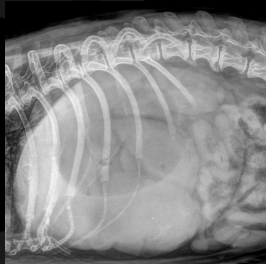





Key points for chronic pyloric subocclusion

- Enlarged and rounded pyloric antrum
- Fluid more than gas filled
- Gravel sign

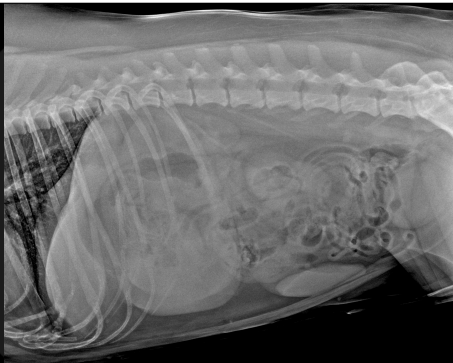


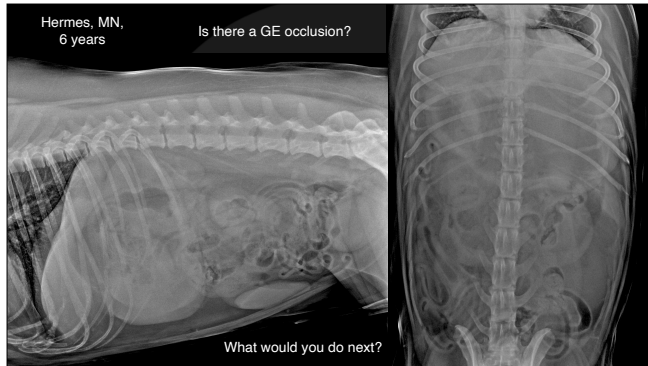
Hermes, Australian Shepherd, MN, 6 years

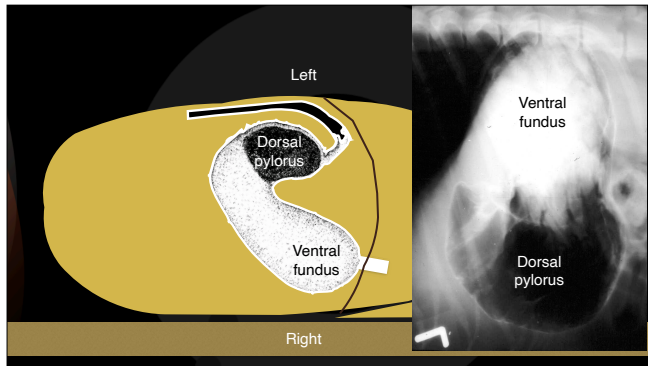
- Vomiting for three days
- Reduced appetite
- Drinks but then vomits bile

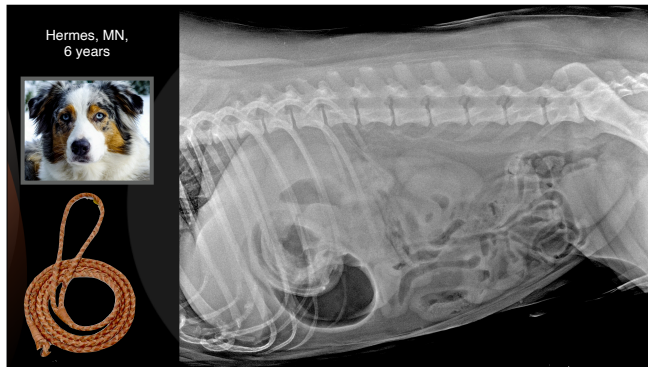


Hermes, MN,
6 years









Thank you



Diagnostic Mindset

www.diagnosticmindset.com
