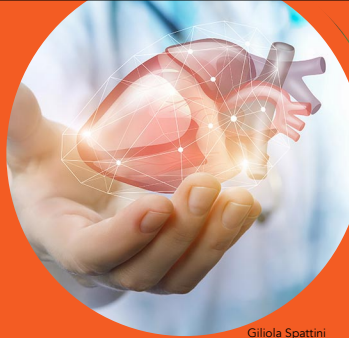

Come interpretare uno scompenso cardiaco sinistro nel cane



Diagnostic Mindset



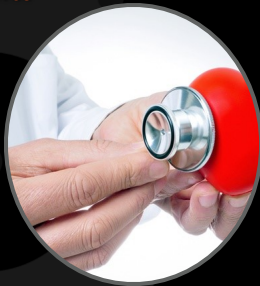Giliola Spattini
DVM, PhD, DECVDI

Objectives

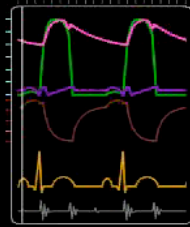
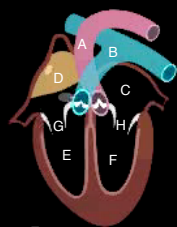
Introduction to Cardiac Physiology

Essential cardiac measurements

Cardiomegaly and left heart failure



Check the anatomy of the heart



A
B
C
D

E
F
G
H

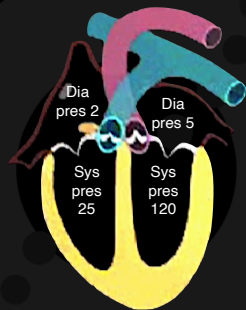
How many cardiac phases do you know?

Systole

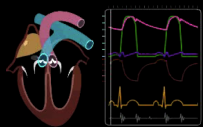
Diastole

Isovolumetric
contraction

Isovolumetric
relaxation

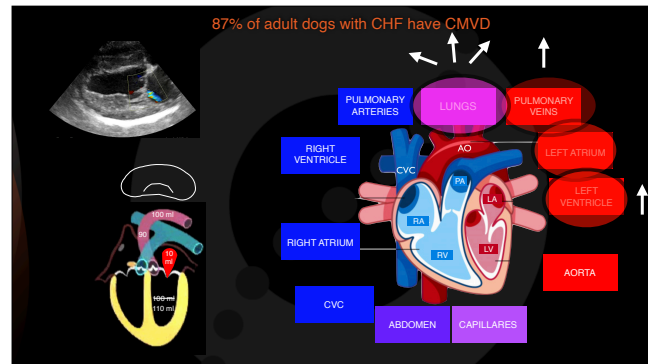


Diastole



What is the cardiac main function?

To maintain the cardiac output



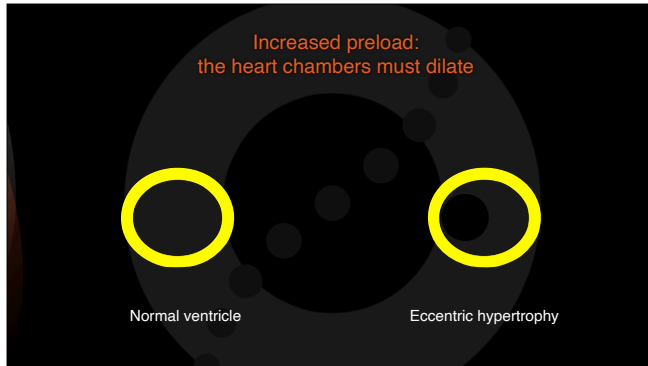
How does cardiac contraction behave if the volume of blood to be injected increases?

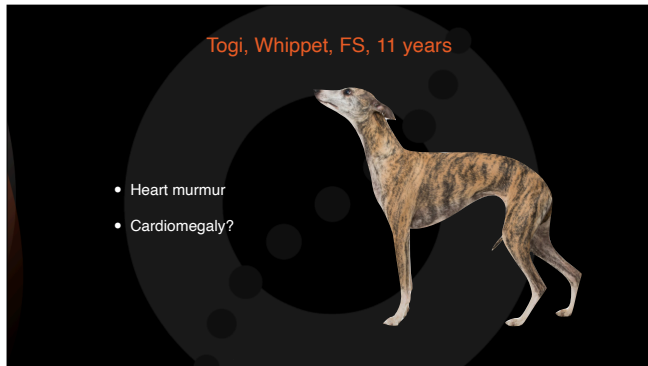STARLING'S LAW

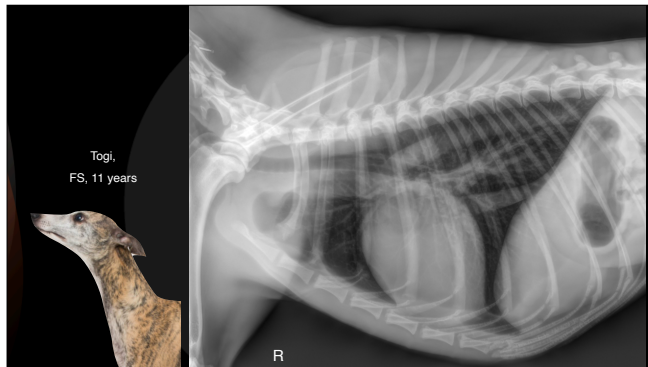
If the volume of blood in the ventricle increases, then the contractile force of the myocardium will increase.

If the sarcomeres are less elongated, myocardial contraction will decrease.



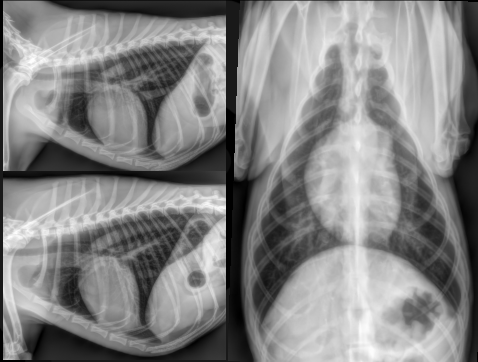




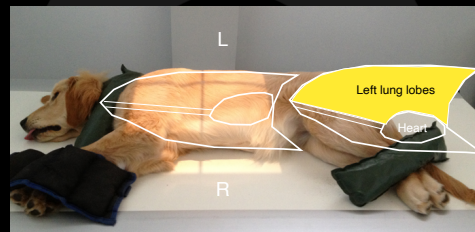


Which projection to check for size?

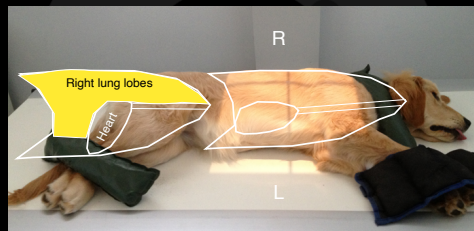
1. RLR
2. LLR
3. DV



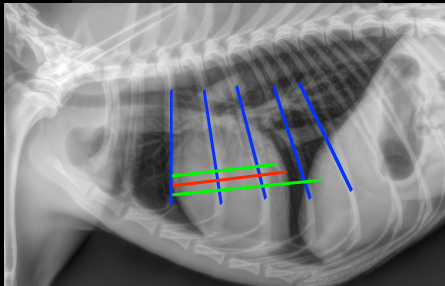
What happens when I put the patient in right lateral recumbency?



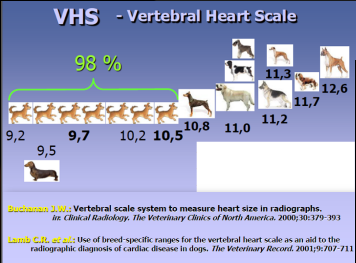
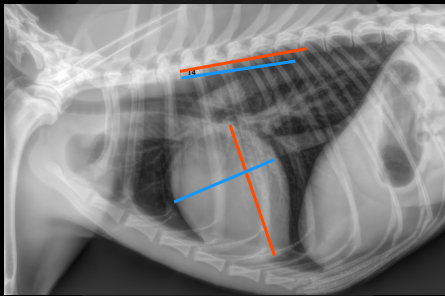
What happens when I put the patient in left lateral recumbency?



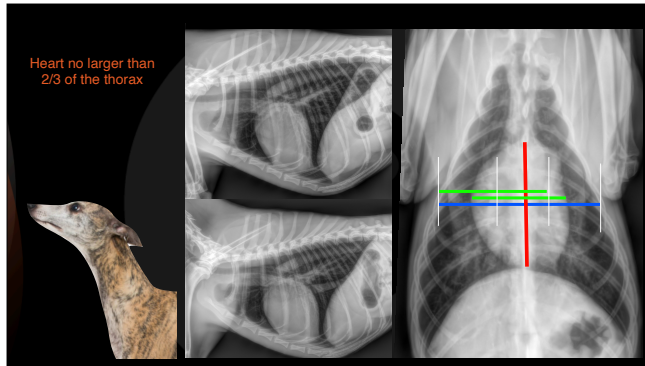
Size: between 2.5 and 3.5 intercostal spaces

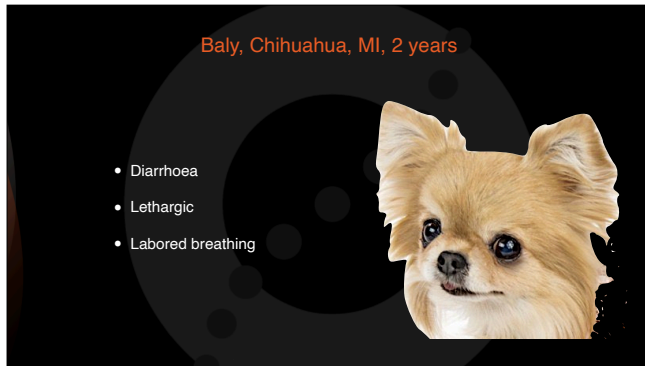


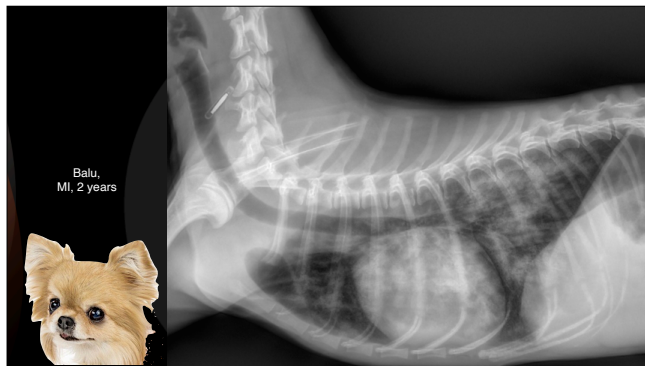
VHS 5,2 + 4,8



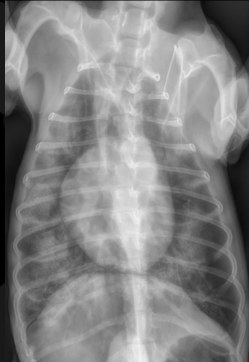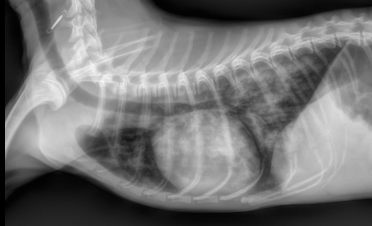Media nel cane	9.7 +/- 0.5	8.5 - 10.6
Media nel gatto	7.5 +/- 0.5	7.3 +/- 0.5
York shire	> 10.4	83% cardiomegala
Kavalier King C.	> 11.1	79%
Doberman	> 10.5	68%
Labrador	> 10.9	66%
Boxer	> 11.6	58%
Past Tedesco	> 10.2	75%
Greyhound	10.5 +/- 0.1	
Rottweiler	9.8 +/- 0.2	
Whippet	> 11.0	



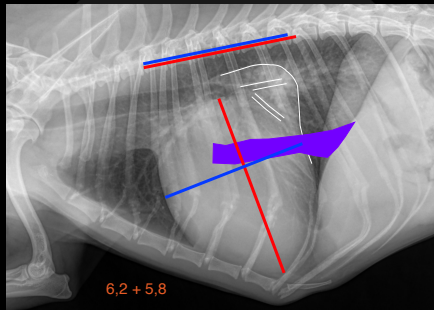




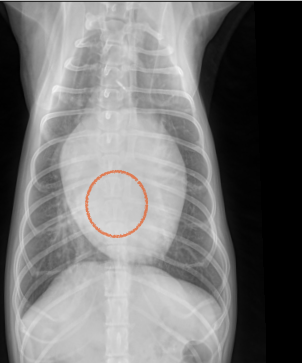
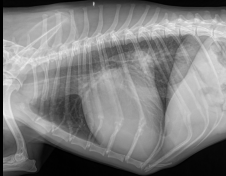
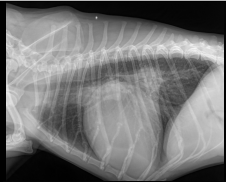
Is the cardiac silhouette increased in volume?



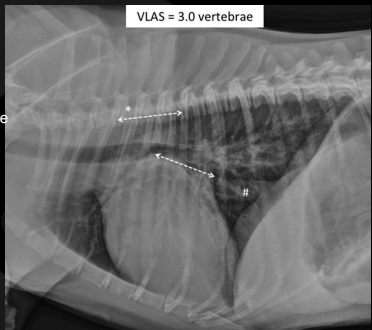
Radiographic signs of left heart enlargement



6,2 + 5,8

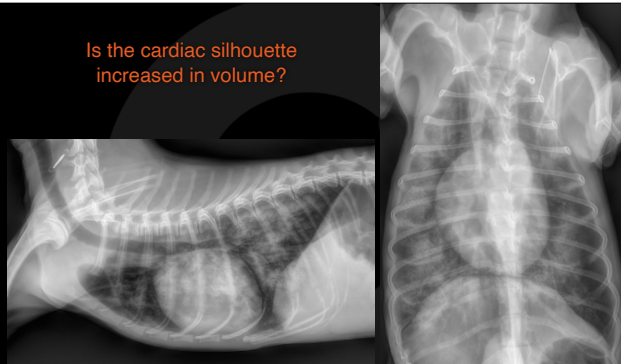


- 1) Line from the centre of the ventral margin of the hull to the dorsal margin of the CVC
- 2) The same line is carried from the cranial margin of T4
- 3) Increased atrium if VLAS > 2.3



J. Am. Vet. Med. Assoc. 2018; Oct 15; 253(10):1038-1041. doi: 10.2460/javma.253.8.1038.
Diagnostic value of vertebral left atrial size as determined from thoracic radiographs for assessment of left atrial size in dogs with myxomatous mitral valve disease
Elizabeth L. Makiuchi, Lauren C. Weiss, Kathryn L. Phillips, Lyndee R. Johnson
PMID: 30272919 DOI: 10.2460/javma.253.8.1038

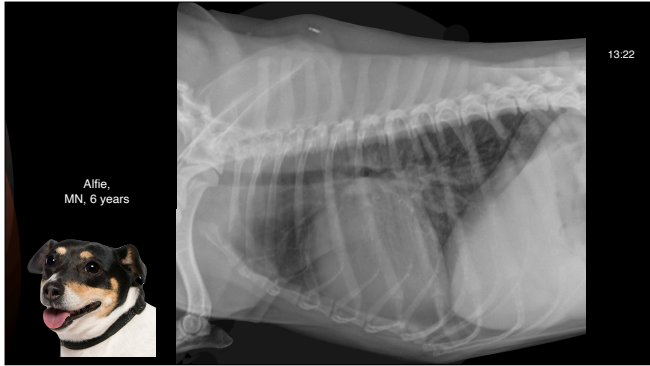Is the cardiac silhouette increased in volume?

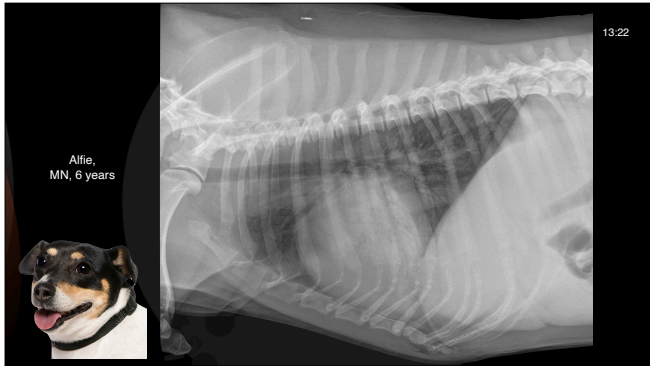


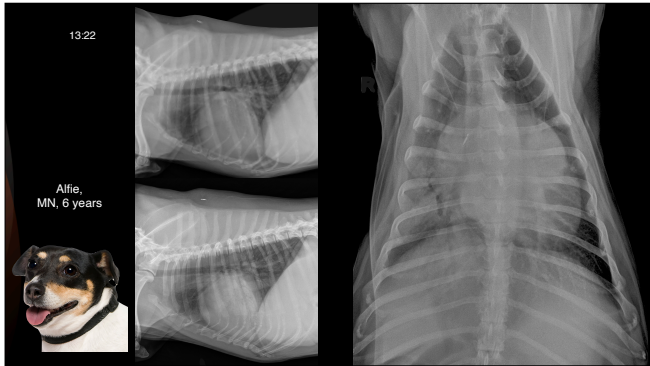
Alfie, Mongrel, MN, 6 years

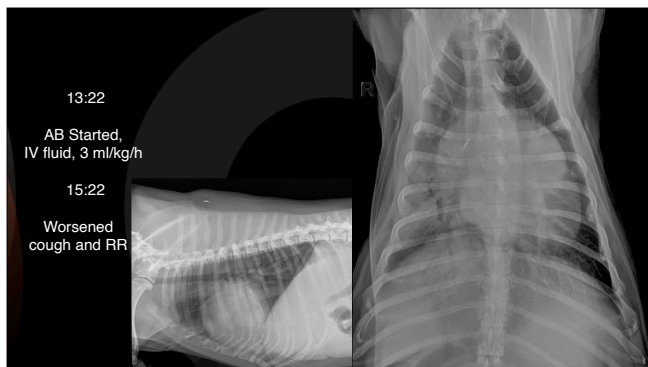
- Panting for two days
- Exercise intolerance
- Coughing
- 4/6 heart murmur
- Vomiting and not eating

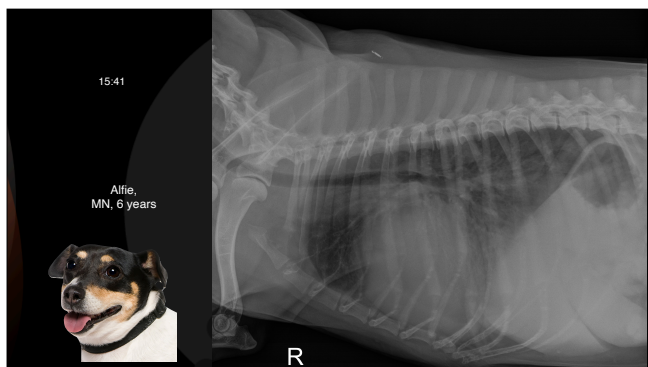


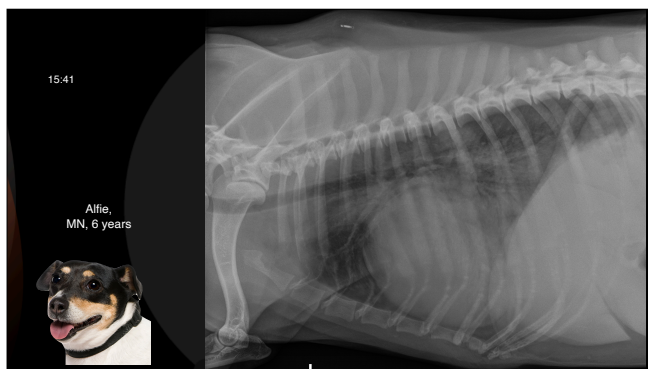


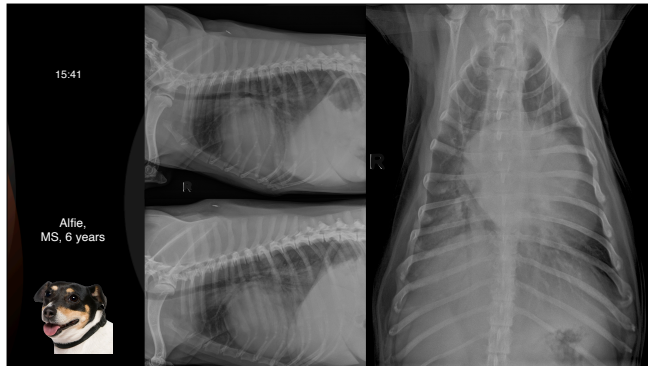


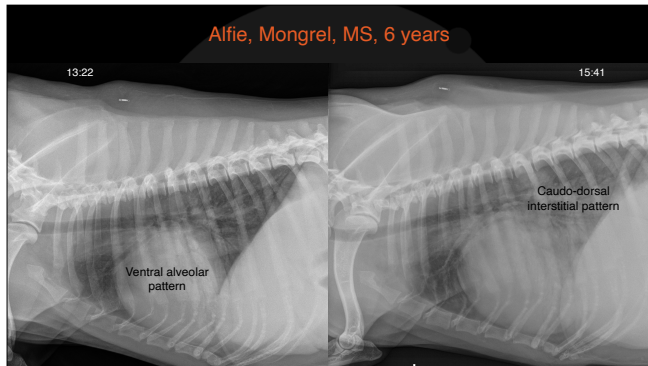


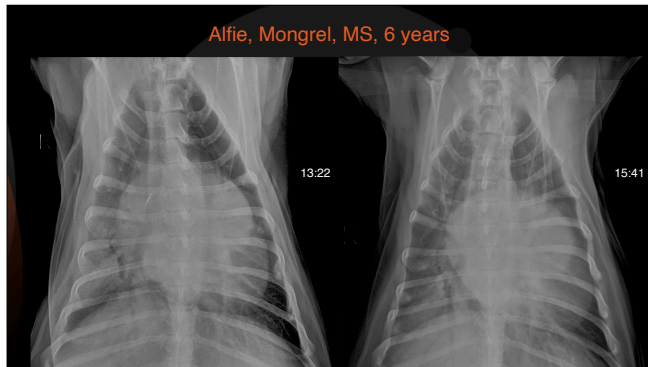


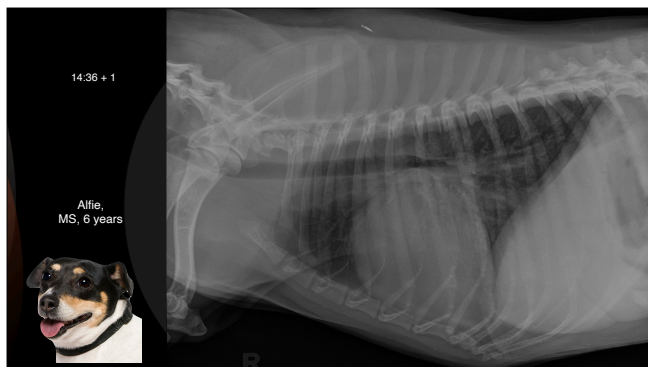


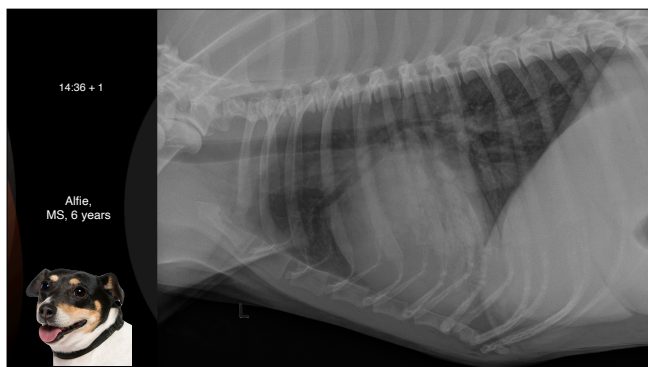
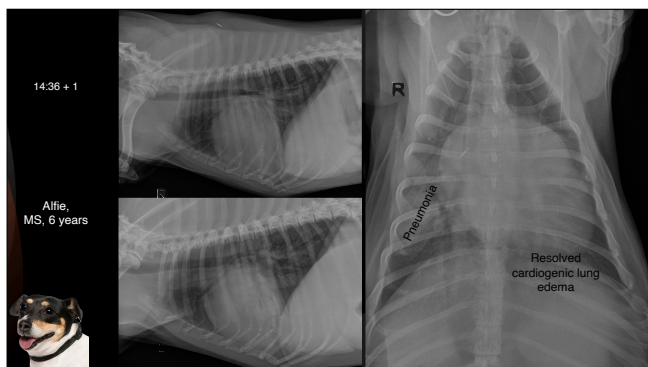












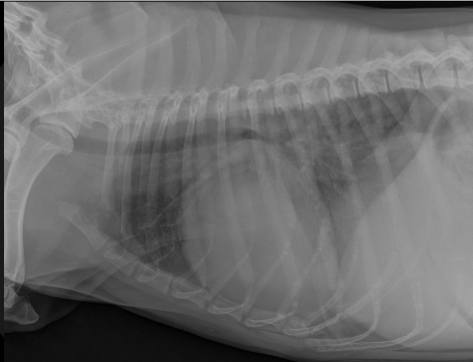
Alfie, Mongrel, MN, 6 years

- 24 days later
- Recheck for pneumonia and cardiac condition



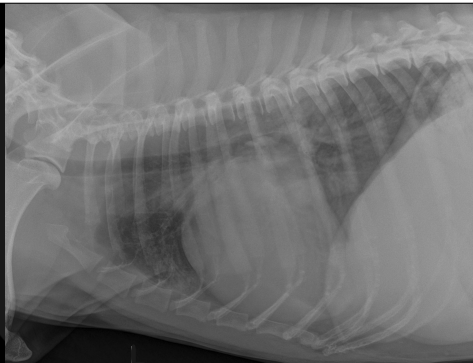
24 days later

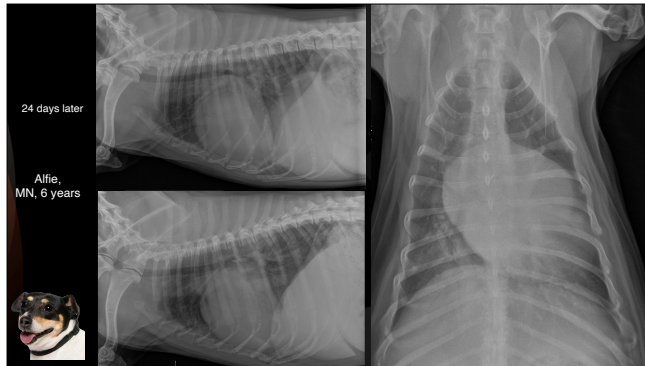
Alfie,
MN, 6 years

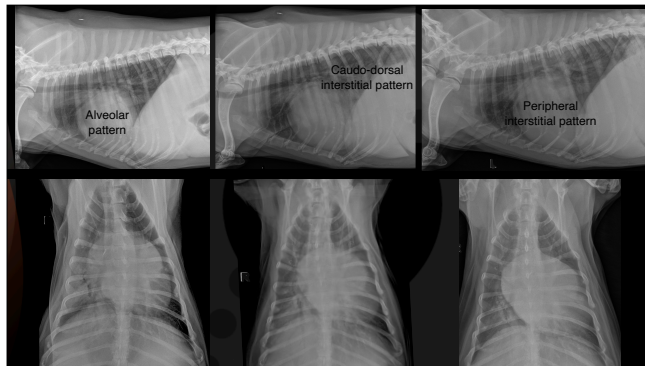


24 days later

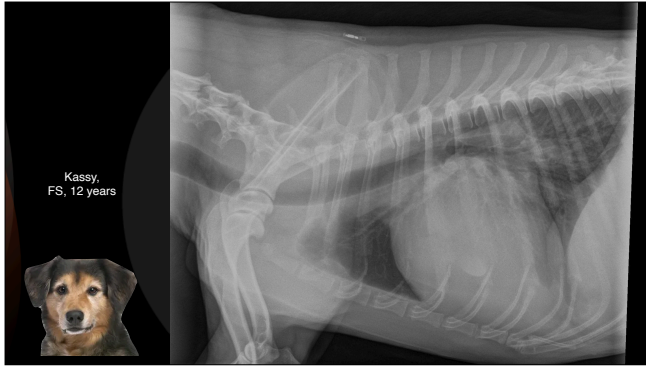
Alfie,
MN, 6 years

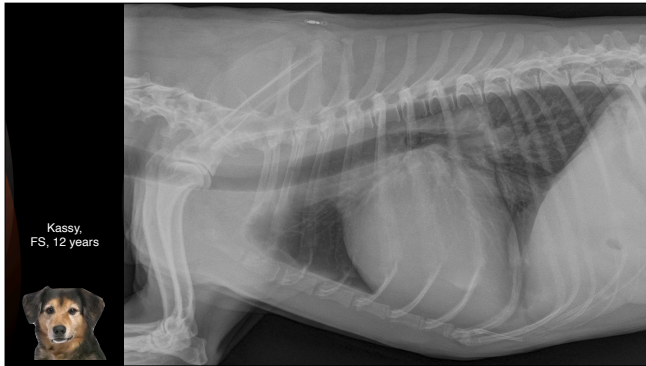


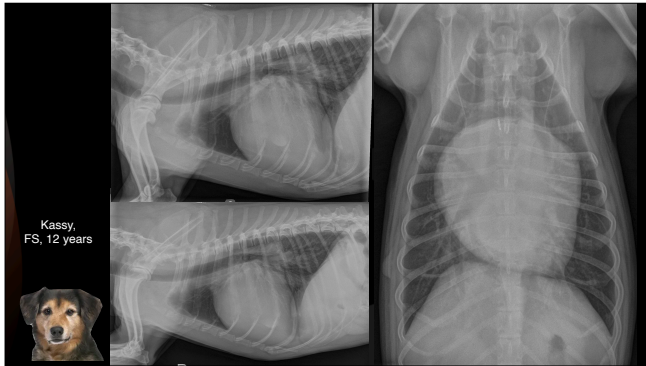


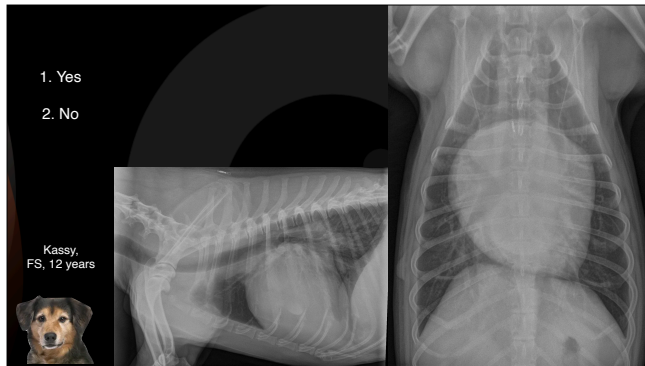


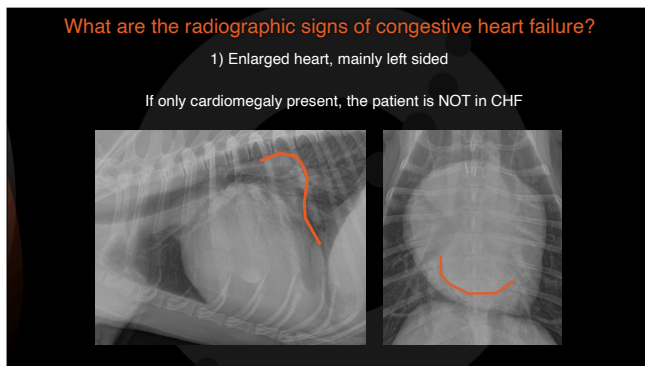


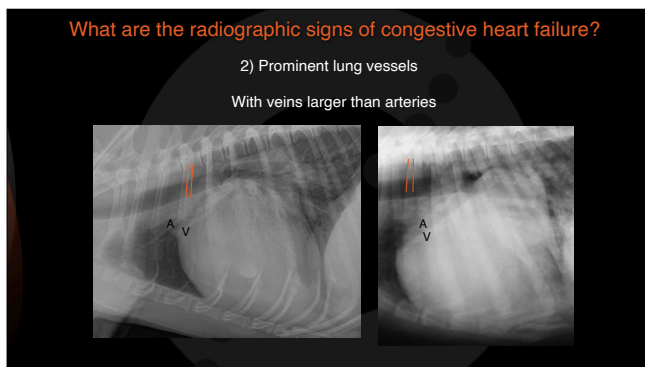






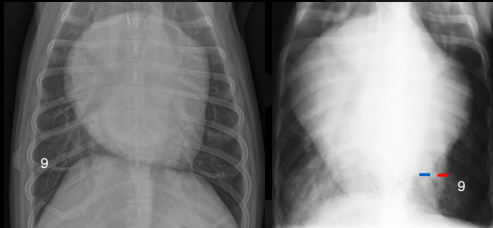






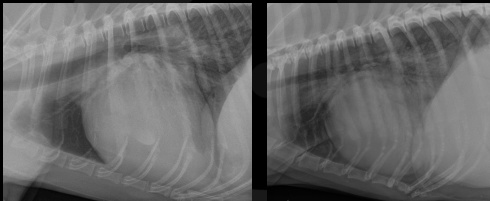
What are the radiographic signs of congestive heart failure?

2) Prominent lung vessels



What are the radiographic signs of congestive heart failure?

3) Increased caudo-dorsal interstitial pattern

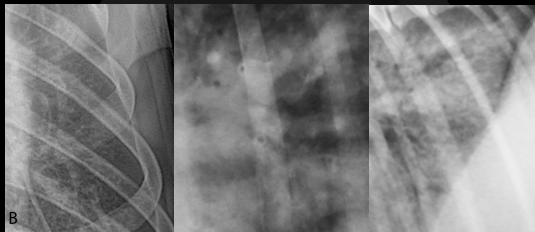


Stages of lung edema

Diffuse unstructured interstitial

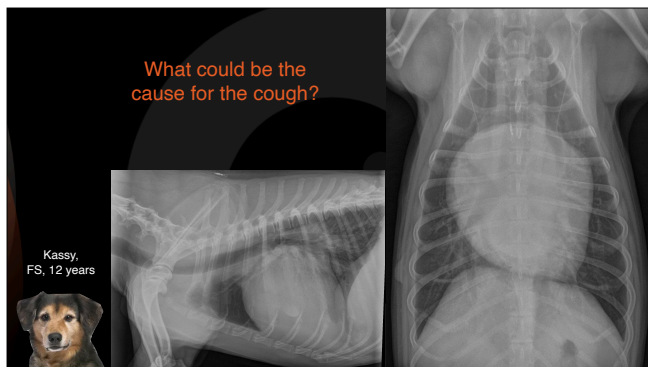
Peribronchial interstitial

Alveolar



What could be the cause for the cough?

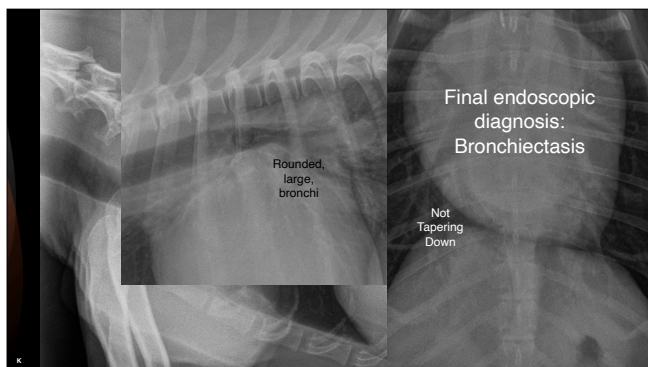
Kassy,
FS, 12 years



Rounded,
large,
bronchi

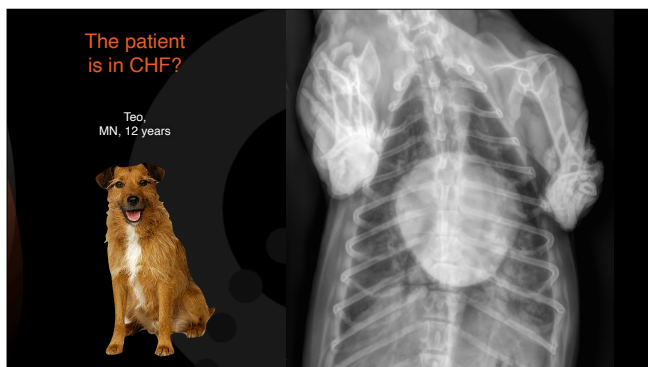
Final endoscopic
diagnosis:
Bronchiectasis

Not
Tapering
Down



The patient
is in CHF?

Teo,
MN, 12 years



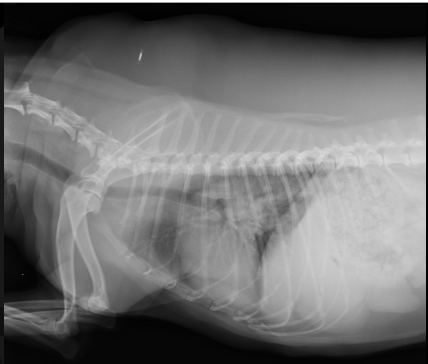Buffy, Cockapoo, MN, 8 years

- Persistent cough

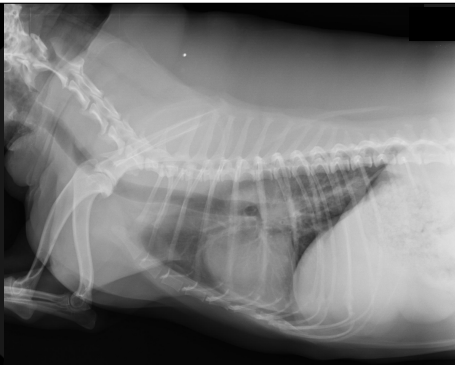

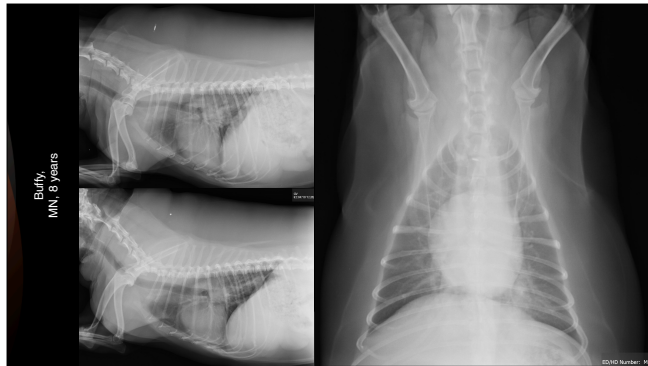
Is the left
atrium enlarged?

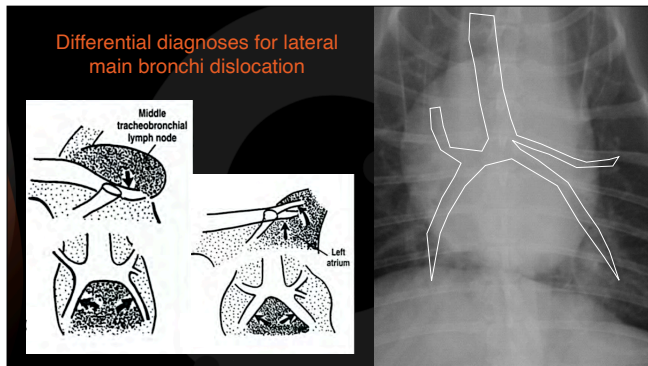
Buffy,
MN, 8 years

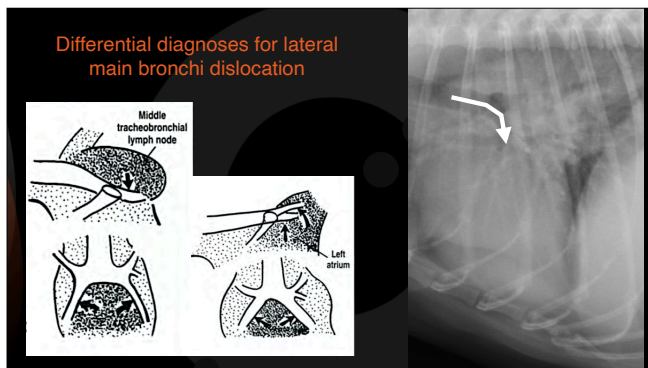


Buffy,
MN, 8 years



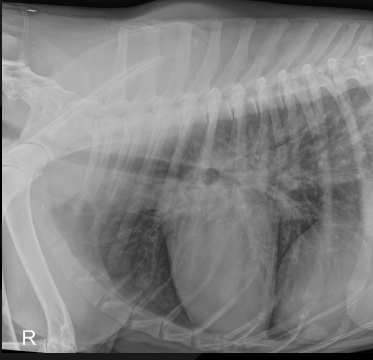






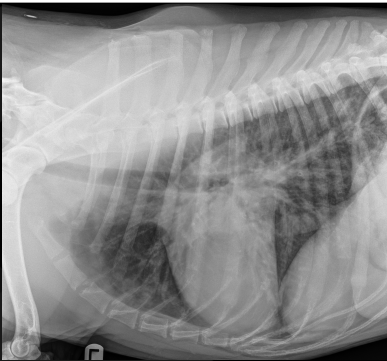
Leo, MN, 7 years

- Exercise intolerance
- Cough



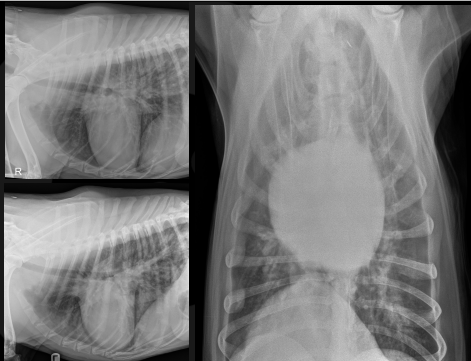
Leo, MN, 7 years

- Exercise intolerance
- Cough



Leo, MN, 7 years

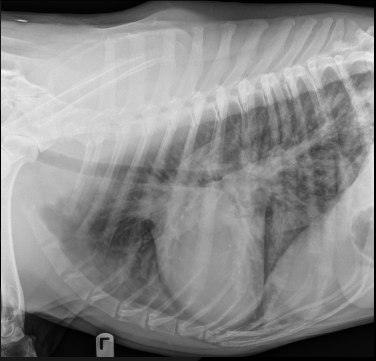
- Suspected pneumonia



Leo, MN, 7 years

Three days later

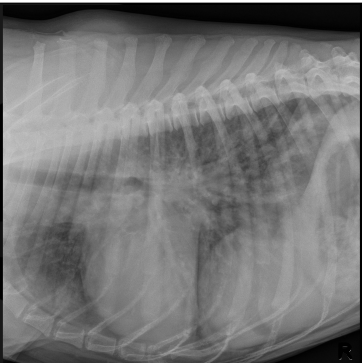
- Polypneic, fever
- Exercise intolerance
- Cough



Leo, MN, 7 years

Three days later

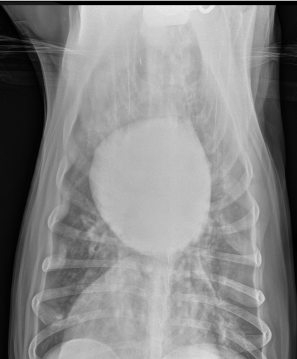
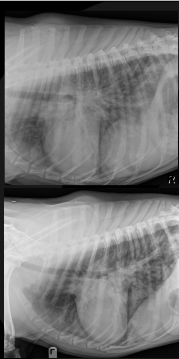- Polypneic, fever
- Exercise intolerance
- Cough



Leo, MN,
7 years

Three days later

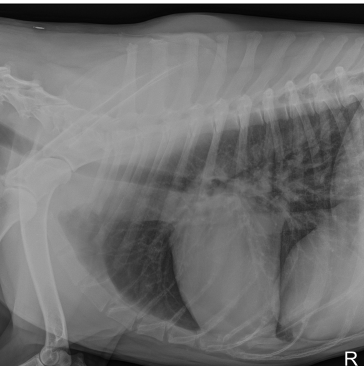
- Change the AB?
- Add NSAD?
- Add SAD?



Leo, MN, 7 years

Four days later

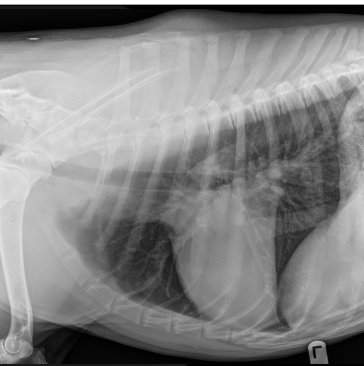
- Improved clinical signs



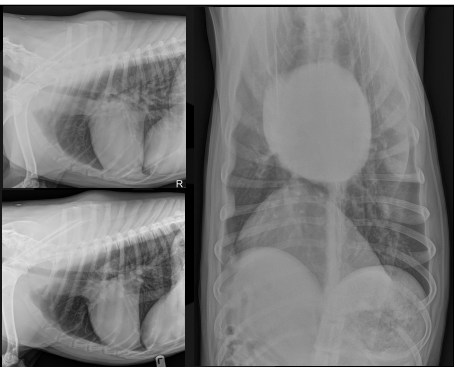
Leo, MN, 7 years

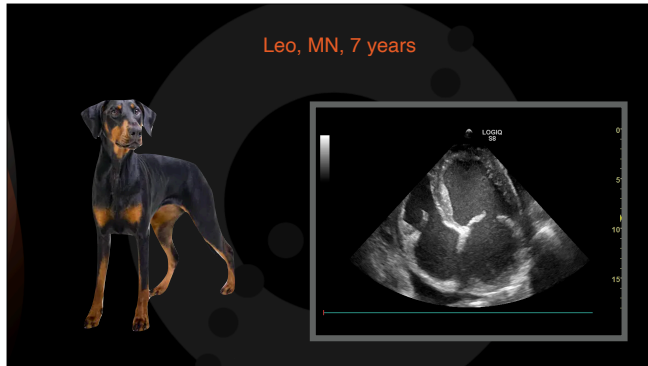Four days later

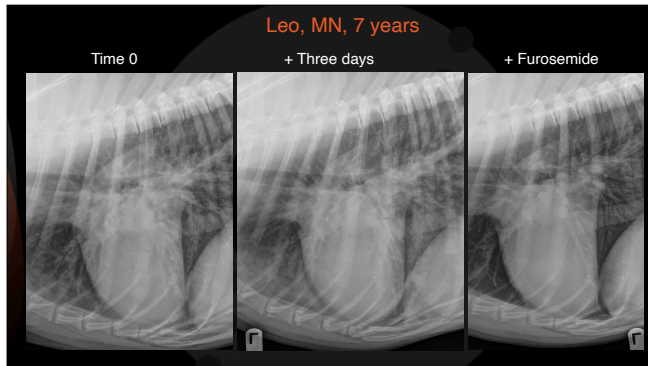
- Improved clinical signs

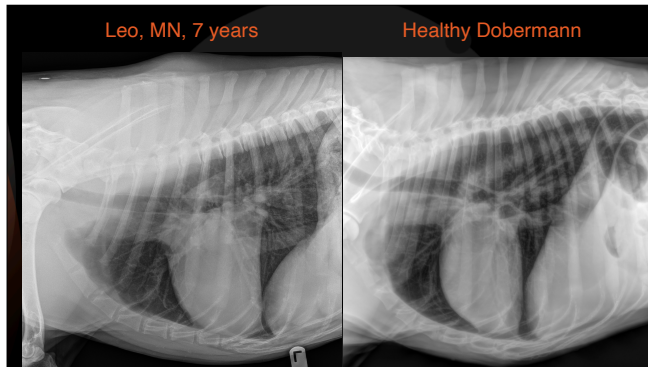


Leo, MN, 7 years










Conclusions

A large heart is not a sign of CHF

Check the vessels!

Check the breed!



Thank you



Diagnostic Mindset

www.diagnosticmindset.com
