

Perchè il gatto scompensato si comporta diversamente rispetto al cane?




Diagnostic Mindset Thanks to Clinica Veterinaria Castellarano

Giliola Spattini
DVM, PhD, DECVDI

Objectives

- Feline heart diseases are different from canine conditions
- This lecture discusses why and how
- The lecture will show the typical radiographic signs of feline heart failure



Which is the most common canine heart condition?

Chronic mitral valve disease

Insufficient valve with blood leakage Healthy myocardium

Which is the most common feline heart condition?

Hypertrophic cardiomyopathy

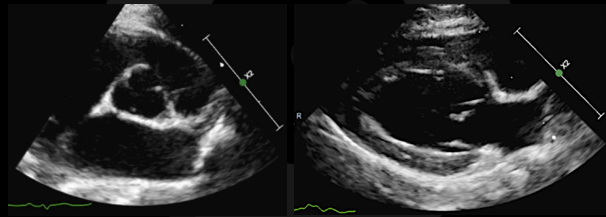
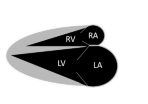
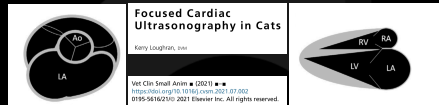
Competent valve Disease myocardium

The most commonly diagnosed feline heart diseases

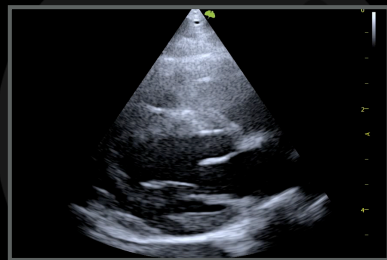
- Hypertrophic cardiomyopathy
- Restrictive cardiomyopathy
- Unclassified cardiomyopathy
- Dilated cardiomyopathy (rare)



Normal ultrasonographic anatomy of the feline heart

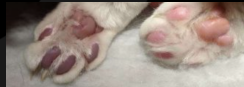


Feline cardiac anatomy



Tato, DLH, MN, 5 years

- Sudden paralysis of the left hindlimb
- Cold at the touch
- Blu paw



Hypertrophic cardiomyopathy



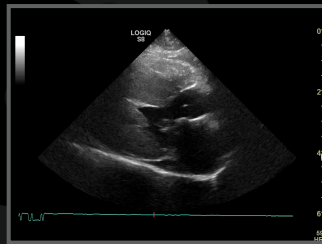
Tato,
MN, 5 years

Thickened, not elastic myocardium

Decreased ventricular diameter

Increased circulating blood

Enlarged left atrium



Hypertrophic cardiomyopathy



Healthy cat



HCM cat

Ciobin, Birman, MN, 10 years

- Seizures



Restrictive cardiomyopathy



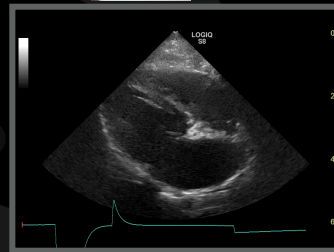
Ciobin,
MN, 10 years

Loss of contraction of the pericardium

Not thickened but not elastic

Increased circulating blood

Enlarged left atrium



Paul, , MN, 4 years

- Depressed
- Dyspneic
- Anorexic



Dilated cardiomyopathy



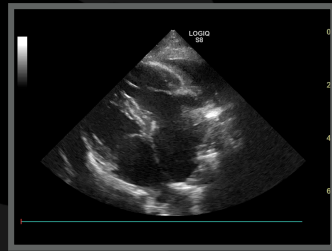
Paul,
MN, 4 years

Loss of contraction of the myocardium

Severely dilated cardiac chamber

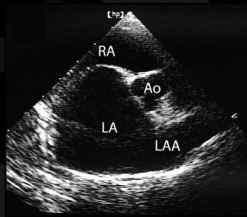
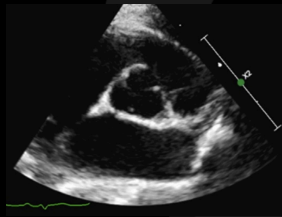
Increased circulating blood

Enlarged left atrium



What is common for these conditions?

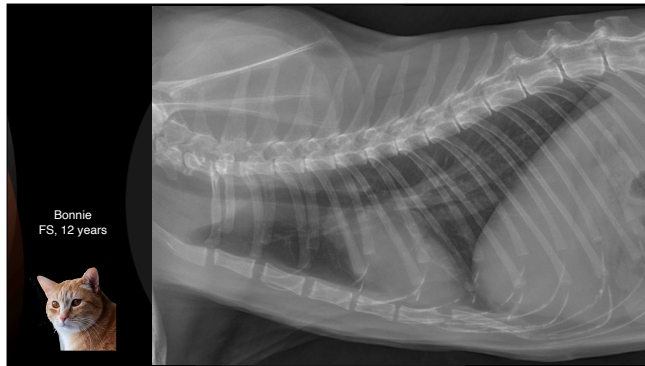
Enlarged left atrium

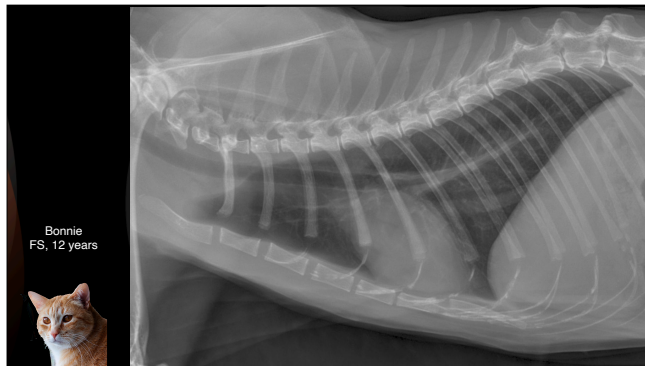

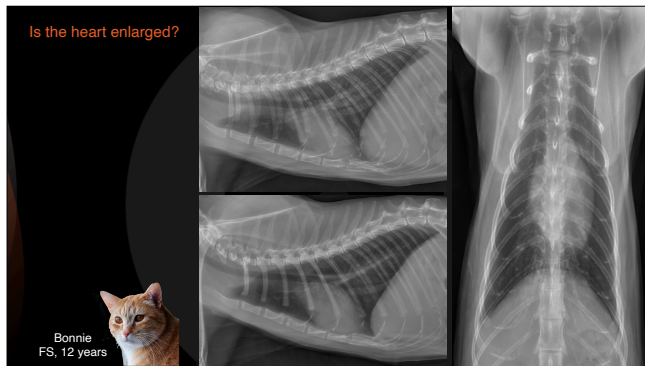
Bonnie, DMH, FS, 12 years

- Metastatic check for bladder tumor

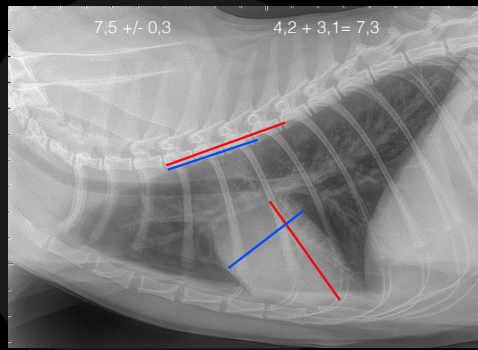








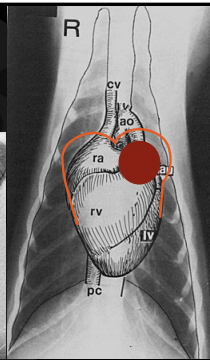
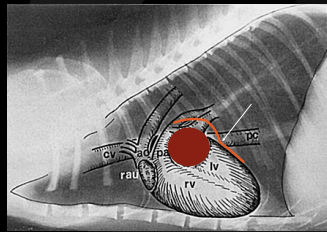
Cardiac measurements
in cat



Feline left atrium enlargement

Cardiac waist

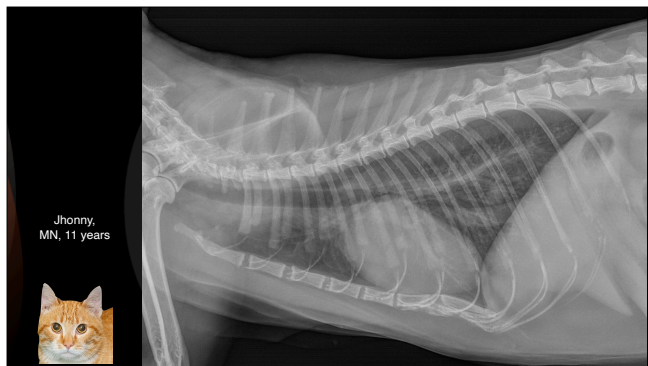Valentine shaped heart on VD

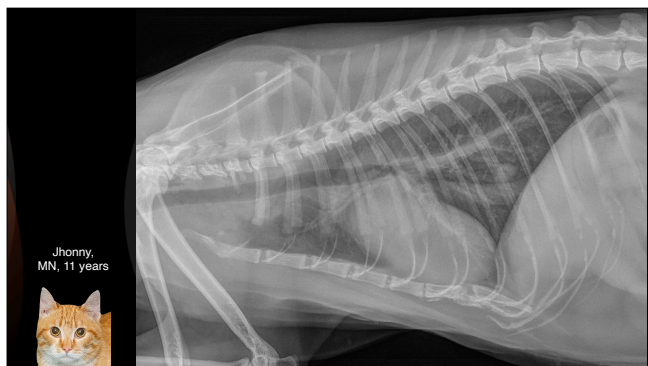

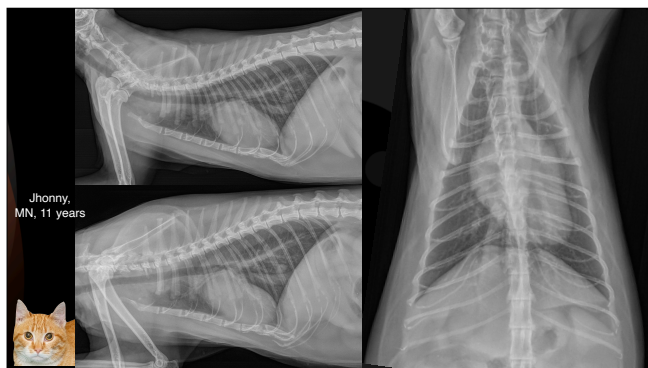
Jhonny, DSH, MN, 11 years


- Senior wellness

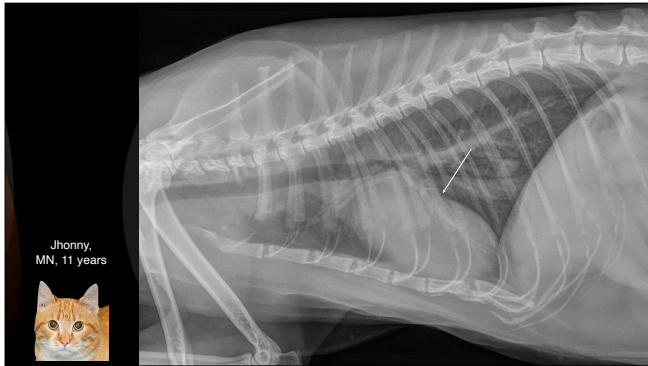


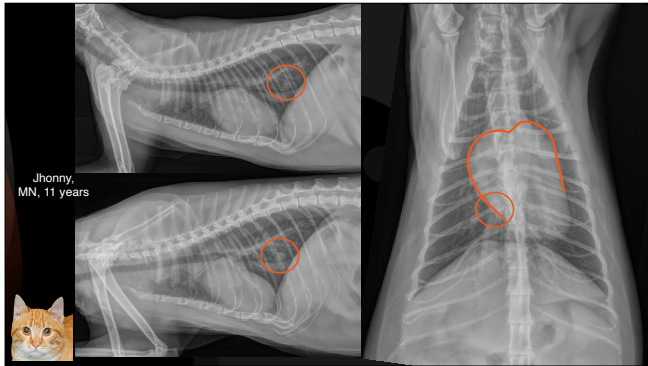












Jhonny, DSH, MN, 11 years

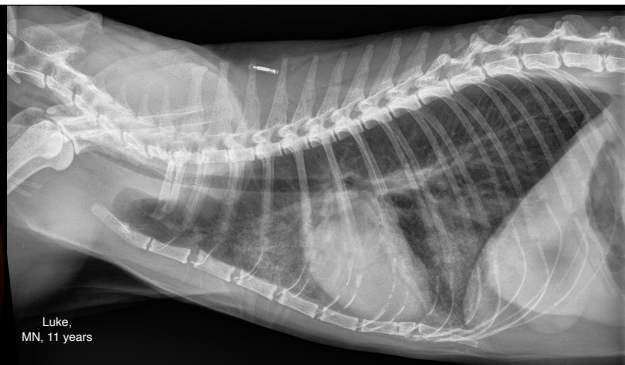- An echo was performed: moderate HCM, atenolol 6,25 mg/sid started
- CT confirm pulmonary nodule, no metastasis
- Lobectomy: carcinoma totally excised

Cancer free three years later, HCM under control

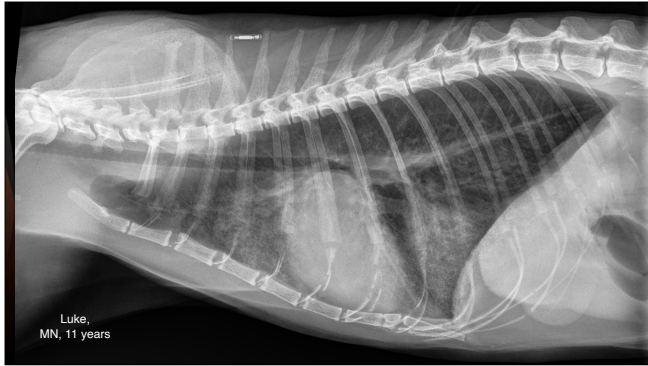

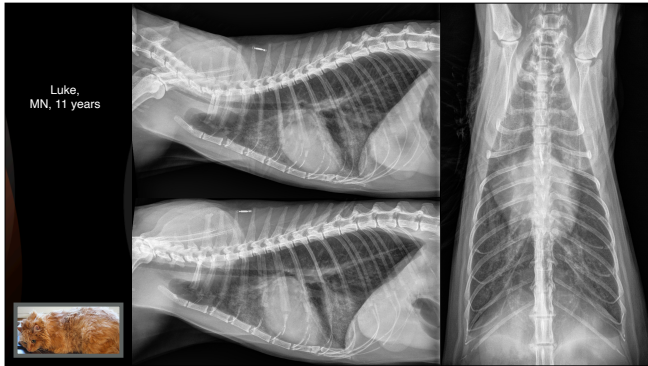
Luke, DLH, MN, 11 years


- Presented with labored breathing after gone missing for two days

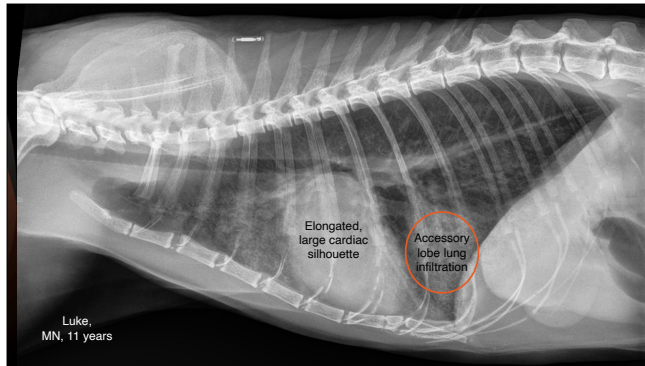


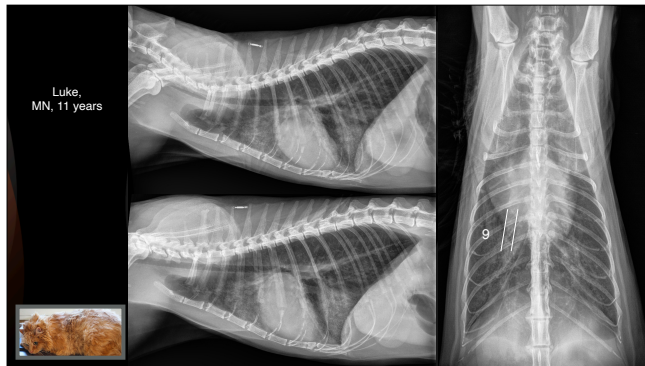
Luke,
MN, 11 years











Accessory lung lobe area mostly affected Heterogeneous, not symmetric distribution

All patient had an enlarged left atrium

**Radiographic appearance of
cardiogenic pulmonary oedema
in 23 cats**

L. BENIGNI, N. MORGAN* AND C. R. LAMB

Journal of Small Animal Practice (2009)
50, 9-14
DOI: 10.1111/j.1748-5827.2008.00655.x

Albus, DSH, MN, 7 years

- Dyspneic
- Yesterday He was fine







