

La parete toracica:
perché non ce ne
dobbiamo dimenticare




Diagnostic Mindset

Gilola Spattini
DVM, PhD, DECVDI

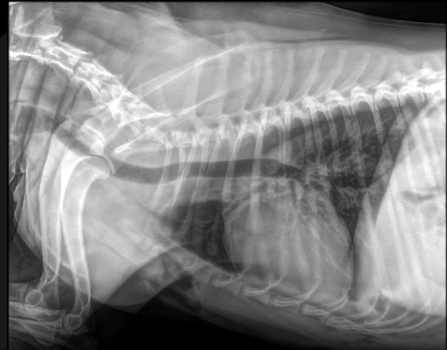
Objectives

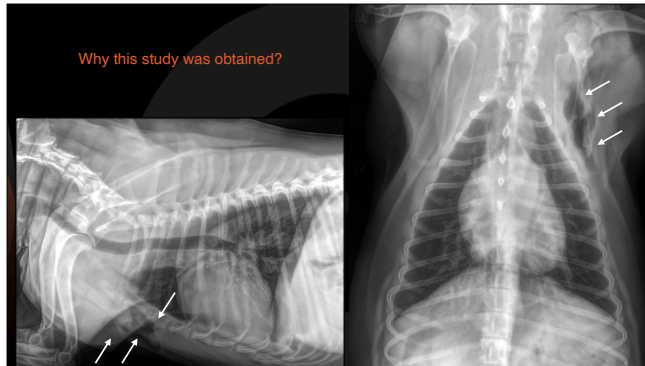
- Every part of the thoracic cavity needs to be carefully evaluated
- A systematic approach should start from the thoracic walls and contour

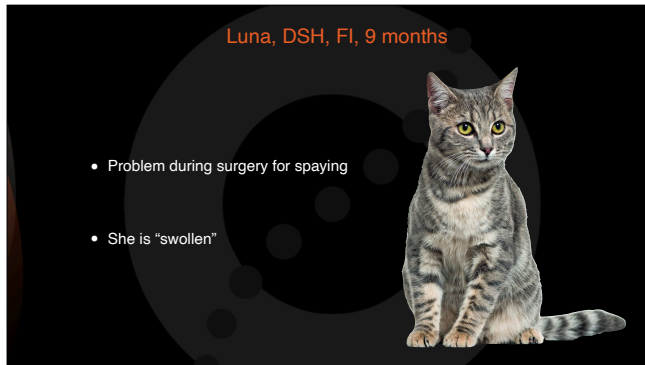

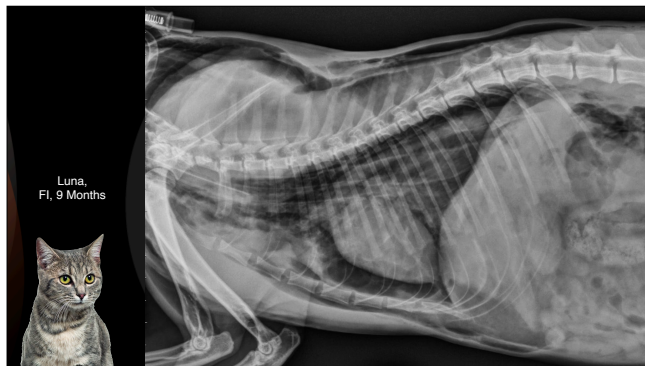Thoracic cage

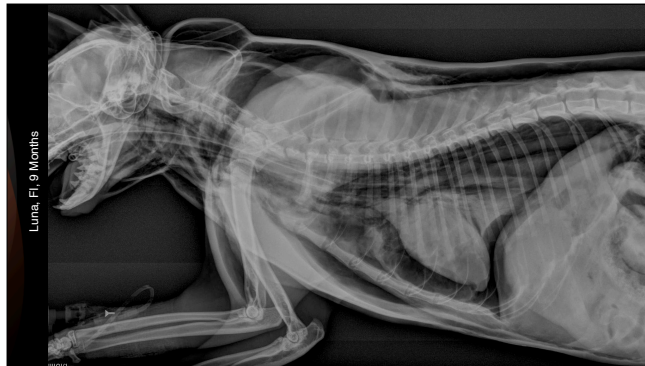
- Skin and subcutis
- Vertebrae
- Ribs
- Sternebrae
- Diaphragm

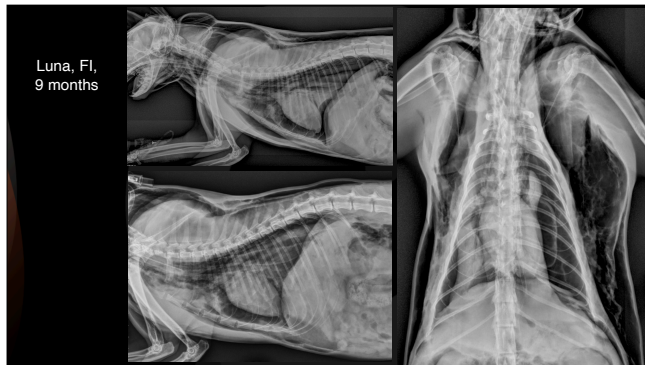







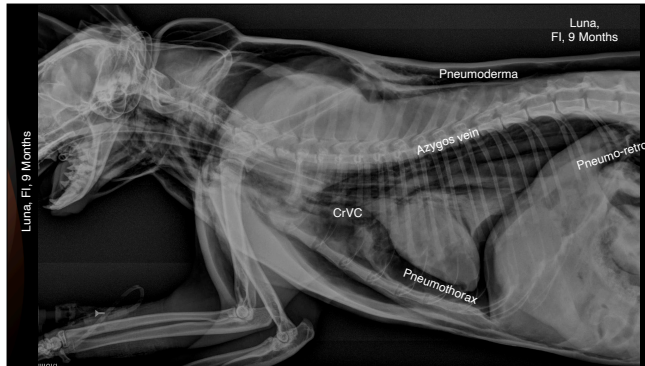


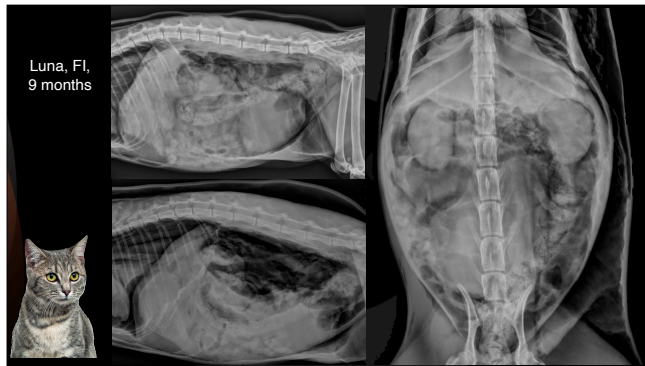


Your evaluation

- Is there pneumothorax?
- Are there rib fractures?
- Is there a pneumoretroperitoneum?

A photograph of a sitting tabby cat with yellow eyes, looking directly at the camera. The cat is positioned on the right side of the slide, next to the evaluation questions.



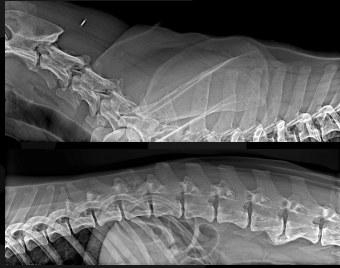


Differential diagnosis of pneumoderma/ pneumomediastinum

Macklin effect (severe dyspnea)	Esophageal perforation
Dissection of gas in fascial planes of the neck	Extension of retroperitoneal gas into the mediastinum
Tracheal perforation/rupture	Presence of a gas-producing organism

Thoracic cage

- Skin and subcutis
- **Vertebrae**
- Ribs
- Sternebrae
- Diaphragm

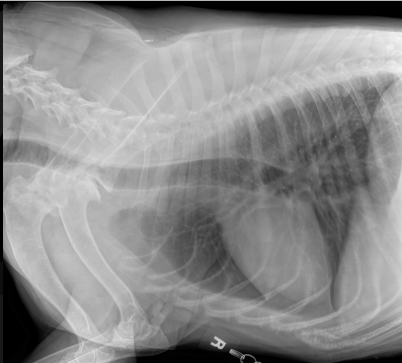


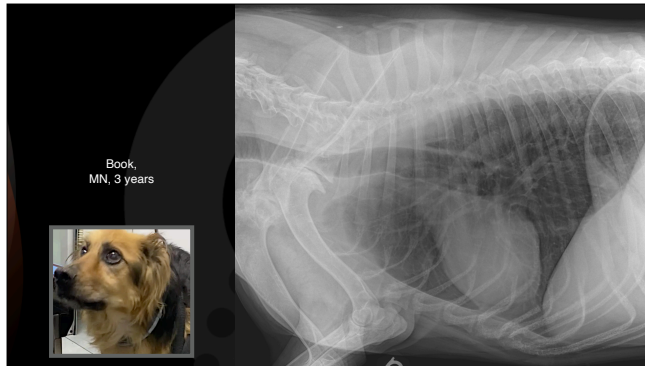
Book, Mongrel, MN, 3 years

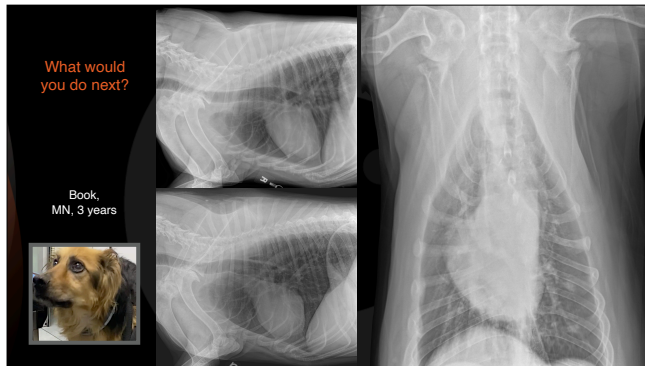
- Just adopted from the shelter
- Reluctant to move
- Intolerant of exercise
- Low budget

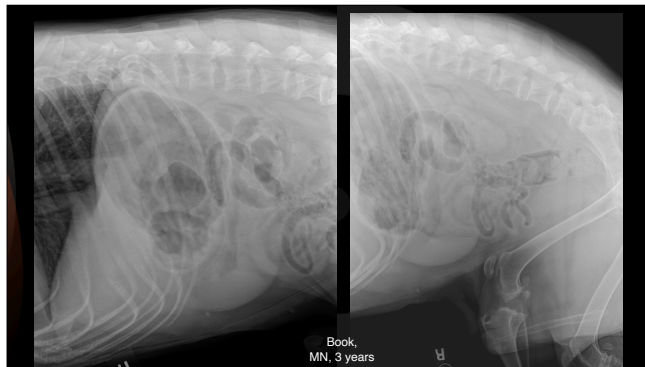


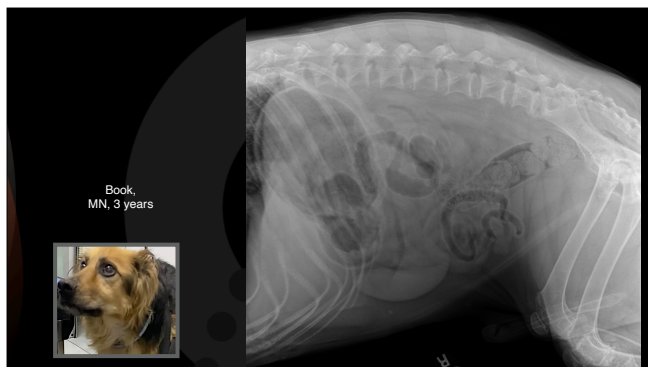Book,
MN, 3 years

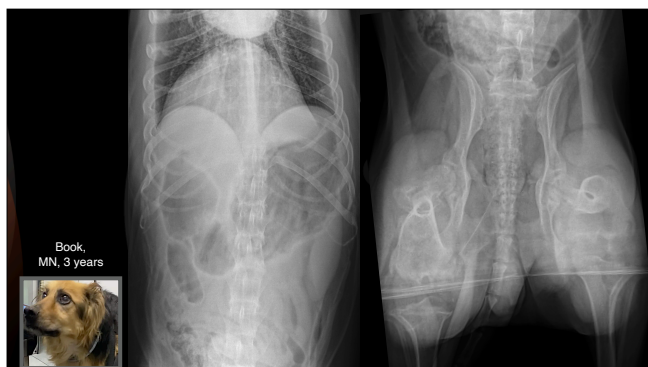

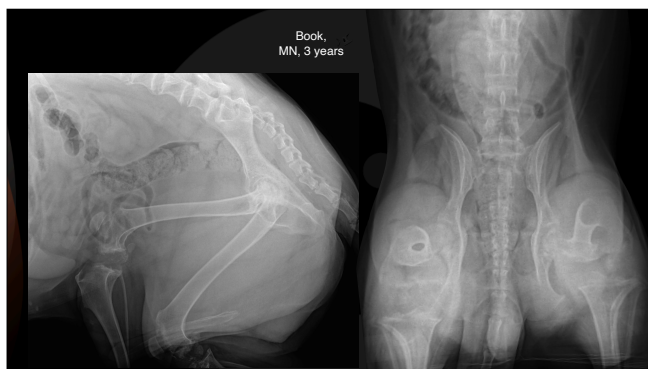


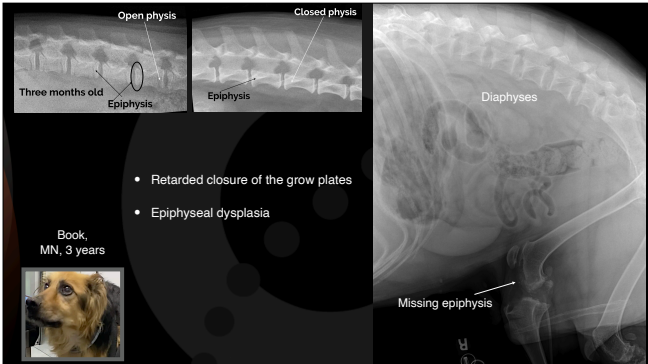
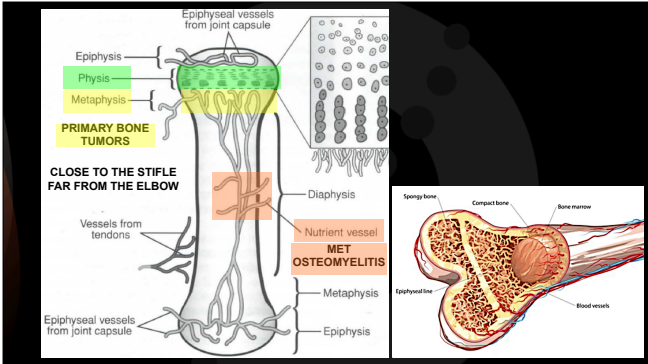












Book, MN, 3 years

Final diagnosis:
Congenital hypothyroidism

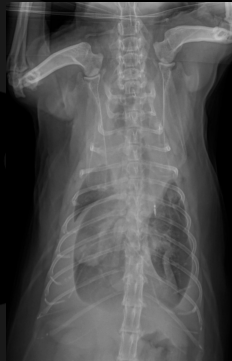Table 1.3 Radiographic changes that may be present in animals with growth disturbances

	EPHYPHSEAL DYSPLASIA	WIDE PHYSES	LATE-CLOSING PHYSES	OSTEOPENIA	STUNTING
Chondrodysplasia	Yes	Yes	Some	No	Yes
Congenital hypothyroidism	Yes	Yes	Yes	No	Yes
Hypervitaminosis A in miniature dogs	No	No	No	Yes	Yes
Pituitary dwarfism	Yes	Yes	Yes	No	Yes
Mucopolysaccharidosis	Yes	Irregular	Not reported	Yes	Possible
Rickets	No	Yes	Yes	Yes	Yes

TEST:
PRL WNL
ACTH WNL
TSH LOW

Thoracic cage

- Skin and subcutis
- Vertebrae
- Ribs
- Sternebrae
- Diaphragm

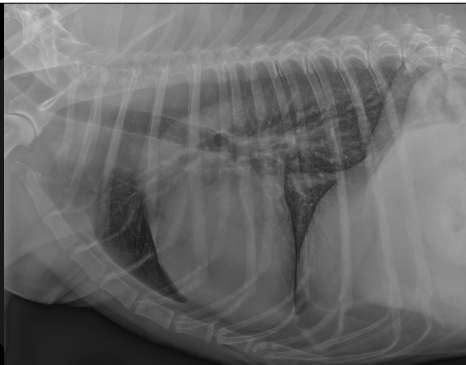


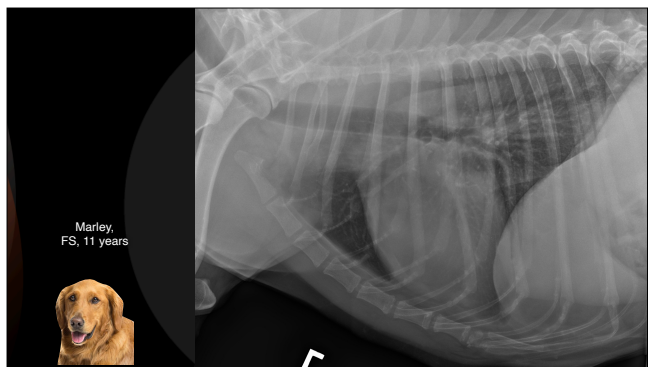
Marley, Mongrel, FS, 11 years

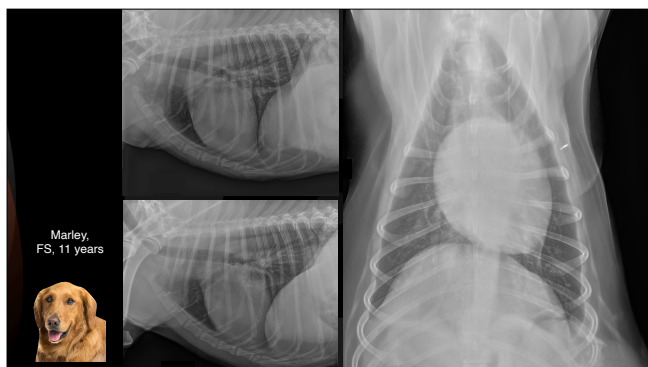
- A lump was detected on the thoracic wall

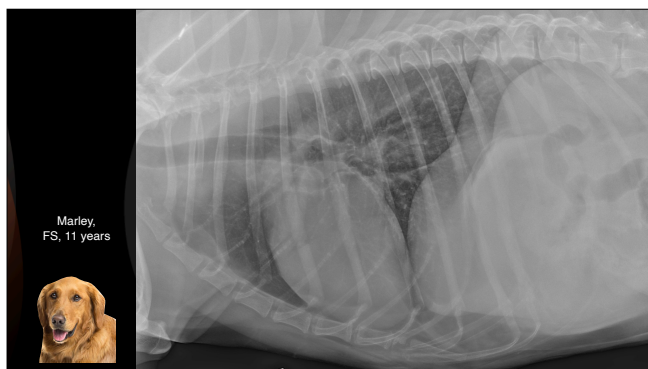

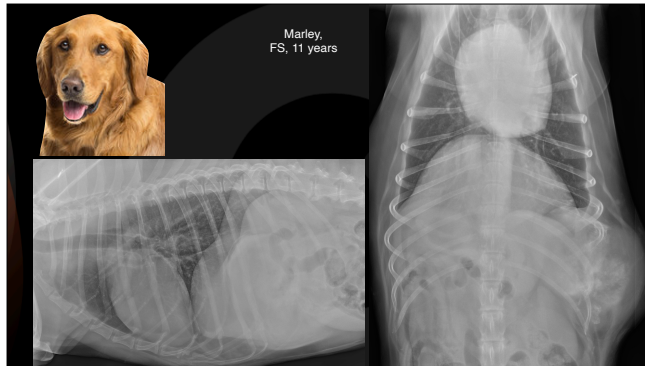
Marley,
FS, 11 years







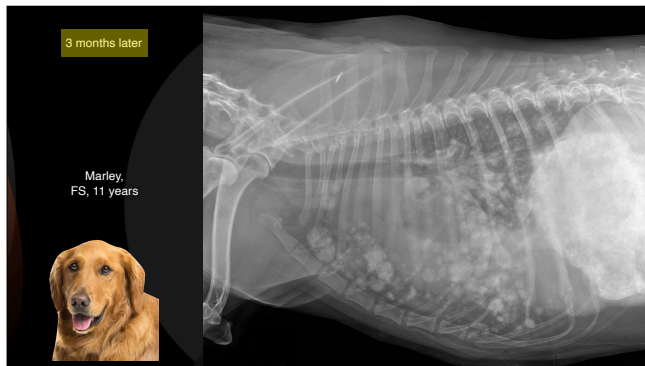


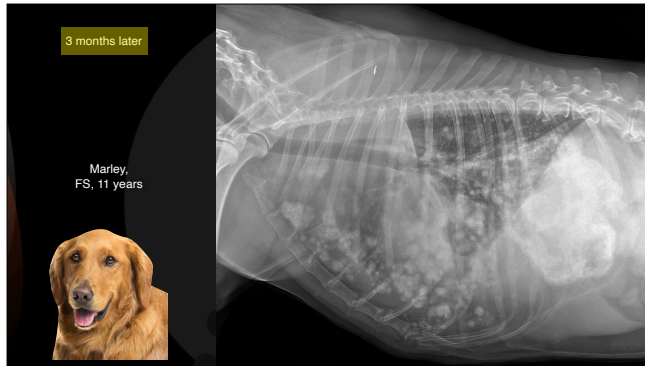


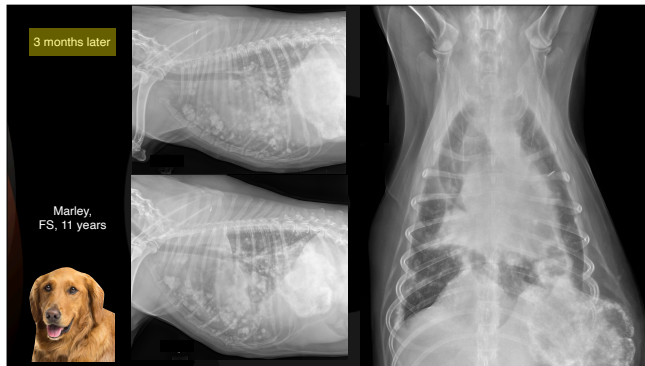Marley, Mongrel, FS, 11 years

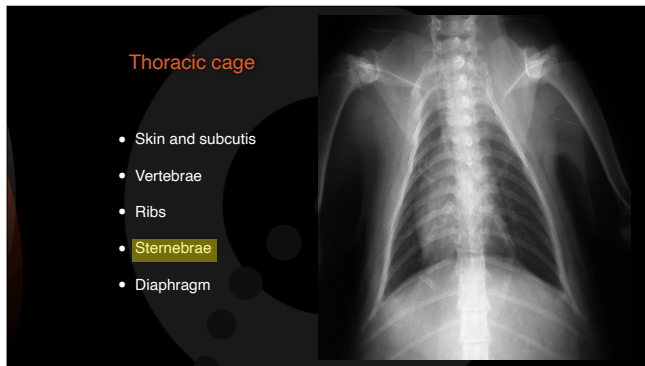
- CT performed: not resectable
- Histology: undifferentiated sarcoma
- Recheck three months later, under chemo







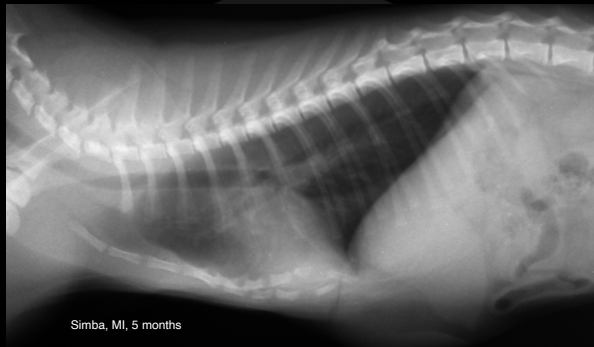




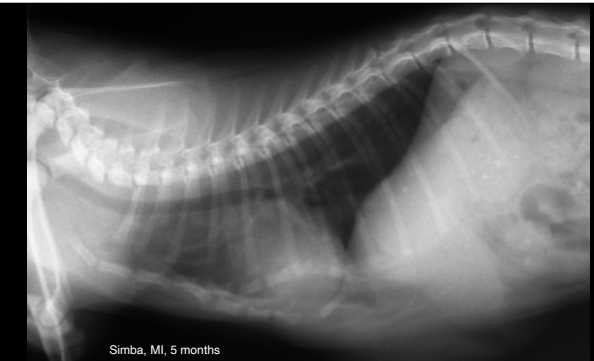Simba, DSH, MI, 5 months

- The owner "feels" the heart
- No other clinical signs

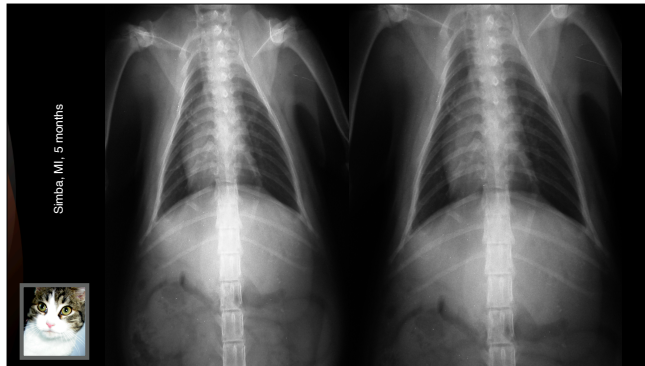




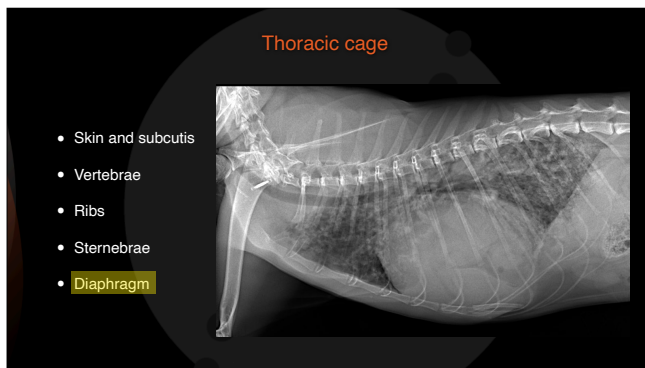
Simba, MI, 5 months



Simba, MI, 5 months







Thank you



Diagnostic Mindset

www.diagnosticmindset.com
