

Masse addominali di grosse dimensioni: quando l'ecografia non ci arriva



Diagnostic Mindset



Giliola Spattini
DVM, PhD, DECVDI

Objectives

- The mass effect is an essential factor in defining the origin of a mass in radiology
- Sometimes different modalities are essential to define the origin of a large abdominal mass



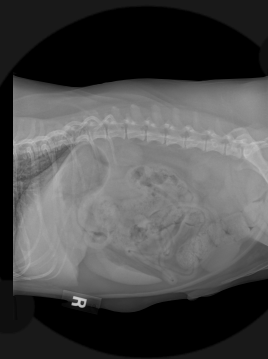Abdominal mass: radiology or ultrasound?

Radiology

General overview

Easy to define the location and the interaction with other abdominal organs

If effusion present only visible the mass effect



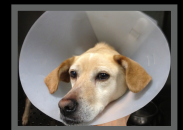Ultrasound

Focal spot

More detailed morphology

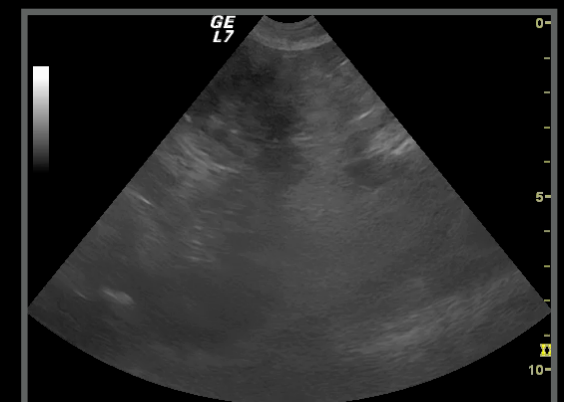
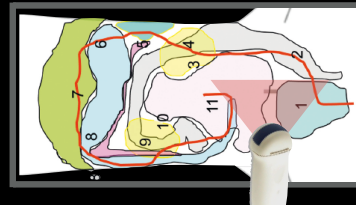
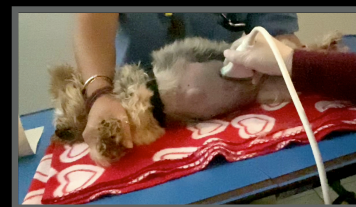More difficult to locate

Scilla, FI, 7 years

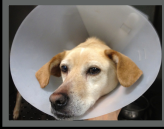

1-11

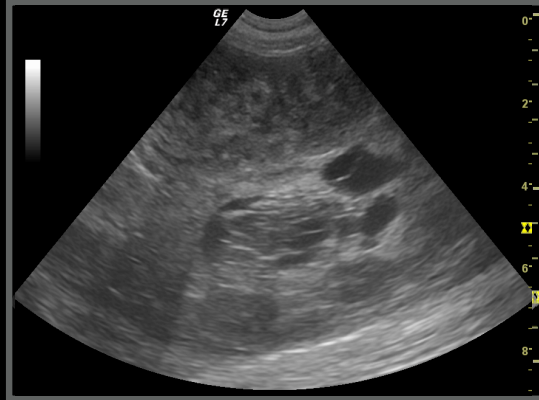
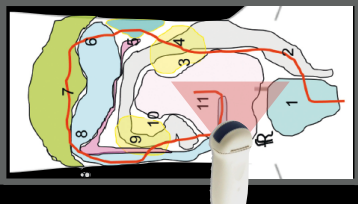
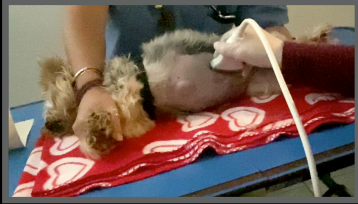Probe position in a different patient



Scilla, FI, 7 years



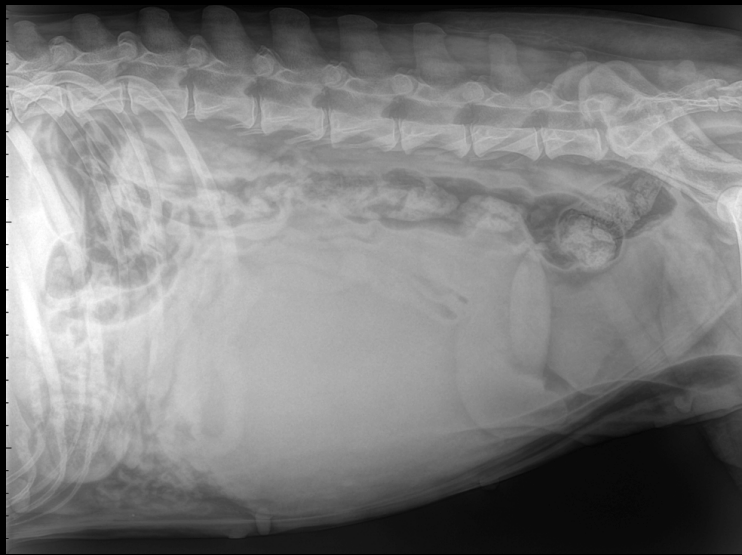
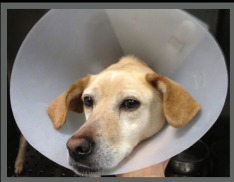Probe position in a different patient



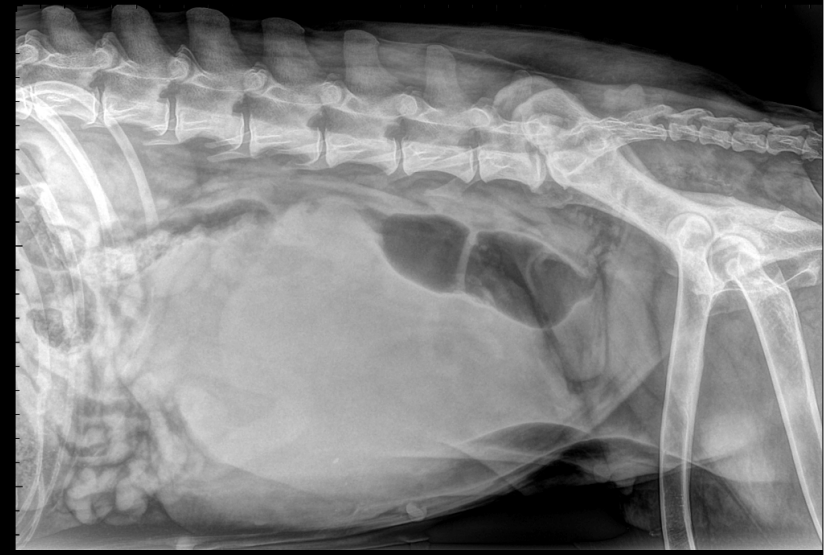
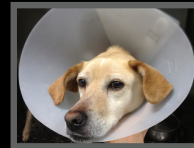11

Your evaluation?

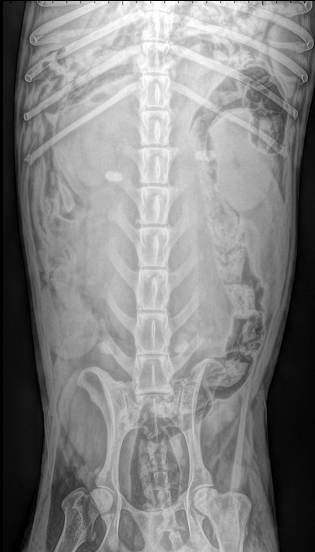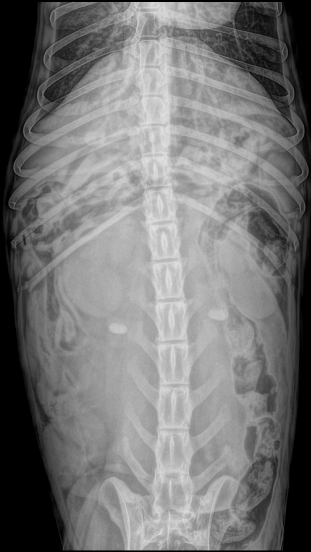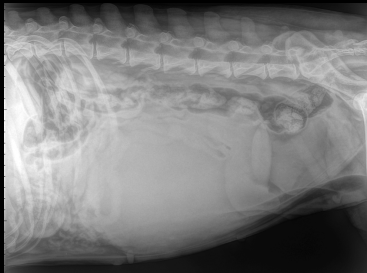
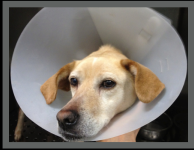Scilla, FI, 7 years



Scilla, FI, 7 years



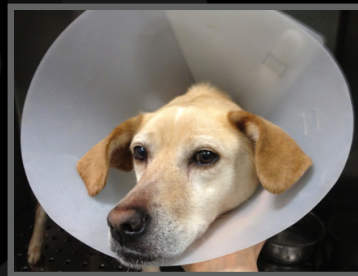Scilla, FI, 7 years



Your evaluation?

Scilla, Mongrel, FI, 7 years

- Nobody's dog
- Progressive abdominal distension last two months
- Bloody vaginal discharge since last week



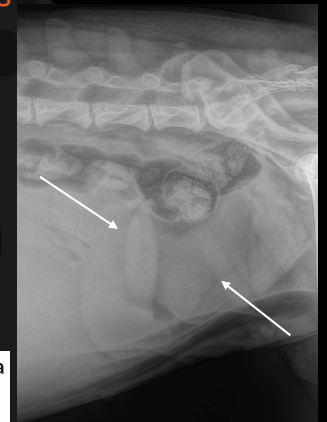
Scilla, Mongrel, FI, 7 years

Radiographic diagnoses:

- Space occupying uterine mass
- Possible associated pyometra

Conclusions:

- Surgery



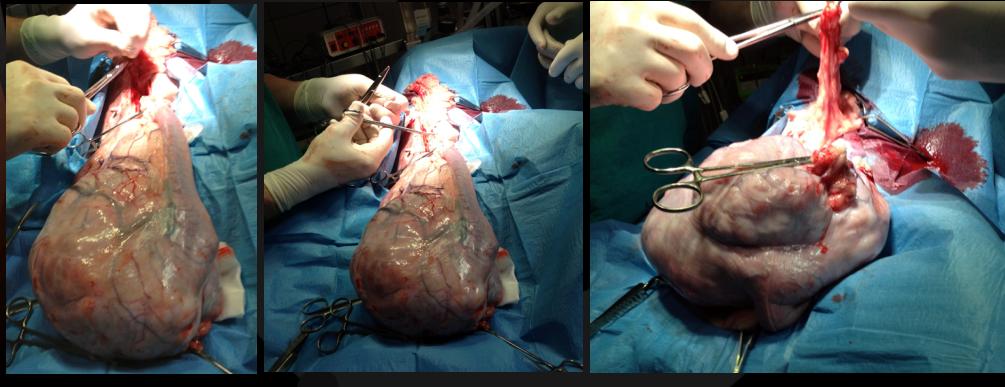
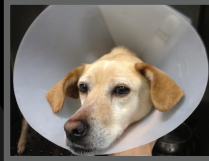Co-existing monophasic teratoma and uterine adenocarcinoma in a female dog

Reprod Dom Anim. 2019;54:1044–1049

Maria dos Anjos Pires¹ | José Carlos Catarino² | Hugo Vilhena^{1,3,4} | Susana Faim⁵ |
Tiago Neves⁵ | Andreia Freire⁵ | Fernanda Seixas¹ | Leonor Orge^{1,6} |
Rita Payan-Carreira^{1,7}

Scilla, Mongrel, FI, 7 years

Histology report: uterine fibroma

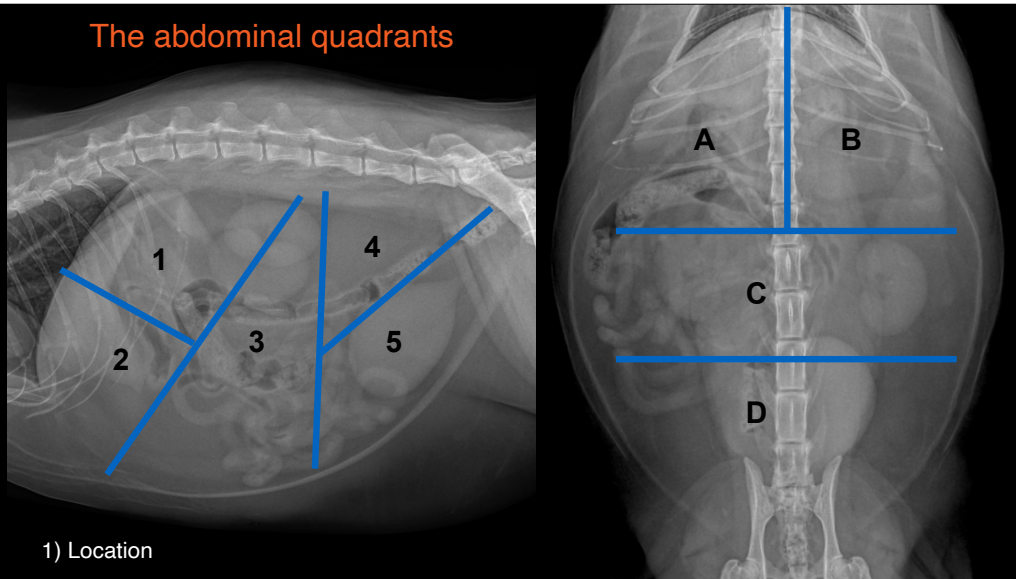


Characteristics used to define an abdominal mass on radiology

- Location
- Opacity
- Mass effect / dislocation
- Mass continuation



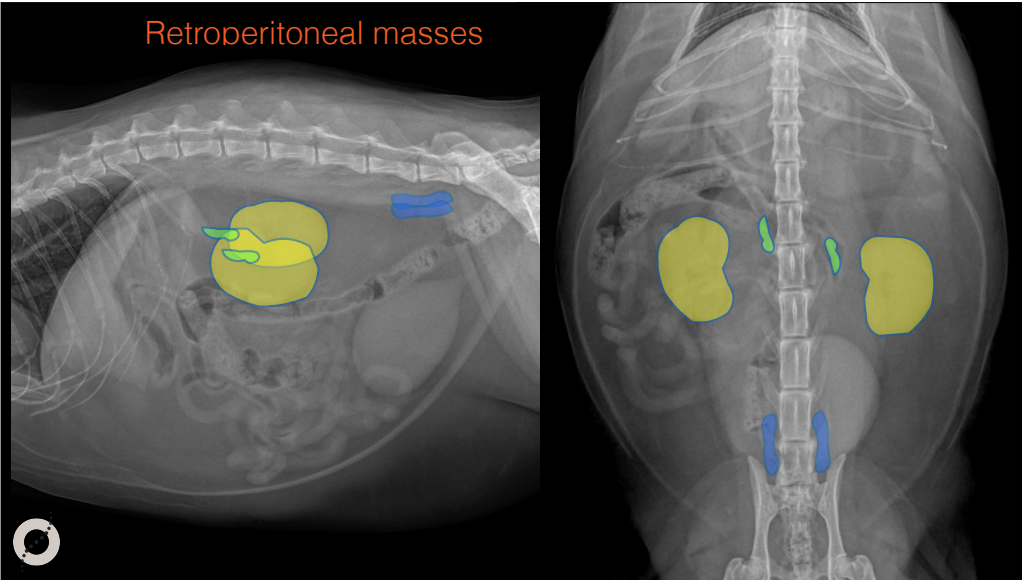
The abdominal quadrants



1) Location

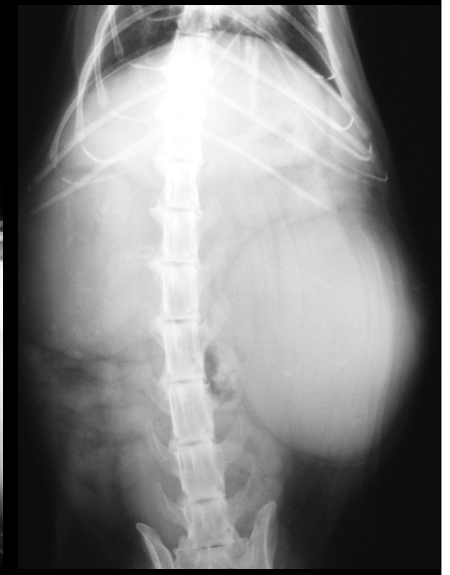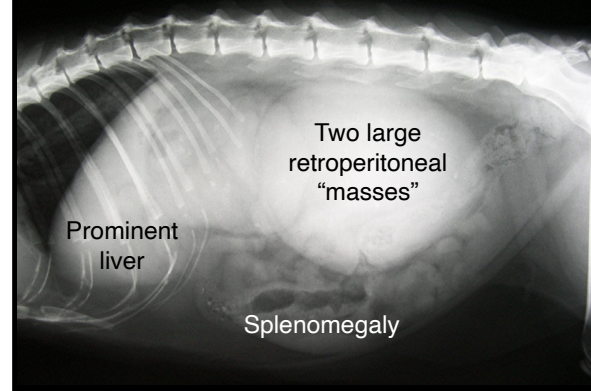

AREA	ORGANS
1A	LIVER AND GB PYLORUS DUODENUM PANCREAS
1B	LIVER STOMACH PANCREAS HEAD OF THE SPLEEN
2A	LIVER AND GB STOMACH PANCREAS
2B	LIVER STOMACH PANCREAS SPLENIC BODY
3C	KIDNEYS, ADRENALS SPLEEN, LYMPH NODES UTERUS, OVARY, RETAINED TESTICLE GI TRACT
4D	URETERS ILIAC LYMPH NODES
5D	COLON, URINARY BLADDER UTERUS, PROSTATE RETAINED TESTICLE

Retroperitoneal masses



Benito, DSH, MI, 6 years

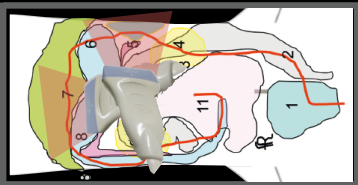
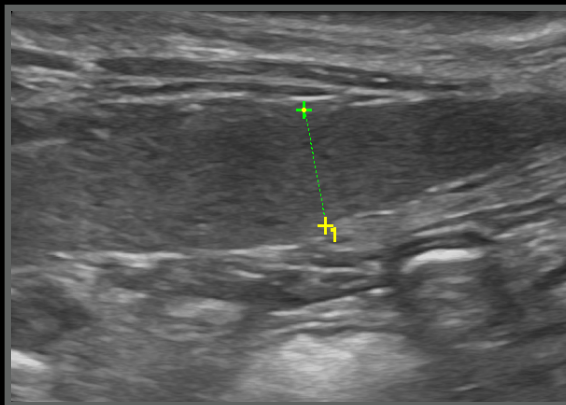
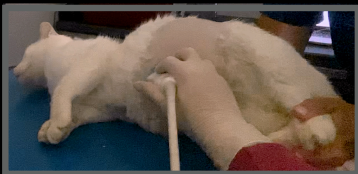
- Loosing weight
- Lethargic



Benito, DSH, MI, 6 years

Another patient, to show the position of the probe

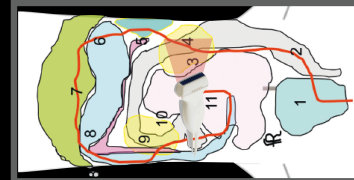
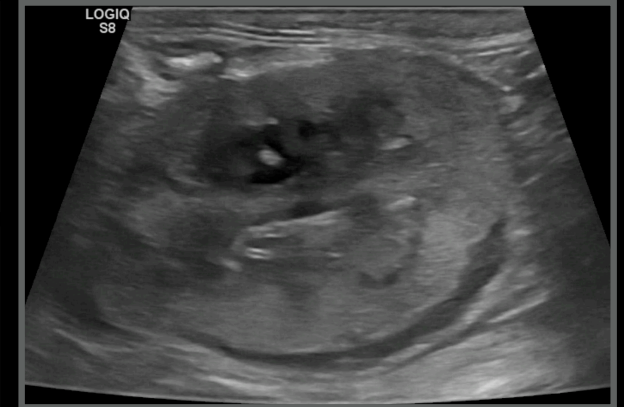7 - 5



Benito, DSH, MI, 6 years

Another patient, to show the position of the probe

4 long



Benito, DSH, MI, 6 years

Another patient, to show the position of the probe

9 long

Benito, DSH, MI, 6 years

Radiographic diagnoses:

- Two large retroperitoneal masses
- Splenomegaly

Ultrasonographic diagnoses:

- Subcapsular effusion/hypoechoic band
- Nefromegaly
- Splenomegaly

Next step

- Cytology: lymphoma

Lilly, Mongrel FS, 12 years

- PU/PD
- Extreme weakness
- Diarrhoea

Lilly, FS, 12 years

Mineralised retroperitoneal mass

Hepatomegaly

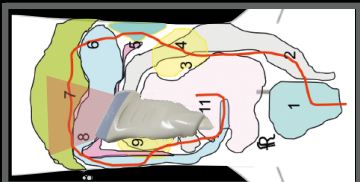
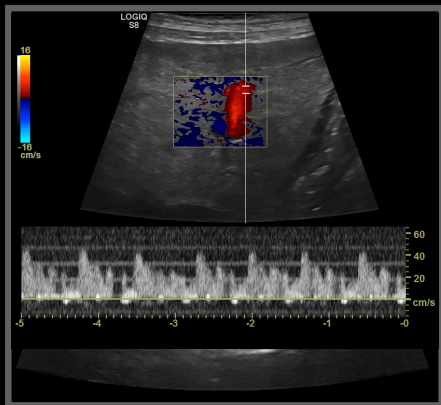
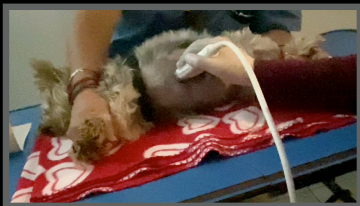Mineralised retroperitoneal mass



Lilly, FS, 12 years

Another patient, to show the position of the probe

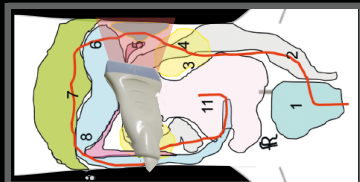
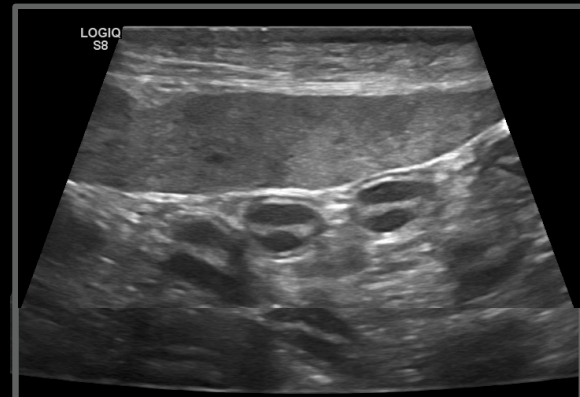
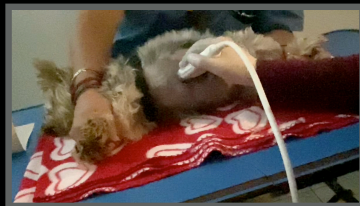6-7-8



Lilly, FS, 12 years

Another patient, to show the position of the probe

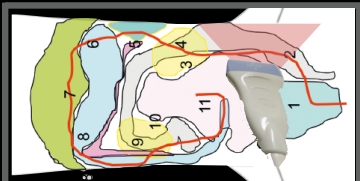
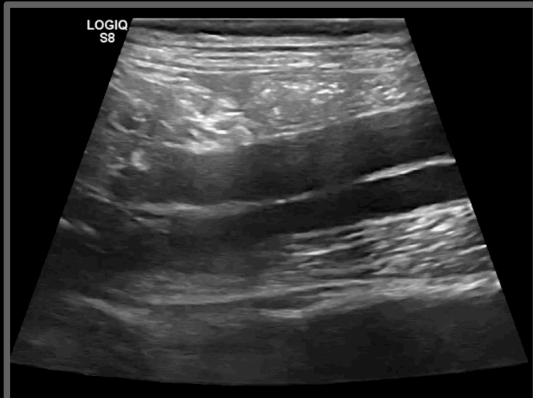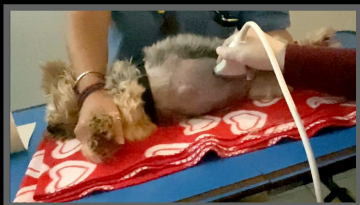6-5



Lilly, FS, 12 years

Another patient, to show the position of the probe

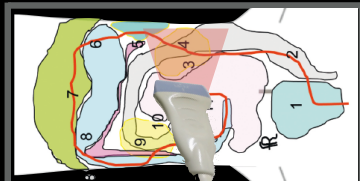
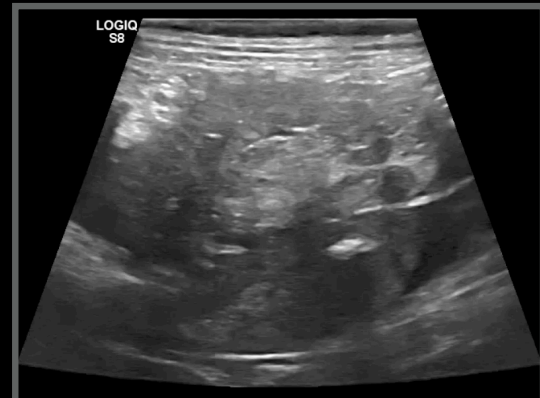
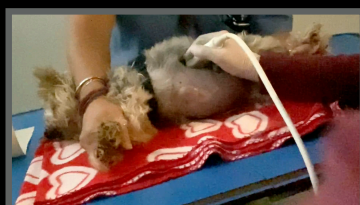2



Lilly, FS, 12 years

Another patient, to show the position of the probe

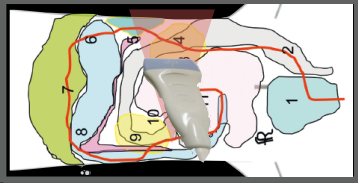
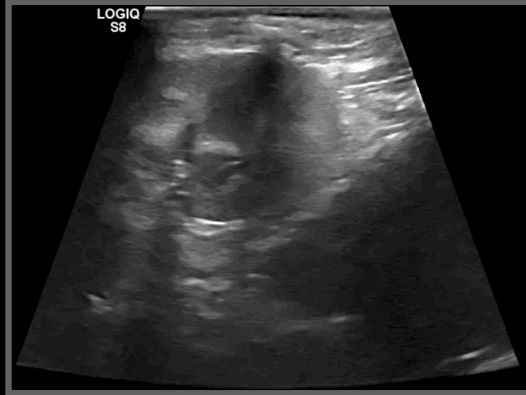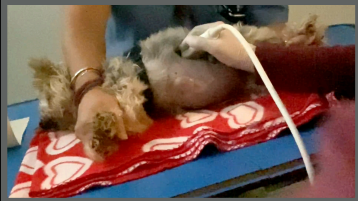3



Lilly, FS, 12 years

Another patient, to show the position of the probe

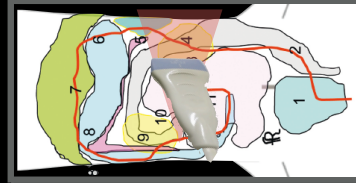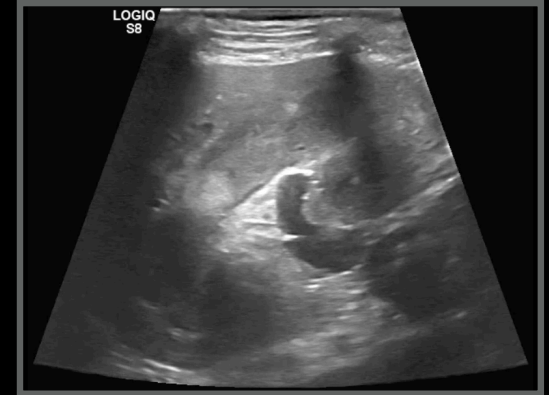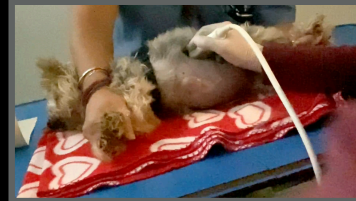3-4



Lilly, FS, 12 years

Another patient, to show the position of the probe

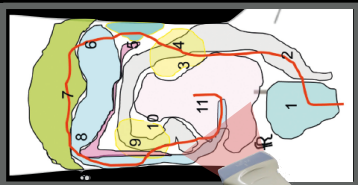
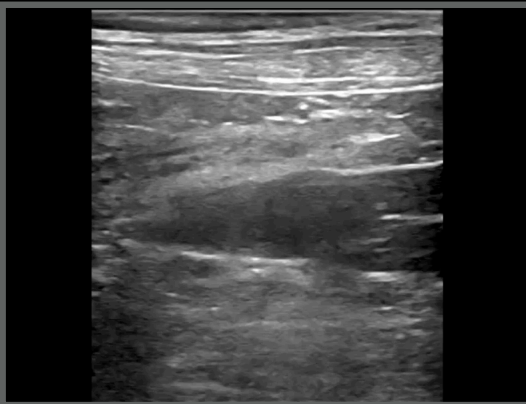
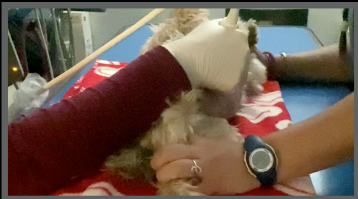4



Lilly, FS, 12 years

Another patient, to show the position of the probe

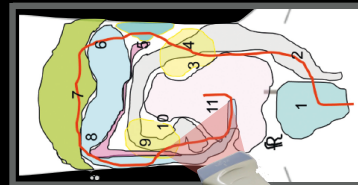
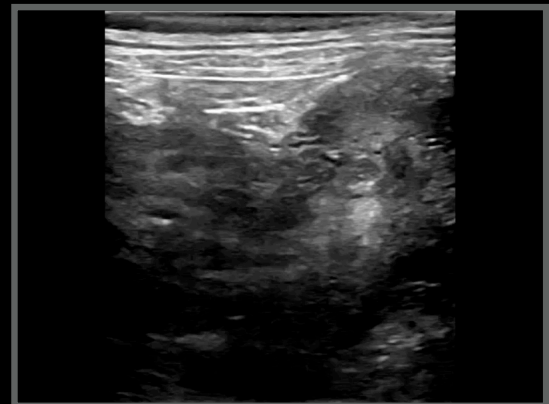
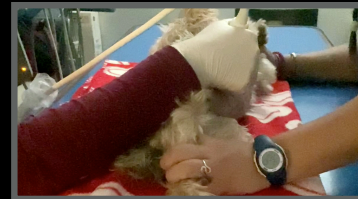12



Lilly, FS, 12 years

Another patient, to show the position of the probe

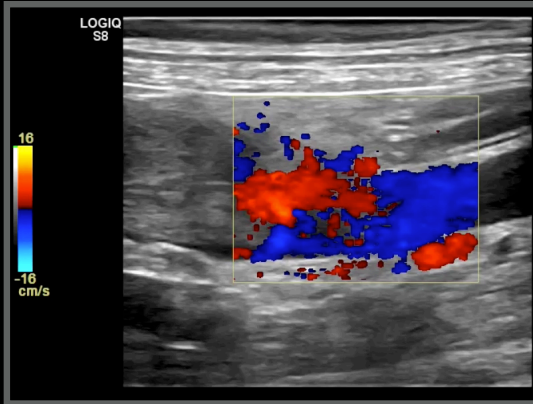
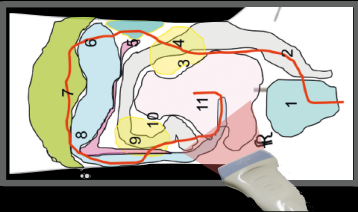
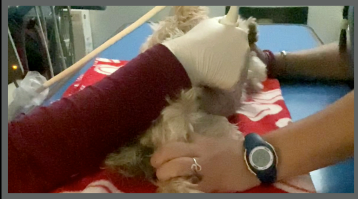9-12



Lilly, FS, 12 years

Another patient, to show the position of the probe

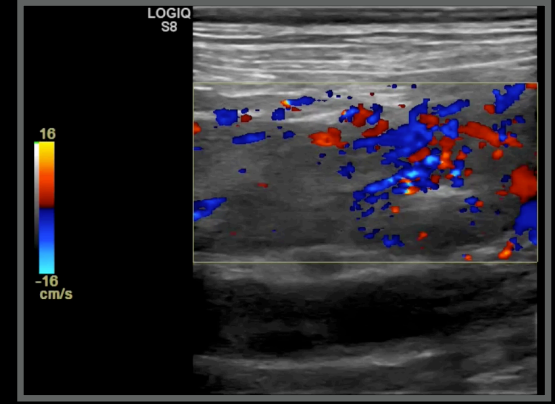
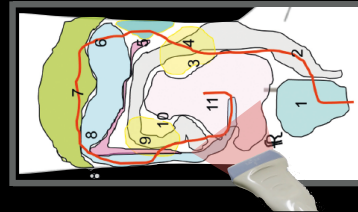
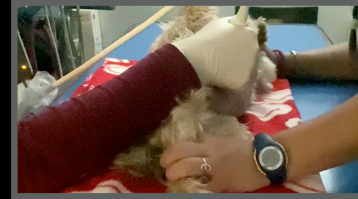9-12



Lilly, FS, 12 years

Another patient, to show the position of the probe

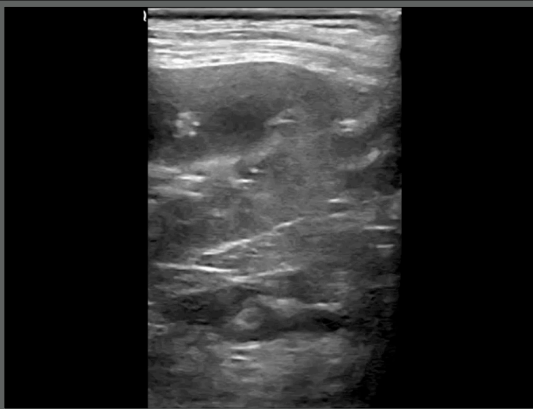
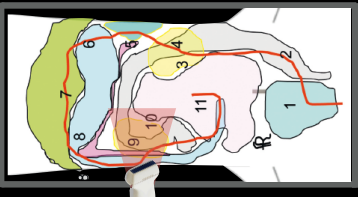
9-12



Lilly, FS, 12 years

Another patient, to show the position of the probe

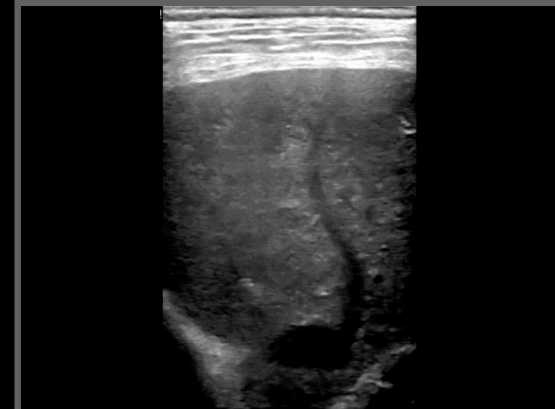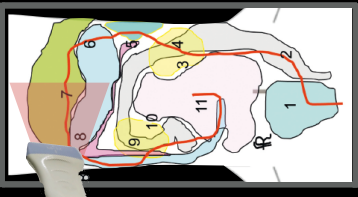
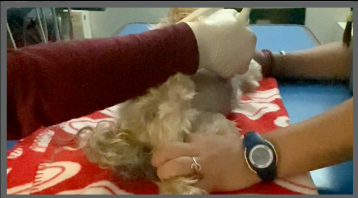9



Lilly, FS, 12 years

Another patient, to show the position of the probe

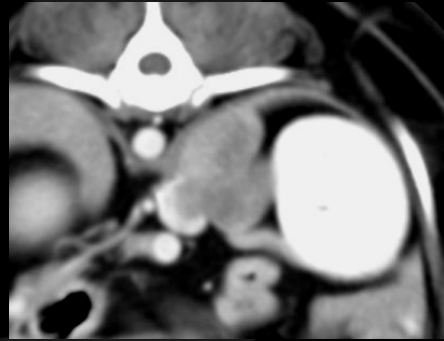
8'



Lilly, Mongrel, FS, 12 years

Ultrasonographic diagnoses:

- Mass invading the caudal vena cava
- Extending to the left renal vein
- Likely arising from the left adrenal gland
- Suspected severely atrophied right adrenal gland



Conclusions:

- US suspicion confirmed on CT
- Adenocarcinoma diagnoses on FNA

Characteristics used to define an abdominal mass

- Location
- Opacity
- Mass effect / dislocation
- Mass continuation

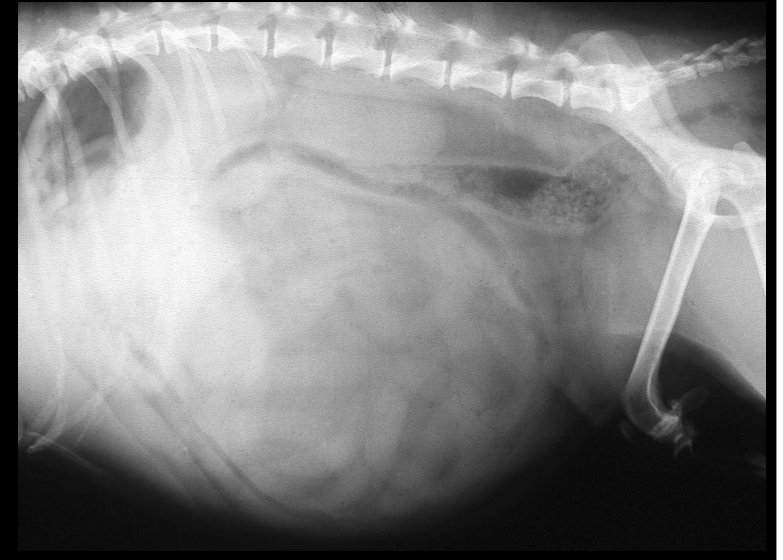



Luna, Mongrel, FS, 11 years

- Progressively over distended abdomen
- Otherwise healthy

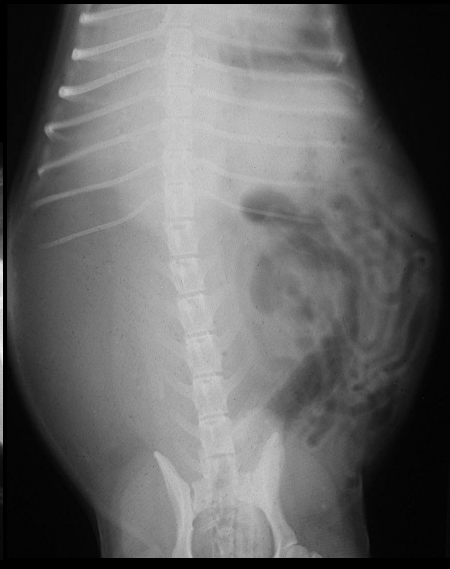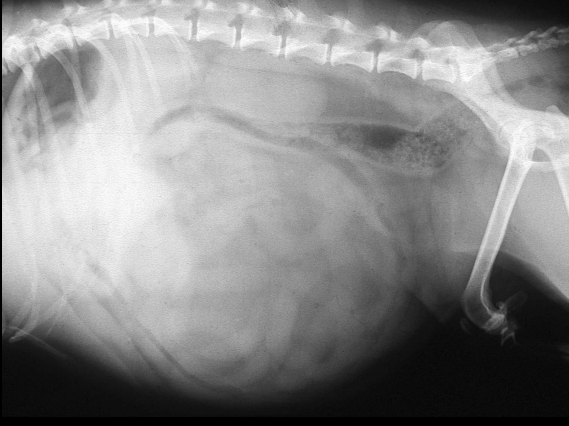


Luna, FS, 11 years



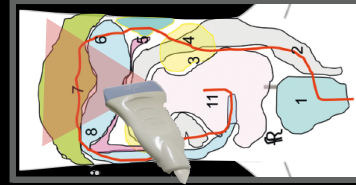
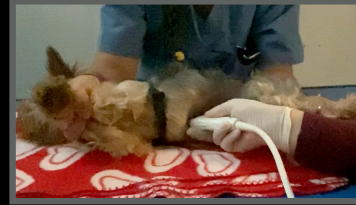

Luna, FS,
11 years

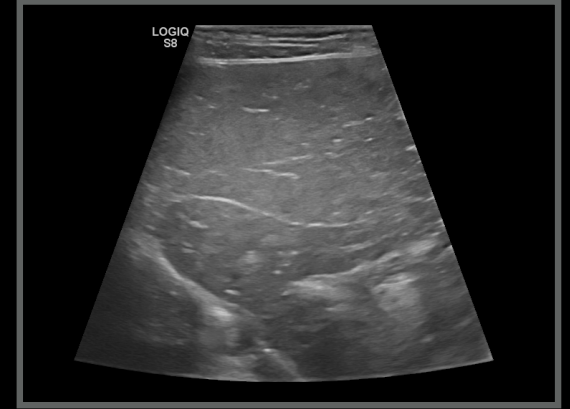

Luna, FS, 11 years

Another patient, to show the position of the probe



6-7 long

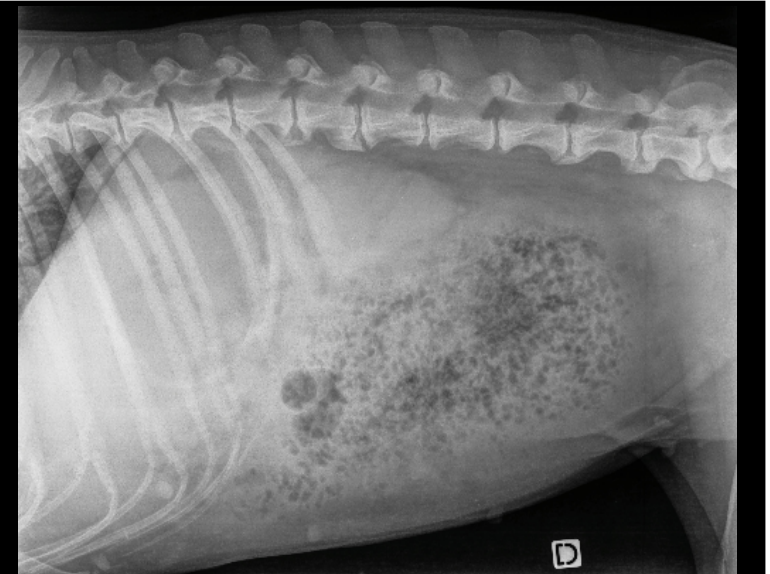



Lu, Malinois, FI, 5 year

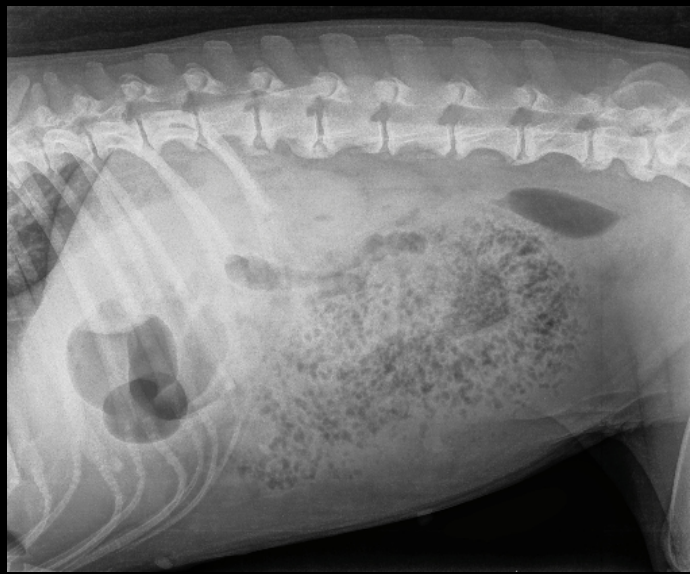

• Acute abdomen



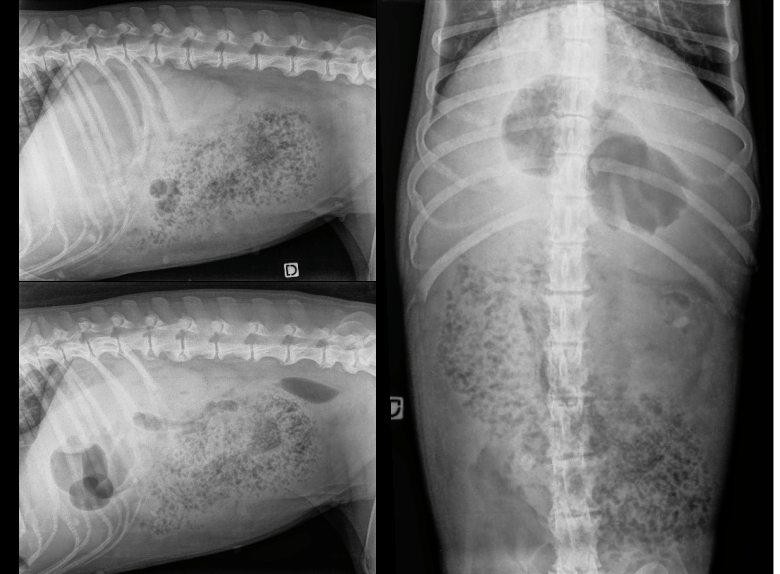
Lu, FI, 5 years



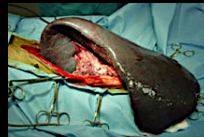Lu, FI, 5 years



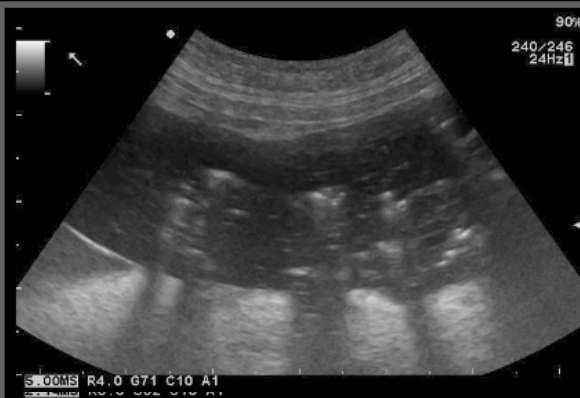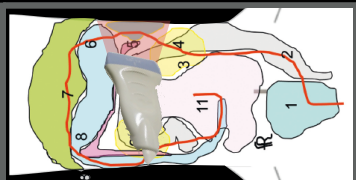
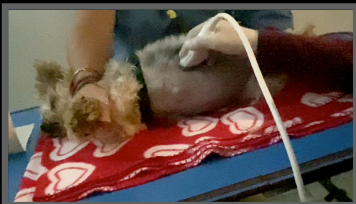Lu, FI, 5 years



Luna, FI, 5 years



Another patient, to show the position of the probe



5

Primary splenic torsion in dogs: 102 cases (1992–2014)

JAVMA • Vol 248 • No. 6 • March 15, 2016

Whitney DeGroot DVM
 Michelle A. Giuffrida VMD
 Jacob Rubin DVM
 Jeffrey J. Runge DVM
 Amy Zide BS
 Philipp D. Mayhew BVMS&S
 William T. N. Culp VMD
 Kelley Thieman Mankin DVM, MS
 Pierre M. Amsellem DVM, MS
 Brandi Petrukovich DVM
 P. Brendon Ringwood DVM, MS
 J. Brad Case DVM, MS
 Ameet Singh DVM, DVSC

RESULTS

93 of the 102 (91.2%) dogs survived to hospital discharge. German Shepherd Dogs (24/102 [23.5%]), Great Danes (15/102 [14.7%]), and English Bulldogs (12/102 [11.8%]) accounted for 50% of cases. Risk factors significantly associated with death prior to hospital discharge included septic peritonitis at initial examination (OR, 32.4; 95% confidence interval [CI], 2.1 to 502.0), intraoperative hemorrhage (OR, 22.6; 95% CI, 1.8 to 289.8), and postoperative development of respiratory distress (OR, 35.7; 95% CI, 2.7 to 466.0). Histopathologic evidence of splenic neoplasia was not found in any case.

CONCLUSIONS AND CLINICAL RELEVANCE

Results suggested that the prognosis for dogs undergoing splenectomy because of PST was favorable. Several risk factors for death prior to discharge were identified, including preexisting septic peritonitis, intraoperative hemorrhage, and postoperative development of respiratory distress. (*J Am Vet Med Assoc* 2016;248:661–668)

Characteristics used to define an abdominal mass

- Location
- Opacity
- Mass effect / dislocation
- Mass continuation



Newton, DSH, FI, 16 years

- Distended abdomen
- One episode of vomiting
- Less active
- Indoor only

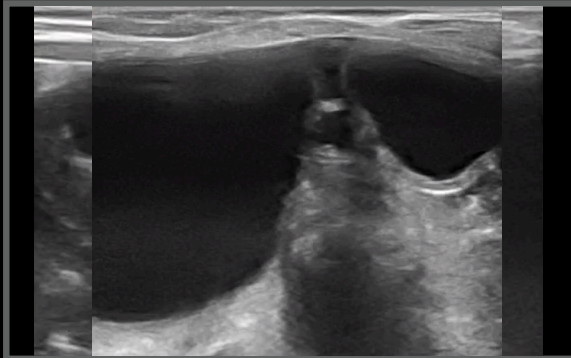
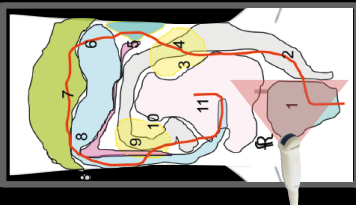
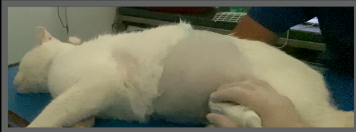

Newton, FI, 16 years



Another patient, to show the position of the probe

1



Newton, DSH, FI, 16 years

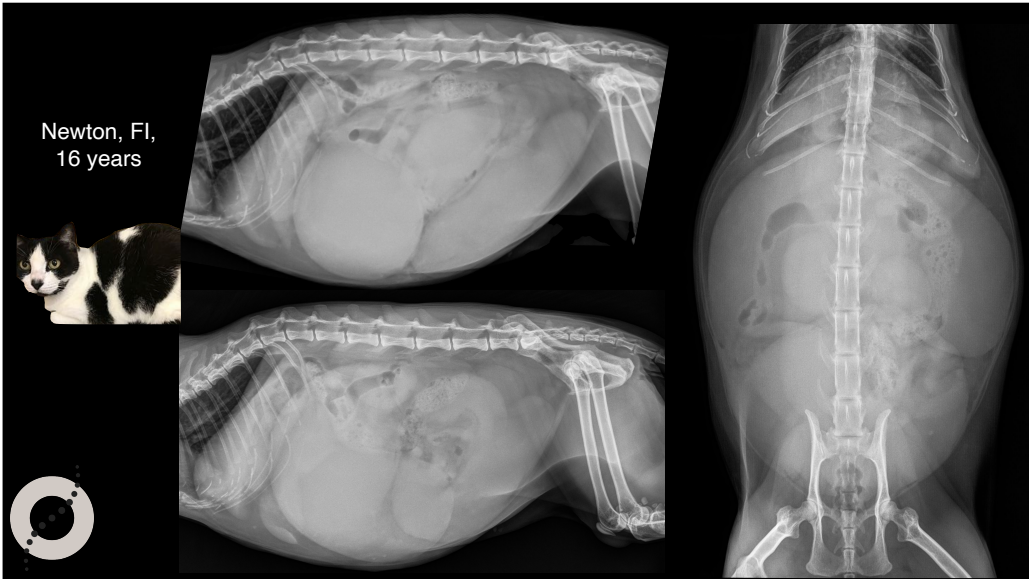
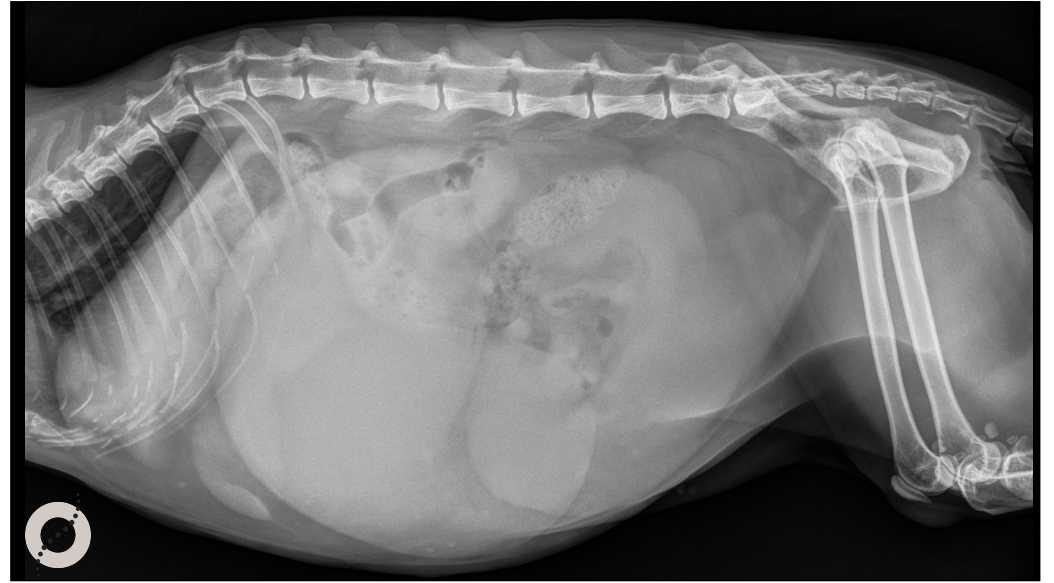
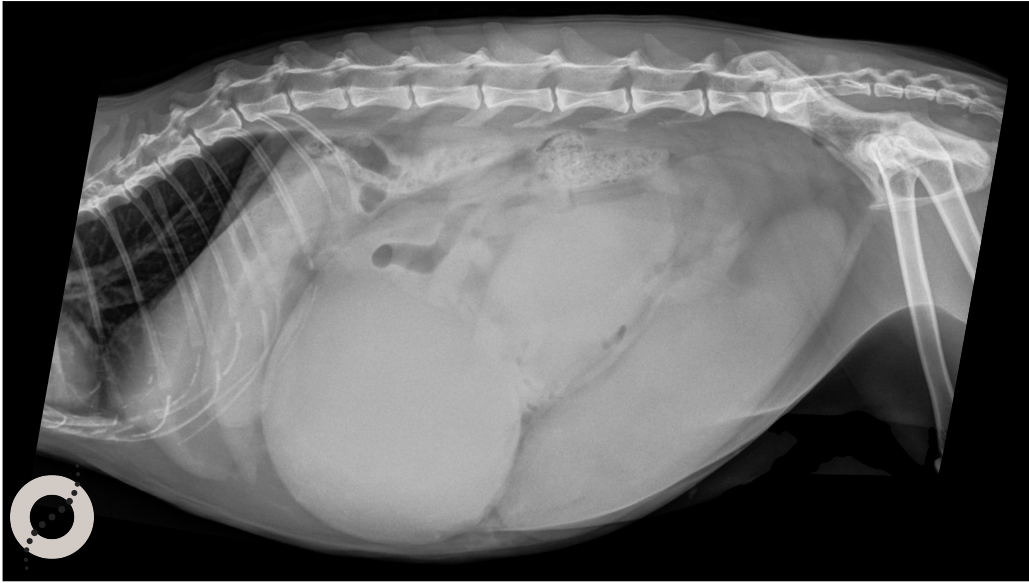
Ultrasonographic diagnoses:

- “Double” urinary bladder, only one has a neck region
- Cystic structure inside a fluid filled structure?
- The kidneys were unremarkable for the age
- Uterus not seen, could be involved?

Conclusions:

- ???
- Pyometra/hydrometra?





Uterine torsion

- Pregnancy predisposing factor
- One overdistended by fluid horn
- Focal eccentric "lump"

[Bilateral segmental aplasia with unilateral uterine horn torsion in a Pomeranian bitch.](#)
 Nakamura K, Yamasaki M, Osaki T, Ohta H, Sasaki N, Aoshima K, Kimura T, Takiguchi M.
 J Am Anim Hosp Assoc. 2012 Sep-Oct;48(5):327-30. doi: 10.5326/JAAHA-MS-5771. Epub 2012 Jul 27.
 PMID: 22843825

Characteristics used to define an abdominal mass

- Location
- Opacity
- Mass effect / dislocation
- Mass continuation

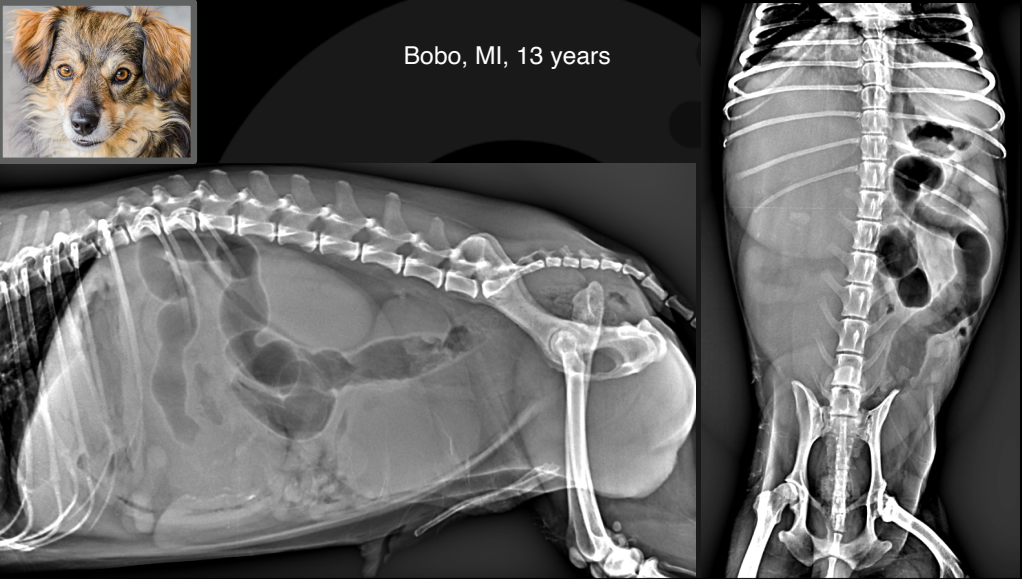
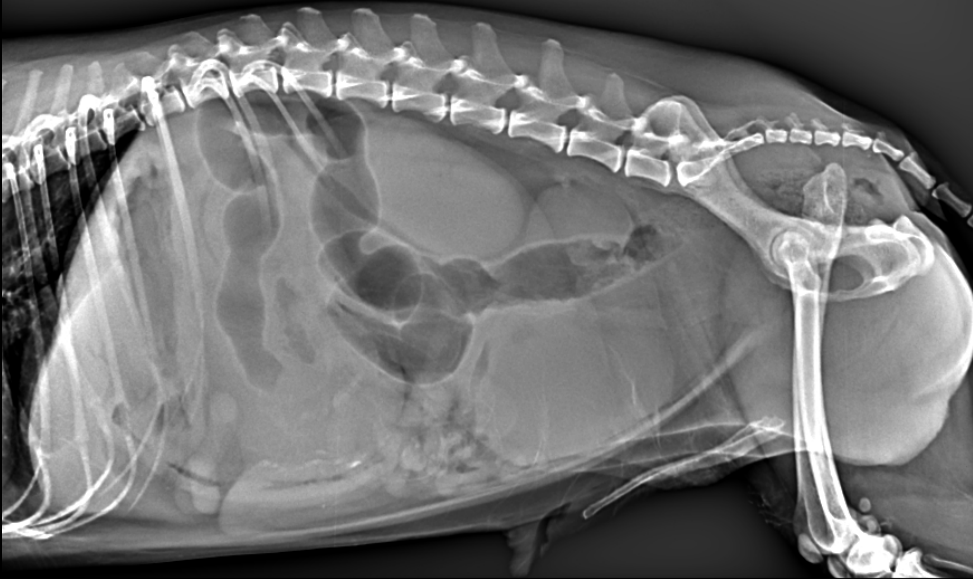

Bobo, Mongrel, MI, 13 years

- Progressively distended abdomen for the last weeks
- Acute abdomen



Newton, FI, 16 years

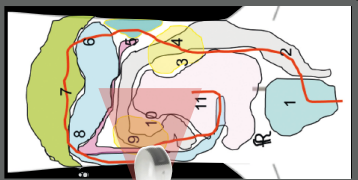
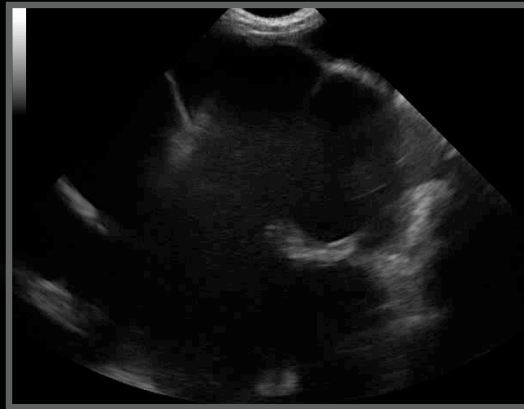

Bobo, MI, 13 years

Bobo, MI, 13 years

Another patient, to show the position of the probe

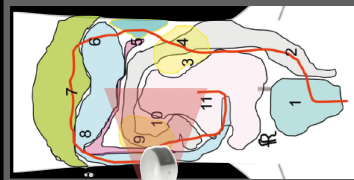
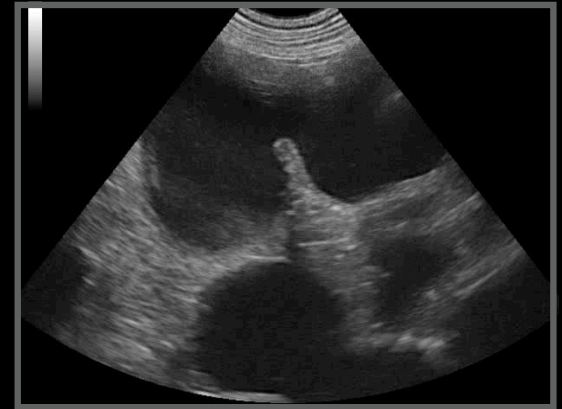9



Bobo, MI, 13 years

Another patient, to show the position of the probe

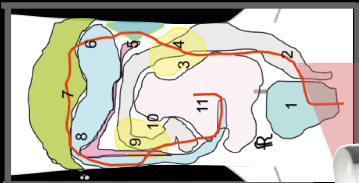
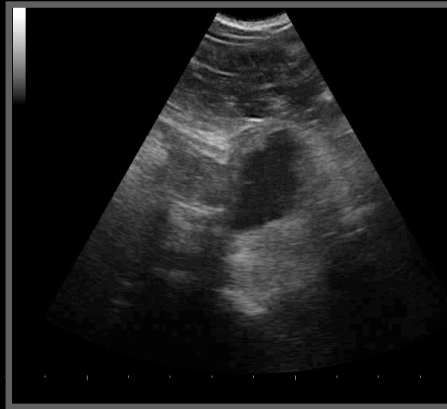
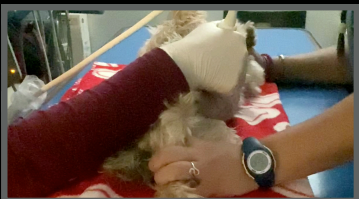9



Bobo, MI, 13 years

Another patient, to show the position of the probe

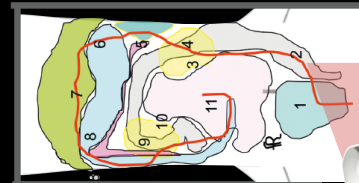
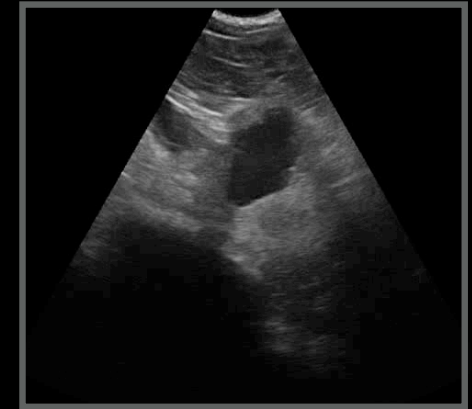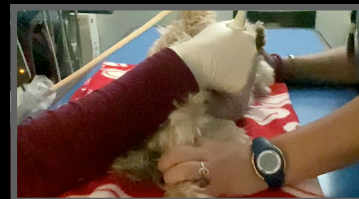1



Bobo, MI, 13 years

Another patient, to show the position of the probe

1



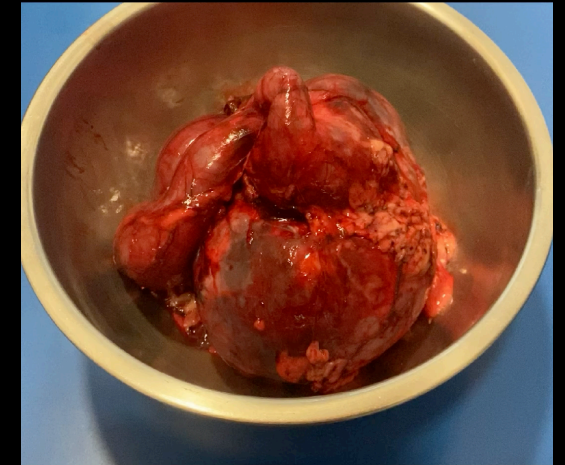
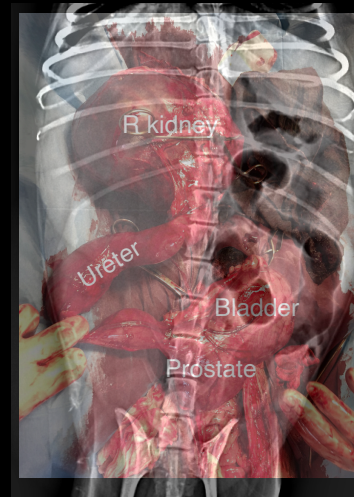
Bobo, Mongrel, MI, 13 years

Ultrasonographic diagnoses:

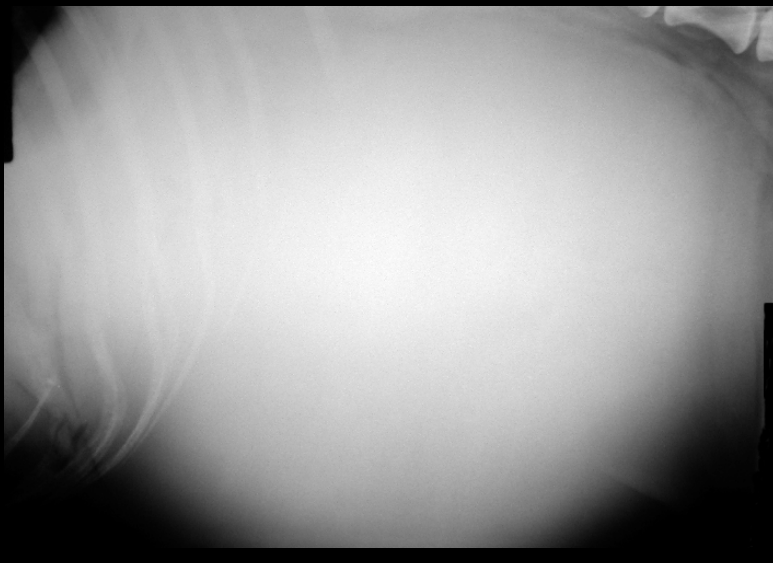
- Severe right sided ureter
- Severely over distended right ureter
- Prostatic termination of the right ureter



Bobo, Mongrel, MI, 13 years



Mass or
abdominal effusion?



Thank you



Diagnostic Mindset

www.diagnosticmindset.com