


Lo spazio retroperitoneale, una continua sorpresa



Diagnostic Mindset



Giliola Spattini
DVM, PhD, DECVDI

Objectives

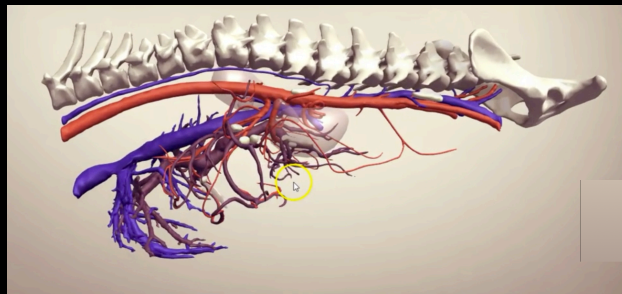
Retroperitoneal space is often neglected

Often a change is very relevant for the health of the patient

Some normal structures can be mistaken for pathologies



Retroperitoneal organs

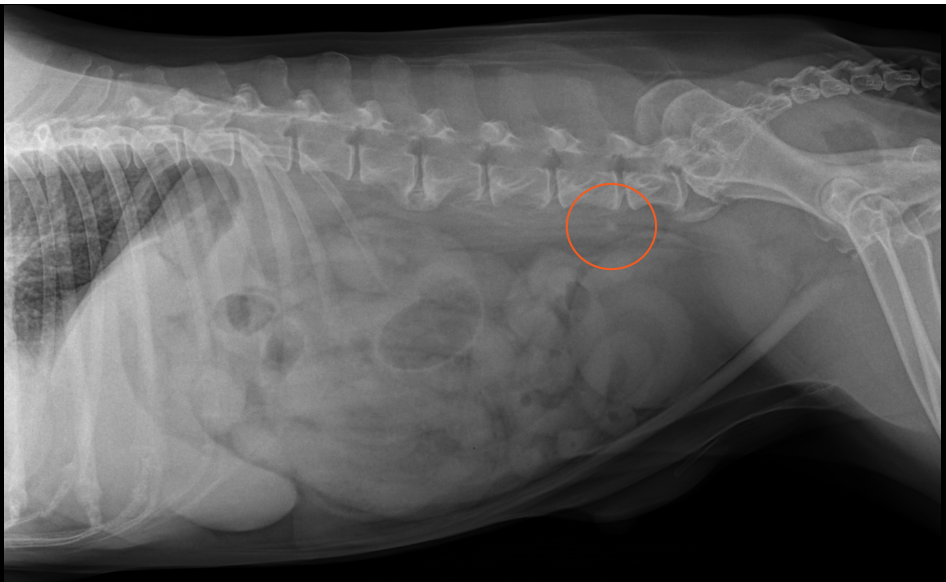


Frazier, Mongrel, MN, 12 years

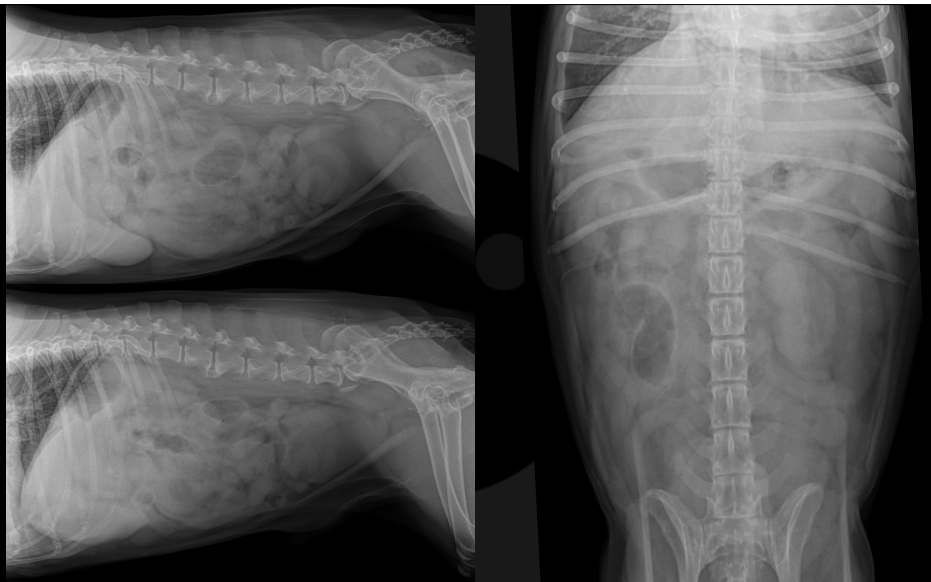
- Vomiting blood
- Abdominal pain
- History of cardiomegaly
- Medicines: gabapentin, furosemide, pimobendan



Frazier, MN, 12 years

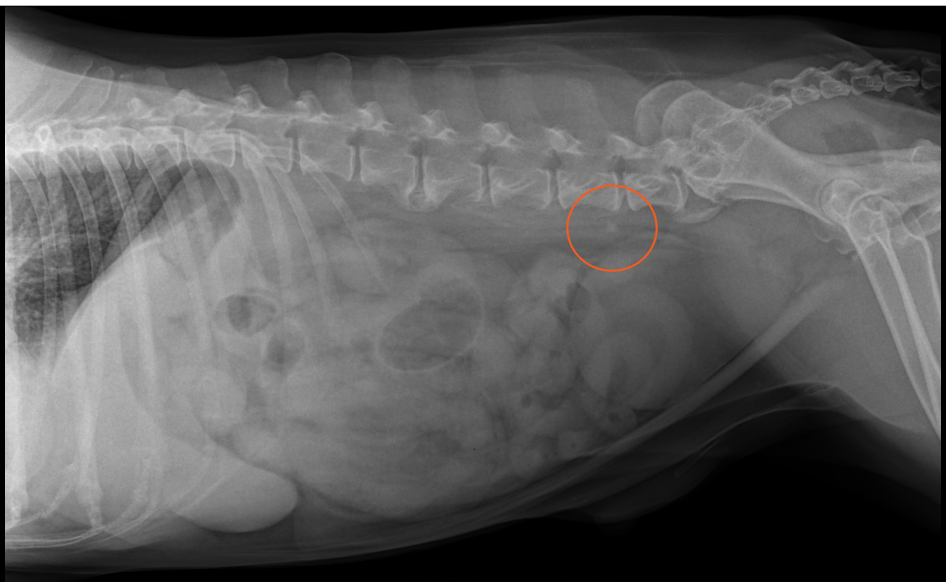


Frazier, MN, 12 years

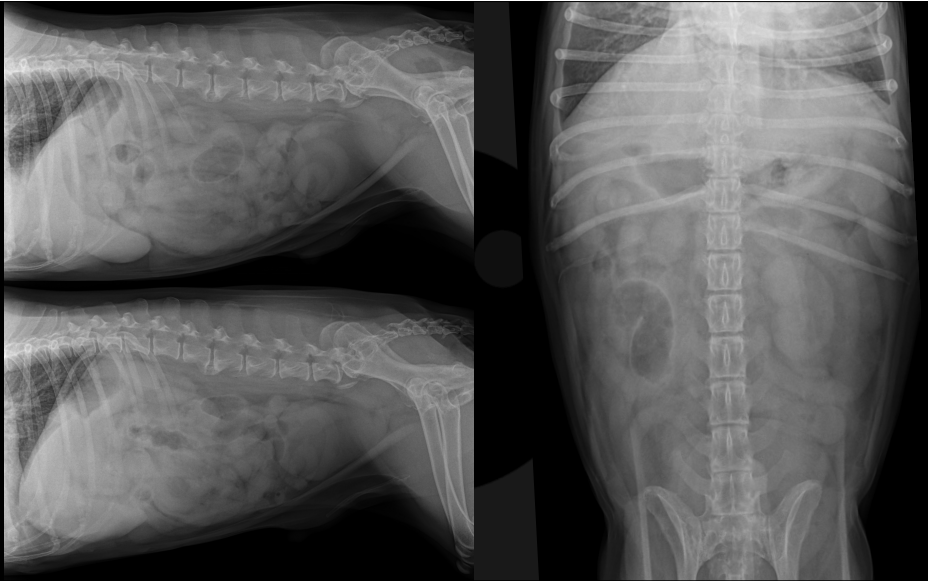


Your evaluation?

Frazier, MN, 12 years

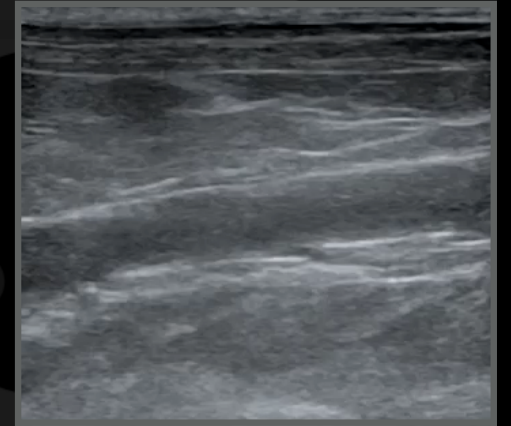
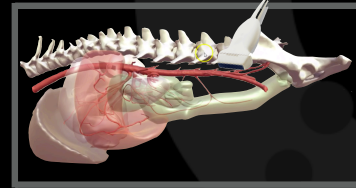
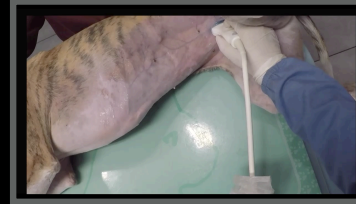

Frazier, MN, 12 years



Frazier, MN, 12 years

Another patient, to show the position of the probe



Aorta Anatomy

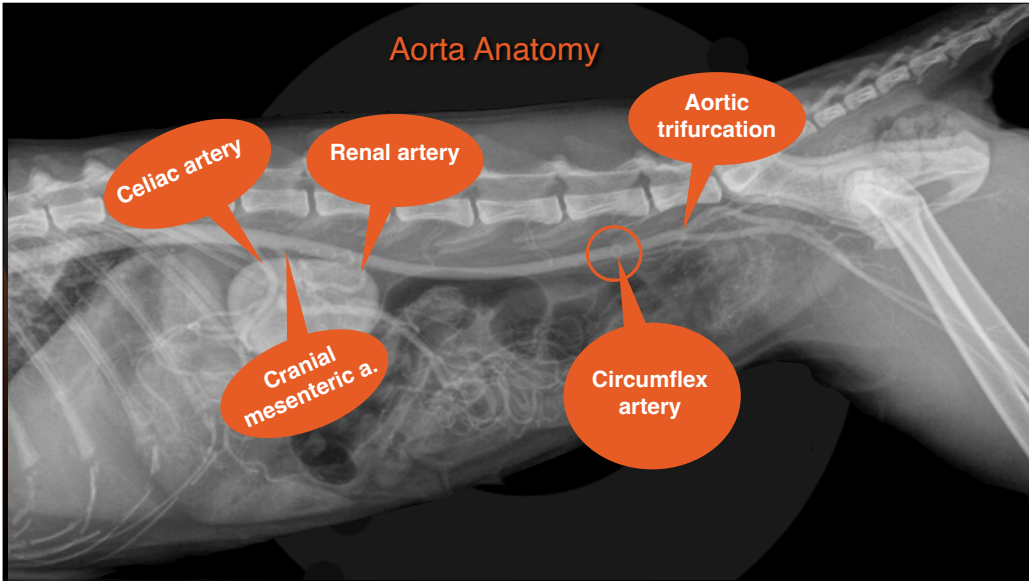
Celiac artery

Renal artery

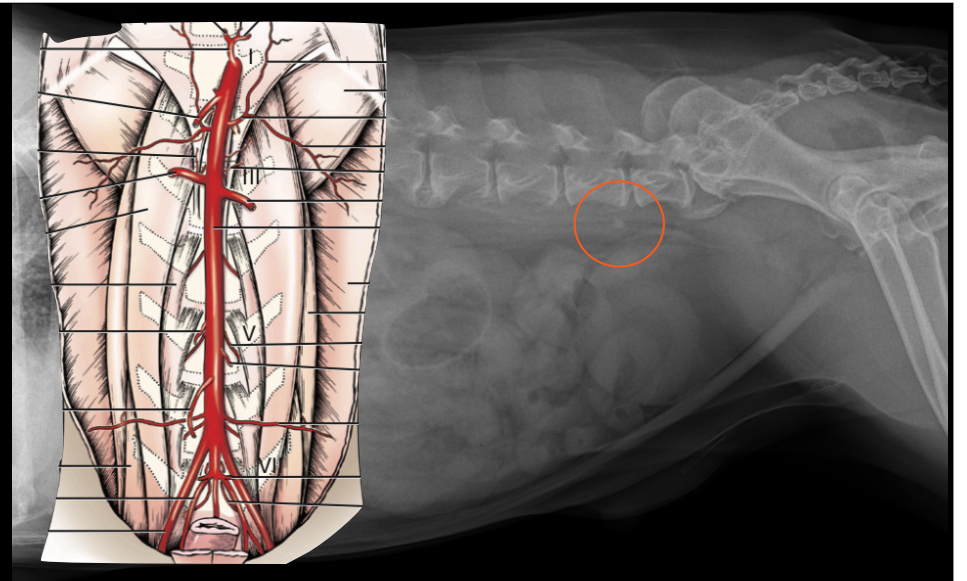
Aortic trifurcation

Cranial mesenteric a.

Circumflex artery



Frazier, MN, 12 years

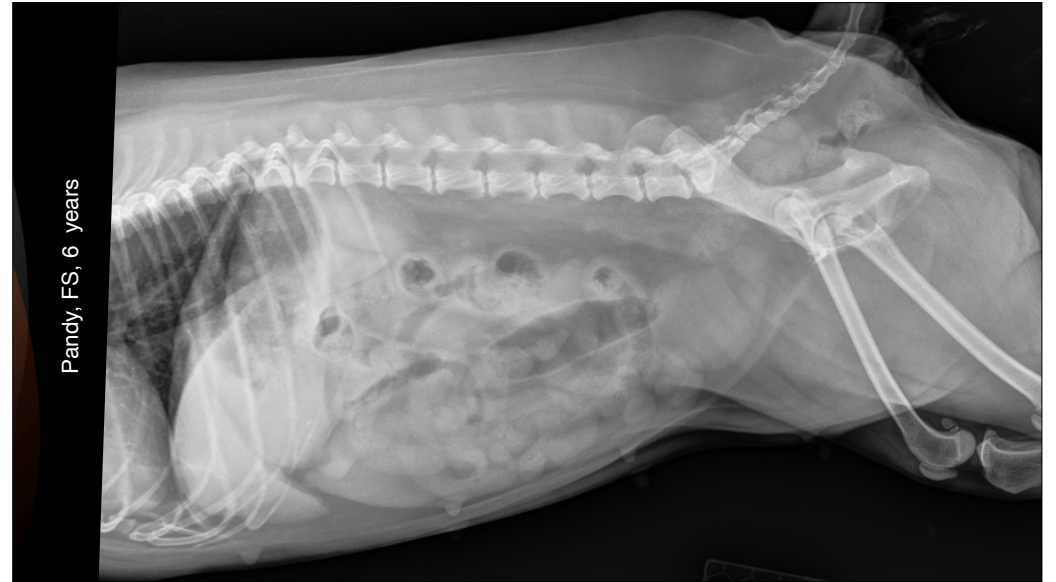


Pandy, Pomeranian, FS, 6 years

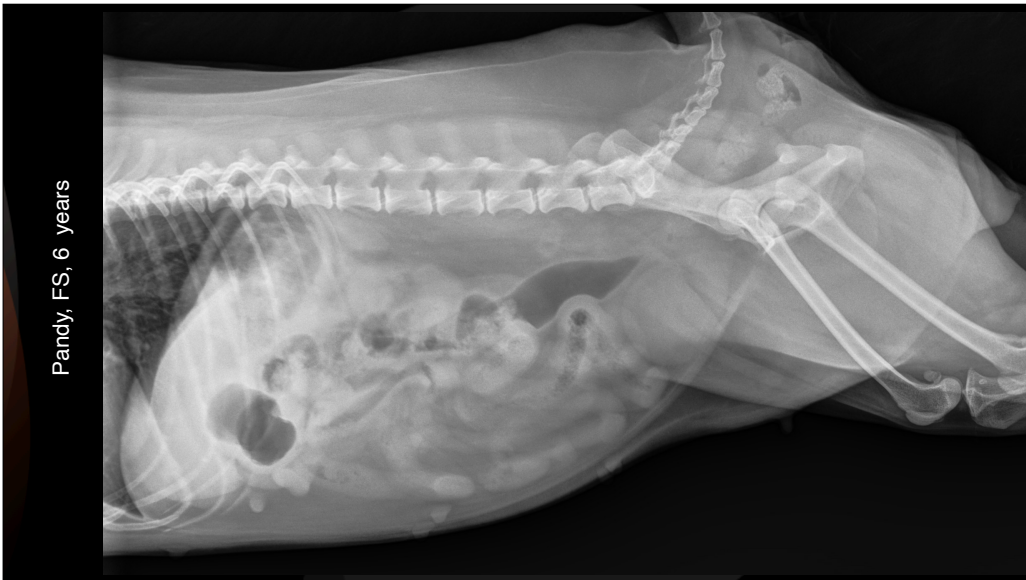Visited by the referring veterinarian
the day before for anxiety

Now circling and whining

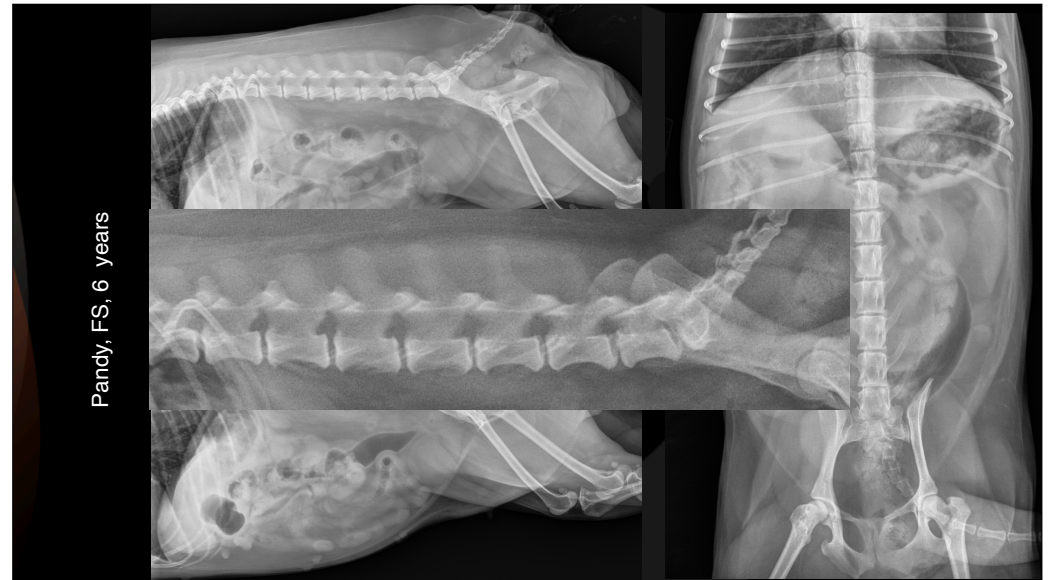
Eaten very little since yesterday



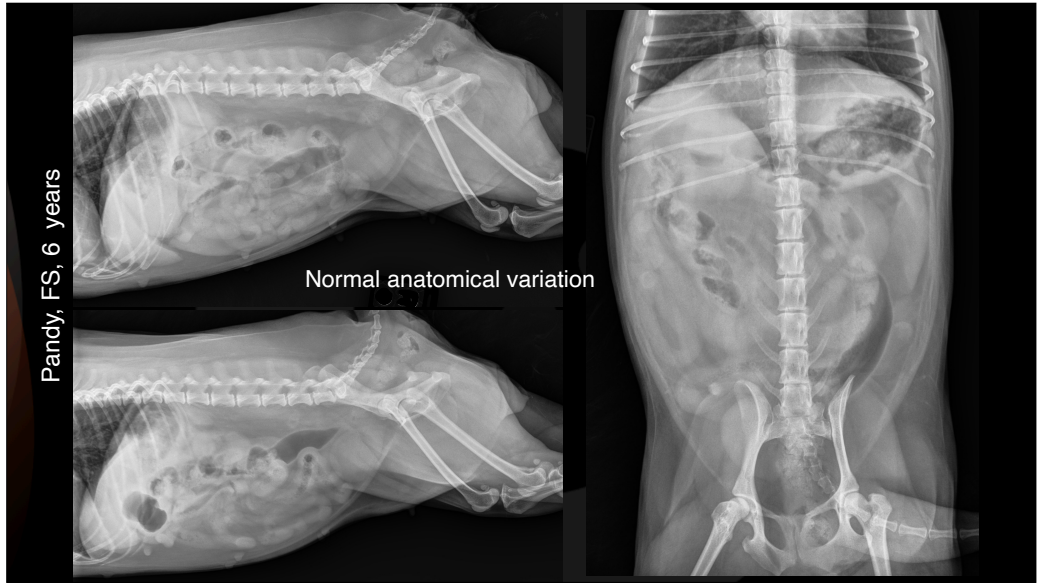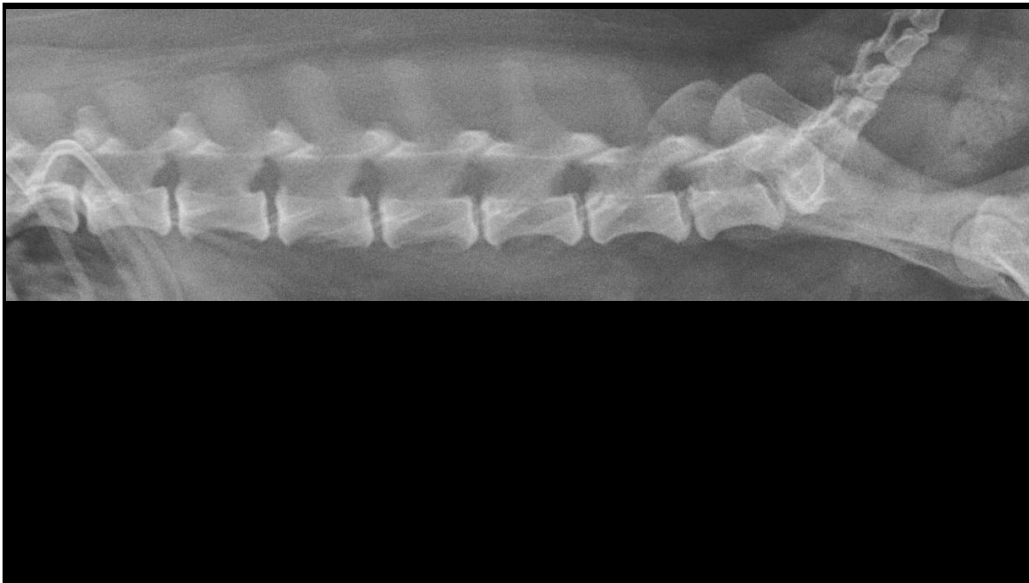
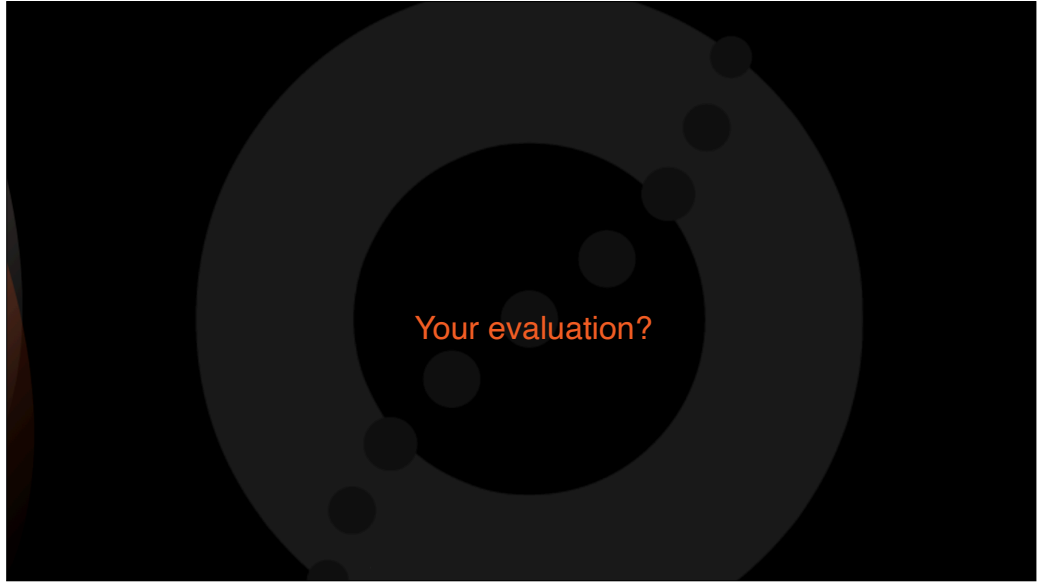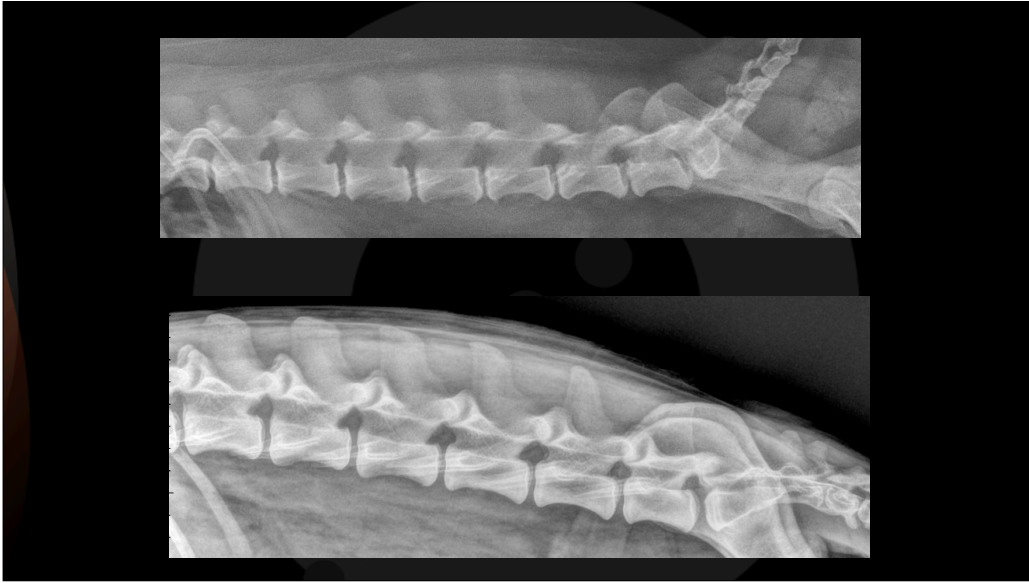
Pandy, FS, 6 years



Pandy, FS, 6 years



Pandy, FS, 6 years

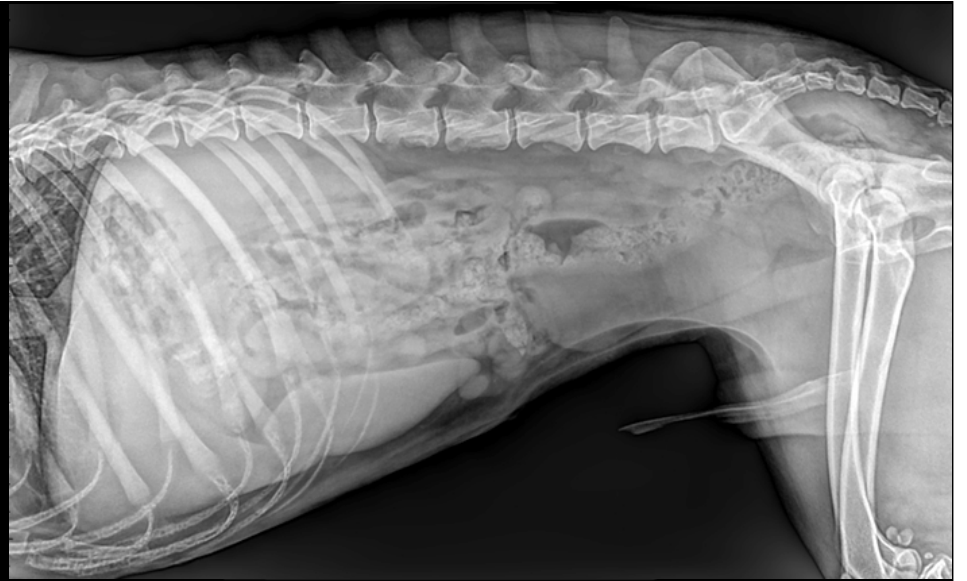


Kim, Breton, MI, 3 years

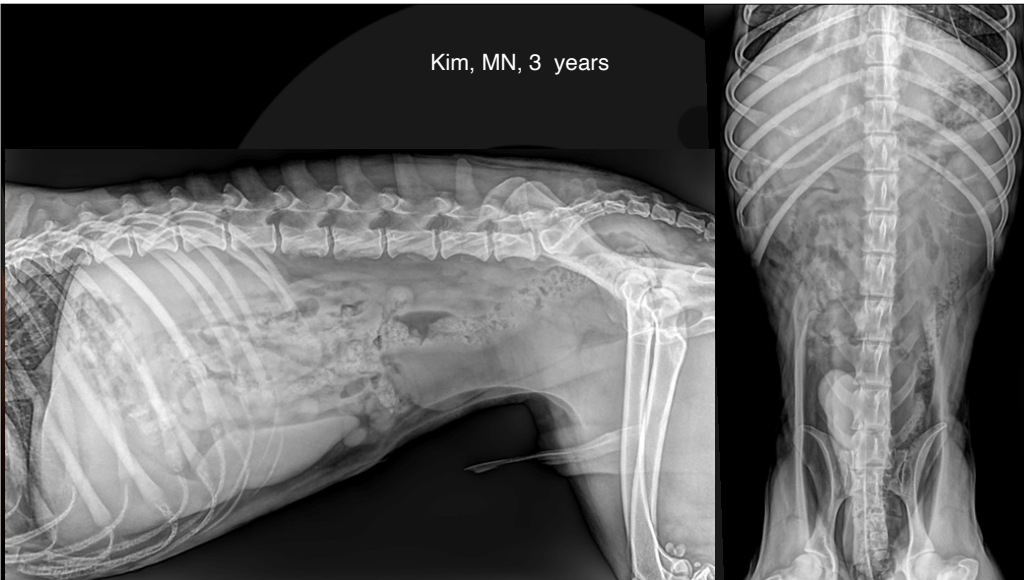- Not jumping
- Seems sad
- He tries to bite when touched



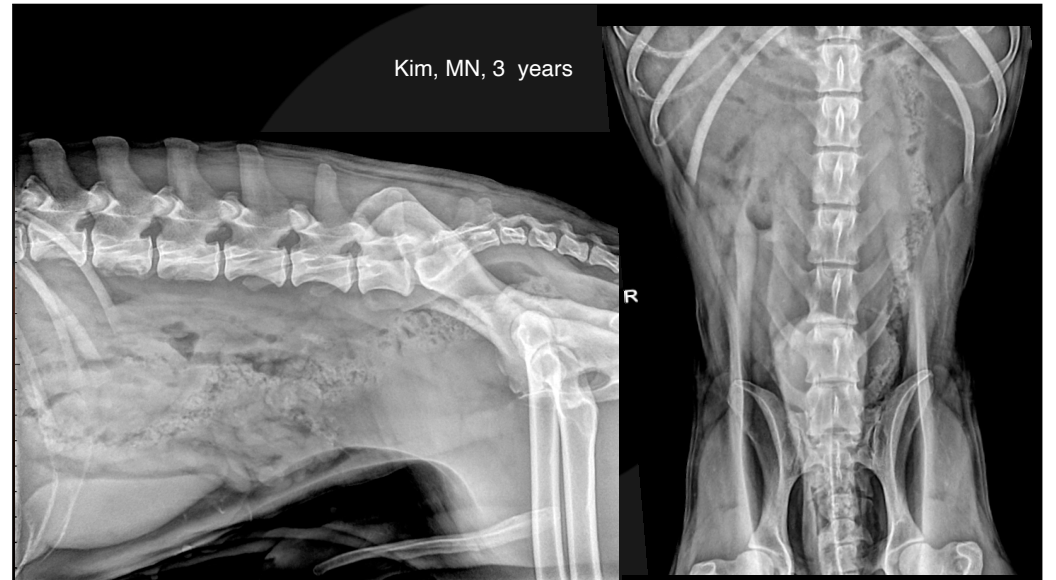Kim, MN, 3 years



Kim, MN, 3 years

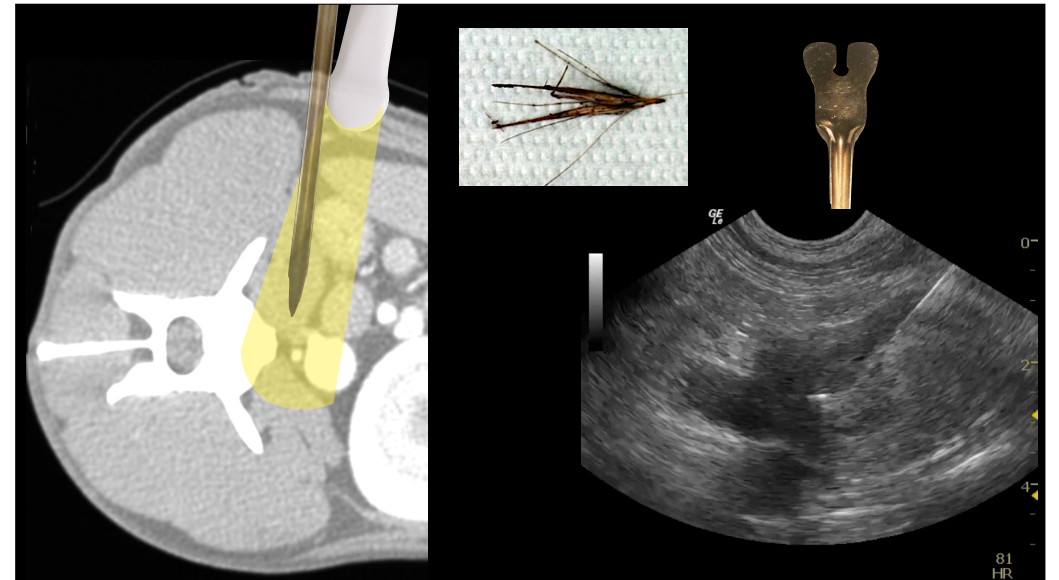
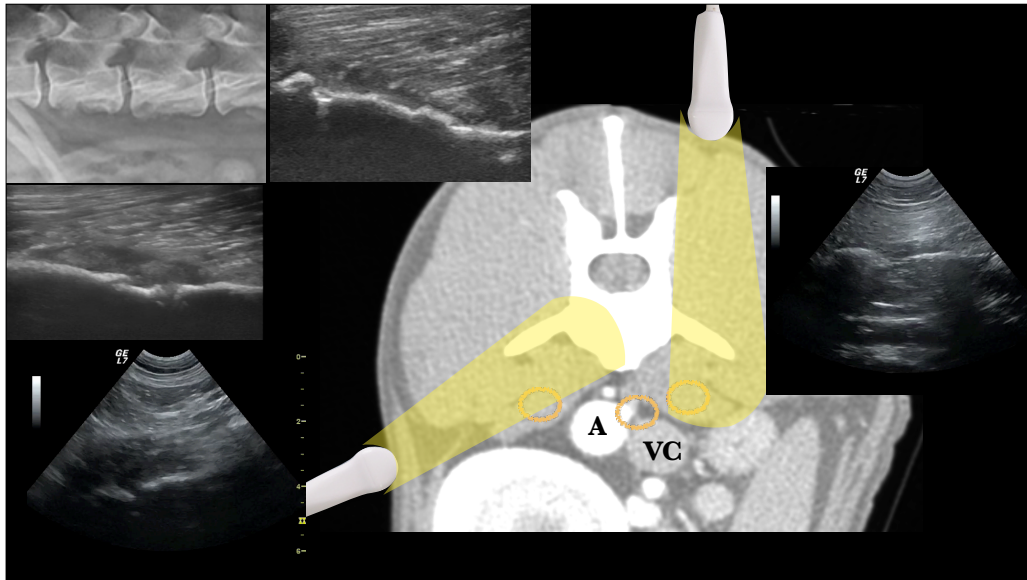


Kim, MN, 3 years



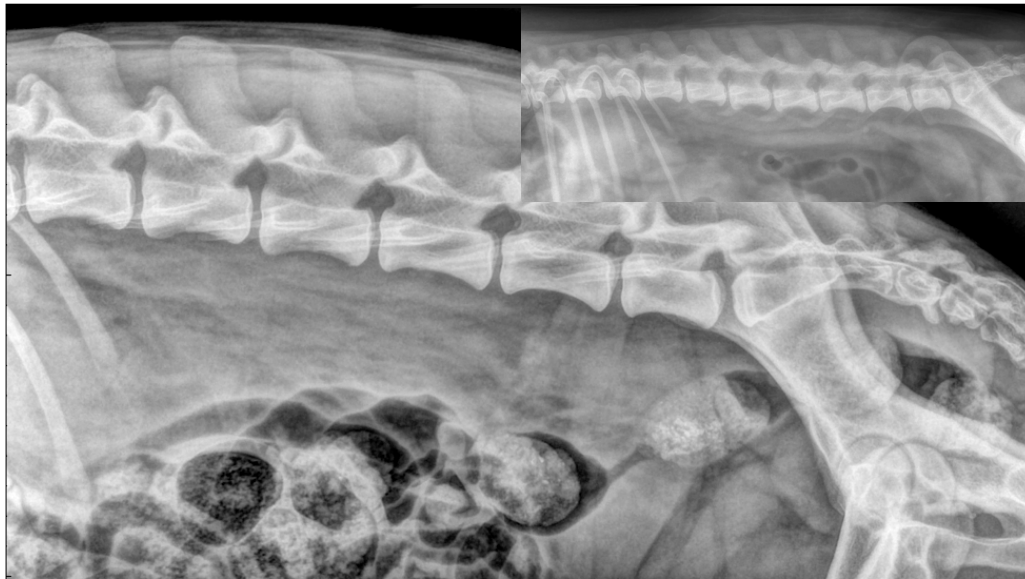
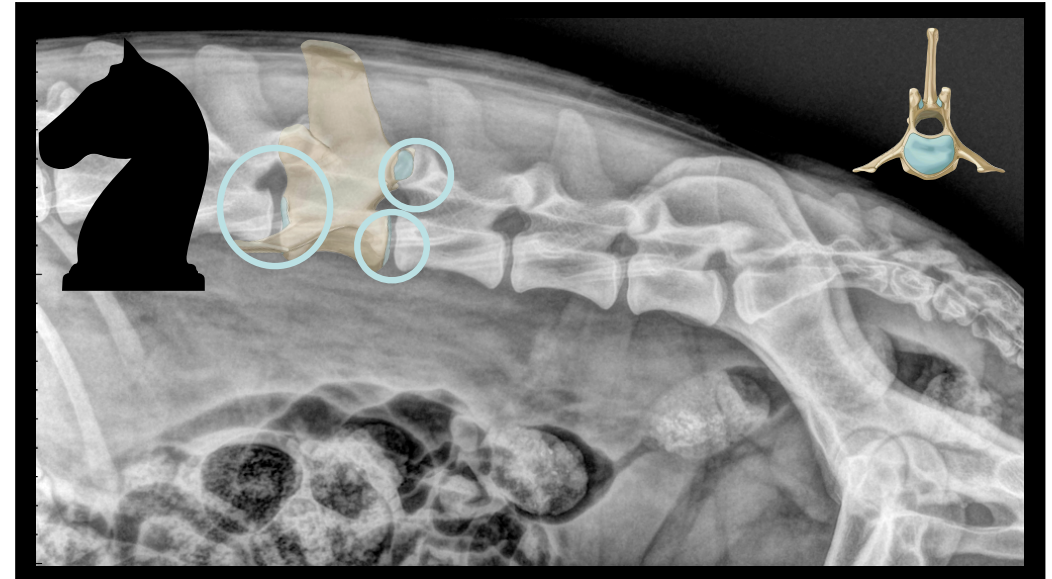
Your evaluation?

Kim, MN, 3 years



Dream, Golden Retriever, MI, 6 years

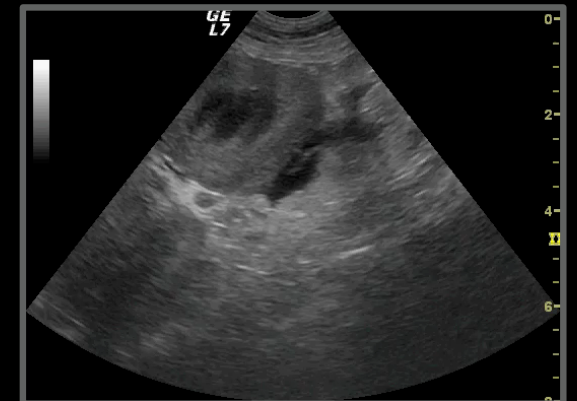
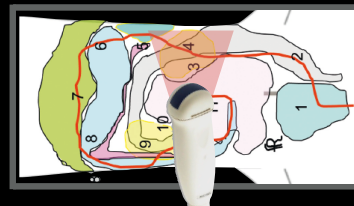
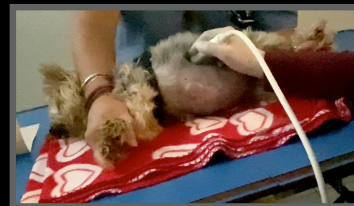- Walking on egg shells
- Seems painful
- Stoic on palpation



Dream, MI, 6 years

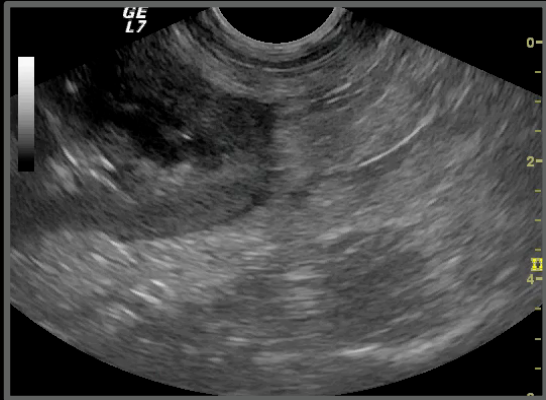
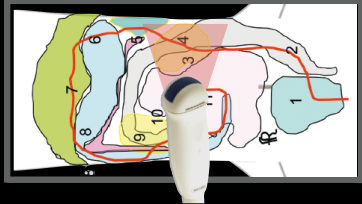
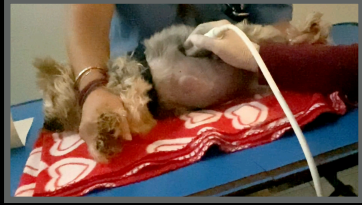

Another patient, to show the position of the probe



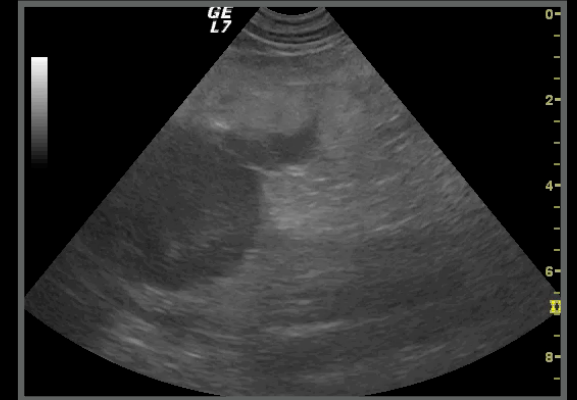
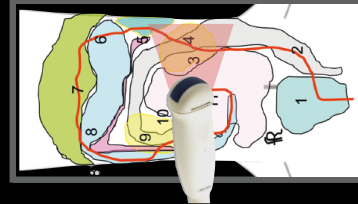
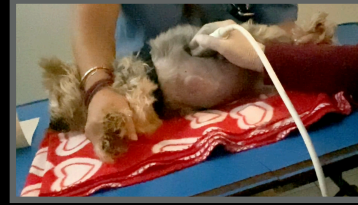Dream, MI, 6 years

Another patient, to show the position of the probe



Dream, MI, 6 years

Another patient, to show the position of the probe



Dream, Golden Retriever, MI, 6 years

Ultrasonographic diagnoses:

- Focal detachment of the left renal capsule
- Retroperitoneal effusion

Conclusions:

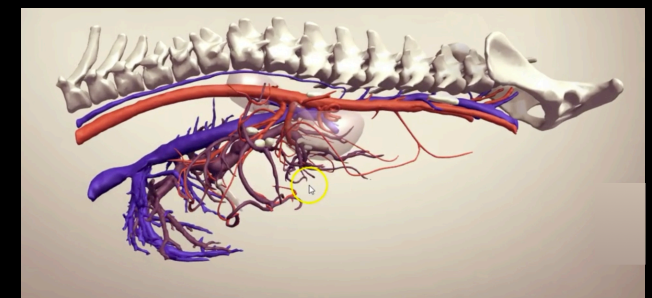

- Possible left renal rupture

What next?

- Systemic pressure measurement: 240/180



Differential diagnoses for retroperitoneal effusion

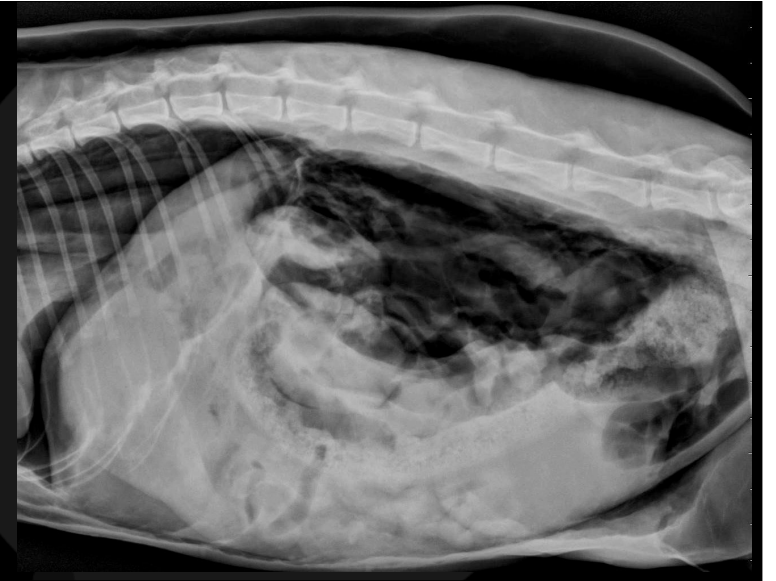

Luna, DSH, FI, 9 months

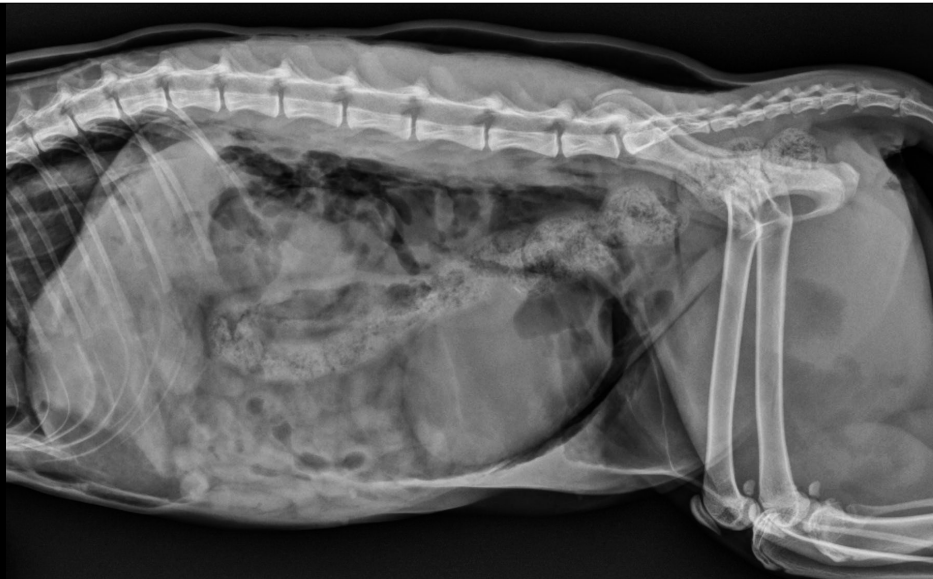- Spaying scheduled
- Aborted due to unstable anaesthesia
- Check for post anaesthetic abdominal pain



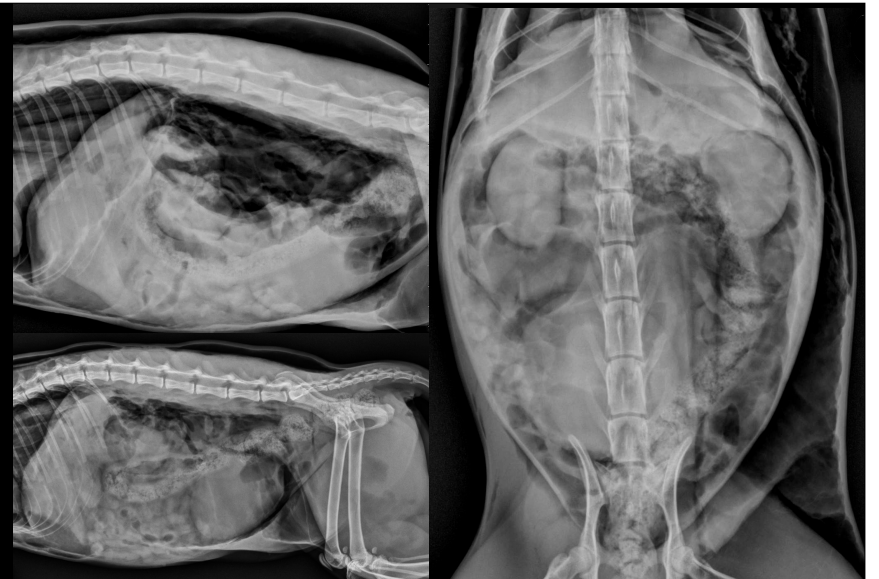
Luna, FI, 9 months



Luna, FI, 9 months

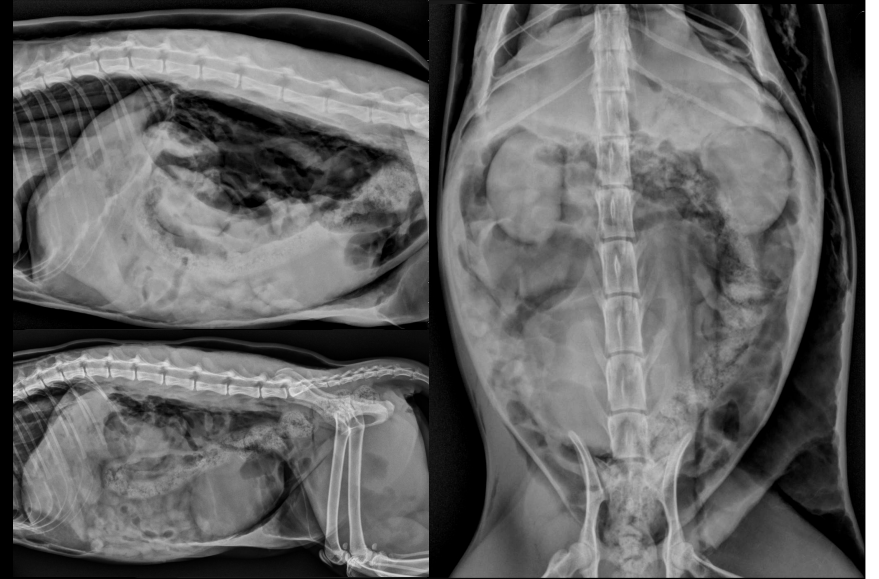


Luna, FI, 9 months



Your evaluation?

Luna, FI, 9 months



Luna, DSH, FI, 9 months

Radiographic diagnoses:

- Pneumoretroperitoneum
- Pneumoderma
- Pneumothorax
- Pneumomediastinum
- Gas in the ventro-caudal aspect of the abdominal wall

Conclusions:

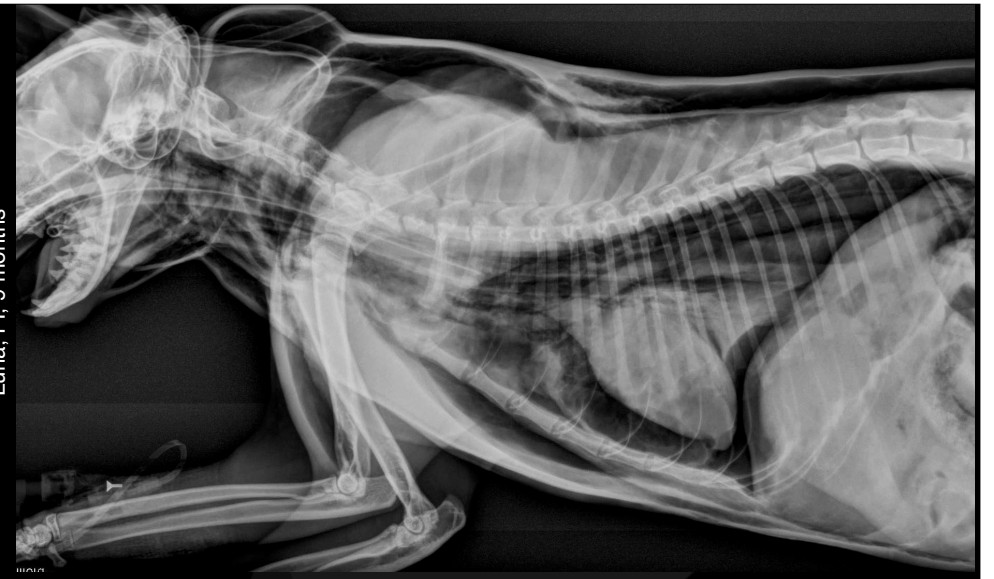- Suspected ruptured trachea

What next?

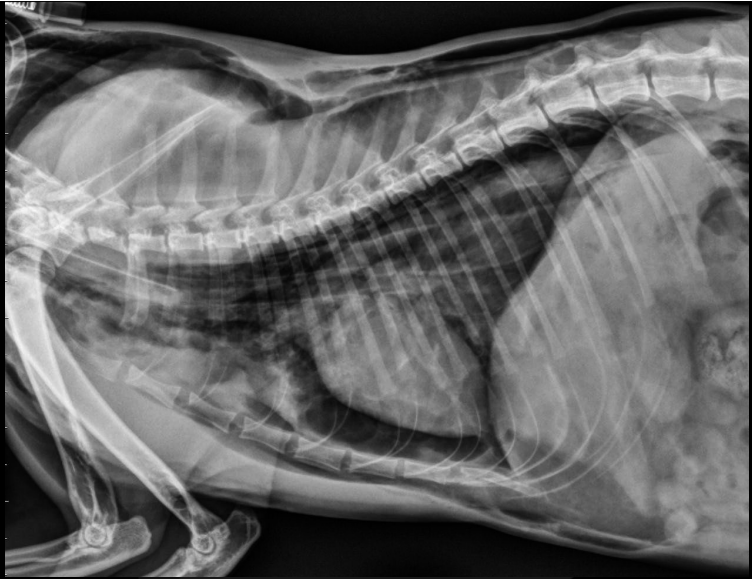- Follow up



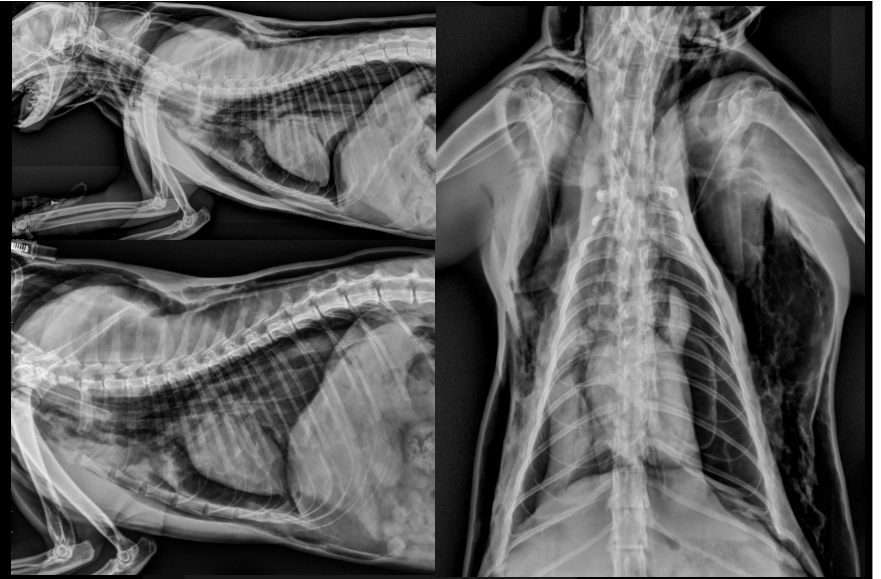
Luna, FI, 9 months



Luna, FI, 9 months

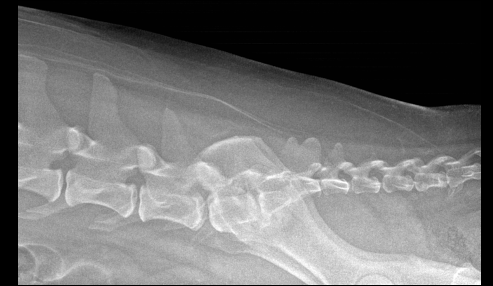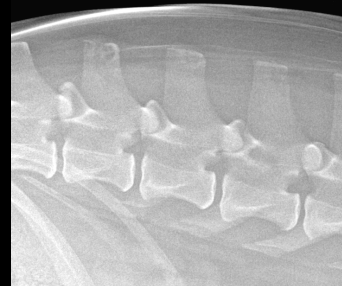

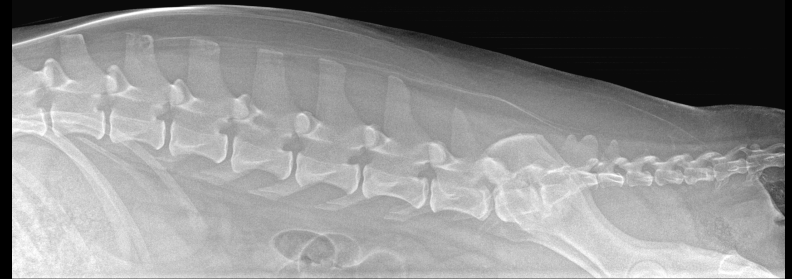
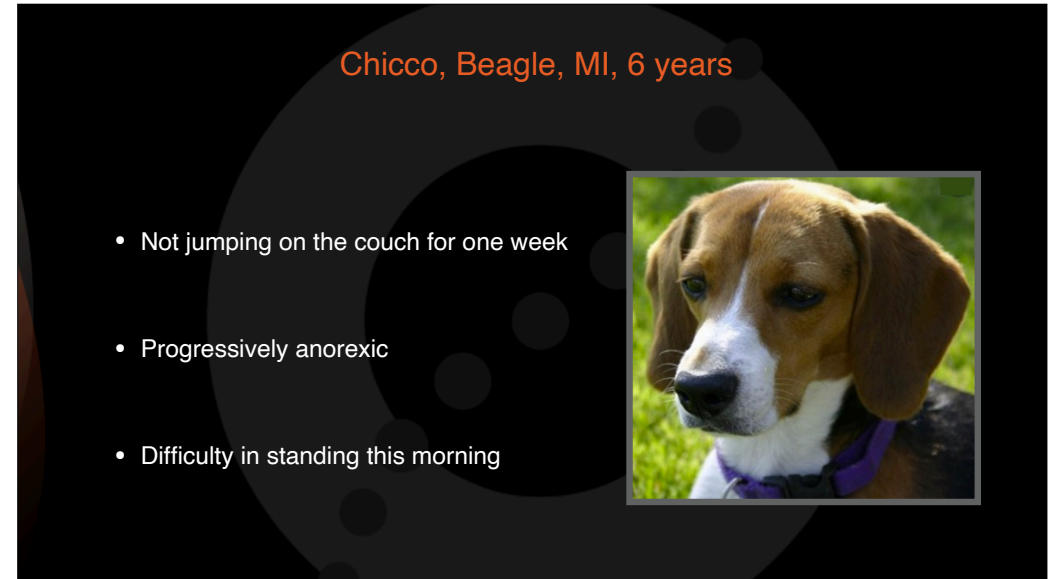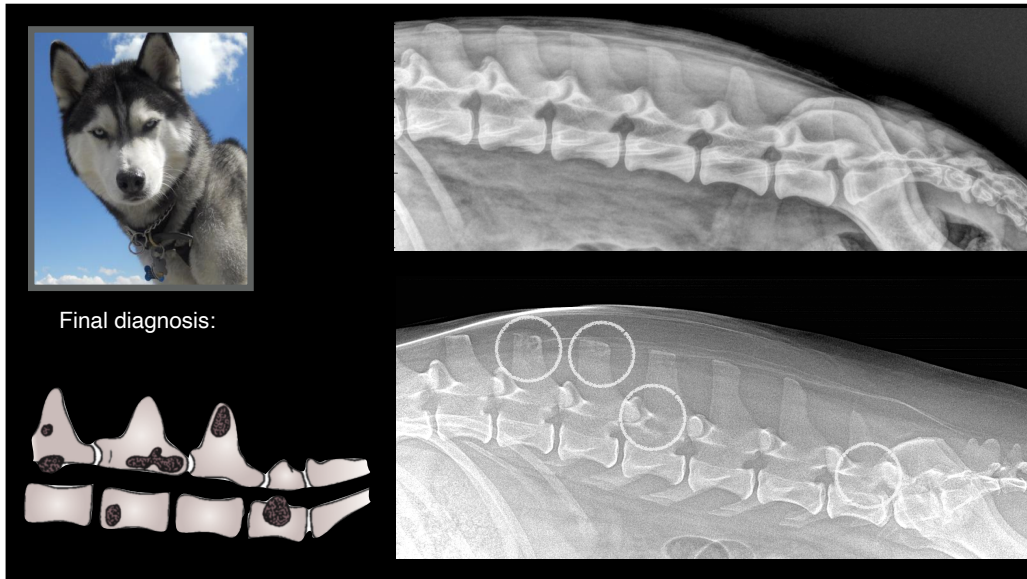
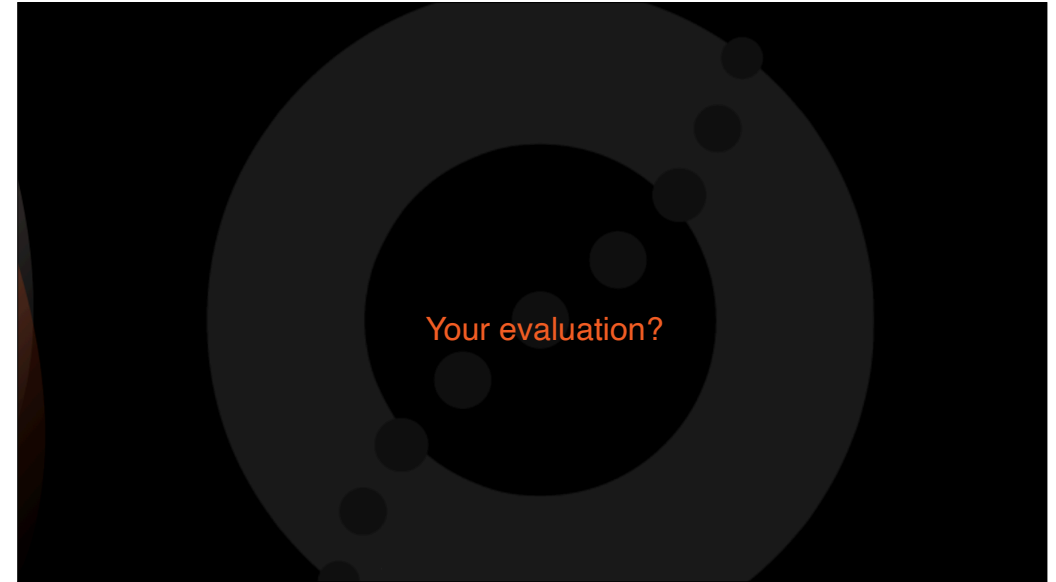
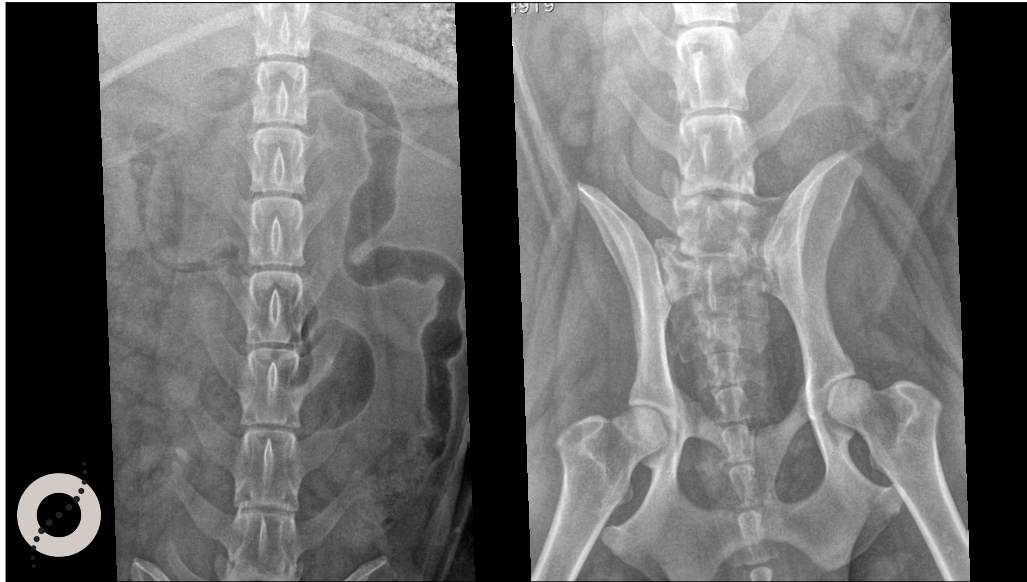
Luna, FI, 9 months



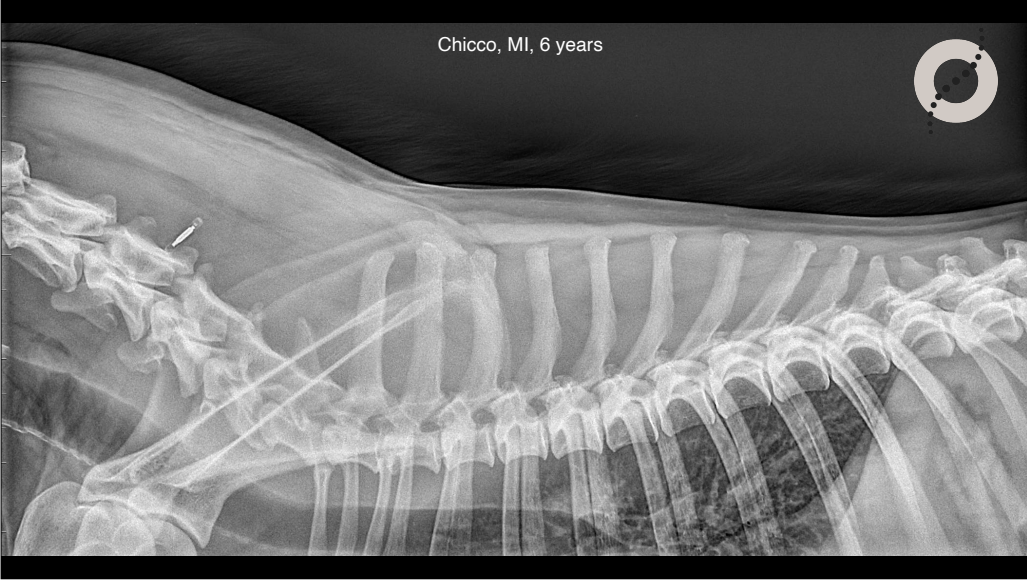Dewdrop, Siberian Husky FS, 5 years

- Acute paraparesis
- Under AB for the last week for a suspected pneumonia
- Yesterday She was fine

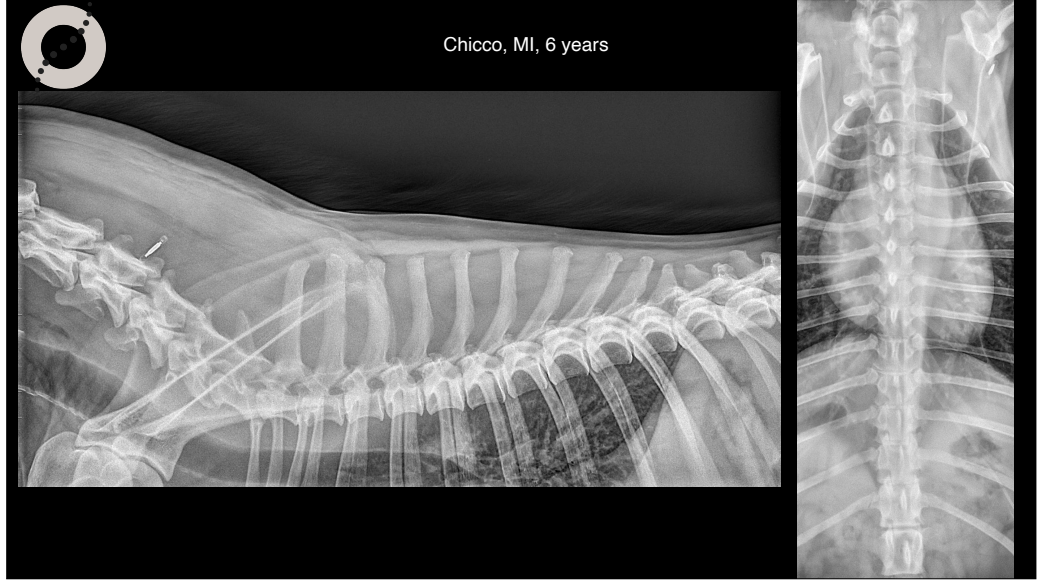



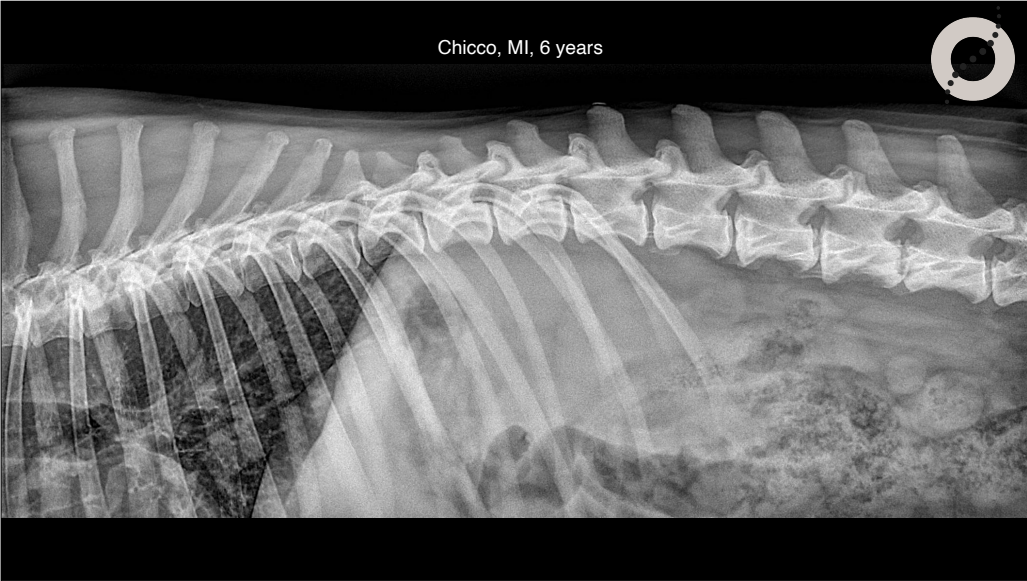Chicco, MI, 6 years



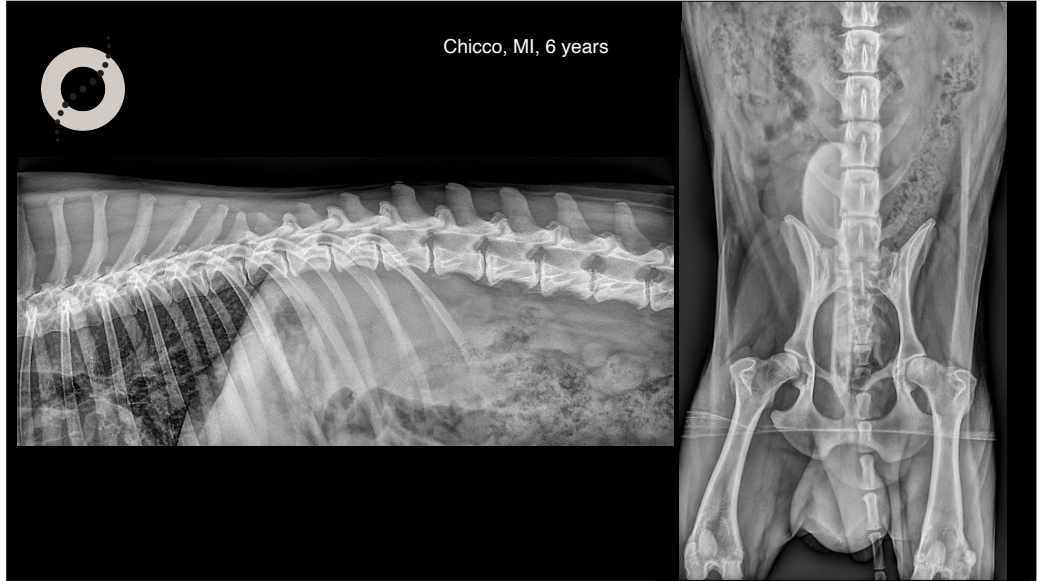Chicco, MI, 6 years



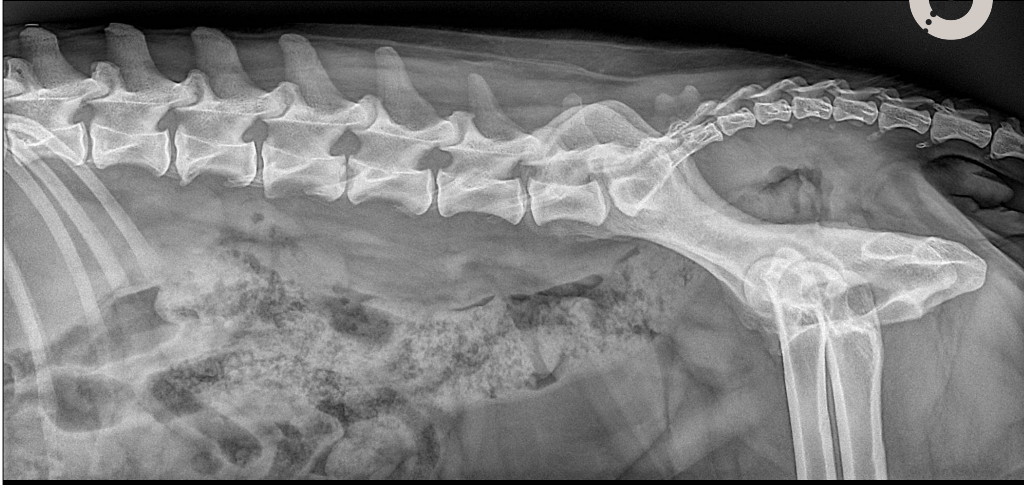Chicco, MI, 6 years



Chicco, MI, 6 years



Chicco, MI, 6 years

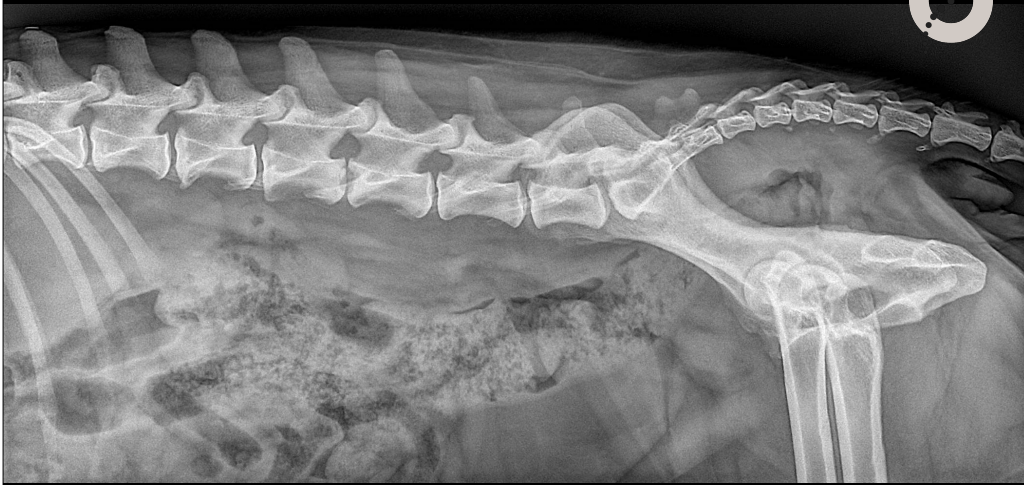

Your evaluation

- Is the spine of the patient radiographically within normal limits?
- Are there signs of disc herniation?
- Are there signs of neoplasia?

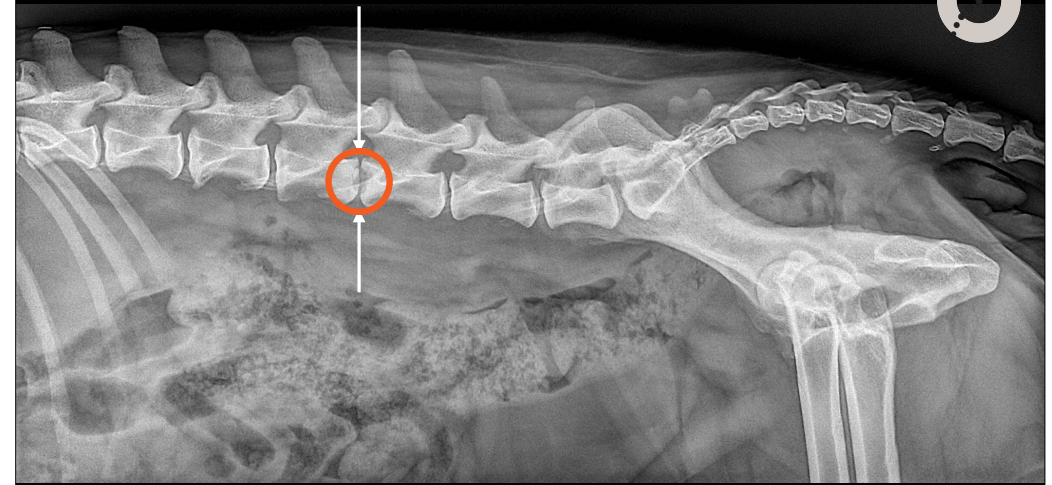


Chicco, MI, 6 years



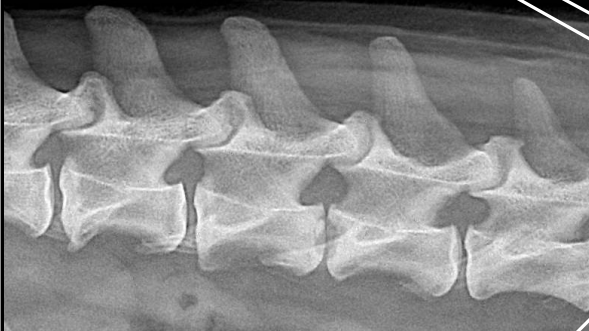
Chicco, MI, 6 years

Collapsed inter-vertebral disc space

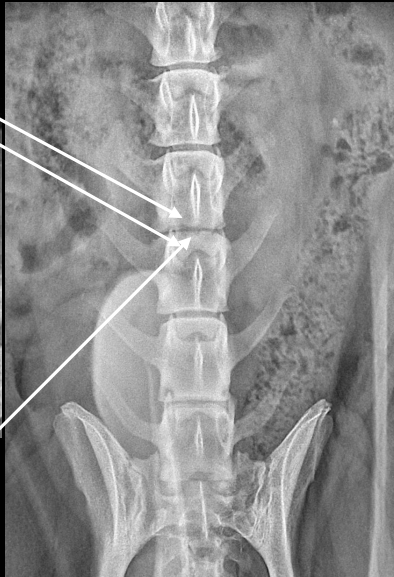


Chicco, MI, 6 years

Collapsed inter-vertebral disc space



Lack of sclerotic rims of the end plates



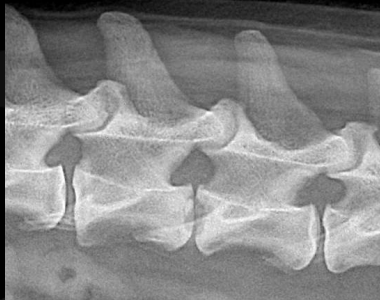Your evaluation

- How would you managed this patient?
- How often will you check this patient?
- When the patient will be healed?



Chicco, Beagle, MI, 6 years

- A healed discospondylitis will show uniformly opaque bone proliferations
- No lytic changes

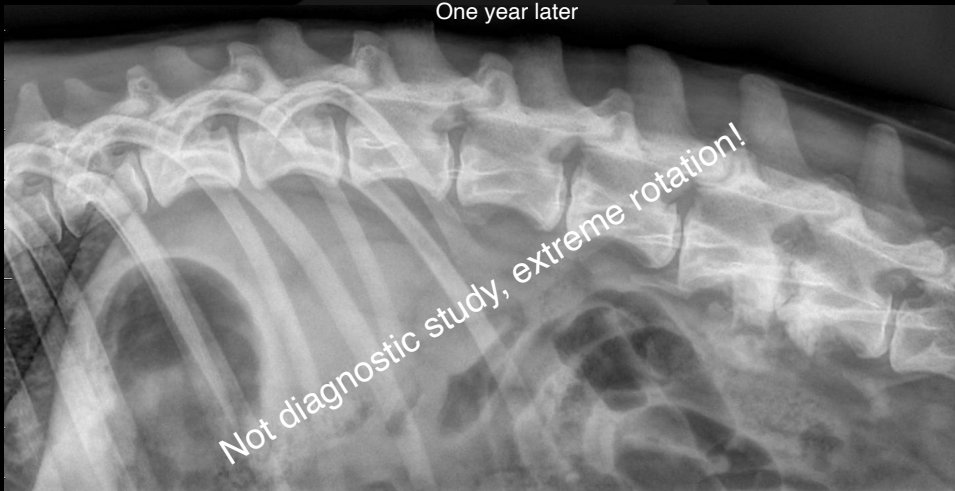


Chicco, Beagle, MI, 7 years

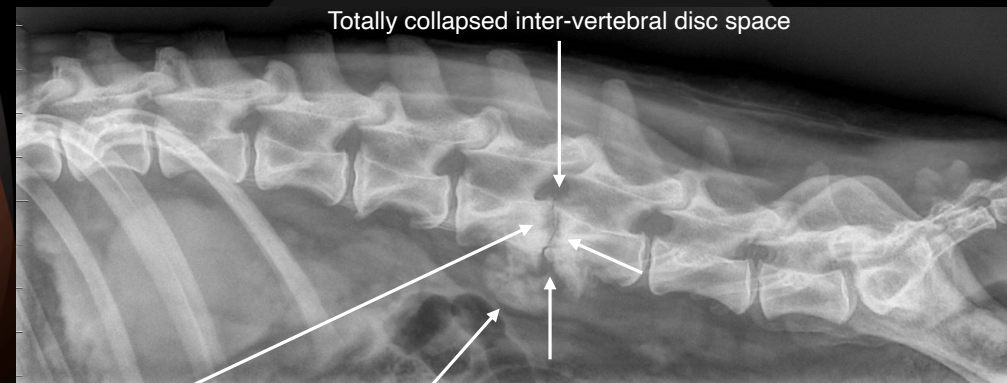
- The referring veterinarian treated Chicco for three months
- Now doing fine
- Recheck after one year



Chicco, MI, 7 years
One year later

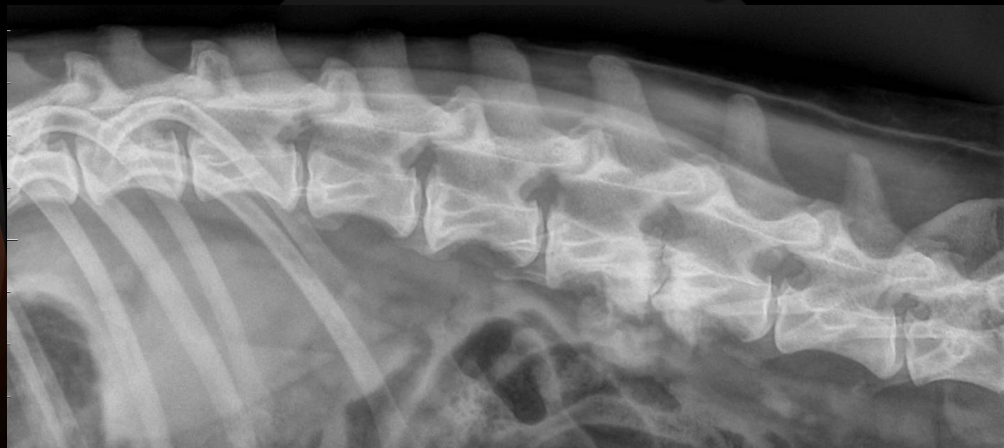

Chicco, MI, 7 years
One year later



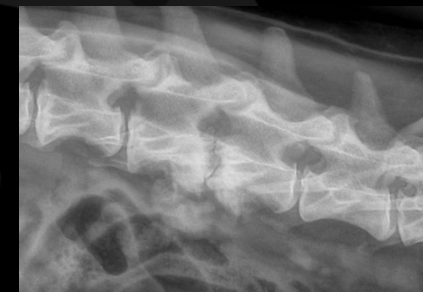
Sclerosis of the end plates Bridging spondylosis

Chicco, MI, 7 years
Two years later



Key points

- Bridging spondylosis stabilises the affected IVDS
- No lytic changes
- Chronic well-defined osseous margins
- Sclerosis surrounding the affected end plates

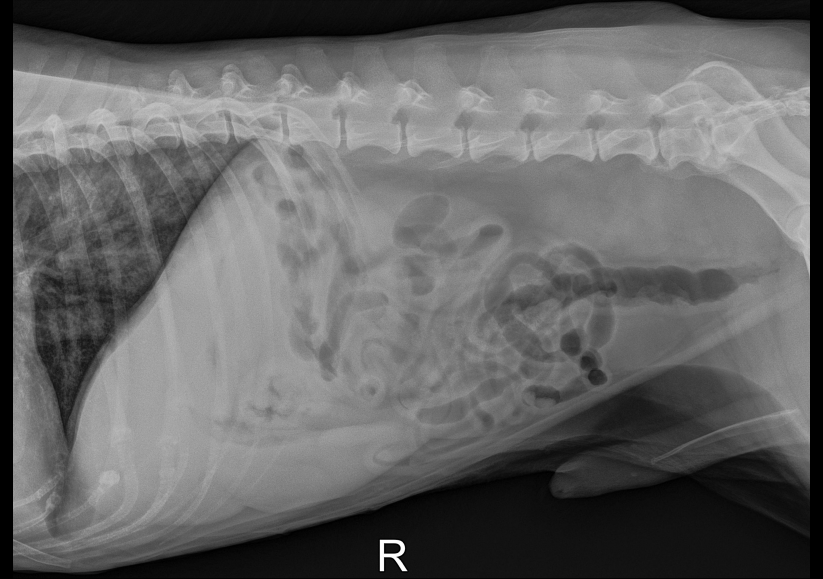


Simbad, Siberian Husky, MN, 14 years

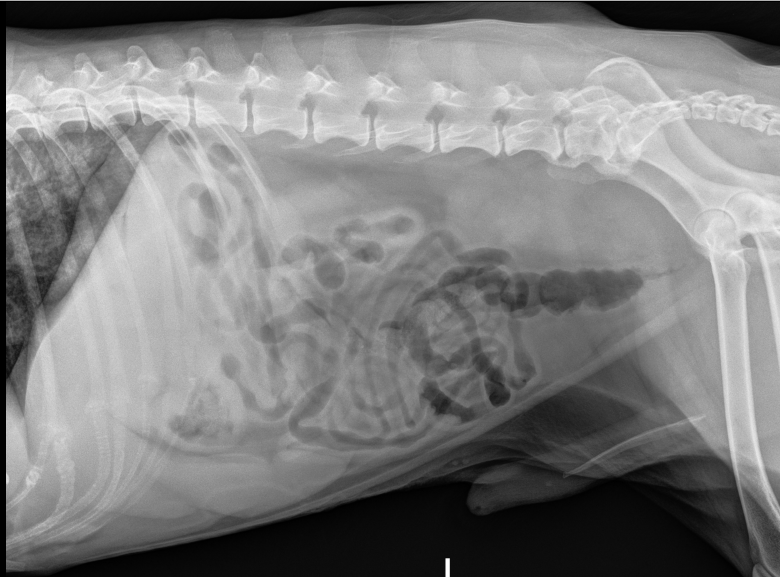
- Let hind limb oedema
- Thin stool for the last weeks, possibly more



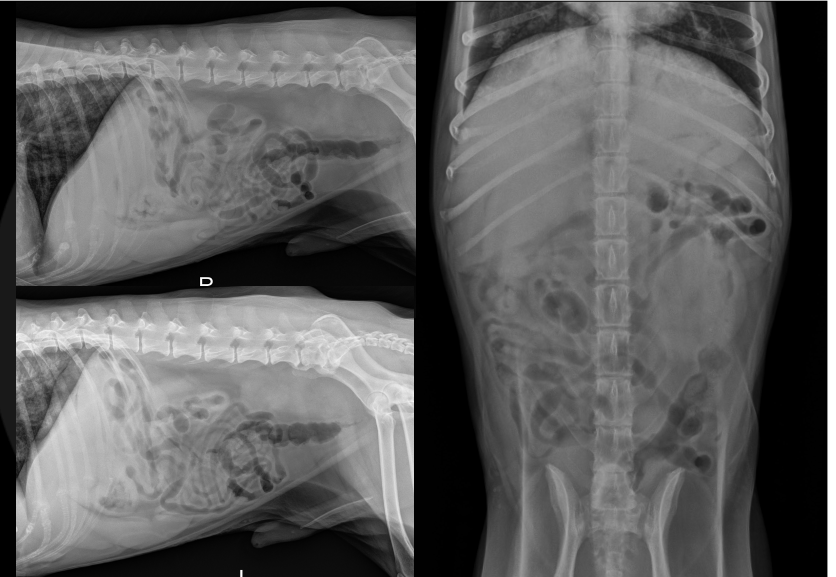
Simbad, MN, 14 years



Simbad, MN, 14 years

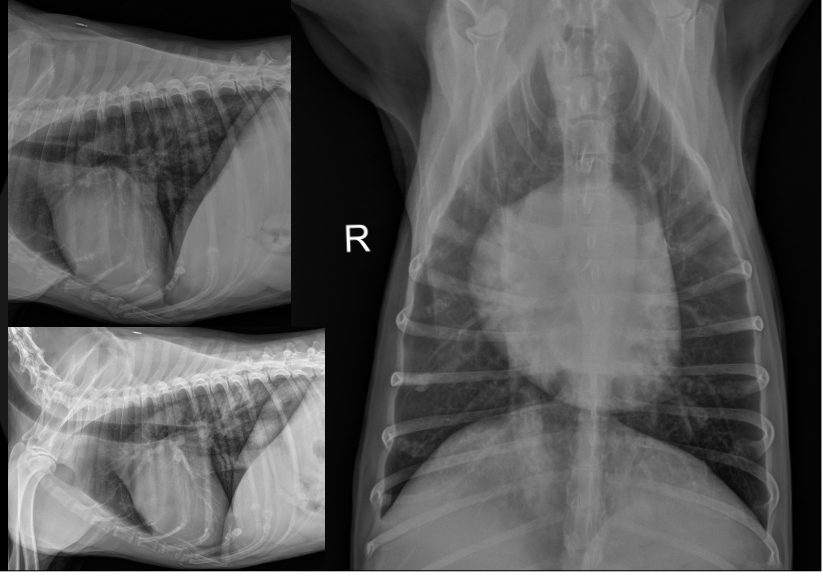


Simbad, MN, 14 years

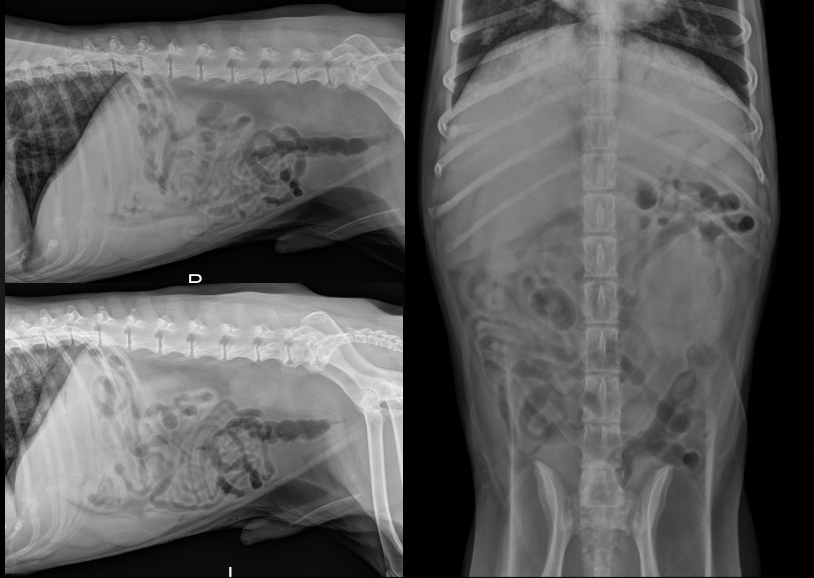

Your evaluation?

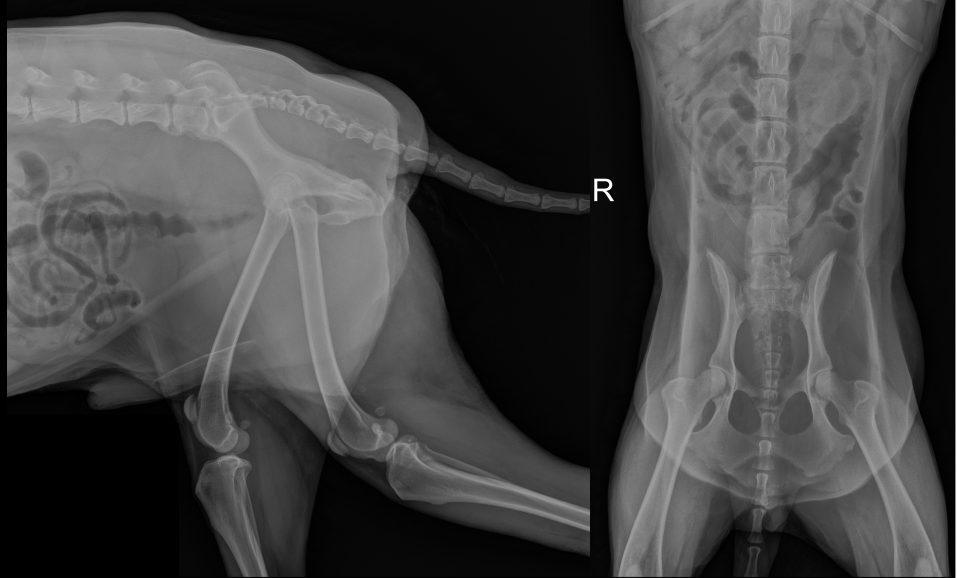
Simbad, MN, 14 years



Simbad, MN, 14 years

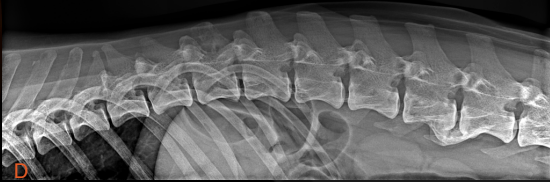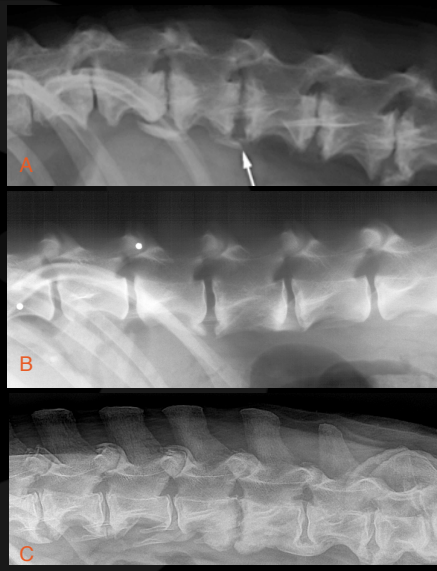


Simbad, MN, 14 years



Quiz time!


1. Spondylosis A, B, C, D
2. Acute spondylitis B
3. Chronic discospondylitis A, C
4. Multiple lytic osseous lesions D
5. Acute discospondylitis 0



Conclusions

The anatomy and peculiarity of the retroperitoneal space allow us to increase our diagnostic capacity

Basic knowledge of bone pathology will help our clinical skills



Frida Kahlo, spina bifida and fibromyalgia testimonial

Thank you



Diagnostic Mindset

www.diagnosticmindset.com