

# Apparato genitale: la radiologia serve ancora?



Diagnostic Mindset



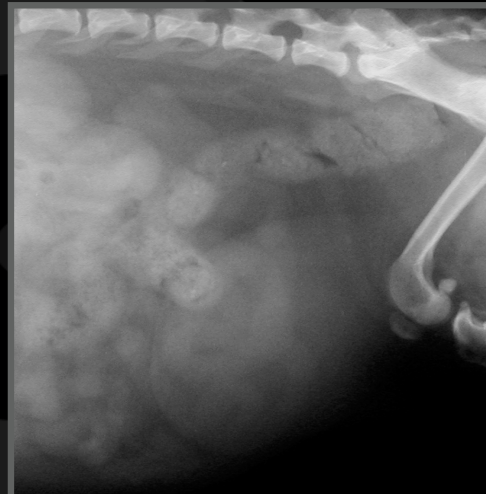
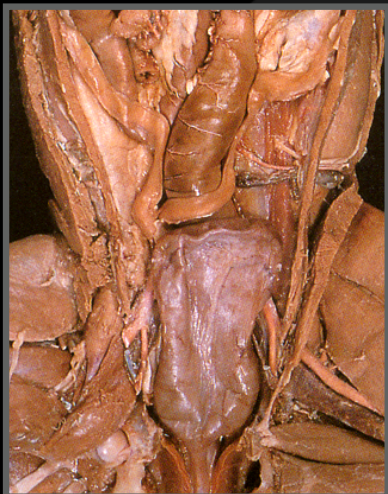Giliola Spattini  
DVM, PhD, DECVDI

## Objectives

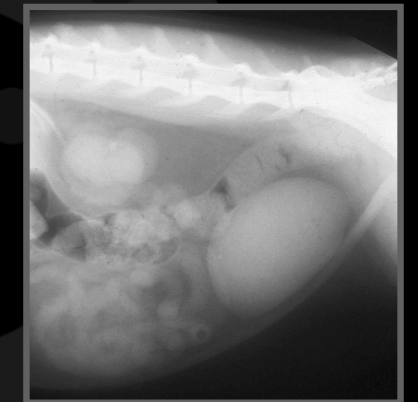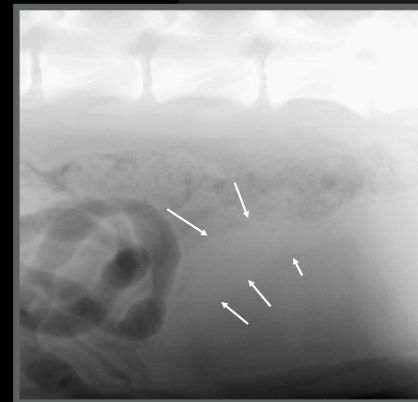
- When radiology is still useful in assessing the genital tract?
- When is better or needed despite of ultrasound?

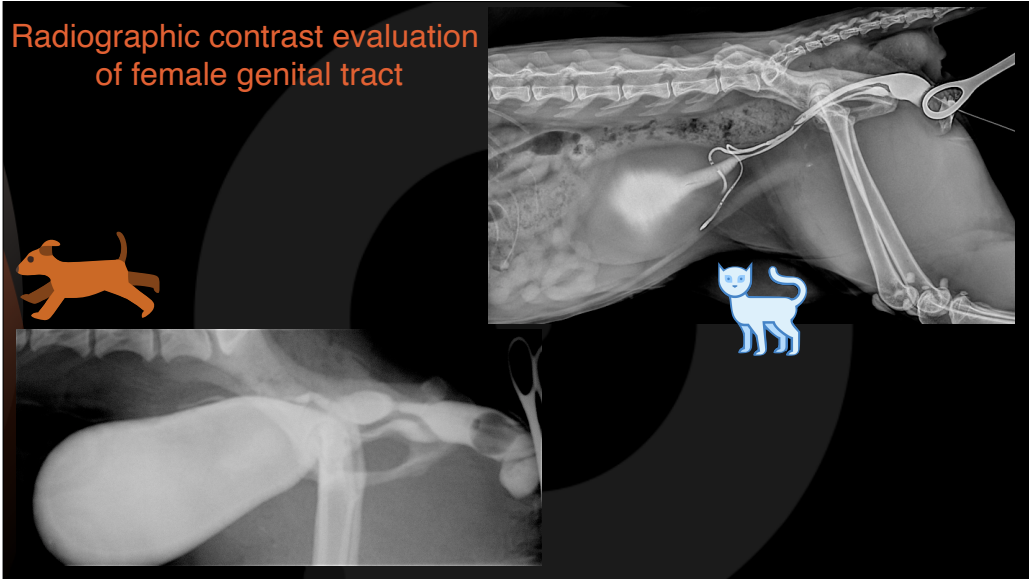


## Radiographic anatomy of female genital tract



## Radiographic anatomy of female genital tract





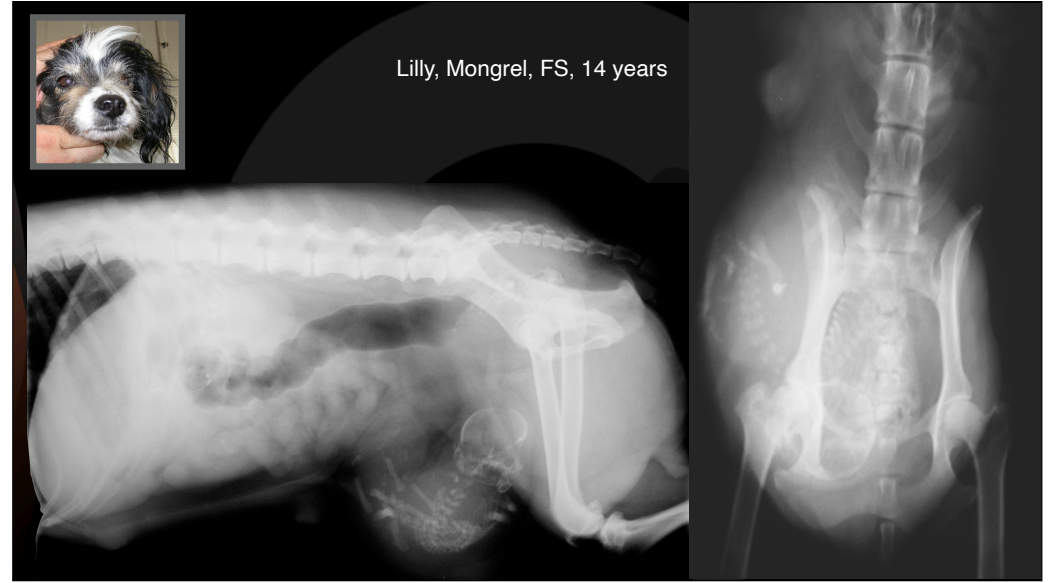
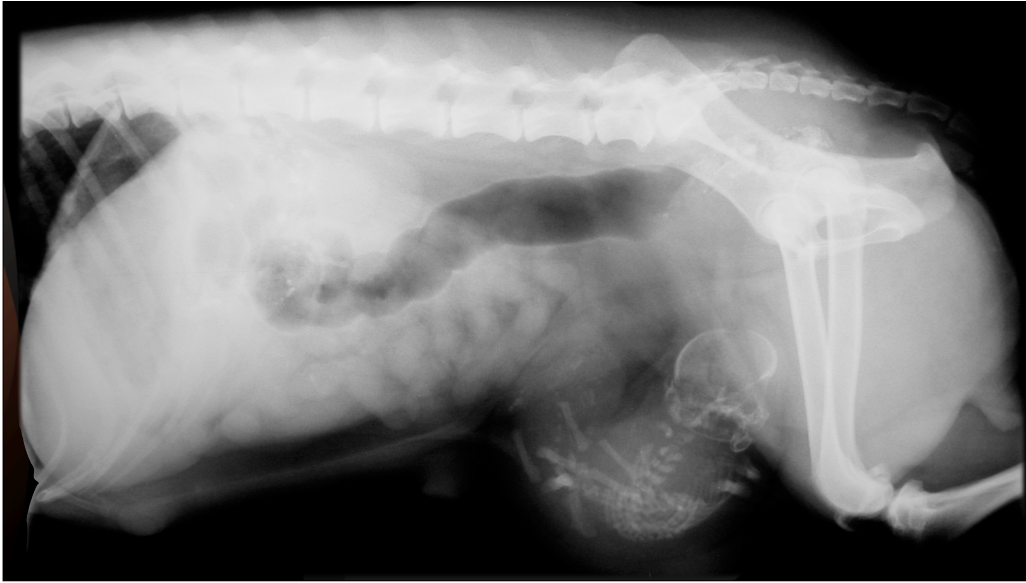
Lilly, Mongrel, FS, 14 years

- The owner said:
- Yesterday this lump was not there
- She is otherwise doing fine, today mildly depressed

Lilly, FI, 14 years

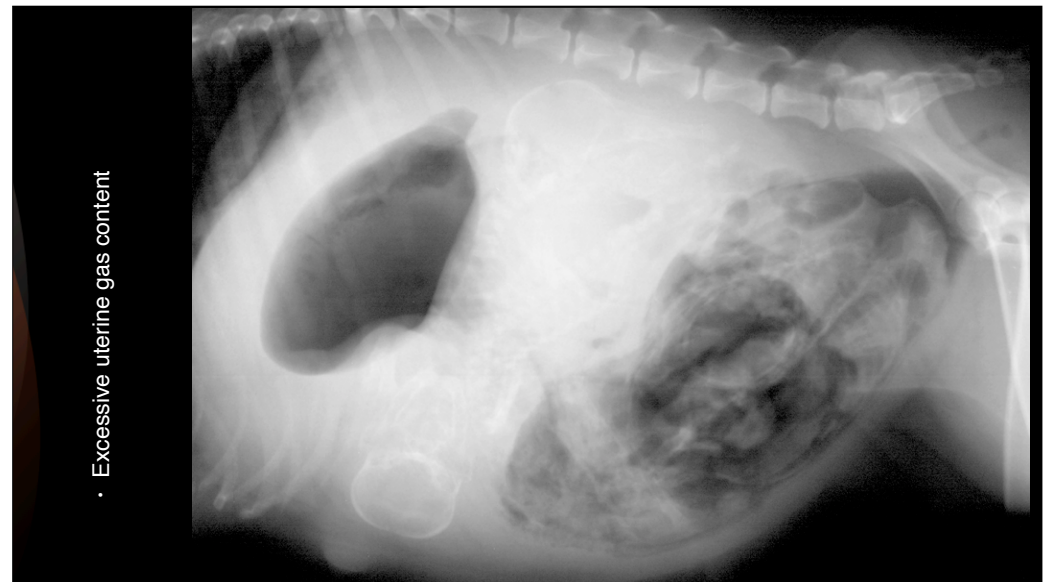
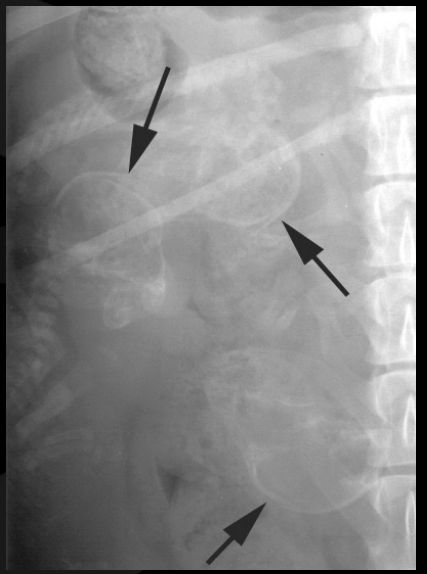
11-2

Your evaluation?

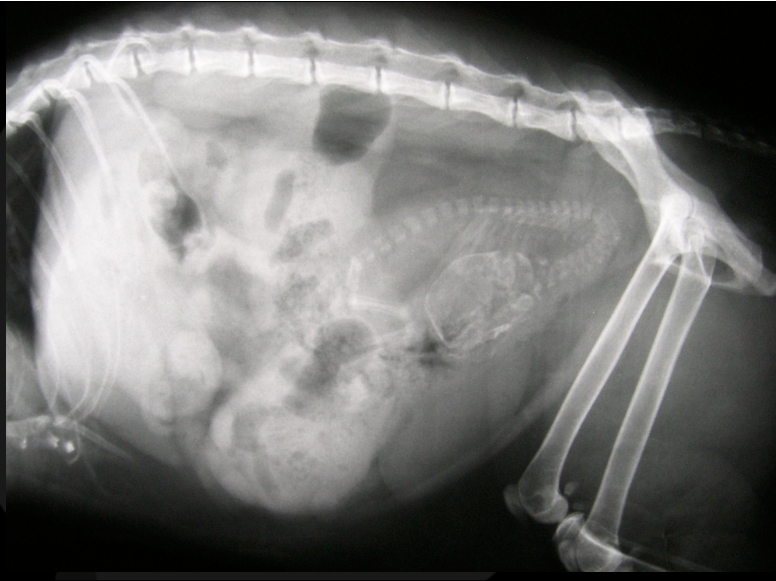


### Radiographic diagnosis of fetal death

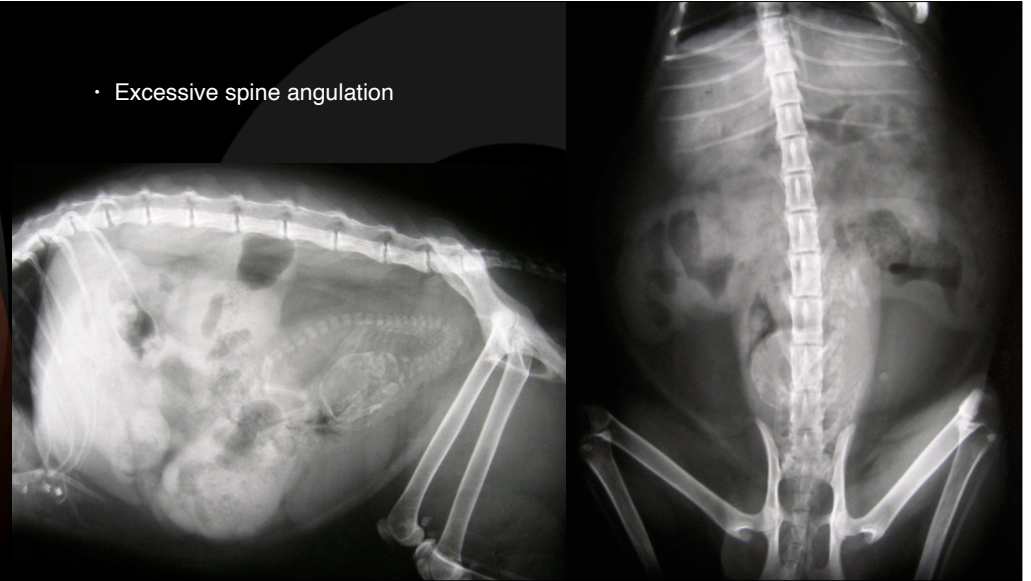
- Head splitting
- Generalised reduced fetal opacity
- Not uniform fetal opacity



· Excessive spine angulation

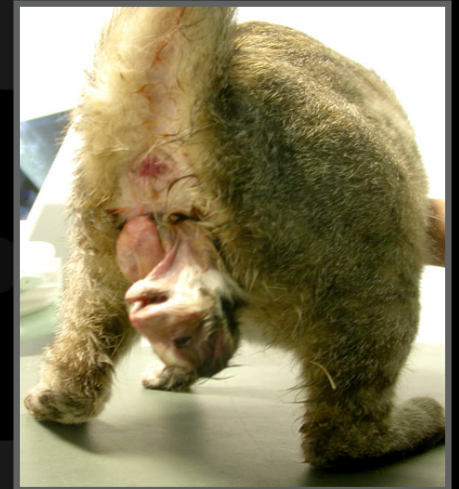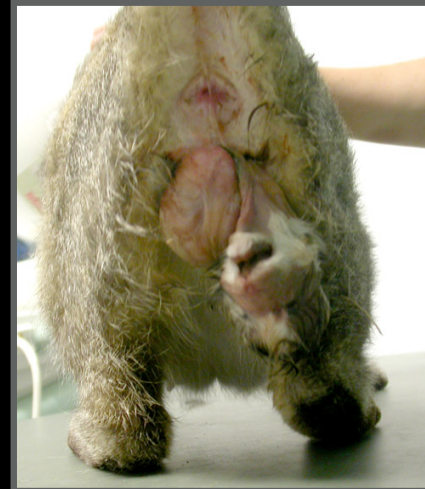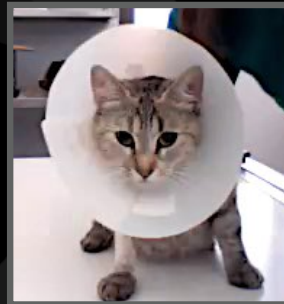


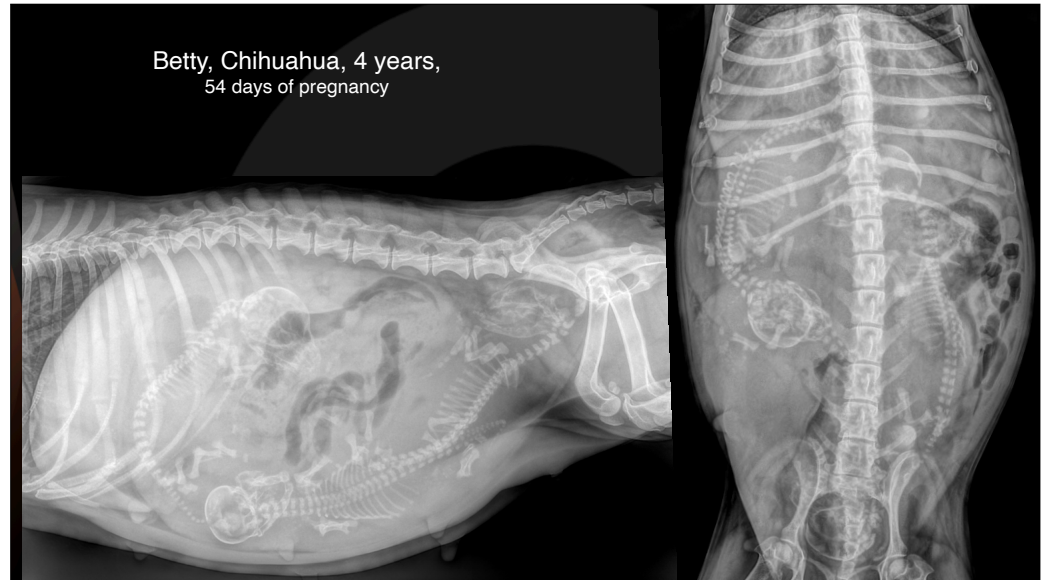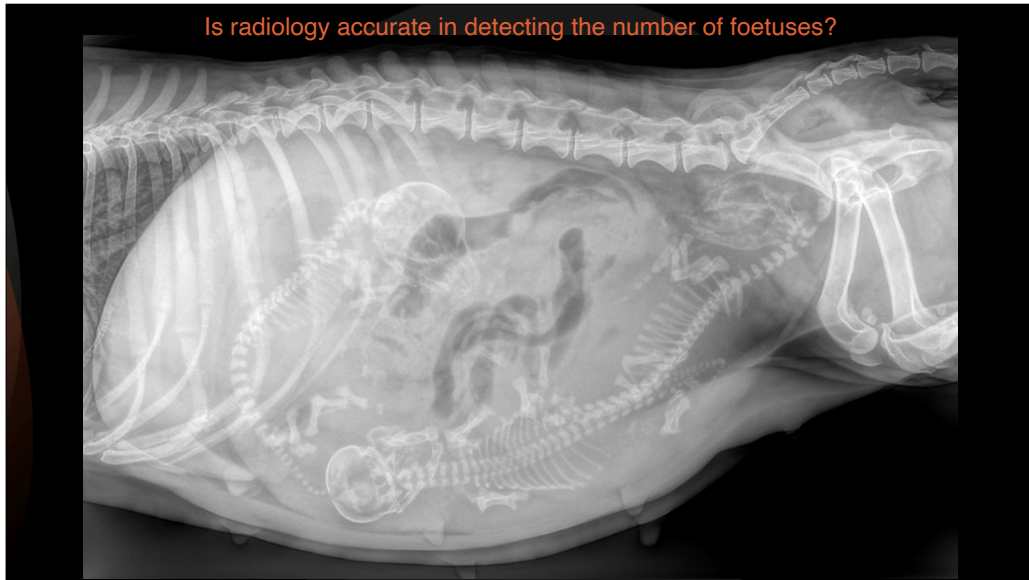
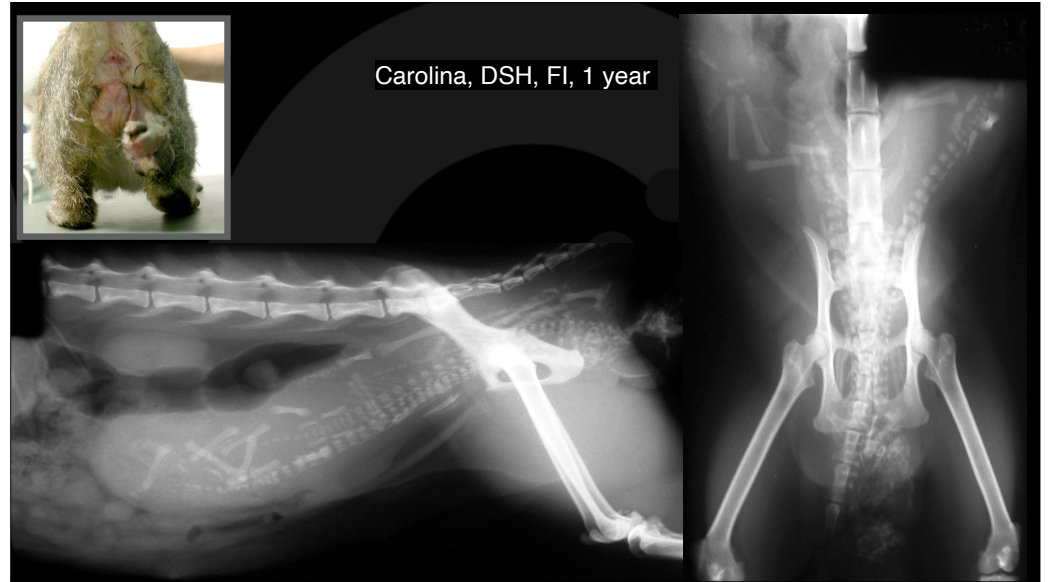
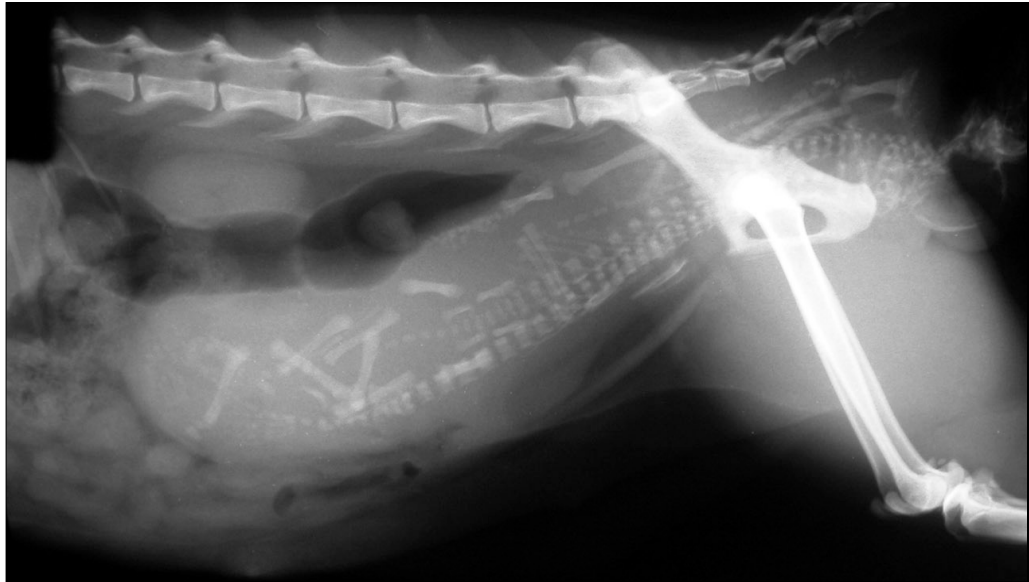
· Excessive spine angulation



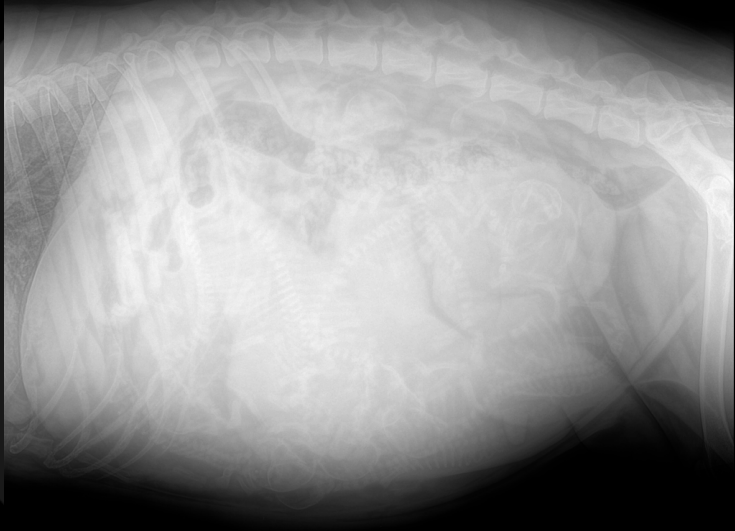
Carolina, DSH, FI, 1 year

- The owner said: the cat smell badly
- Outdoor and indoor
- Not clear if She is eating or urinating

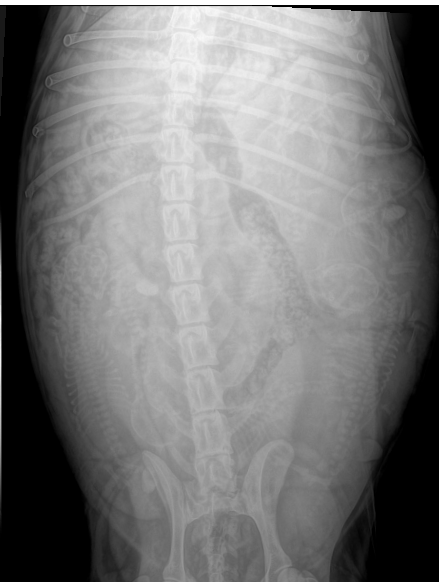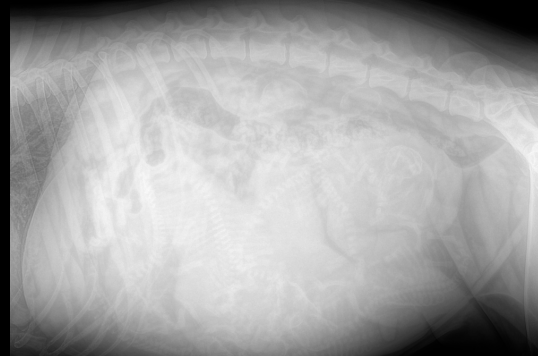




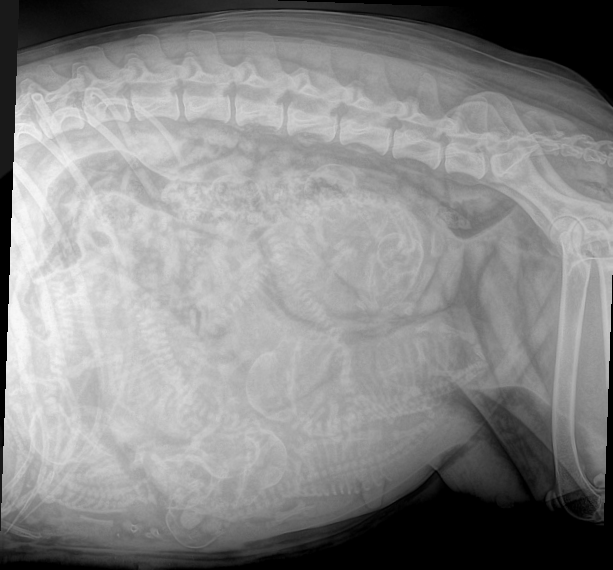Wendy, Newfoundland, 3 years,  
41 days of pregnancy



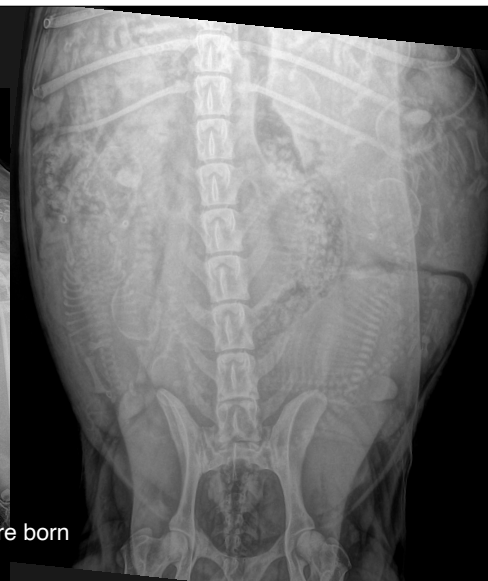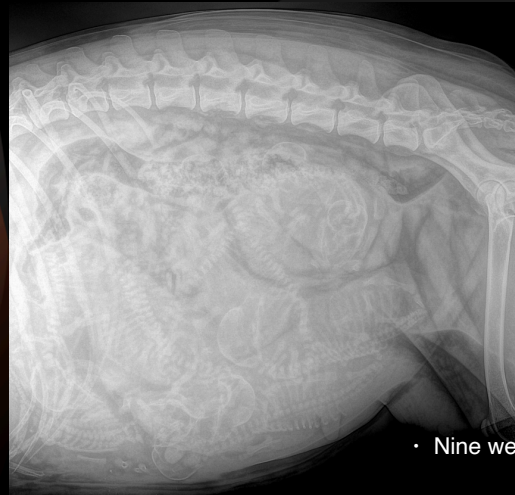Wendy, Newfoundland, 3 years,  
43 days of pregnancy



Wendy, Newfoundland, 3 years,  
55 days of pregnancy

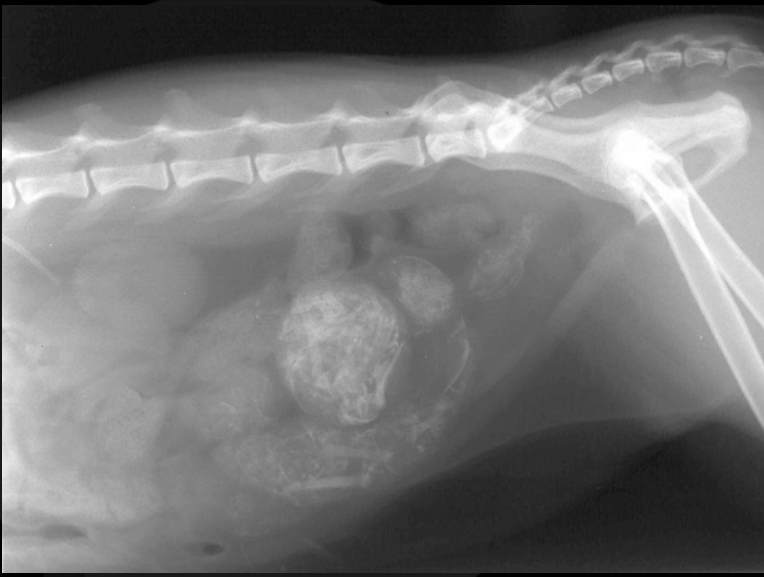

Wendy, Newfoundland, 3 years,  
55 days of pregnancy



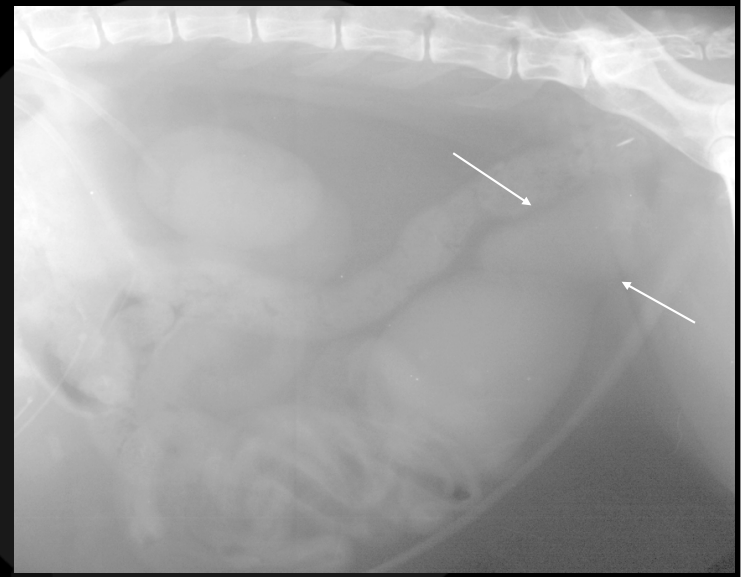
• Nine were born

Uterus or intestine?



What is the problem?

Stump granuloma

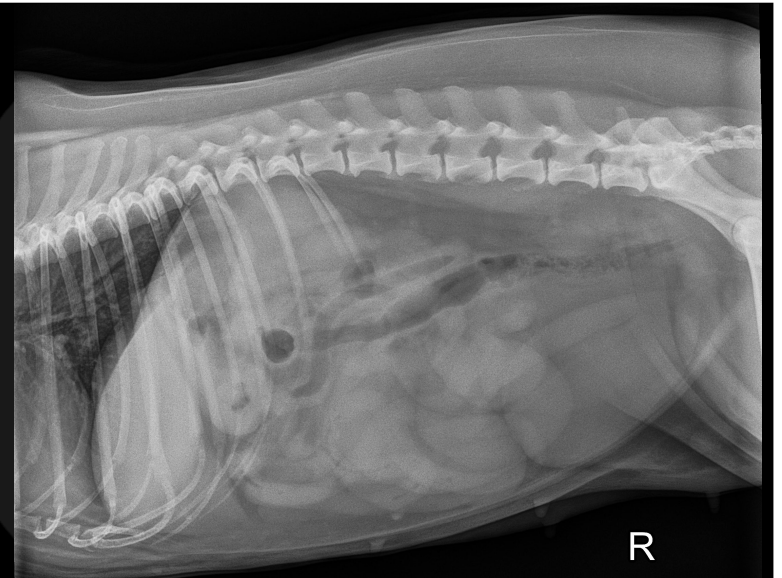


Luna, Beagle, FI, 10 years

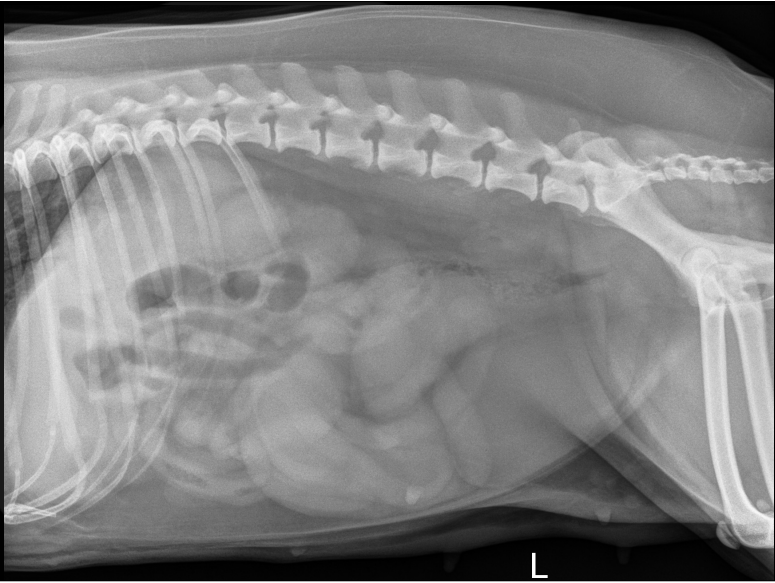
- Vomiting
- Distended abdomen
- Abdominal pain on PE



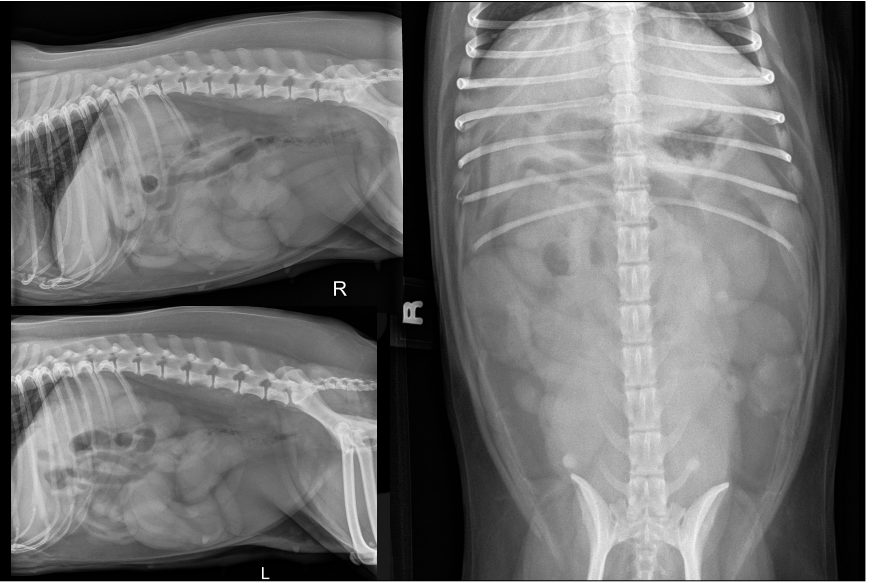
Luna, FI, 10 years



Luna, FI, 10 years

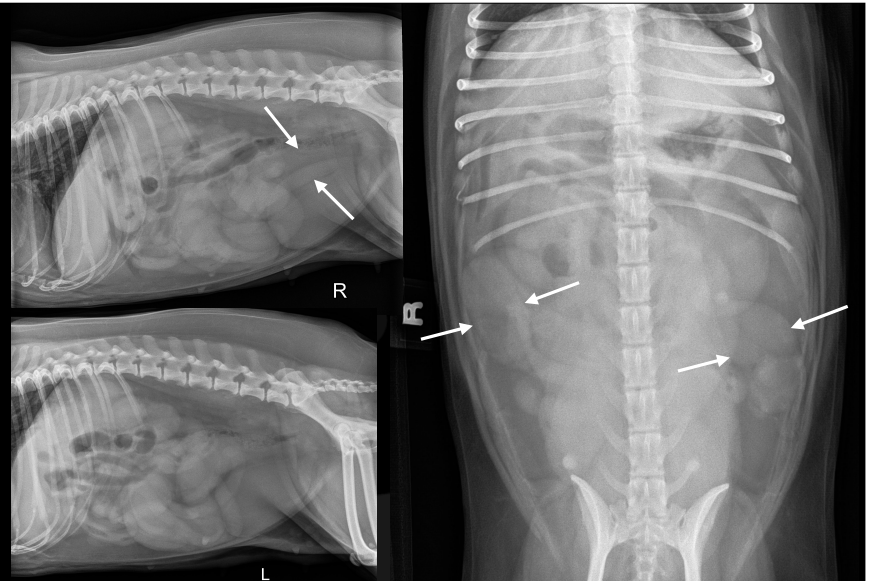


Luna, FI, 10 years



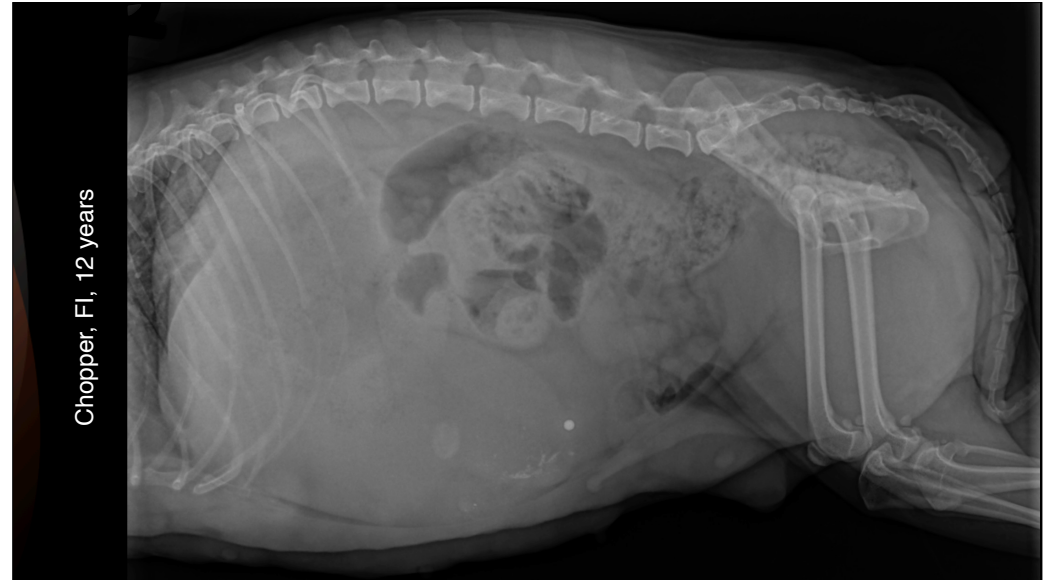Your evaluation?

Luna, FI, 10 years



Chopper, York Shire, FI, 12 years

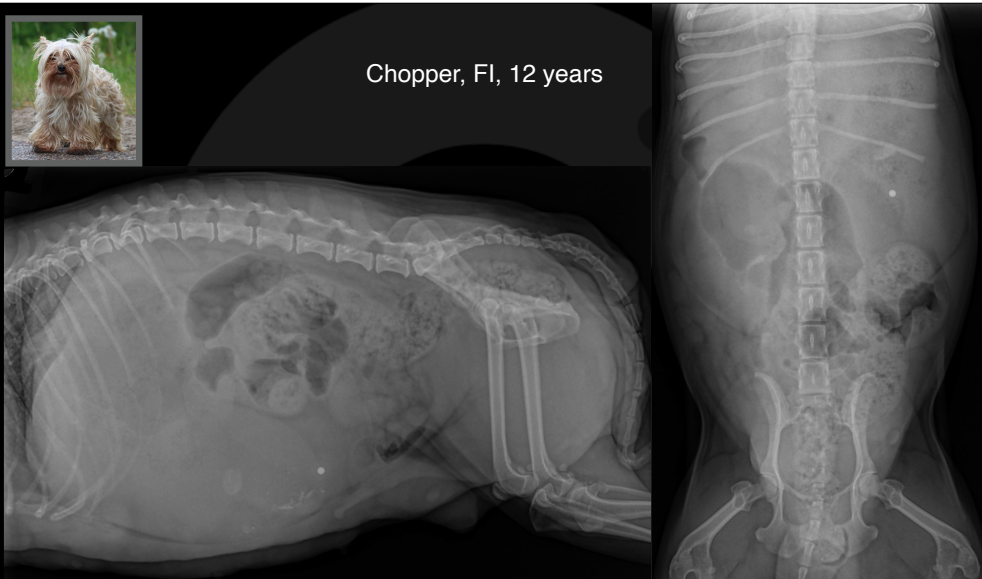
- Give birth one week ago
- Now lethargic, is not taking care of the puppies
- Progressively distended abdomen



Chopper, FI, 12 years



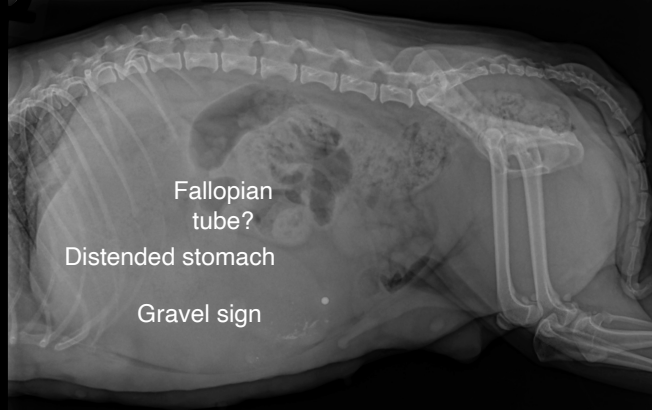
Chopper, FI, 12 years



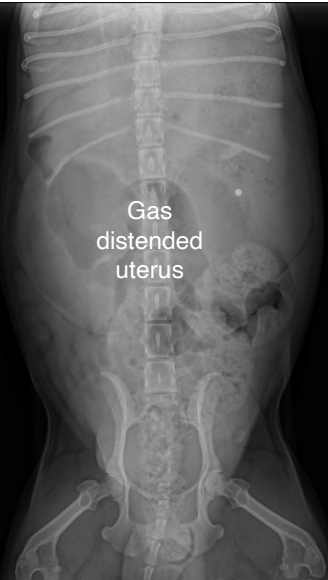Your evaluation?



Chopper, FI, 12 years



Fallopian tube?  
Distended stomach  
Gravel sign



Gas distended uterus

Chopper, York Shire, FI, 12 years

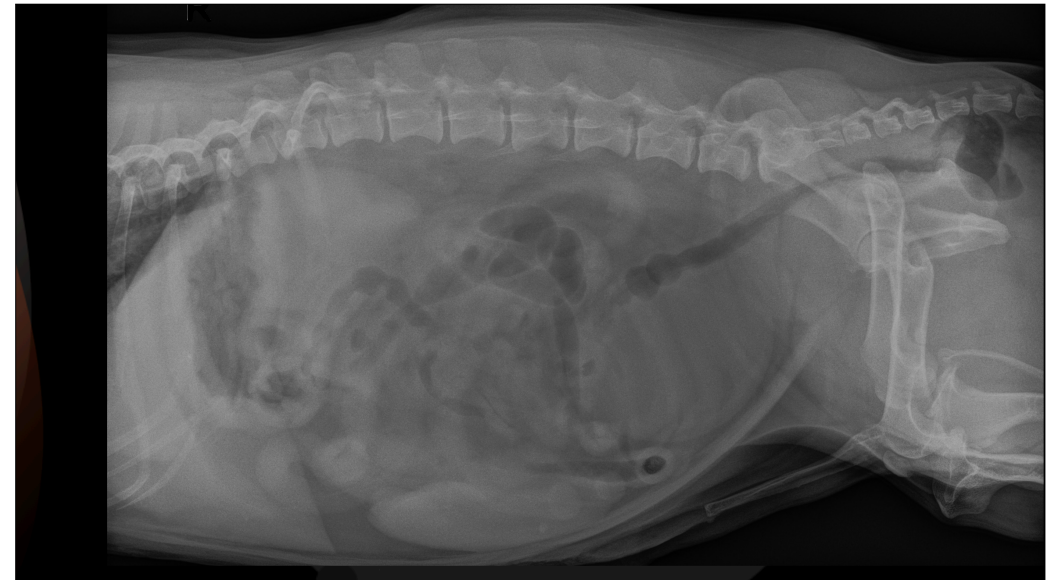
- Final diagnosis:
  - Emphysematous pyometra
  - Pyloric occlusion by a pancreatic mass

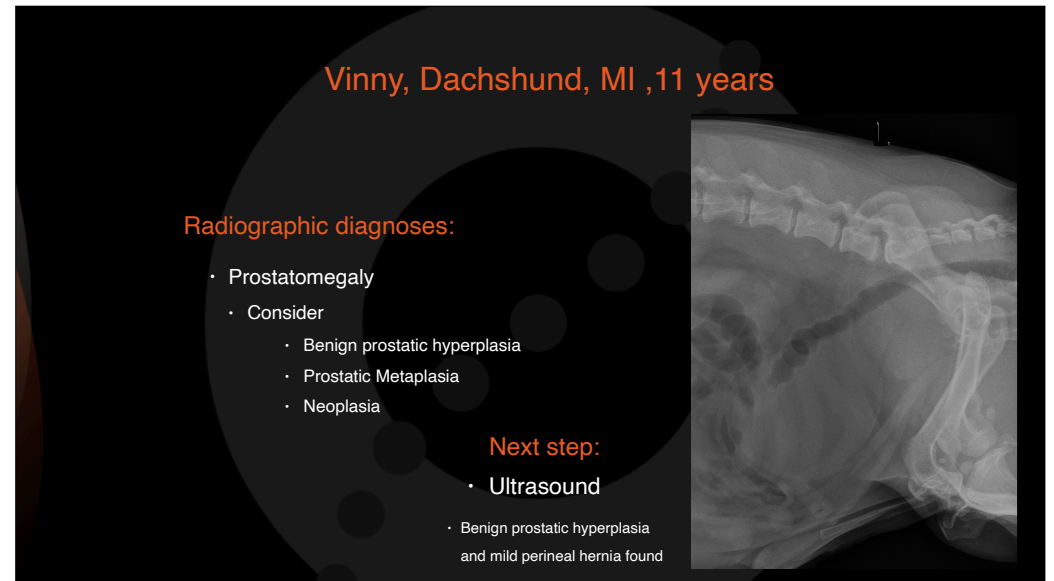
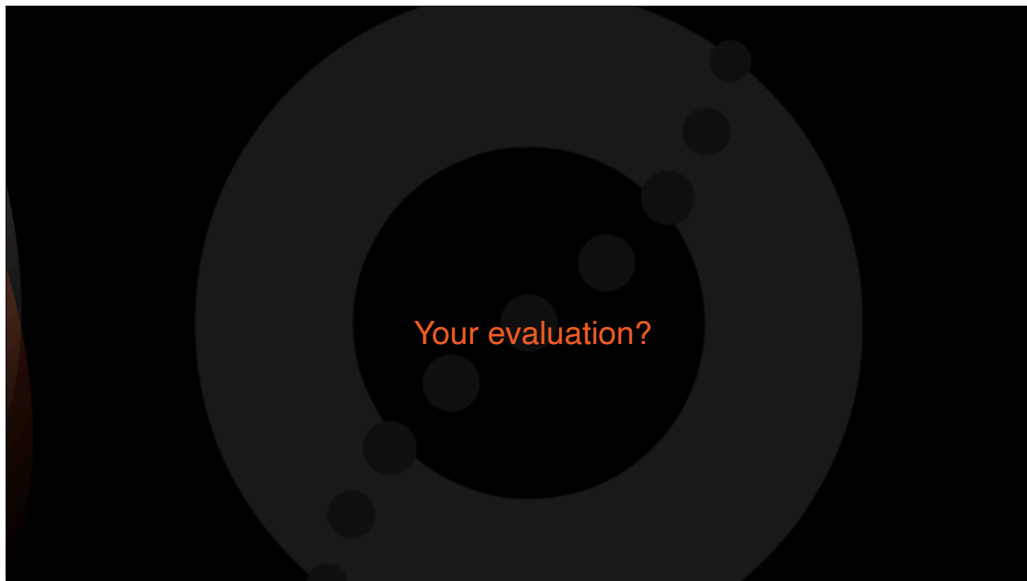
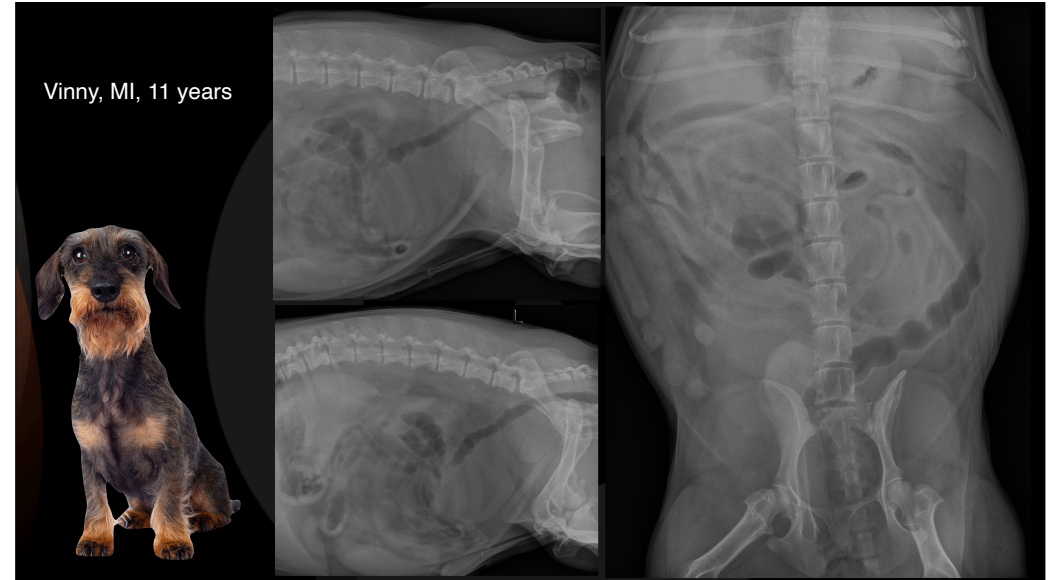
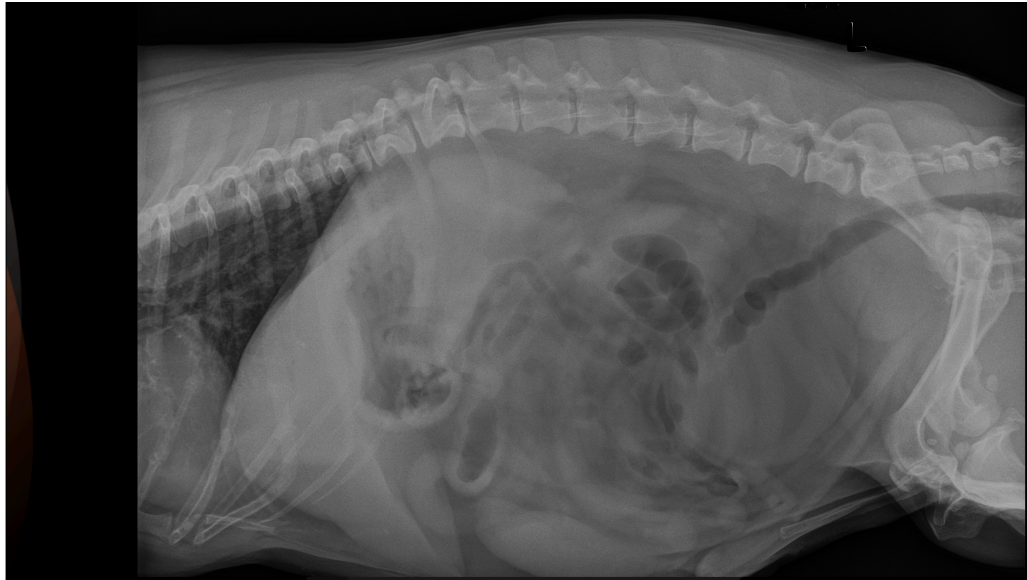

- Euthanasia

Vinny, Dachshund, MI, 11 years

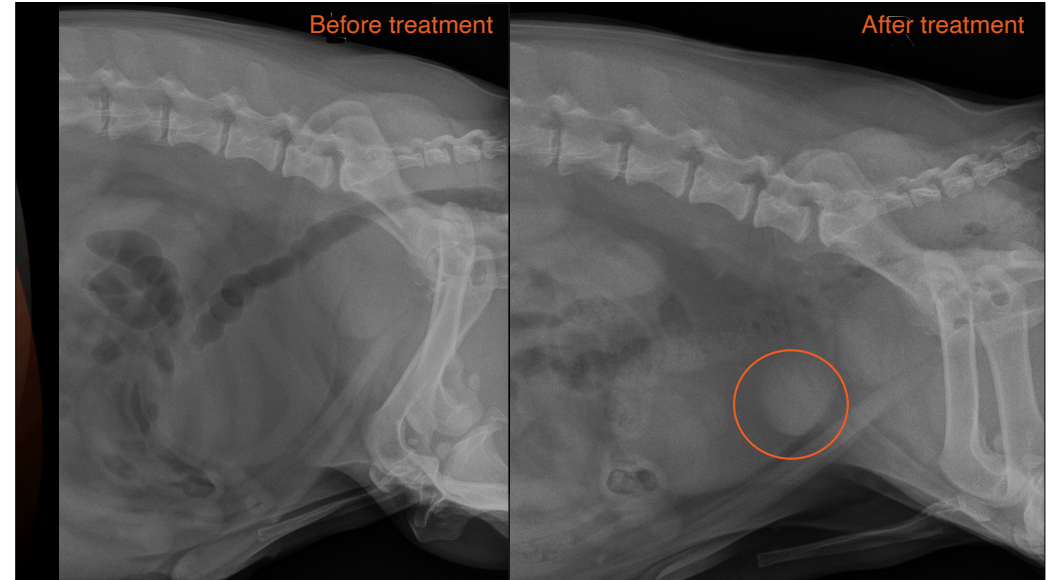
- Tenesmus
- Mildly tense abdomen
- In the past back pain



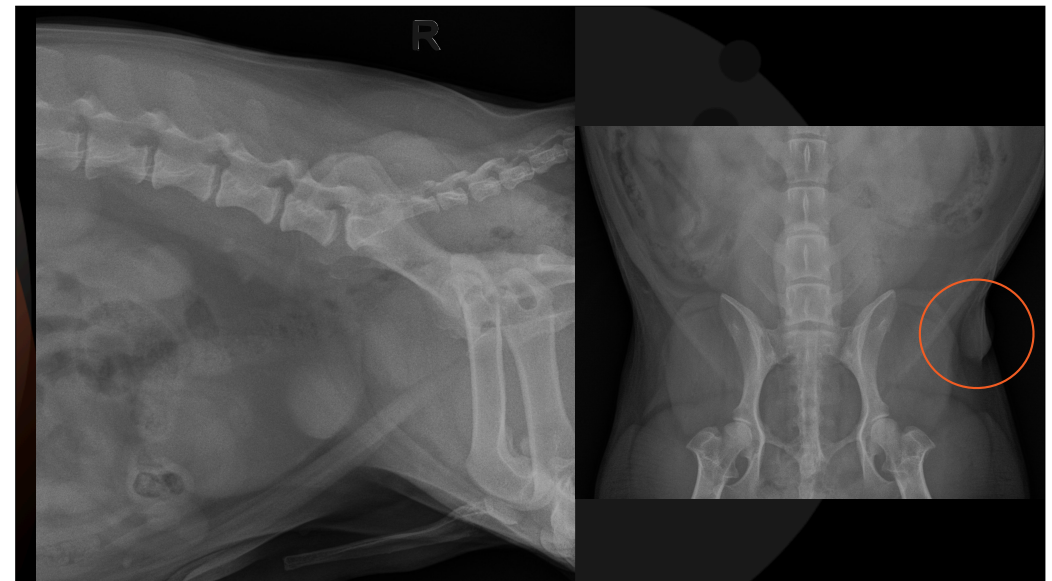


Vinny, Dachshund, MI, 11 years

- Treated with finasteride for BPH for 2 months
- No clinical signs
- Prostate size recheck

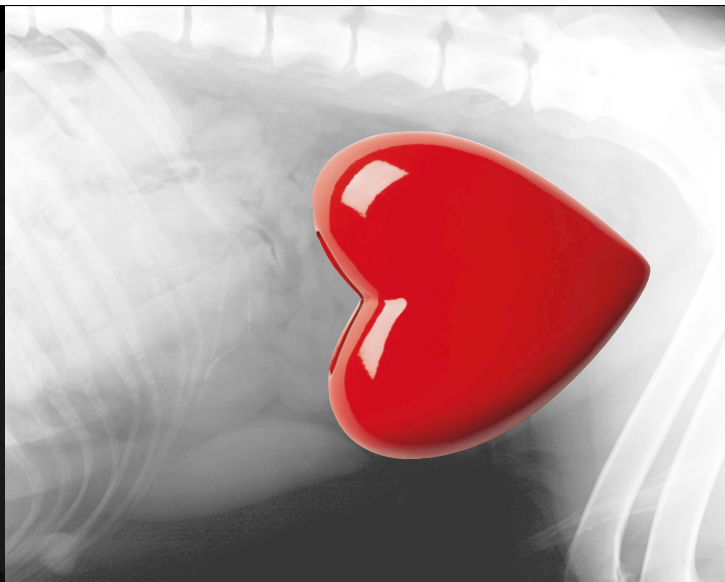

Your evaluation?



Benny, Beagle, MI, 9 years

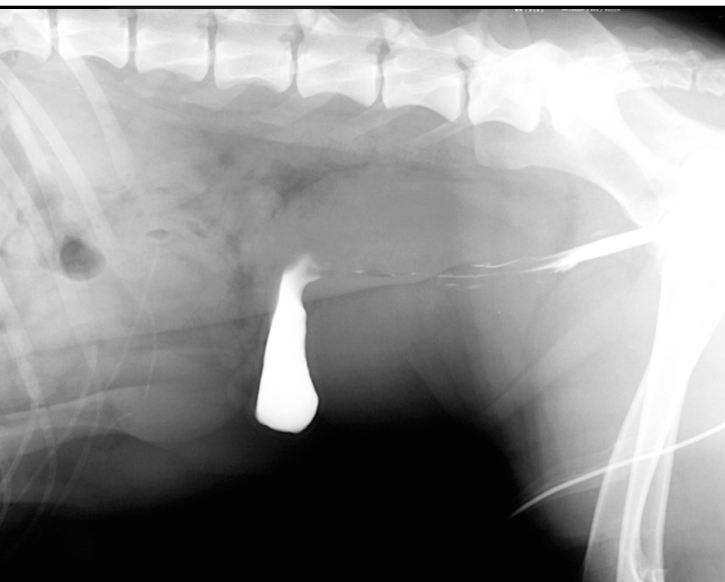
- Hematuria
- Episodes of constipation



Your evaluation?

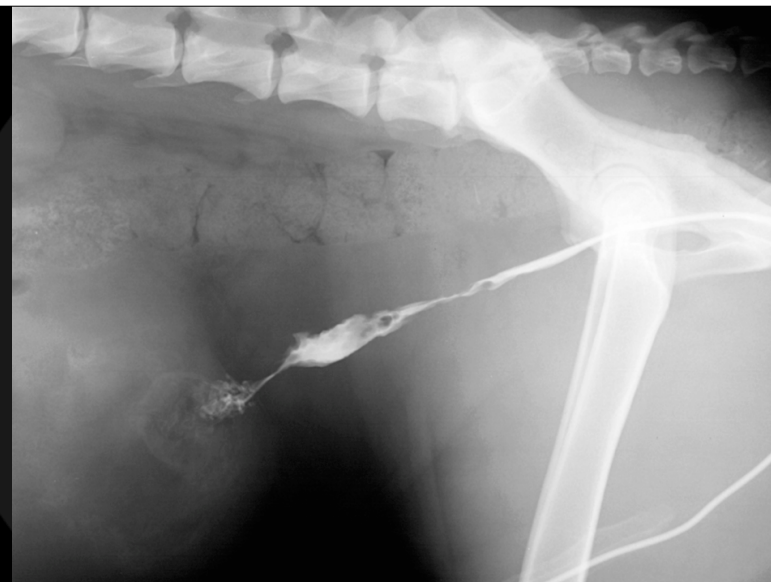

Benny, Beagle, MI, 9 years

- Hematuria
- Episodes of constipation



Tod, Mongrel, MI, 11 years

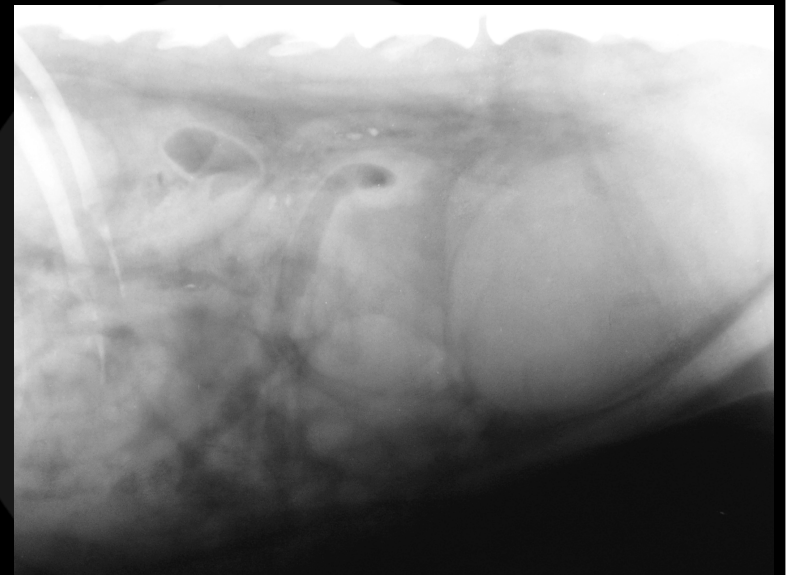
- Hematuria
- Stranguria



Your evaluation?

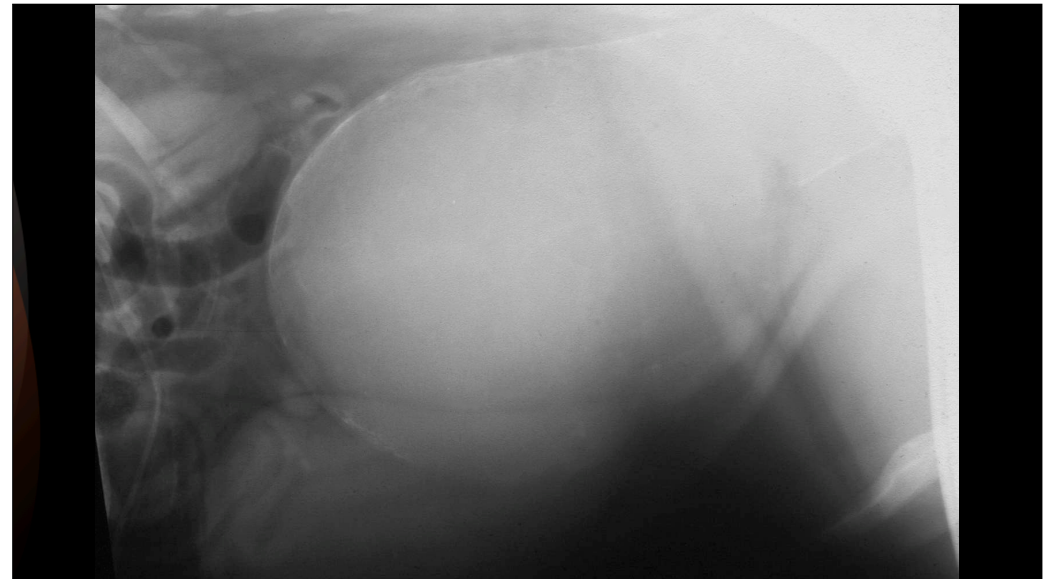
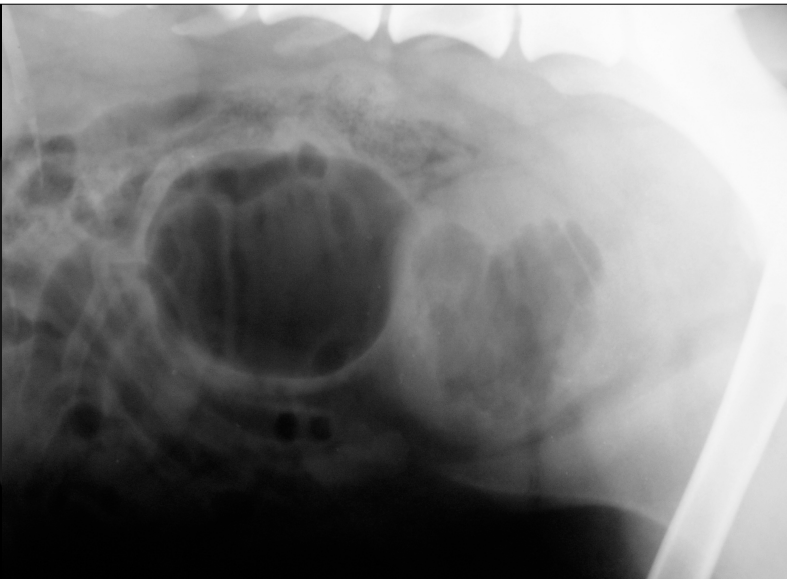
Berto, Mongrel,  
MI, 12 years

- Hematuria
- Stranguria



Berto, Mongrel,  
MI, 12 years

- Hematuria
- Stranguria



## Conclusions

- Radiology can still be helpful in the genital tract for:
  - Count of the foetus
  - Incidental diagnosis of uterine disorder
  - Large uterine mass
  - Prostatic carcinoma
  - Para-prostatic cysts, size of the prostate



Dante Alighieri

# Thank you



Diagnostic Mindset

[www.diagnosticmindset.com](http://www.diagnosticmindset.com)