


Radiographic technique needed to obtain diagnostic abdominal imaging



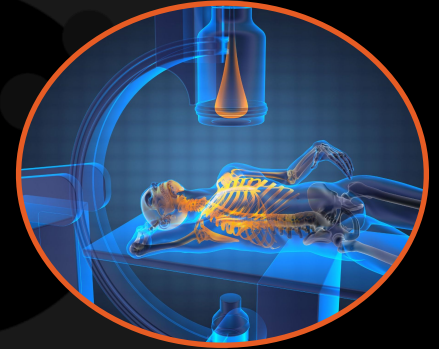
Diagnostic Mindset



Giliola Spattini
DVM, PhD, DECVDI

Objectives

- Human safety
- Knowledge of the radiographic equipment
- Optimise radiology setting and positioning



Lucy, Irish Setter, FS, 9 years

- Recurrent sialorrhea
- Food bloat every time she eats
- Abdominal check



Abdominal positioning

RLR view



Abdominal positioning

RLR view




Abdominal positioning

RLR view




Abdominal positioning



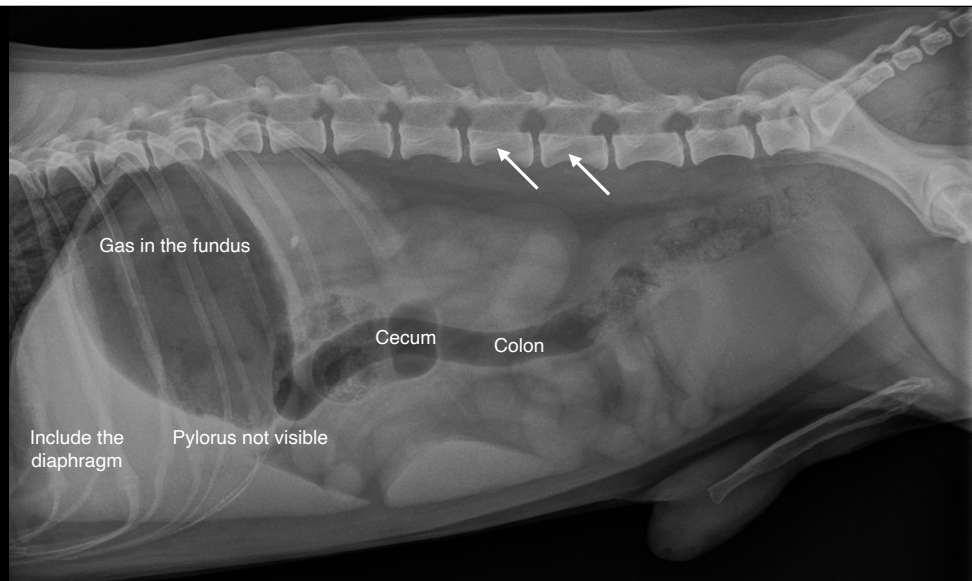
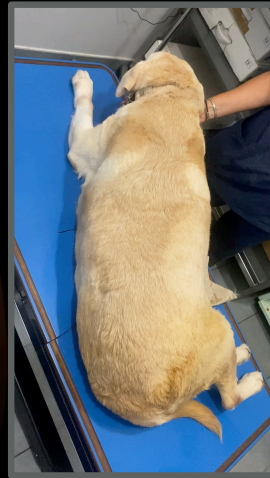
Abdominal positioning RLR



Abdominal rotation



Abdominal rotation

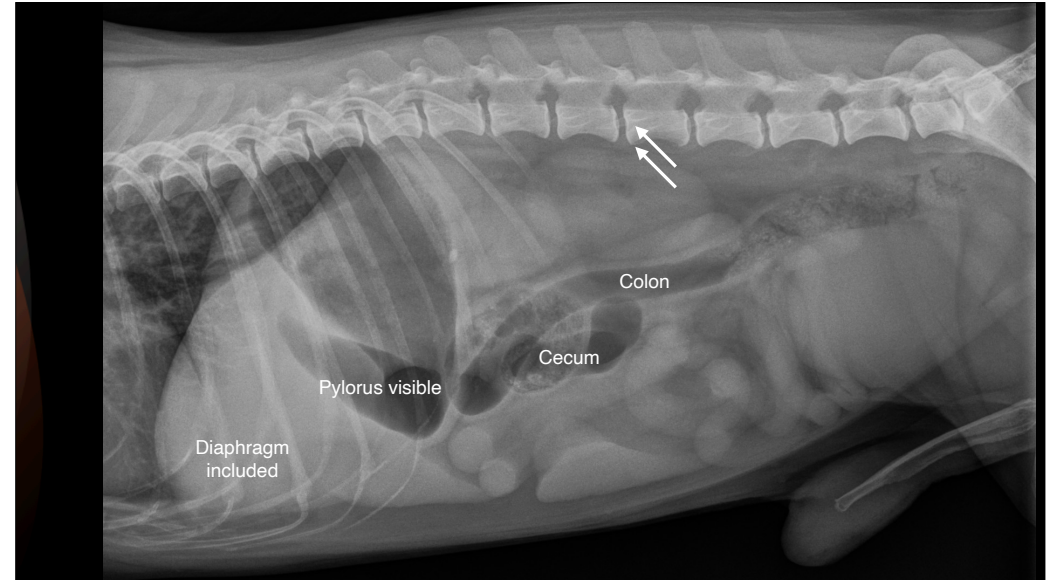


Abdominal positioning

LLR view



Abdominal positioning LLR



Alex, Italian short-haired Segugio, MI, 7 years

- Chronic cough
- Suspected to have ingested a bone



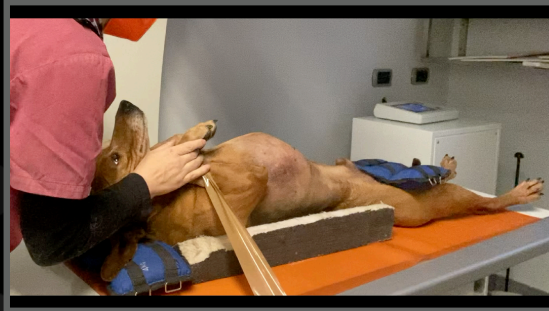Abdominal positioning VD

- Put the dog on the table, standing
- Flip the patient gently
- Use an holding device




Abdominal positioning VD

- Gently extend the head
- Put a holding bag on the mandible
- Keep the patient relaxed

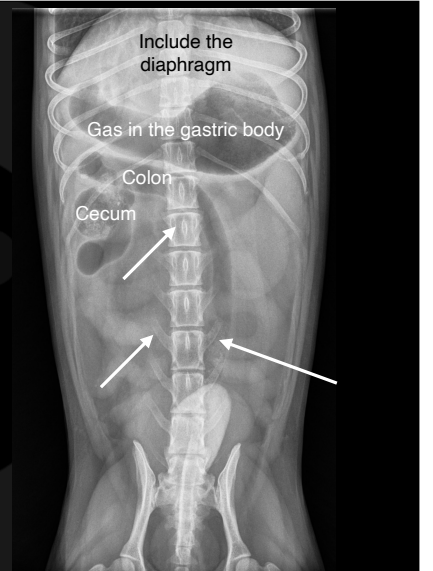




Abdominal positioning



Abdominal positioning VD

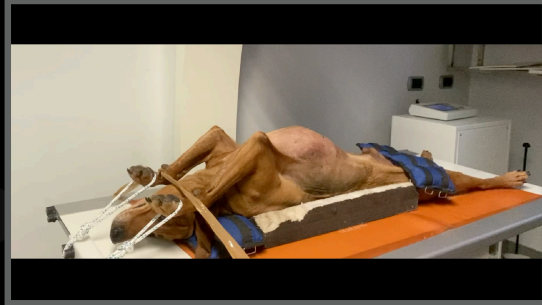- 1) The head needs to be hold straight and symmetric
- 2) The front limbs need to be out of the way



Abdominal positioning

Aftercare VD view

- Gently remove the tape
- Gently remove the ropes
- Hold and keep the dog relaxed



Conclusions

Be safe and stay away from the primary beam

Choose exposure based on thickness and not kgs

Choose the correct exposure for the area to be imaged



Thank you



Diagnostic Mindset

www.diagnosticmindset.com