

The systematic approach to interpret an abdominal study



Diagnostic Mindset

Thanks to Clinica Veterinaria Castellarano

Strategy



Giliola Spattini  
DVM, PhD, DECVDI


## Objectives

1. Optimise the exposure
2. Optimise the positioning
3. Systematic evaluation



## How to reduce the mistakes:

- To be systematic !
- To be systematic !
- To be systematic !
- To be systematic !
- To be systematic !
- To be systematic !
- To be systematic !
- To be systematic !
- To be systematic !



QUALITA'			COMMENTI
ESPOSIZIONE	OK	ERRATA	
POSIZIONAMENTO	OK	ERRATO	
IDENTIFICAZIONE	OK	ERRATA	
SVILUPPO	OK	ERRATO	
ARTIFATTI	OK	ERRATI	
INTERPRETAZIONE			
TESSUTI MOLLI EXTRA-ADDOMINALI	OK	NON OK	
STRUTTURE OSSEE	OK	NON OK	
PARETE ADDOMINALE	OK	NON OK	
TORACE CAUDALE	OK	NON OK	
DIAPHRAMMA	OK	NON OK	
FEGATO	OK	NON OK	
MILZA	OK	NON OK	
STOMACO	OK	NON OK	
PANCREAS	OK	NON OK	
PICCOLO INTESTINO	OK	NON OK	
GROSSO INTESTINO	OK	NON OK	
CAVITA' PERTONEALE	OK	NON OK	
SPAZIO RETROPERTONEALE	OK	NON OK	
RENI	OK	NON OK	
VESCICA	OK	NON OK	
PROSTATA	OK	NON OK	

## • Valutazione sistematica

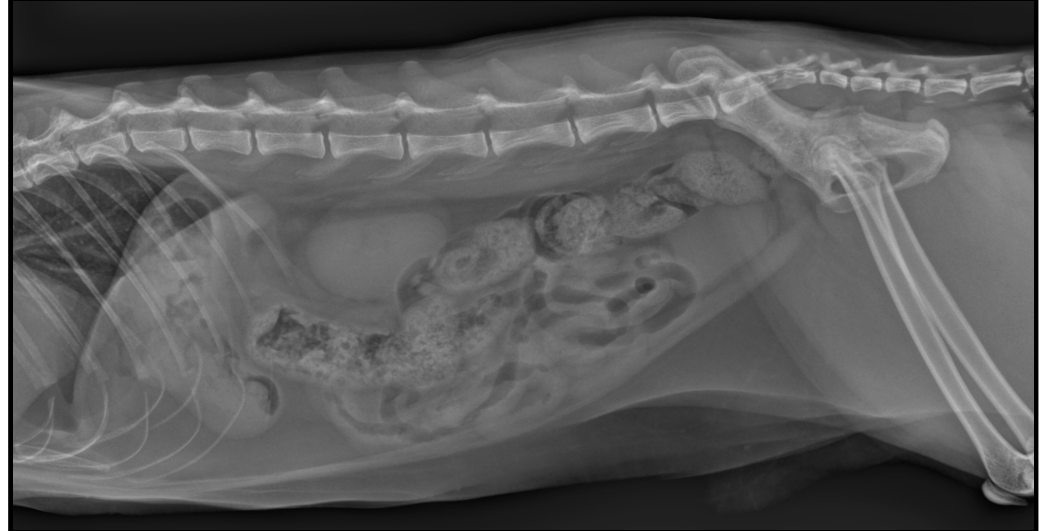
UTERO ED OVAIE	OK	NON OK	
LINFONODI	OK	NON OK	
<b>SE TUTTO OK</b>			<b>ADDOME NEI LIMITI DELLA NORMA</b>
<b>DIAGNOSI RADIOGRAFICA</b>			
<b>DIAGNOSI DIFFERENZIALI</b>			
<b>COME CONTINUARE</b>			

Duffy, DHS, FS, 7 years

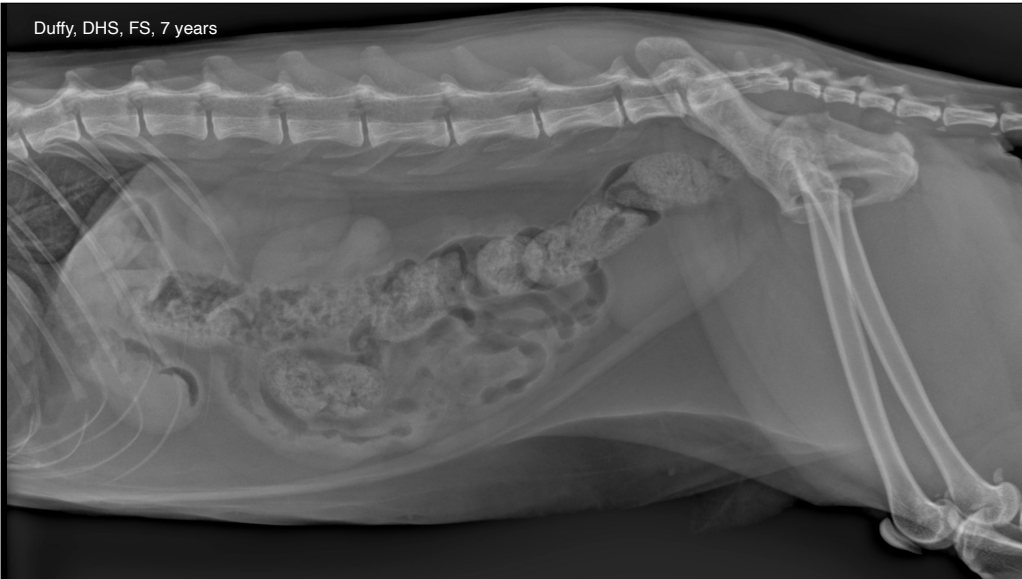
- Attacked by a dog
- Laceration of the soft tissues between the shoulder blades and swelling on the abdominal wall
- Abdominal perforation?



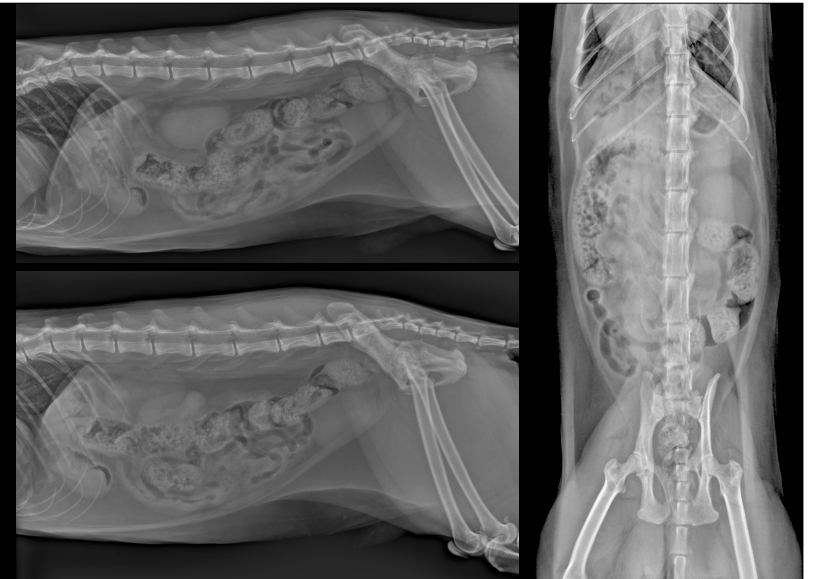
Duffy, DHS, FS, 7 years



Duffy, DHS, FS, 7 years



Duffy, DHS, FS, 7 years



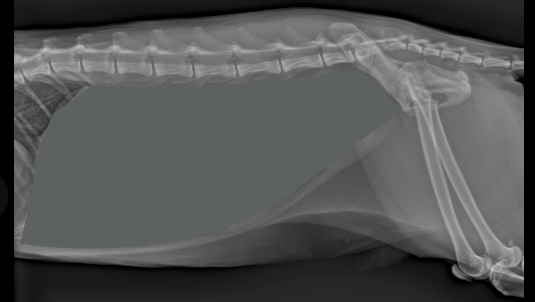
## Your evaluation

- Is there hip dysplasia?
- Is there hepatomegaly?
- The stomach is full?



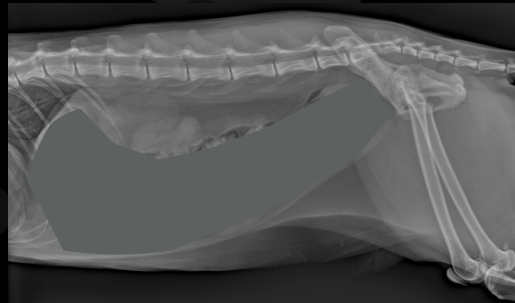
## Systemic evaluation: 1

- Extra-abdominal structures:
  - Thorax
  - Vertebral column
  - Pelvis and hind limbs
  - Subcutaneous tissues
  - Abdominal walls



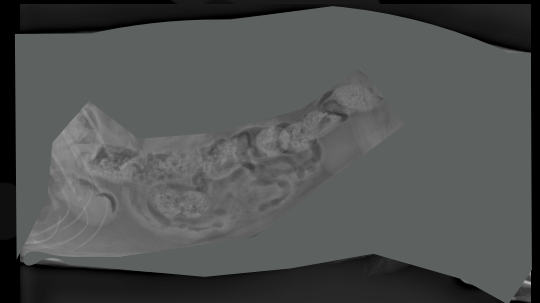
## Systemic evaluation: 2

- Retroperitoneal space



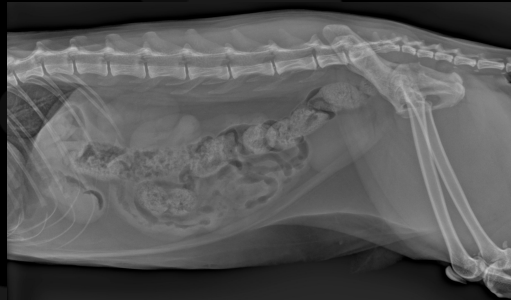
## Systemic evaluation: 3

- Peritoneal space:
  - How is the detail?
  - How is the contrast?



## Systemic evaluation: 4

- The abdominal organs:
- Evaluation by Roentgen numbers



## Roentgen Numbers

- M
- N
- O
- P
- S
- S



You need to know the normal to be able to understand the abnormal

## Radiopacity

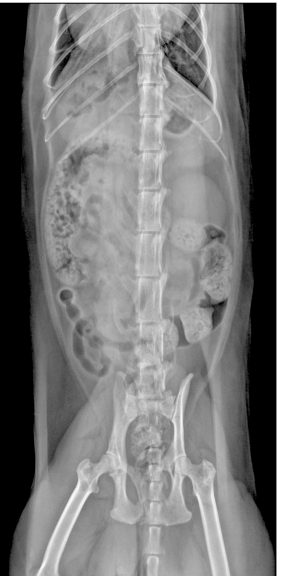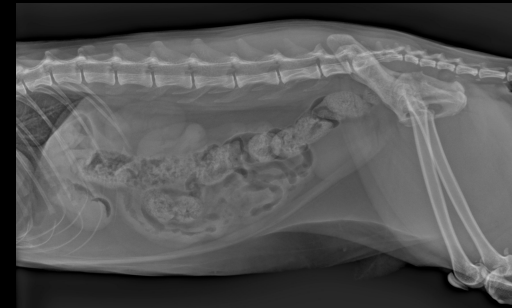
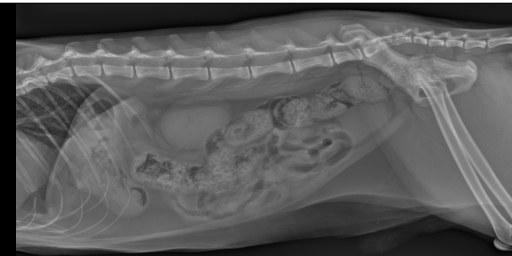
Opacity >>

<< Opacity



Duffy, DHS, FS, 7 years

Radiographic diagnoses



Duffy, DHS, FS, 7 years

Radiographic diagnoses:

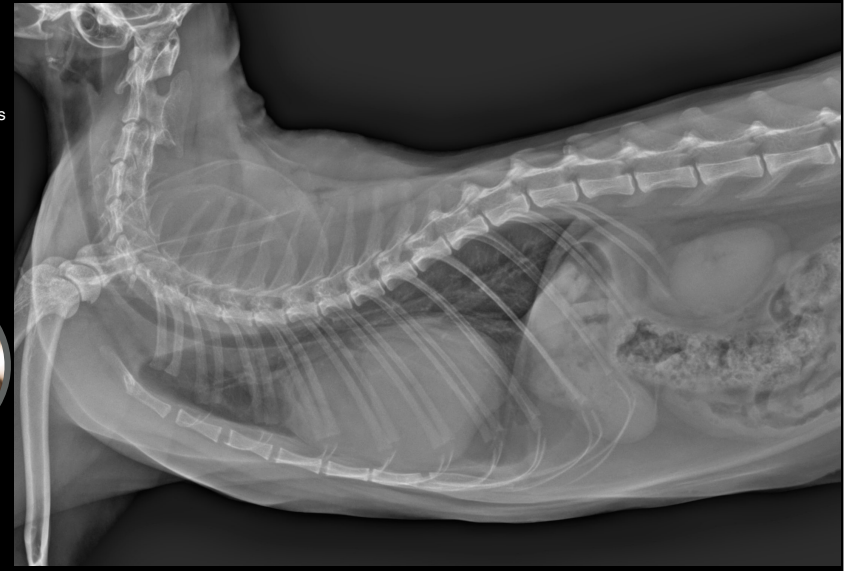
- Displaced-absent liver
- No signs of abdominal perforation

Conclusions:

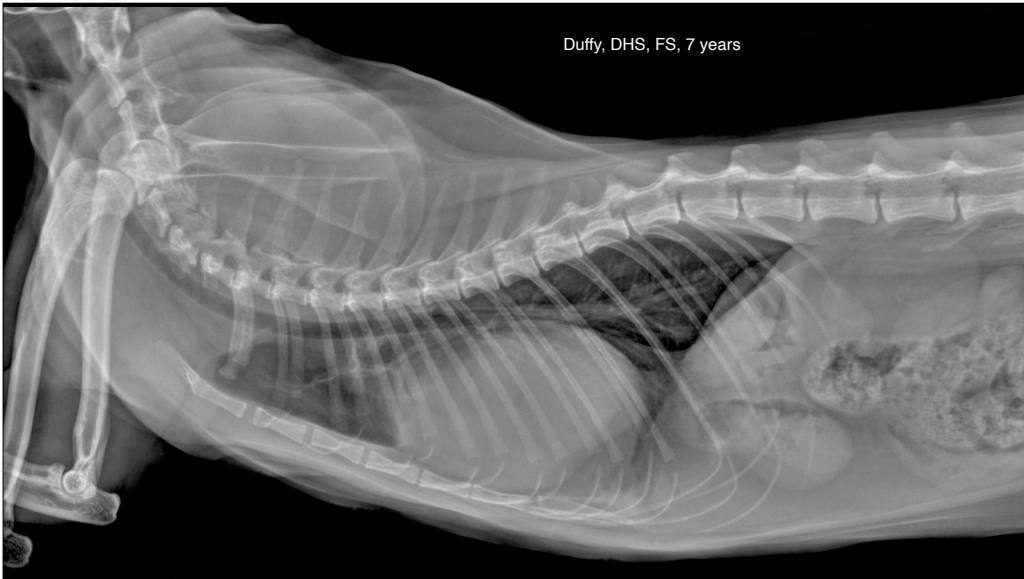- Suspected ruptured diaphragm or PPDH
- Thoracic imaging



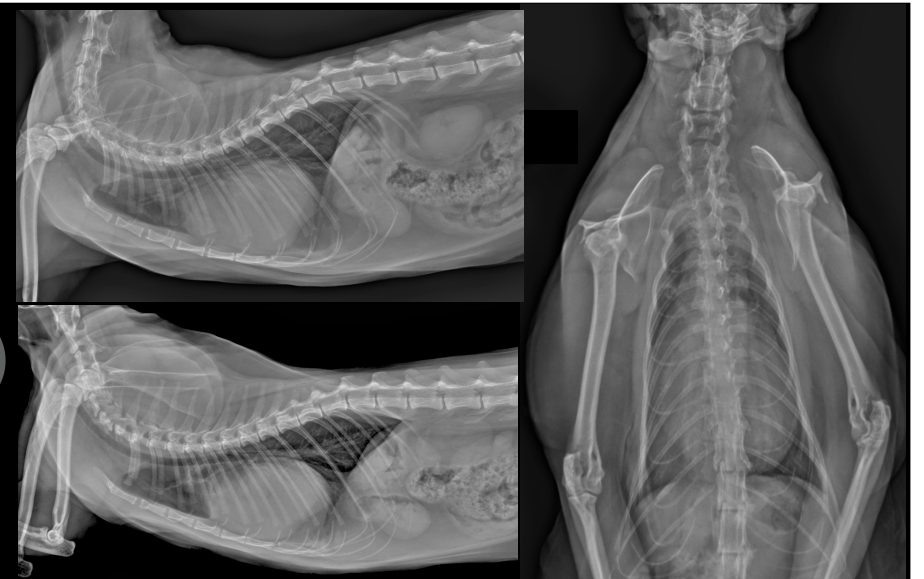
Duffy, DHS, FS, 7 years



Duffy, DHS, FS, 7 years

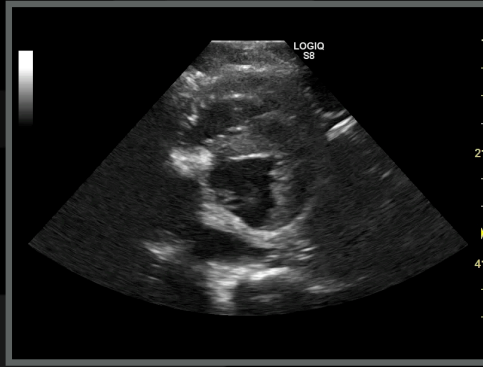
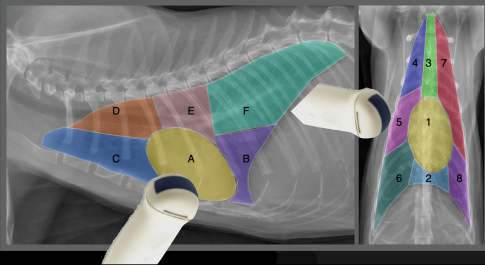
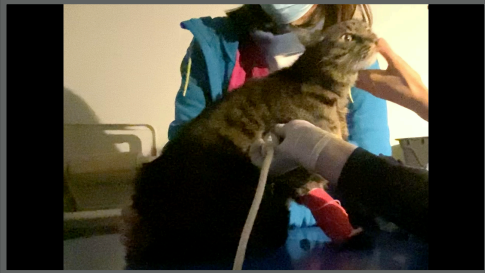

Duffy, DHS, FS, 7 years

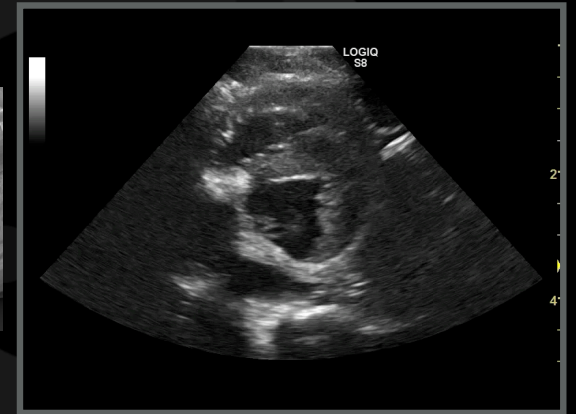
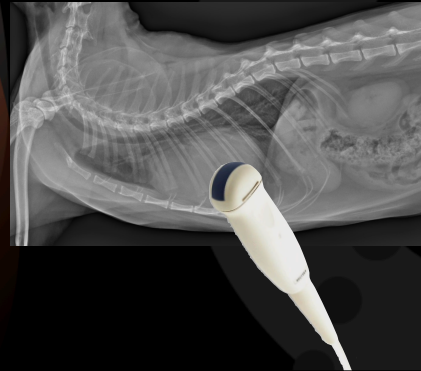


Duffy, DHS, FS, 7 years

A1

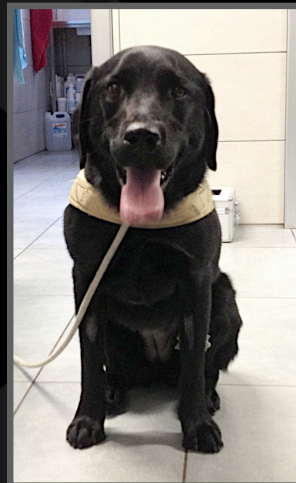


Duffy, DHS, FS, 7 years



Maya, Labrador, FI, 3 years

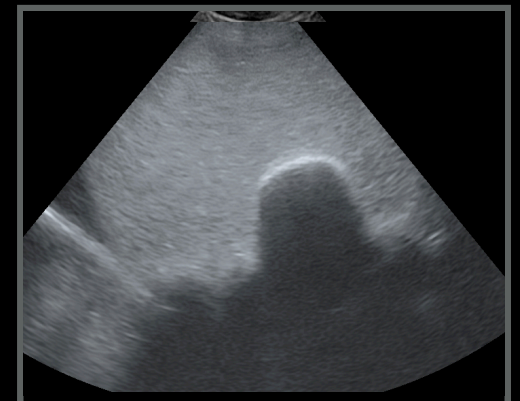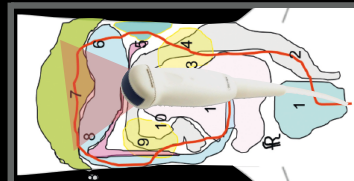
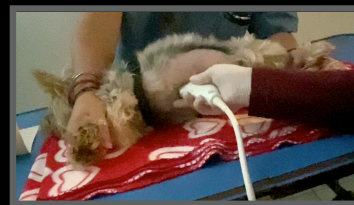
- Vomiting since yesterday
- Still eating but vomit
- Unremarkable abdominal palpation
- Unremarkable lab-works



Maya, FI, 3 years

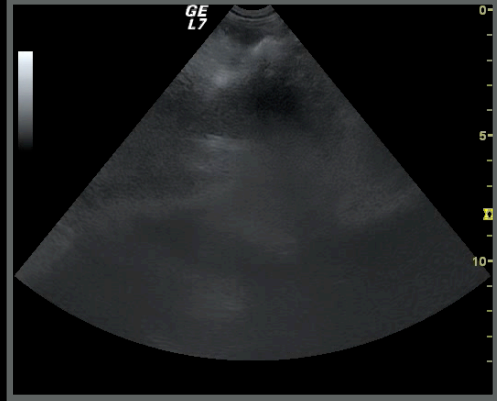
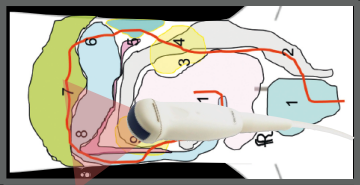
Probe position in a different patient

7



Maya, FI, 3 years

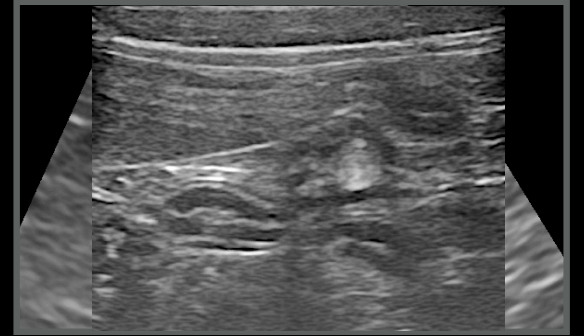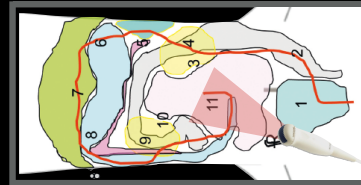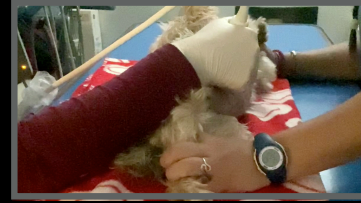Probe position in a different patient



8

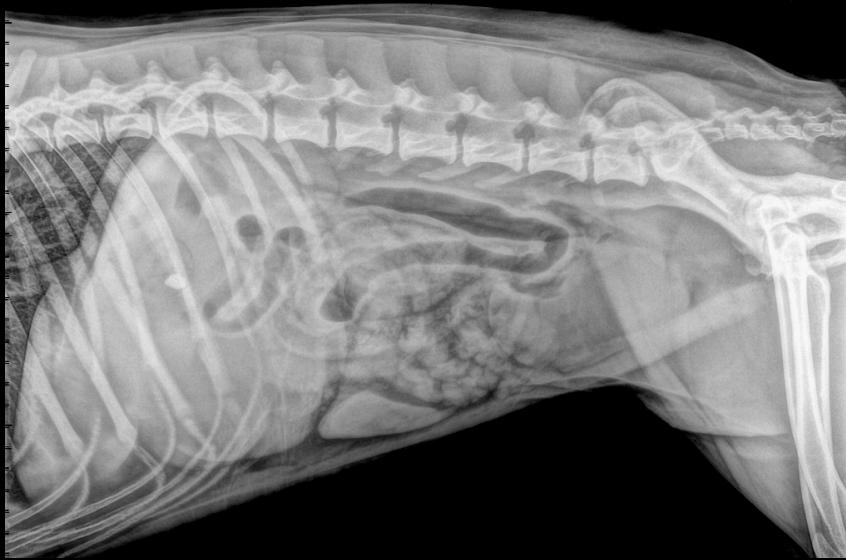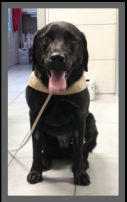
Maya, FI, 3 years

Probe position in a different patient

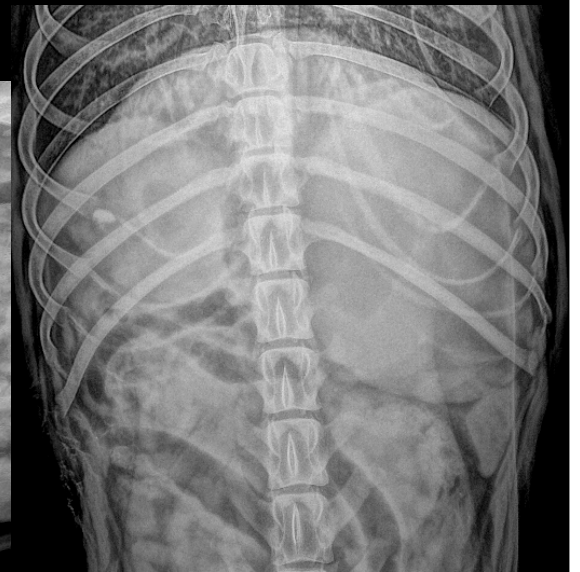
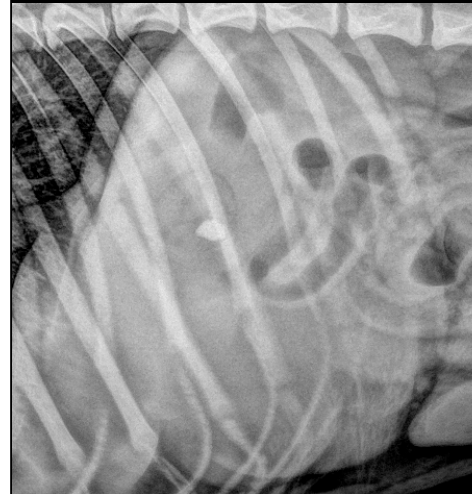


11

Maya, FI, 3 years



Maya, FI, 3 years



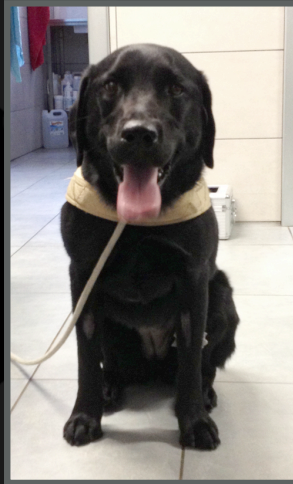
Maya, Labrador, FI, 3 years

Radiographic diagnoses:

- Pyloric obstruction by a FB



Conclusions:

- Surgery?
- Endoscopy?

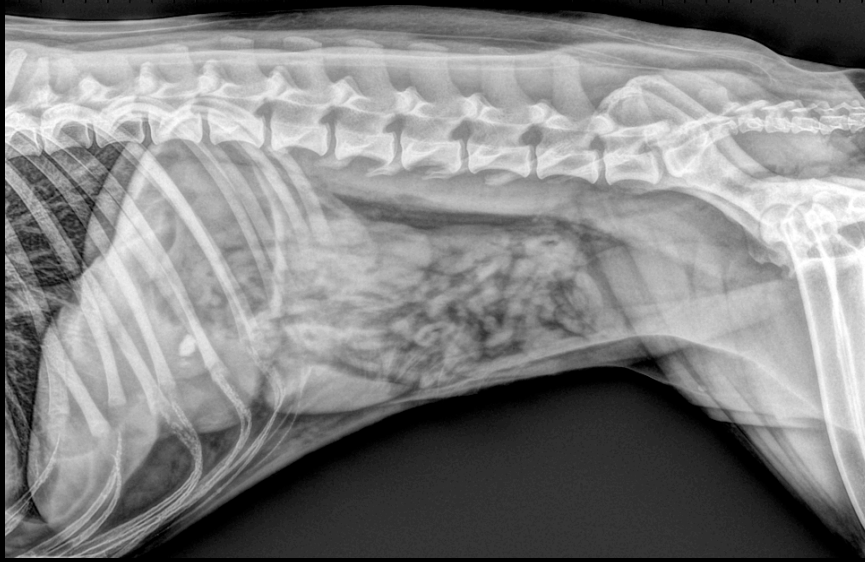


Maya, Labrador, FI, 3 years

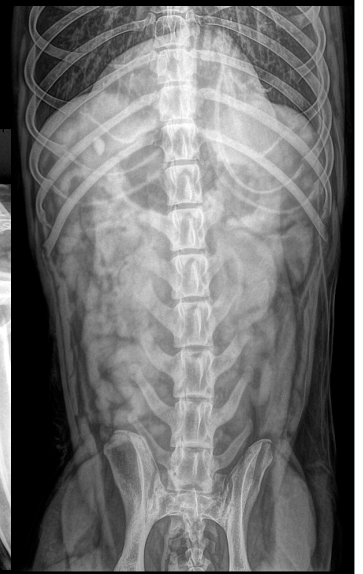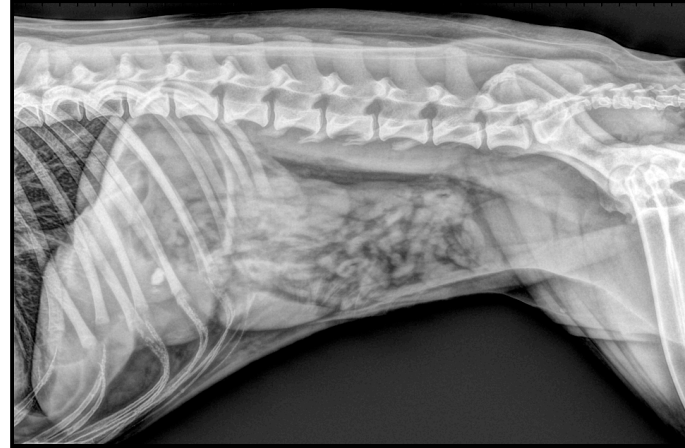
- While the medical team discuss about Maya, She vomits the foreign body!



Maya, FI,  
3 years

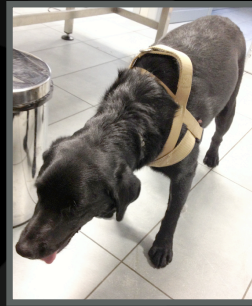


Maya, FI, 3 years



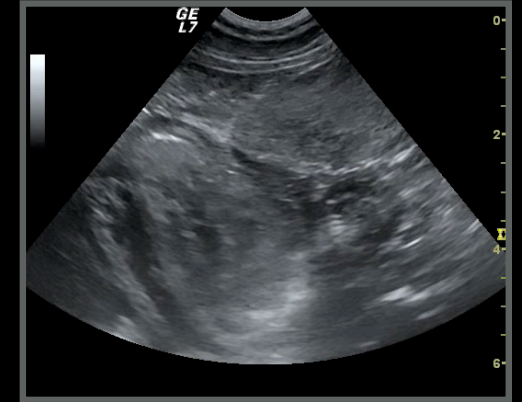
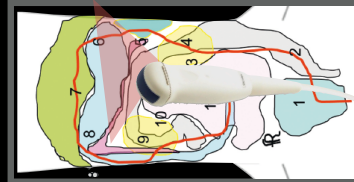
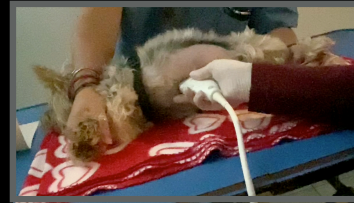## Maya, Labrador, FI, 3 years

- Diagnosed a pyloric FB-resolved
- Send home, recheck in two days
- Come back the day after for acute vomiting
- Not eating
- Abdominal pain



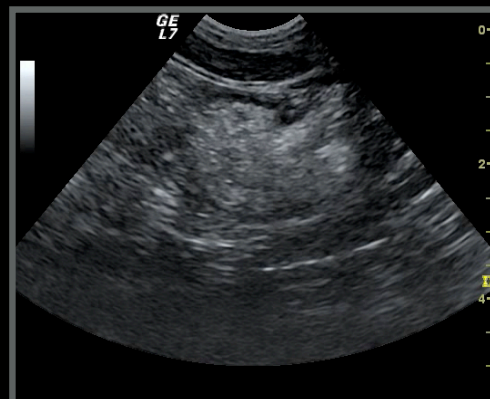
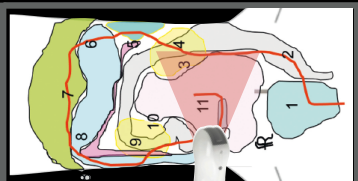
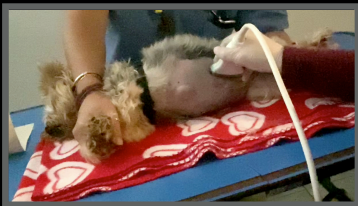## Maya, FI, 3 years

Probe position in a different patient



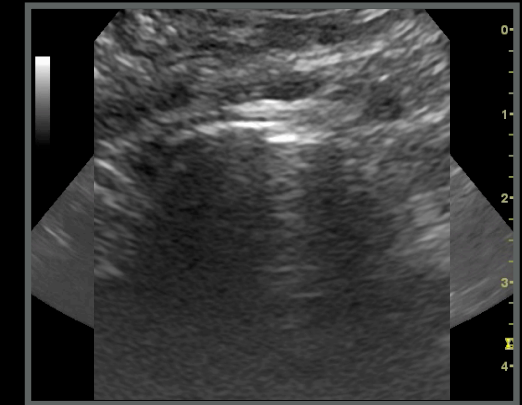
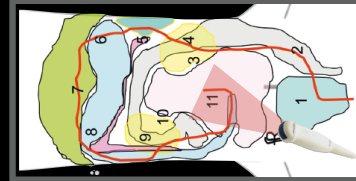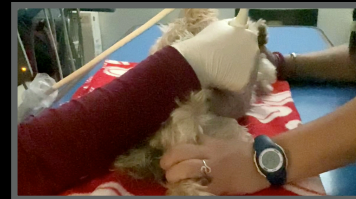## Maya, FI, 3 years

Probe position in a different patient



## Maya, FI, 3 years

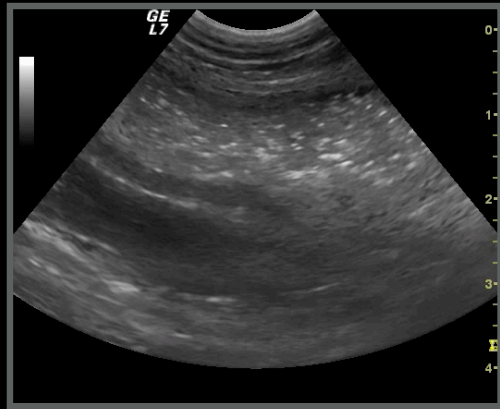
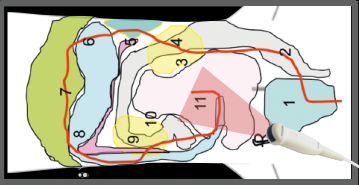
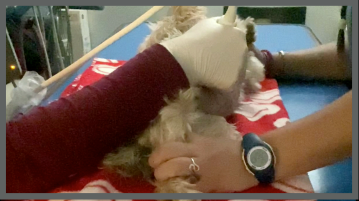Probe position in a different patient





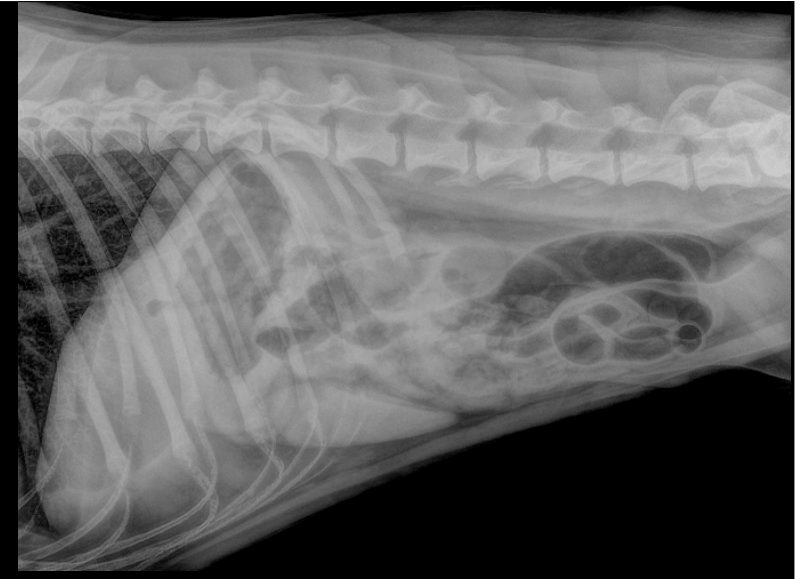
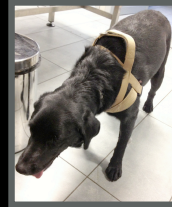
Maya, FI, 3 years

Probe position in a different patient

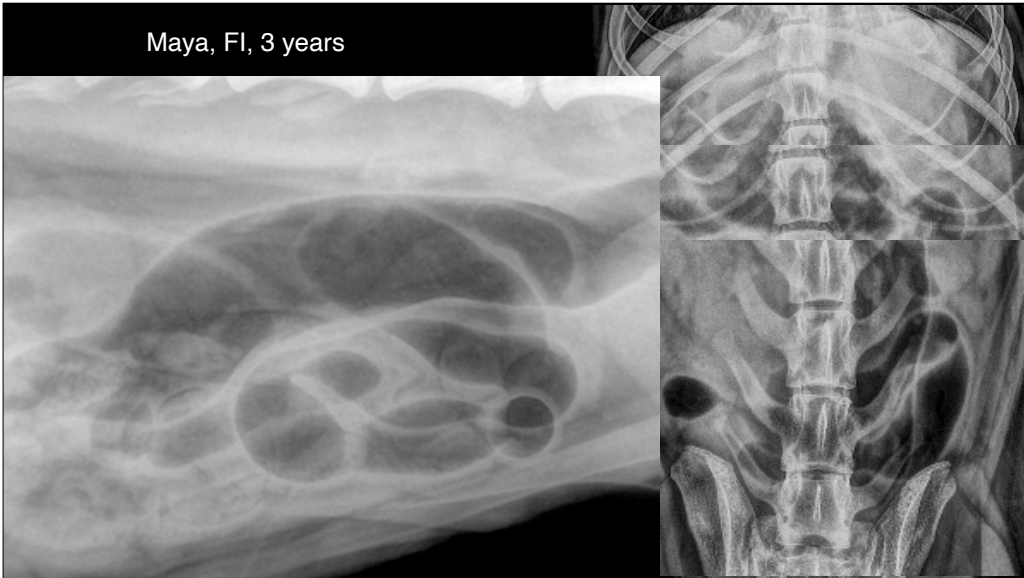

11

Maya, FI,  
3 years



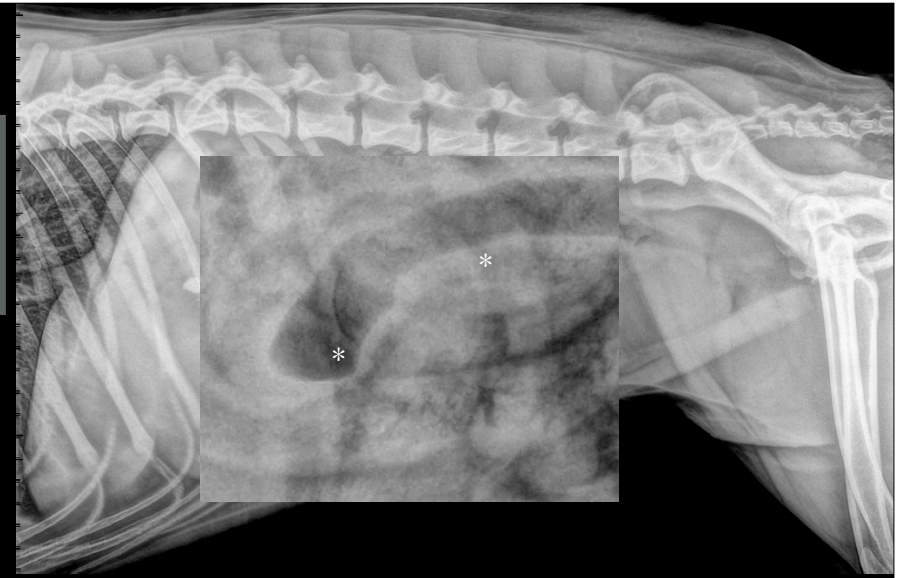
Maya, FI, 3 years



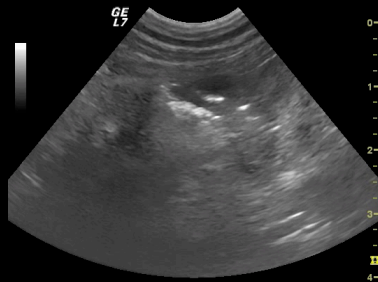
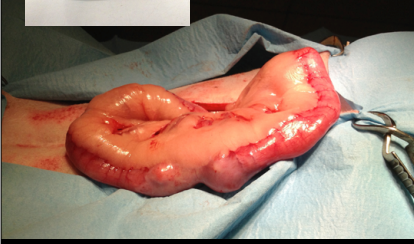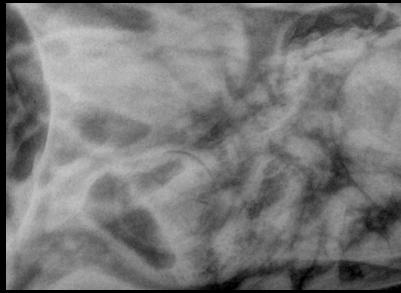
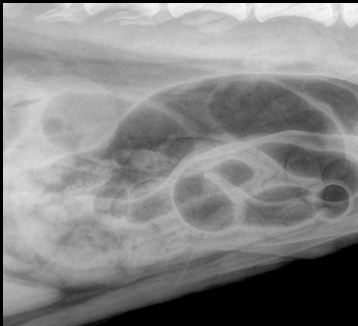Maya, FI,  
3 years



Revision!



Maya, FI, 3 years




## Conclusions

To decrease the interpretation errors it is necessary to be systematic!!!

Three views better than two!

Good positioning

Good exposure



# Thank you



Diagnostic Mindset

[www.diagnosticmindset.com](http://www.diagnosticmindset.com)