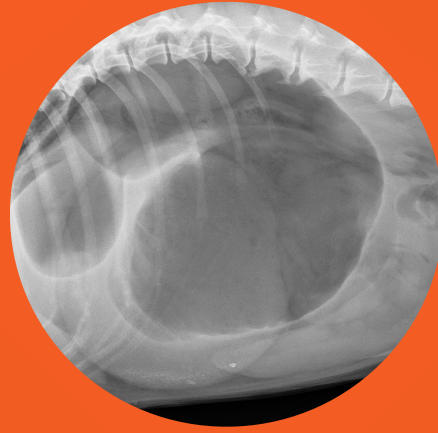


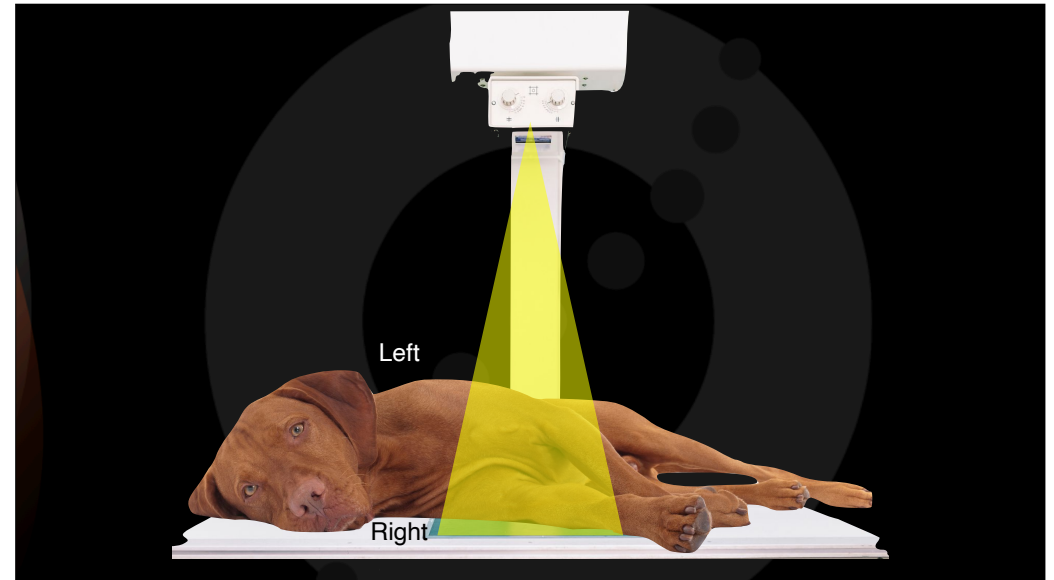
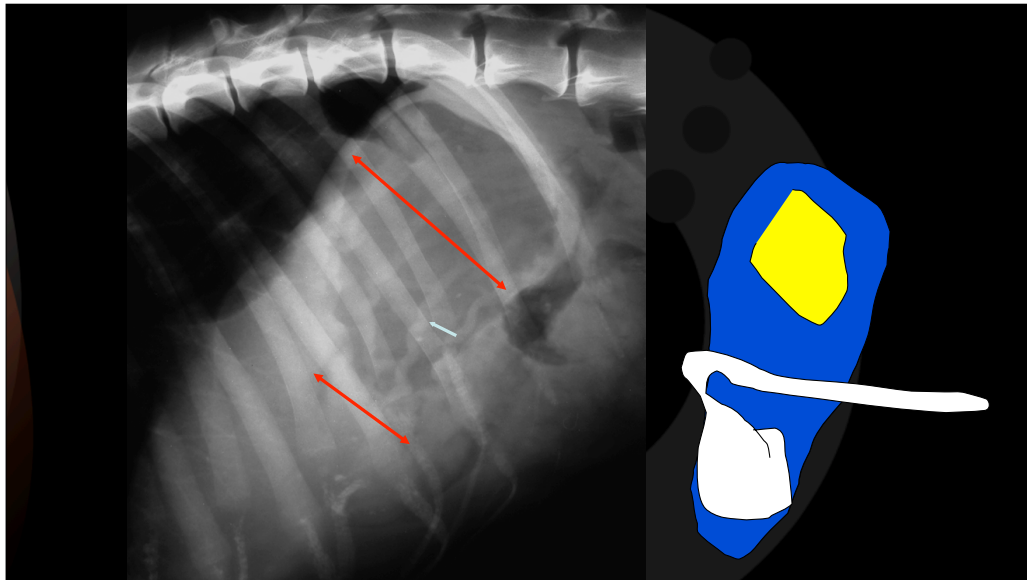
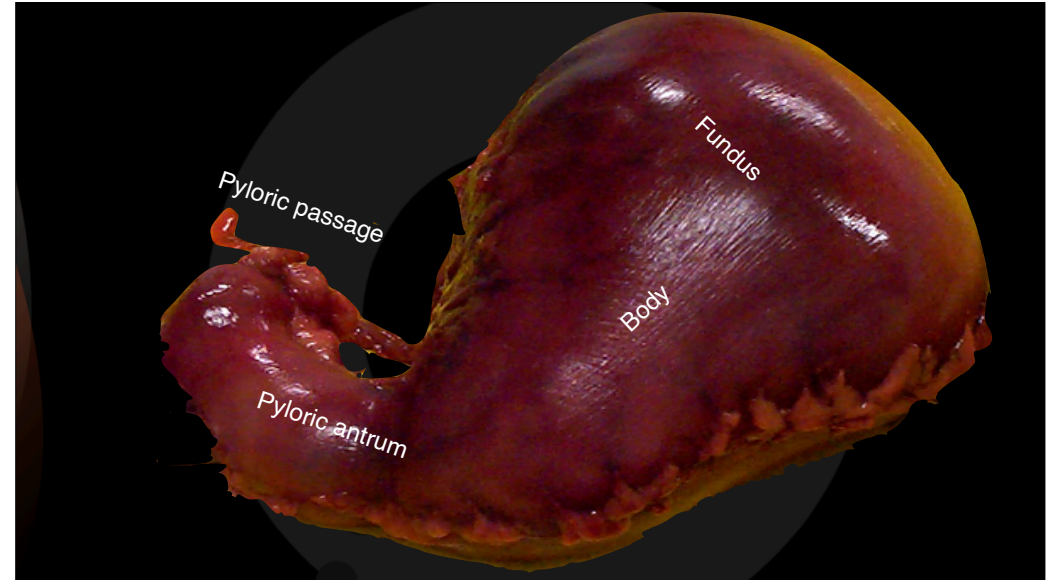
Torsione, dilatazione,
congestione o
occlusione gastrica?

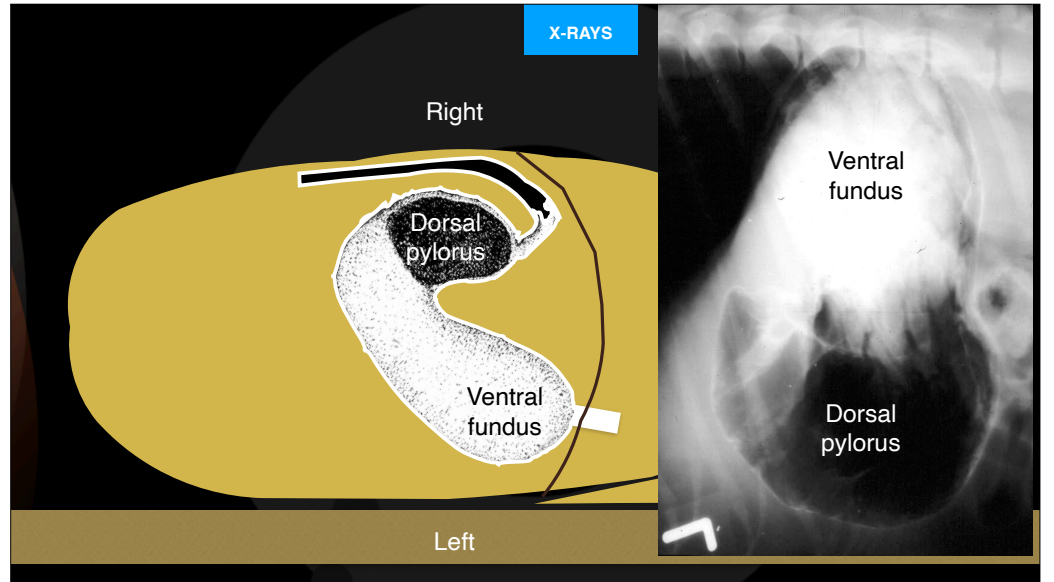
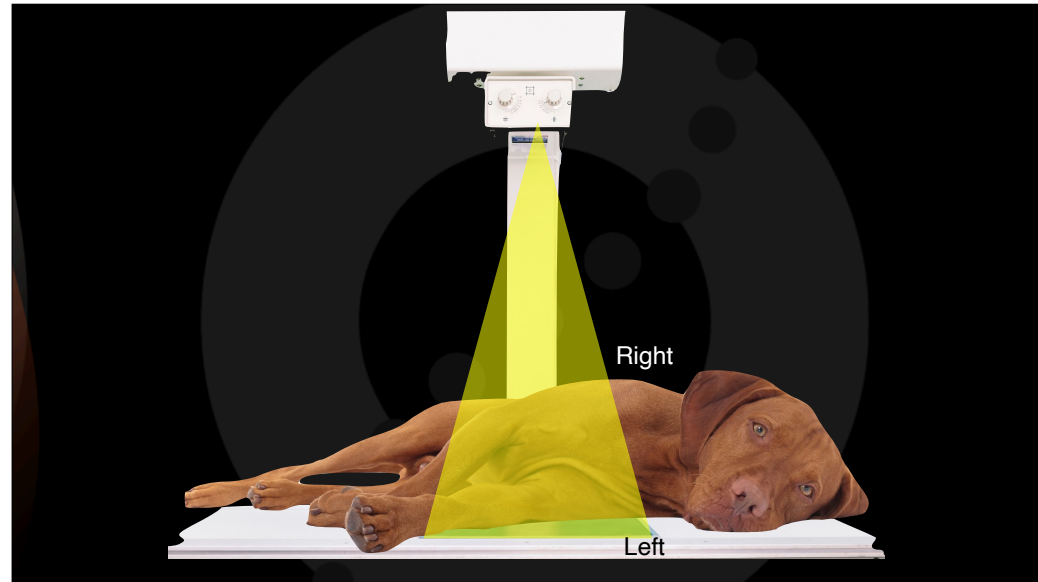
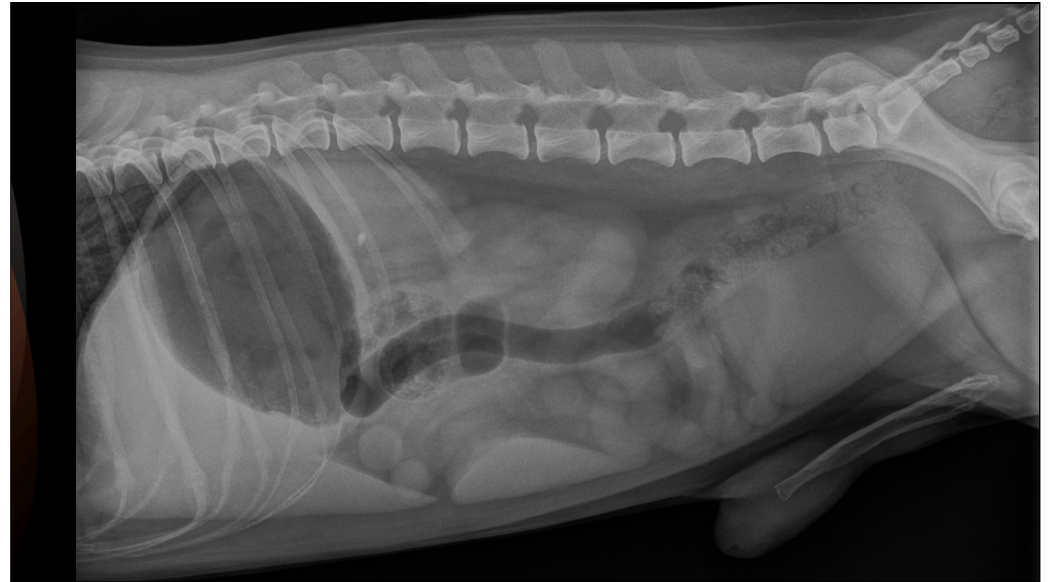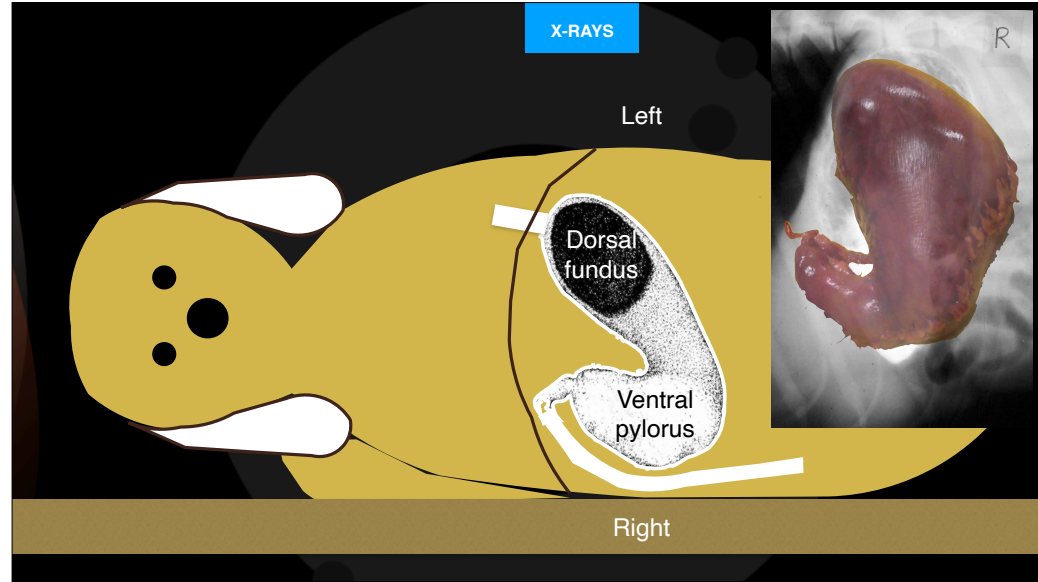


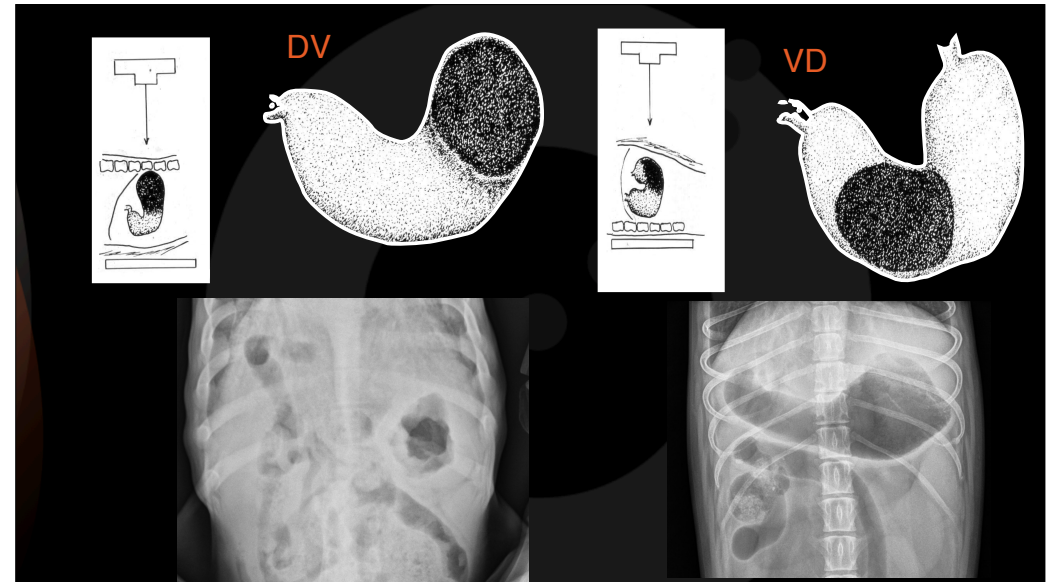
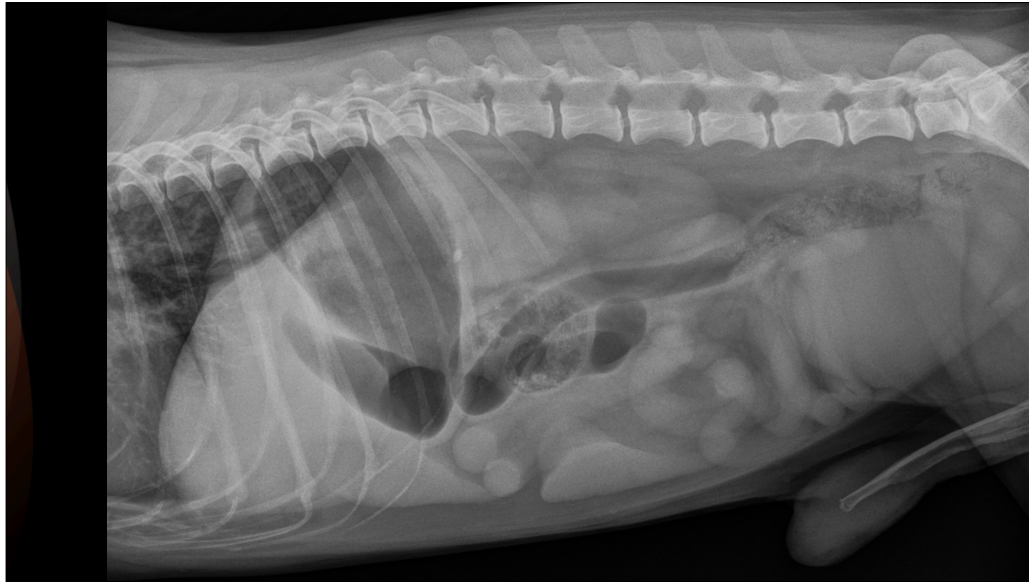Diagnostic Mindset

Thanks to Clinica Veterinaria Castellarano

Giliola Spattini
DVM, PhD, DECVDI

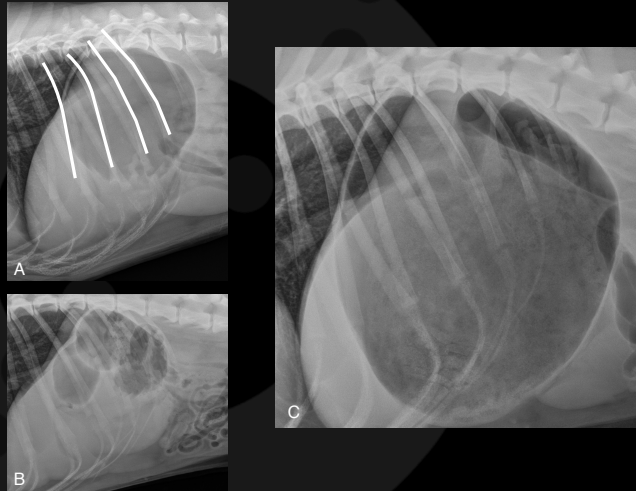






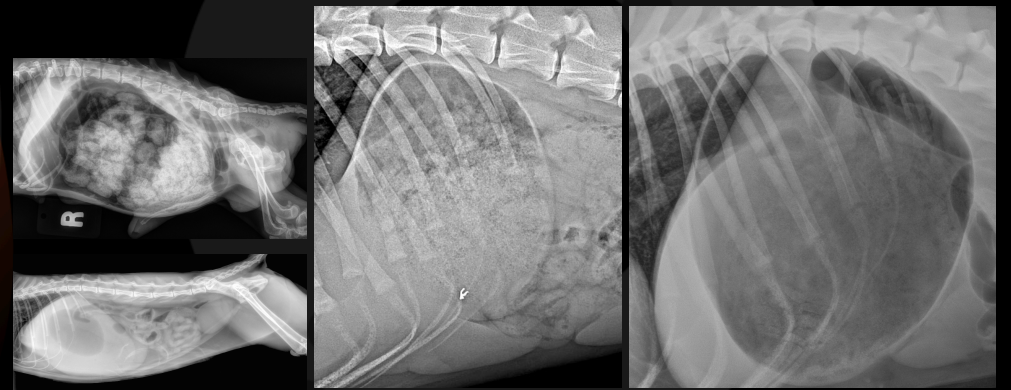
When the stomach is considered enlarged?

- When the width of the fundus is more than three intercostal space



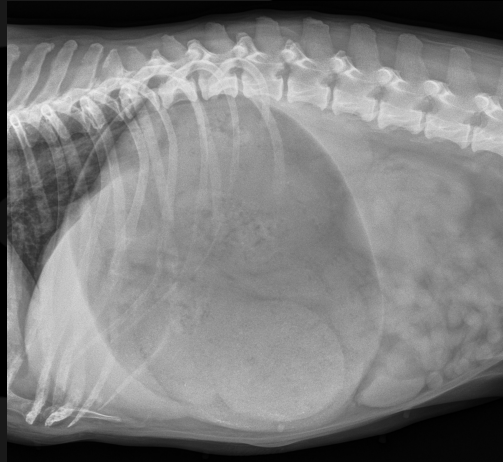Does the gastric content matters?

- Gas · Dilatation or Volvulus
- Fluid · Sub-occlusion or severe gastritis
- Granular material · Gastric congestion



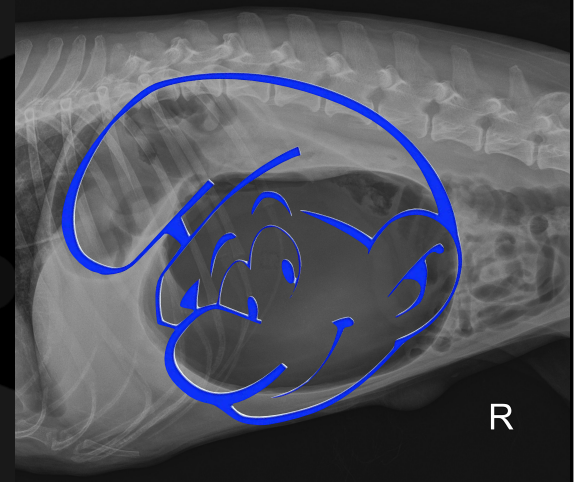
How to check for a gastric volvulus

- The fundus is dorsal and to the left?
- The pylorus is ventral and to the right?



How to check for a gastric volvulus

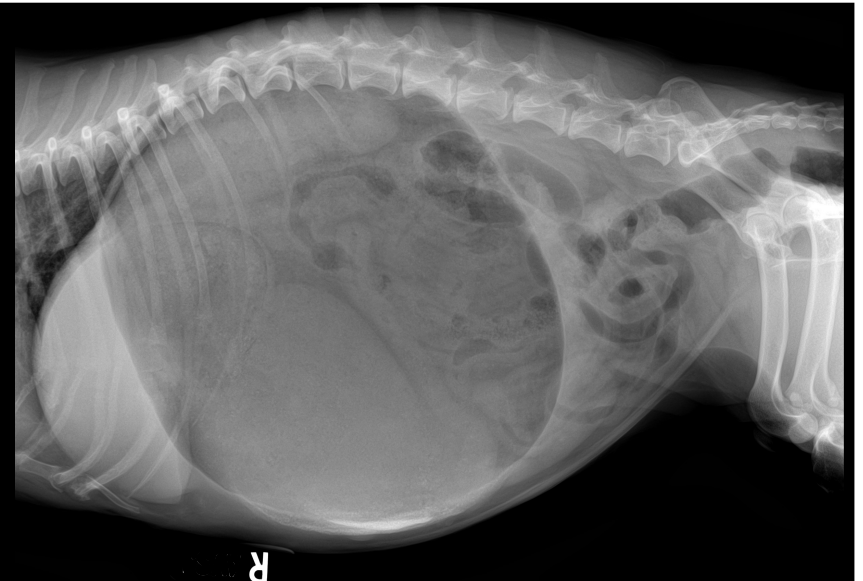- Is the fundus dorsal and to the left?
- Is the pylorus ventral and to the right?
- Can you see a smurf face?



Learning check!

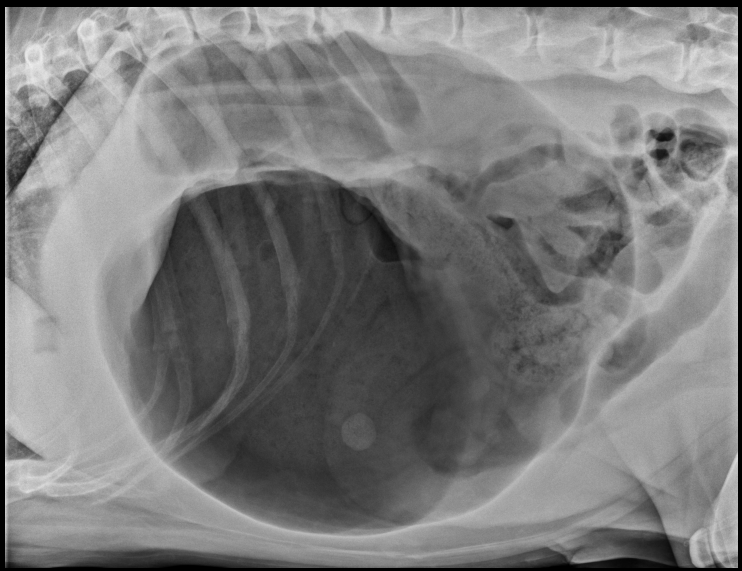CASE 1

Lilly, Dachshund, FS, 15 years



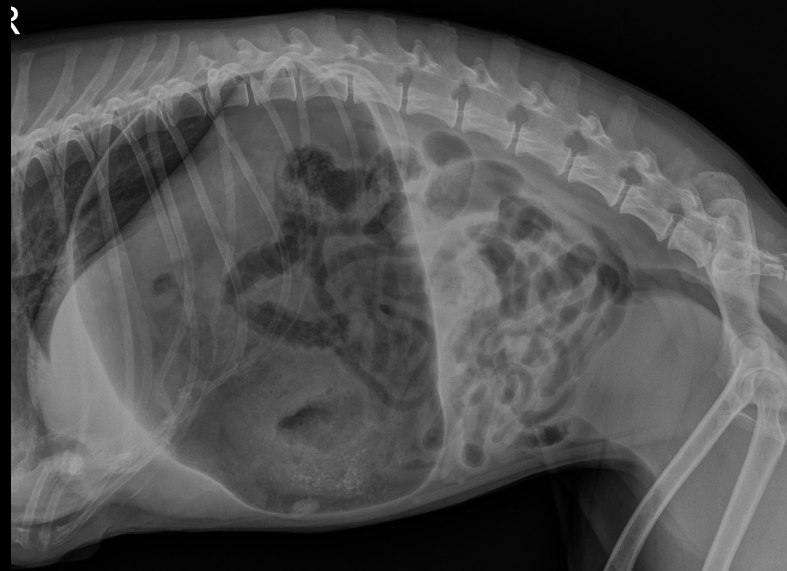CASE 2

Tank, American SH, MN, 10 years



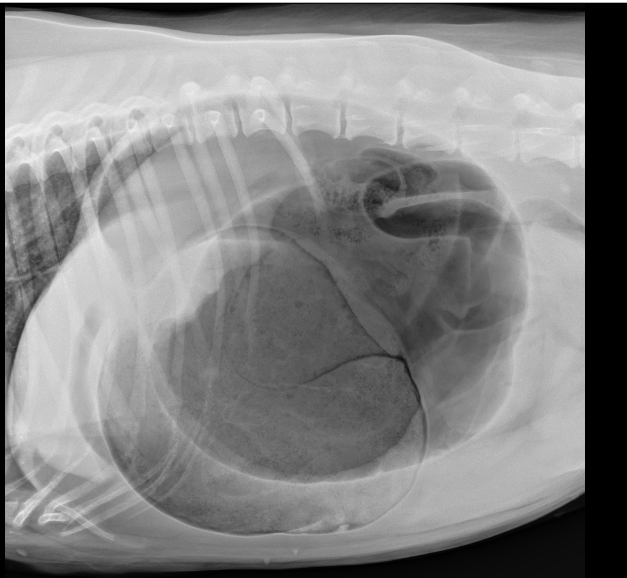
CASE 3

Princess, Mongrel, FS, 17 years



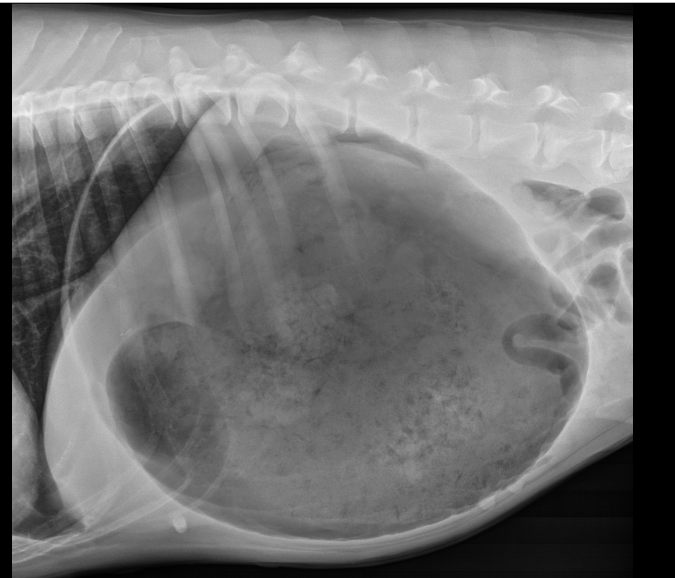CASE 4

Bella, Mongrel, FS, 7 years



CASE 5

Basil, Great Dane, FI, 7 years

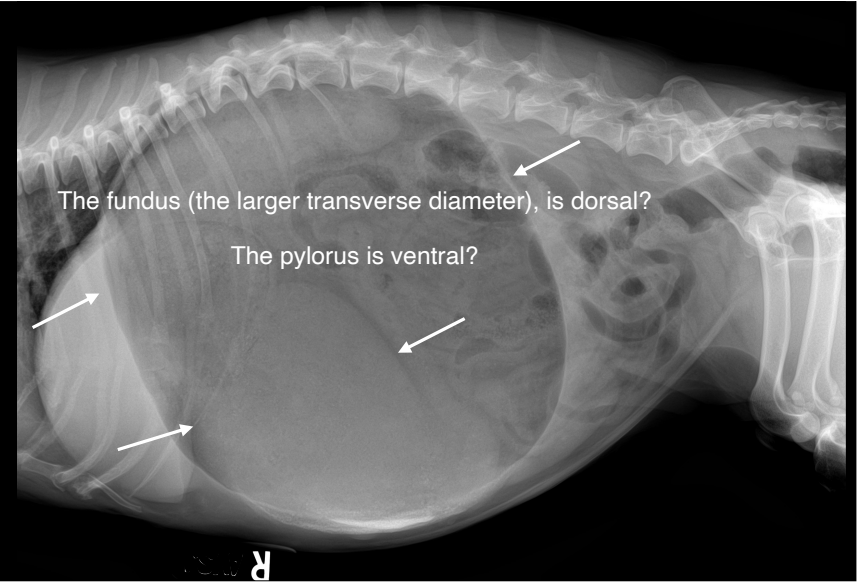


Your evaluation

- Which patient has a gastric volvulus, and which has a gastric dilatation?
- Where is the fundus, and where is the pylorus?

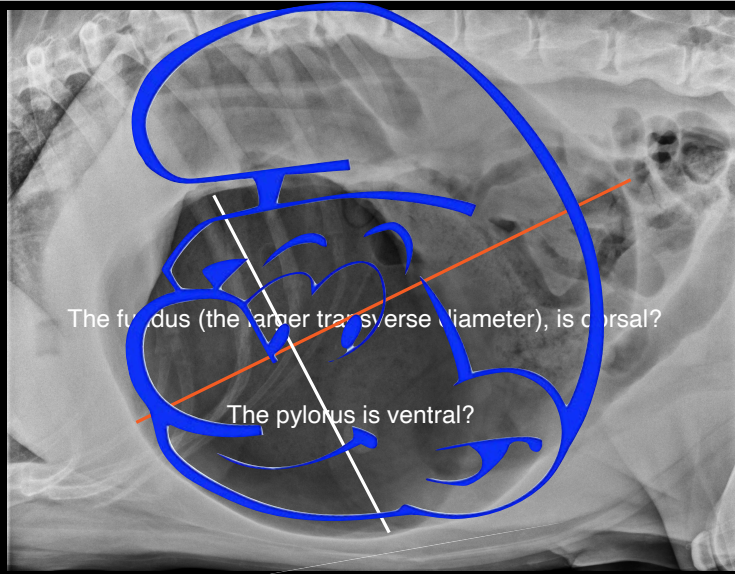
CASE 1

Lilly, Dachshund, FS, 15 years



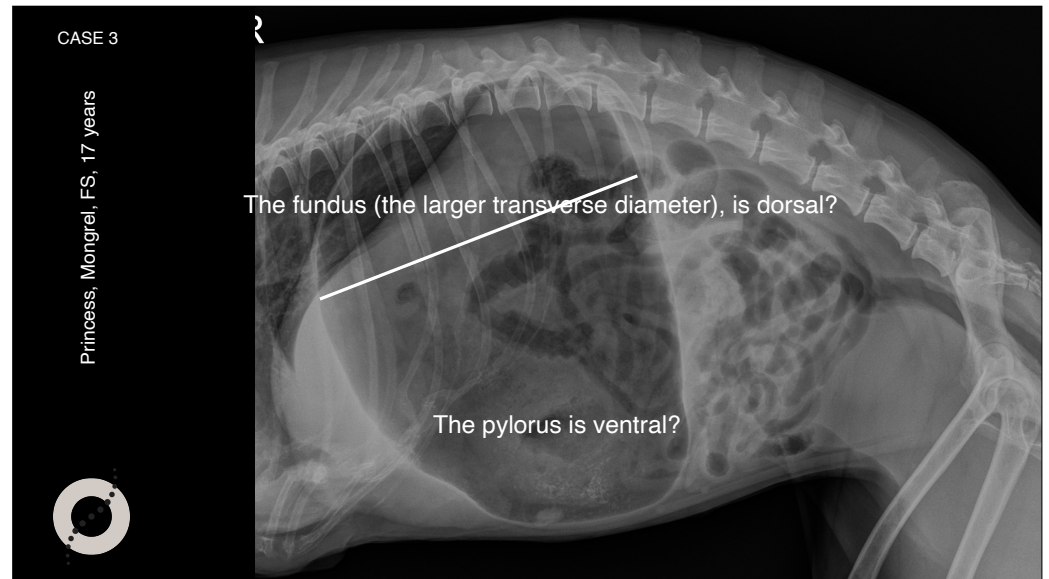
CASE 2

Tank, American SH, MN, 10 years



CASE 3

Princess, Mongrel, FS, 17 years

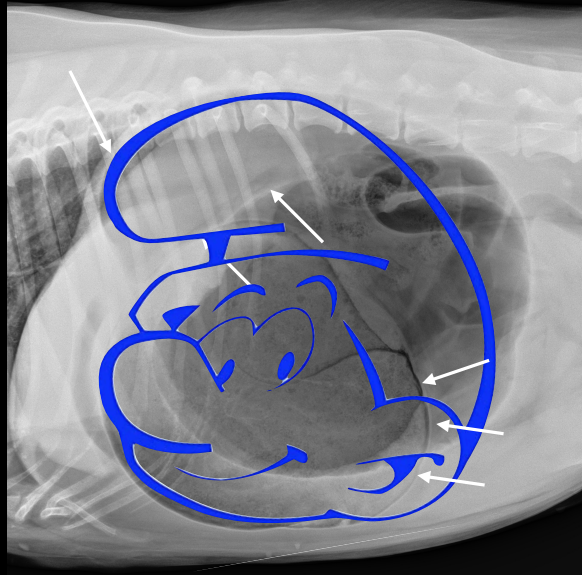


CASE 4

Bella, Mongrel, FS, 7 years

The fundus (the larger transverse diameter), is dorsal?

The pylorus is ventral?

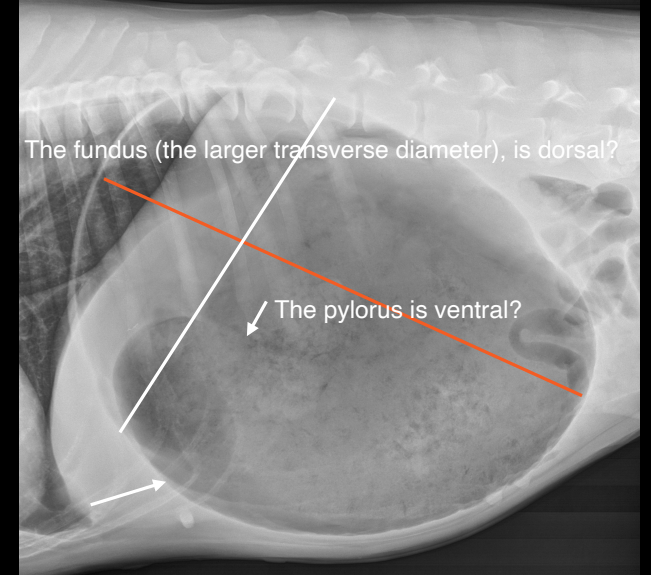


CASE 5

Basil, Great Dane, FI, 7 years

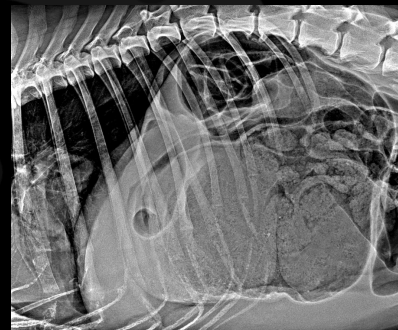
The fundus (the larger transverse diameter), is dorsal?

The pylorus is ventral?



Key points

- Check the pylorus
- Check the fundus
- Smurfs face
- Check every radiographic details



Rocky, Mongrel, MN, 13 years

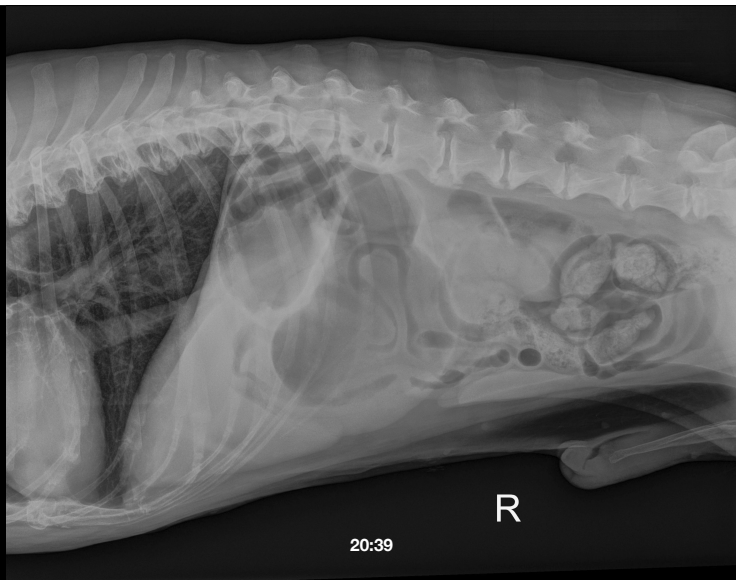
Stiff gait

The owner is concern for back pain

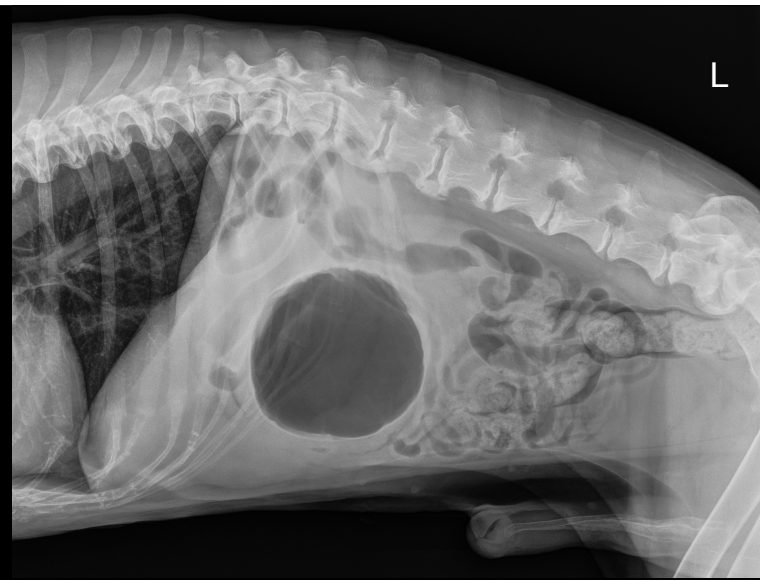
Tense abdomen on PE



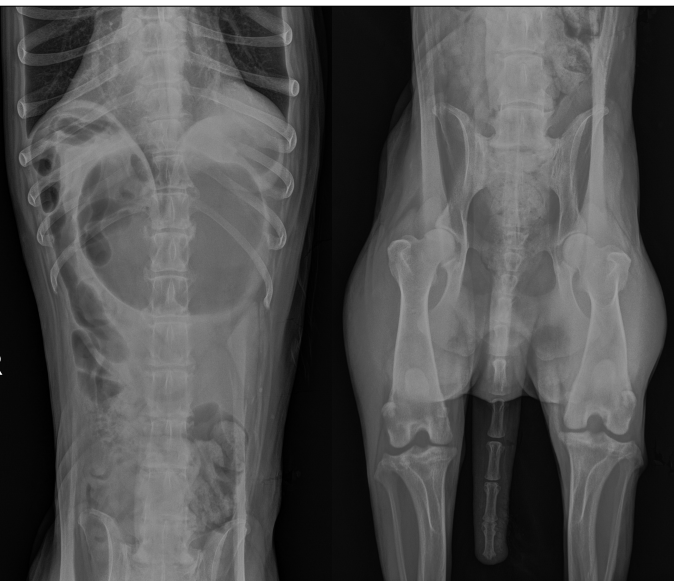
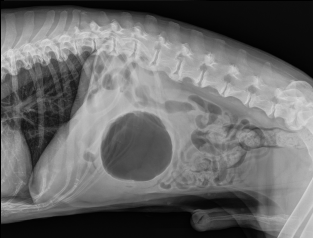
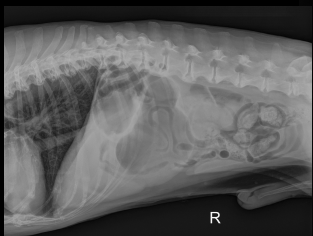
Rocky
MN, 13 years



Rocky
MN, 13 years



Rocky
MN, 13 years



Your evaluation

- Is there gastric torsion?
- Is there gastric dilatation?
- Is there hip dysplasia?



Rocky, Mongrel, MN, 13 years

Radiographic diagnoses:

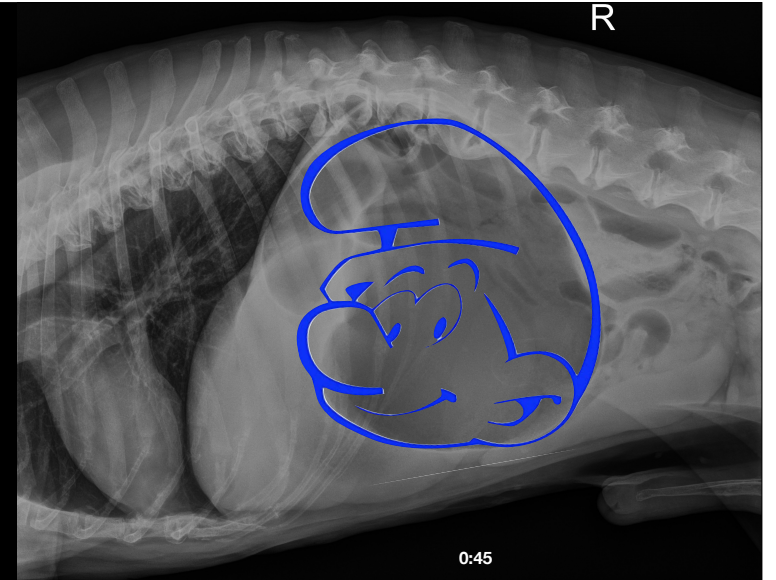

- Multiple sites of chronic thoracolumbar spondyloses
- Ventral displacement of the fundus
- Dorsal displacement of the pylorus



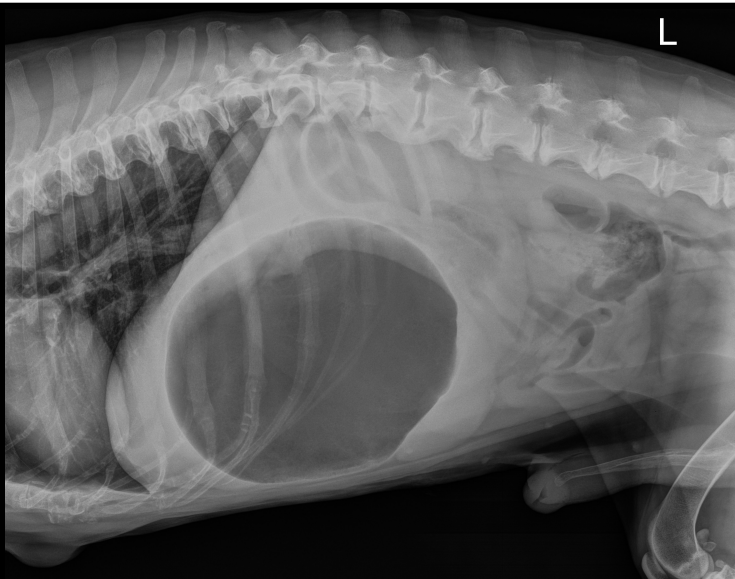
Rocky
MN, 13 years

Sialorrhea

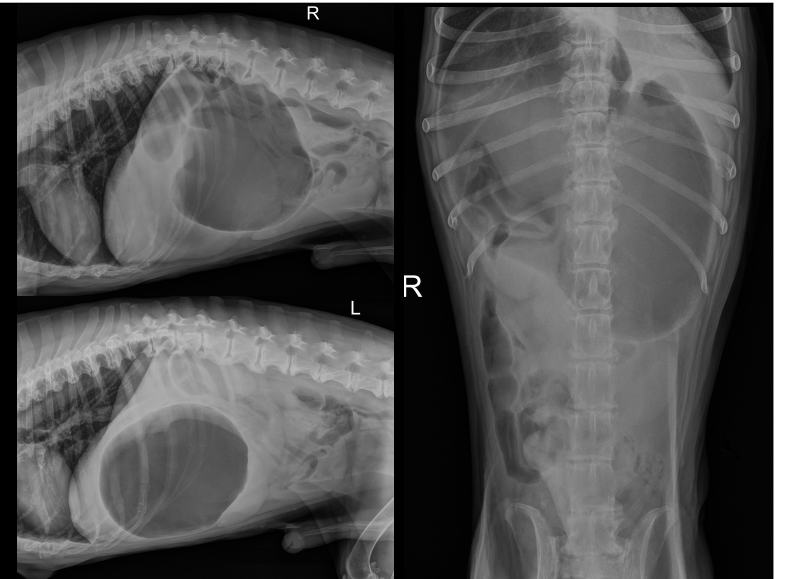
Distended abdomen

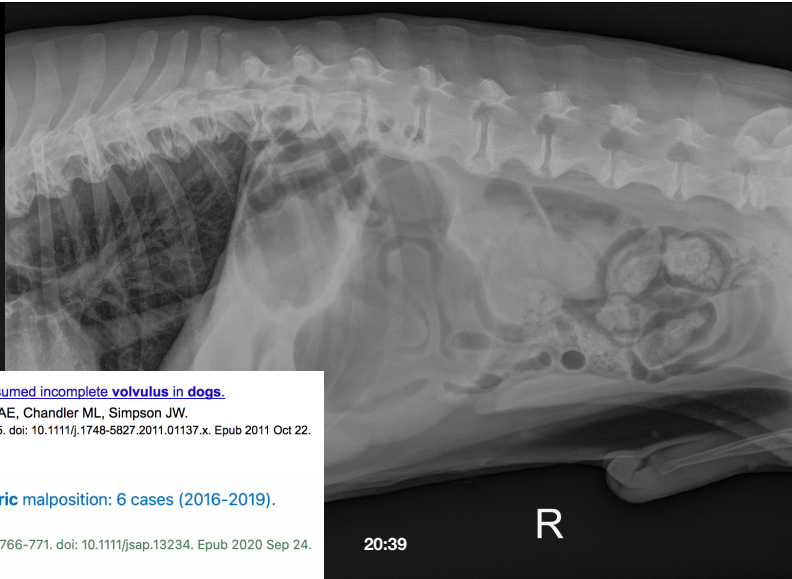


Flocky
MN, 13 years



Flocky
MN, 13 years





Chronic gastric instability and presumed incomplete volvulus in dogs.

Paris JK, Yool DA, Reed N, Ridyard AE, Chandler ML, Simpson JW.
J Small Anim Pract. 2011 Dec;52(12):651-5. doi: 10.1111/j.1748-5827.2011.01137.x. Epub 2011 Oct 22.
PMID: 22017675
[Similar articles](#)

CT findings in dogs with gastric malposition: 6 cases (2016-2019).

White C, Dirrig H, Fitzgerald E.
J Small Anim Pract. 2020 Dec;61(12):766-771. doi: 10.1111/jsap.13234. Epub 2020 Sep 24.
PMID: 32974915

20:39

R

Principessa, English Bulldog, FI, 12 years

- Severe vomiting for the last two months

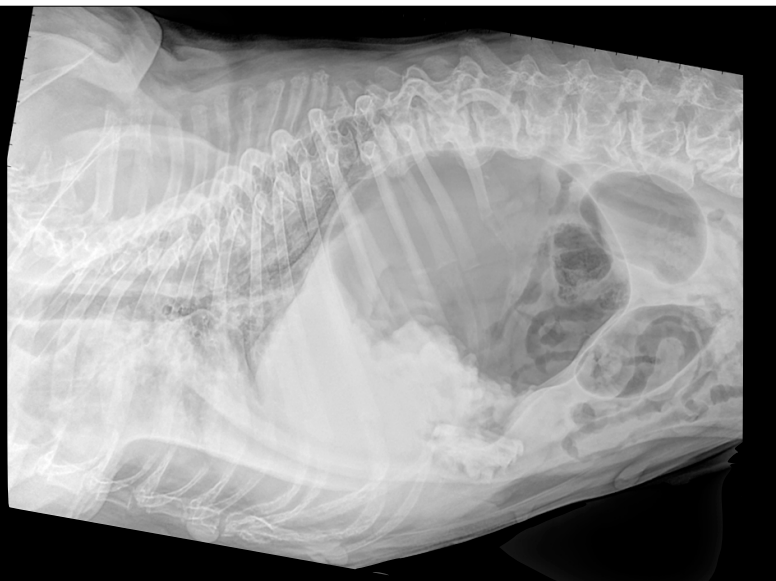
Severe weight loss

Suspected gastric mass on first ultrasonographic consultation

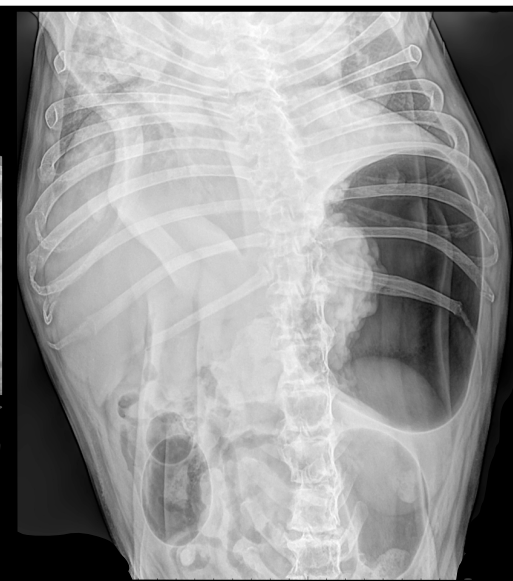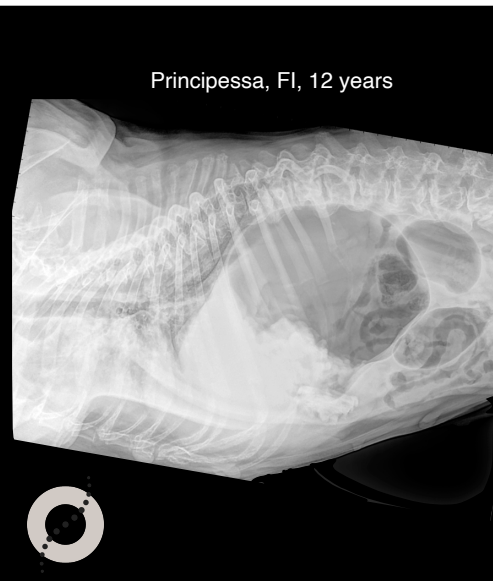Second ultrasonographer didn't find the suspected mass



Principessa, FI, 12 years




Principessa, FI, 12 years

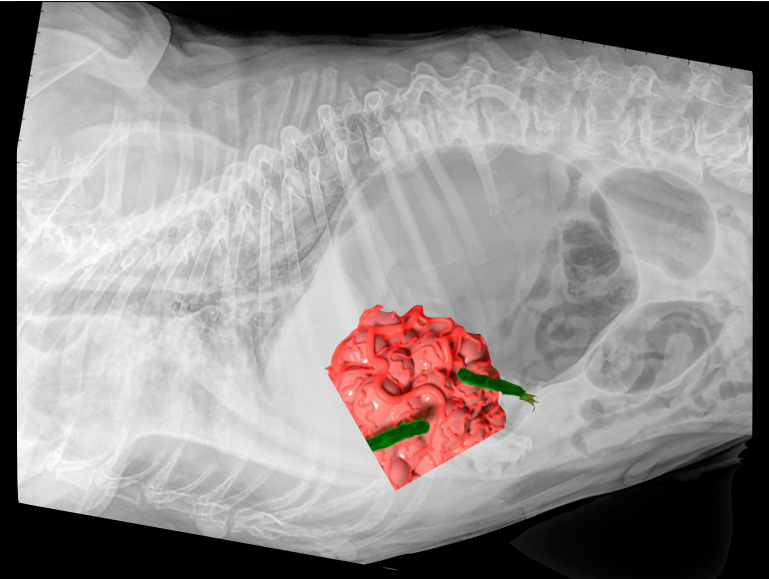



Your evaluation

- Is there pneumonia?
- Is there a gastric FB?
- Is there a gastric mass?

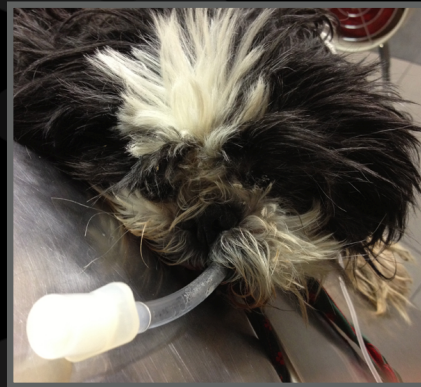

Principessa, FI, 12 years

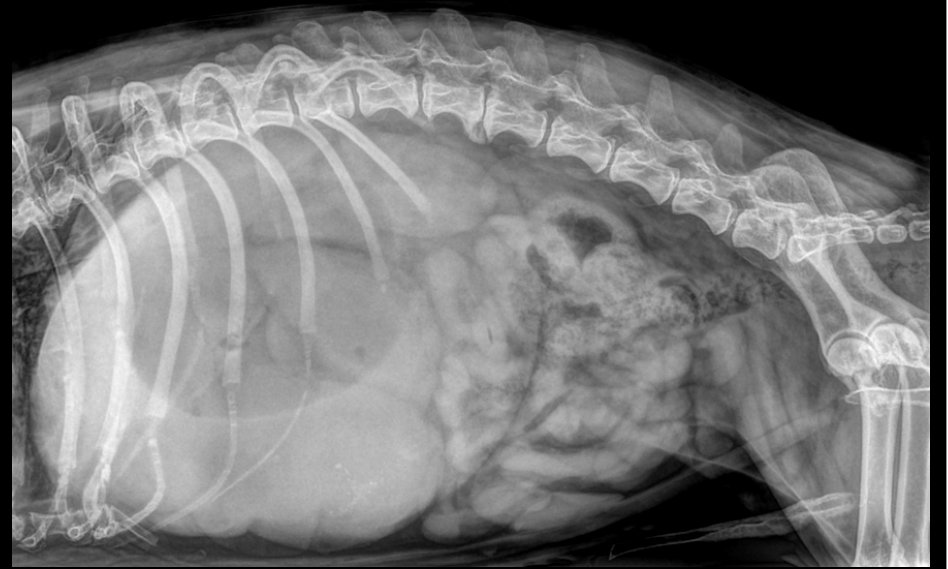


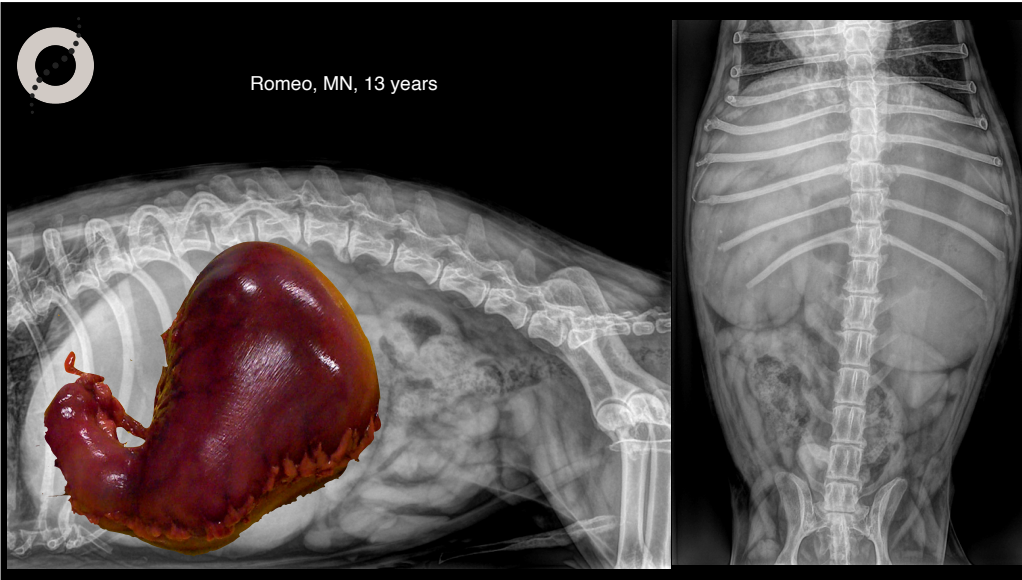
Romeo, Shitzu, MN, 13 years

- Chronically vomiting twice weekly
- Now worsening
- Still eating



Romeo, MN, 13 years





Your evaluation

- Is there gastric dilatation?
- Is there a gastric torsion?
- Is there a gastric FB?

Romeo, MN, 13 years

Probe position in a different patient

7

Romeo, MN, 13 years

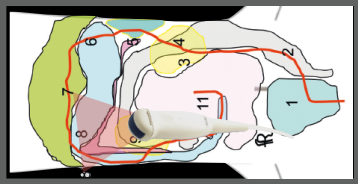
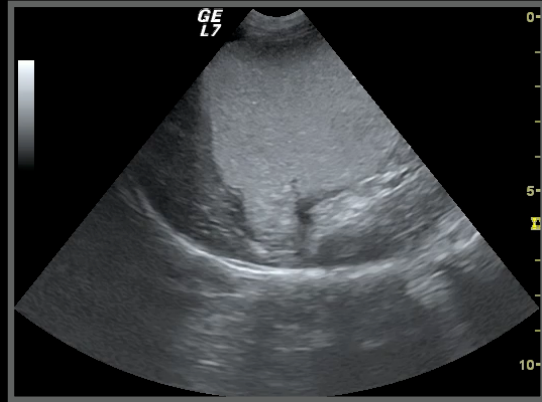
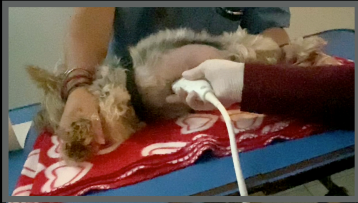Probe position in a different patient

7-8

Romeo, MN, 13 years

Probe position in a different patient

7-8

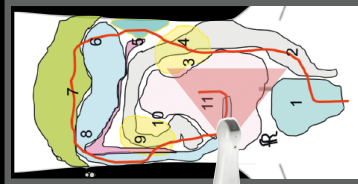
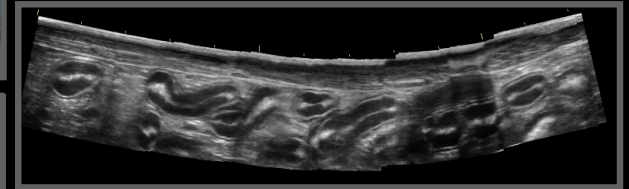
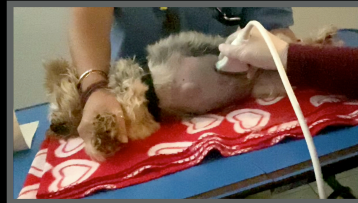

Romeo, MN, 13 years



Probe position in a different patient

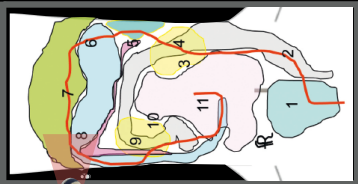
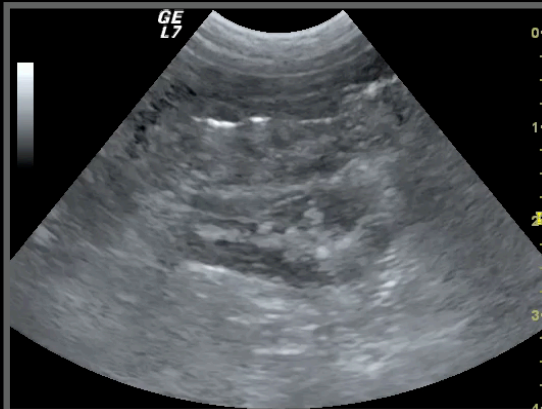
7-11



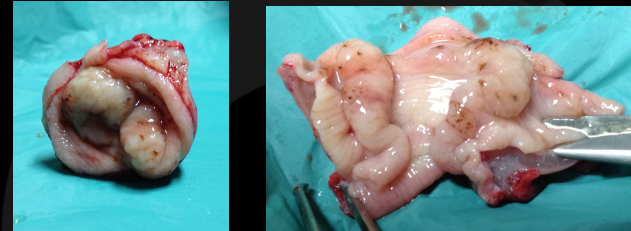Romeo, MN, 13 years

Probe position in a different patient

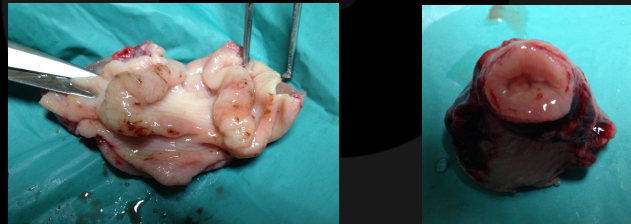8'



Romeo, Shitzu, MN, 13 years

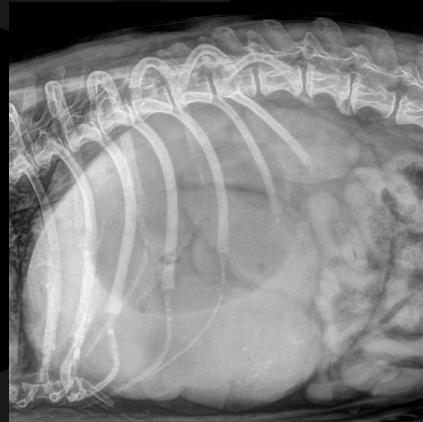

Chronic gastropathy with pyloric obstruction



Key points for chronic pyloric subocclusion

- Enlarged and rounded pyloric antrum
- Fluid more than gas filled
- Gravel sign

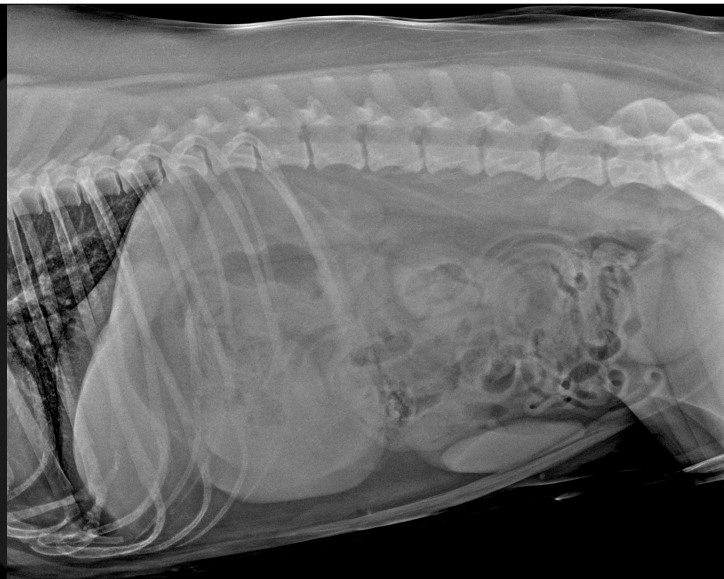


Hermes, Australian Shepherd, MN, 6 years

- Vomiting for three days
- Reduced appetite
- Drinks but then vomits bile

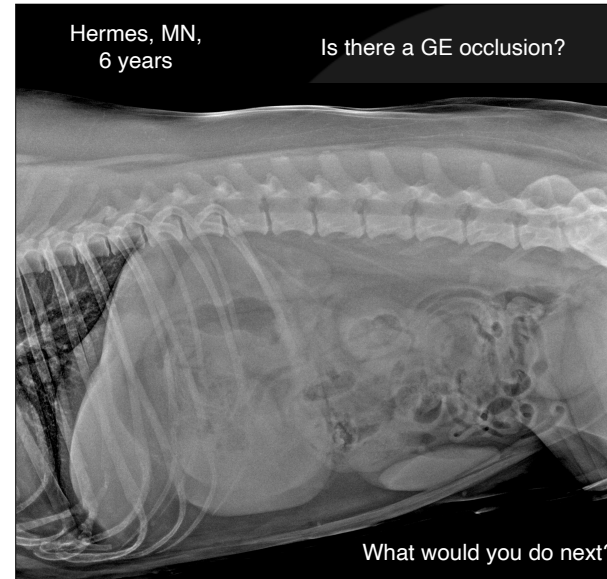


Hermes, MN,
6 years

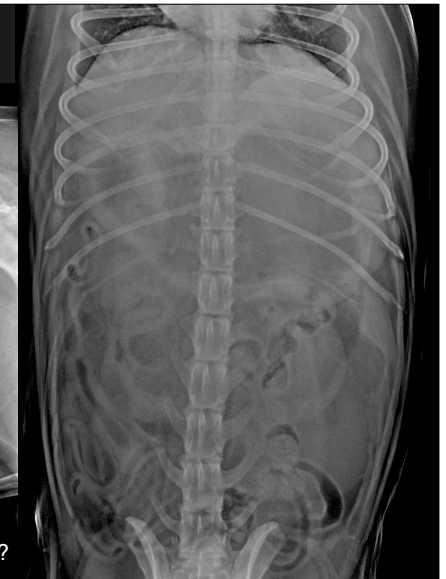

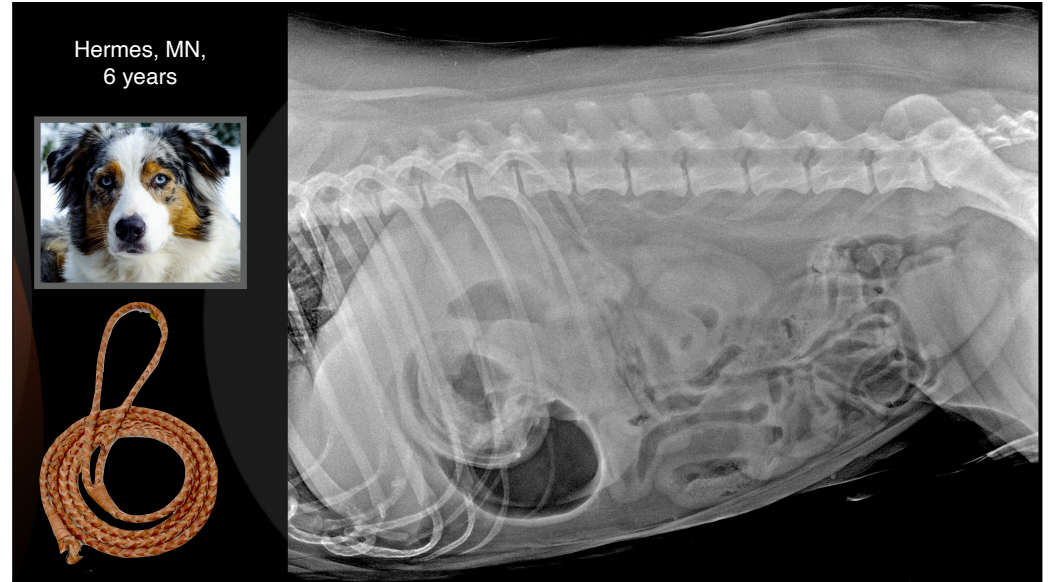
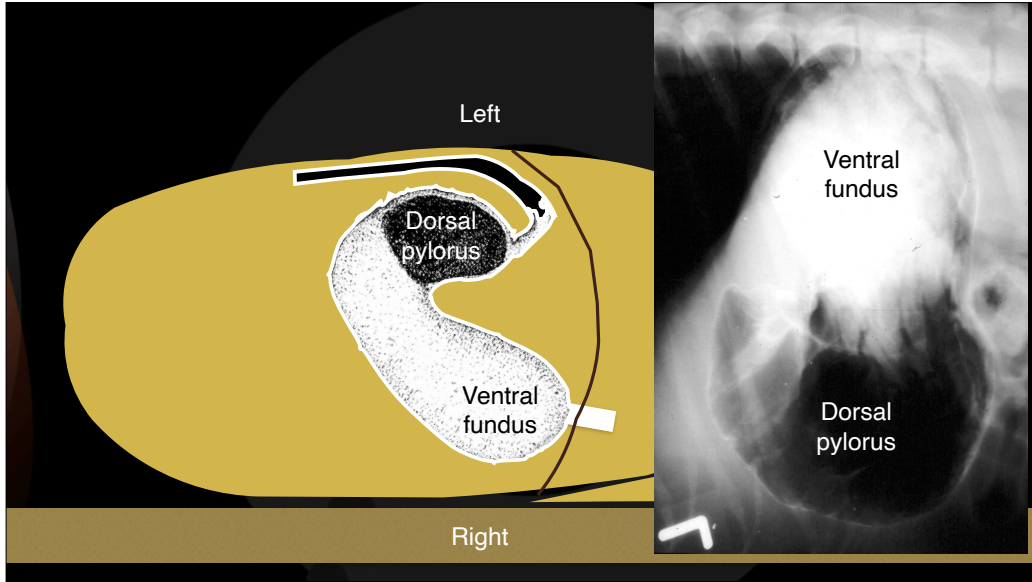
Hermes, MN,
6 years

Is there a GE occlusion?



What would you do next?





Thank you



Diagnostic Mindset

www.diagnosticmindset.com

The slide has an orange background with a white curved shape on the left side. It features the text 'Thank you' at the top, a logo consisting of a white circle with a red dot and a trail of black dots, the text 'Diagnostic Mindset', and the website address 'www.diagnosticmindset.com' at the bottom.