

Occlusione intestinale o ileo paralitico? Quando ho davvero bisogno di una ecografia?



Thanks to Clinica Veterinaria Castellarano

Giliola Spattini  
DVM, PhD, DECVDI

## Objectives

- Radiology play an important role in management of small intestinal occlusion
- Can we increase radiology accuracy in patent management?



## Radiology need to answer to these questions:

Is there an intestinal occlusion?

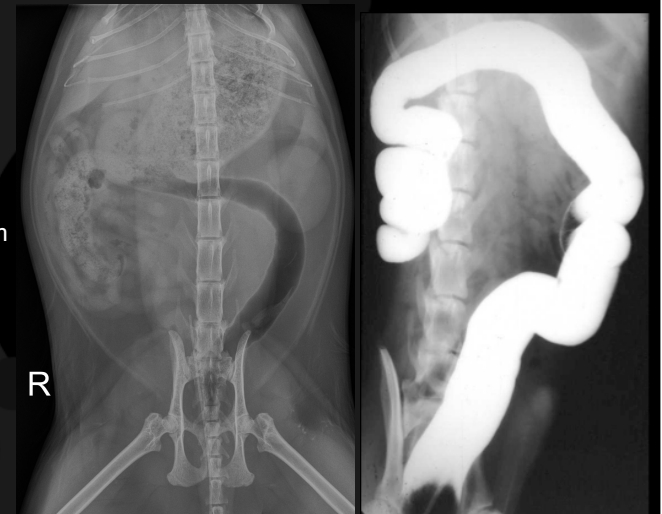Is surgery necessary?

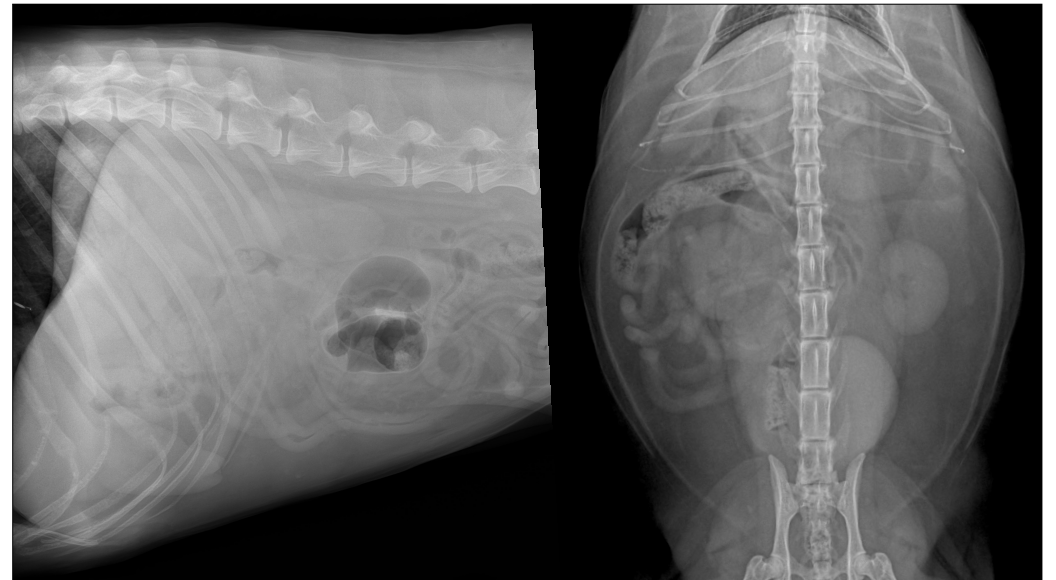
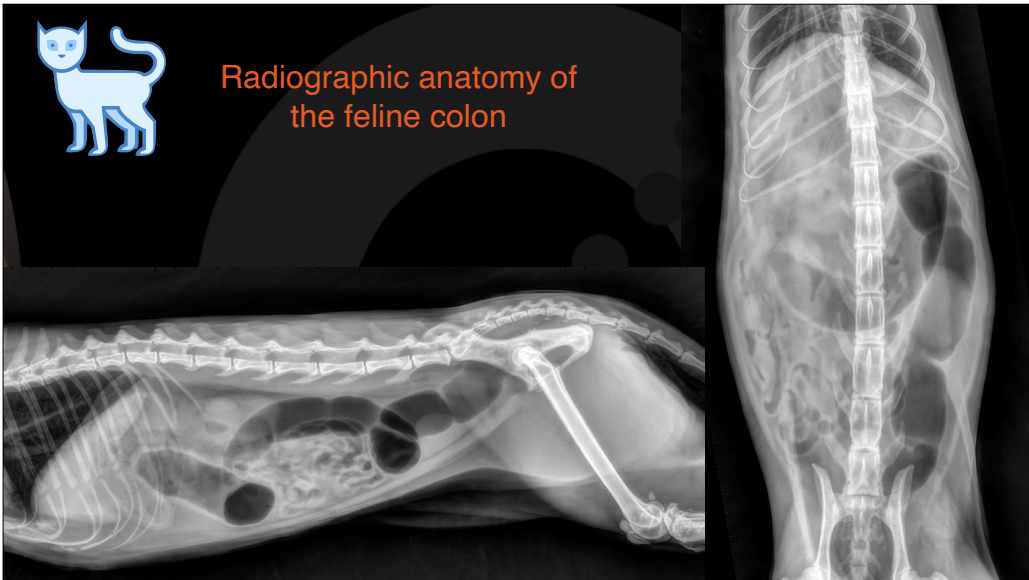
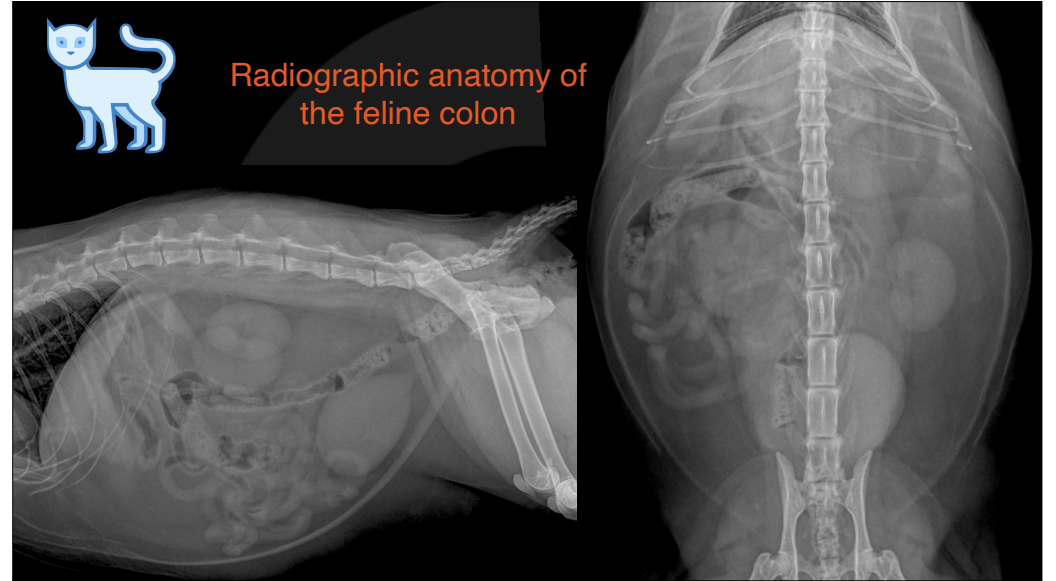
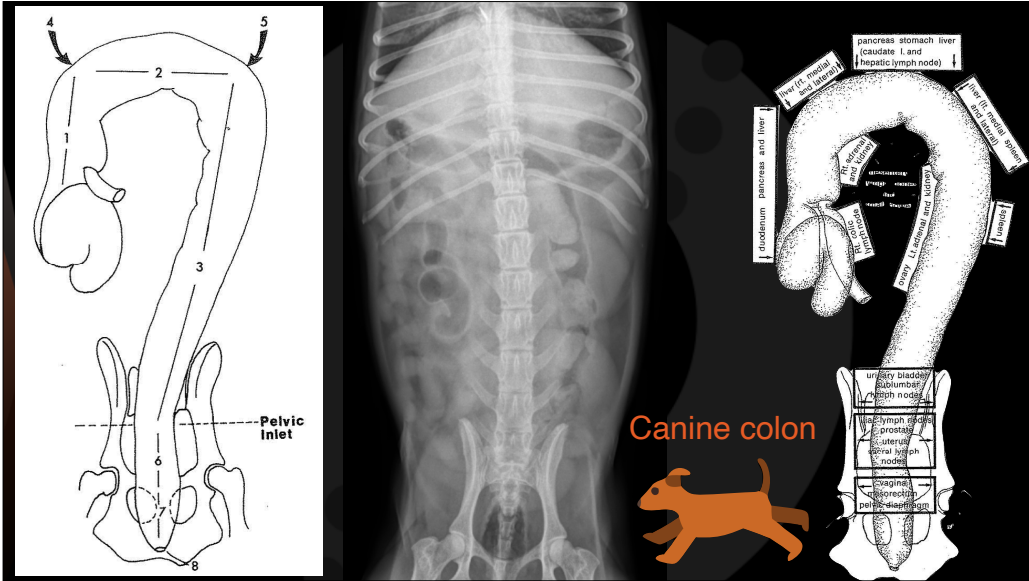
When?

I'm really sure that surgery is not necessary?

## Radiographic strategy to increase the accuracy of SI occlusion:

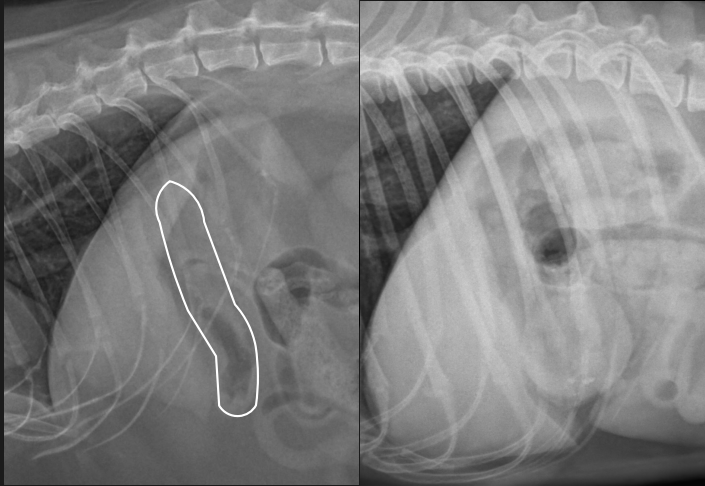
- 1) Find the colon and the cecum






Radiographic strategy to increase the accuracy of SI occlusion:

- 2) Check the stomach



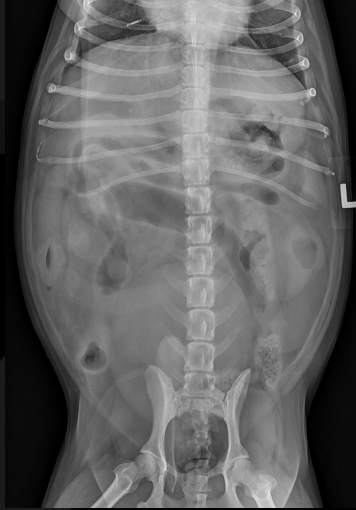Radiographic strategy to increase the accuracy of SI occlusion:

- 3) There is a single small intestinal population?



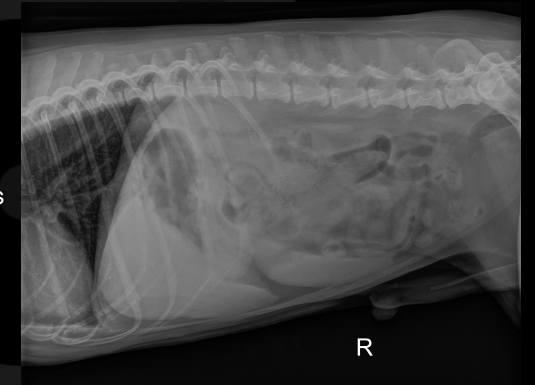
## Radiographic strategy to increase the accuracy of SI occlusion:

- 4) Where is and what type of content?



## Radiographic strategy to increase the accuracy of SI occlusion:

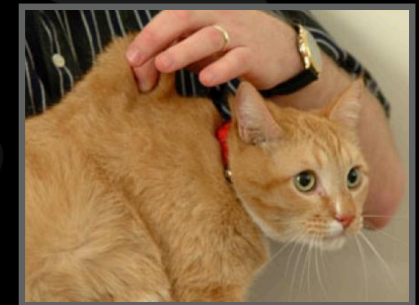- 1) Gastric emptying time 0-2 hours
- 2) Small intestine emptying time 2-8 hours
- 3) Large intestine emptying time 48 hours



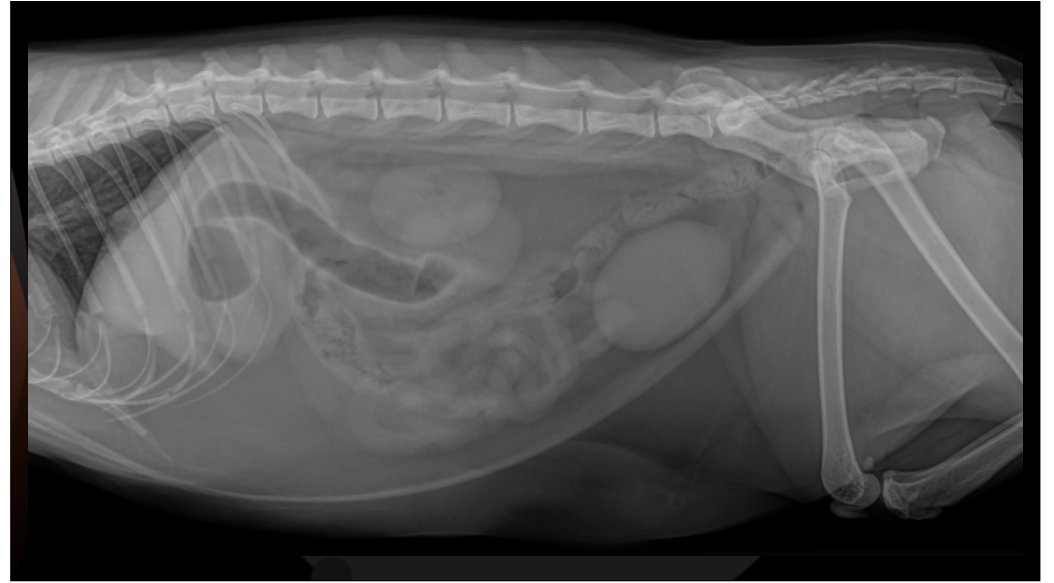
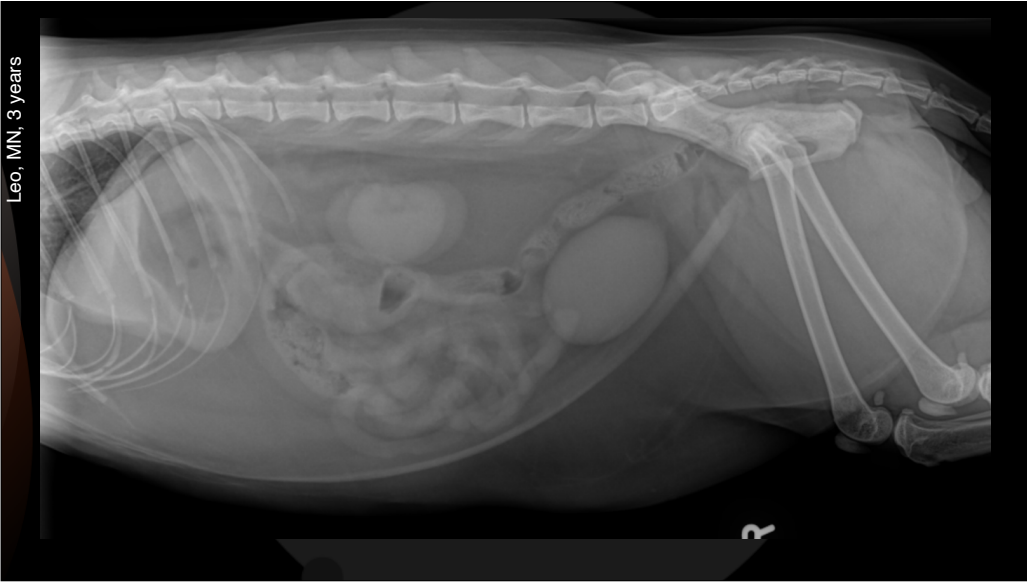
Learning check!

Leo, DSH, MN, 3 years

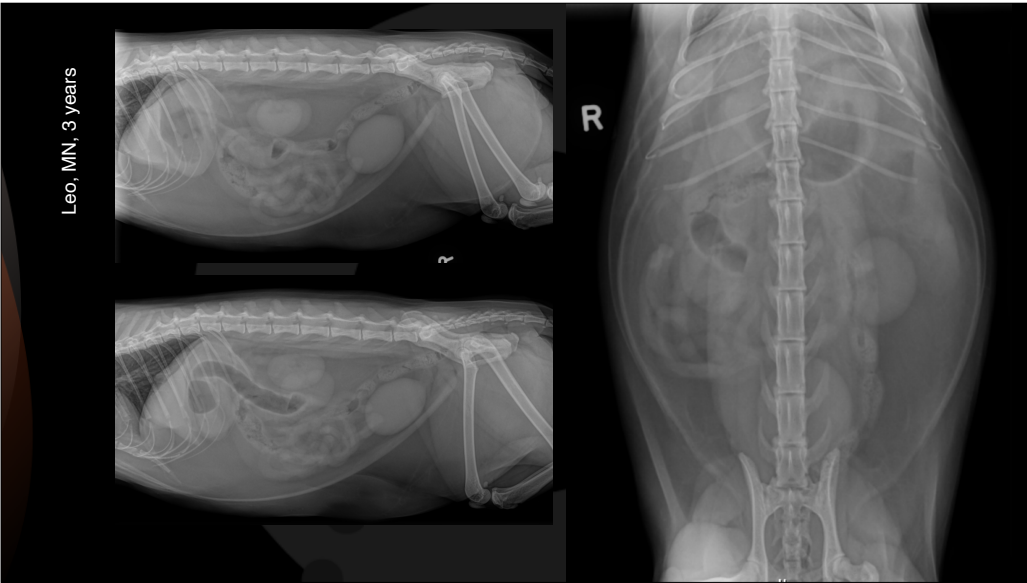
- Not drinking
- Not eating
- Now vomiting
- Dehydrated
- Diarrhea



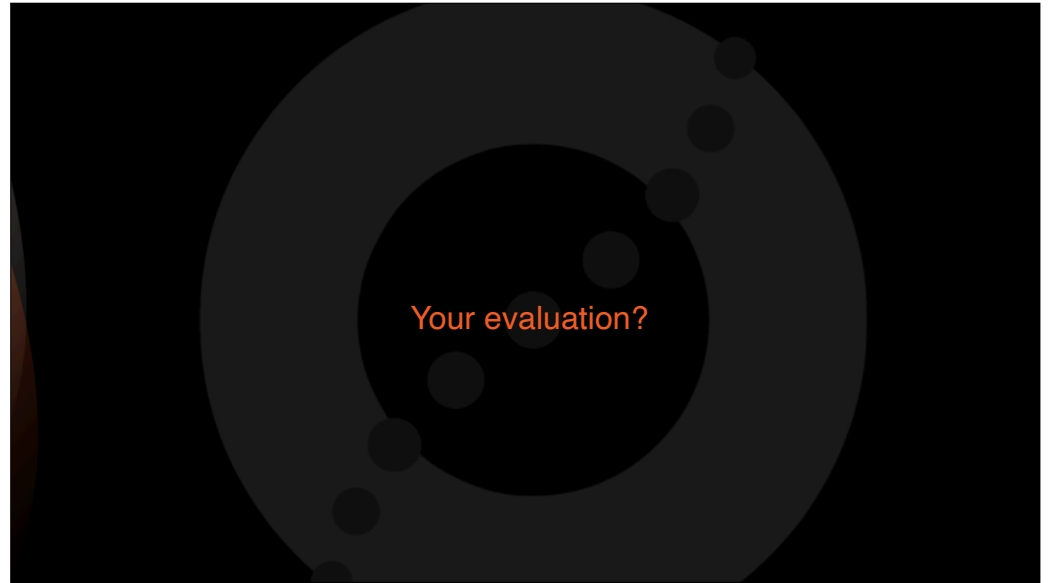
Leo, MN, 3 years



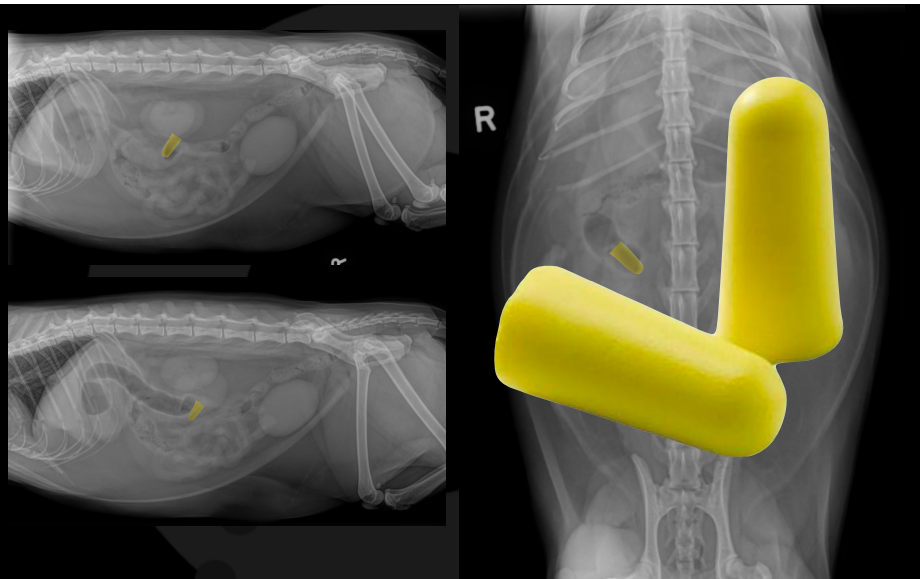
Leo, MN, 3 years



Your evaluation?

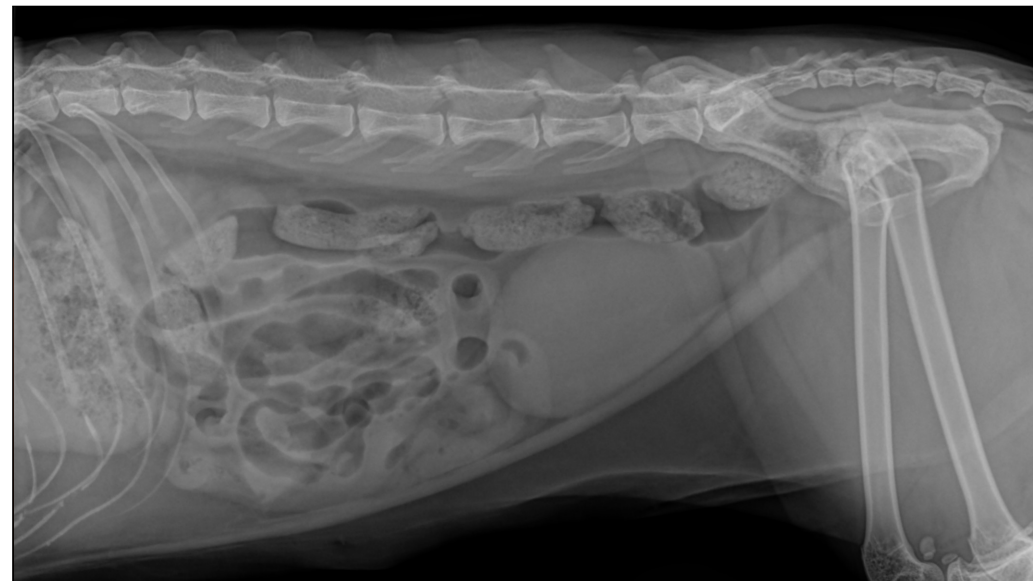
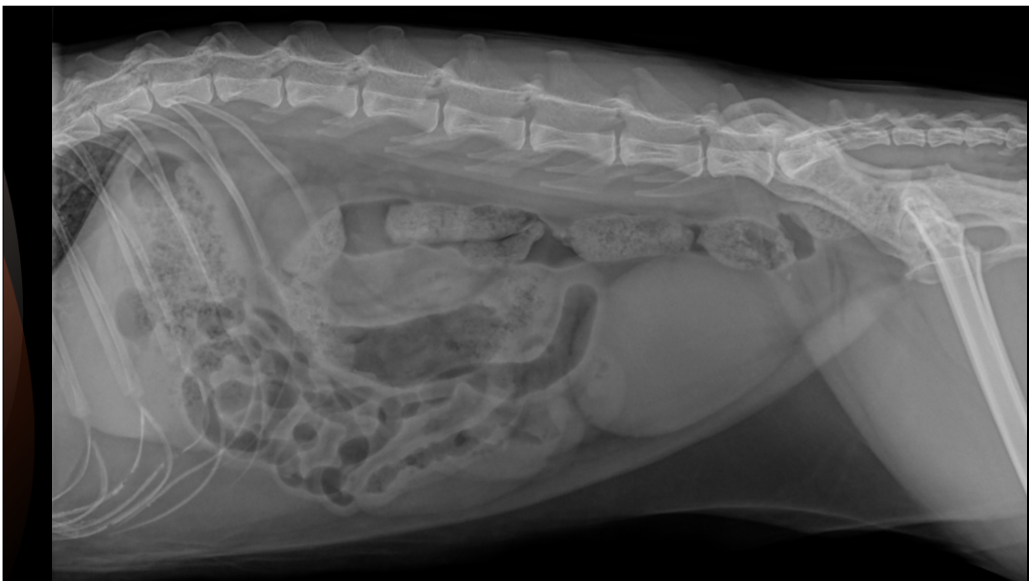

Leo, MN, 3 years

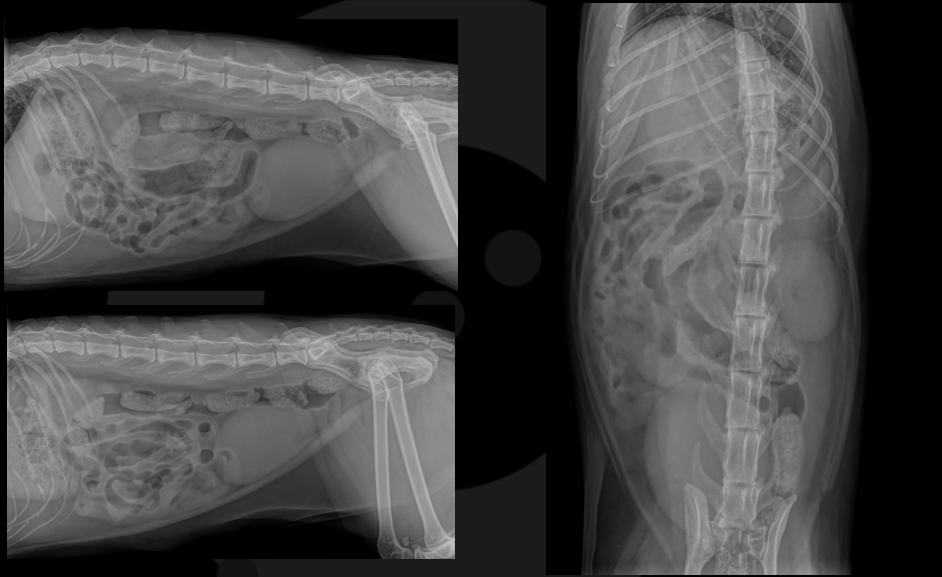


Pauly, DSH, MN, 7 years

- Still eating but vomiting
- Lethargic
- Occasionally coughs and regurgitates clear fluid
- He ate well two days ago



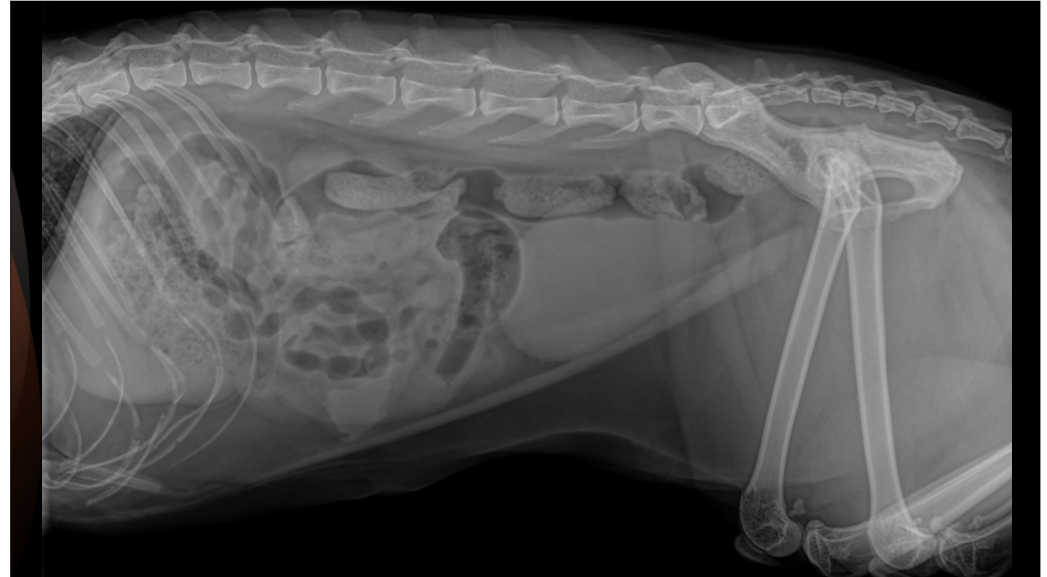
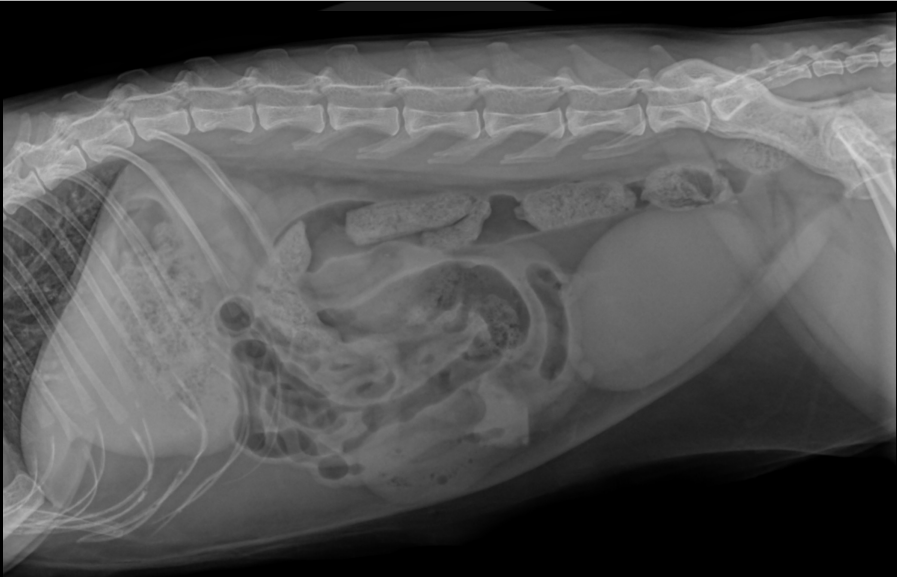Pauly, MN, 7 years



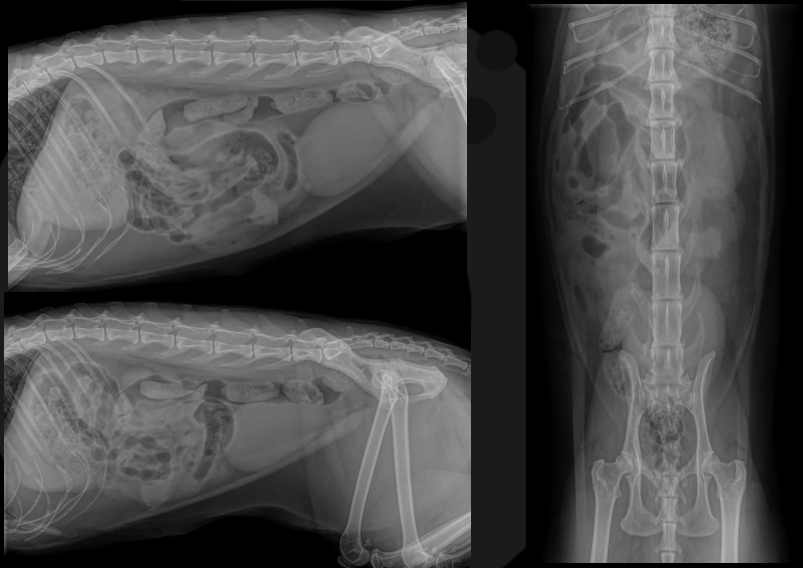

Pauly, DSH, MN, 7 years

12 hours later

- Still vomiting
- Lethargic
- Not eating
- Dehydrated

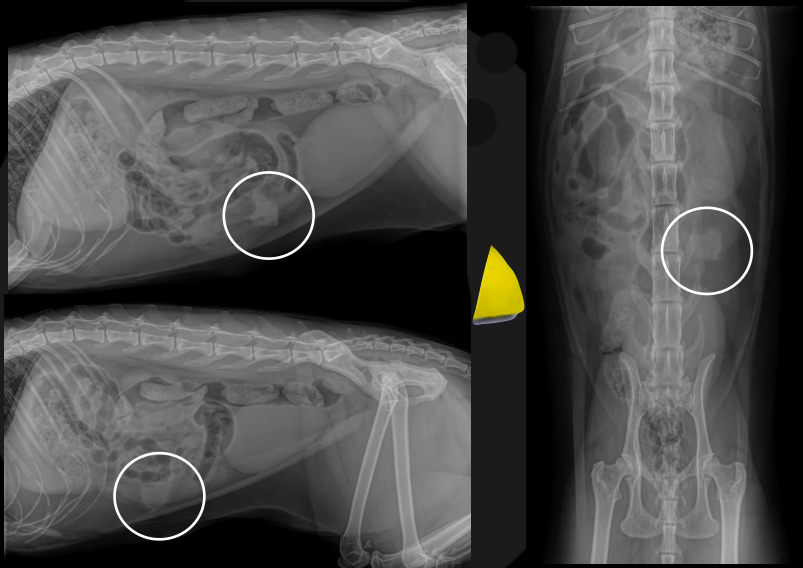



Pauly, MN,  
7 years



Your evaluation?

Pauly, MN,  
7 years

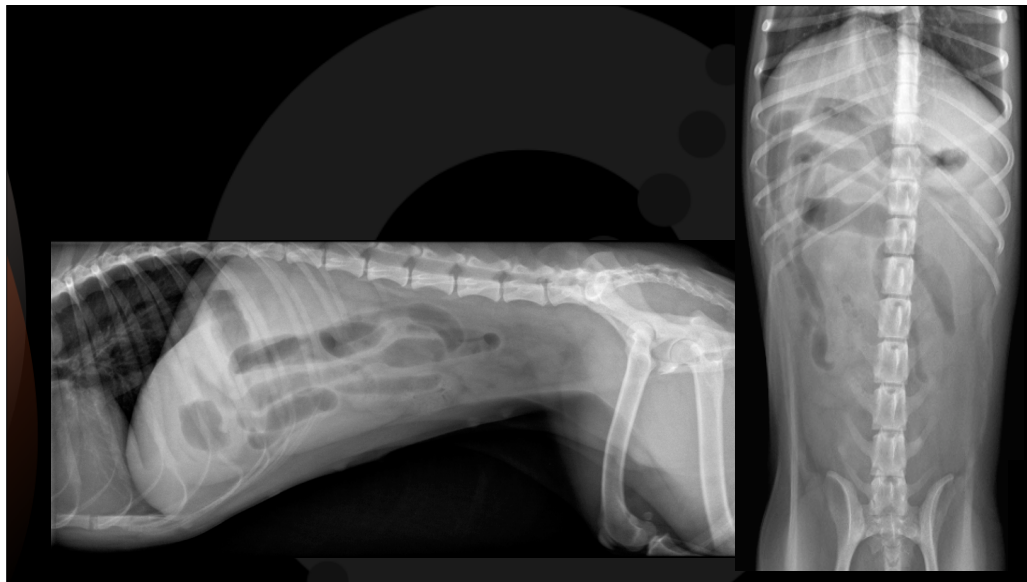
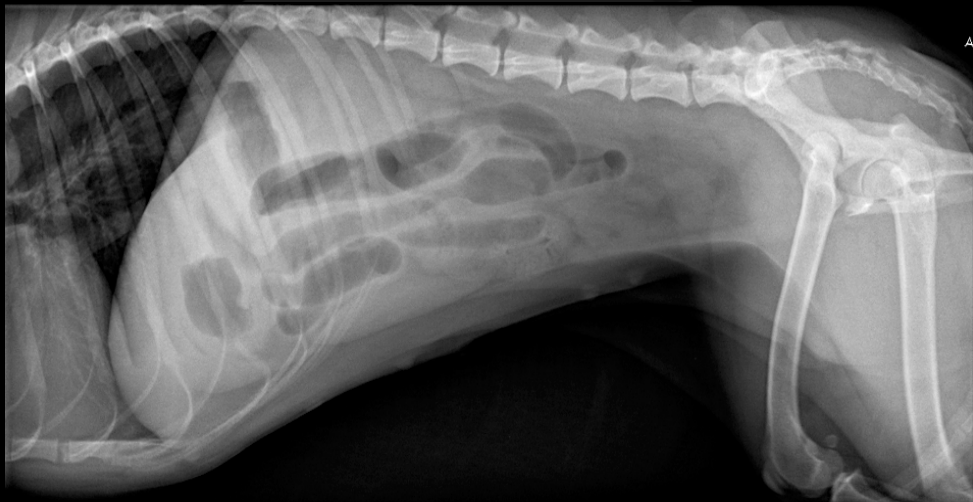

Peppi, Mongrel, FI, 4 years

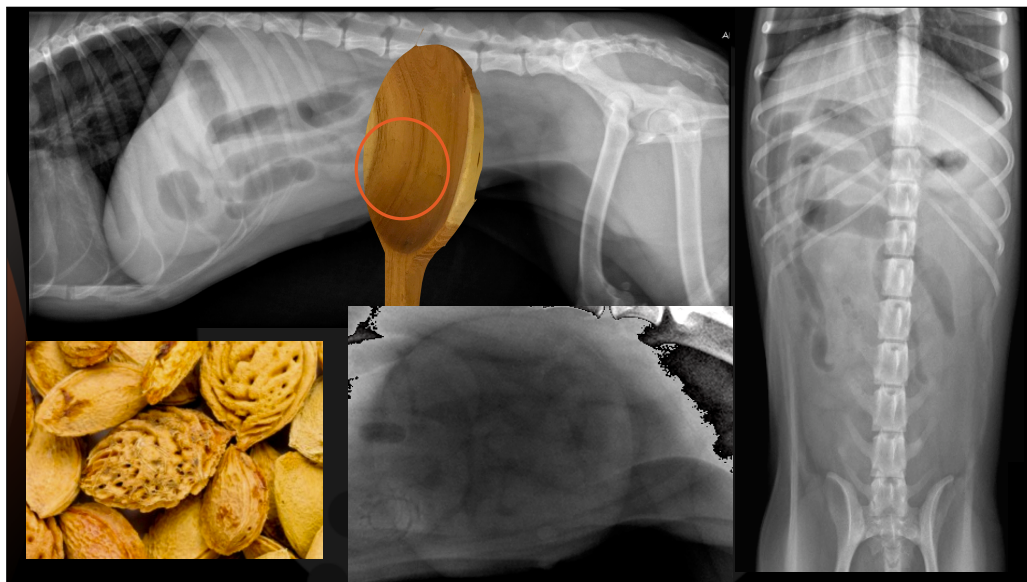
- Not eating
- Palpated an abdominal FB



Peppy, FI, 4 years



Your evaluation?

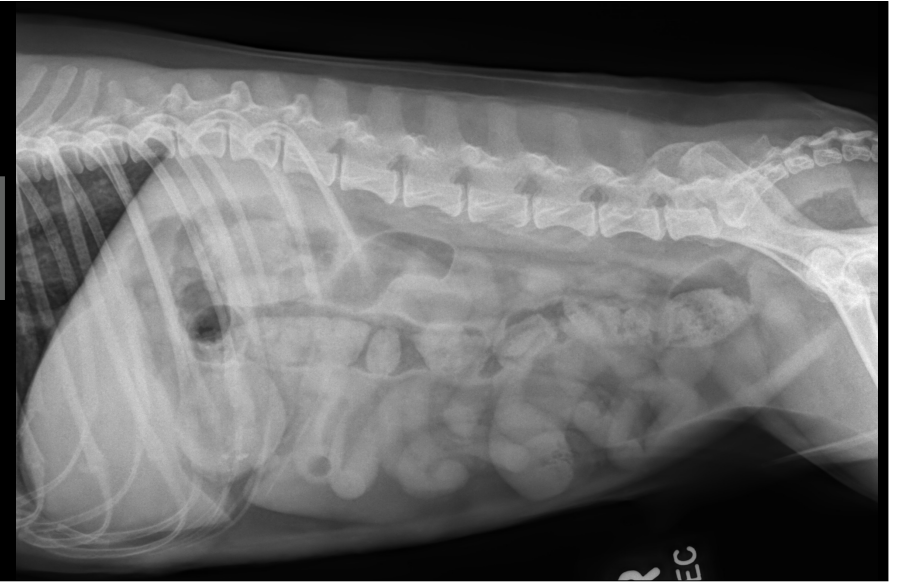


Erik, Jack Russel, MI, 3 years

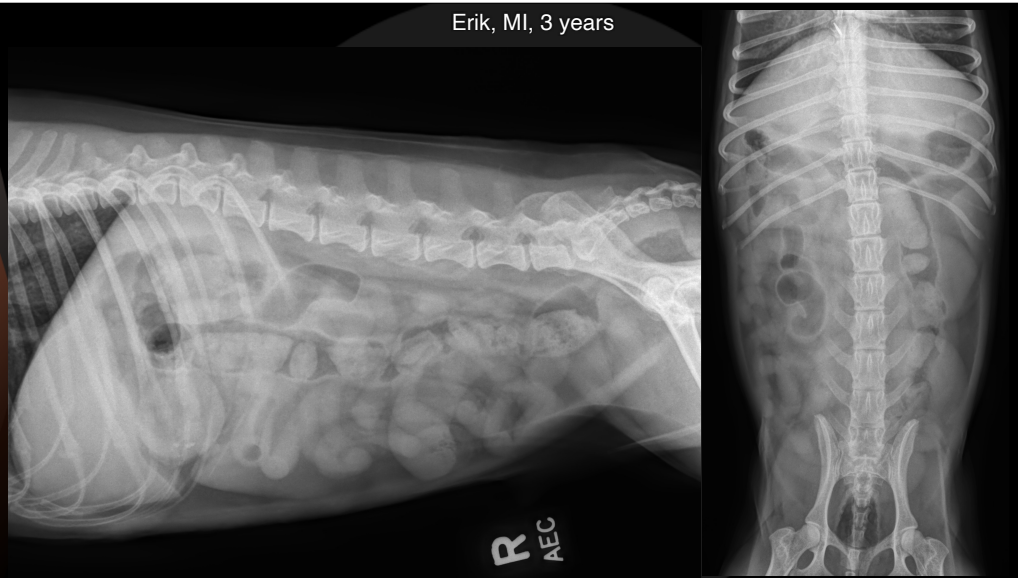- Not jumping
- Not eating
- No abdominal pain



Erik, MI,  
3 years

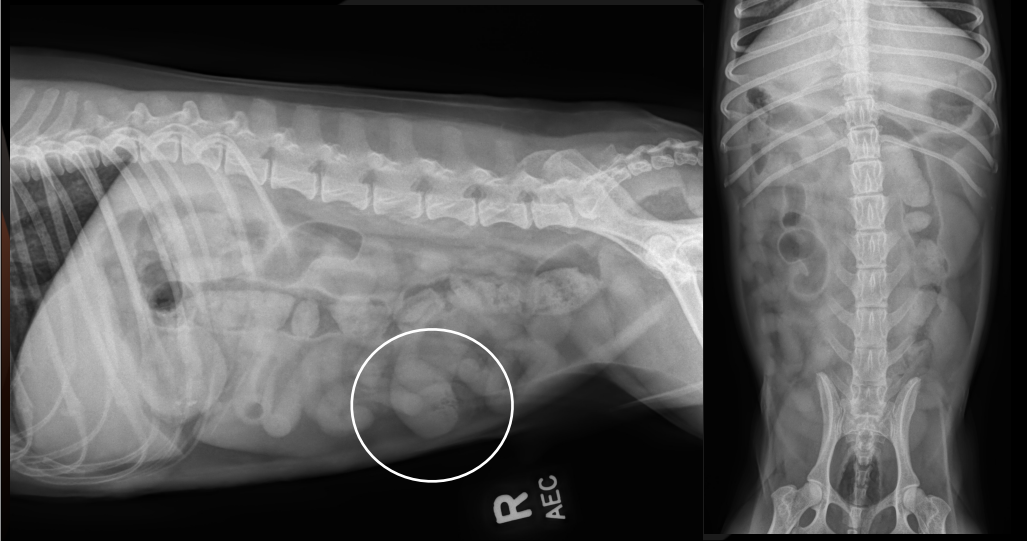


Erik, MI, 3 years



Your evaluation?

Erik, MI, 3 years



Tigro, DSH, MN, 6 years

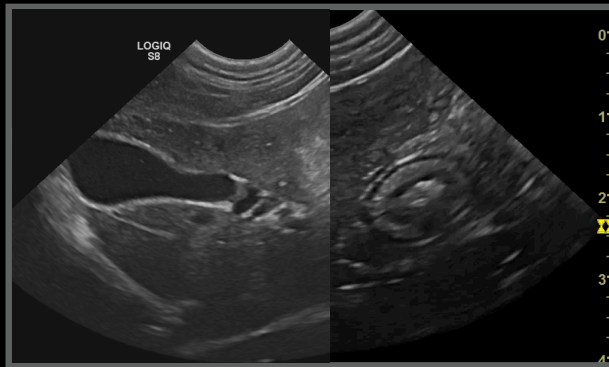
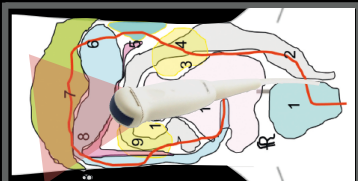
- Chronic vomiting
- Very aggressive patient
- Sedation is planned



Tigro, MN, 6 years

Probe position in a different patient

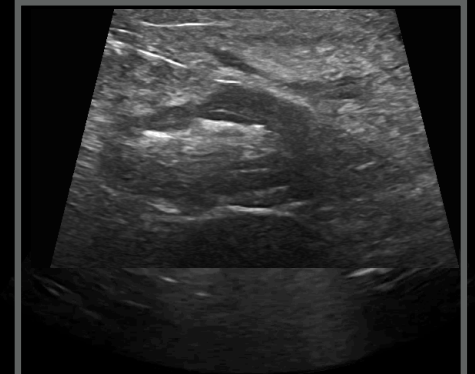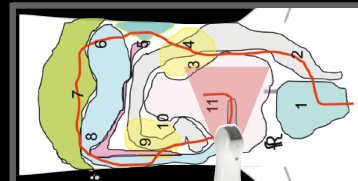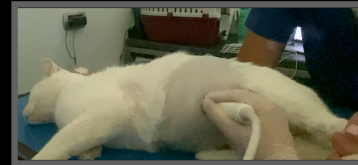
7-8



Tigro, MN, 6 years

Probe position in a different patient

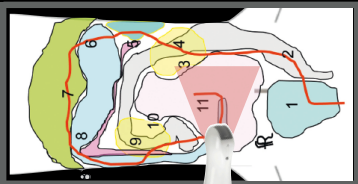
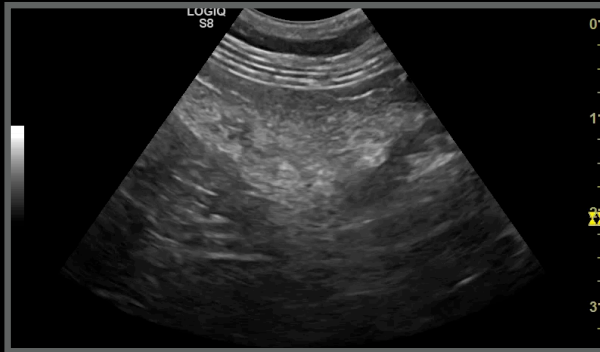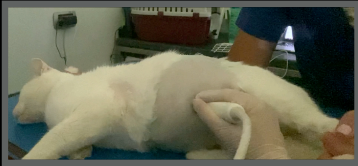
11



Tigro, MN, 6 years

Probe position in a different patient

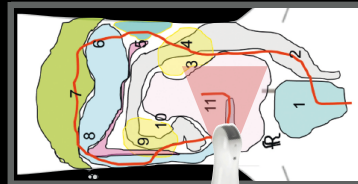
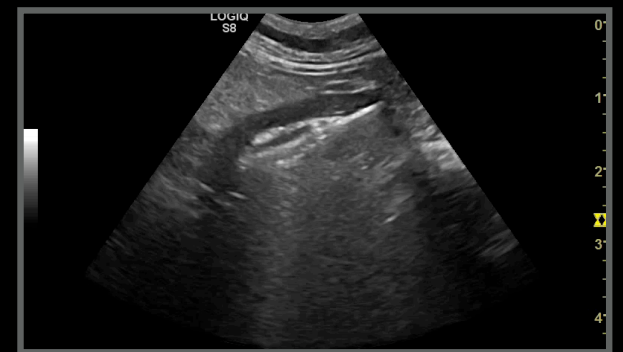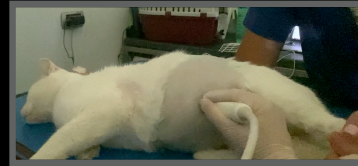
11



Tigro, MN, 6 years

Probe position in a different patient

11

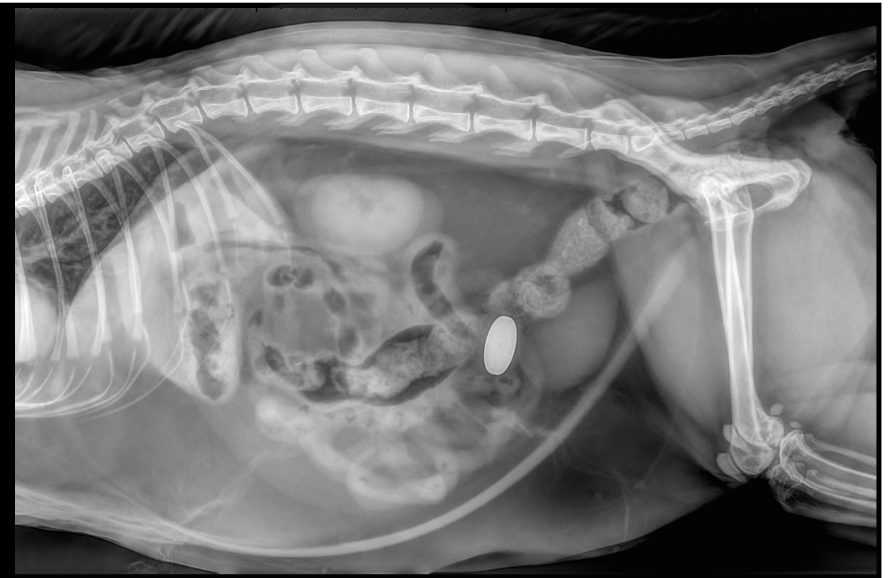


Your evaluation

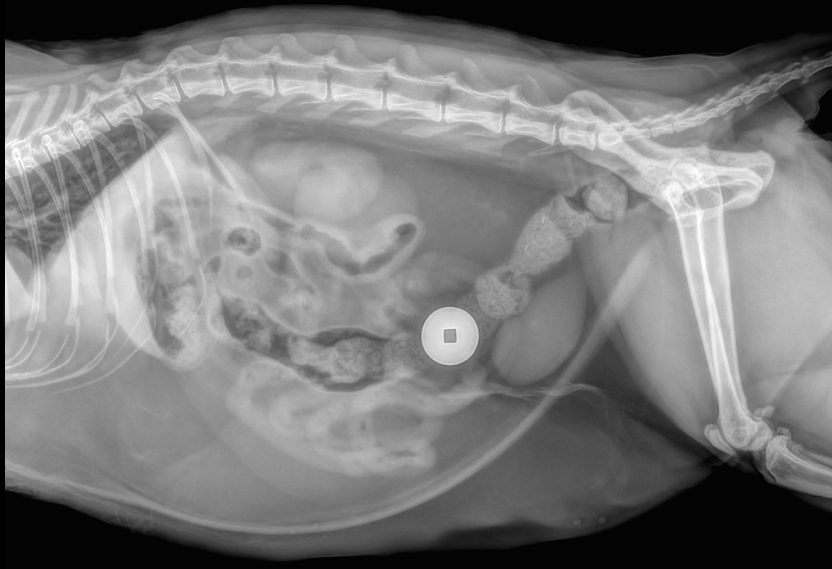
- Is there a focal peritonitis?
- Is there hepatitis?
- Is there a FB?




Tigro, MN,  
6 years



Tigro, MN,  
6 years



Tigro, MN, 6 years



Fiamma, Boxer, FS, 6 years

- Lethargic and anorexic since yesterday
- Six months ago amputated left front limb for osteosarcoma
- Three weeks before negative radiographic and ultrasonographic staging



Fiamma, Boxer, FS, 6 years

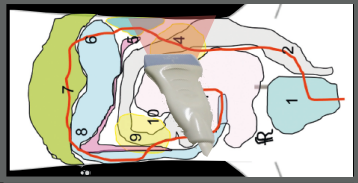
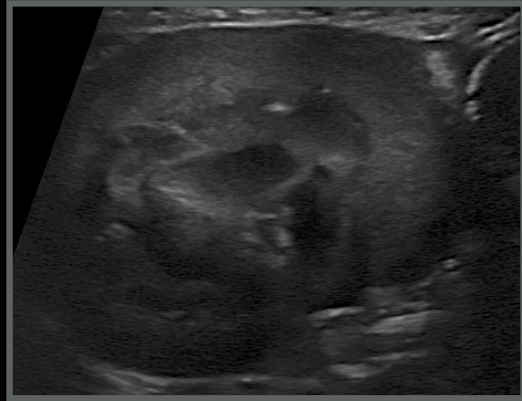
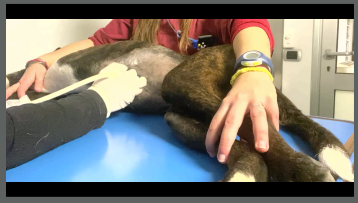- Responding well to chemotherapy
- Experimental vaccination for osteosarcoma
- Pink mucous membrane
- Abdominal pain
- Dark faeces and coca-cola like urine





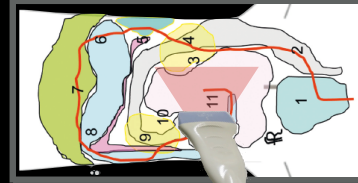
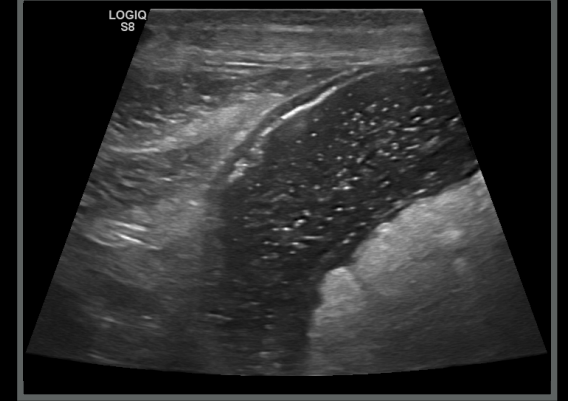
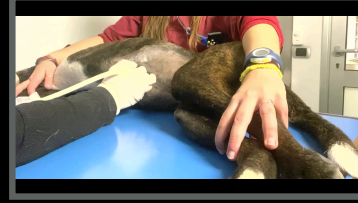Fiamma, FS, 6 years

4



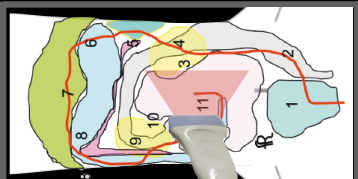
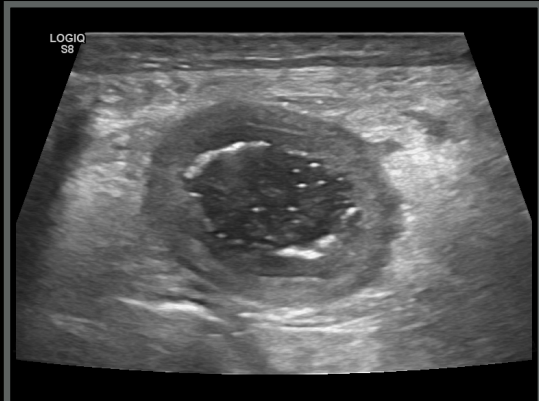
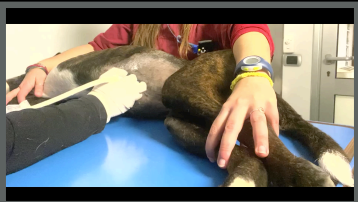Fiamma, FS, 6 years

11



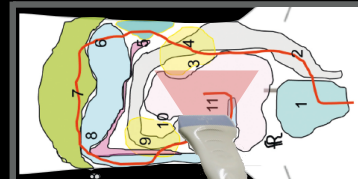
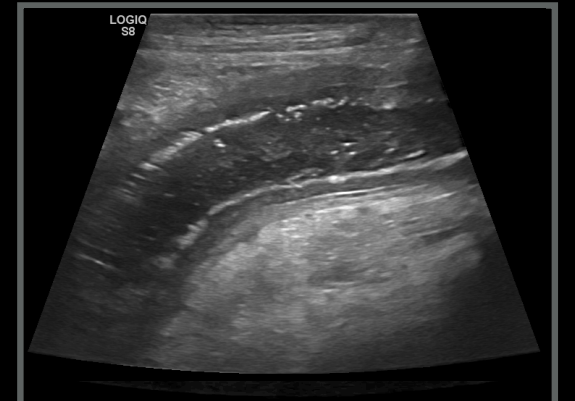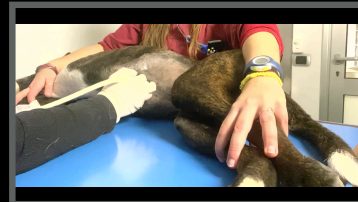Fiamma, FS, 6 years

11



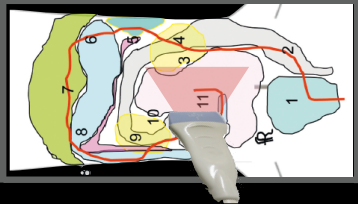
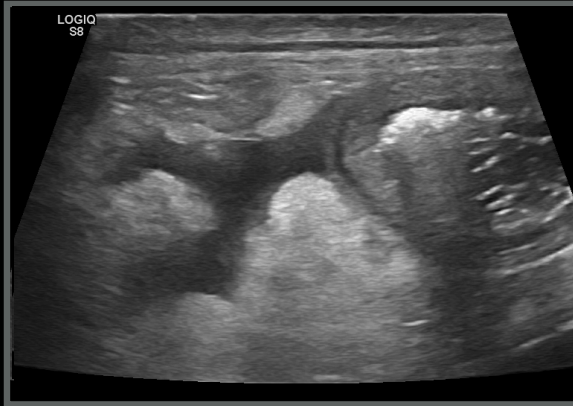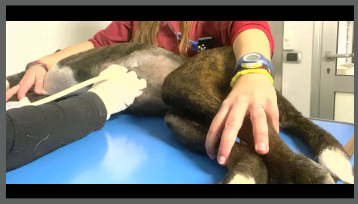Fiamma, FS, 6 years

11



Fiamma, FS, 6 years

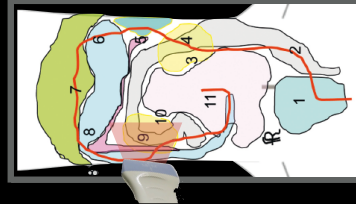
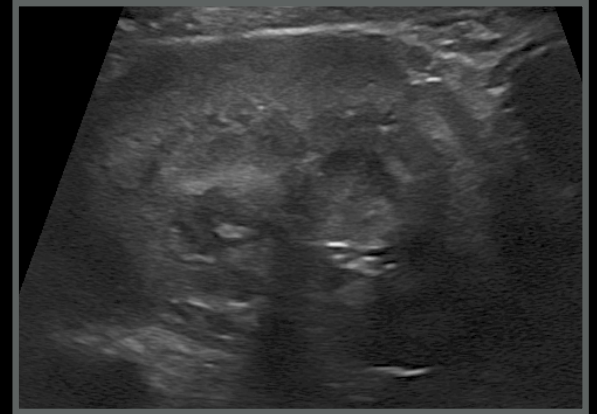

11



Fiamma, FS, 6 years

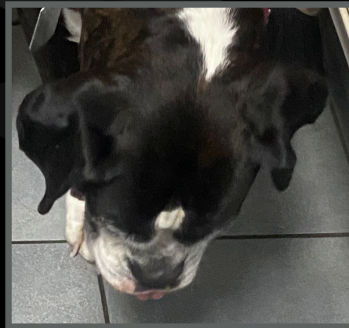9

Probe position in a different patient

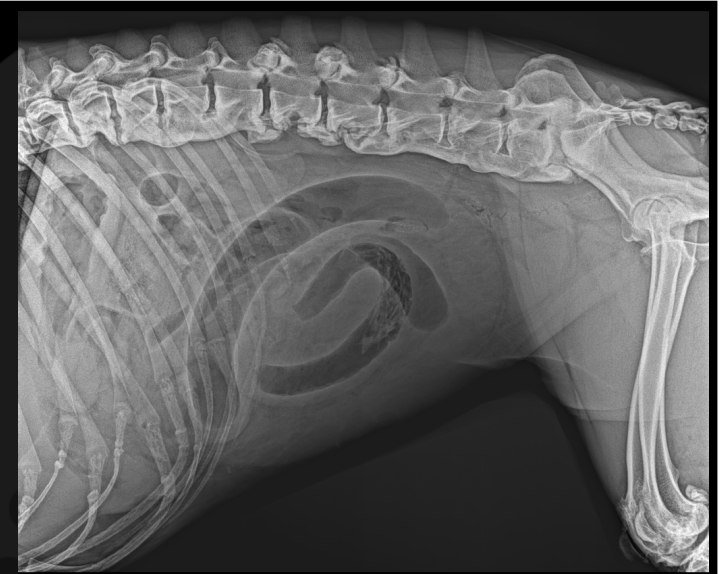



### Your evaluation

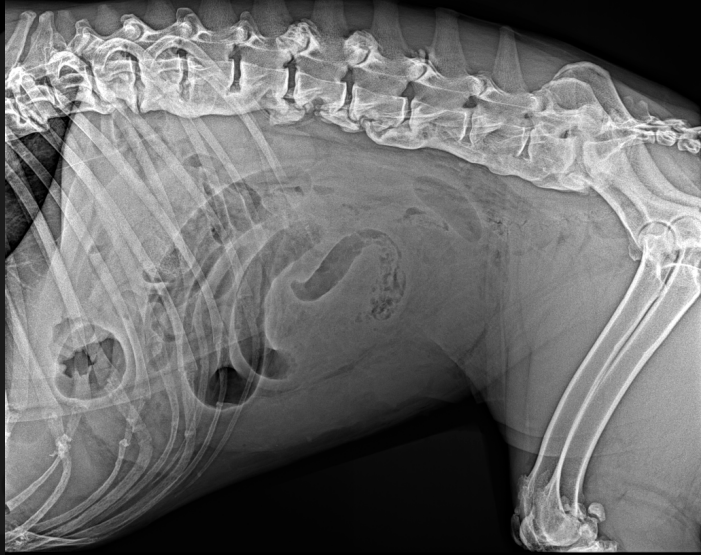
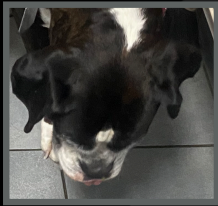- Are there metastasis?
- Is there a splenic mass?
- Is there a gastroenteritis?



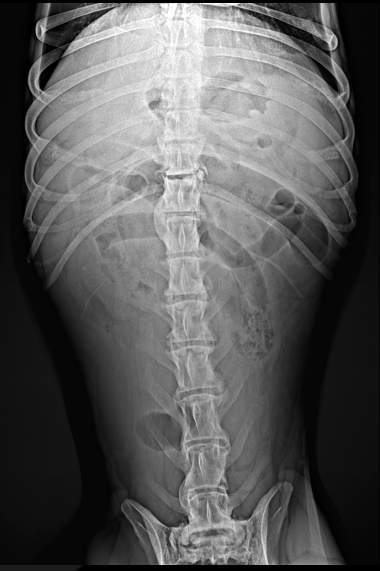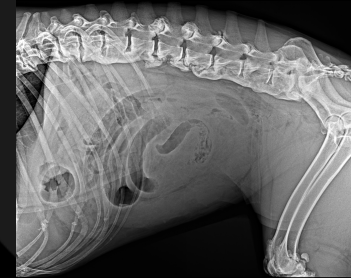
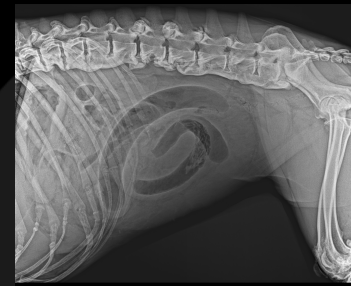
Fiamma, FS, 6 years



Fiamma, FS, 6 years



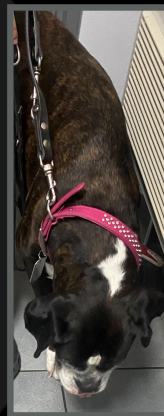Fiamma, FS, 6 years



Fiamma, Boxer, FS, 6 years

Radiographic diagnoses:

- Whirlpool sign
- Sentinel loops



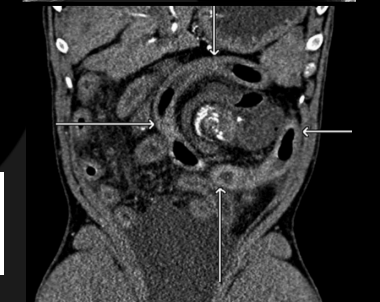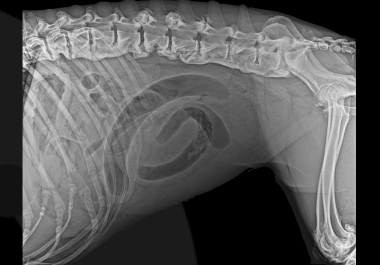
Mesenteric torsion

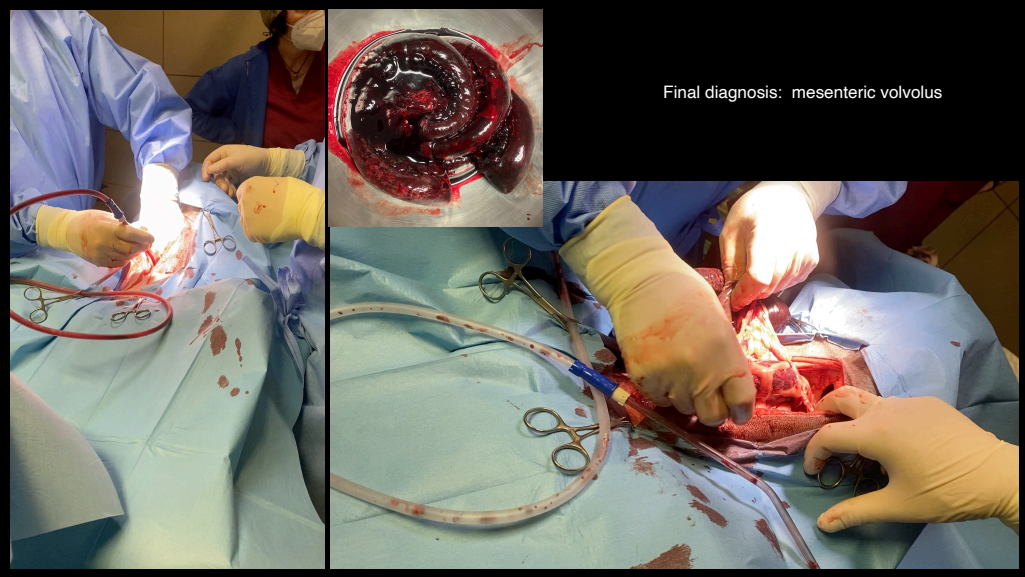
- Whirl sign
- Two populations of loops
- Lack of peristalsis-necrosis
- Some empty loops

IMAGING DIAGNOSIS—USE OF MULTIPHASIC CONTRAST-ENHANCED COMPUTED TOMOGRAPHY FOR DIAGNOSIS OF MESENTERIC VOLVULUS IN A DOG

KATHLEEN ELLA CHOW, ANDREW WILLIAM STENT, MARJORIE MILNE

*Vet Radiol Ultrasound*, Vol. 55, No. 1, 2014, pp 74–78.







### Lucky, German Shepherd, MI, 7 years

- Chronic enteropathy
- Anorexic for the last three days
- Anorexic



This block features a black background with a large, semi-transparent grey circle. The title 'Lucky, German Shepherd, MI, 7 years' is written in orange text at the top. Below the title is a bulleted list of clinical signs in white text. On the right side, there is a cutout image of a German Shepherd dog's head with its tongue hanging out.

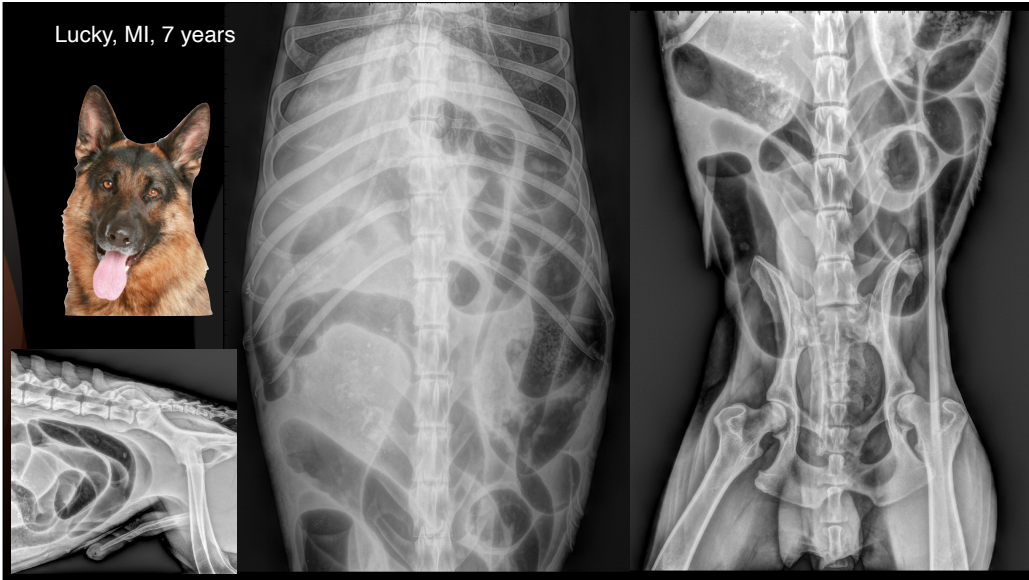
### Lucky, MI, 7 years



This block has a black background with a large, semi-transparent grey circle. The title 'Lucky, MI, 7 years' is written in white text at the top left. Below the title is a cutout image of a German Shepherd dog's head with its tongue hanging out. To the right of the dog image is a lateral chest X-ray showing the ribcage and internal organs.



This block shows a lateral chest X-ray of a dog, similar to the one in the previous block, but without the dog's head image. The X-ray clearly shows the skeletal structure of the chest and the internal organs, including the lungs and stomach.



Your evaluation

- Is there a functional ileum?
- Is there a SI occlusion?
- Is there a severe gastroenteritis?

Lucky, MI, 7 years

Probe position in a different patient

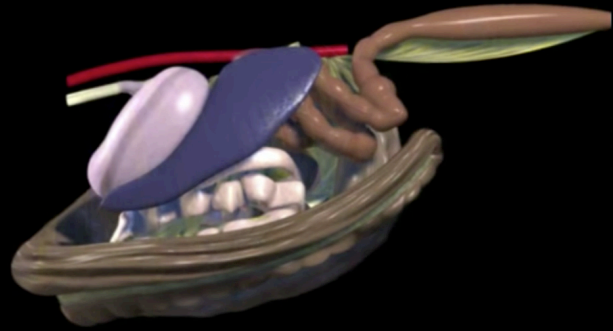
7

Lucky, MI, 7 years

Probe position in a different patient


7-11

Colonic torsion in the horse

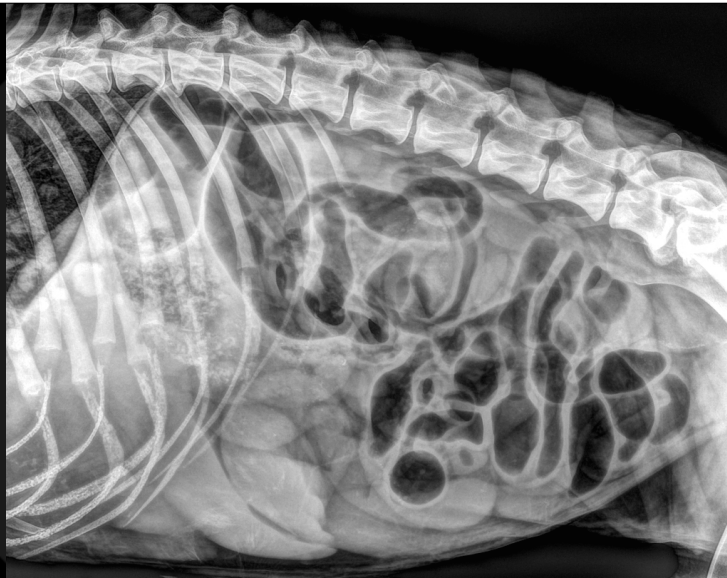



Dylan, Rottweiler, MN, 9 years

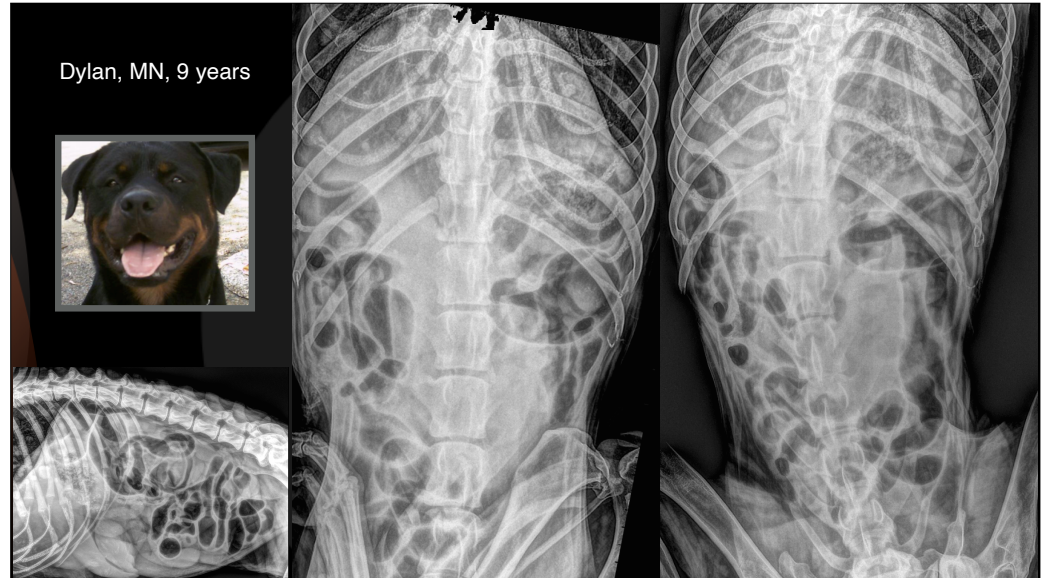
- Vomiting
- Polypnea



Dylan, MN, 9 years




Dylan, MN, 9 years

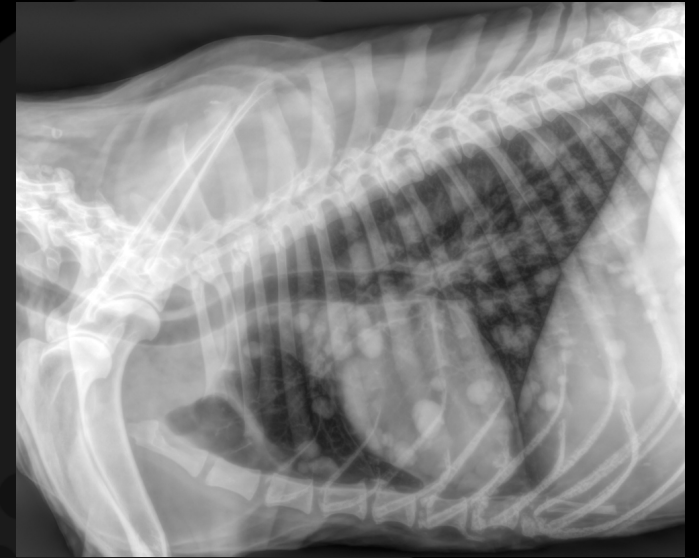



## Your evaluation

- Is there a functional ileum?
- Is there a SI occlusion?
- Is there a severe gastroenteritis?



Dylan, MN, 9 years

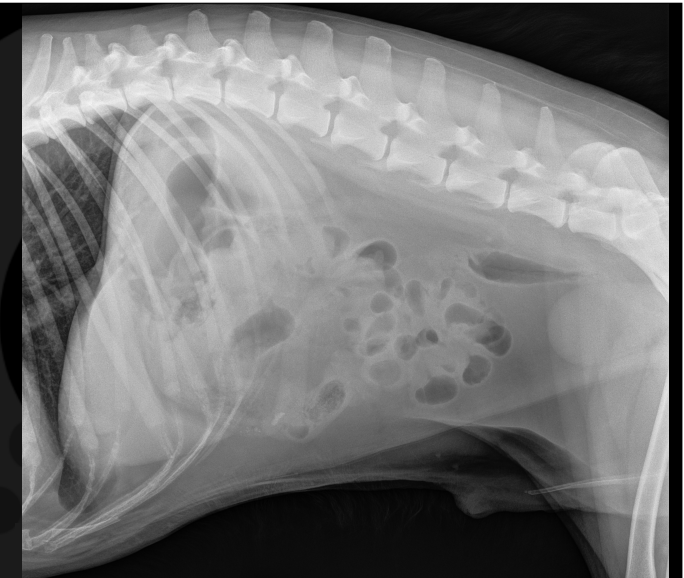

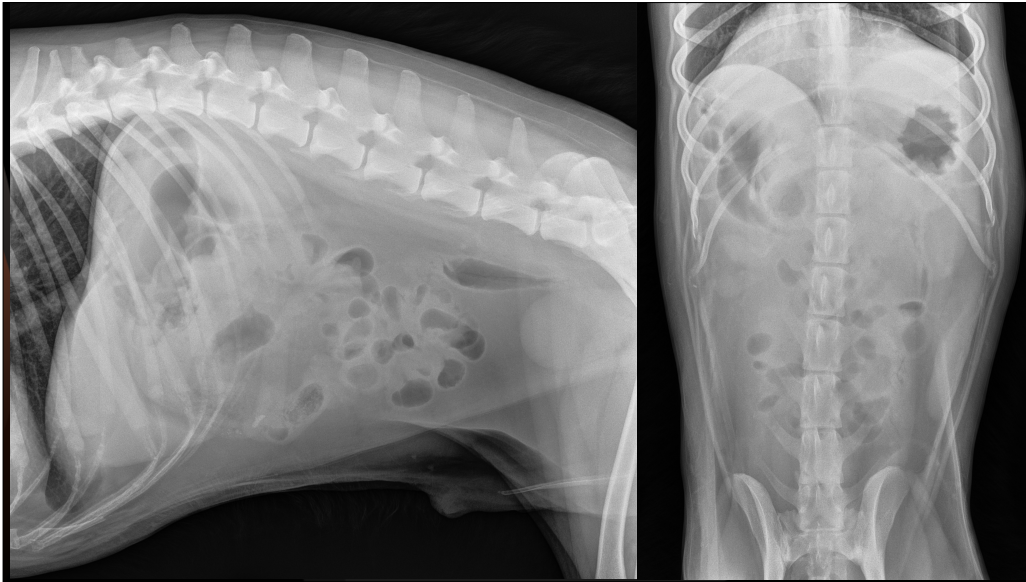
Baker, Mongrel, MN, 7 years

- Acute vomiting
- Tense abdomen



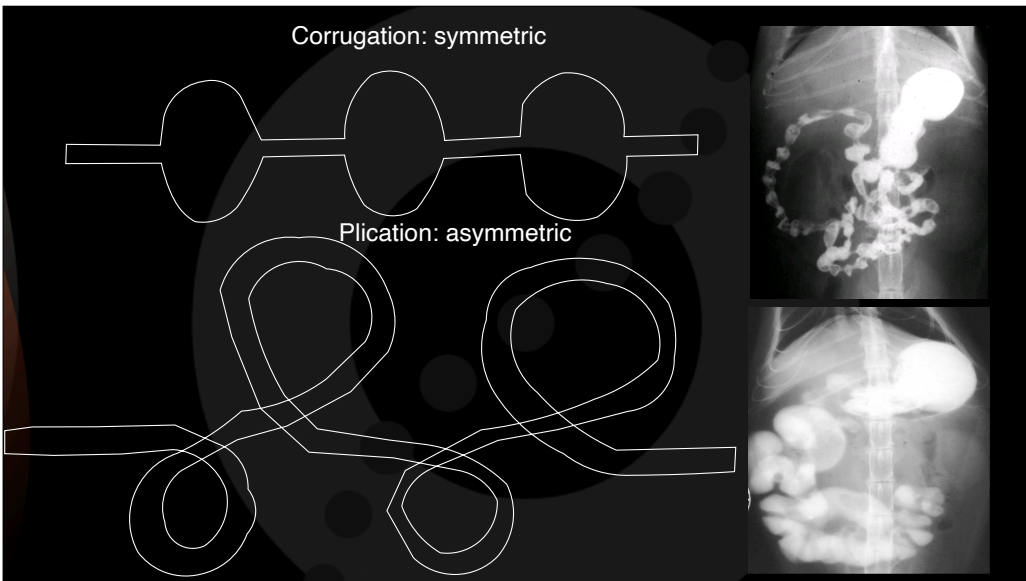

Baker, MN, 7 years






### Your evaluation

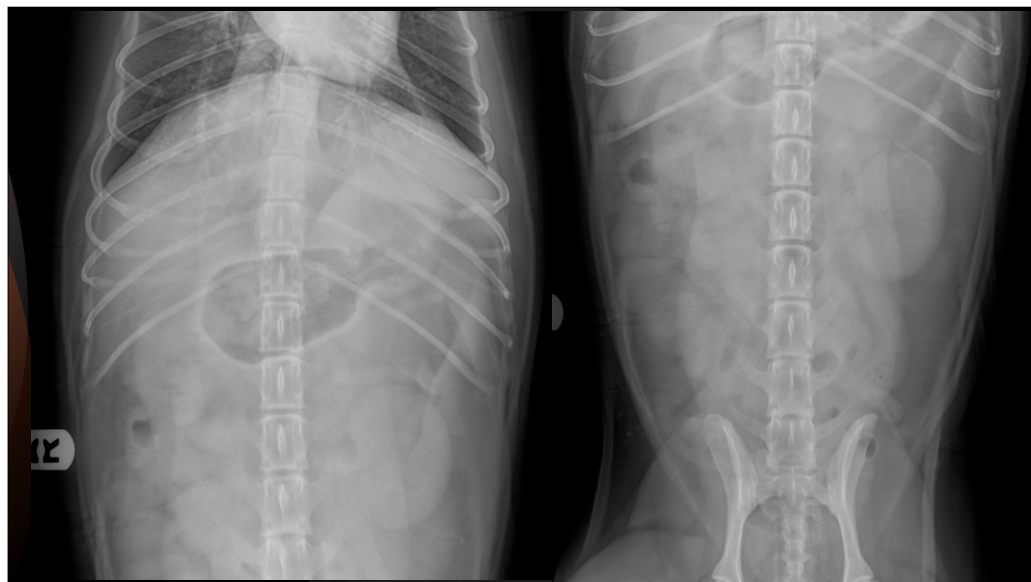
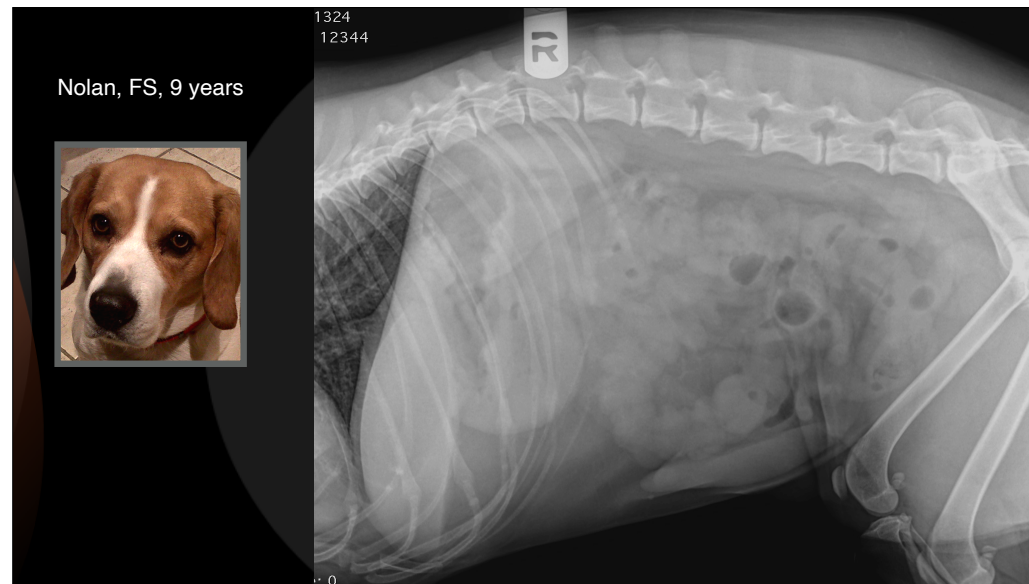
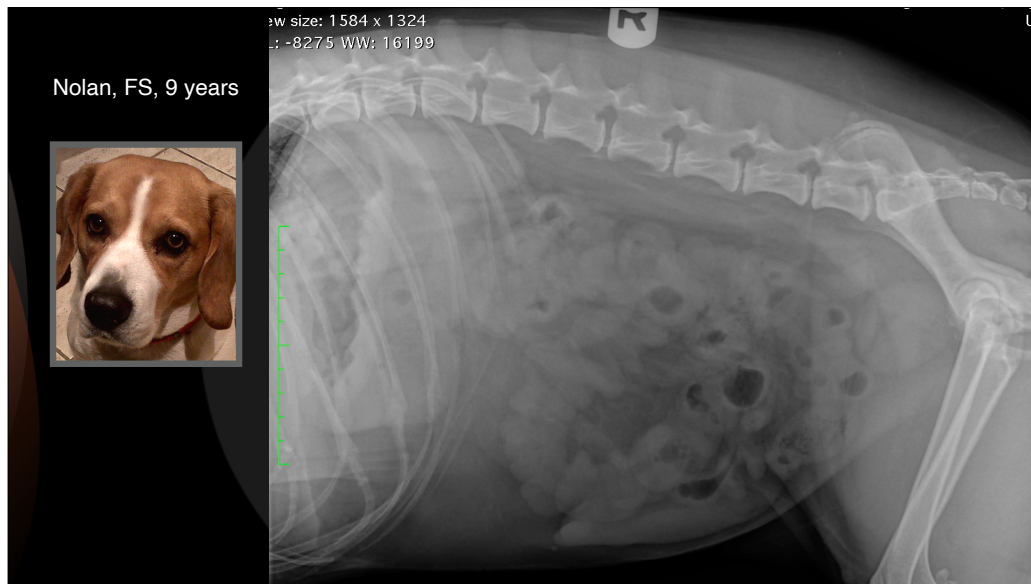
- Name the first three differential diagnoses



### Nolan, Beagle, FS, 9 years

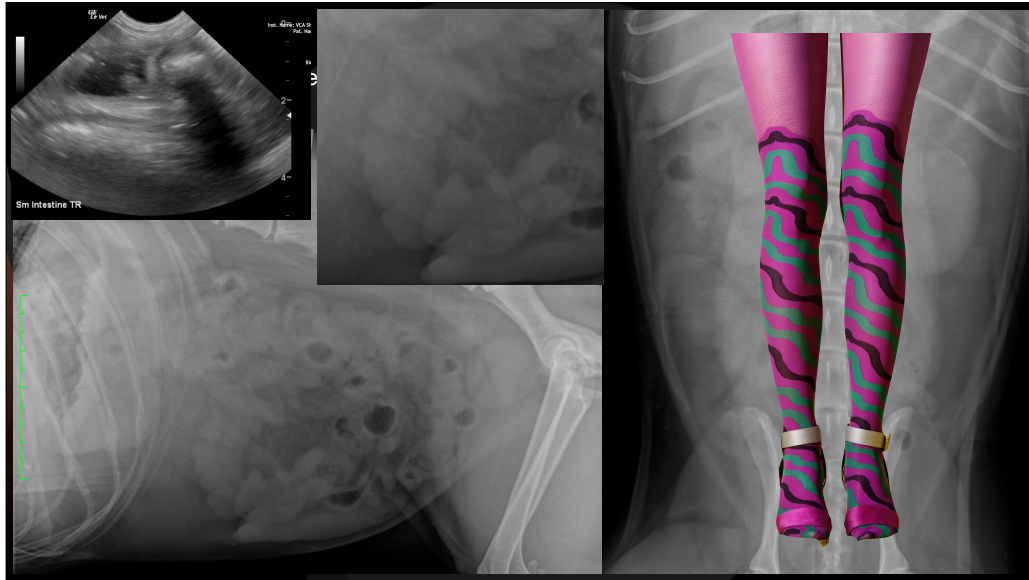
- She likes to check the trash
- Two years ago, an enterectomy for underwear occluding the SI
- Anorexic since yesterday
- Not vomiting





Your evaluation

- Name the first three differential diagnoses

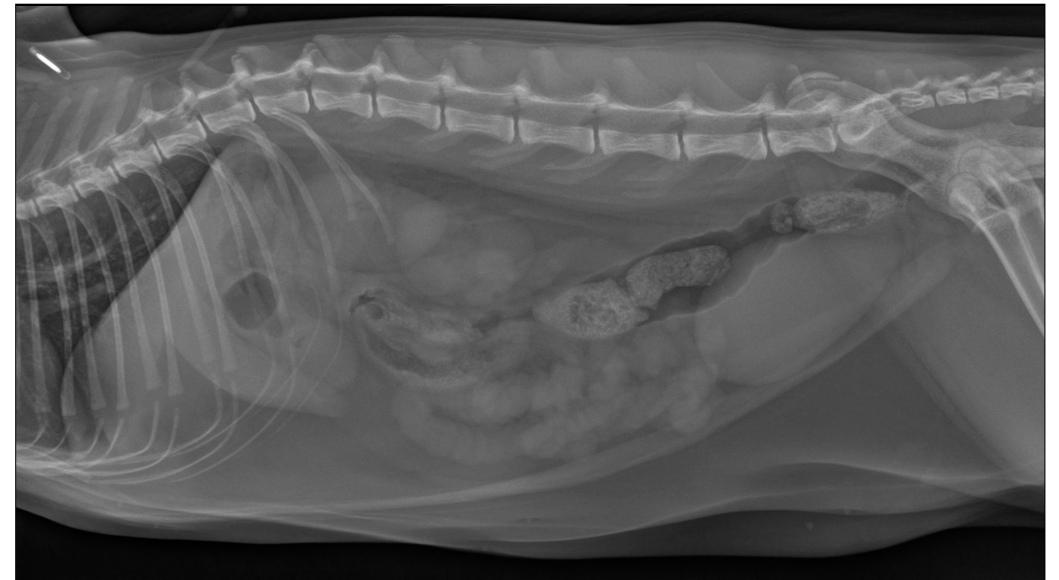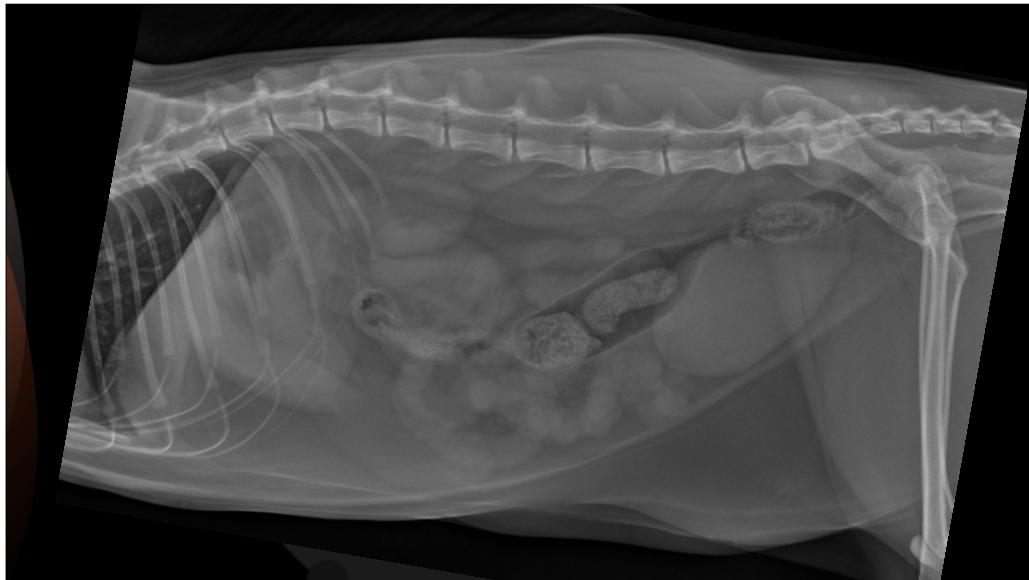


Tommy, DSH, MN, 4 years

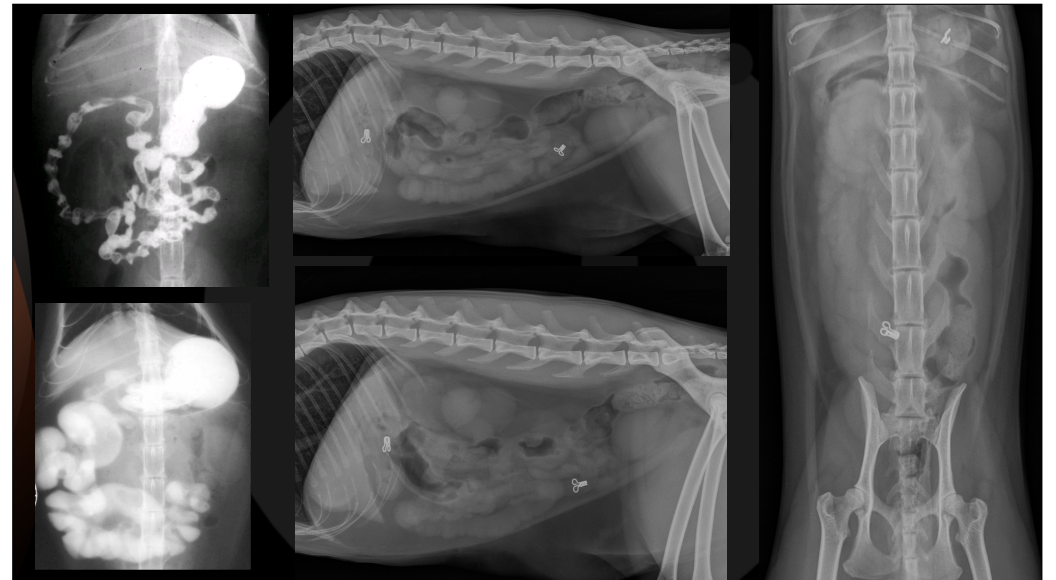
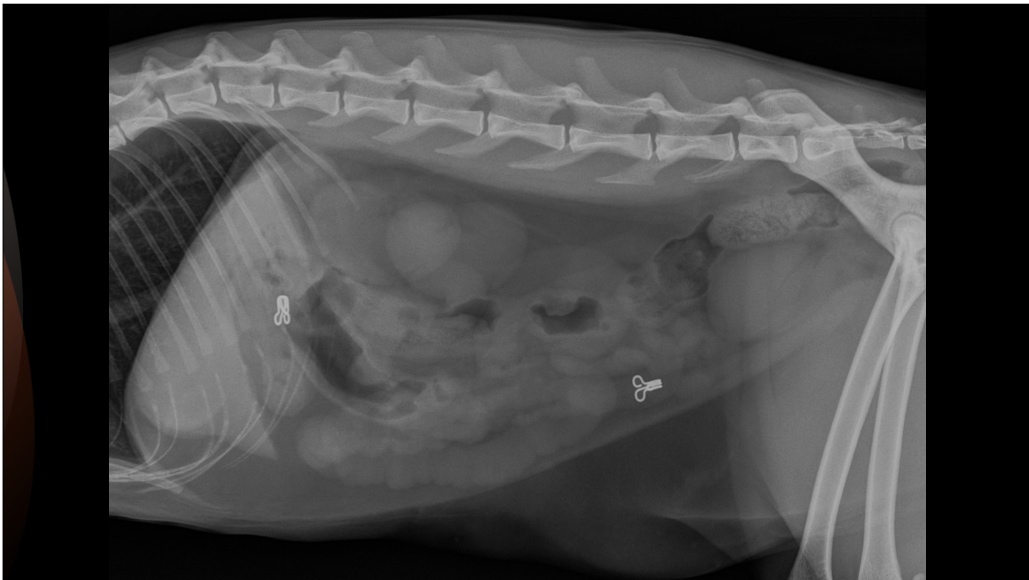
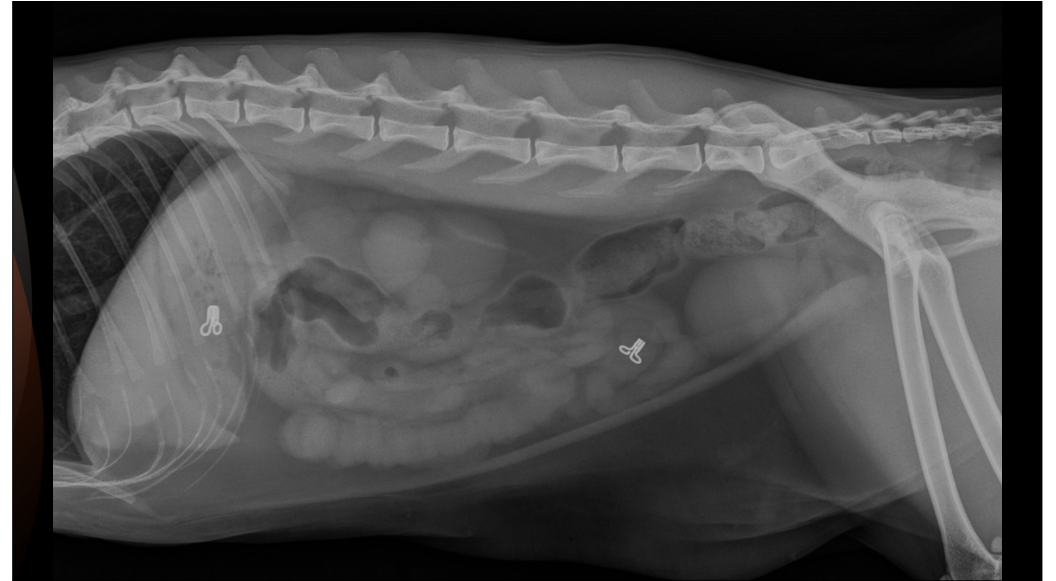
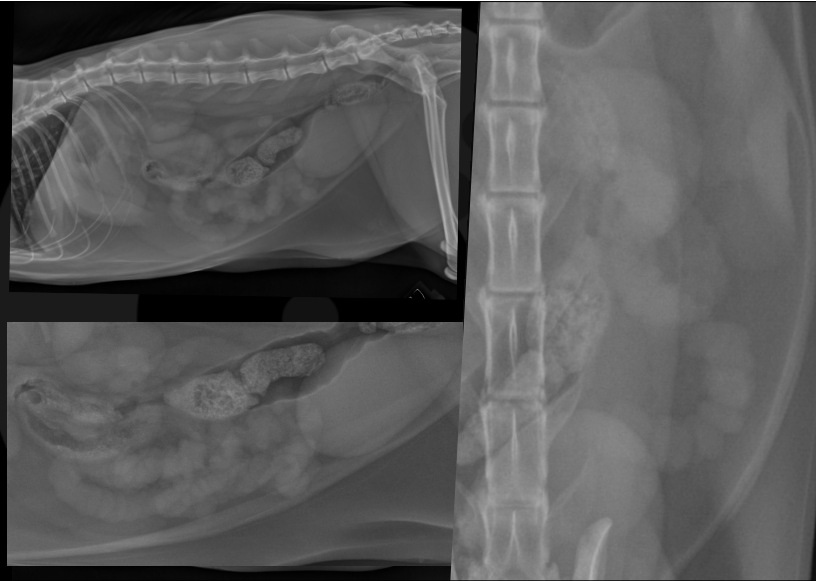
- He seems to be in abdominal pain
- Under the bed, lethargic



This slide features a black background with a large, semi-transparent grey circle in the center. The text "Tommy, DSH, MN, 4 years" is written in orange at the top. Below the text, there are two bullet points in white. To the right of the text, there is a close-up photograph of an orange tabby cat's face, looking slightly to the left. The cat has bright green eyes and is wearing a teal collar.



Tommy,  
MN, 4 years



## Conclusions

Follow the steps to increase the radiographic accuracy in predicting SI occlusion



delle **ore fredde sopportate, aspettando la luce perfetta per quella foto**», ha commentato **Giulio Montini** dopo essere stato premiato come Weather Photographer of the Year 2021. «**Questa foto** - ha raccontato - **può essere scattata solo da un punto**. C'è una piccola chiesa in cima a una collina nel comune di Airuno, in provincia di Lecco in Italia. Sotto la nebbia passa il fiume Adda. Nei mesi autunnali, in alcune

# Thank you



Diagnostic Mindset

[www.diagnosticmindset.com](http://www.diagnosticmindset.com)