

I mezzi di contrasto servono ancora per l'apparato gastroenterico?



Diagnostic Mindset

Gliola Spattini
DVM, PhD, DECVDI

Objectives

- Radiology is an essential diagnostic modality, and the contrasts expand its diagnostic value



Positive

Negative

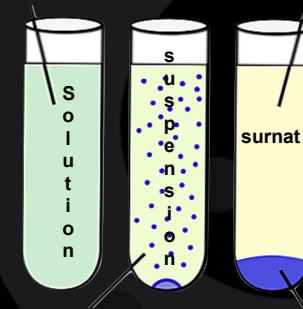
Barium

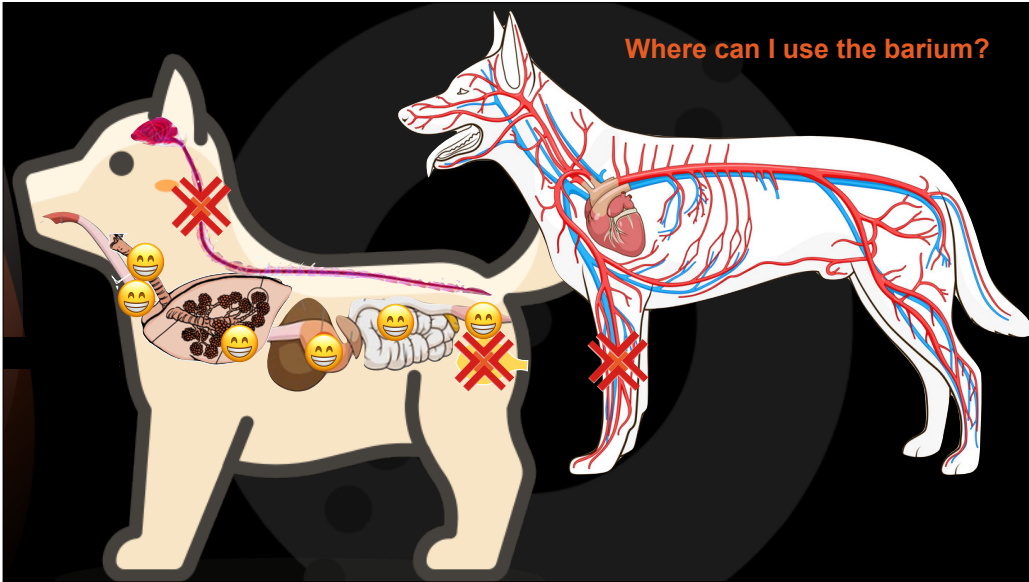
Gas

Iodinated non ionic

Barium

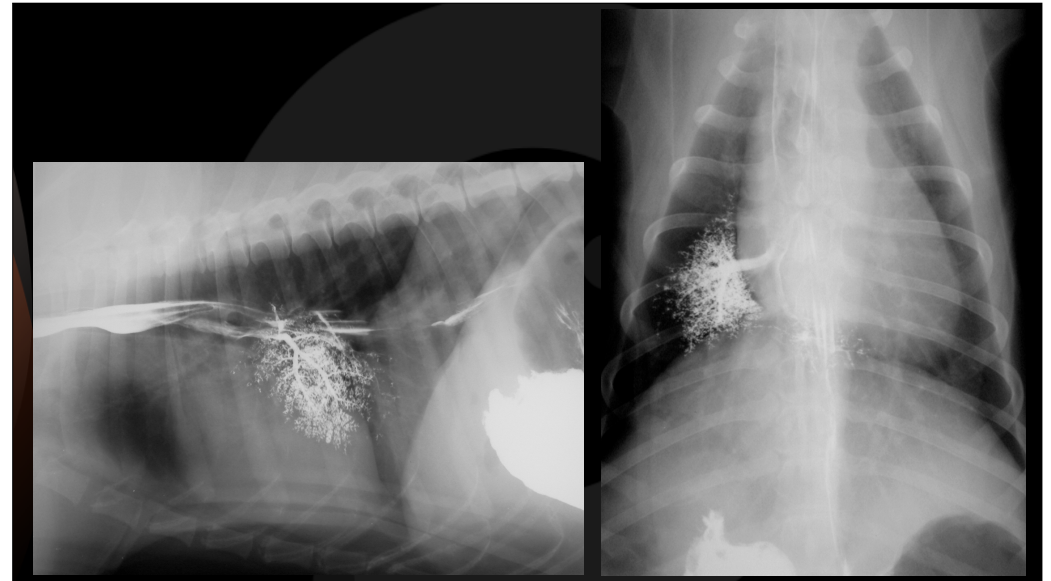
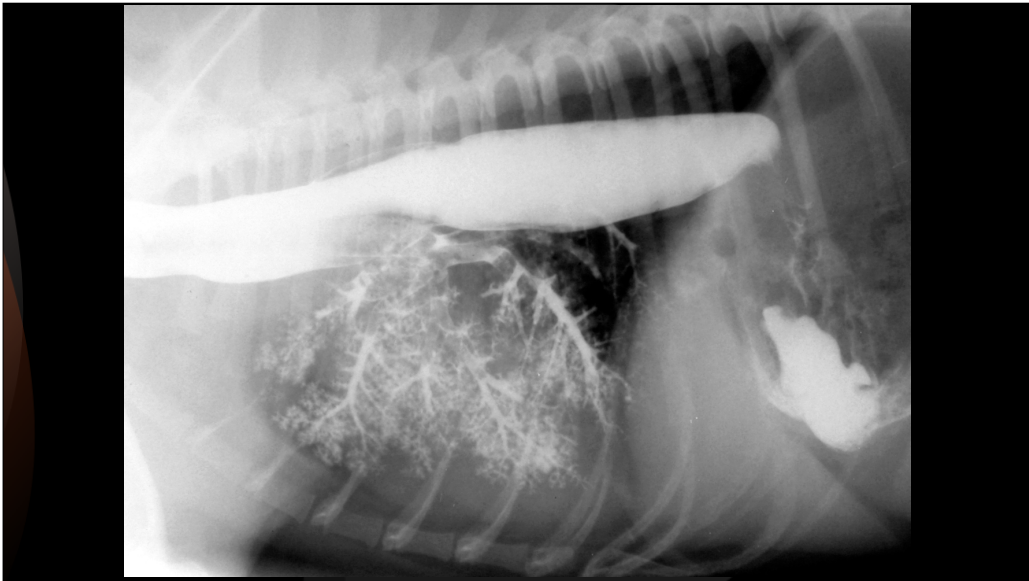
- Powder
- Paste
- W/V

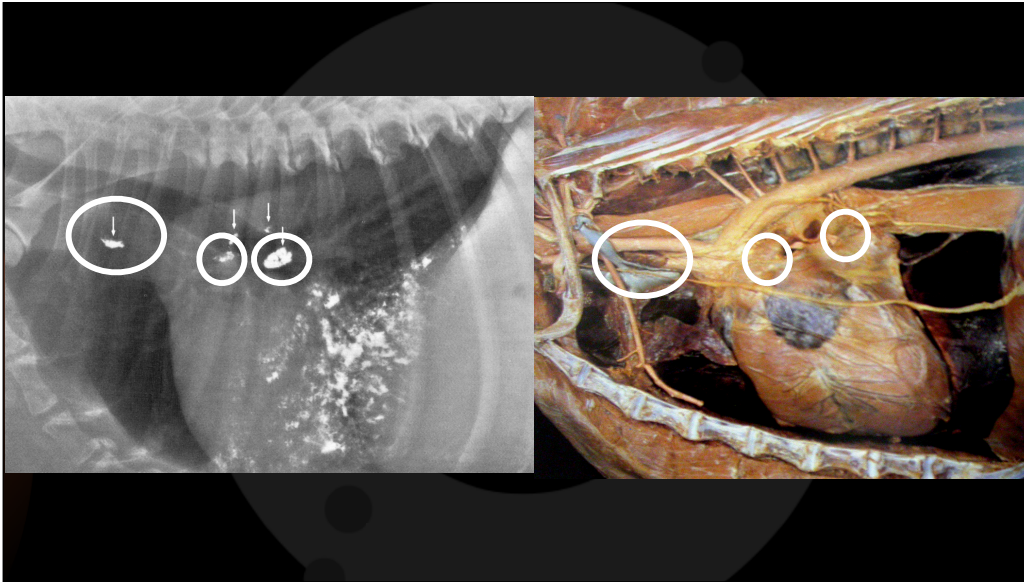




Barium

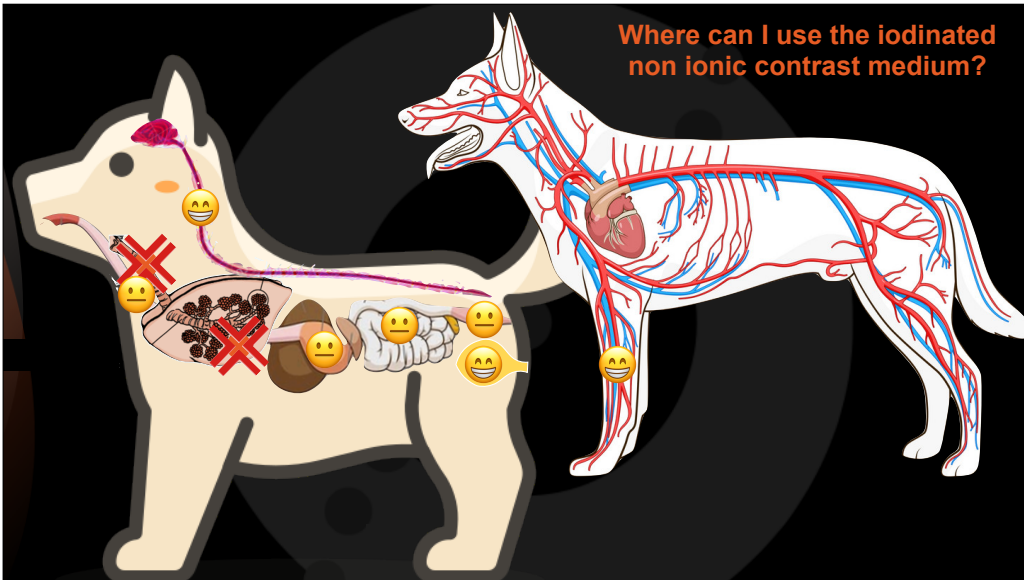
| Powder | Paste |
|------------------|--------------------------|
| Tasteless | Flavored |
| Not hypertonic | Hypertonic |
| Easier to dosage | More difficult to dosage |





Iodinated non ionic

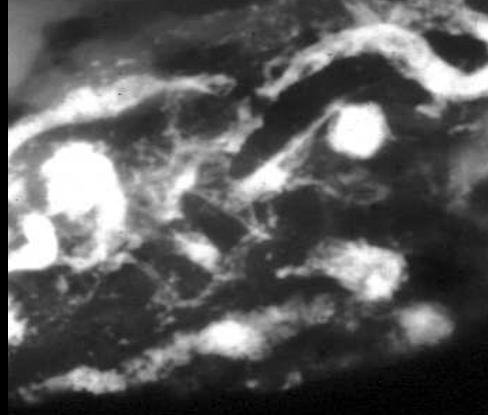
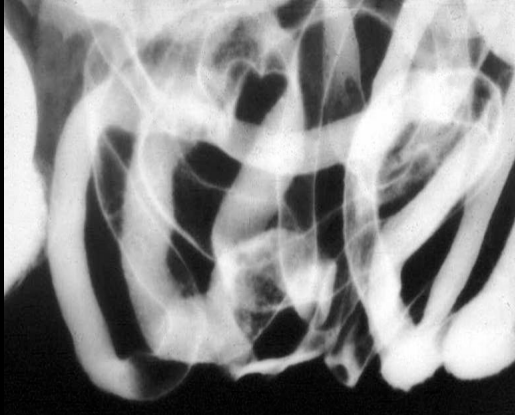- Solution
- Hypertonic



| Barium | Iodinated non ionic |
|----------------------------------|---|
| Dangerous in case of perforation | Safe in case of perforation |
| Best mucosal and GI outline | Poor image quality of the GI but quicker passage time |
| Safe in case of ab ingestis | Severe pulmonary edema in case of ab ingestis |
| Helps in case of severe diarrhea | Dangerous in patient with hypotension |

Barium

Iodinated non ionic



Negative

- Room air is the most used
- Where barium goes, gas goes!

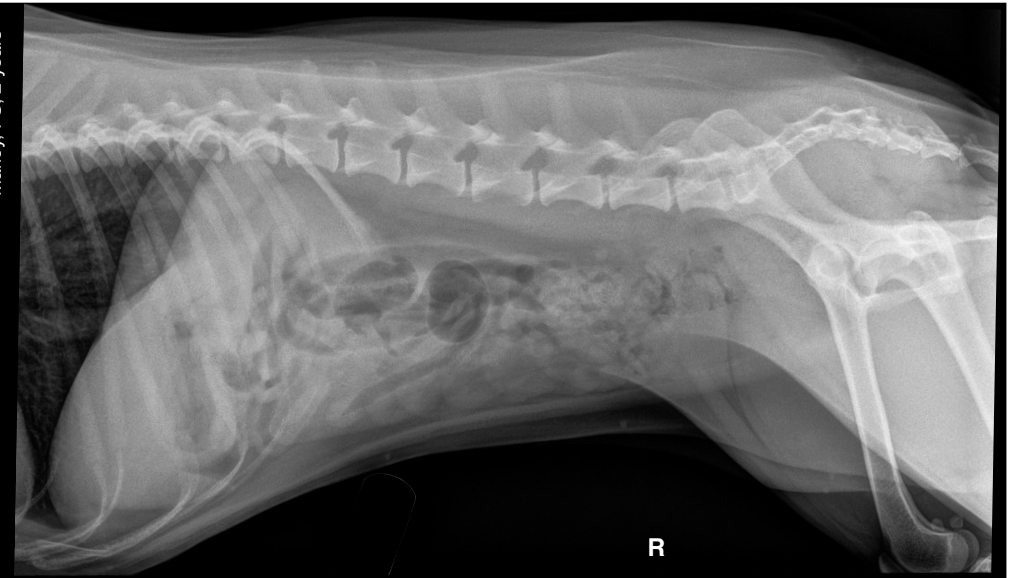


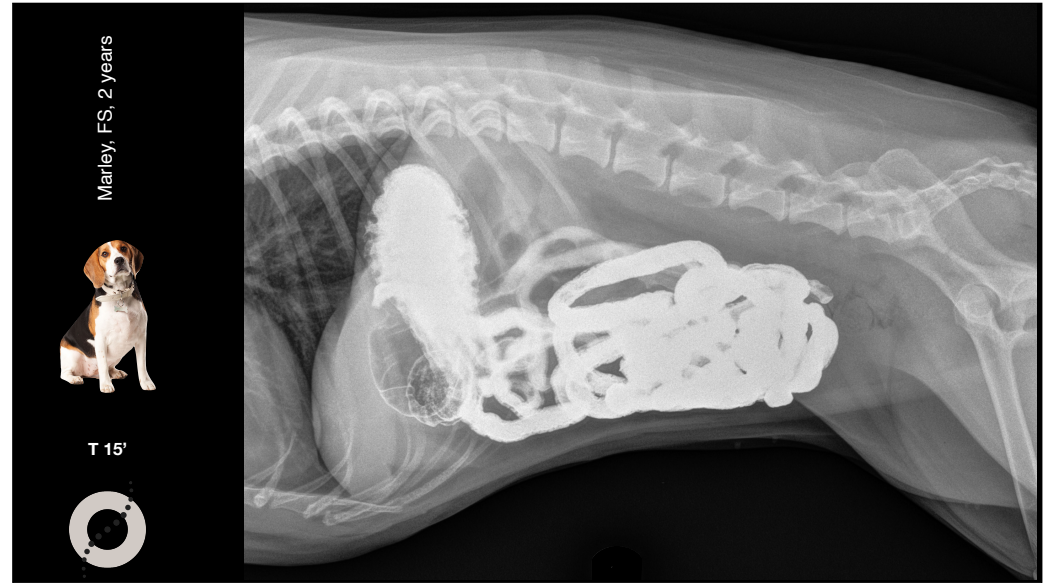
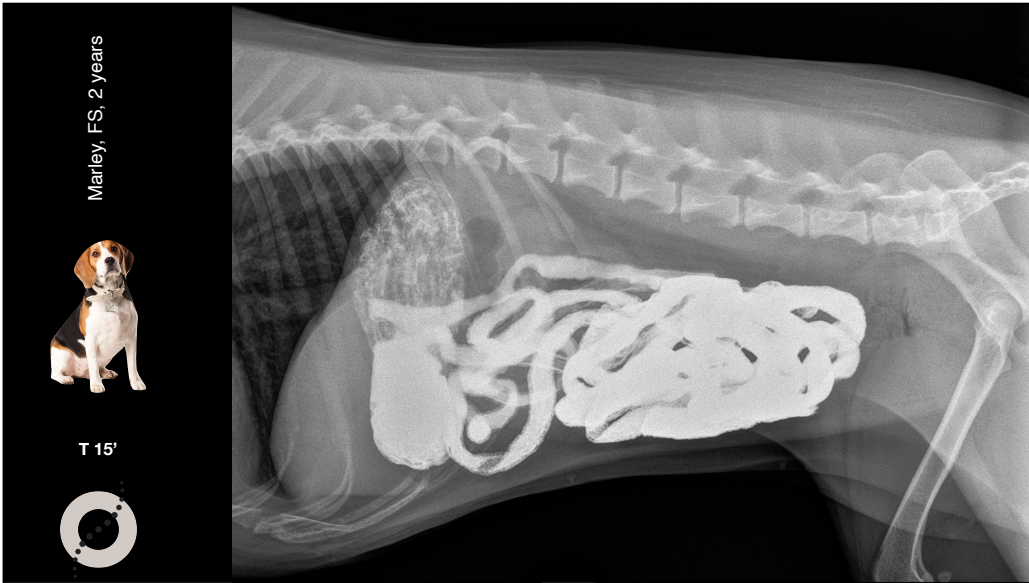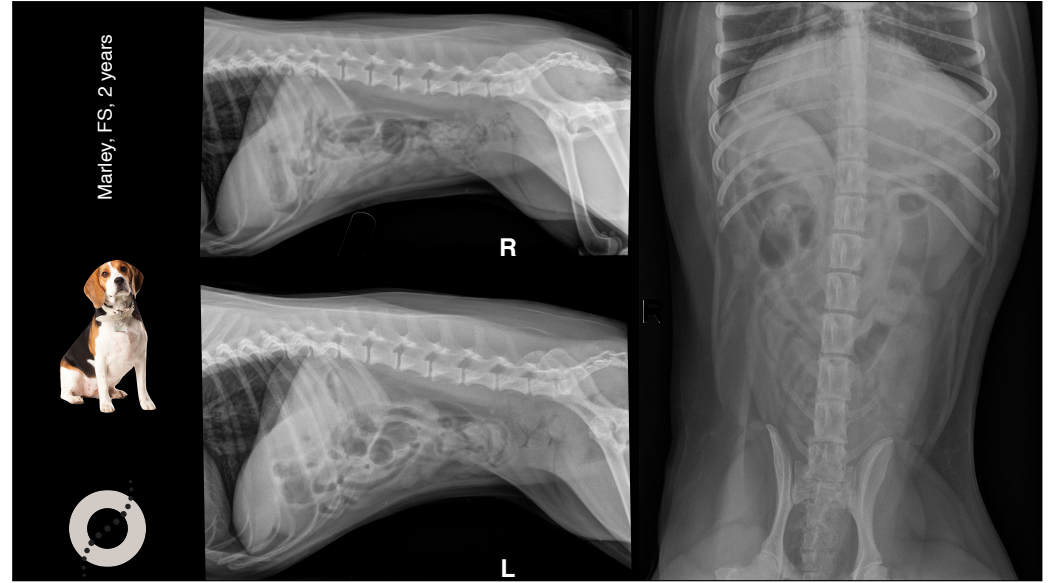
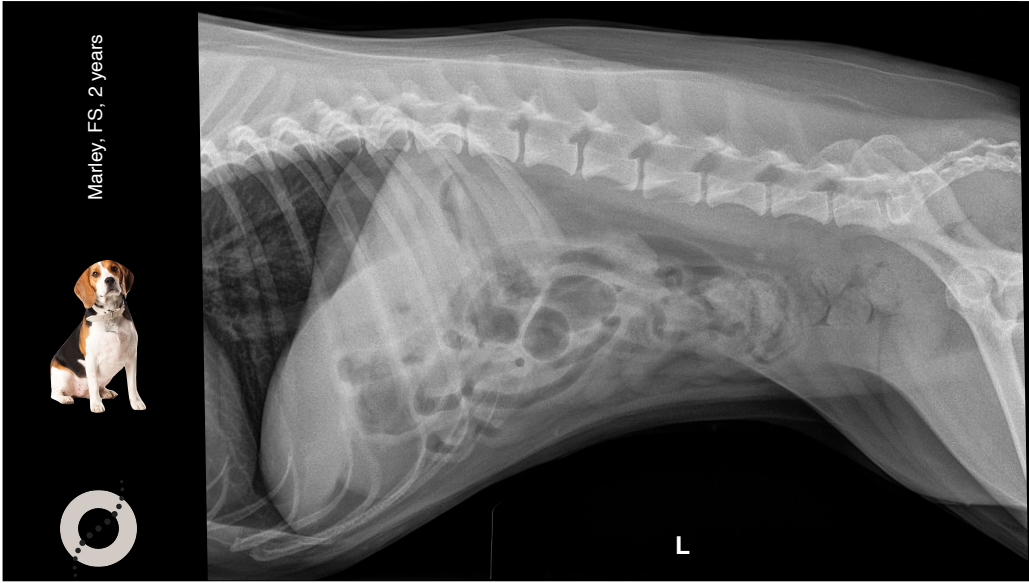
Marley, Beagle, FS, 2 years

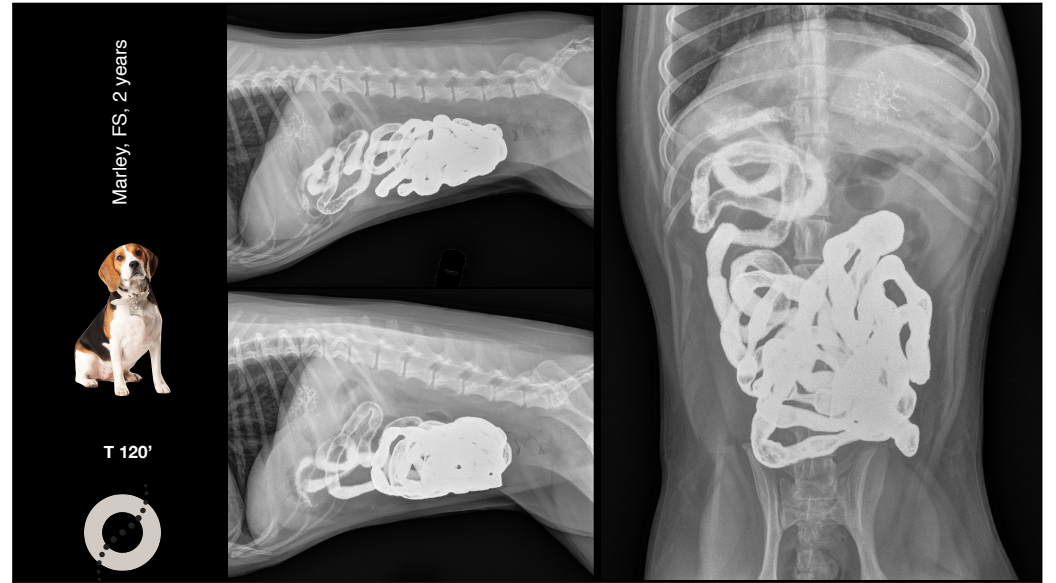
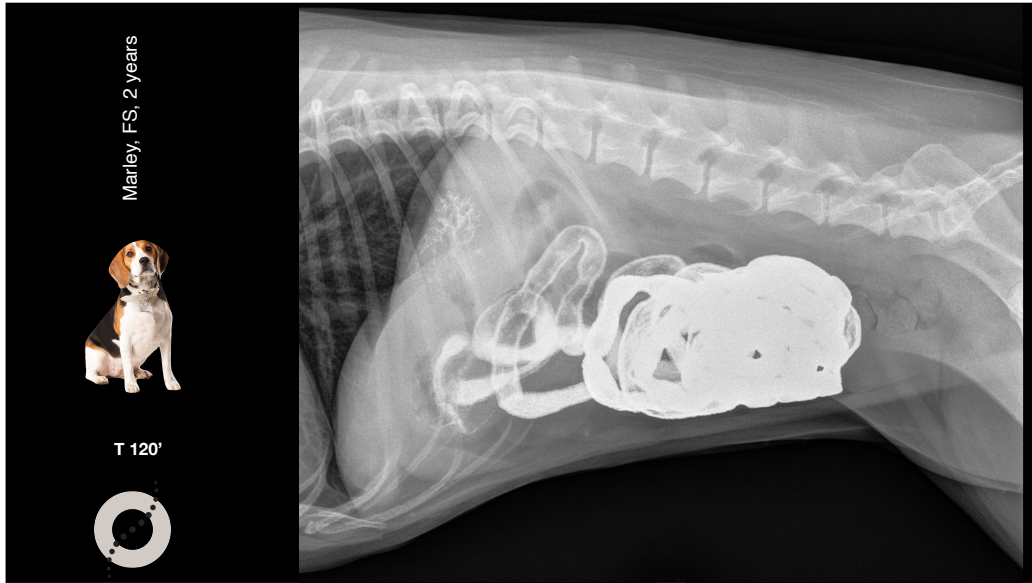
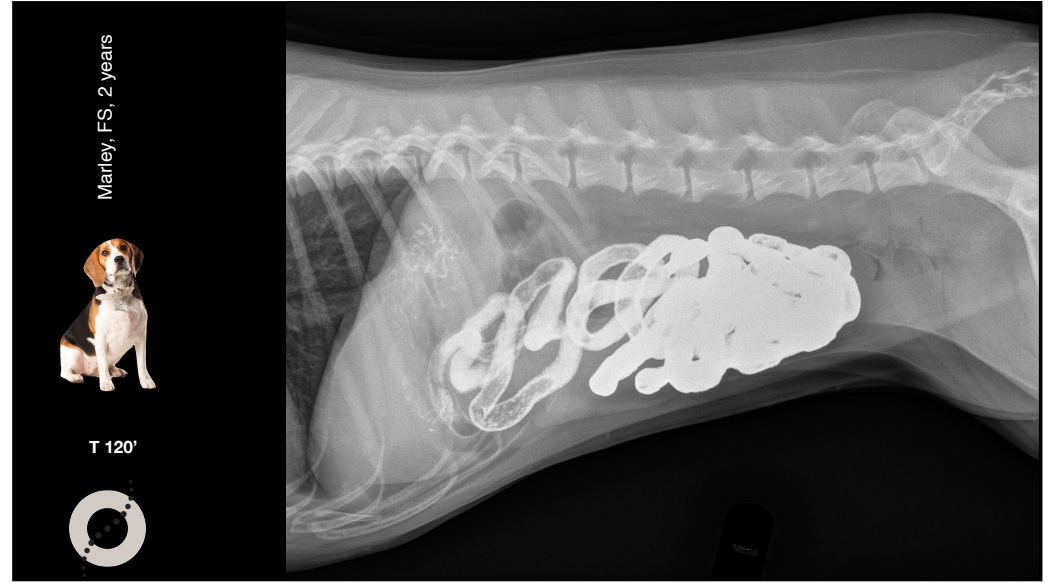
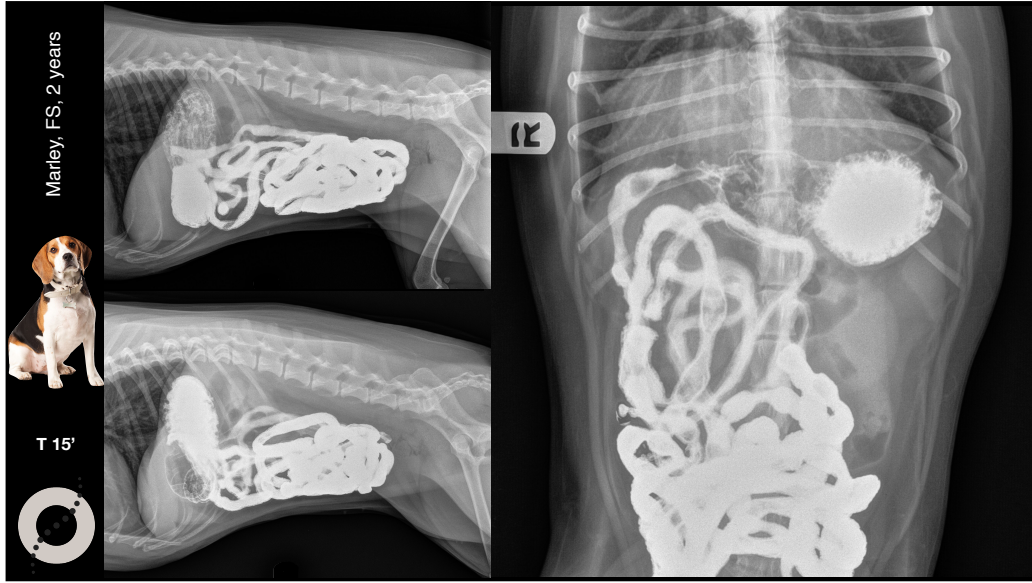
- Vomiting
- Ate mulch 2 weeks ago
- She is vomiting through Cerenia
- No pain on gastric palpation

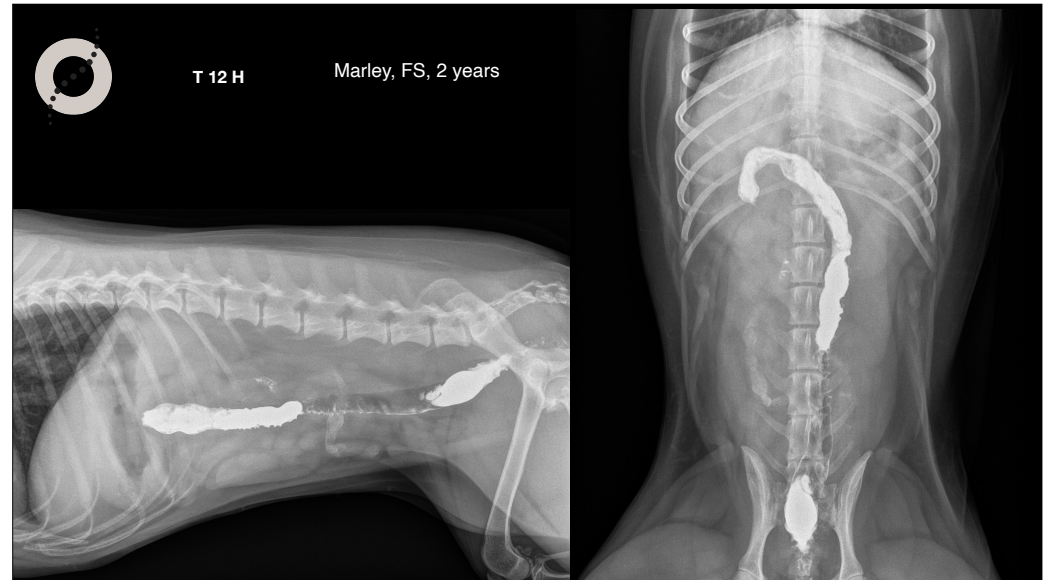

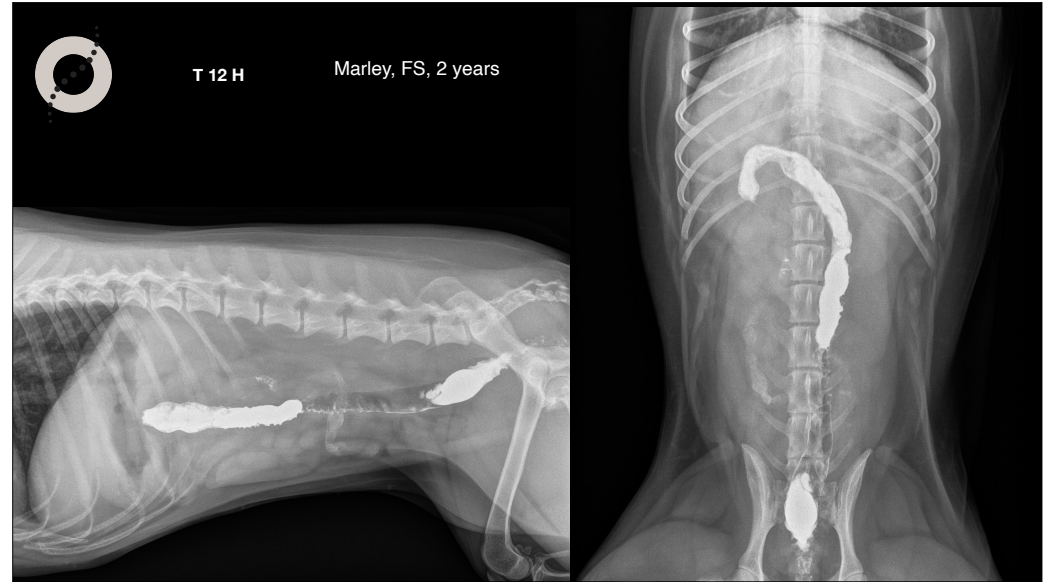
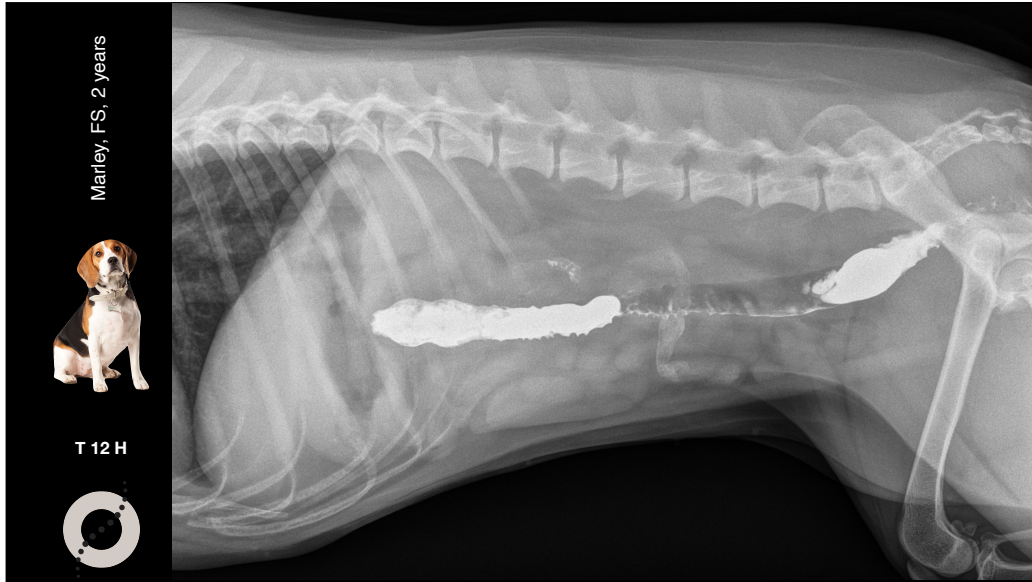


Marley, FS, 2 years









Nola, Golden Retriever, FI, 4 years

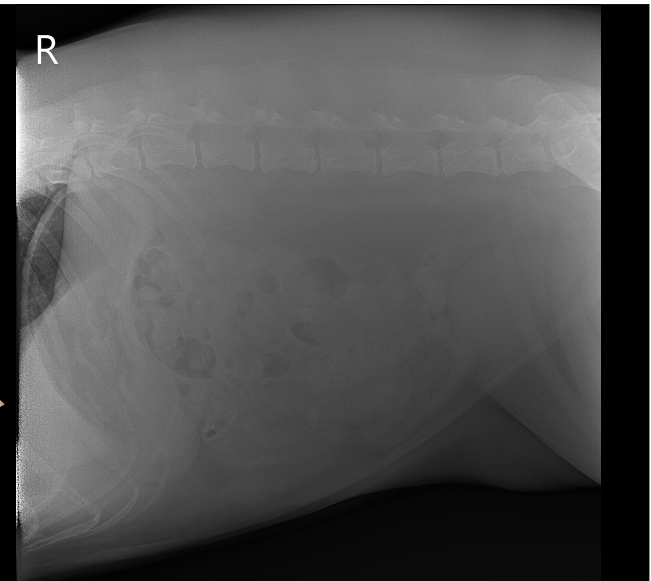
- Refused dinner yesterday
- Vomiting this morning
- New puppy in the house



Nola, FI, 4 years



R

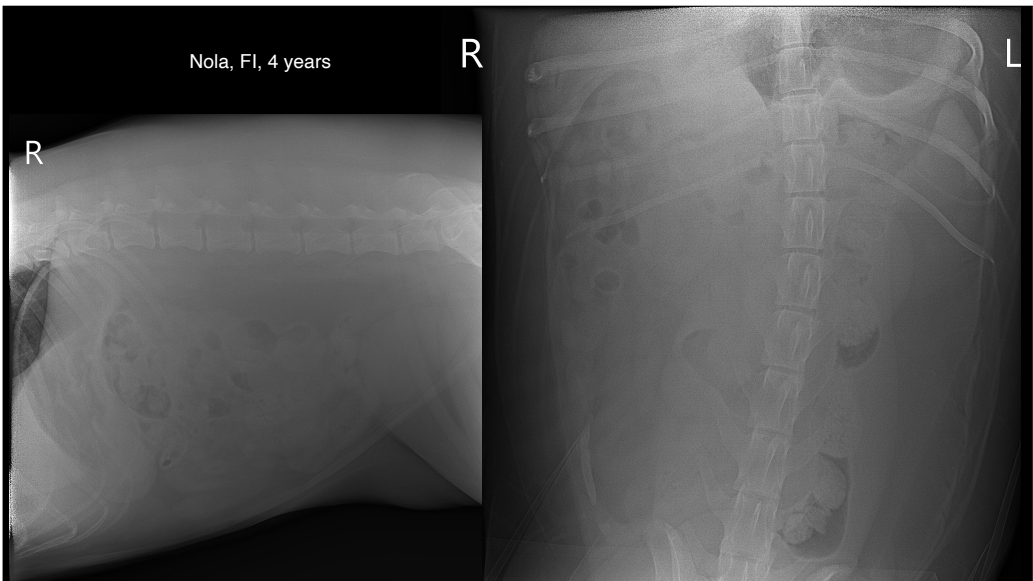


Nola, FI, 4 years

R

L

R

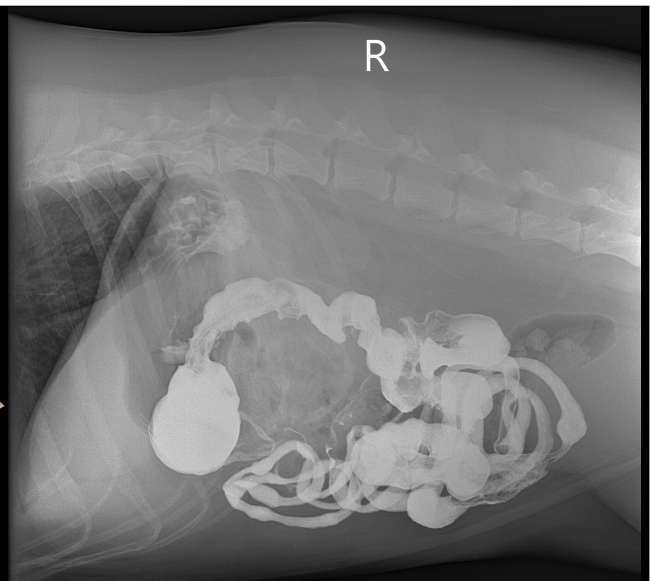


Nola, FI, 4 years



T 15'

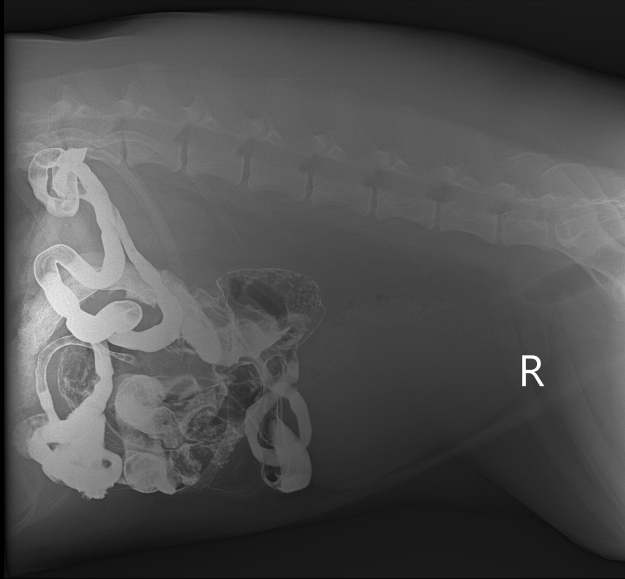
R



Nola, FI, 4 years



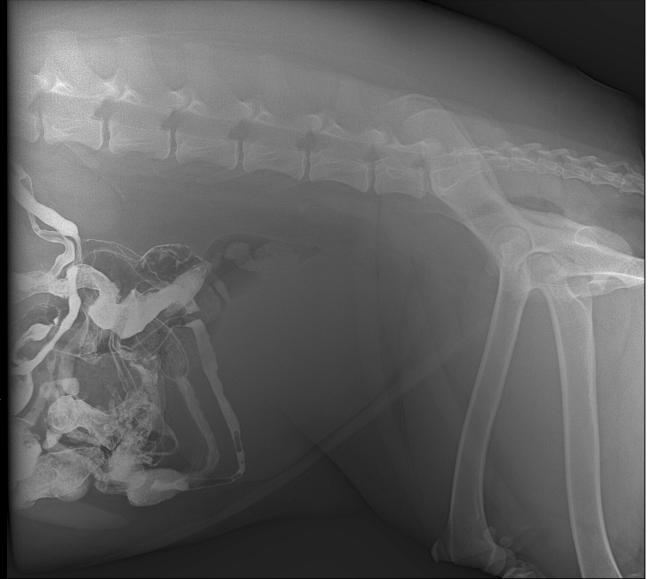
T 40'



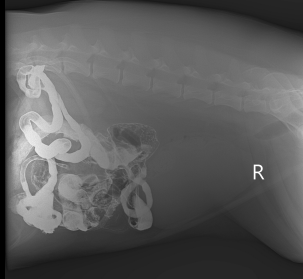
Nola, FI, 4 years



T 40'

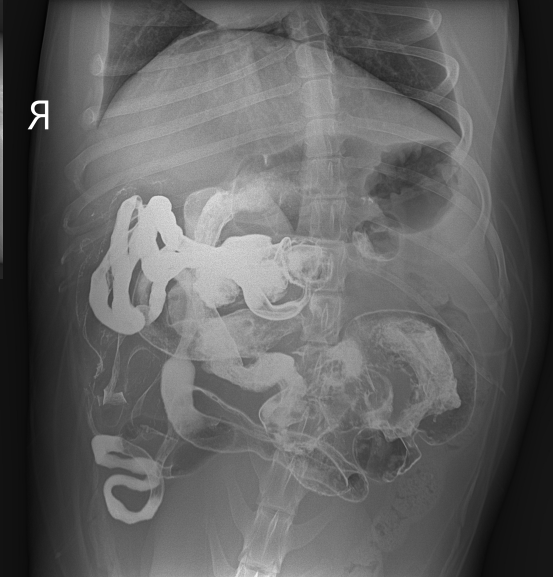

Nola, FI, 4 years



R

R



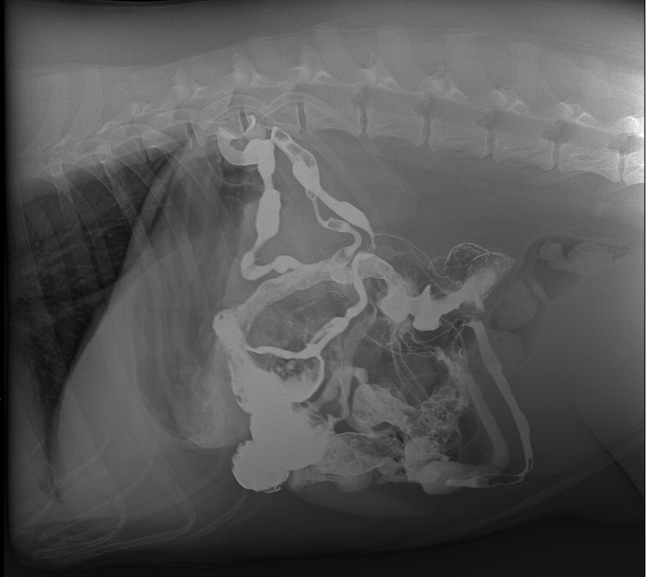
T 40'

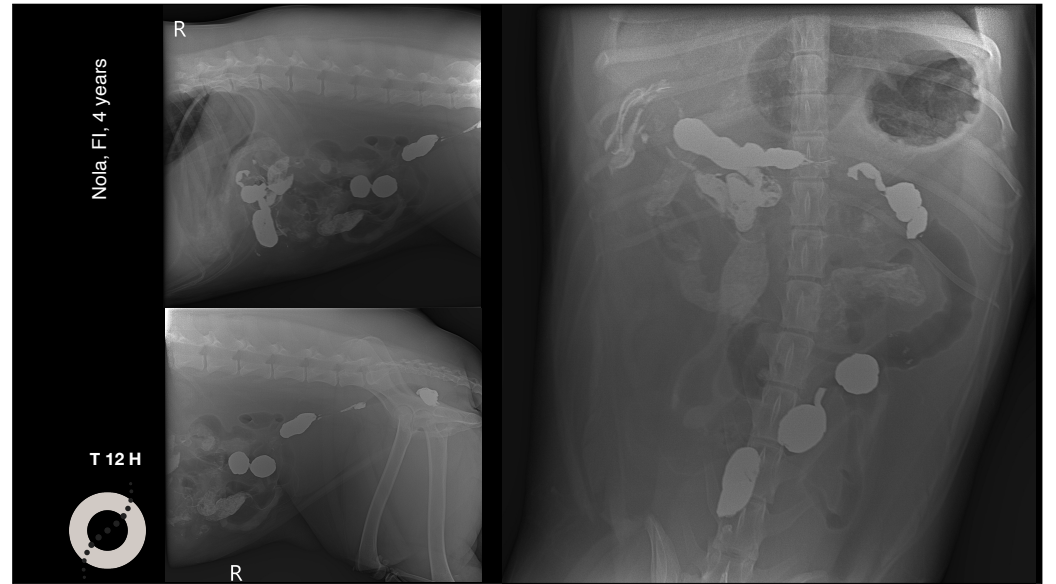
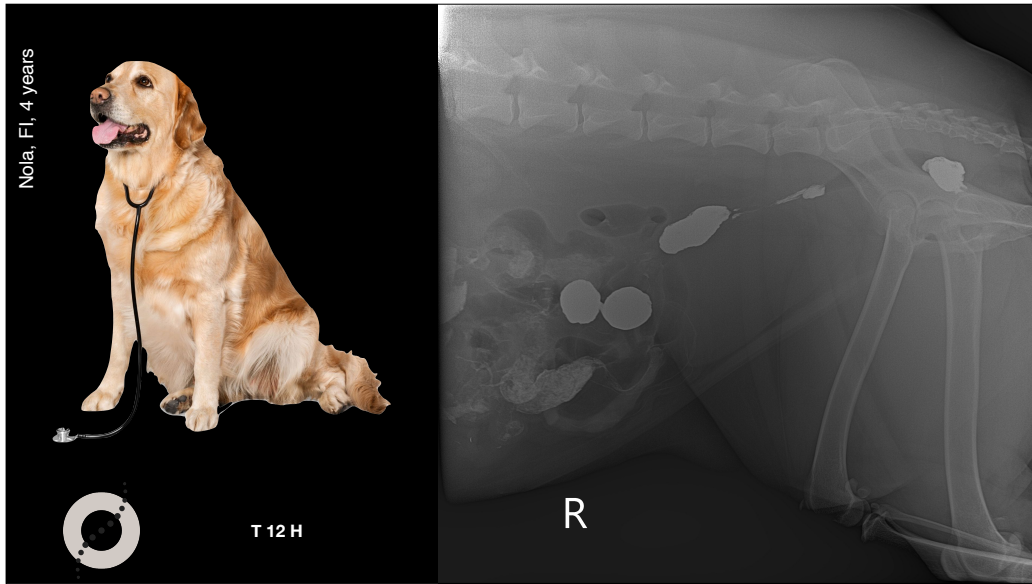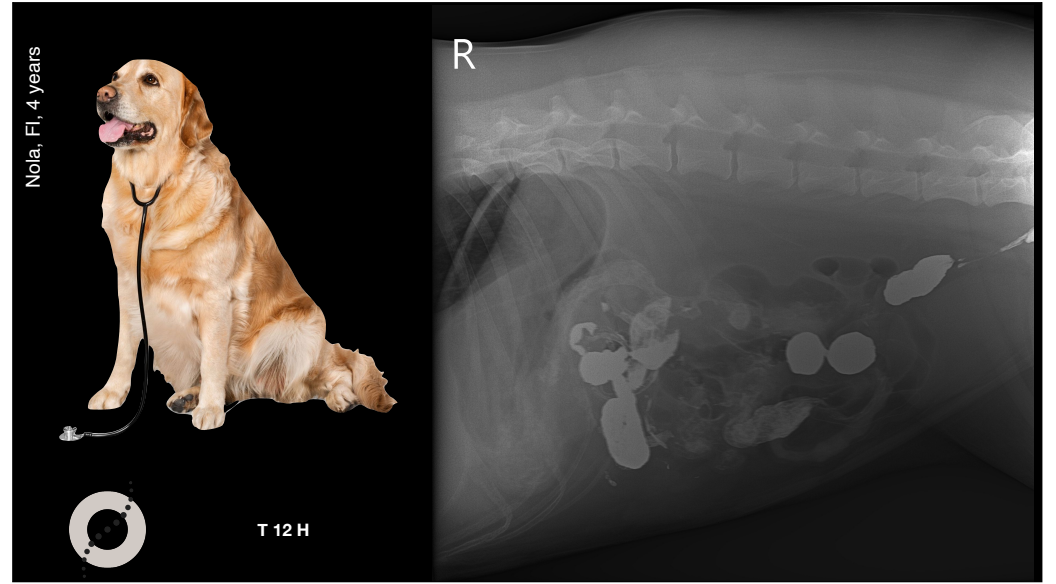
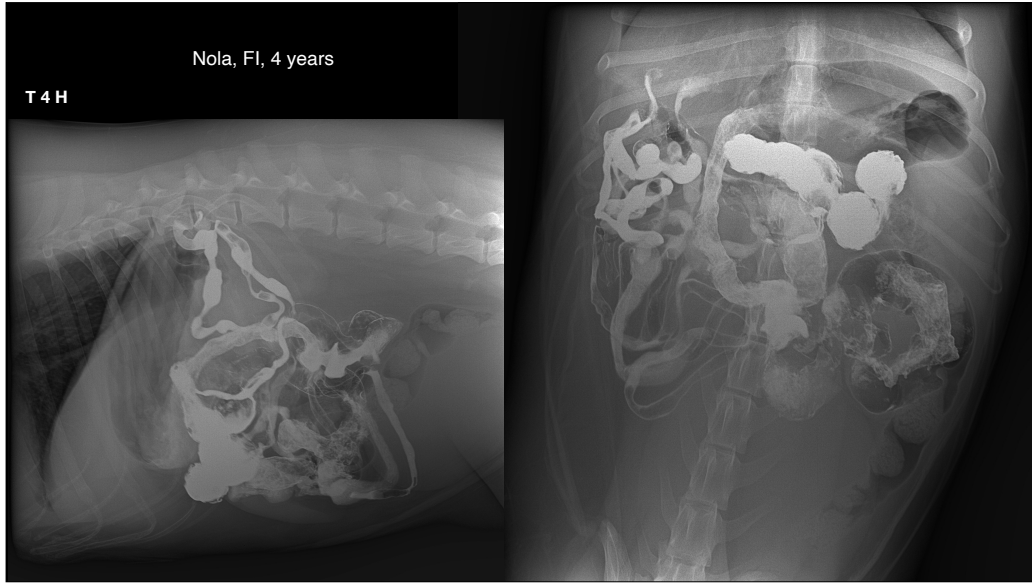


Nola, FI, 4 years



T 4 H

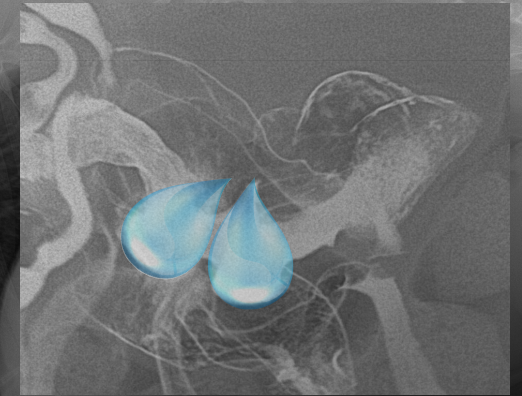




Your evaluation

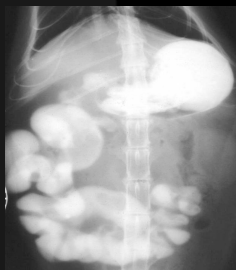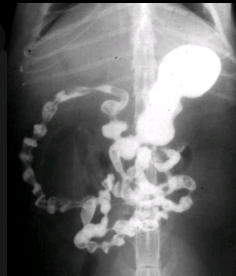Key points:

- Check for GE emptying delay
- Check for drop signs
- Check for abnormal content
- Check for abnormally absorbing tissues



Corrugation: symmetric


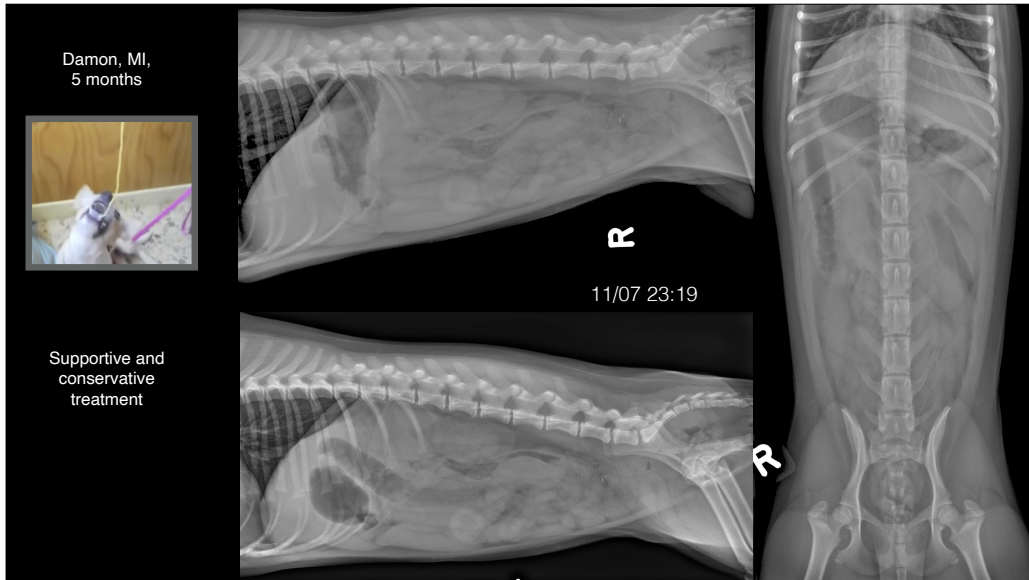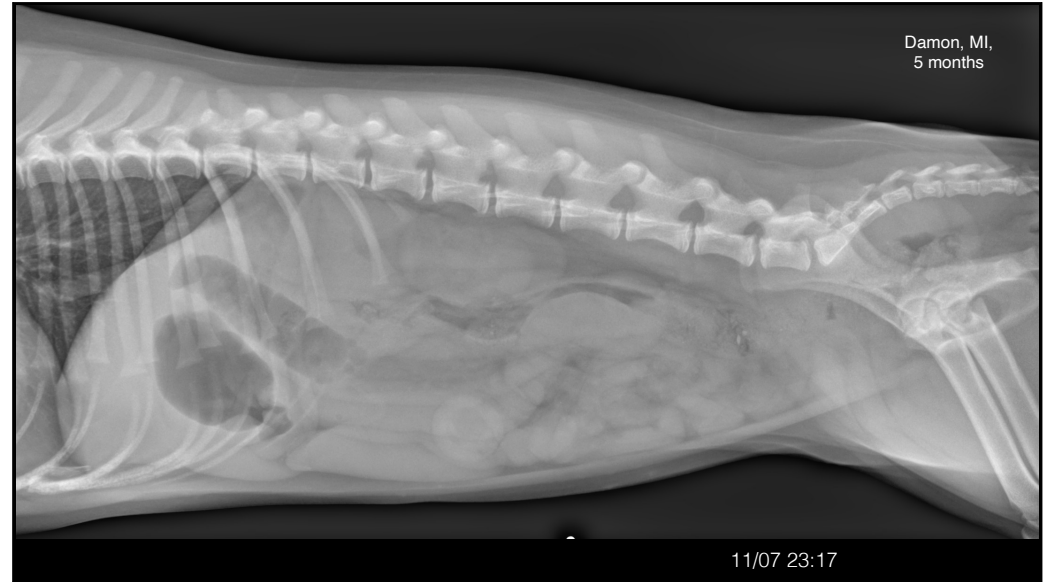
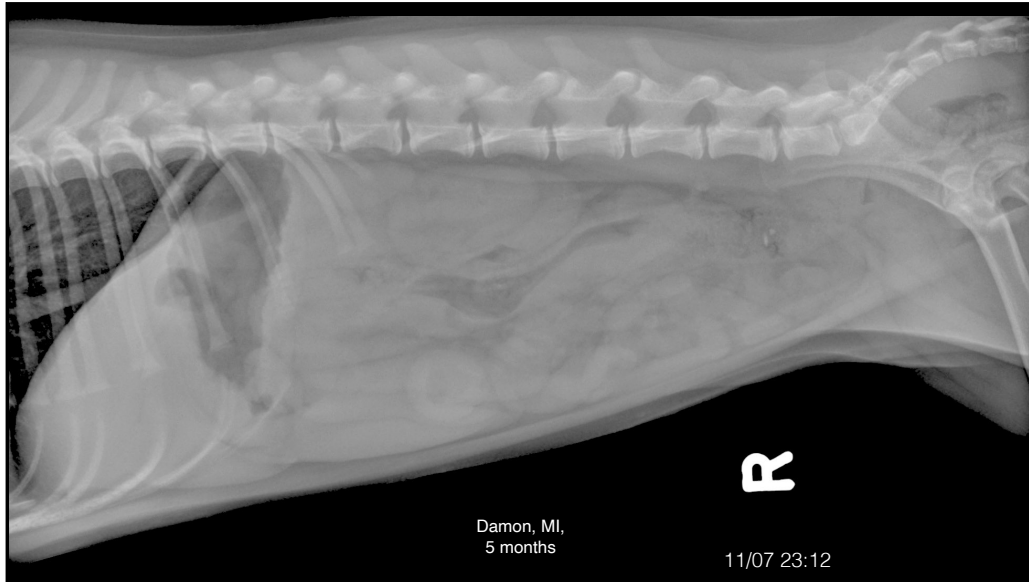
Plication: asymmetric


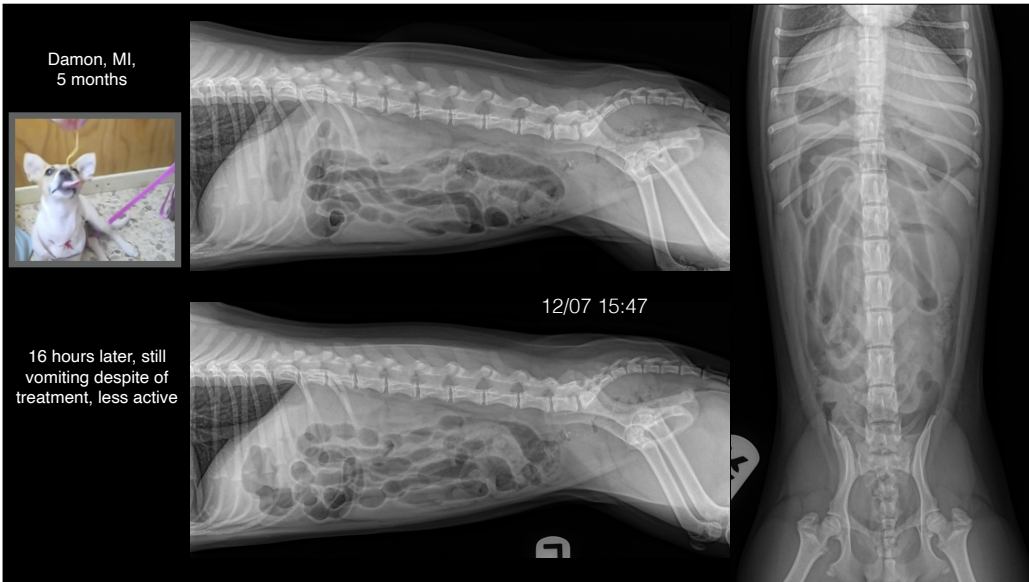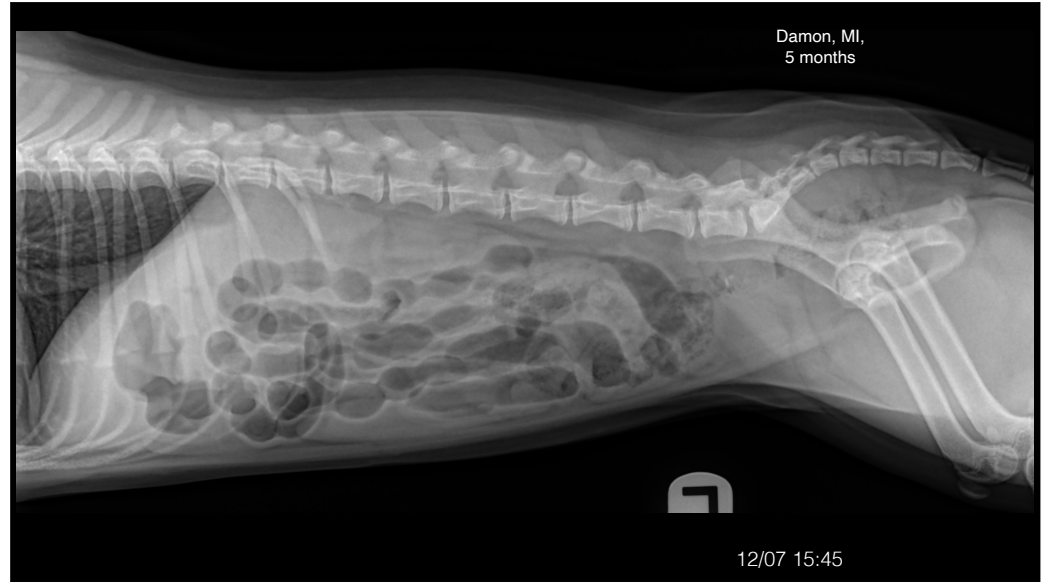
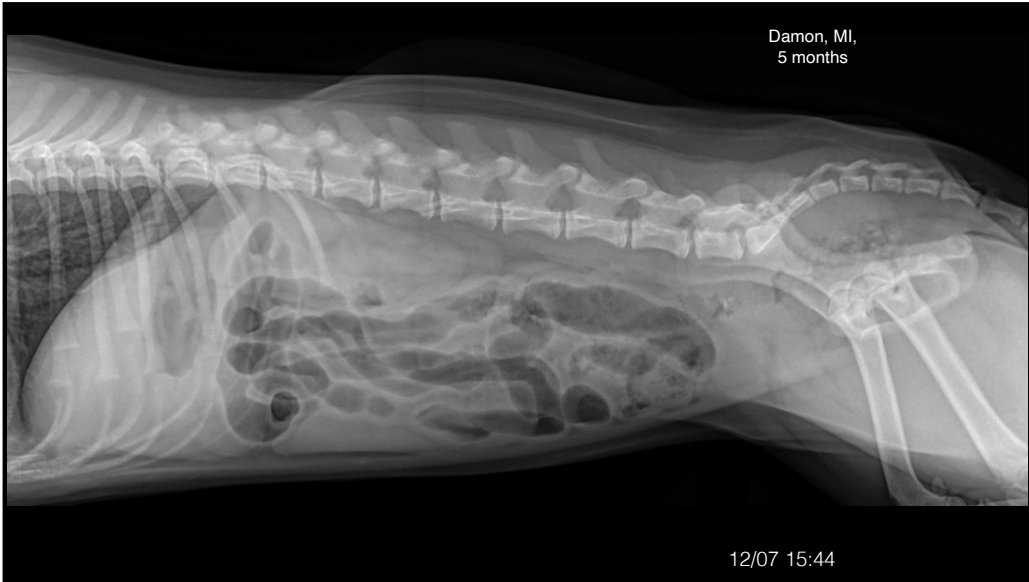



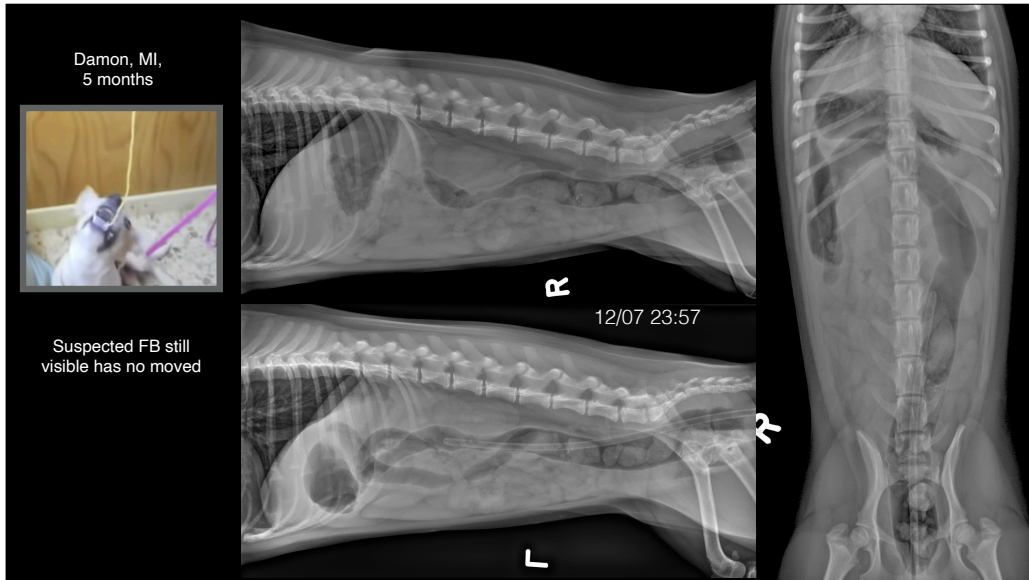
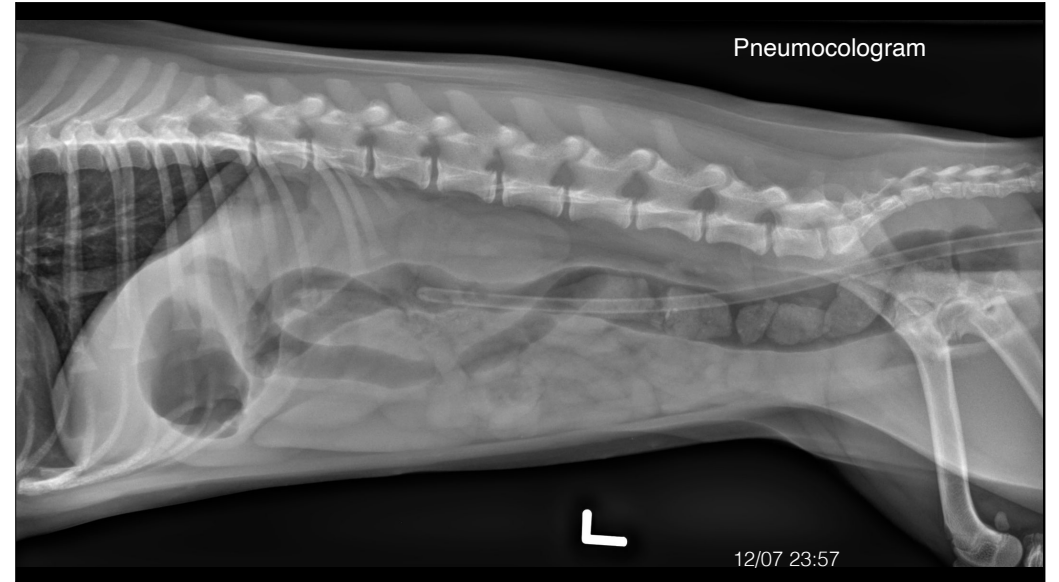
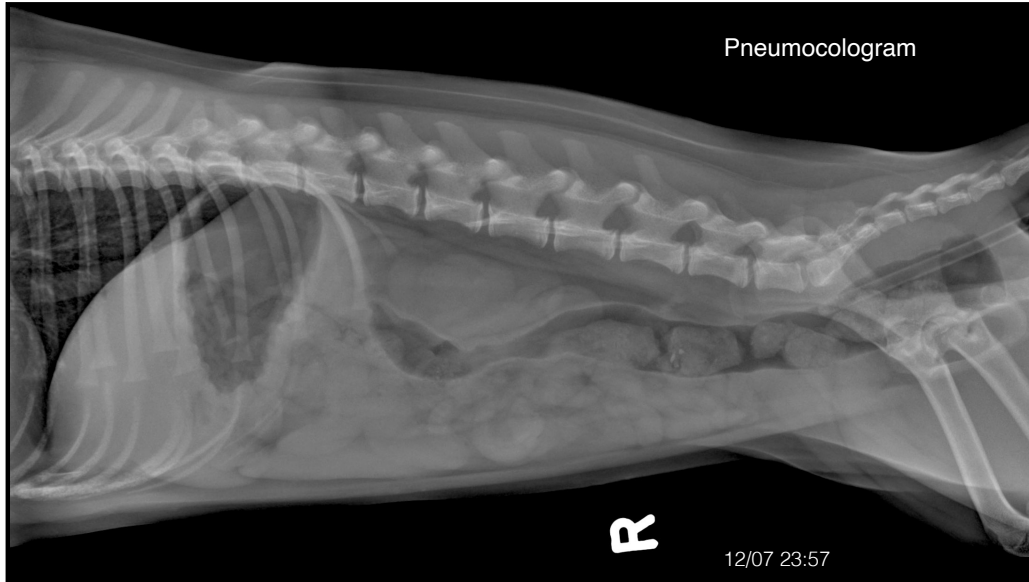
Damon, Jack Russell, MI, 5 months

- Vomiting
- Not eating
- He loves to ingest FBs





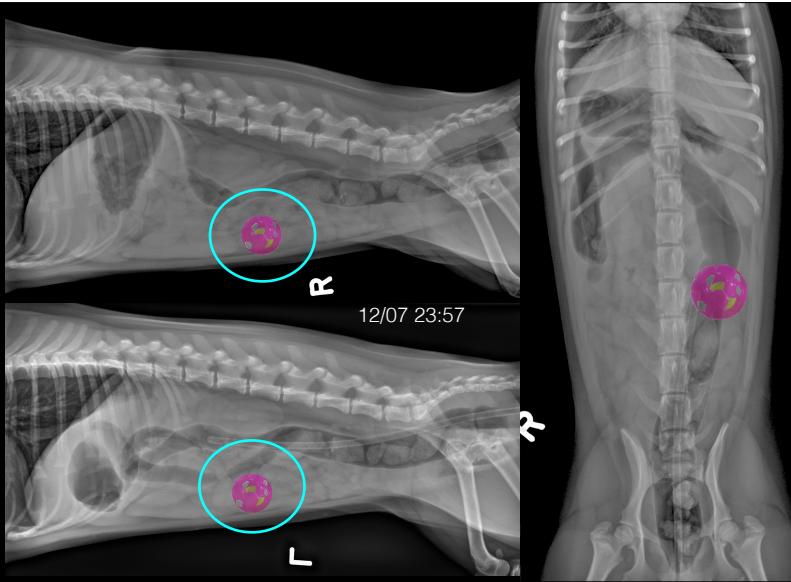




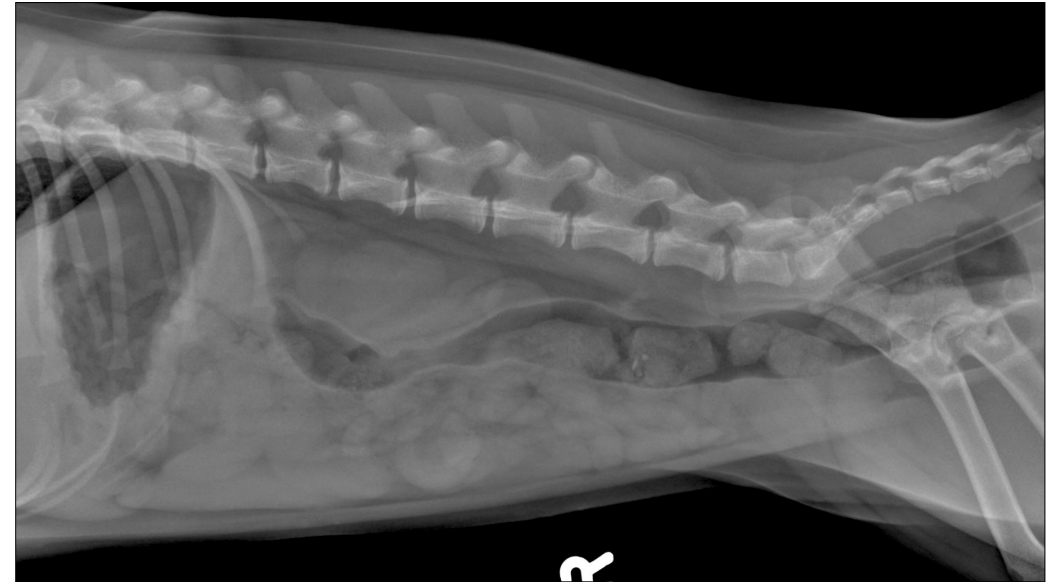
Damon, MI,
5 months



Suspected FB still
visible has no moved

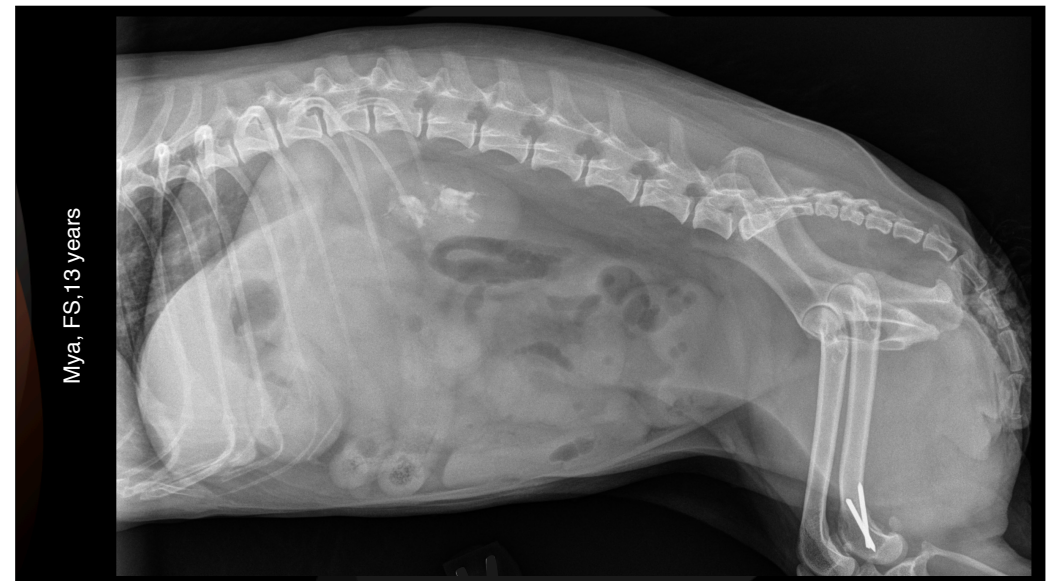

12/07 23:57



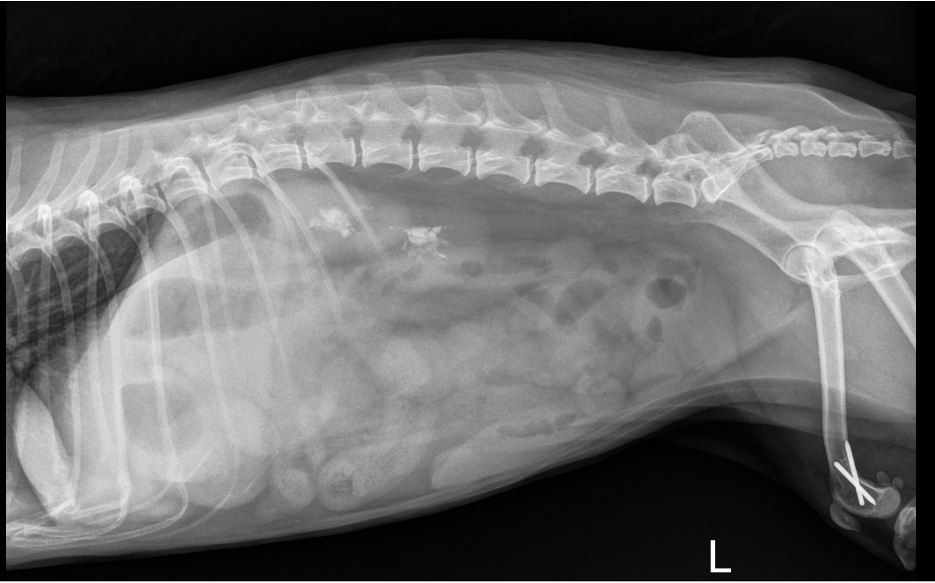
Mya, Yorkshire Terrier, FS, 13 years

- Two days of anorexia
- Vomiting and tense abdomen
- Gauze hanging out of rectum

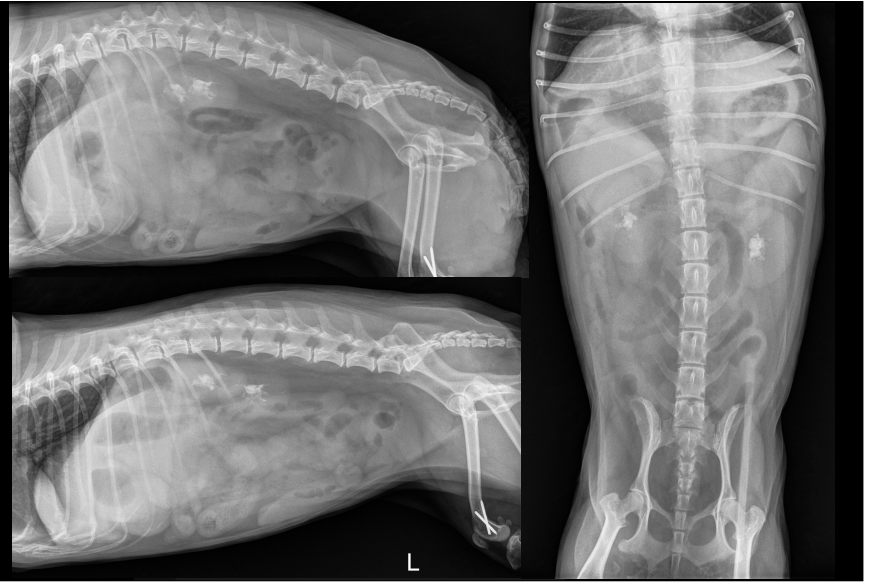


Mya, FS, 13 years

Mya, FS, 13 years



Mya, FS, 13 years

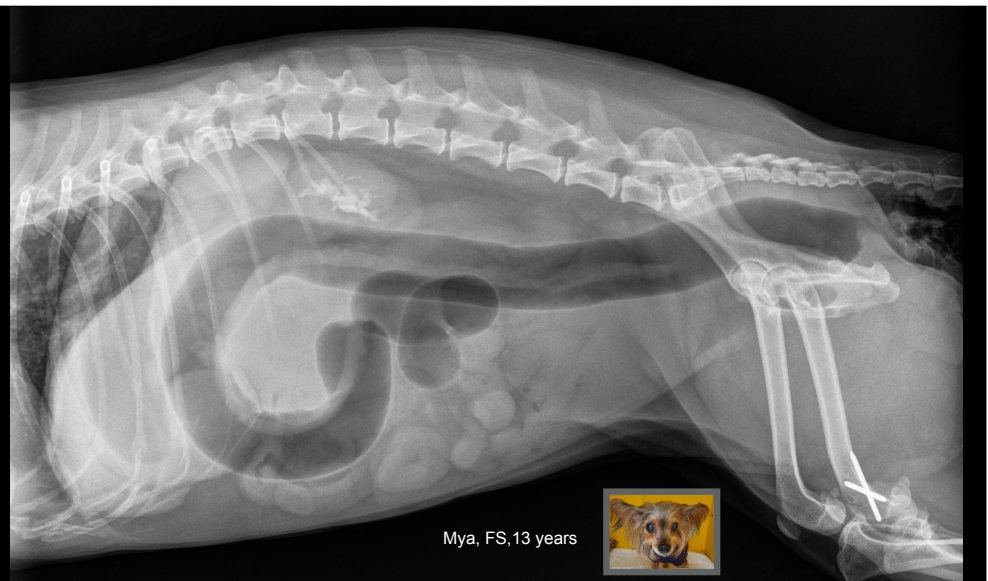
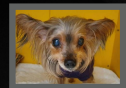


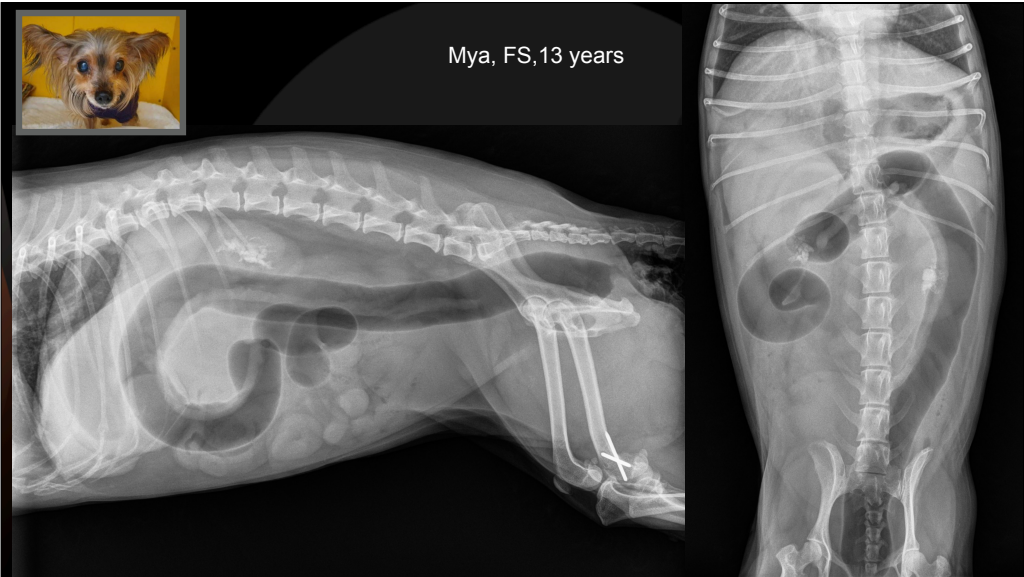
Your evaluation

- How can we improve the recognition of the FB in the colon?
- Pneumocolon:
 - 1-3 ml/kg dog
 - 20 ml cat




Mya, FS, 13 years





Conclusions

- Contrast can still be of some use in modern medicine
- You need to know them to be able to use them



Steve Job tribute to Alan Turing

The slide has a dark background with a large, faint Apple logo in the background. A smaller, white Apple logo is centered in a white circle on the right side. The text is in a clean, sans-serif font.

Thank you



Diagnostic Mindset
www.diagnosticmindset.com

The slide has a solid orange background with a darker orange curved shape on the left side. The text is in a white, sans-serif font. The logo consists of a white circle with a red dot in the center and a series of black dots forming a path that curves around the circle.