

Non è tutto fegato quel che luccica: valutazione ecografica del parenchima epatico con Doppler e radiologia a supporto

Giliola Spattini
DVM, GP cert Cardio, CCRT, PhD, DECVDI



Diagnostic Mindset



Objectives

- Abnormal liver echogenicity is a not common finding
- Severe conditions can be present
- Prompt recognition of these changes can be life-saving for the patient



Deky, Zwergpinscher, MI, 10 years

- Anorexic for the last two days
- Vomiting white foam
- One year ago, bit by a large dog
- Two months ago, severe gastritis resolved



Per gentile Concessione di Davide Cecchieri

Deky, Zwergpinscher, MI, 10 years

- Pain on the cranial abdomen
- Dehydration
- II/VI systolic murmur
 - Responded well to pain killers and hydration
 - Owner refused other diagnostics



Deky, Zwergpinscher, MI, 10 years

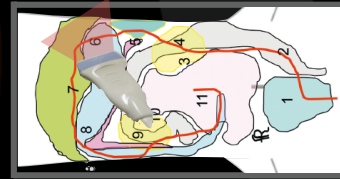
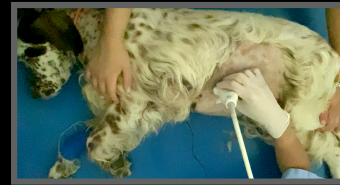The next day

- Collapsed
- Worsened abdominal pain
- Urgent abdominal US performed

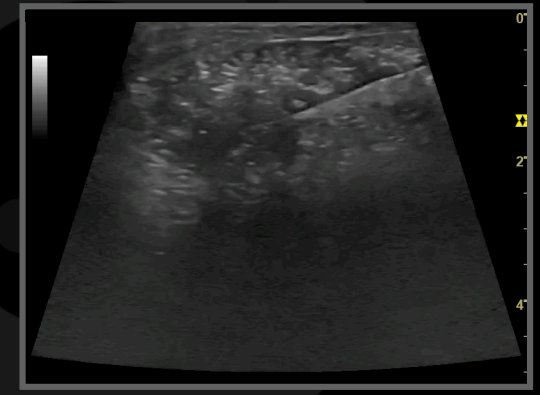


Deky, MI, 10 years

Another patient, to show the position of the probe



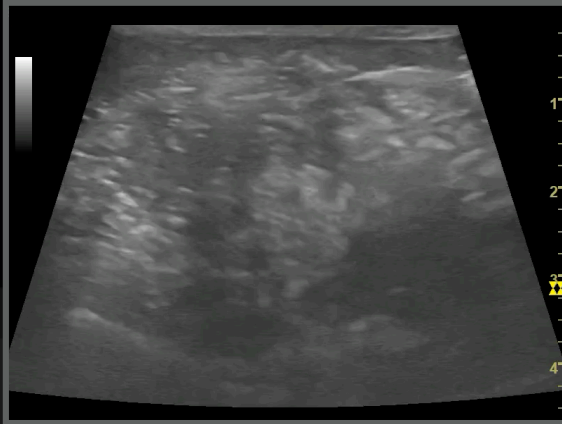
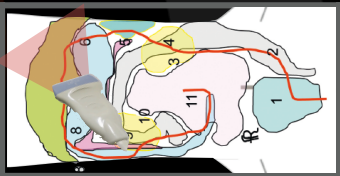
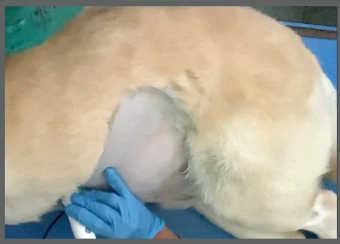
6-7 long



Deky, MI, 10 years

Another patient, to show the position of the probe

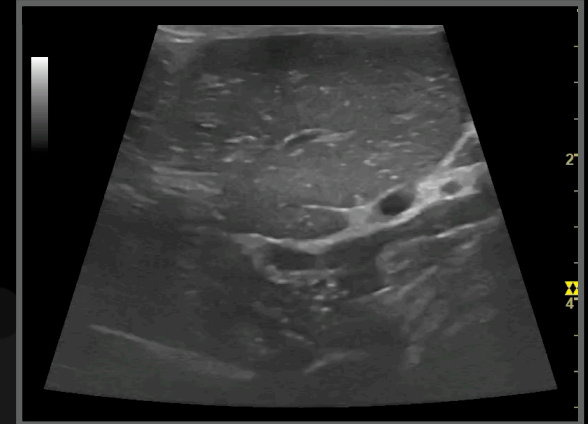
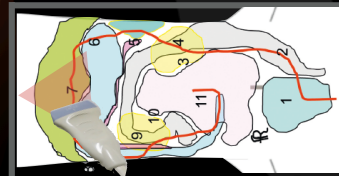
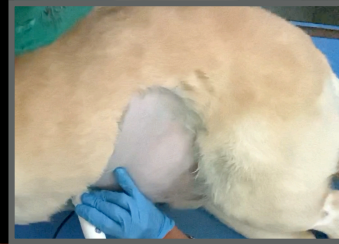
7-6 long



Deky, MI, 10 years

Another patient, to show the position of the probe

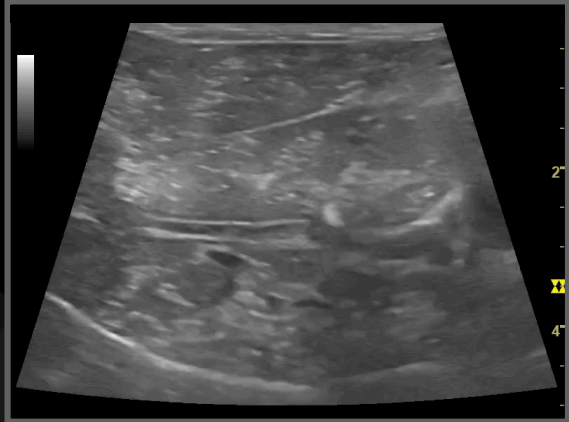
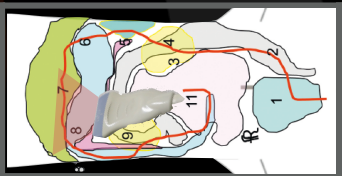
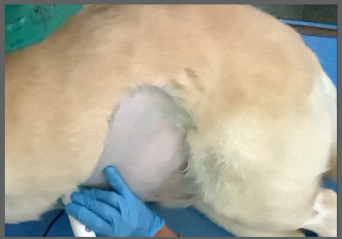7-6 long



Deky, MI, 10 years

Another patient, to show the position of the probe

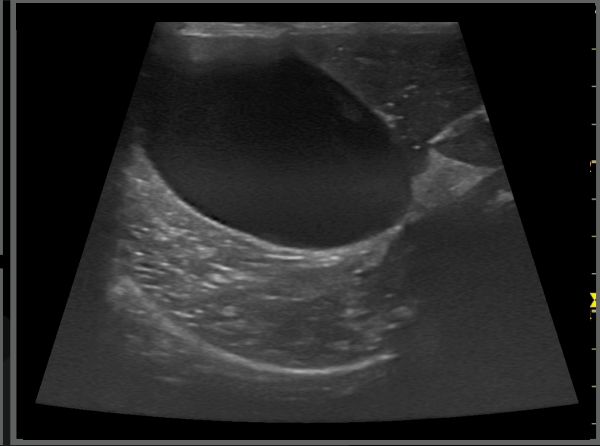
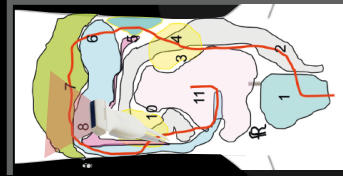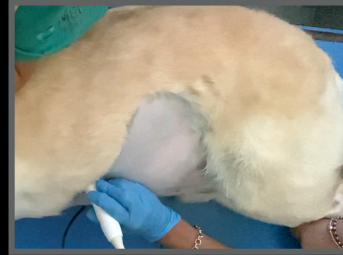
7-8 long



Deky, MI, 10 years

Another patient, to show the position of the probe

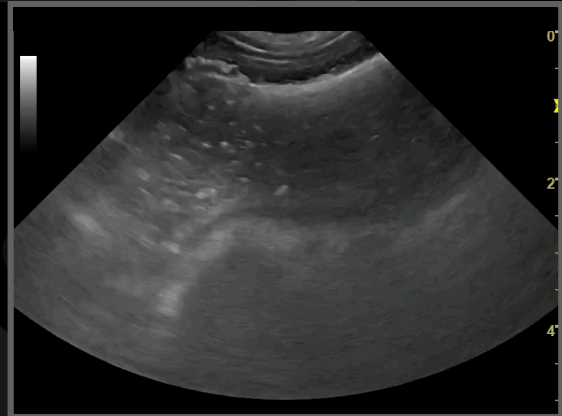
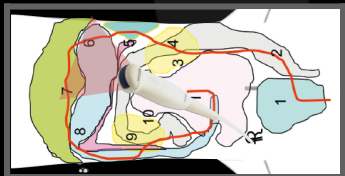
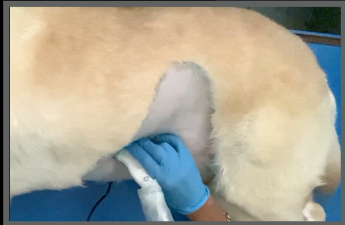7-8 trans



Deky, MI, 10 years

Another patient, to show the position of the probe

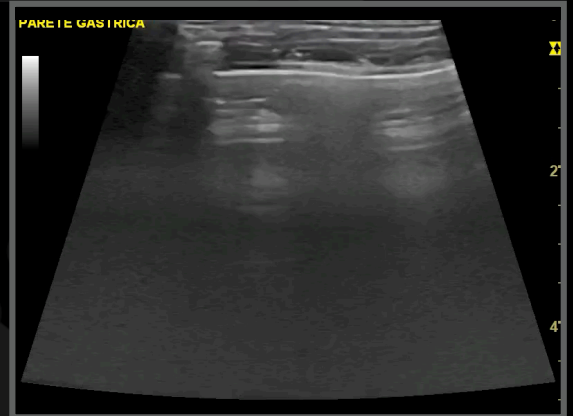
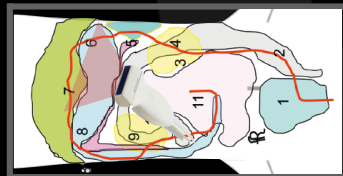
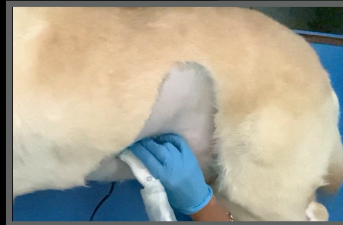7-6 trans



Deky, MI, 10 years

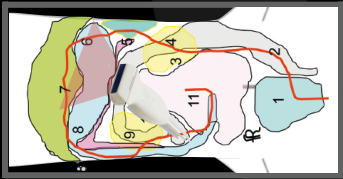
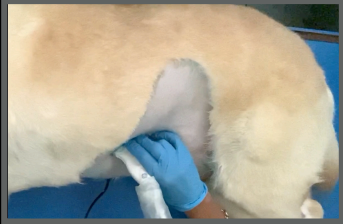Another patient, to show the position of the probe

7-6 trans

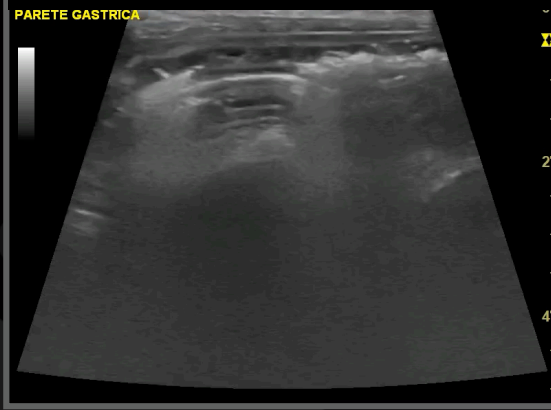


Deky, MI, 10 years

Another patient, to show the position of the probe



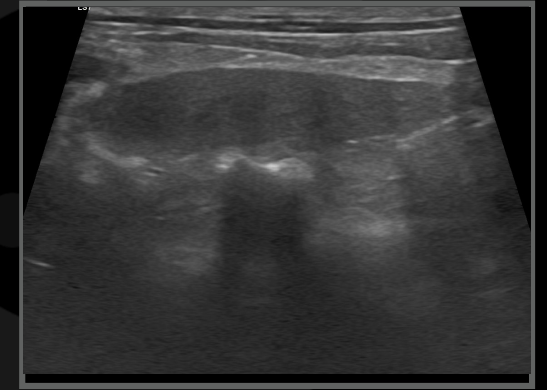
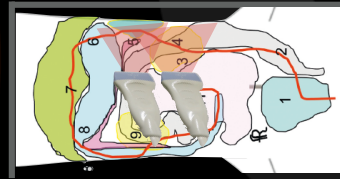
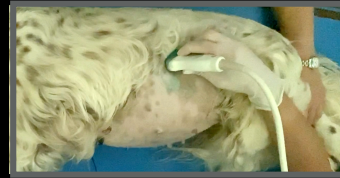PARETE GASTRICA



7 trans

Deky, MI, 10 years

Another patient, to show the position of the probe



5-4 long

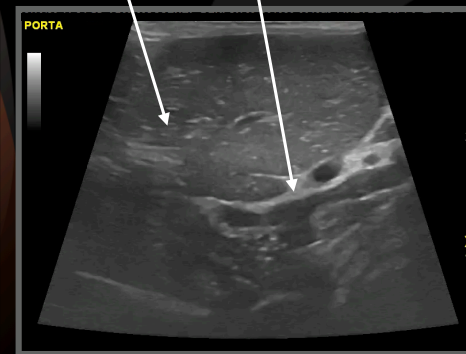
Your evaluation

- Is there hepatitis?
- Is there pneumoperitoneum?
- Is there a gastric ulcer?

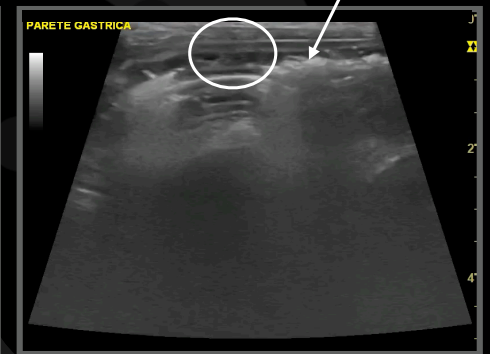


Deky, MI, 10 years

Multiple spots of increased liver opacity
Abnormal portal content



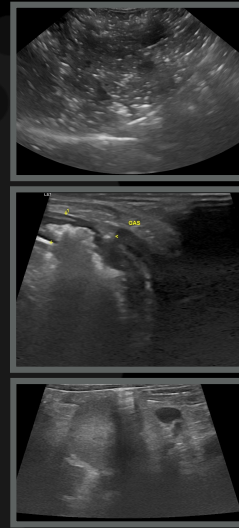
Abnormal gastric wall echogenicity
Reverberation artefact outside stomach



Deky, MI, 10 years

Ultrasonographic diagnoses:

- Hepatopathy
- Gastropathy
- Pneumoperitoneum

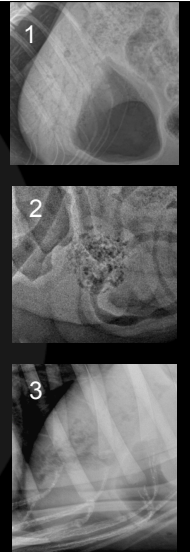

A
Emphysematous
hepatitis

Gas in the
hepatic
parenchyma

B
Gas in the biliary
tract + GB

C
Gas in the portal
system



How to arrive to Conclusions:

- PE examination
- Blood works
- Ultrasonographic findings
- Literature



PubMed®

gas hepatic canine

Search

Advanced Create alert Create RSS

User Guide

Save Email Send to

Sort by: Best match

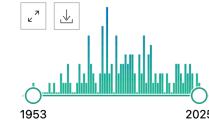
Display options

MY CUSTOM FILTERS

137 results

Page 1 of 14

RESULTS BY YEAR



PUBLICATION DATE

- 1 year
- 5 years
- 10 years
- Custom Range

TEXT AVAILABILITY

- Abstract

High-rise syndrome in cats and dogs.

1 Lefman S, Prittie JE.

Cite J Vet Emerg Crit Care (San Antonio). 2022 Sep;32(5):571-581. doi: 10.1111/vec.13206. Epub 2022 Jun 1.

Share PMID: 35650712 Review.

Animals often fall after slipping from windowsills, engaging in mating behavior, or chasing prey. Cats suffer less severe injuries than dogs due to their "righting reflex" and smaller body mass. Affected animals are younger, and the frequency of falls is higher in warmer m ...

Ultrasonographic differentiation between portal venous and parenchymal gas may be important for the prognosis of canine and feline hepatic emphysema: 37 cases.

2 Manfredi S, Fabbi M, Bonazzi M, Leonardi F, Miduri F, Parrocchini I, Daga E, Gnudi G, Volta A.

Cite Vet Radiol Ultrasound. 2019 Nov;60(6):734-744. doi: 10.1111/vru.12797. Epub 2019 Aug 16. PMID: 31418983

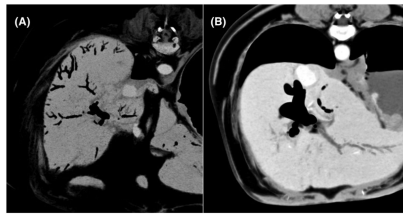
Share A total of 33 dogs and four cats met the inclusion criteria. Among these, 23 cases were classified as hepatic portal venous gas, 10 as parenchymal emphysema, and four as biliary emphysema. ...A significant difference was found between mortality by portal veno ...

Multiphase multidetector-row CT reveals different patterns of hepatic portal venous gas and pneumobilia

Alessia Cordella* | Giovanna Bertolini

Vet Radiol Ultrasound, 2021;62:68-75.

eral location, whereas in PB was characterized by a central location. The aspect of the gas was tubular in case of HPVG and mixed tubular and rounded in PB. An analogous number of animals between the two groups showed comparable amount (mild, moderate, and severe) and distribution (diffuse and focal). Thin-section CT can detect the presence of gas in the liver, and a combination of two-dimensional and thin-slab MinIP can differentiate between HPVG and PB in dogs and cats. **The distinctive features are peripheral versus central location and tubular versus rounded aspect of the gas.**



Ultrasonographic differentiation between portal venous and parenchymal gas may be important for the prognosis of canine and feline hepatic emphysema: 37 cases

Sabrina Manfredi¹ | Martina Fabbi¹ | Mattia Bonazzi^{1,2} | Fabio Leonardi¹ |
Francesca Miduri¹ | Ilaria Parrocchini² | Eleonora Daga¹ | Giacomo Gnudi¹ |
Antonella Volta¹

Vet Radiol Ultrasound, 2019;1-11.

(9), trauma (5), and liver neoplasia (5). An increase in serum liver enzymes was significantly associated with parenchymal emphysema ($P = .03$). Other clinical and laboratory findings were not associated with the type of hepatic emphysema. Hepatic portal venous gas was mostly transient in patients with ultrasonographic follow-up. The overall mortality was 40.5%. **A significant difference was found between mortality by portal venous gas (21.7%) and mortality by parenchymal emphysema (90%)** ($P = .003$). In conclusion, the ultrasonographic differentiation of hepatic

Received: 23 March 2018 | Revised: 7 July 2018 | Accepted: 8 August 2018
DOI: 10.1111/vru.12691

ORIGINAL INVESTIGATION

Canine and feline emphysematous gastritis may be differentiated from gastric emphysema based on clinical and imaging characteristics: Five cases

Florence Thierry¹ | Marisa F. Ferreira | Gavin K. Paterson | Tiziana Liuti |
Jorge Del-Pozo

Vet Radiol Ultrasound, 2018;1-9.

Evidence of pneumoperitoneum was described in dog 2 and likely resulted from gas diffusion from the gastric wall to the peritoneum. which also appears to be the case in the present study.¹ Intramural gastric gas can diffuse into the gastric vascular supply before being **drained by the portal vascular bed**, which was not clinically significant in dog 3.

Deky, Zwergpinscher, MI, 10 years

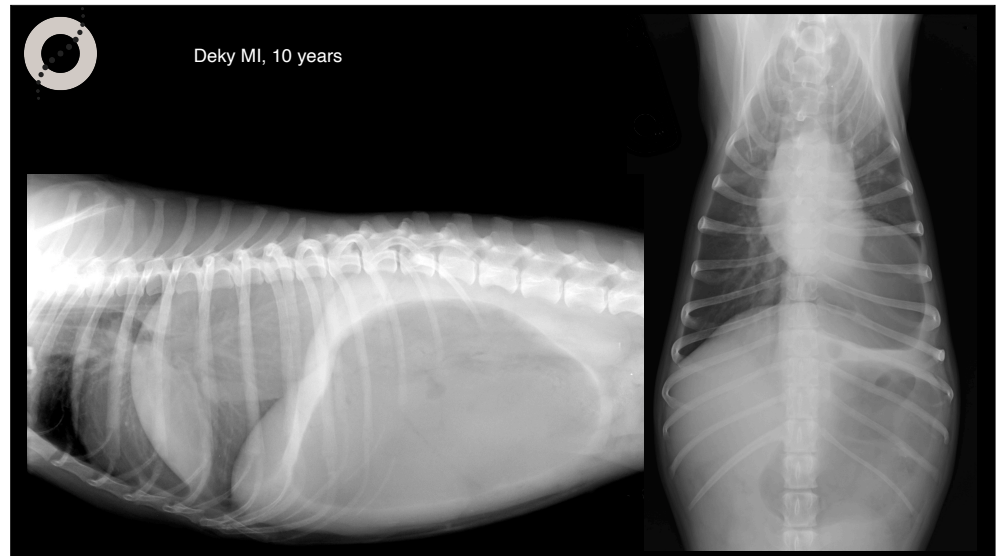
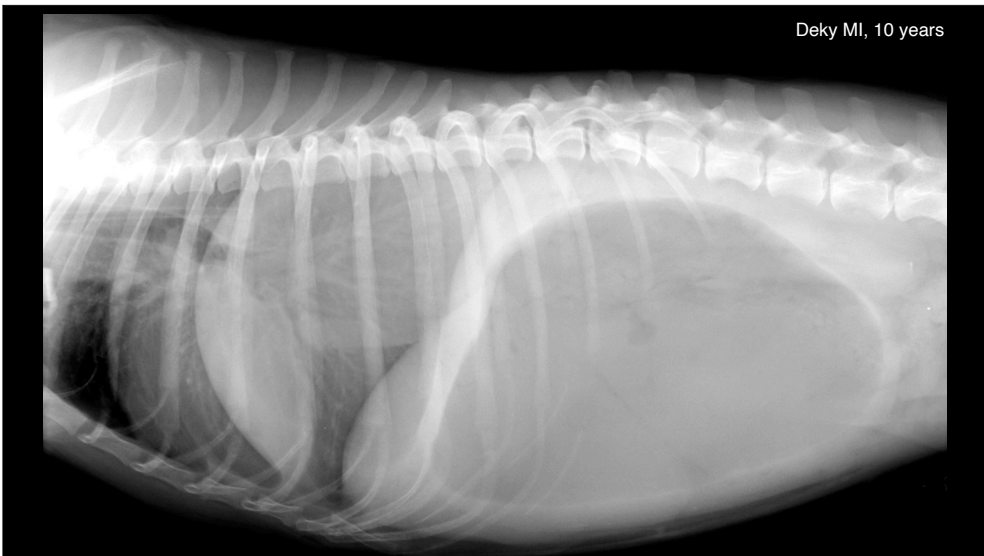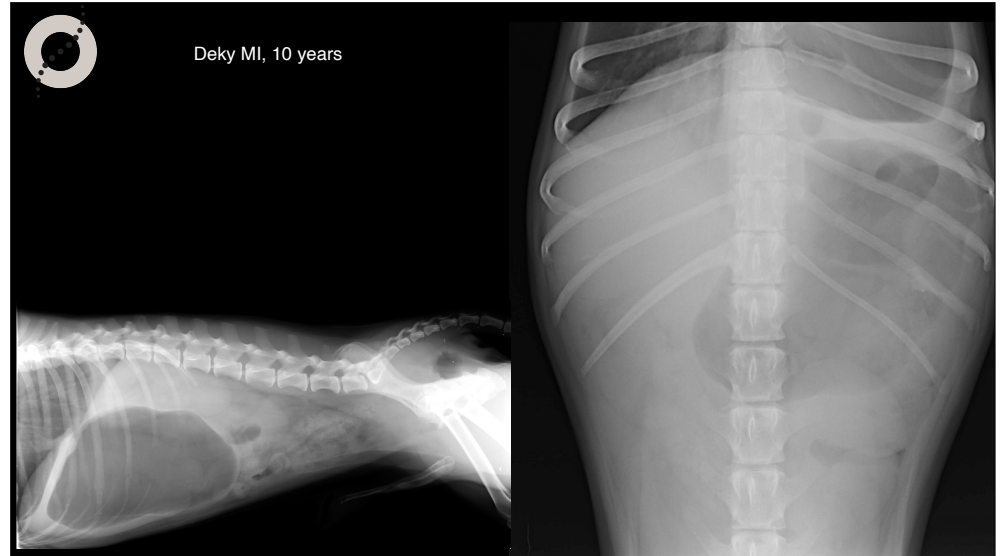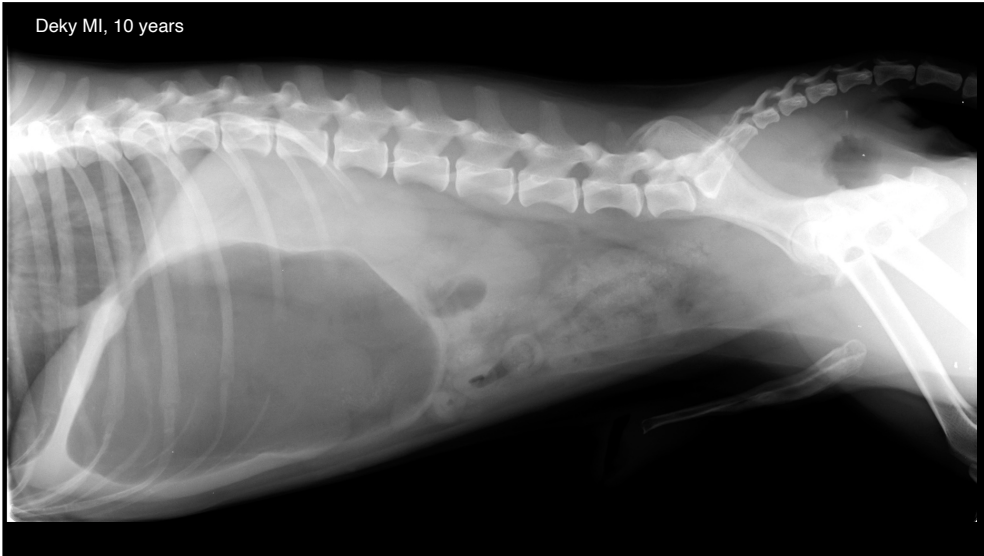Conclusions:

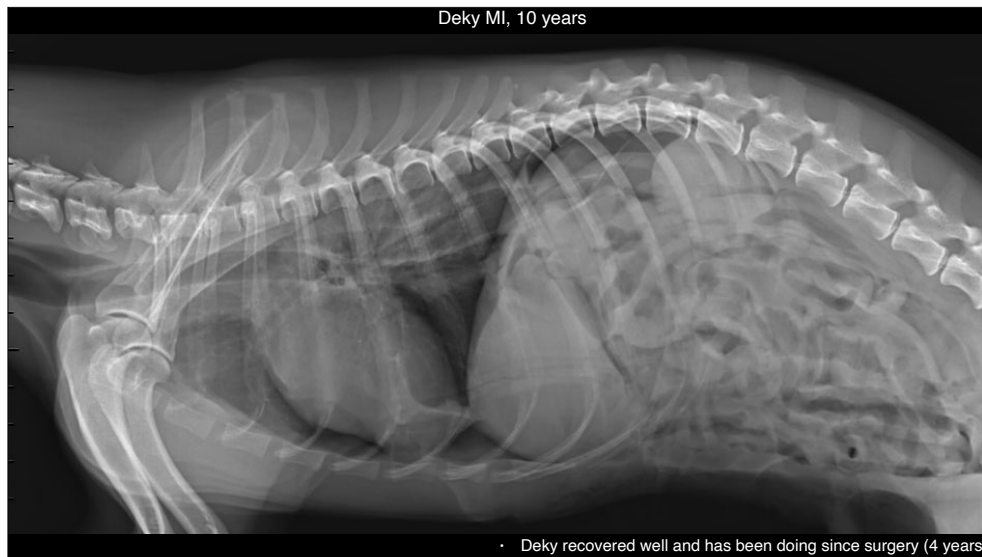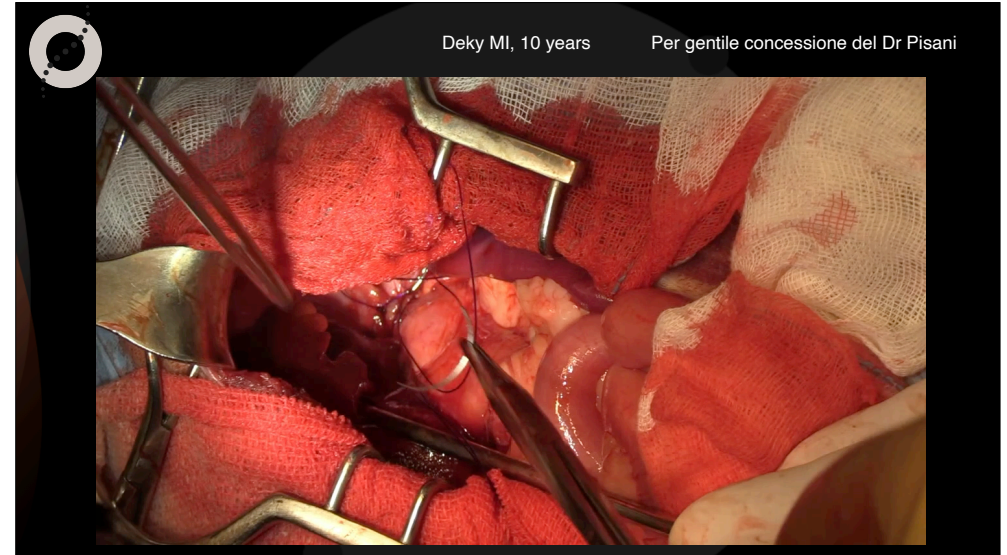
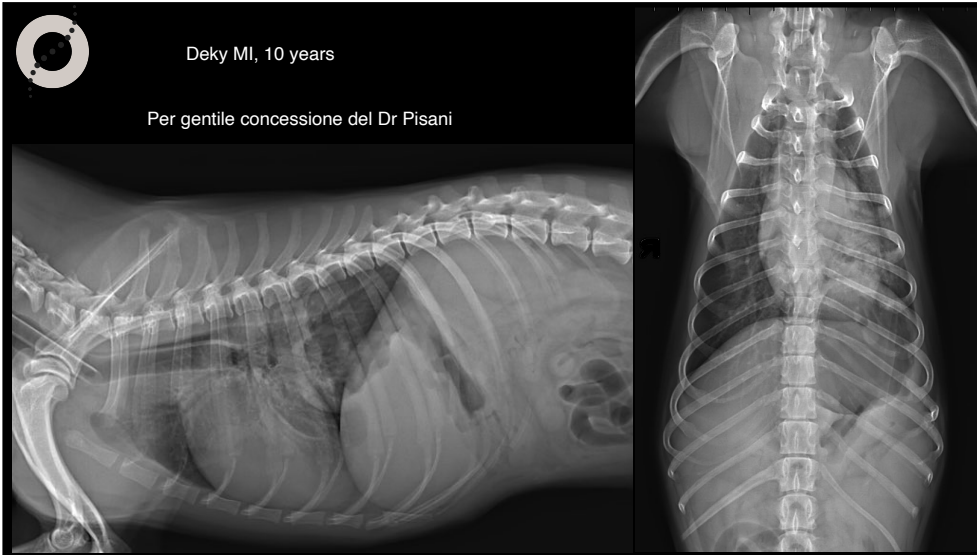
- Gastric pneumatosis
- Portal and hepatic gas infiltration
- Pneumoperitoneum



Next steps:

- Abdominal radiographs





Key points
Portal gas

- Gas in the portal system (check the stomach, intestine, spleen and pancreas)
- Gas in tubular structures at the hepatic parenchyma periphery
- Prognosis dependent on the primary cause but most likely good

Meggy, Bernese Mountain dog, FI, 7 years

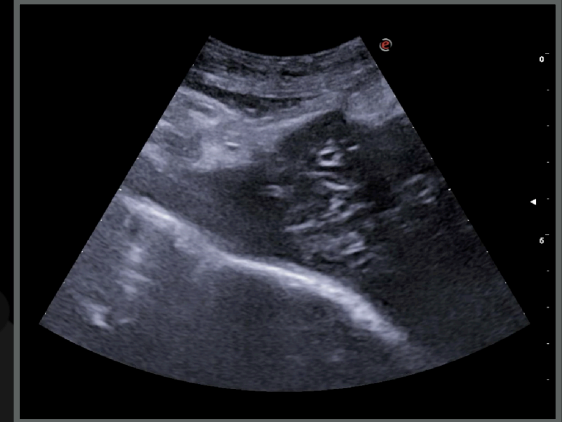
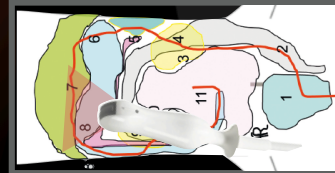
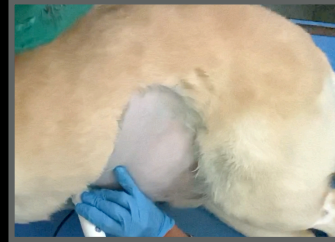- Vomiting for three days
- Fever and severely lethargic
- Jaundice
- Cranial abdominal pain



Per gentile Concessione del Dr Giovanni Baldanzini

Meggy, FI, 7 years

Another patient, to show the position of the probe

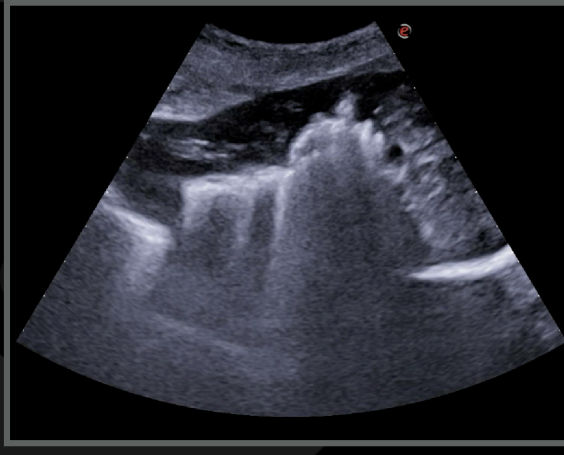
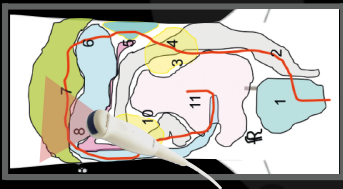
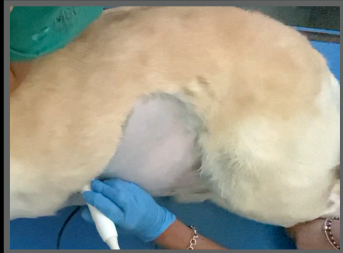

7-8 long

Meggy, FI, 7 years

Another patient, to show the position of the probe

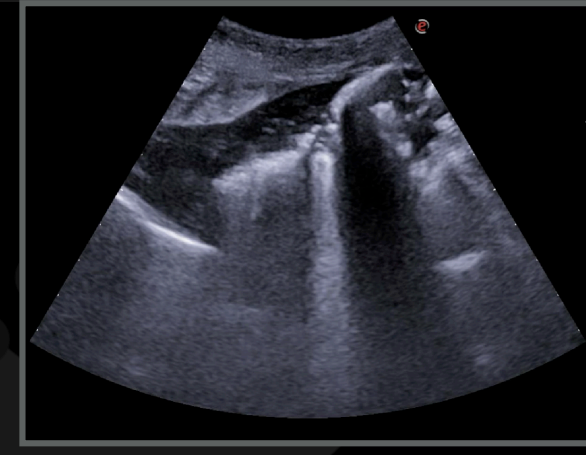
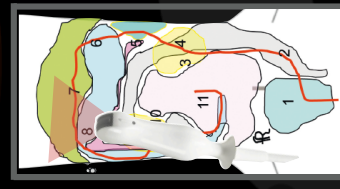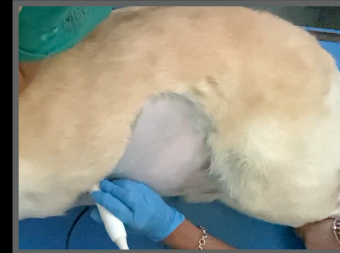
7-8 trans



Meggy, FI, 7 years

Another patient, to show the position of the probe

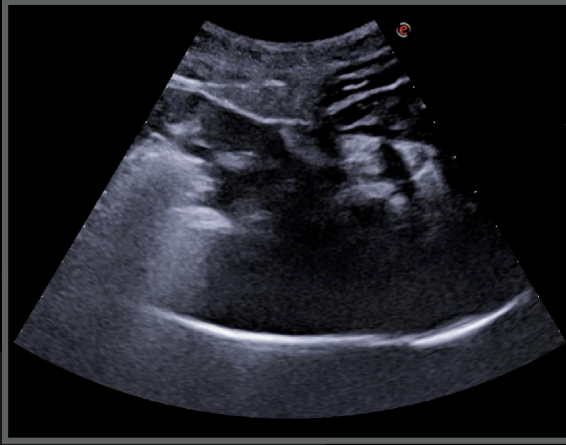
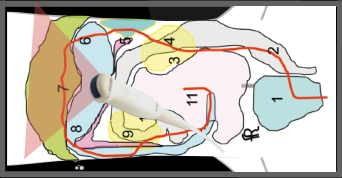
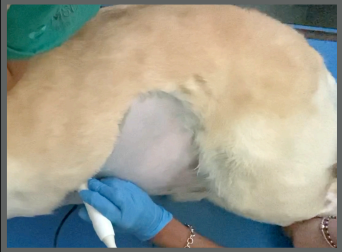
7-8 trans



Meggy, FI, 7 years

Another patient, to show the position of the probe

8-7-6 trans



Meggy, Bernese Mountain dog, FI, 7 years

Ultrasonographic diagnoses:

- Hepatopathy

Conclusions:

- Suspected emphysematous cholecystitis

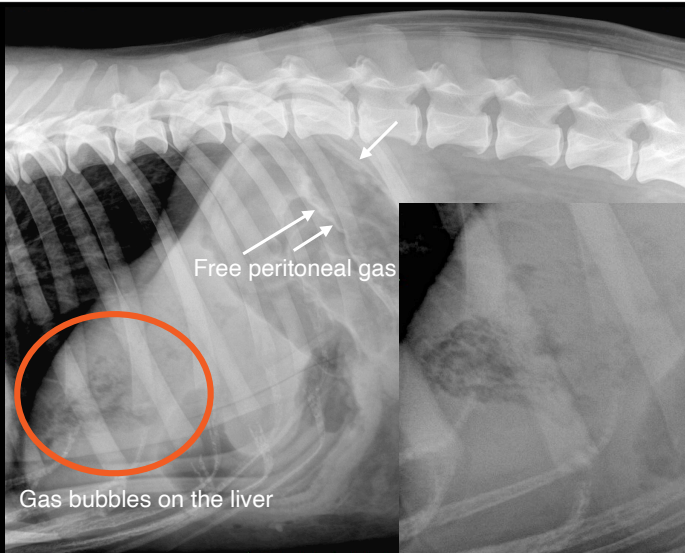

What Is Your Diagnosis?

Andrew Lindau, DVM from the Animal Specialty Group Incorporated, 441 Colorado Blvd, Los Angeles, CA 90010
JAVMA, Vol 226, No. 10, May 15, 2005
Clinical signs of emphysematous cholecystitis include vomiting, lethargy, inappetence or anorexia, signs of abdominal pain, and fever.^{1,2} Causes of emphysematous cholecystitis include gallstones, incompetent sphincter of the gallbladder duct, or occlusion of the cystic artery.^{3,4} Anaerobic organisms may enter the gallbladder via reflux from the intestine. Gas-forming organisms time.^{5,6} Prognosis is usually poor without early surgical intervention.⁷ Age, condition of the animal before surgery, and duration from examination to surgery directly influence survival.^{4,5}

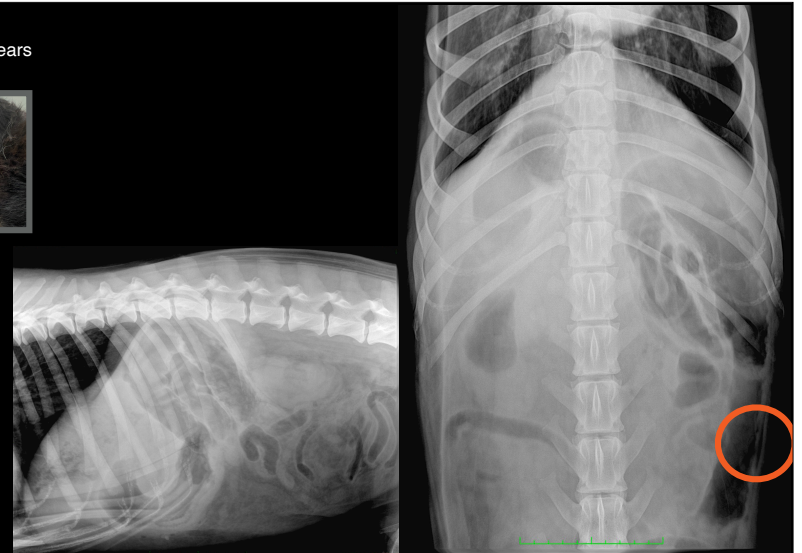

- The patient died nearly immediately

Meggy, FS, 7 years

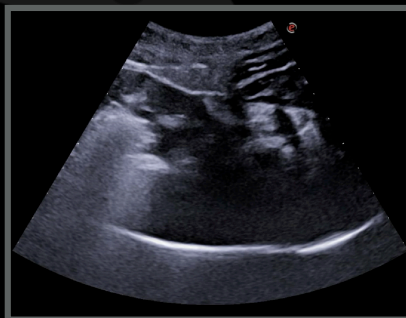


Meggy, FS, 7 years



Key points Emphysematous cholecystitis and pneumobilia

- Gas in the biliary system and GB
- Gas in rounded pocket relatively centrally located
- Prognosis poor



Dea, Mongrel, FS, 12 years

- Abdominal and back pain
- Hyperthermia
- Weakness




Dea, Mongrel, FS, 12 years



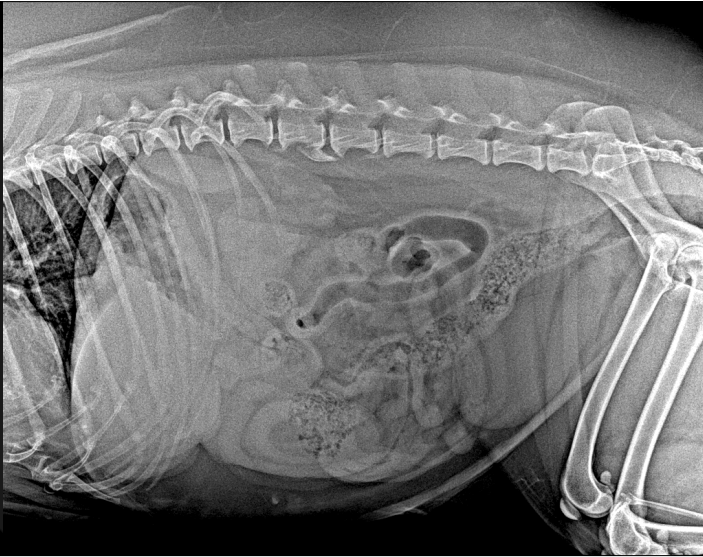

RBC (milioni /µL):	6.55	5.70	8.56	Acantociti:		Elipociti:	
HGB (g/dL):	15.2	14.1	21.2	Anisocitosi:	+	Ipcromia:	
HCT (%):	43.4	39.0	59.2	Agglutinazione:		Macroci:	
MCV (fL):	66.3	63.1	72.6	Codociti:	+	Microci:	
MCH (pg):	23.2	21.8	25.4	Cheratociti:		Parassiti eritrocitari:	
MCHC (g/dL):	35.0	33.3	36.8	Cnizociti:		Policromasia:	
MCHC/CHCM:		34.3	37.8	Corpi di Heinz:		Punteggiature basofile:	
CH (pg):		0.94	1.01	Corpi di Howell-Jolly:		Rouleaux:	
CHDW (pg):		22.0	26.0	Cristalli di Hb:		Schistociti:	
RDW (%):	13.7	2.72	3.34	Dacriociti:		Selenociti:	
HDW (g/dL):		11.6	14.7	Drepanociti:		Sferociti:	
NRBC/100 WBC:	0	1.63	2.22	Eccentricociti:		Stomatociti:	
		0	0	Echinociti:		Torociti:	
Varie RBC:							
WBC (x 1000 /µL):	6.6	5.45	12.98	Linfociti attivati:			
Conta corr. WBC (x 1000 /µL):		5.45	12.98	Linfociti atipici:			
Mielociti (/µL):	0	0	0	Neutrofili tossici:			
Metamielociti (/µL):	0	0	0	Corpi di Doehle:			
Neutrofili banda (/µL):	462	0	286	Schiuosità citopl:			
Neutrofili segmentati (/µL):	5742	3555	9314	Vacuolizzazione citopl:			
Linfociti (/µL):	198	1169	3810	Basofilia citopl:			
Monociti (/µL):	132	186	798	Granuli tossici:			
Eosinofili (/µL):	66	104	1164	Neutrofili giganti:			
Basofili (/µL):	0	0	106	Macropoliciti:			
Danneggiate (/µL):	0	0	0				
Indifferenziate (/µL):	0	0	0				
Altre (/µL):	0	0	0				
Varie WBC:							
PLT (1000 /µL):	244	176	479	Stima PLT:	ADEG.: <input checked="" type="checkbox"/> INADEG.: <input type="checkbox"/> AUMENT.: <input type="checkbox"/>		
MPV (fL):	9.3	8.9	15.0	Varie:	Plastine attivate: <input type="checkbox"/> Macropiastrine: <input type="checkbox"/>		
PCT (%):	0.226	0.21	0.52		Plastine allungate: <input type="checkbox"/> Inclusi piastrinici: <input type="checkbox"/>		
PDW (%):	18.6	51.8	74.5				

CPK (IU/L):	191	42-155	UIBC (µg/dL):	182-306
AST (IU/L):	71	20-50	TIBC (µg/dL):	318-479
ALT (IU/L):	310	15-50	Saturazione (%):	28.2-56.8
ALP (IU/L):	1465	20-110	Prot. C Reattiva (mg/dL):	0.01
GGT (IU/L):	12.6	1-11		0.01-0.22
Colinesterasi (IU/L):		3347-7074	Lipasi (dggr) (UI/L):	46
Bilirubina Totale (mg/dL):	0.32	0.15-0.4		
Proteine Totali (g/dL):	6.6	5.5-7.5		
Albumine (g/dL):	3.4	2.7-3.6		
Globuline (g/dL):	3.2	2.6-3.9		
Rapporto A/G:	1.06	0.7-1.2		
Colesterolo (mg/dL):	247	150-350		
Trigliceridi (mg/dL):	144	30-110		
AMILASI (IU/L):	755	300-1800		
Urea (mg/dL):	42	18-45		
Creatinina (mg/dL):	0.76	0.75-1.3		
Glucosio (mg/dL):	104	60-100		
Calcio (mg/dL):	10.5	8.2-12		
Fosforo (mg/dL):	1.9	2.1-6.2		
Magnesio (mg/dL):		0.67-0.94		
Sodio (mEq/L):	149	143-151		
Potassio (mEq/L):	4.3	3.9-5.1		
Rapporto Na/K:	34.7	28.5-37.4		
Cloro (mEq/L):	113	109-118		
Cloro corretto (mEq/L):	110.7	109.1-115.9		
HCO-3 (mmol/L):		18.4-24.8		
Divario Anionico:		13.1-19.4		
Osmol. sier. calc. (mOsm):	293	277-291		
Ferro totale (µg/dL):	47	100-200		

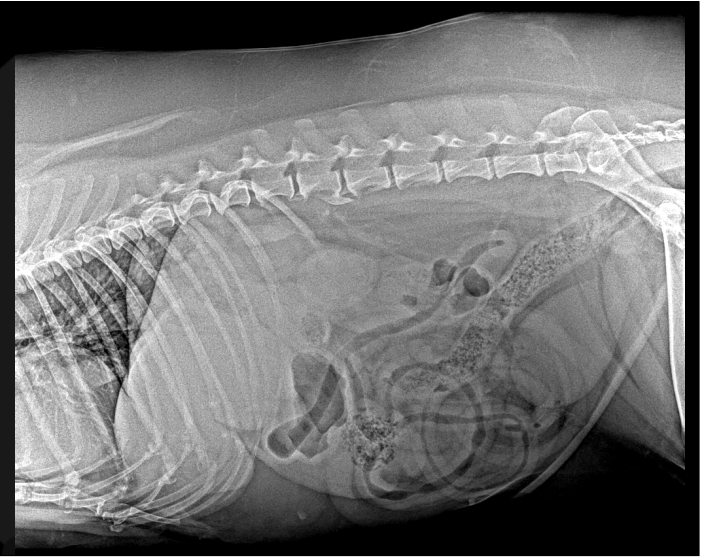
Dea, Mongrel, FS, 12 years



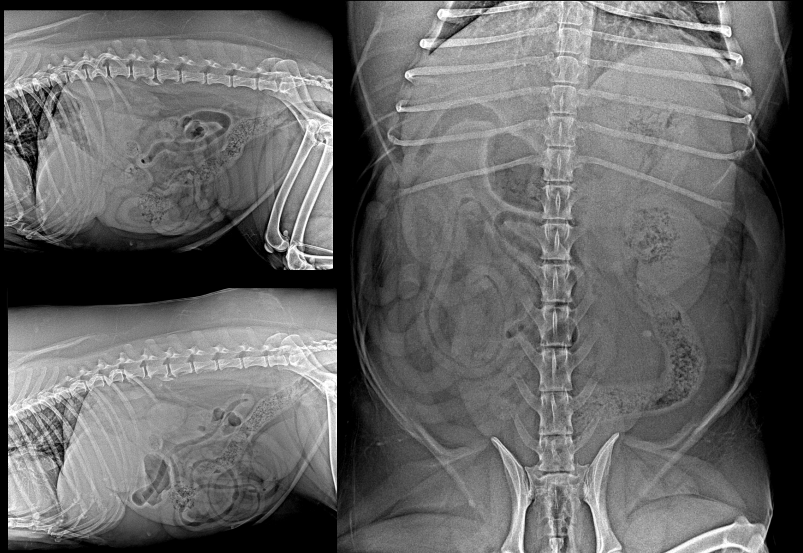
Dea, Mongrel,
FS, 12 years



Dea, Mongrel,
FS, 12 years



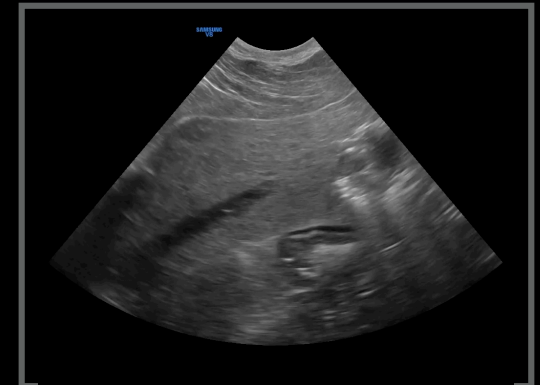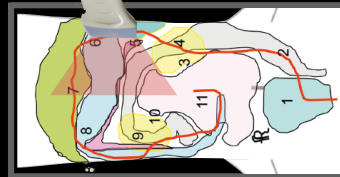
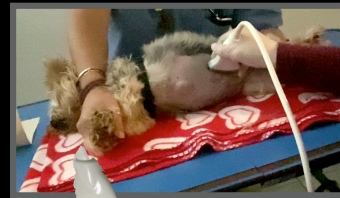Dea, Mongrel,
FS, 12 years



Dea, FS, 12 years

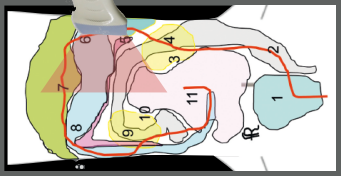


Probe position in another patient

6-7



Dea, FS, 12 years

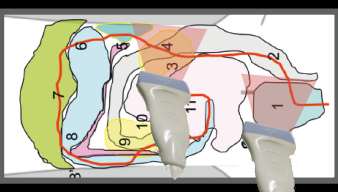

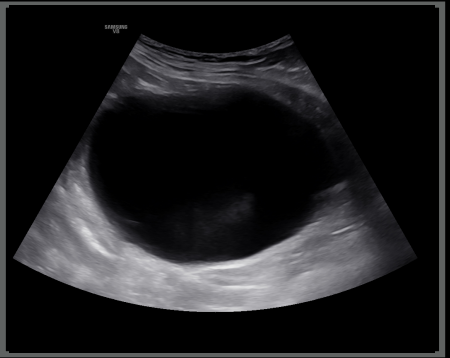
Probe position in another patient 6-7



This slide shows a side view of a dog's head with an ultrasound probe placed on the side of the skull. Below the photo is a diagram of a dog's head with numbered regions (1-11) and colored areas (green, yellow, red, blue). To the right is a B-mode ultrasound image showing a dark, anechoic region within the brain tissue.

Dea, FS, 12 years

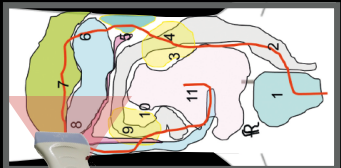

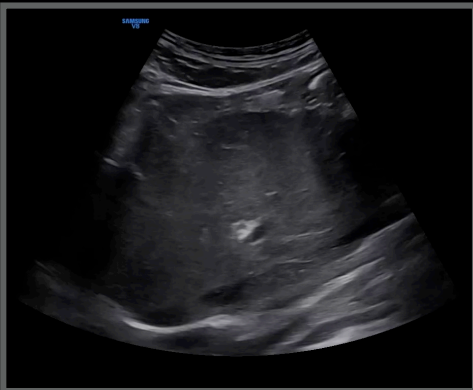
Probe position in another patient 3-4



This slide shows a side view of a dog's head with an ultrasound probe placed on the side of the skull. Below the photo is a diagram of a dog's head with numbered regions (1-11) and colored areas (green, yellow, red, blue). To the right is a B-mode ultrasound image showing a dark, anechoic region within the brain tissue.

Dea, FS, 12 years

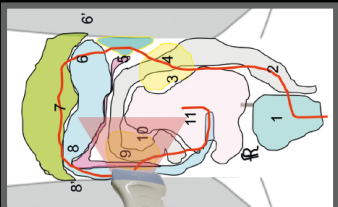

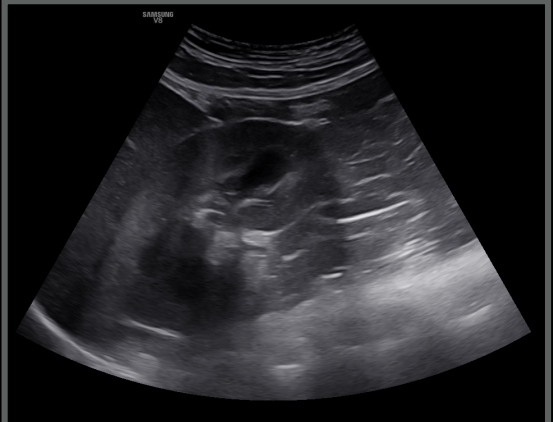
Probe position in another patient 7-8



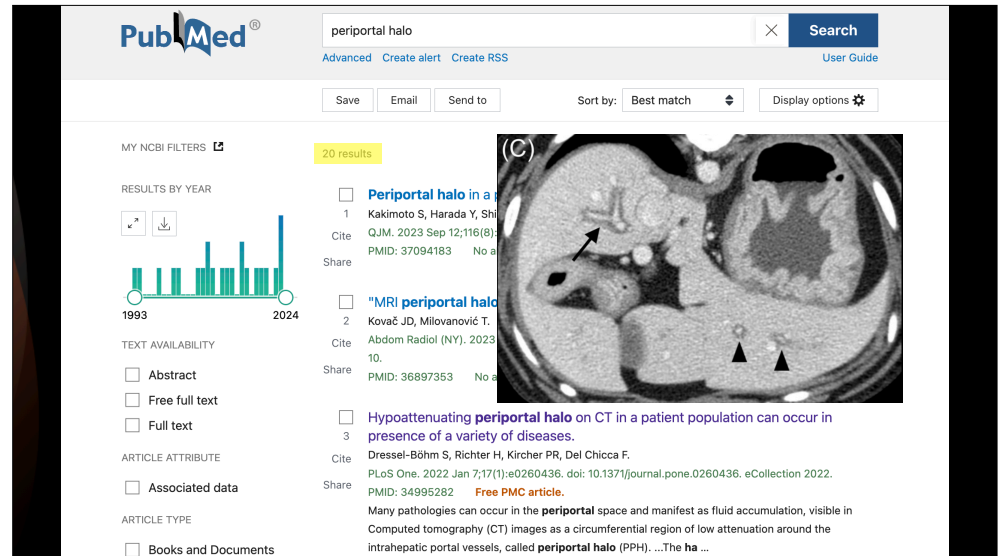
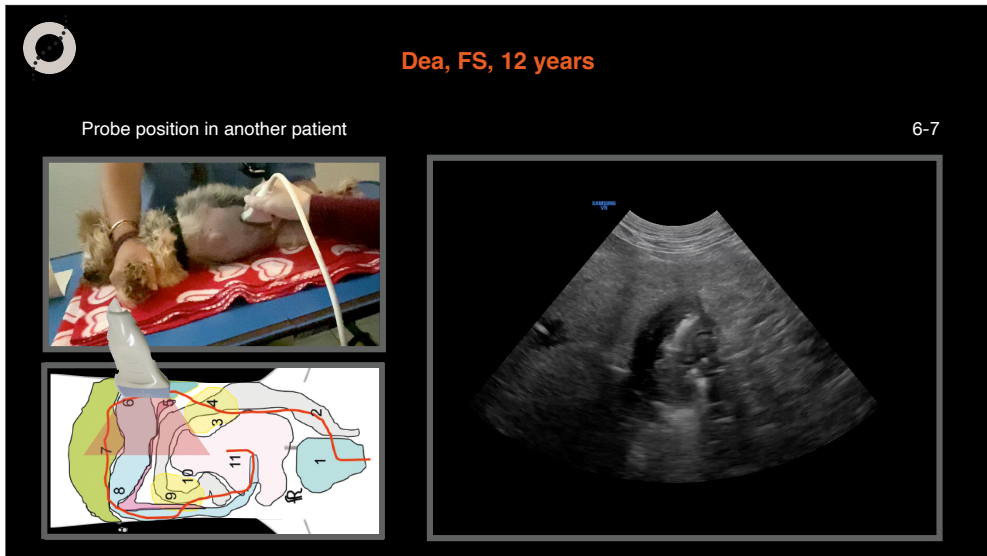
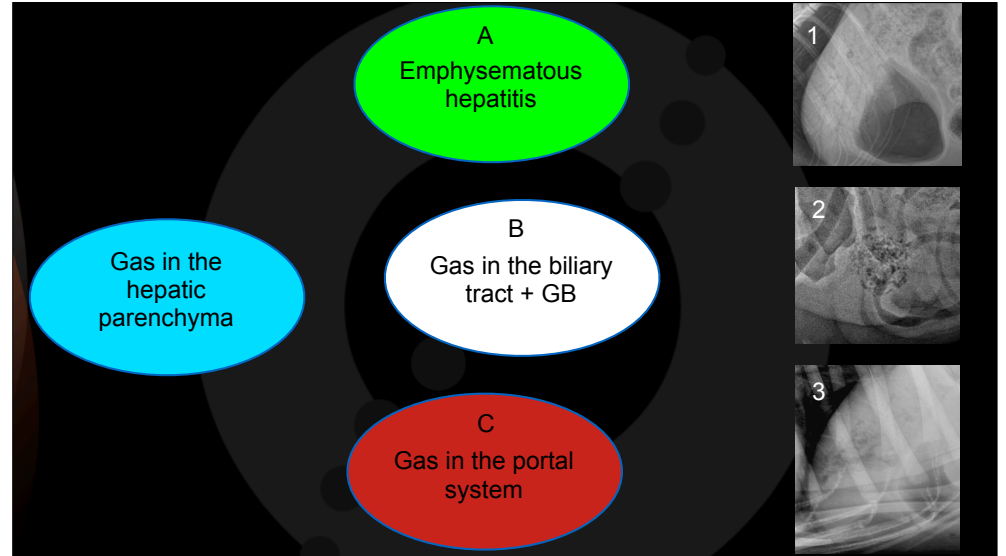
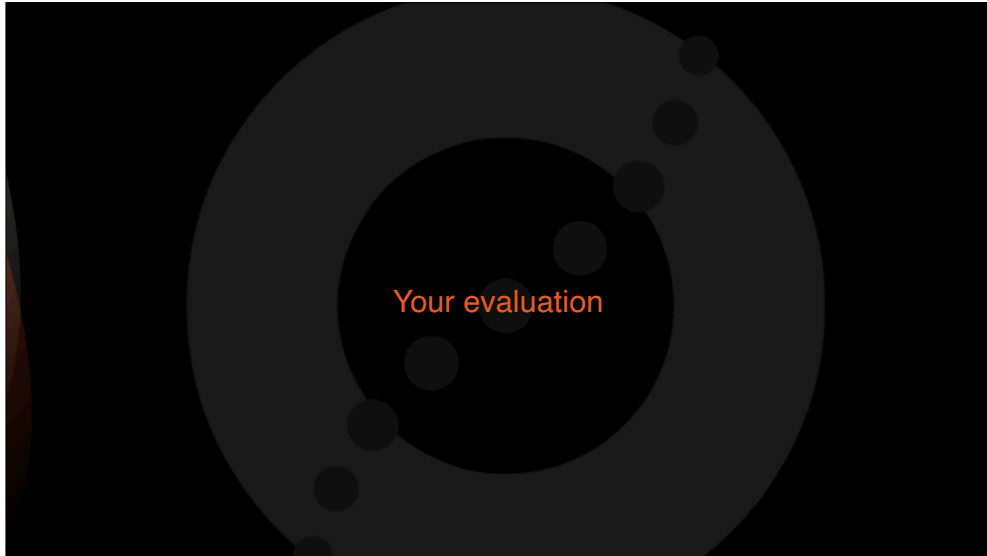
This slide shows a side view of a dog's head with an ultrasound probe placed on the side of the skull. Below the photo is a diagram of a dog's head with numbered regions (1-11) and colored areas (green, yellow, red, blue). To the right is a B-mode ultrasound image showing a dark, anechoic region within the brain tissue.

Dea, FS, 12 years

Probe position in a different patient 9

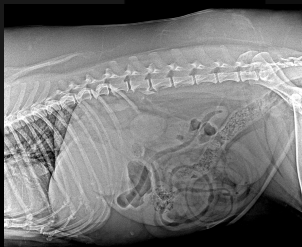
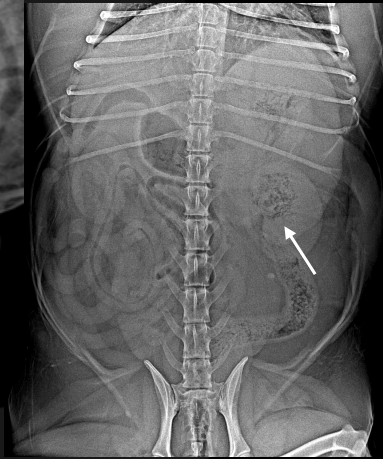
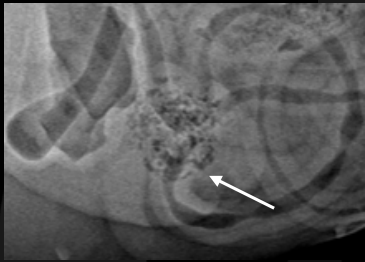
This slide shows a side view of a dog's head with an ultrasound probe placed on the side of the skull. Below the photo is a diagram of a dog's head with numbered regions (1-11) and colored areas (green, yellow, red, blue). To the right is a B-mode ultrasound image showing a dark, anechoic region within the brain tissue.





Dea, Mongrel,
FS, 12 years



Dea, Mongrel, FS, 12 years

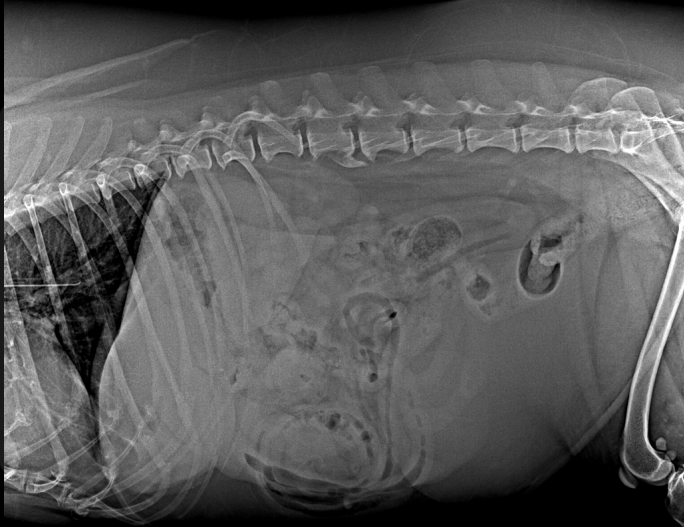Four days later

- Responded well to treatment
- Went home



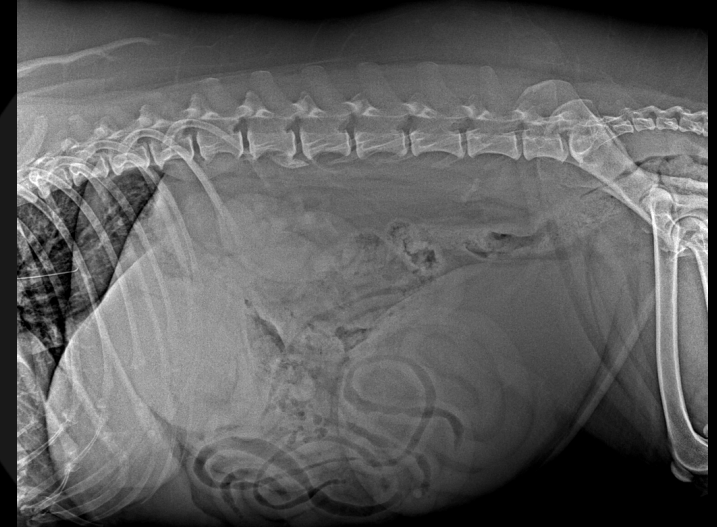
Dea, Mongrel,
FS, 12 years

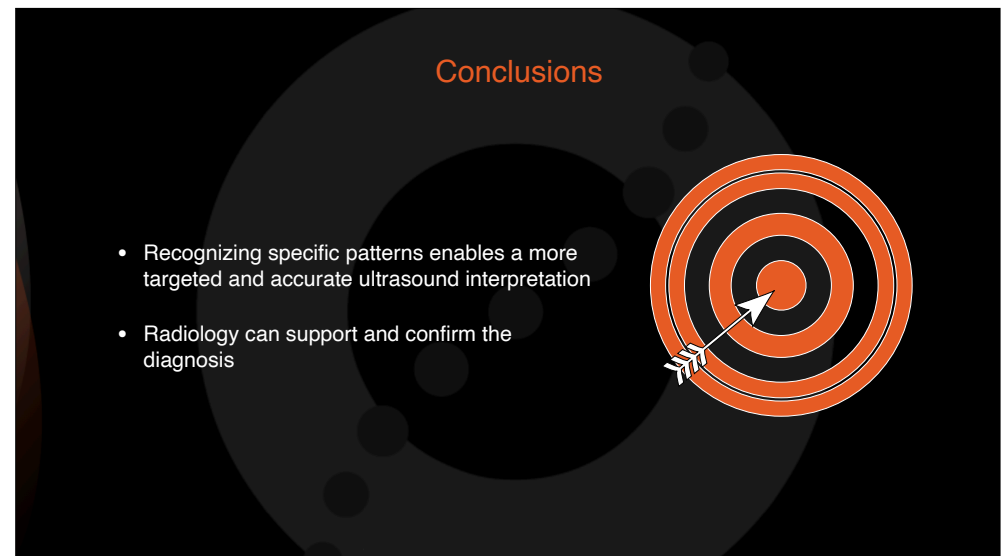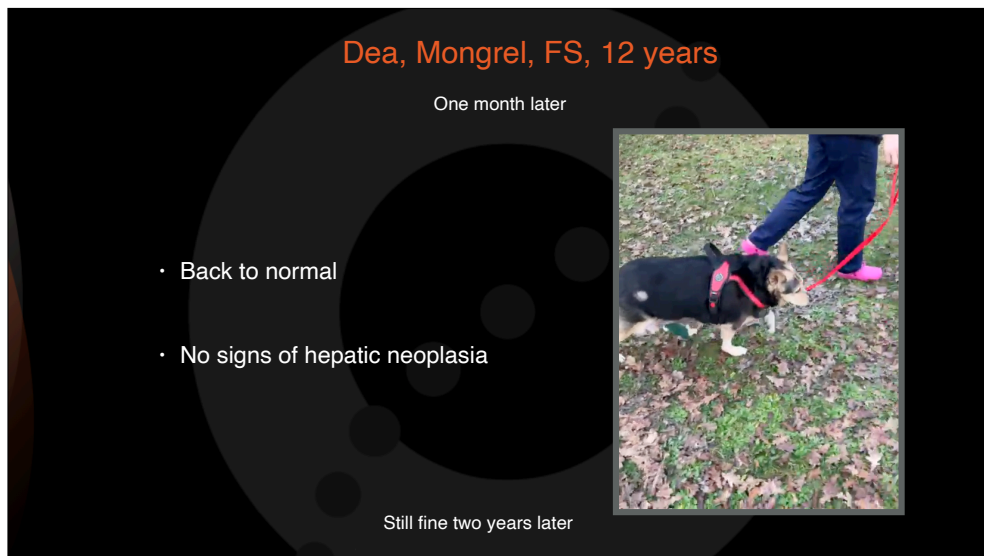
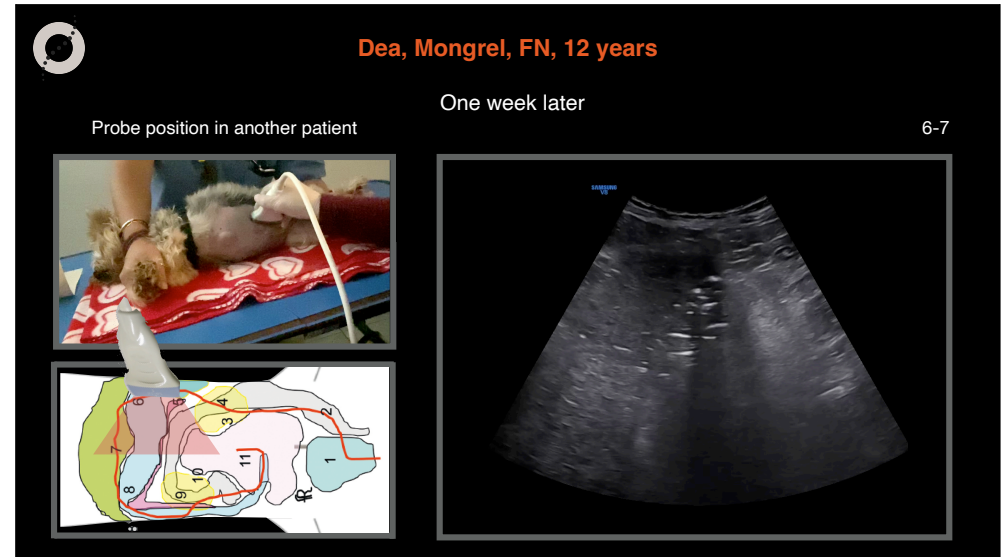
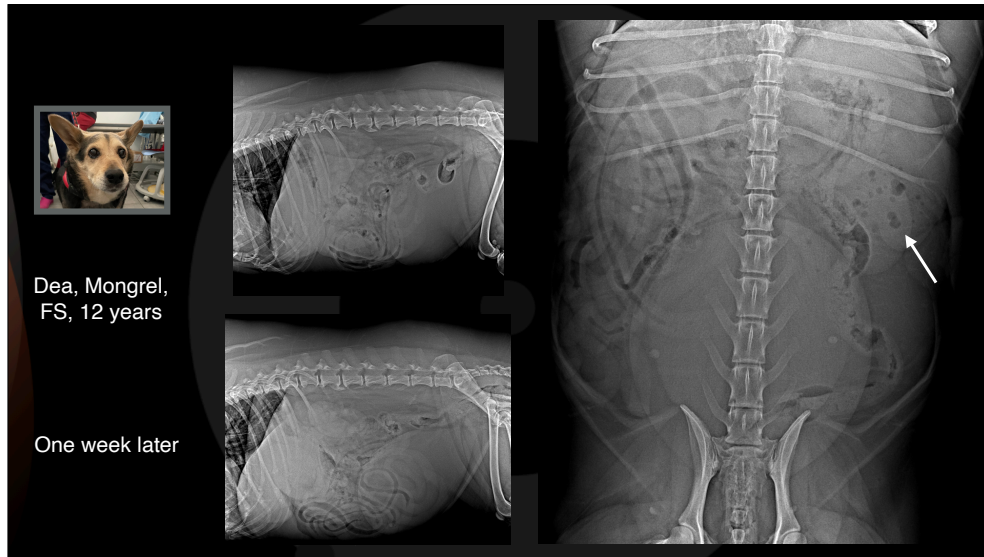
One week later



Dea, Mongrel,
FS, 12 years

One week later





Thank you



Diagnostic Mindset

www.diagnosticmindset.com